



HAL
open science

Manual of poultry diseases

Brugère-Picoux Jeanne, Vaillancourt Jean-Pierre, Shivaprasad H.L., Venne Daniel, Bouzouaia Moncef

► **To cite this version:**

Brugère-Picoux Jeanne, Vaillancourt Jean-Pierre (Dir.). Manual of poultry diseases. AFAS, 2015, 9782908014020. hal-04053935

HAL Id: hal-04053935

<https://enva.hal.science/hal-04053935v1>

Submitted on 28 Apr 2023

HAL is a multi-disciplinary open access archive for the deposit and dissemination of scientific research documents, whether they are published or not. The documents may come from teaching and research institutions in France or abroad, or from public or private research centers.

L'archive ouverte pluridisciplinaire **HAL**, est destinée au dépôt et à la diffusion de documents scientifiques de niveau recherche, publiés ou non, émanant des établissements d'enseignement et de recherche français ou étrangers, des laboratoires publics ou privés.



Distributed under a Creative Commons Attribution - NonCommercial - NoDerivatives 4.0 International License

Jeanne Brugère-Picoux • Jean-Pierre Vaillancourt
HL Shivaprasad • Daniel Venne • Moncef Bouzouaia

Manual of
**POULTRY
DISEASES**





Burrard-Lucas Photography / www.burrard-lucas.com

Fig.1.1: It is considered that chickens originate from India, and that this red jungle fowl is an ancestor to today's modern chicken.

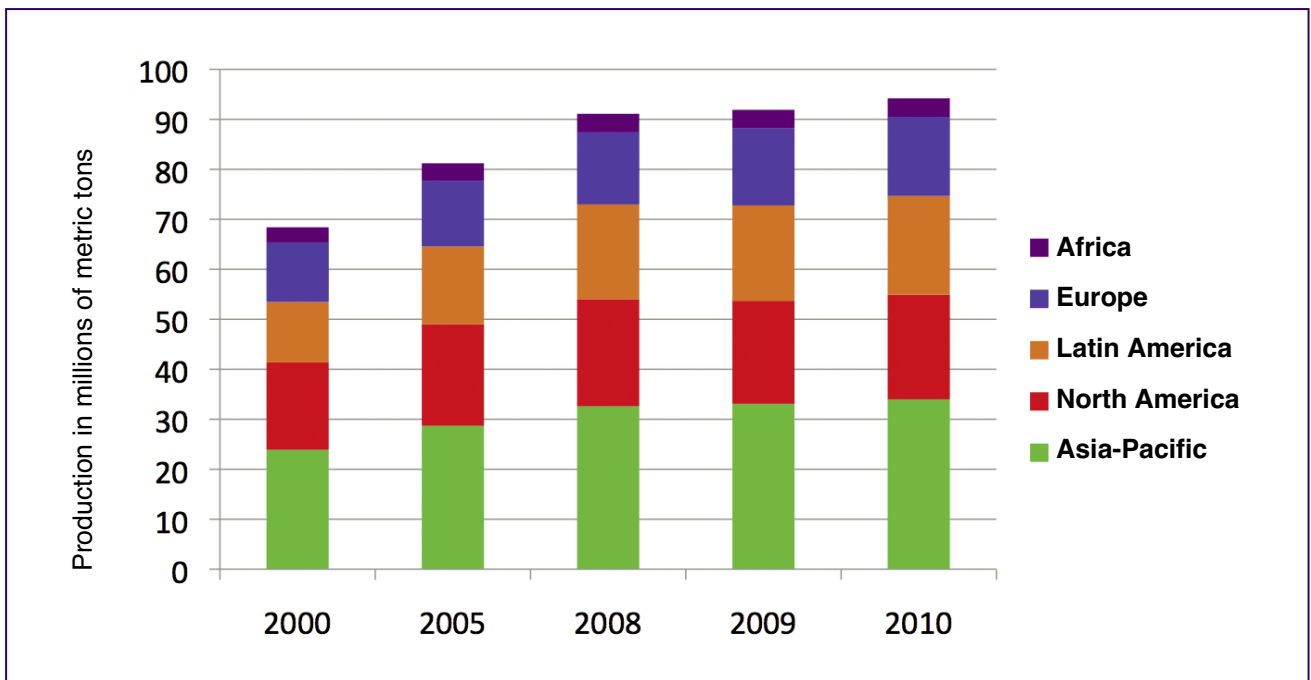


Fig.1.2: Poultry meat production by region of the world over time.

1. POULTRY PRODUCTION IN THE WORLD

INTRODUCTION

It is believed that poultry production started in Asia over 3000 years ago. Although some records suggest that chickens were raised around 3200 BC, archaeological evidence only goes back to about 2000 BC. It is considered that chickens originate from India, and that the red jungle fowl is an ancestor to today's modern chicken. The breeding of chickens in captivity dates back to at least 1400 BC in Egypt. But intensive poultry production only began in the 20th century. Indeed, the past 100 years have seen an impressive growth, chiefly in the production of chickens and eggs, turkeys, ducks, and geese. It is the advent of vaccination for conditions such as Marek's disease, in addition to remarkable improvements in nutrition, genetics, and management, that has allowed the poultry industry to quickly develop since the late 1960s.

By the early 1980s, breeding increased greatly in complexity because of carcass and meat yield requirements and continuing improvement in feed conversion and livability. Selection practices have had to factor in numerous variables, such as breeding value estimation, feed conversion, meat yield and disease resistance. Moreover, unique selection indices or markers have been created, considering production, health and well-being traits. Concerns

over the welfare of birds in developed countries have also resulted in new production standards.

About 75% of poultry production in the world is done in intensive operations using confinement systems. Difficulties in maintaining a cold chain, a traditional consumer preference for live poultry, and the lack of organization of industries are limiting efficiency and profitability in many developing countries.

POULTRY MEAT PRODUCTION

About 281.5 million metric tons of all meats were produced worldwide in 2009. Estimates for poultry production vary between 92 and 95 million tons. This makes poultry the second most important meat after pork (103.6 million tons) and ahead of beef (64.7 million tons).

Although global poultry production and consumption have grown about 4% a year over the past 10 years, European poultry production and consumption have increased at a slower rate. Asia and the Americas are the main poultry meat producing regions in the world. Recent growth is also the largest in these two regions. Indeed, about 55% of the growth between 2000 and 2010 came from Brazil (21%), China (19%) and the USA (14%).

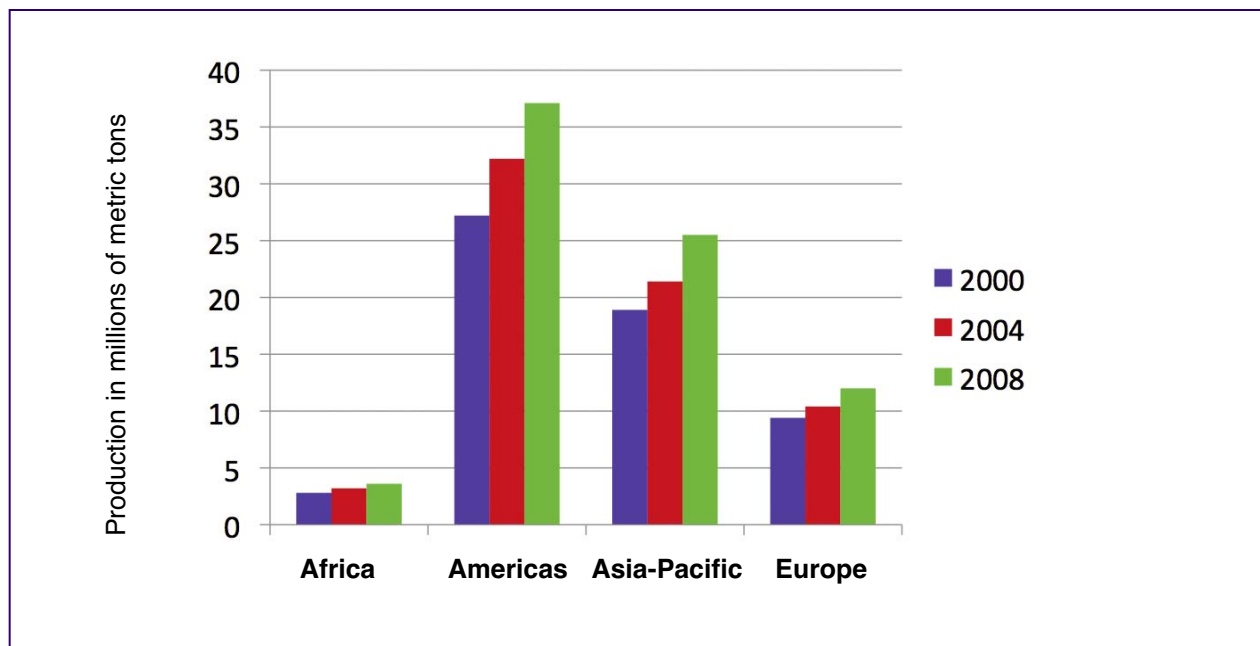


Fig.1.3: Recent evolution of chicken meat production by region and year of production.

Chicken production

Chicken production is, by far, the largest source of poultry meat in the world. It is mainly concentrated in North America, Latin America, and Asia. In the Americas, the fastest growth over the past two decades has come from Brazil. Other Latin countries, such as Peru, are also expanding quickly. Brazil and the United States are the two main exporting countries. Equally impressive is the recent growth of the poultry industry in Asia, independently of the fact that highly pathogenic avian influenza H5N1 has been an issue in this region since the 1990s. Progression in Europe is slower. Although production in Africa is increasing, the

size of the industry and its growth are in no relation with the size and growth of its human population.

Turkey production

Overall, turkey meat production is about 15 times smaller than chicken production. Well over 90% of it is concentrated in the Americas and Europe. The United States of America is by far the largest producer. Although US producers have been plagued by serious enteric conditions, such as the poulter enteritis complex (PEC), production has significantly increased since 2000. For the past few years, gangrenous dermatitis caused by clostridia

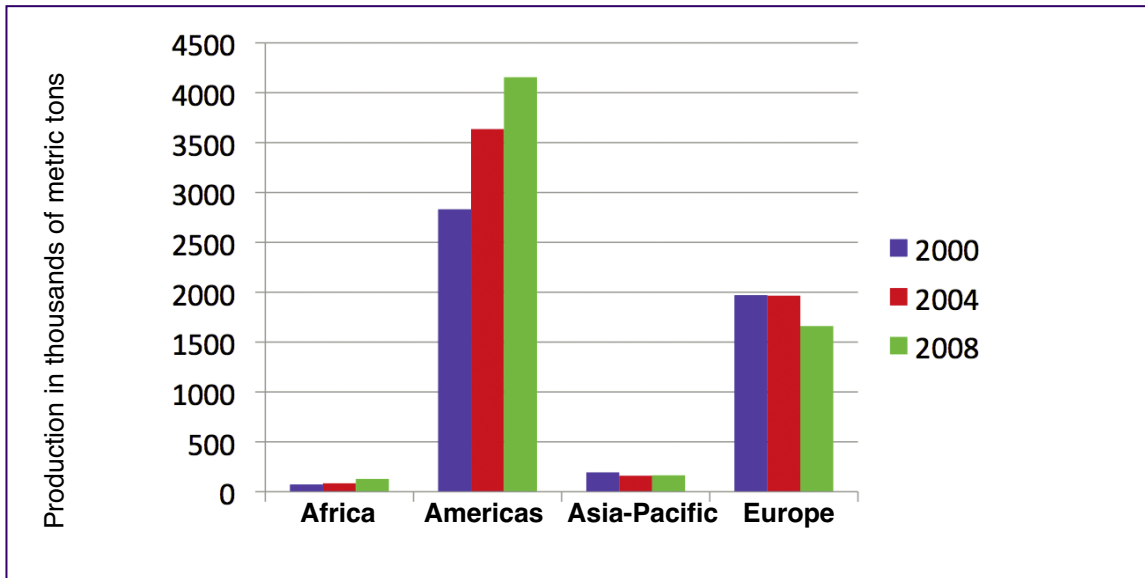


Fig.1.4: Recent evolution of turkey meat production by region and year of production.

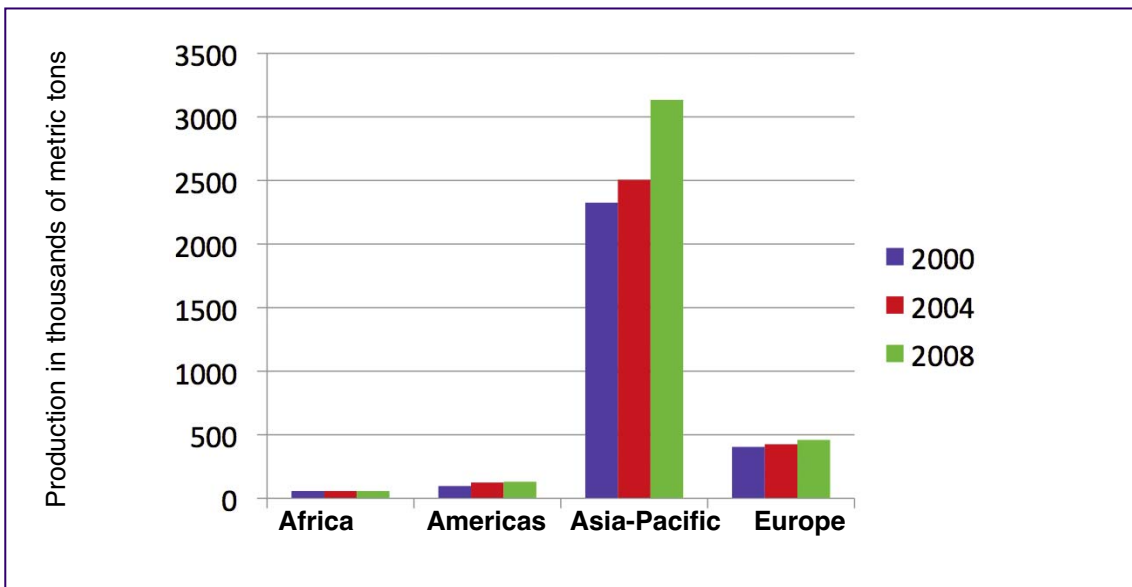


Fig.1.5: Recent evolution of duck meat production by region and year of production.

has been one of the most significant challenges for this industry. In Europe, production has decreased since 2004. The French industry, in particular, has been affected by enteric diseases, including PEC and histomoniasis, and clostridial conditions, such as botulism.

Duck and Goose productions

The duck and goose industries represent about 7.5% of the world poultry meat production. Asia is by far the largest duck producing region of the world. It is also where the growth has been most important. France, Thailand, Taiwan, the Ukraine and Vietnam are the main duck producing countries after China. Although all regions of the world have recorded growth over the past few years, it is clear that this industry is dominated by Asia, which has increased its share of the world market from 80.3% in 2000 to 83.5% in 2009. An average growth of 3.8% per year has been recorded during this period.

The production of ducks and geese can contribute to improving human nutrition standards, particularly in Asia, since feed ingredients for these birds are not commonly used for human consumption. Waterfowls are also a source of downs and feathers. Although it is a relatively marginal industry, countries like China (22,500 tons), Taiwan (9,000 tons), Thailand (3,000 tons) and Hungary (3,000 tons) are key players in the 55,000 ton world feather and downs trade.

The importance and recent growth of goose production in Asia is noteworthy. China is the top goose producer, followed by the Ukraine, Hungary, Egypt and Taiwan. In Europe, Poland has a long tradition of goose meat production. In China, Taiwan, and Hungary, duck and goose meat productions occur in large-scale farms as well as in small-scale rural farms. In Taiwan, duck meat production is based on Mule ducks. Thailand and Malaysia are also intensive duck meat producing countries. In other Asian countries, local breeds dominate and are used for egg production, with meat being a by-product. In the USA, totally confined duck operations have been introduced mainly in the Midwest in order to achieve year-round production. Goose meat production remains a more extensive, pasture based production. Indeed, with less than 2,000 metric tons, goose production in the Americas is not important.

The leading European duck producing country, France, has changed over the past 30 years from about 80-90% of Peking ducks to mainly Muscovy and Mule ducks. Geese for production of “*foie gras*” (fatty liver) are also partly replaced by male Mule ducks, geese, psittacines, passerines and wild birds.

EGG PRODUCTION

The highly intensive practice of cage operations dates back to the 1950s. It was first saluted as the best approach to protect hens from unfavorable environmental conditions, predation, external and

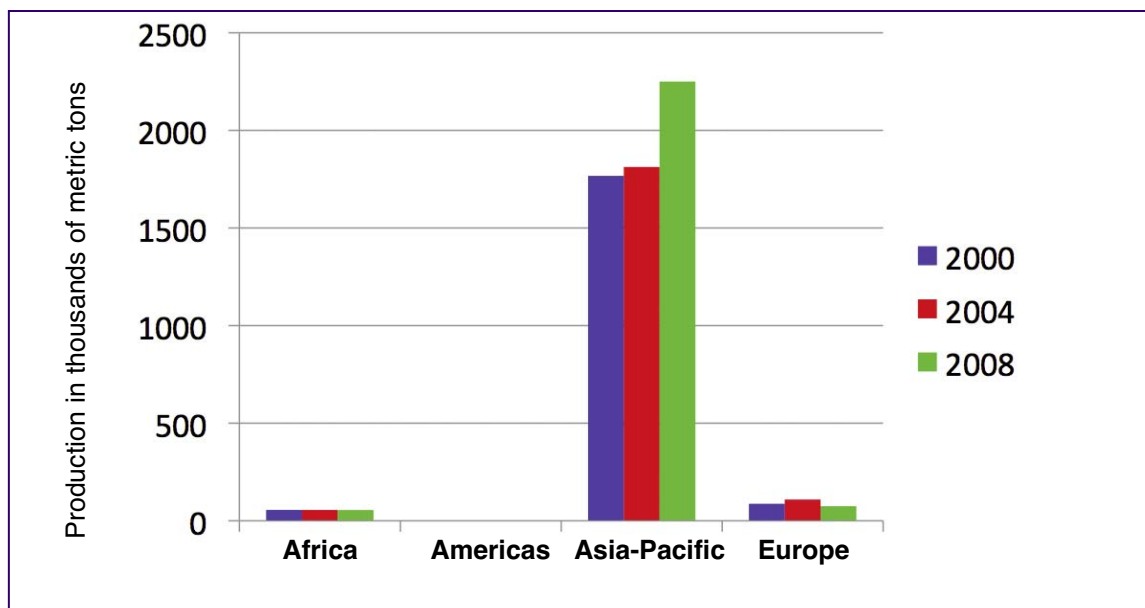


Fig. 1.6: Recent evolution of goose and guinea fowl meat productions by region and year of production. Data for only goose production was not available, but the guinea fowl component of this graph is very small.

internal parasites, and disease. Although most eggs are still produced in cages, there is significant pressure to enrich them with features to improve the birds' welfare (more space per hen than a conventional battery cage and resources that enable hens to perform natural behaviors, such as nesting and perching) and to consider producing in aviaries, i.e., without cages.

Between 1999 and 2009, the world's production of table eggs grew from around 49.8 million tons to more than 62 million tons, with a projected 16.5% increase by 2015 to 71 million tons. In 2010, the world produced approximately 63 million metric tons of eggs. Most egg layers are in Asia, with the

most spectacular growth occurring in China. By contrast, the USA, the second major egg producing country, has only seen a modest increase in production between 2000 and 2009.

In China, eggs of waterfowl are processed to produce salted eggs and alkalised duck eggs (thousand year eggs). About 15% of the total egg production in this country is duck eggs. In Thailand, around 35% of total egg production comes from ducks. In China, Taiwan and Thailand this production is based on breeds with high productivity in intensive systems, like Jinding and Shao ducks in China and Tsaiya duck in Taiwan with 260-300 eggs per year.

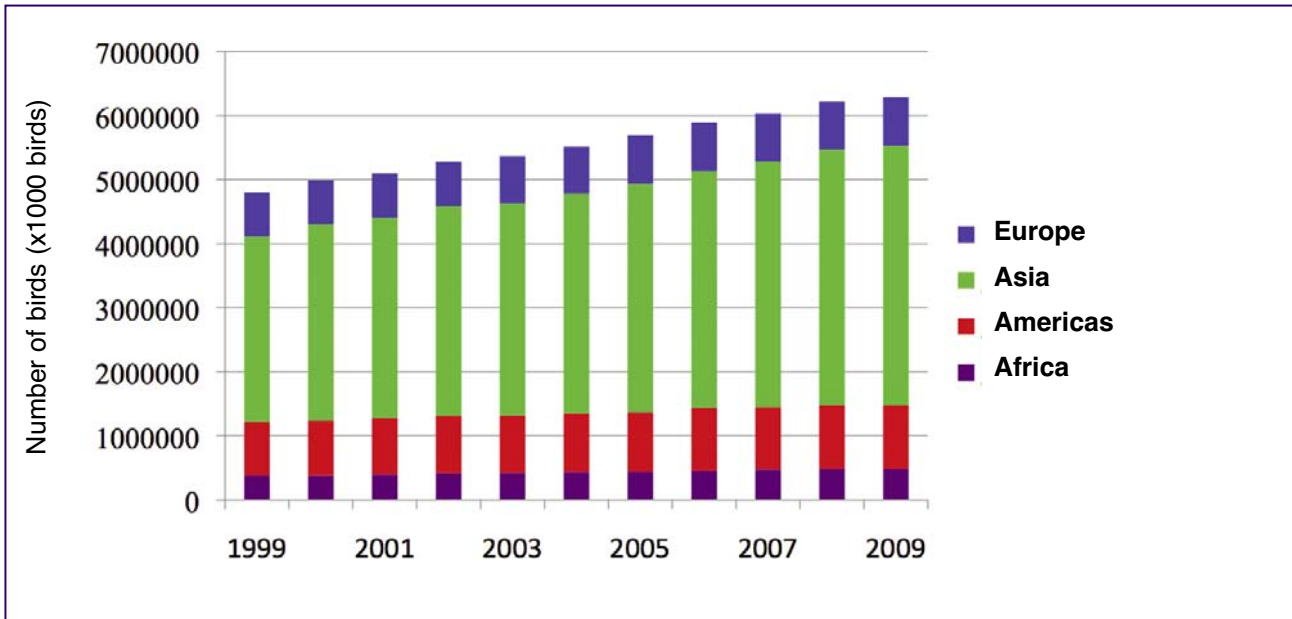


Fig.1.7: Number of egg layers by region of the world.

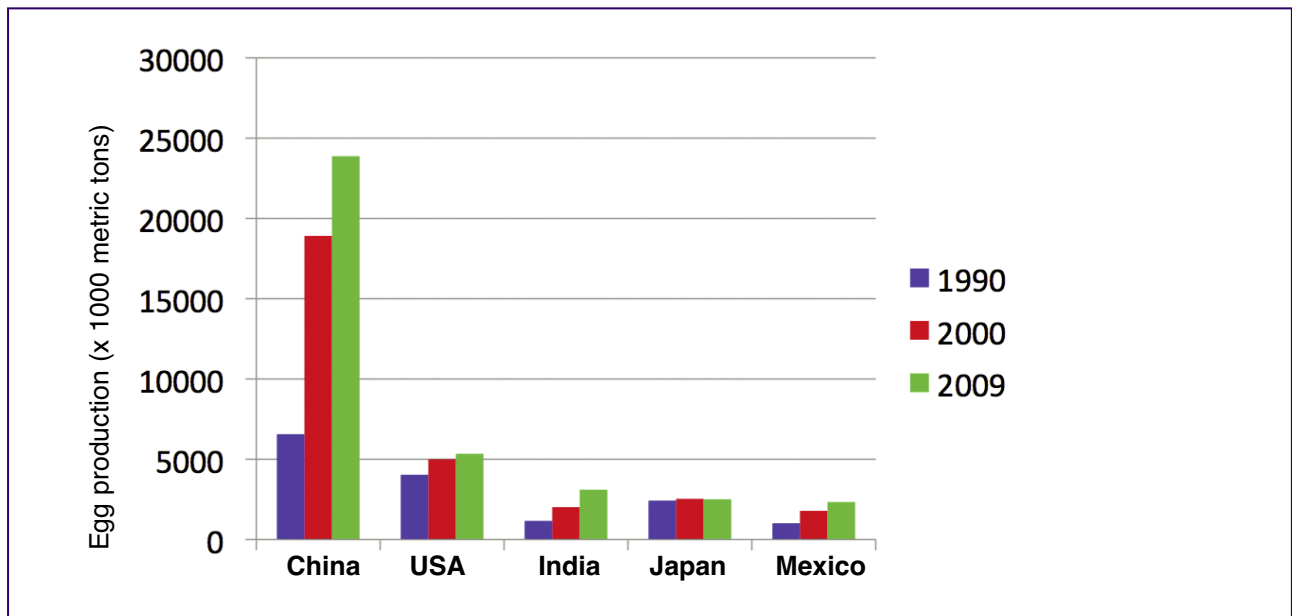


Fig.1.8: Evolution of egg production over time in the top 5 producing countries.

THE FUTURE OF POULTRY PRODUCTION

Public policies and international trade regulations will continue to have a significant impact on the poultry sector. Foodborne infections, in particular salmonellosis, campylobacteriosis and listeriosis, are a continuing concern that will continue to impact poultry production and trade.

The trend will persist towards better meat quality in a production context where bird physiology, health and well-being will occupy center stage. Technologies such as blood oximetry X-rays, and genetic markers, will contribute to the development of new genetic lines. The sequencing of the chicken genome has made it possible to identify genes associated with specific diseases. Hence, chicken lines with enhanced disease resistance and with better response to vaccines and medications will be developed. An incorporation of gene-related technologies to turkey and waterfowl breeding programs is also occurring. Resulting improvements will require ongoing efforts to offer the best adapted environment to these new lines of birds.

When times are difficult economically, consumers tend to prefer cheaper non processed products. However, when the economy is thriving, other purchasing criteria emerge such as the impact on the environment, animal welfare, local preference, etc. This may favor domestic products and may lead to new niche markets.

If about 95 million tons of poultry meat production were recorded in 2010, current estimates indicate that it could reach close to 118 million tons by 2019, a 24% increase. A FAO report suggests that meat production could increase as much as 30%, and most of the growth would be in developing countries, most notably in Asia, Eastern Europe, the Middle East, and Latin America. Globally, this would be an annual growth of 2.4%, less than in previous years. World consumption is expected to rise from 13.64 kg per person per year in 2010 to 15.3 in 2019. It is worthwhile to note that the continuing increased demand for poultry meat will challenge the agronomic sector and the environment, resulting in deforestation and conversion of

grasslands to crop production. More water will also be needed for irrigation and the end result will be an increase in nitrogen and phosphorus in agricultural run-off and plant effluent.

Many current health issues will still play a significant role in poultry production. There will be increasing restrictions placed on the use of growth-promoting antibiotics as feed additives. The withdrawal of growth promoters with activity against Gram-positive intestinal flora has resulted in an increase in necrotic enteritis. So, emphasis now and in coming years will be on improving the environment, sanitation, effective control of coccidiosis, and using prebiotics, probiotics and fermentation products. For the past few decades, mycotoxins have also impacted reproductive efficiency, growth rate and meat quality. This will remain a worldwide issue in the future.

The emergence of highly pathogenic avian influenza in Asia and Africa, with occasional outbreaks in Europe and the Americas has raised the issue of increased risks of disease transmission in commercial operations located in high poultry density areas. This will require enhanced on-farm and regional biosecurity programs. New communication and traffic control technologies may play an important role to facilitate compliance, which will remain an important issue for years to come.

REFERENCES

- Daghir N.J. 2008. *Poultry production in hot climates*. 2nd edition. CAB International, Cambridge, MA; 2008: 377 pages.
- Gillespie JR & Flanders FB. 2009. *Modern livestock and poultry production*. 8th ed. Delmar, Cengage Learning, Clifton Park, New York: 1136 pages.
- Jez C et al. 2011. *Poultry production in 2025: learning from future scenarios*. World's Poultry Science Journal, 67: 105-113.
- Livestock and Poultry: *World Markets and Trade*. United States Department of Agriculture. April 2011. <http://www.fas.usda.gov/psdonline>.
- Watt Executive Guide 2010 to world poultry trends. www.WATTAgNet.com.

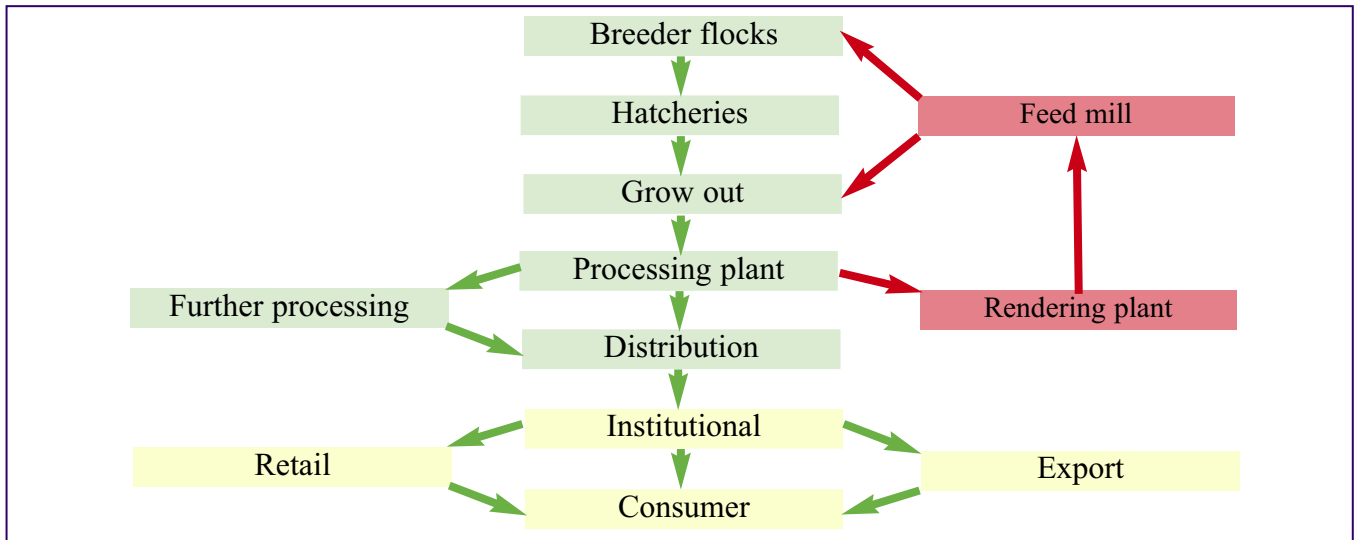


Fig.2.1: Vertical integration diagram. Shows possible segments that may be included within a vertically integrated broiler company.



Fig.2.2: Separation of male and female areas is shown. Female feeders and nest boxes are positioned on the outer raised slatted area. Male feeders are located in the central area where there is litter.



Fig.2.3: Egg storage in hatchery.



Fig.2.4: In ovo inoculation machine used at transfer from incubator to hatcher.

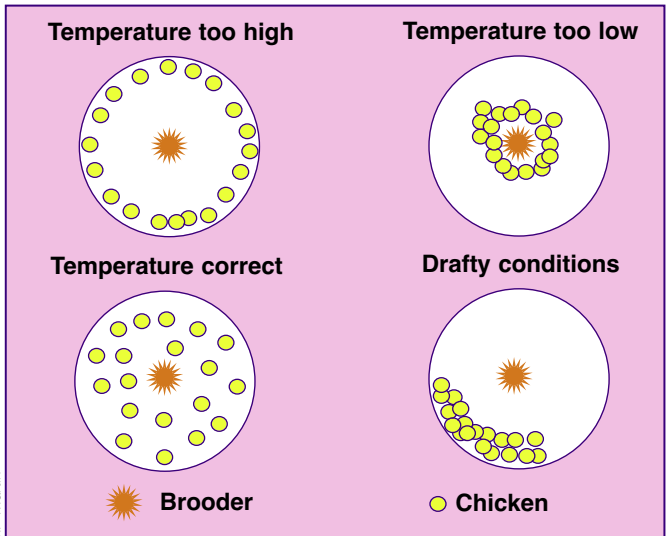


Fig.2.5: Behavior patterns of a flock can signify discomfort based on ventilation and temperature issues.

2. CHICKEN PRODUCTION

INTRODUCTION

Commercial meat chicken production originated in the United States in the early 20th century as demand for poultry meat was rising. This demand led to the rise of larger flocks of chickens with the primary intention of selling the birds for meat. Chickens grown primarily for the purpose of meat production, or broilers, can be found throughout the world raised in a diversity of management systems. Many commercial broiler producers are vertically integrated (Fig.2.1) where multiple segments of production are controlled by the same company. Proponents of this type of production assert that it provides better control and continuity of production, better understanding of the value of each segment, and improved ability to plan product supply to meet future market demands. Depending on the size and goals of a specific broiler company, they may have variability in the integrated segments that are internally owned.

Many broiler integrators have most or all chicken farms privately owned and under contract by the integrated company. Within this model, family run farms are paid and given bonuses based on various predetermined productivity parameters. The cooperative model also shares similar elements of the integrated model, but with growers as part owners of the company. There are many more production models, but the objective of this chapter is to present the basic components required to produce chickens at a commercial level.

As chicken flocks started being raised solely for mass meat production, genetic selection became an important aspect of broiler production and still is today. Established chicken breeds throughout the world that had good meat characteristics were often used as the starting point for genetic selection where an emphasis was placed on growth rate, feed conversion, and muscle yield amongst other production parameters. Some selection emphasis is on egg production parameters to improve breeder efficiency.

Disease resistance has also been an important part of genetic selection over the years providing resistance to specific diseases such as Marek's disease and avian leucosis or improving general hardiness of the birds so that they are productive across a diversity of environments. Often this selection is

done by a separate primary breeder company that then sells parent stock or broiler breeders to a commercial integrator or breeding company. There are some commercial integrators that have their own primary breeder stock that is maintained internally.

ANIMAL PRODUCTION SEGMENTS

There is wide variability of management and housing methods in raising broilers that are implemented based on several factors including but not limited to potential disease challenges, company goals, personal experience, breed of birds raised, market demand, economic factors, and geographic region where birds are raised. Included in this chapter are some common ways these segments are operated, but they are not intended to be all inclusive of the wide range of broiler management styles and methods.

Broiler breeders

Most broiler breeders are housed to allow for natural breeding. Young male and female chickens may be raised separately or together prior to breeding age. Because broiler chicken strains have the potential for very rapid growth, breeder chickens are often feed restricted. Weight management by feed restriction prevents disease issues such as obesity related disorders, lameness, and reproductive disorders. Feed restriction programs may include restriction of volume of feed, frequency of feeding, and/or energy levels in the feed.

During the growing stages, breeders are often housed in an environment where light duration is restricted so the birds are exposed to a short day length. The basic goal of a lighting program for broiler breeders is to have birds become reproductively active at approximately the same age by uniformly increasing the day length prior to reproductive maturity. Breeders are often moved just before breeding (approximately 19-23 weeks of age) into a breeding house specifically designed to facilitate reproductive activity and egg collection. This may include designated areas where the males and female preferentially eat and spend most of their time and nest boxes that facilitate egg collection (Fig.2.2).

Slats may be provided in hen areas to minimize bird contact with fecal material, which can



Fig.2.6: Birds behavior avoiding the brooder pan demonstrates that the temperature is set too high.



Fig.2.7: Partition within a commercial broiler house to reduce the risk of piling of birds.

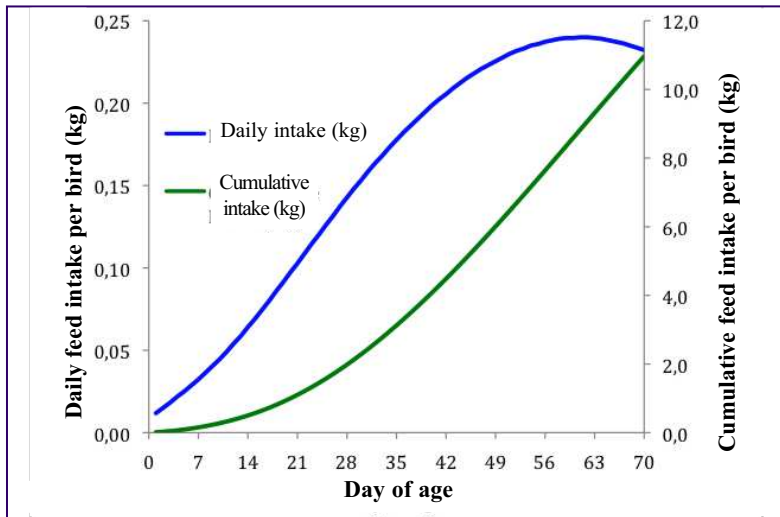


Fig.2.8: Representative daily and cumulative feed intake per bird (kg). Feed intake is breed specific. The primary breeder supplier should be contacted with the most accurate information for the bird being used. The following chart is derived from the Ross 708 Broiler Performance Objectives, 2012.

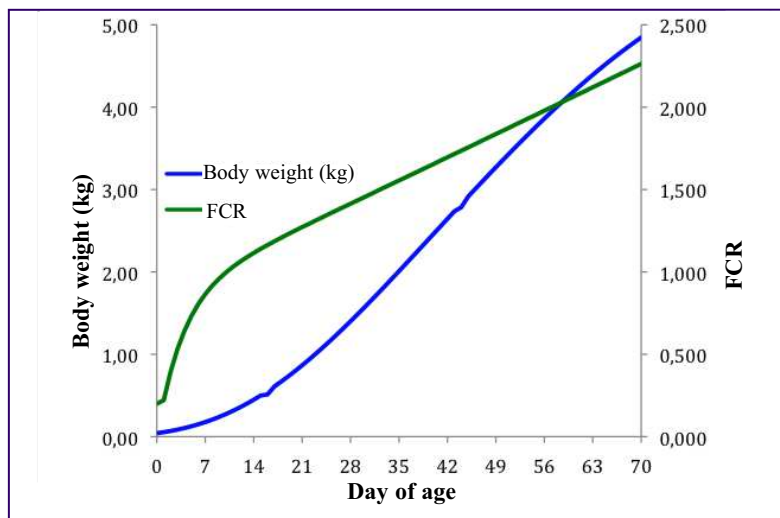


Fig.2.9: Representative weight gain and feed conversion ratio (FCR) of a commercial broiler. Growth curves and FCR are breed specific. The primary breeder supplier should be contacted with the most accurate information for the bird being used. The following chart is derived from the Ross 708 Broiler Performance Objectives, 2012.

decrease the incidence of disease and keep eggs cleaner. For natural breeding the ratio of females to males is approximately 10:1 but may vary with management system and breed. Mortality, flock behavior, and egg fertility may be monitored to adjust male to female ratio. Farms can have automated egg collection or hand collection. Eggs should be collected frequently to decrease shell contamination, consumption of the eggs by the breeder chickens, and risk of partial incubation on farm.

Eggs are stored on site until they are able to be brought to the hatchery. Egg storage on farm is optimally in a controlled temperature environment [approximately 55-65°F (12.8-18.3°C) and 70-75% relative humidity] where eggs are not too warm so that incubation begins not too cold for embryo viability. Many breeder facilities have feeding systems that allow feeding different rations to the males and females based on their separate nutritional requirements. Broiler breeders may be molted to improve egg production parameters when the flock is older. However, it is common to only have one reproductive cycle for broiler breeders and then start with a new flock of breeders after egg production parameters decline.

Broiler hatchery

Chicken eggs are often stored prior to incubation to improve hatchability. Although optional storage time at ideal storage temperatures is approximately 7 days, eggs may be stored for significantly more or less time based on supply and demand, availability of eggs, and needs for placement of chicks on open farms (Fig. 3). Eggs may be pre-warmed prior to incubation for several hours. Only clean eggs should be set to minimize the risk of disease causing hatchability issues and poor chick quality and uniformity. Broiler eggs are typically incubated for approximately 21 days with 18 days of the total incubation time in the incubator and 3 days in the hatcher. The length of incubation can change based on individual hatcheries, equipment used, breed of chicken, and other variables. Although incubation temperatures are approximately 99.5°F (37.5°C) at the start of incubation and may decrease slightly during hatching and relative humidity is approximately 55% and may increase during hatching, there are many variables that can affect optimal hatchability. As such, incubation programs are best designed to meet individual hatchery needs and challenges.

As eggs are transferred between incubation and

hatching systems, they may be given an *in ovo* inoculation (Fig.2.4). *In ovo* inoculations may contain labeled vaccines or antibiotics or other products labeled for *in ovo* use. The most common products given *in ovo* are Marek's disease vaccines, which provide a uniform delivery of the vaccination, cost savings in decreased labor in larger hatcheries, and reduction of clinical disease. Hatched chicks may have some handling depending on the management system, but often in large hatcheries automation separates the chicks from the shells, counts chicks into transport trays, provides any necessary vaccinations via spray, and stacks trays in preparation of being moved to farms.

Most commercial broiler chickens do not require separate sex rearing so they are not sexed at the hatchery. If sexing is required, many of the common commercial breeds have a feather sexing gene that allows for easy identification of males and females with minimal handling (most often by observing differences in wing feathers between males and females). Birds are moved to the farm as needed, usually the same day as hatch and during cooler temperatures to minimize stress.

Commercial broilers

Prior to placement, commercial broiler farms should be prepared to receive new chicks. If litter has been recycled, it may be turned, treated, and/or otherwise managed to reduce ammonia, pathogen, and insect load. Houses will be heated to provide adequate temperature for the chicks and feed and water lines may be primed so that they are at room temperature prior to placement. Temperature may be uniform within houses or a temperature gradient may be provided to allow chicks to better adjust their individual temperatures. If a temperature gradient is provided, feeders and waterers should be placed so that birds can adjust their temperature and still have easily access to feed and water.

In general, chicks are placed at a ground temperature of approximately 90-95°F (32.2-35°C) and temperature is decreased as the birds age at approximately 5°F (2.8°C)/week until the temperature is around 70°F (21°C). However, this greatly varies based on the management system and breed of bird so temperature should be adjusted based on flock behavior (Fig.2.5 & 2.6). Many commercial broiler houses have some or extensive environmental control and the ability to implement standard program flock profiles for temperature and ventilation. Chickens in these environments

Age (Weeks)	Liters per 1000 birds	Gallons per 1000 birds
1	61	16.1
2	106	28.0
3	171	45.2
4	237	62.6
5	293	77.4
6	336	88.8
7	363	95.9
8	374	98.8

Tabl.2.1: Representative water consumption chart for broilers. Water consumption charts can be breed specific. The primary breeder supplier should be contacted with the most accurate water consumption chart for the bird being used. The following chart is derived from the Ross Broiler Management Manual, 2009. Consumption assumes 21°C uniform house temperature.



MP Martin

Fig.2.10: Good access to feed. There is no overcrowding and the equipment is well maintained.

Age (Processing Weight)	Week 1 (Any)	Week 2 - pre-processing * (x < 2.5kg)	Week 2 - pre-processing * (x > 2.5kg)
Intensity (lux)	30-40	5-10	5-10
Day Length (hours)	23	20	18

Tabl.2.2: Representative lighting requirements chart. Basic light intensity and photoperiod recommendations can be breed specific. The primary breeder supplier should be contacted with the most accurate information for the bird being used. The following chart is derived from the Ross Broiler Management Manual, 2009.

* Pre-processing is 3 days prior to scheduled processing



MP Martin

Fig.2.11: Good access to water. There is no overcrowding and the height is appropriate to allow birds easy access with minimal water leaking to the litter.



MP Martin

Fig.2.12: Ventilation maintaining good air quality and litter conditions.



MP Martin

Fig.2.13: Chick with conjunctivitis associated with high ammonia levels.



MP Martin

Fig.2.14: Temperature probe to monitor temperature at bird level.

should always be monitored visually on a regular basis as individual flocks may vary and equipment failures may occur.

Partitions may be present in larger broiler houses to reduce the risk of piling of birds but do not need to completely restrict bird movement between sections of the house (Fig.2.7). Commercial broilers are typically given *ad libitum* feed and water throughout the growing period but adjustments may be made based on past performance, breed, and company goals.

Breed standards often exist for feed and water consumption (Fig.2.8 & Tabl.2.1) as well as weight gain and feed conversion (Fig.2.9) to guide growers and help them identify problems. Many commercial broiler operations have reduced lighting intensity throughout the growing period to decrease the risk of traumatic injury that may cause mortality and processing condemnations, but long day lengths facilitate feed intake and rapid growth (Tabl.2.2).

Broiler processing

Based on market needs, broilers will be processed at a target weight or age determined by the individual company. Loading chickens into transport vehicles to move to processing may be done at night or early morning to decrease physical and heat stress during loading.

At the processing plant, misting or fans may help keep birds cool and reduce mortality while birds are waiting to be processed. In colder regions, heating systems may be needed. Handling of birds at processing, including unloading and shackling, should be done in a way to minimize trauma to the birds, which would not only be a welfare concern but would lead to increased condemnations. Birds should be rendered unconscious and/or euthanized in a manner that does not cause undue stress, increase condemnations, or adversely affect food safety.

BASIC HUSBANDRY

Feed & Water

Clean feed and water should be provided to broiler chickens with adequate space and sufficient access per bird (Fig.2.10 & 2.11). Feed formulations may change throughout the life of a flock based on the nutritional needs throughout growth and reproductive development. This feeding strategy is called

phase feeding. Maintenance of feed and water equipment can minimize the risk of leaking/spilling into the environment.

Poorly maintained equipment may increase litter moisture, adversely affect birds health by exposure, increase the risk of enteric pathogens, and attract wild animals including rodents.

Temperature & ventilation

Uniformity of ventilation is ideal to improve flock performance (Fig.2.12). Poor ventilation may promote excessive litter moisture and increase the exposure of the chickens to enteric pathogens. Poor ventilation may cause excessive ammonia levels, which could be detrimental to the health and welfare of animals and employees (Fig.2.13). Excessive ammonia at the level of the chicks may be less detectable to a standing human and high levels can cause health problems such as corneal ulceration, conjunctivitis, and inflammation/deciliation of the trachea thereby predisposing birds to respiratory pathogens.

Poor temperature control may cause birds to be less productive, decrease consumption of feed and water, and predispose birds to secondary infections. Continual monitoring of birds behavior can minimize the risk of excessive temperature stress (Fig.2.14). Care should be given to provide adequate ventilation during times of inclement environmental temperatures.

Litter

Excessive litter moisture can increase environmental load of enteric pathogens, predisposing the flock to disease. Wet litter can also lead to exposure where birds become wet and are unable to thermoregulate, leading to morbidity and mortality problems. Wet and caked litter can trap ammonia and potentially cause scalding of the foot pads and lameness. Excessively dry litter can lead to high levels of dust in the environment, which can damage the respiratory tract and predispose chickens to respiratory pathogens.

Type and quality of litter can affect moisture absorption and litter longevity. Litter is commonly recycled between flocks in the United States. In some other countries, it is replaced after each flock. Litter should be changed out between flocks when there is evidence of increased morbidity, mortality or condemnations that could be attributable to poor litter conditions or enteric pathogens.

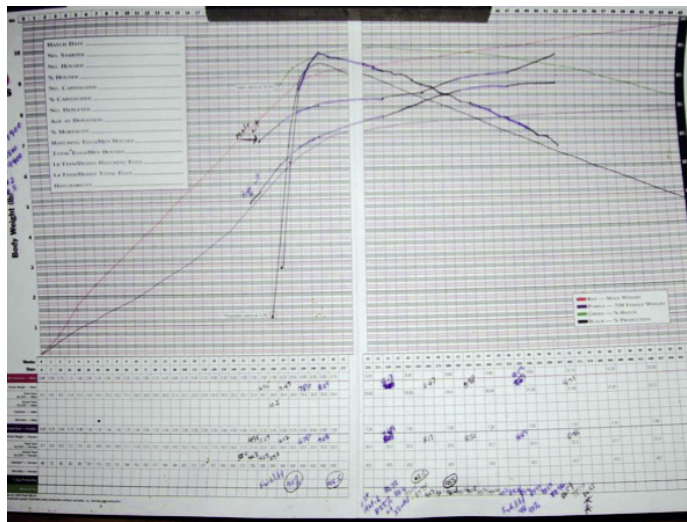


Fig.2.15: Data record chart for broiler breeders. Chart helps track % egg production, hatchability, hen weight, and rooster weight compared to breed standard.

DAY	EGGS					FEED		MORTALITY		HEADCOUNT	
	HATCH	CULL	DV	TOTAL	% WATER	HENS	MALES	H	M	H	M
1	Fri					2880		2	-	9235	297
2	Sat					2880		3	2	9232	292
3	Sun					OFF	(1420)	6	2	9236	290
4	Mon					2880		3	-	9225	290
5	Tue					2880		7	2	9216	288
6	Wed					OFF		6	1	9210	287
7	Thu					3010		7	1	9203	286
8	Fri	3	-	8		3010		2	-	9201	286
9	Sat	14	-	14				4	-	9197	286
10	Sun	23	-	23		OFF	(1490)	3	1	9194	285
11	Mon	30	-	30		3010		4	-	9190	285
12	Tue	46	1	47	(23)	2140	(90)	2	1	9188	284
13	Wed	63	3	66		2230		4	-	9184	284
14	Thu	93	4	97	1%	2230		4	3	9184	281
15	Fri	153	8	161	1.8%	2230		3	1	9182	280
16	Sat	240	11	251	2.7%	2140	(1420)	5	1	9172	279
17	Sun	360	30	390	4.3%	2140	(90)	7	1	9154	273
18	Mon	490	30	520	5.2%	2360	(90)	11	2	9144	276
19	Tue	630	30	660	7.3%	2360	(90)	4	1	9100	276
20	Wed	940	45	985	11.4%	2360	(90)	2	-	9098	275
21	Thu	1380	45	1425	19.7%	2400	(90)	-	-	9098	274
22	Fri	1620	-	1620	18.5%	2400	(90)	1	-	9097	274
23	Sat	2070	30	2100	25.0%	2500	(90)	1	2	9096	272
24	Sun	2460	30	2490	28.8%	2550	(90)	1	1	9095	271
25	Mon	2970	30	3000	34.2%	2600	(90)	5	2	9090	269
26	Tue	3390	30	3420	39.2%	2640	(100)	1	-	9089	267
27	Wed	3750	30	3780	45.1%	2700	(100)	-	-	9089	267
28	Thu	4290	30	4320	51.4%	2730	(100)	1	1	9088	266
29	Fri	4890	30	4920	58.6%	2800	(100)	1	-	9087	266
30	Sat	5240	60	5300	61.1%	2850	(100)	1	1	9086	266

COMMENTS:
 23 wk wt 510
 690
 523 818 111 (4.13)
 647 810 100 (6.13)
 25 wk wt 580 Goal
 730
 604 867 94 (4.24)
 757 882 67 (4.27)

Fig.2.16: Data record chart for broiler breeders. Chart helps track egg production, feed consumption, and separate sex mortality.

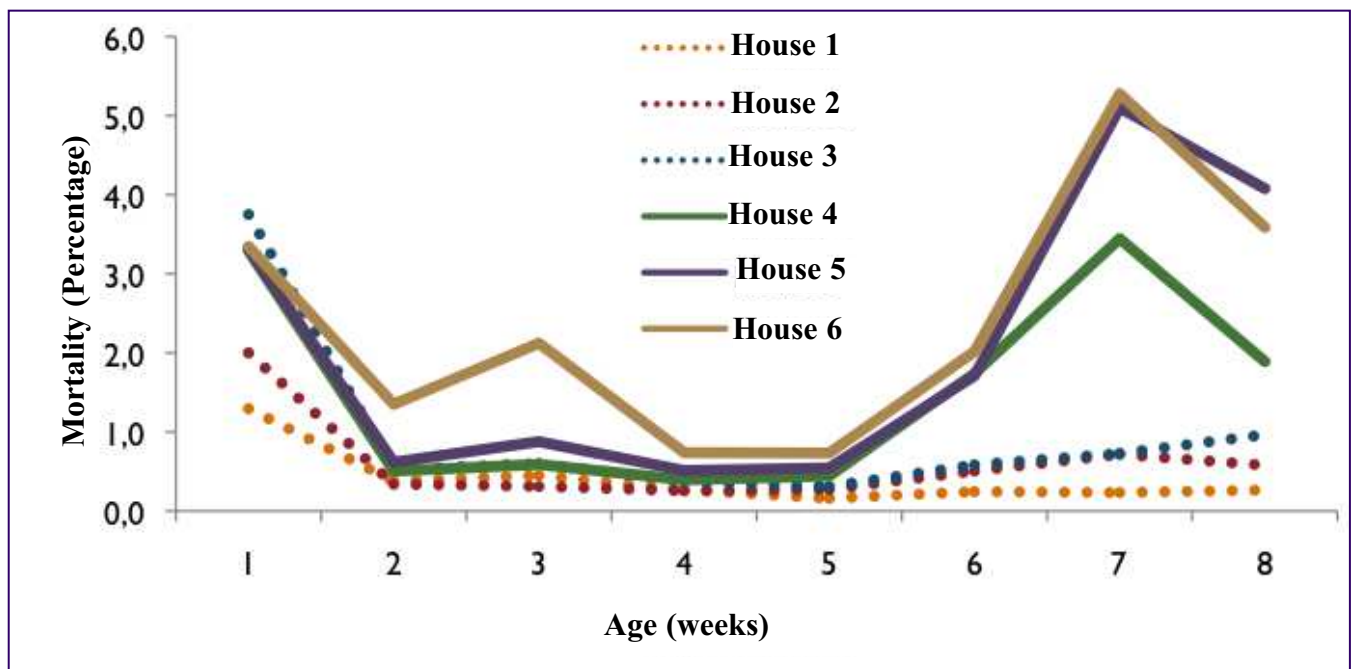


Fig.2.17: Example of weekly broiler mortality curve by house.

DISEASE PREVENTION

Many strategies are used in commercial broiler production to mitigate the risk of disease. Genetic selection, as previously mentioned, can be done to improve the general hardiness of the bird and increase resistance to specific disease agents. Vaccination programs are critical in broiler production (see chap.V.82). Vaccination programs should be focused on pathogens which commonly affect broilers and strains which are geographically relevant and/or are historical threats within the company. Vaccination programs should be monitored through routine flock surveillance and/or serology.

Biosecurity is critical to disease prevention in broiler flocks (see Chap.V.80). In general, biosecurity programs should mitigate the risk of infectious disease transmission by controlling insects, rodents, wild animals, pets, employees, human visitors, and vehicles that may potentially carry disease. It is not cost effective to mitigate all risk and depending on bird value (i.e breeders vs. commercial broilers) there may be a greater investment of resources for biosecurity. General management can greatly affect disease. Any deficiency in feed, water, litter, ventilation, or temperature management may lead to excessive stress in the flock and predispose the birds to disease associated with infectious agents. Care should be given to provide broiler chickens with good environmental conditions and monitor flocks for disease.

Monitoring is essential to disease prevention programs including diagnostics for specific infectious agents, monitoring vaccination programs, and general flock/mortality assessments to look at patterns of morbidity and mortality. Routine assessment of average weights and feed/water intake can also help identify disease problems before they become severe.

Good record keeping of production parameters (Fig.2.15 & 2.16), mortality charts (Fig.2.17), biosecurity procedures, and flock assessments are beneficial and facilitate monitoring broiler and broiler breeder flocks for disease also occurring. Resulting improvements will require ongoing efforts to offer the best adapted environment to these new lines of birds.

REFERENCES

A Practical Guide for Managing Risk in Poultry Production. R. L. Owen, Editor. American Association of Avian Pathogens, Inc. 2011.
 Broiler Management Guidelines, Aviagen. <http://en.aviagen.com/>
 Broiler Management Guidelines, Cobb. <http://www.cobb-vantress.com/products/guide-library/general/broiler-management-guide>
 Diseases of Poultry, 12th ed. Y. M. Saif, Editor-in Chief. Blackwell Publishing, Ames, Iowa. 2008.
 National Chicken Council Animal Welfare Guidelines and Audit Checklist <http://www.nationalchickencouncil.org/wp-content/uploads/2012/01/NCC-Animal-Welfare-Guidelines-2010-Revision-BROILERS.pdf>

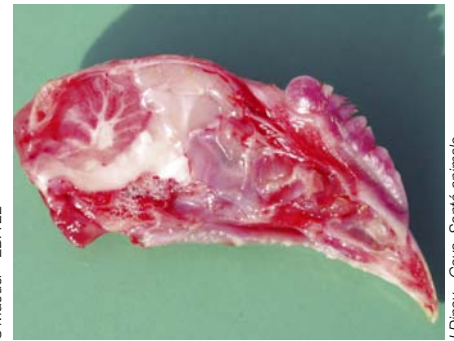
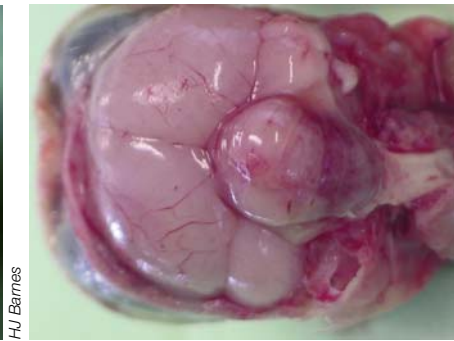

Fig.3.1, 3.2 & 3.3: Early embryonic death can be seen with vitamin E deficiency (vascular lesions). Encephalomalacia in chick is usually observed at the age of 15-30 days but can also be present as early as the 7th day (Fig.3.1: 10 day-old chicks with nervous signs). At necropsy, vascular lesions lead to edema and petechia or larger hemorrhages in the cerebellum, with ensuing neuron degeneration.

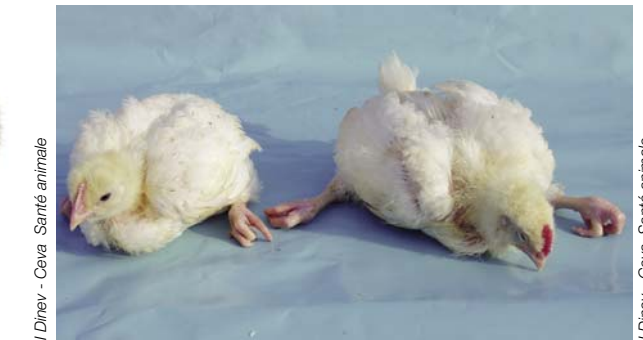
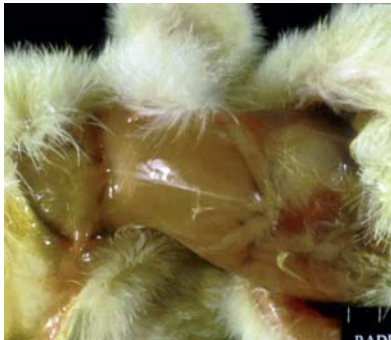
Fig.3.4: Breeder (4 days). Subclinical edema, caused by vitamin E deficiency or hypoproteinemia.

Fig.3.5: Vitamin B₁ (thiamine) deficiency (nervous signs). The chickens acquire a specific posture with flexed legs and head drawn backwards (stargazing).

Fig.3.6: Vitamin B₂ (riboflavin) deficiency. Dystrophic changes in peripheral nerves leads to toes flexion.

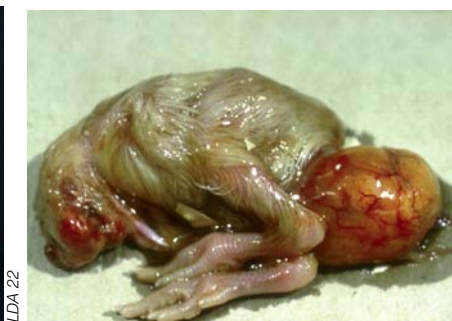

Fig.3.7: Biotin deficiency. The occurrence and age incidence of lesions in young birds may be influenced by the biotin level in the egg. Affected feet of 4 day-old chicks.

Fig.3.8: Congenital anomalies. Embryo: craniofacial malformation.

Fig.3.9: Congenital anomalies. Anophthalmia and crossed beak deformity (one day-old chick).

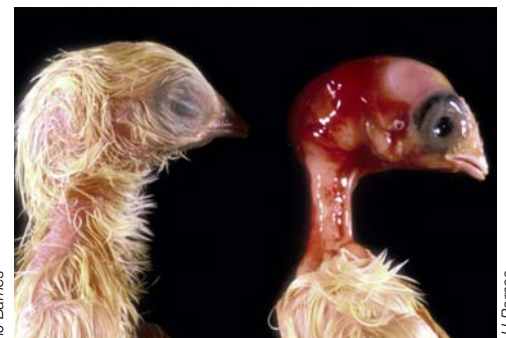
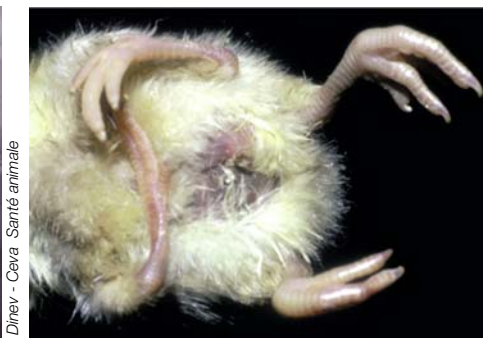
Fig.3.10: Congenital anomalies. Open body cavities. An additional skin formation (pouch) to the left lateral abdominal wall, with part of the abdominal organs found within.

Fig.3.11: Congenital anomalies. Dipygus with supernumerary limbs. Such birds frequently survive up to the end of the growing period.

Fig.3.12: Improper incubation. Myopathy of pipping muscle is associated with nutritional deficiencies in breeder hens. The Muscle complexus (pipping muscle) is the primary muscle responsible for the embryo's pipping action at hatching.

3. CHICK QUALITY

INTRODUCTION

Day-old chick quality is an important factor in obtaining maximum production results, both in meat producing birds and in egg laying birds. The modern breeds available to the industry have an enormous production potential, but this potential can only be fully expressed if all factors involved in producing high quality hatching eggs and chicks are optimized. During incubation and immediately after hatch the bird is still developing its skeleton, organs, immune system, thermoregulation, *etc.* A poor chick quality and poor start at the farm will negatively influence production performances later in the life of the bird.

Producing good quality day-old chicks starts with the breeder flock. Not only is the quality of the egg important, but also the health and nutritional status of the breeders are having an impact on day-old chicks; so do several other factors. Although much is known about the influence of the breeder flock on the quality of day-old chicks, not all factors are fully understood yet.

In the field, differences in chick quality can be observed between eggs coming from different breeder flocks and associated with differences in genetic background, nutrition, health status, *etc.* However, it is not always possible to quantitatively explain these differences. Furthermore, these differences between breeder flocks may also impact fertility and hatchability rates, as well as other parameters. Subclinical factors and other health considerations likely play a significant role, but we have yet to determine how to identify and measure them.

In general we can divide the factors associated with chick quality in two categories: breeder flock related factors (egg related factors) and hatchery and brooding management factors (egg handling, incubation, chick processing and placement).

EGG RELATED FACTORS

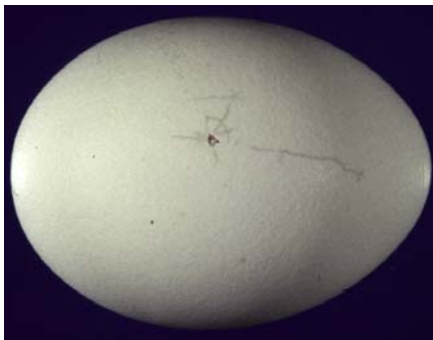As the quality of the egg is a separate subject (Chap.I.5), this section will be limited to some general remarks.

Nutrition

For an optimal development of the embryo, a correct balance of the different nutrients is essential. This balance is delicate, since embryo development is an incredibly complex process, requiring adequate quantities of energy, protein, essential fatty acids, vitamins (especially vitamin B complex), minerals, *etc.* Likewise, the egg development and its nutritional composition are the result of a very demanding process for the hen, and any changes or deficiencies may make it impossible for the chick to hatch. Some of these changes may not impede hatching but may result in noticeable differences in chick quality. Especially suboptimal levels of several B-vitamins can cause substantial problems leading to poor chick quality, malformations, *etc.* Often the problem is not so much the lack of vitamins per se, but rather factors that influence their availability or absorption, as for instance when mycotoxins are present in the feed.

Nutritionists may occasionally recommend higher dosage of vitamins, minerals, *etc.*, based on published research. Formulating higher levels of some microelements than necessary is a relatively affordable way of minimizing risks of poor hatchability and chick quality, especially when taking into account that substantial differences can sometimes be observed between calculated feed formulations and actual nutritional levels in the finished feed, due to raw material variation, storage time, mixing problems, *etc.* But we also must keep in mind that scientific results are often obtained under well controlled conditions, where all breeder hens receive the appropriate amount of nutrients. In the field, problems resulting from marginal nutritional intake are often observed only in breeders that are already more fragile than most. If this small percentage of breeders produces eggs giving weak day-old chicks, it is often considered a flock problem when in reality only a few breeders may be affected. This type of problem is usually resolved by formulating higher nutritional levels.

Although breeders are not extremely sensitive to feed formulation factors, embryo development is a very delicate process that can easily be disturbed. Some chemicals can very easily have a toxic



S Gillingham

Fig.3.13: If eggs are too big, the risk of damage while placing and turning them increases, resulting in more hair cracks and reduced hatchability.



I Dinev - Ceva - Santé animale

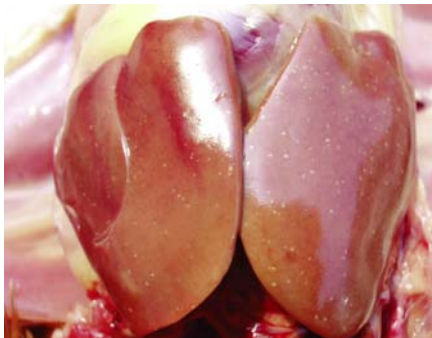


I Dinev - Ceva - Santé animale

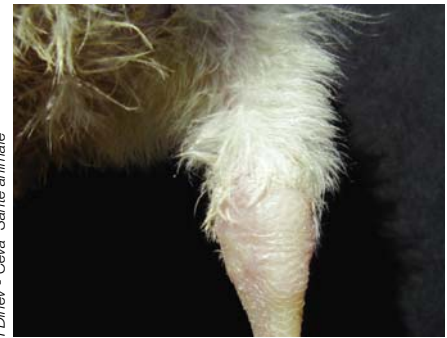Fig.3.14 & 3.15: Pullorosis is transmitted by the egg and is commonly characterized by a white diarrhea and high death rate. The feathers around the vent are stained with diarrheic feces or pasted with dry feces.



I Dinev - Ceva - Santé animale



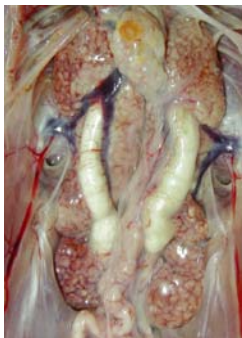I Dinev - Ceva - Santé animale



I Dinev - Ceva - Santé animale

Fig.3.16 & 3.17: Pullorosis. Greyish-whitish nodes are seen in gizzard walls (Fig.3.16), heart, lungs, liver, peritoneum and intestines. In Fig 3.17, the liver presents greyish-whitish miliary necrosis

Fig.3.18: Pullorosis. Edema of tibiotarsal joints is a frequent lesion.



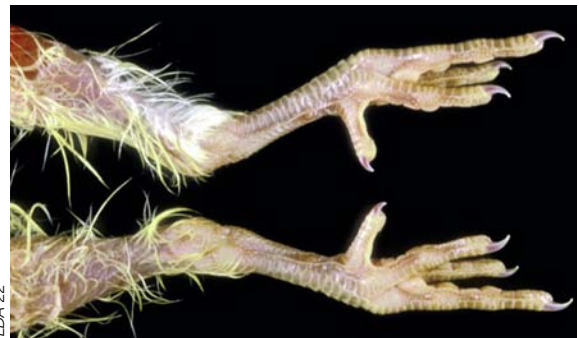I Dinev - Ceva - Santé animale

Fig.3.19: Pullorosis. Ureters are often filled with urates.



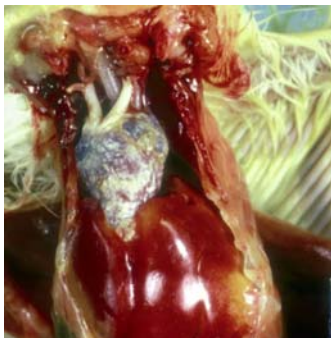
LDK 22

Fig.3.20: Avian encephalomyelitis. Vaccination of breeders prevents subsequent egg transmission of the virus and provides protective maternal immunity lasting through a highly sensitive period in the chick's life.

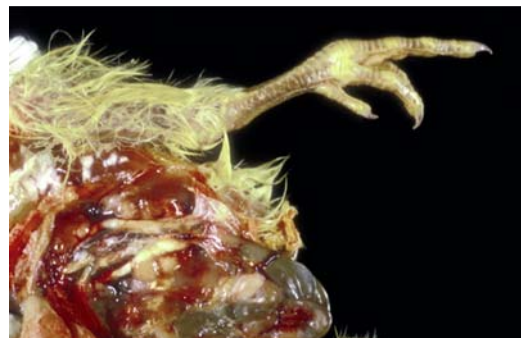

HJ Barnes

Fig.3.21: Dehydration (three day-old broiler).



HJ Barnes



HJ Barnes

Fig.3.22 & 3.23: Outbreaks of baby chick nephropathy can be due to inappropriate egg storage conditions with excessive water loss during incubation or during chick holding/transport, or inadequate water intake during the first few days of life. Left, visceral gout on heart of a four day-old broiler. Right, kidney, visceral and articular gout in one week-old broiler chick.



HJ Barnes

Fig.3.24: Egg tooth is a protuberance on the beak used to break the shell of the egg upon hatching.

influence on the embryo, often resulting in early mortality. Several chemicals used for chicken or turkey broilers are known to have a severe effect on embryo survival. A well-known example is feed contamination with Nicarbazin, used for coccidiosis control. Even minor traces of Nicarbazin in the feed of breeders can be detrimental and result in early embryo mortality.

Breeder health status

Day-old chicks need maternal antibodies against several diseases. This is achieved by applying a strict breeder vaccination program based on regional risks and legal requirements. Although protection provided by vaccination is very significant, day-old chicks remain susceptible to diseases not covered in the program and that may affect the parental flock. Often these infections have a negligible impact on the parents but a significant effect on progeny. This is why strict disease prevention measures must be in place on breeder farms. When disease occurs in a breeder flock, in addition to the potential impact on egg and chick quality, the condition may also influence behavior (which could lead to lower fertility) and the consistency of droppings (having a detrimental impact on egg sanitation).

Therefore, it is of the utmost importance not only to properly vaccinate a breeder flock to ensure adequate maternal immunity, but to manage the flock in such a way as to optimize its health so that, in turn, these breeders lay top quality eggs. For example, a subclinical infectious bronchitis infection will negatively impact production parameters (egg-laying, fertility, hatchability rates) and lower both egg quality and chick quality. In other words, a breeder hen with problems will produce progeny with problems.

Breeder age

One of the most significant but least understood factors that influence day-old chick quality is the age of the breeder flock. Young breeders produce chicks that are more susceptible to brooding conditions and that are more likely to die within the first week of life. Research has shown that the development of their thermoregulation capacity is delayed. From the end of day 19 of incubation until day 4-5 post-hatch, the poikilothermic embryo changes to a homeothermic chick. Chicks from young breeder flocks take longer to develop their homeothermic responses, which makes them more sensitive to suboptimal temperatures. This effect is compounded by the fact that they have less body mass to

produce heat and they also produce less heat per gram of body mass. The role that the lack of maturity of a young breeder flock may have on the thermoregulation of their progeny is not well understood. The problem seems to disappear when broiler breeders reach the age of physical maturity at approximately 32-35 weeks. Layer breeders reach maturity a few weeks earlier. Experiments with different diets, especially diets designed to modify the fatty acid composition of the yolk, has not resulted in any consistent improvement.

Egg size

Chick size is almost completely dependent on egg size. In general, the weight of the day-old chick will be 2/3 of the original egg weight. As weight of the day-old chick is positively associated with slaughter weight, farmers aim at achieving a higher egg weight. However, there is an upper limit for optimal egg weight. If eggs are too big, several problems can occur.

- As hens can only deposit a limited amount of shell material in a given time frame, bigger eggs tend to have poorer shell quality, which has a negative influence on hatchability and chick quality.
- Not all egg trays are capable of holding bigger eggs. If eggs are becoming too big, the risk of damage while placing and turning the egg increases, resulting in more hair cracks and reduced hatchability.
- Bigger eggs are more likely to overheat during incubation, resulting in poor chick development and poor chick quality. The reason for this overheating is the higher embryo mass in the egg, resulting in more heat production. Air also does not travel as well in the incubator and, finally, bigger eggs have a reduced shell surface per gram of egg, resulting in lower heat transfer from egg to air.

Egg quality

Chap.I.5 covers egg quality. A very important factor in egg and chick quality is egg sanitation, as embryos are very sensitive to bacterial contamination. Eggs containing gas-forming bacteria tend to explode during the incubation process, spreading out a massive amount of bacteria. Therefore, egg sanitation is a crucial incubation factor. For example, introduction into an egg of bacteria found in the intestinal tract of healthy birds at day 18 of incubation will reduce hatchability to almost zero. When bacteria are introduced into the air cell of an egg, not only is hatchability reduced by 10%, but first-week mortality rate increases dramatically due to navel/yolk sac infection.

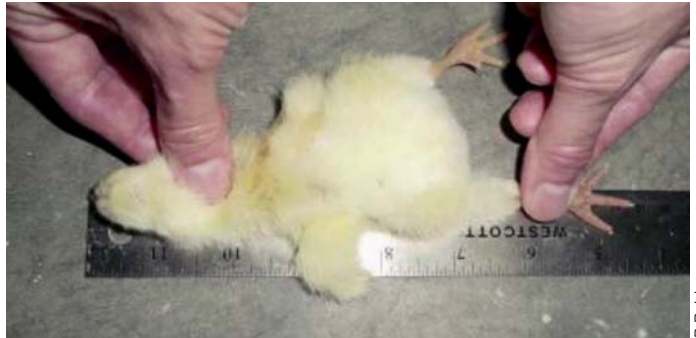
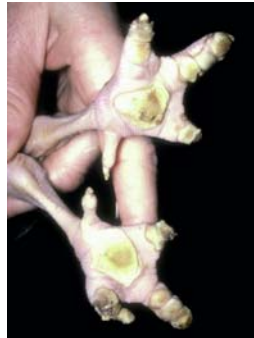
Fig.3.25 & 3.26: Turkey poults. Burns caused by standing on brooder.

Fig.3.27: Evaluation of poor development or poor chick quality can be measured: length of the tibia, length of the spine, or length of the total chick from beak to tip of toe, and amount of residual yolk.

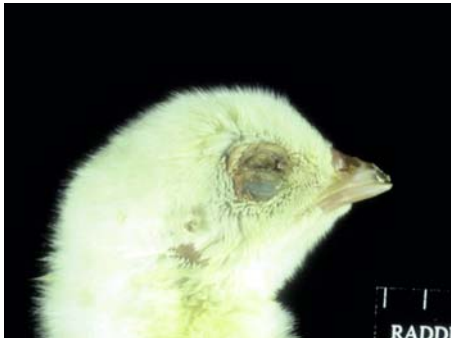

Fig.3.28: Four day-old breeder. Severe beak trim. Swollen eye.

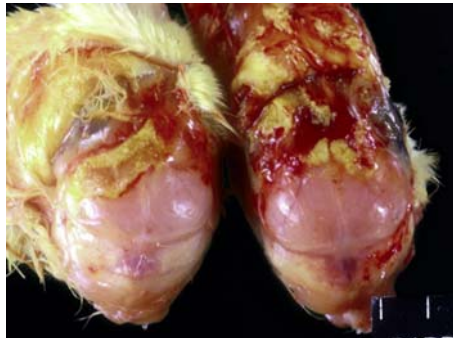

Fig.3.29: *Pseudomonas aeruginosa* contamination of Marek's vaccine will lead to massive mortalities in young chicks.

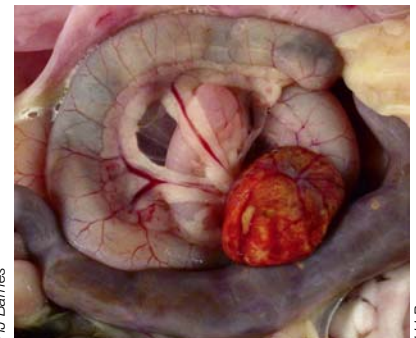

Fig.3.30: Retained yolk sac.

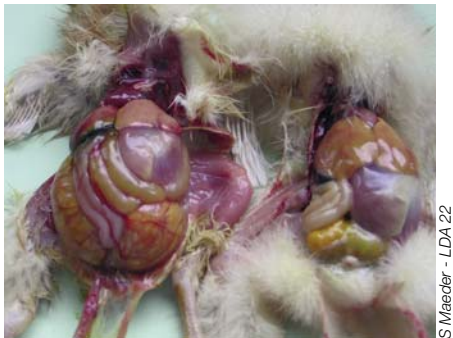

Fig.3.31: Delayed absorption of the yolk sac may lead to omphalitis and septicemia.

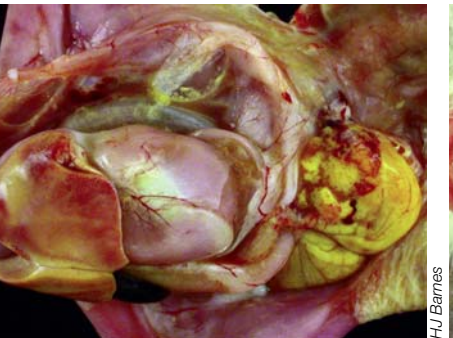

Fig.3.32 & 3.33: Turkey poult with ruptured yolk sac. Yolk sac can be ruptured during sexing. Body cavity can be filled with turbid and yellow fluid.

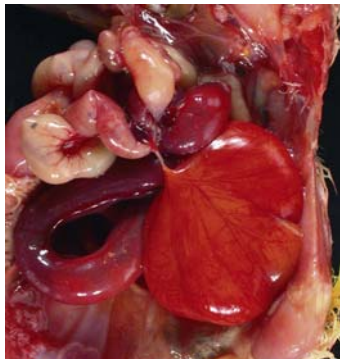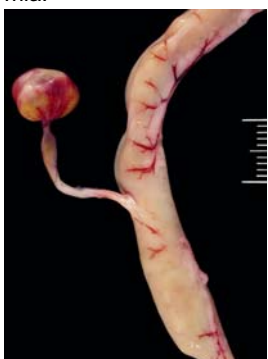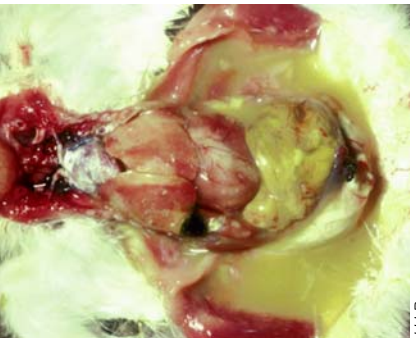


Fig.3.34 & 3.35: Rarely the elongated stalk of the yolk sac will wind around the intestine and cause strangulation (three day-old chicken).

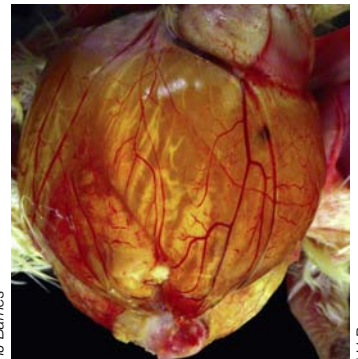
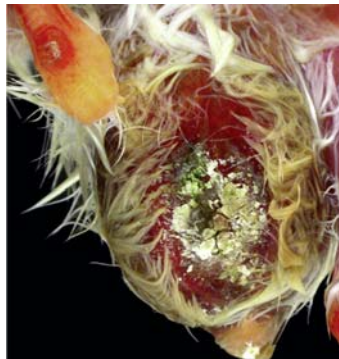


Fig.3.36 & 3.37: Omphalitis (one day-old broiler). Fecal contamination of eggs is considered to be the most important source of omphalitis. Several types of bacteria can cause omphalitis, but *Escherichia coli* is most common. The incidence of omphalitis increases after hatching and declines after about 6 days. Swelling, edema, redness, and possibly small abscesses characterize acute inflammation of the navel.

It has been shown that the explosion of a *Salmonella* positive egg into a hatcher containing *Salmonella* free eggs may result in the infection of all hatched chicks. As day-old chicks have hardly any bacteria in their intestines, any colonizing bacteria introduced at a very early stage can multiply very rapidly. This again stretches the point of egg sanitation, which starts at the breeder farm but needs attention at every stage of the incubation process.

FACTORS RELATED TO THE INCUBATION PROCESS

Incubation is a very delicate process that requires tight control. Many factors influence the transformation of an egg into a day-old chick. During incubation, the environment must be set to favor the optimal development of the embryo. The main factors that can be controlled during incubation are temperature, relative humidity, ventilation and egg turning.

Temperature

The internal temperature of the egg is crucial as it is the driving force of the embryo's metabolism. The internal temperature of the egg is the result of a balance between heat production and heat loss.

Heat production varies throughout the incubation period. At the start of incubation, heat production is practically *nil*. After approximately four days, a noticeable production of heat occurs. Although the nine to ten day-old embryo is only 3 grams in weight, its heat production becomes significant enough that air temperature adjustment is needed to maintain the egg/embryo internal temperature at the desired level of 100-100.5°F (38°C). In the second half of the incubation period, heat production and embryo weight increase very rapidly, and a constant reduction of air temperature is needed.

The amount of embryo heat production varies according to the genetic line. Modern, high yield, fast growing broiler lines produce more heat during incubation than more rustic lines, although reliable scientific data is lacking. Also, bigger eggs produced by older breeder flocks tend to produce more heat than eggs from younger flocks. Eggs from layer breeders seem to produce less heat.

Heat loss of eggs is influenced by air temperature, but also by air velocity over the eggs, as well as by water evaporation. The evaporation comes from the natural moisture loss by the eggs and is partly regulated by the system controlling the relative

humidity in the incubator. Although air temperature in commercial machines is fairly well distributed, air velocity and water evaporation are not. This can lead to significant differences in embryo temperature throughout the machine.

Relative humidity

During incubation, metabolic water formed in the egg is lost through the pores in the shell. This loss in moisture leads to the formation of the air cell, which is opened by the embryo just prior to hatching. During this internal pipping stage, the air is absorbed by the lungs of the embryo, which helps in the process of escaping from the egg shell. It is important that enough moisture is lost to create a sufficient air cell. Ideally, the moisture loss of an egg is approximately 12 to 14% of the initial egg weight. As weight loss of the egg is completely due to loss in moisture, this weight loss can be used to assess moisture loss.

Moisture loss is dependent on the conductance of the shell, and the water vapor pressure inside and outside of the egg. Conductance of the egg is determined during the process of shell formation, and is dependent on genetic line, age of the flock, nutrition and health status of the breeder hen, but it can be altered if, for example, the bird is kept at a different altitude. Water vapor pressure inside the shell varies according to temperature, while outside the shell it varies according to temperature and relative humidity. As temperature during incubation is fixed according to the embryo's needs, relative humidity is the key factor that can be used to alter the loss in moisture of the egg. For optimal incubation results, it is advisable to measure the weight loss of the eggs regularly, and adjust the relative humidity of the air in the incubator accordingly. It is important to realize that changing the relative humidity of the incubator often requires an adjustment of the amount of water sprayed in the incubator. As spraying and evaporation of water has a strong cooling effect, changing the relative humidity can have a significant effect on the temperature and its distribution in the incubator.

Ventilation

Incubators need to be ventilated to allow sufficient elimination of metabolic carbon dioxide and to allow oxygen in the machine. Also, ventilation is used to remove metabolic heat from the incubators, as well as moisture produced by the embryos. In practice, ventilation is more often determined by the need to control heat loss and humidity, than by the requirements in O₂ and CO₂ levels.

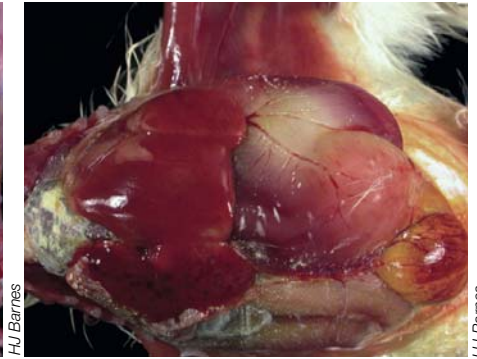
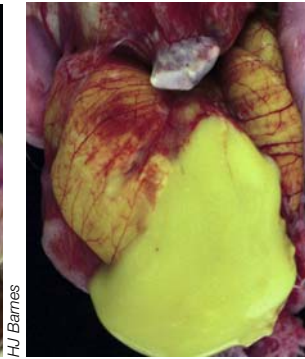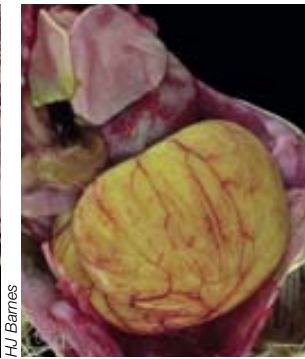

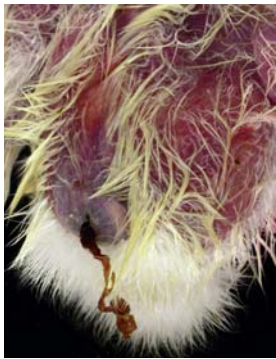
Fig. 3.38, 3.39 & 3.40: String omphalitis (two day-old poult). Affected carcasses may show a distinctive, putrid smell. The yolk, often with a foul odor, may be yellow or brownish green and thickened or watery.

Fig. 3.41: Omphalitis and visceral gout on heart, intestines and kidneys (four day-old broiler).

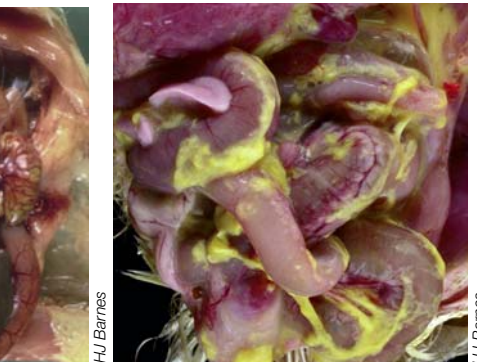
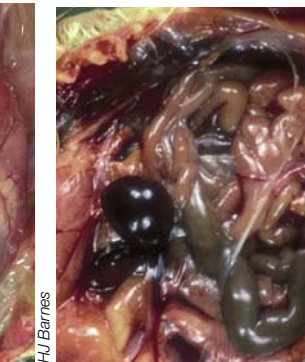
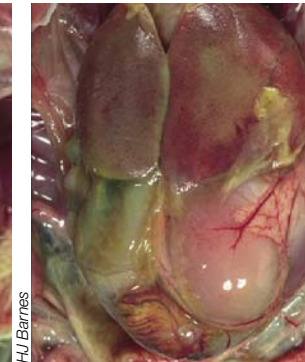
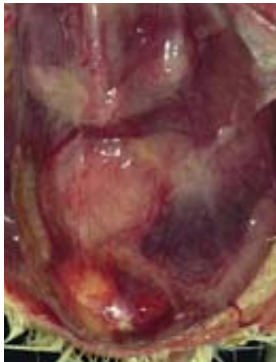


Fig. 3.42, 3.43, 3.44 & 3.45: Omphalitis. Chicks or poults living more than four days with infected yolk sacs may also have pericarditis, splenomegaly, perihepatitis and peritonitis, indicating systemic spread of the pathogen from the yolk sac (Fig. 3.42: five day-old chicken; Fig. 3.43: four day-old chick with septicemia; Fig. 3.44: splenomegaly and septicemia; Fig. 3.45: 10 day-old poult with peritonitis).

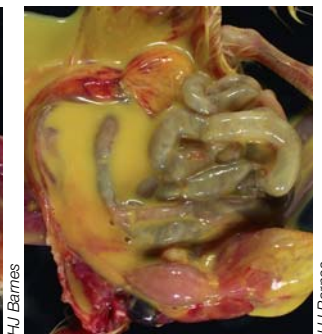
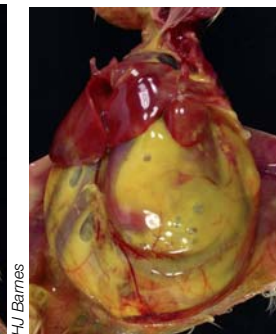
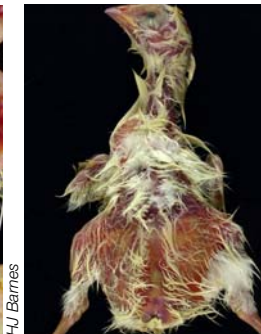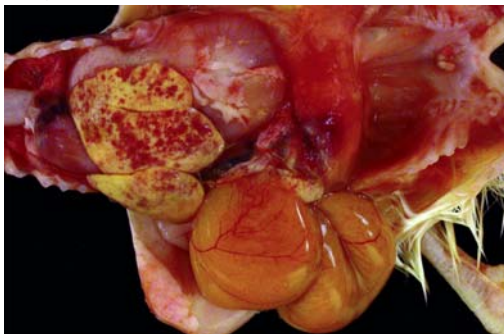


Fig. 3.46: Omphalitis and yolk sacculitis hepatitis. Spread of *E. coli* into the body cavity or colisepticemia.

Fig. 3.47, 3.48 & 3.49: «Mushy» chick (four days old). In severe cases of omphalitis, the body wall and overlying skin undergo lysis and are wet and dirty.

Hatching & processing

During the last three days of incubation, eggs are moved to the hatchers for the final incubation phase. During this period, the embryo needs to prepare to come out of the egg shell. As this process varies depending on the chick, hatching time varies. Often the time difference between the first and the last chick hatching is more than 36 hours. The biggest risk in this process is overheating the hatched chicks, which will try to expel heat by panting. This can dehydrate and weakened these birds.

After hatching, chicks are taken from the hatcher

baskets, selected, eventually sexed and vaccinated, counted, placed in boxes, put in a holding section of the hatchery and finally transported to the farm. The total time between exiting the hatcher and placement on the farm can vary substantially, but is usually several hours. During this time, it is important to avoid any cold stress but conversely to avoid overheating the chicks, as this will influence their survival rate early in life.

Determination of incubation results

Quality of the incubation process is often estimated by determining the number of chicks hatched from the number of eggs set. Of course, this is a

very rough estimation, as fertility of the eggs has a significant influence on hatching results. In a good quality control program, a regular investigation of the actual fertility rate is necessary. This can be done by candling the eggs during transfer to the hatchers at day 18. However, very early mortality cannot be detected at that stage, especially if the eggs are not opened and the blastoderms examined. Candling at seven to nine days provides a more accurate measurement, especially if a number of eggs are opened to assess the true fertility rate.

Regular assessment of eggs that did not hatch, known as a breakout, is advisable. It provides valuable information about the number and causes of deaths for the different stages of development of the embryos, and can be used for further optimization of the incubation process.

Hatching numbers and mortality parameters are not the only indicators of the quality of the incubation process. Chick development and quality parameters can also provide important information about the quality of this process.

CHICK WEIGHT & RESIDUAL YOLK

As mentioned before, chick weight is directly related to egg weight, and since chick weight is related to slaughter weight, higher day old chick weights are considered desirable. However, we have to take into account that the weight of a day old chick is a combination of its real body weight and the weight of the residual yolk. The residual yolk serves as a source of nutrients for the first few days after hatching, but is not an integral part of the chick's body. Residual yolks can vary substantially in size. A target residual yolk of 8-10% of the total chick weight is considered optimal, which in most cases would mean approximately 4 grams. In the field, larger residual yolks, up to 10 to 12 grams, can often be observed, especially with eggs from older breeders. As the residual yolk is not part of a functional organ, a difference of 8 grams in residual yolk between two chicks of equal body weight means a true body weight difference of 8 grams. As the weight of a yolk in a fresh egg is approximately 20 grams, a difference of 8 grams in residual yolk means that a significant part of the yolk was not used for embryo development.

CHICK DEVELOPMENT & QUALITY

Temperature is a key element favoring a chick's development. So, technically, higher temperatures should favor a better development. But as energy sources in eggs are limited, and since the oxygen needed for development of the embryo cannot quickly go thru the eggshell, higher temperatures may result in poor embryo development and quality, because the embryo's demands are not met by the available supply of nutrients. When this happens, the embryo has to find other sources of energy, starting with proteins as source for the energy metabolism, instead of using the yolk fat. This results in a degradation of body tissues, as well as lower development and consequently poorer chick quality. This can be measured: length of the tibia, spine, total chick length from beak to tip of toe, amount of residual yolk. In general, a positive correlation between development and quality can be expected.

The quality of the navel is also a very important determinant of chick quality. In the last days of incubation, the navel is where the residual yolk is drawn into the body cavity. If the navel is not properly closed at the end of this process, bacteria can enter the body cavity and infect the chick. This results in an increase in mortality after approximately three to four days post-hatch. So, a properly healed navel is crucial for obtaining low mortality rates during the first week of life.

Other methods of determining chick quality are based on several parameters such as the evaluation of the navel, mobility of the chick, feather length, color, yolk residue, *etc.* Several methods are available, all having advantages and disadvantages.

REFERENCES

- Cox NA *et al.* Research note: Presence and impact of Salmonella contamination in commercial broiler hatcheries. *Poultry Sci*, 1990,69:1606-1609.
- Dinev I. *Diseases of Poultry, a colour Atlas*. Ceva Santé animale. First edition, 2M Print House Ltd, 2007.
- Meijerhof R & Hulet RH. In ovo injection of competitive exclusion culture in broiler hatching eggs. *J Appl Poultry Res*, 1997,6:260-266.
- Meijerhof R & van Beek G. Mathematical modeling of temperature and moisture loss of hatching eggs. *J Theor Biol*, 1993,165:27-41.
- Weytjens S *et al.* Thermoregulation in chicks originating from breeder flocks of two different ages. *J Appl Poultry Res*, 1999,8:139-145.



Fig.4.1: Egg-type breeder flock in Pennsylvania.

E GINGERICH



Fig.4.2: Placing chicks in cage house.

E GINGERICH



Fig.4.3: Moving pullets to lay house.

E GINGERICH



Fig.4.4: Multi-age layer complex in Pennsylvania.

E GINGERICH



Fig.4.5: Stacked tier, manure belt layer house for 350,000 birds.

E GINGERICH



Fig.4.6: Egg washing equipment.

E GINGERICH

4. COMMERCIAL TABLE EGG PRODUCTION

INTRODUCTION

Shell and egg products are a very important part of the diets of people worldwide, supplying complete protein and energy nutrition plus essential vitamins and trace minerals. In many countries, commercial operations supply a majority of the needs of the consumer. Operation size varies greatly from small farms of 100 to 1 000 birds with a single caretaker to as many as 6 million birds in several houses in a multi-age complex with a hundred or more workers caring for the birds and processing the eggs.

SOURCES OF CHICKENS

Primary breeding companies supply the breeder stock chickens for various breeder/hatchery companies who then supply the day-old pullet chicks to be grown into laying hens. The major breeding companies at this time are the EW Group (Hy-Line, H&N, and Lohmann lines), Hendrix Genetics (Bovans and ISA lines), and Tetra. They supply both white and brown egg commercial lines for breeder/hatchery companies to choose.

These white hybrid layers are capable of laying 324 eggs per hen housed at 72 weeks of age with a feed conversion of 3.04 pounds of feed per dozen or 1.91 kg feed per kg of egg. Brown egg layers are very close in performance with expected 323 eggs per hen housed at 72 weeks of age with a feed conversion of 3.39 pounds of feed per dozen or 2.07 kg feed per kg of egg.

INDUSTRY STRUCTURE

The majority of egg producers purchase day-old pullet chicks from a breeder/hatchery organization. This organization purchases day-old pullet breeder females and males from the primary breeder, grows them in a grower house until point-of-lay, then moves them to a layer house for hatching egg production. This breeder/hatchery company also owns the hatchery from which they ship the day-old chicks. Most operations then grow the day-old pullets in company-owned or contract grow-out housing to point-of-lay, usually about 17 weeks of age. At point-of-lay, the pullets are moved to company-owned or contract layer housing for the egg production cycle. The company normally owns the feed mill for both pullets and layers although some purchase feed from feed mills that use their feed

formulations. The production company usually owns the processing plant as well. For multi-age complexes, the processing plant is normally on site and the eggs go directly into the processing plant and called in-line processing. For eggs produced on farms off site away from the processing plant, the eggs are “farm-packed” meaning they are placed on flats and pallets then shipped to the plant for processing.

Fully integrated companies exist as well and own the breeders, growout houses for breeders, lay houses for breeders, hatchery, feed mill for breeder and layer feeds, grow houses for commercial pullets, lay houses, and processing equipment.

Very few operations are stand-alone independent egg or pullet producers where they sell pullets or eggs on the open market.

BREEDER HOUSING

The grower house is normally all litter with perches and the lay house is either an all-slat high rise house, partial litter partial slat, or all litter floor house. Most modern layer breeder houses now have automatic nests for the birds to lay their eggs and gathering is done by conveyer belt after the eggs rollout from the nesting area. Only nest clean eggs are used for hatching and placed on flats that are placed in a cooler at 55 to 62°F (13 to 17°C). Some operations apply a disinfectant by spray or fogging prior to placement of the eggs into the cooler. Hatch eggs are normally stored for no more than 3 days before shipment to the hatchery. Cull eggs not suitable for hatching, go to a breaker for pasteurization, are sent to the landfill, or are composted.

HATCHERY OPERATION

Hatch eggs are normally set within 1 to 7 days after laying. After incubation at 99.7°F (37.6°C) and 55% relative humidity (RH) for 18 days, they are transferred to a hatcher with flat trays. The egg industry does not utilize *in ovo* Marek's vaccination, as the injection of eggs containing males is cost prohibitive. The eggs remain in the hatcher for 3 days with 99°F (37.2°C) and 55% RH conditions (the RH is raised to 75% after a third of eggs have hatched). The chicks are harvested by separating them from the egg shells and unhatched eggs.



Fig.4.7: Routine bird health examination.



Fig.4.8: Routine necropsies for health surveillance.



Fig.4.9: Spray vaccinator for cage pullet houses.

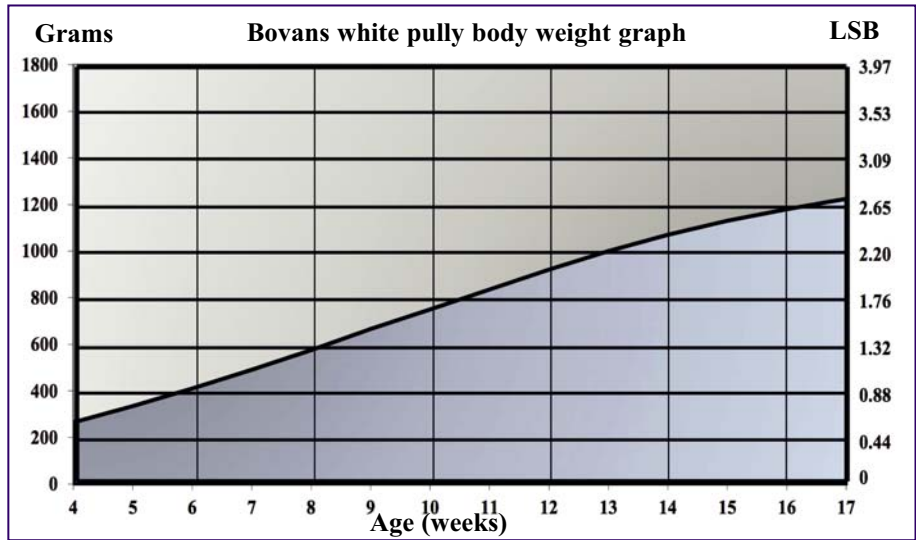


Fig.4.10: Pullet target growth graph from Bovans White 2012 Management Guide.

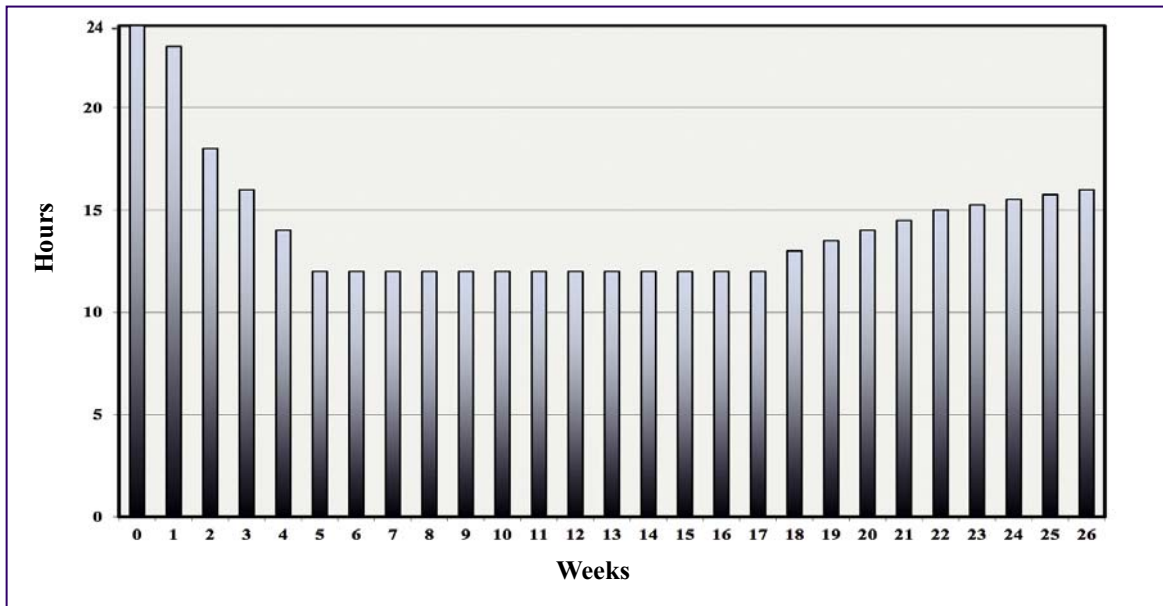


Fig.4.11: Example lighting program from the Bovans White 2012 management guide.

Chicks are then sexed. The white egg layers are feather-sexed (females are fast-feathered and males slow-feathered) and the brown egg layers are color sexed (females have a brown spot on the top of the head and males do not). Only pullets are then vaccinated for Marek's disease and other optional recombinant HVT vectored vaccines, counted into boxes (usually 100 per box), possibly vaccinated with live *Salmonella* and/or coccidiosis vaccines, and moved to the chick holding room. In some hatcheries, an infrared system is used to treat the beaks of chicks to kill the tissue at the end of the beak in place of the standard 7 to 10 day beak trimming done by a hot blade. This device can also be set up to vaccinate for Marek's disease by injection.

Chicks are normally held overnight and delivered to the pullet grow house the next morning in chick trucks that have regulated temperature and humidity condition during transport.

HOUSING SYSTEMS

Growing houses are typically cages (90%+) or litter floor (10%). In cage units, chicks are brooded in one or two tiers of multi-tiered systems with newspaper placed on the cage floor to facilitate movement to feed and water. These papers are removed after 10 days. Each cage has two watering devices, typically nipple drinkers, and feed is mounded in the automatic feeding system and a small amount is placed on the papers. A vitamin-electrolyte mix is often added to the water for the first 3 to 5 days to aid the chicks in getting started. Temperature and humidity levels are critical in getting the chicks started properly. Normally 90 to 92°F (32 to 33°C) in the cage and 40 to 60% relative humidity are desired. In floor houses with litter, brooder stoves provide heat to give 90°F (32°C) underneath the brooder.

The pullets are grown in the growing unit until point-of-lay, usually at 17 weeks of age. In cage rearing, the pullets are spread to all tiers of cages at 3 to 6 weeks of age to give them the proper space, which is normally 44 square inches (284 square centimeters) per bird. Body weights are monitored once a week by weighing at least 100 birds from different cages in a cage house or area of a floor house. These weights are compared to the target weights supplied by the primary breeder for each strain of egg layer. Significant overages or deficits of body weight are addressed by using management practice interventions to correct the situation.

The move to lay unit takes place at around 17 weeks of age using cleaned and disinfected racks and trailers. Crew members also wear cleaned and sanitized clothing, footwear, gloves, headgear, *etc.* Their vehicles are cleaned and disinfected between jobs as well. As with pullet units, in the United States of America (USA), about 90%+ of layers are housed in cages with the rest in cage-free units. Approximately 40% of layers are in high-rise cage units, 50% in stacked tier manure belt housing, and 10% cage-free. There is a split between litter floor and partial or completely slatted floor houses.

FEEDING

Most pullet and layer feeds are fed in the form of mash. Professional nutritionists formulate these rations using a mix of ingredients to supply energy (grains, vegetable fat, and/or animal fat), amino acids (soy meal, meat meal, or synthetic amino acids), calcium (calcium carbonate), phosphorus (inorganic phosphorus products, meat meals), trace minerals, and vitamins.

Pullets are typically fed starter, grower, developer, and prelay rations during the grow period. Each phase has a different level of nutrients to meet the needs of the pullet at the different stages. The starter has relatively high amino acid and energy levels for stimulation of early growth at low feed intakes. The grower and developer have lower energy and amino acid levels due to higher feed intakes at older ages. The prelay is a step-up in amino acids and calcium to transition between grow and lay. Prelay is normally fed for one week and initiated when the birds reach their target body weight for stimulation.

The prelay contains about half of the added calcium as large particles (2 to 5 mm) to aid in retention of calcium in the gizzard to serve as a source of calcium over the night time hours when the egg shell is deposited. The same or higher percent of large particle calcium is continued throughout lay.

Layer rations are most often formulated based on daily feed intake in order to meet the daily nutrient intake requirements. The daily nutrient intake requirements start out relatively higher due to the high rate of egg production, increases in egg weight, and increases in body weight. As the birds age, the nutrient requirements decline due to declining egg production and because of the need to control egg weight.

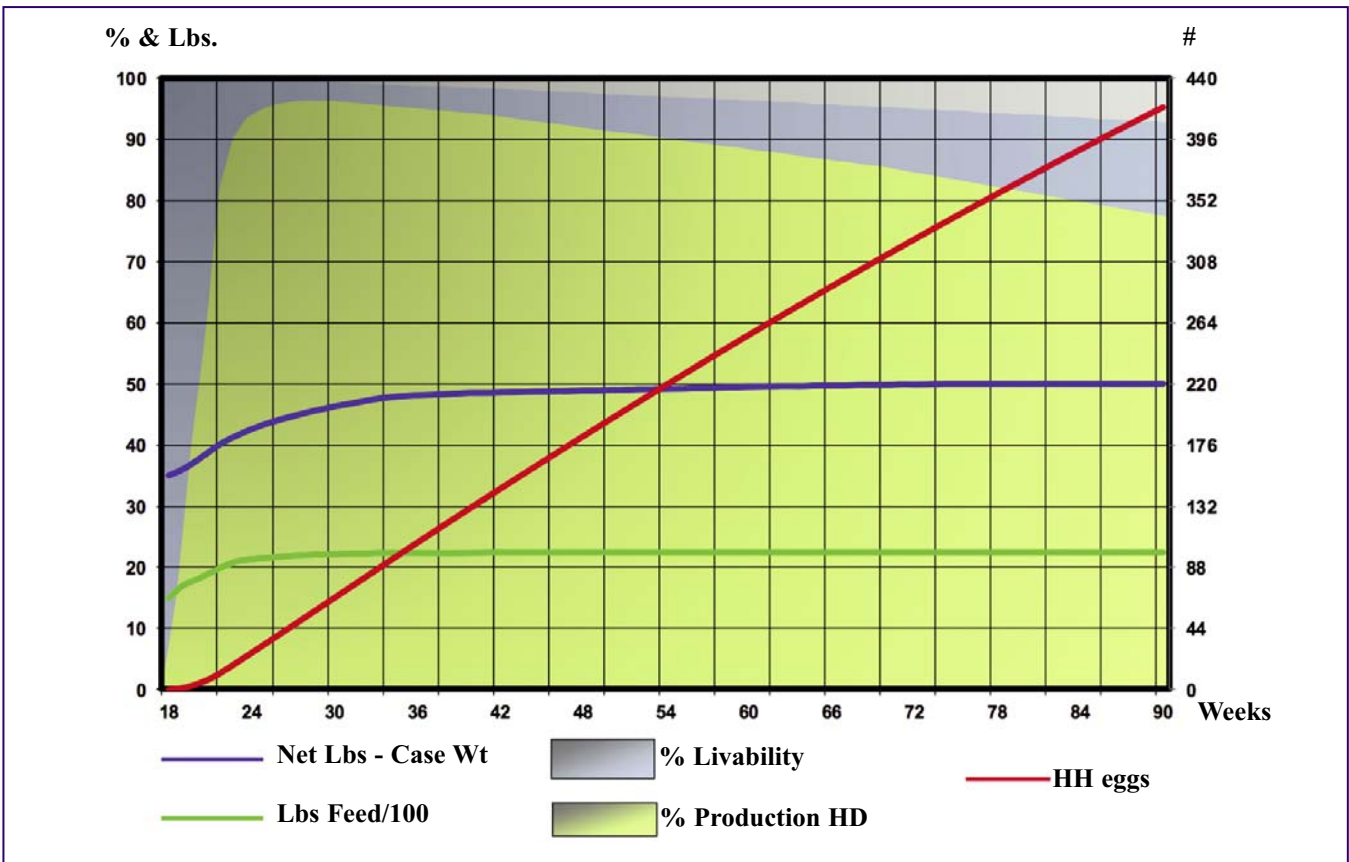


Fig.4.12: Bovans White performance goals from the Bovans White 2012 management guide (USA Standards). Case Wt: 360 eggs weight; Lbs Feed/100: Feed consumption (Lbs)/100 birds daily; HD: per hen per day; HH: per hen housed cumulative.

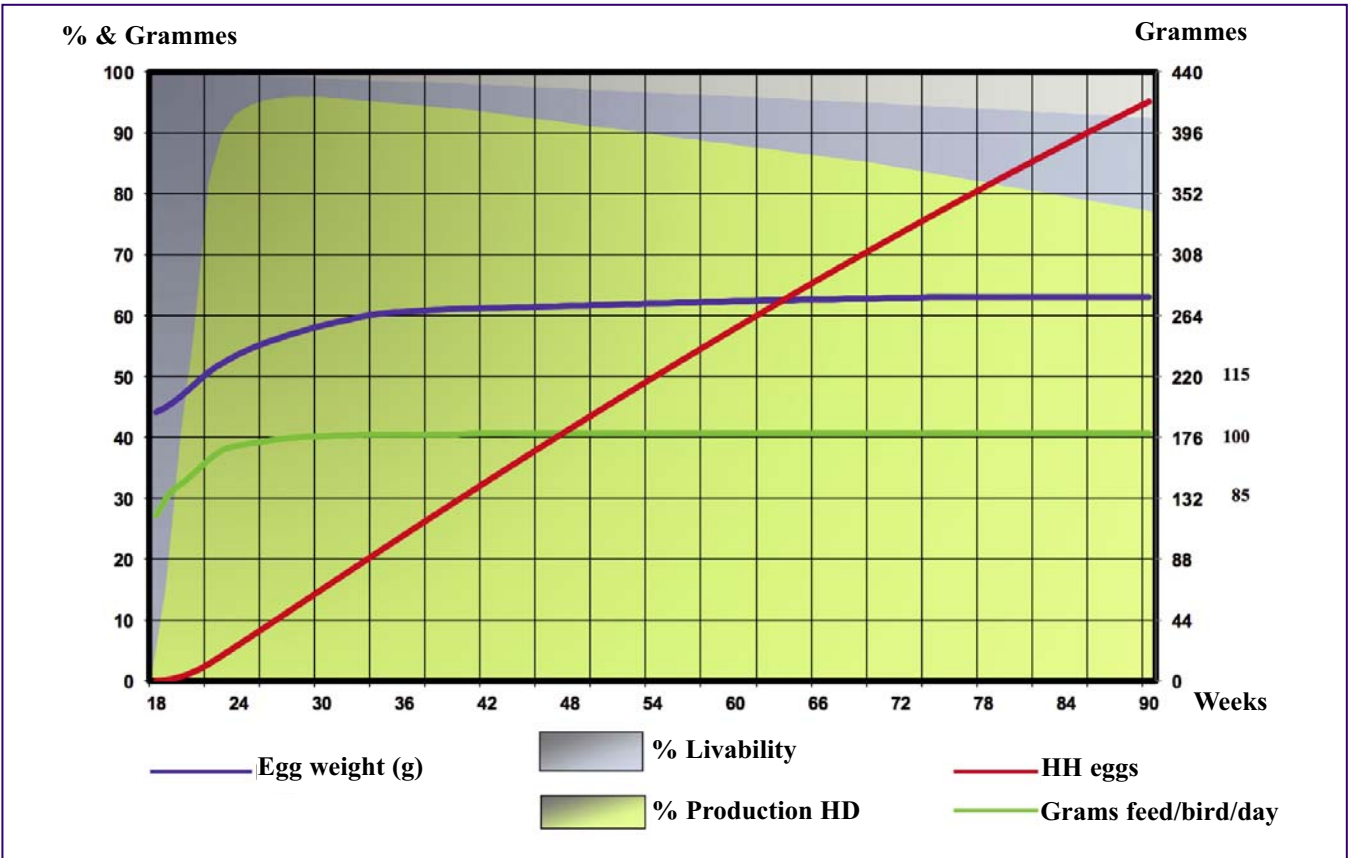


Fig.4.13: Bovans White performance goals from the Bovans white 2012 management guide (metric).

LIGHTING

Lighting programs are utilized to control the onset of sexual maturity and growth pattern of growing pullets. These programs are spelled out in detail in the primary breeder management guides for each bird strain and for different types of housing in regard to outside daylight exposure. In essence, a step-down schedule is used during the first several weeks to start pullets off with a relatively long day to stimulate growth. A constant day length is then given from that point until point-of-lay when weekly increases in day length are given to stimulate the flock into production. The timing of the initiation of this increase is normally triggered by attainment of a target body weight set by the primary breeder rather than by age.

Light intensity is also adjusted to modify bird maturity and/or behavior. Relatively high light intensity (2-3 foot candles = 20-30 lux) is used when chicks are started then lowered (0.25 to 0.5 foot candles = 2.5-5 lux) to aid in maintaining a non-stimulating environment during growing. When moved to the lay unit, the light intensity is normally increased somewhat to a minimum of 0.5 foot candles (5 lux).

Most artificial lighting sources are fluorescent although the newly developed LED (light emitting diode) lights are now coming into use as well. In cases with natural ventilation (curtains) or fans without light traps, light intensity can be very high and result in behavior modification with some strains of layers, i.e. cannibalism, feather pecking, and nervousness. Various light traps or screens are available as solutions to correct problems due to this high light intensity.

VENTILATION

Most modern pullet and layer housing, caged or cage-free, is completely fan ventilated with appropriately placed and sized air inlets to properly direct air flow for dilution of pathogens, control temperature, reduce ammonia, and remove moisture. Circulation fans are also available and appropriately placed to aid in circulating air to avoid temperature stratification especially in the new large multi-tier cage systems.

WATER

Water is a very important nutrient and should be given attention to maintaining high quality. The water source should be free of coliform bacteria, have a pH of 6 to 8, and have relatively low levels

of nitrates (<10 ppm), sulfates (<250 ppm), sodium (<50 ppm), and magnesium (<50 ppm). Continuous sanitation of water to maintain coliform free water at the end of the lines is advised. Water line cleaning to remove biofilms is also advised between flocks using oxidizing products such as peroxide. For more details, see the chapter V.81 on water quality.

EGG PROCESSING

There are two means of processing eggs, 1) shell egg processing and 2) egg breaking for liquid.

U.S. shell egg processing is done either on the same farm as the eggs are produced (in-line processing) or eggs are packed onto flats and pallets (farm-packed), transported to an offsite processing facility (off-line processing). The eggs are processed by first being washed with water that is at least 20°F (11°C) higher than egg temperature and is usually 105 to 110°F (41-43°C). It contains an alkaline egg detergent producing 10+ pH water and the equipment has brushes that aid cleaning by oscillating back and forth while the eggs are rotated on the rolling conveyer. This wash water must be completely changed after 4 hours use. After washing, the eggs are rinsed with water that is 5 to 10°F (3-6°C) higher than the wash water and contains 50 to 200 ppm chlorine. Driers then dry the eggs for proper operation of the dirt and checked egg detection equipment to work.

The eggs are then examined for cracks either by candling or using computer controlled equipment using sonic waves to detect eggs that have cracked shells. The computer will tag cracked eggs by identifying their location on the conveyer and have those eggs placed into flats in the cracked egg lane. Computer controlled equipment is also used to detect dirty eggs. Enclosed boxes containing cameras that take multiple images of the eggs from different angles as they rotate on the conveyer detect specks of feces or dirt on the eggshell surface. The defective eggs are identified by their location on the conveyer by the computer and then either directed to be deposited onto flats in a dirty egg lane or directed to a recycling conveyer that conveys the dirty eggs back to the start of the process to be rewashed. Blood and meat spot eggs are identified in a similar way and sent to the inedible bin.

The eggs are then weighed and deposited into different egg size lanes for packing in flats or cartons. The flats or cartons are then placed in cardboard

cases, taped shut, and labeled with the contents before placement on pallets. The pallets of cased eggs are then placed into the cooler at 45°F (7.2°C). The cased eggs are to be kept at that temperature throughout the trip to and during storage at the retail outlet or food service establishment.

Eggs for breaking and pasteurization generally are sold to food service companies or further processors in bulk but more products for home use are starting to become available. The eggs for breaking are washed and examined for defects just as shell eggs. They then enter a clean room for breaking by a machine that cracks the shell and separates the yolk and albumen into separate systems. The pasteurization process takes place after filtration and homogenization. Combining the albumen and yolk or adding ingredients to the combination or yolk and albumen separately are then options. The temperature and time of pasteurization is different for the different products to be pasteurized. For example, whole egg is pasteurized at 140°F (60°C) for 3.5 minutes while sugared whole egg is treated for 3.5 minutes at 142°F (61.1°C).

LAYER HEALTH MANAGEMENT

Introduction

A team effort characterizes the layer health management program. Veterinarians from various parts of the industry (diagnostic laboratories, vaccine companies, feed additive companies, primary breeder companies, consultants, or company employed) will assist the production management team in all aspects of layer health.

Biosecurity

Biosecurity is the backbone of layer health management. Programs are set up to prevent the introduction of potential pathogens carried in by various sources: equipment (moving of birds, egg trucks, flats and pallets, feed delivery, manure removal, *etc.*), people (workers, veterinarians, repair people, egg truck drivers, crew members to move or place birds, vaccination, beak trimmers, *etc.*), wild animals, rodents, free-flying birds, *etc.* Veterinarians and/or live production managers are responsible for writing SOP's (standard operating procedures) and training on-farm personnel to assure compliance with the programs.

Age	Disease	Vaccine	Route
Hatchery	Marek + IBD	HVT-IBD recombinant + Rispens	Subcutaneous
	<i>Salmonella</i>	Live <i>Salmonella</i> Typhimurium	VC Spray ⁱ
18 days	ND-IB	B1+ Reg Mass + Conn.+ Ark	VC Spray ⁱ
	<i>Escherichia coli</i>	Live <i>E. coli</i>	VC Spray ⁱ
	<i>Salmonella</i>	Live <i>Salmonella</i> Typhimurium	VC Spray ⁱ
35 days	ND-IB	B1+ Reg Mass + Conn.+ Ark	C Spray ⁱⁱ
	<i>Escherichia coli</i>	Live <i>E. coli</i>	C Spray ⁱⁱ
7 weeks	ILT	CEO	Eye
	Pox + AE	Fowl + Pigeon + AE	Wingweb
	<i>Mycoplasma gallisepticum</i>	F strain	Eye
9 weeks	ND-IB	Cloned Lasota + Mass-Connaught + Conn./ Mass Holland (52-72)	F Spray ⁱⁱⁱ
13 weeks	ND-IB-SE	Trivalent inactivated vaccine	Injection
15 weeks	ND-IB	B1 + Mass + Conn	F Spray ⁱⁱⁱ
	<i>Escherichia coli</i>	Live <i>E. coli</i>	F Spray ⁱⁱⁱ

i. VC Spray = Very coarse spray of droplets > 100 microns

ii. C Spray = Coarse spray of 50 micron droplets

iii. F Spray = Fine spray of 5 to 10 micron droplets

Tabl.4.1. Example egg-type pullet vaccination program, USA. HVT: Turkey herpesvirus; IBD: Gumboro disease; ST: *Salmonella* Typhimurium; ND: Newcastle disease; IB: infectious bronchitis; ILT: infectious laryngotracheitis; AE: avian encephalomyelitis; SE: *Salmonella* Enteritidis.

Vaccinations

Vaccines are an essential part of layer health management. The vaccine industry has done a remarkable job in providing high quality, effective vaccines to aid the industry in immunizing growing pullets to withstand the challenges to which they may be exposed during the grow or lay period. Veterinarians and vaccine company technical services people assist in planning the vaccine administration schedule, training of people to properly handle and administer vaccines, and evaluate the results of immunization of the birds.

Cleaning & disinfection of housing

Most all pullet houses are completely dry cleaned, wet washed, preferably with hot water (180°F+ = 82°C+), detergent, and high pressure (180 psi = 12.7 kg force per square centimeter), then disinfected. Standard chemical disinfectants are applied by spray to the point of runoff. In some cases, formaldehyde is applied by thermal fogging. This is mainly due to the presence of pathogenic Marek's virus that has been shed by the previous flock.

If no significant disease issues such as *Salmonella* Enteritidis (SE), influenza, *etc.* have occurred in layer houses, the equipment and houses are normally just dry cleaned. In some cases in high-rise housing, some or all of the manure is left in the pit to allow predator insects to remain to serve as a seed source of predators for improved fly control for the next flock. If a significant disease has occurred during the lay period, the same process as used in pullet grow housing is used.

Routine medications & feed additives

Layers in general do not require many routine medications. Birds on litter will require a coccidiostat unless a coccidia vaccine is used during the

growing period. In the USA, a preventative antibiotic such as bacitracin to prevent clostridial enteritis is usually used until 12 to 16 weeks in litter raised birds. Cage reared birds do not require medication normally. Some layer flocks are fed tylosin starting at the point-of-lay through peak to control mycoplasmosis.

Disease surveillance

Flock supervisors are in charge of monitoring flocks for signs of disease. They do this by examining records of growth rates, egg production, egg weights, feed consumption, water consumption, and mortality rates plus physical examination. Physical examination of flocks may be daily as in the case for a multi-age complex or weekly in the case of smaller units that are in outlying areas from the processing plant. Routine serologic surveillance for diseases like *Mycoplasma gallisepticum*, *M. synoviae*, infectious bronchitis, Newcastle Disease, and avian influenza is done with the frequency depending on the location within a region and state and federal requirements.

REFERENCES

- A Practical Guide for Managing Risk in Poultry Production. R. L. Owen, Editor. *American Association of Avian Pathogens*, Inc. 2011.
- Bovans, Shaver, ISA Management Guides. <http://www.centurionpoultry.com/management-guides/1> or http://www.isapoultry.com/en/products/Commercial_Chicken_Meat_and_Egg_Production, 5th edition. Don D. Bell and William Weaver Jr. editors. Springer Science+Business Media LLC. 2002.
- Diseases of Poultry*, 12th ed. Y. M. Saif, Editor-in-Chief. Blackwell Publishing, Ames, Iowa. 2008.
- Hy-Line International Online Management Guide. <http://www.hyline.com/redbook/RedBook.html>

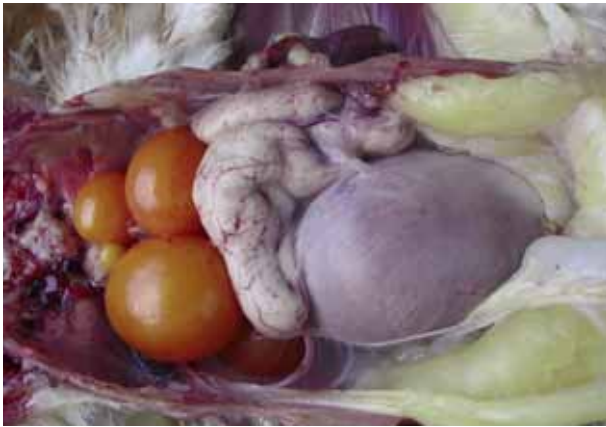

Fig.5.1: The egg is formed gradually over a period of about 24 hours (see Chap.I.10, Fig.10.13).

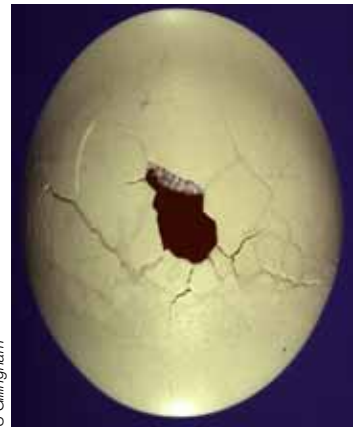

Fig.5.2 & 5.3: Visible cracks usually result in a broken shell membrane. This reduced shell strength may be due to older breeders, poor nutrition (particularly calcium and vitamin D₃), saline water, diseases such as infectious bronchitis, high barn temperature, mechanical damage caused by birds (beak and toenails), infrequent egg collection, rough handling.

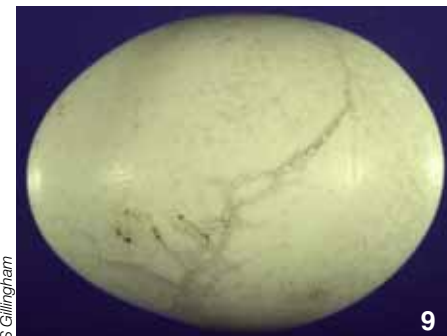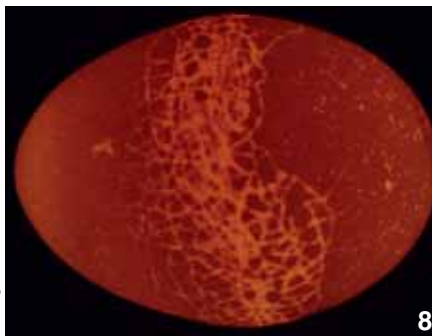
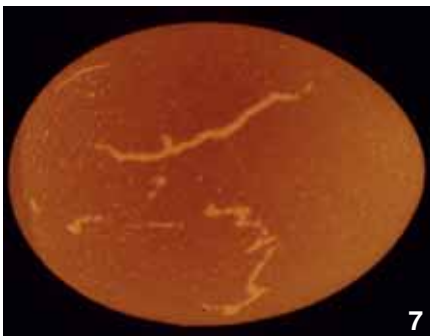
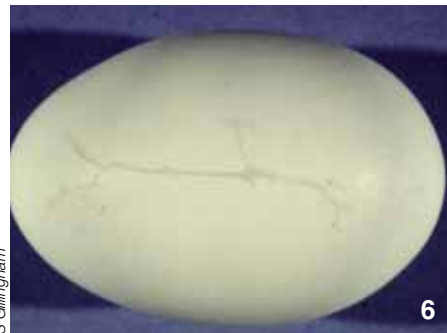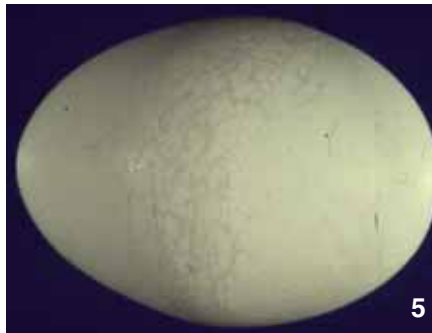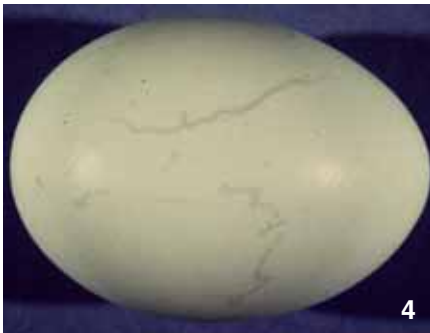


Fig.5.4, 5.5, 5.6, 5.7, 5.8 & 5.9: Hairline cracks are very fine cracks usually running along the length of the egg. The etiology of the problem is the same as for fig.5.2 & 5.3.; one may also consider collisions between eggs or pressure on the egg due to a design problem with the floor of the cage. For fig. 5.7 and 5.8, the egg is placed over a bright light for candling.

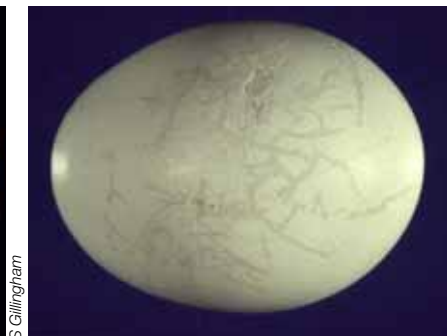
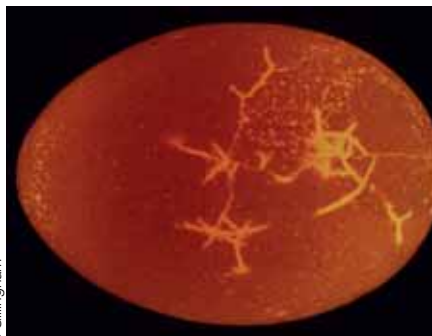
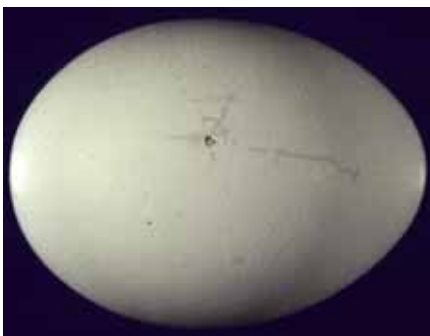

Fig.5.10, 5.11 & 5.12: Star cracks are fine cracks radiating outwards from a central point of impact. The etiology of the problem is the same as for fig.5.2 and 5.3.

5. EGG QUALITY

INTRODUCTION

A good quality hatching egg is crucial for producing good quality chicks. To obtain these quality eggs, attention must be paid to many details, as egg quality cannot improve once the egg is laid. The trend in modern poultry production is towards bigger farms with more automated processes, including egg collection and packing. The same holds for hatcheries. This means that less attention is given to individual egg selection, which increases the importance of having the right conditions at each step of the process in order to obtain predictable results.

Many factors influence the process of egg formation and with it the quality of the egg. Health status and nutrition are without a doubt the most important factors, next to the genetic attributes of the breeder hens. Another determinant of quality is the temperature the eggs are subjected to once they are laid. Indeed, the blastoderm of a freshly laid egg contains approximately 40,000 to 60,000 cells, and needs to be in a specific stage of development for optimal storage conditions. If the temperature of the eggs is above the so-called physiological zero, the temperature at which no development occurs (approximately 26-27°C), development of the blastoderm will continue and can result in an increase in embryonic mortality during and after storage.

One of the biggest risks for egg and chick quality is the contamination of eggs by bacteria. Chicks are very sensitive to bacterial contamination, and a reduction in hatchability and increase in first week mortality will be observed if contamination levels increase. Eggs have a wide range of defense mechanisms against bacterial penetration. A rigid shell structure is a very obvious one. Another important mechanism is the increase in albumen pH occurring within a few days after lay. Due to the release of carbon dioxide, albumen pH rises from 7 to 9.3, which constitutes an effective protection against microorganisms. However, this increase in pH takes two to three days, which means that immediately after lay this defense mechanism is not so effective. Furthermore, immediately after lay, the egg temperature drops and an air cell is formed with air entering the egg. This is why it is very important to produce eggs in a clean environment. Once the egg is older and stored at a low temperature, the risk of micro-organisms penetrating is reduced.

A thick and rigid eggshell is always a plus for table eggs. This is not the case for hatching eggs. In fact, a very thick eggshell lowers conductance resulting in a reduction in gas exchanges and in moisture loss during embryonic development. This means that one should not increase calcium levels or apply any other method to increase shell thickness in breeders as it may be done for table egg production, unless shell quality does need improvement. Indeed, thin shells are a problem because eggs are more fragile and gas exchange/moisture control is as well affected.

EGG LAYING

In modern poultry production, eggs are produced in laying nests. Traditionally these nests are small wooden boxes with a thick layer of litter material (oat hulls, rice hulls, straw, wood shavings, etc.), in which the eggs are protected until they are collected by hand. More recently, a shift towards roll-away nests has occurred, in which the eggs roll away to a central belt after being laid. This automates the process, providing optimal egg collecting conditions and reducing labor costs. Egg cooling is also improved, which has a positive effect on hatchability, especially in older breeder flocks. By contrast, eggs laid in traditional nests rest on isolating litter material keeping them warmer, especially when another hen comes into the nest to lay an egg. To avoid this problem, eggs in these nests must be collected at least four times a day, especially during warm periods.

Eggs that are not produced in the laying nests or eggs laid in nests that do not contain a sufficient amount of clean nesting material have an increased risk of contamination. As the egg temperature drops immediately after being laid, going from the hen's body temperature to ambient temperature, the egg content shrinks, creating a vacuum in the egg. This produces an air flow through the pores of the egg, creating a potential risk of contamination if bacteria, molds or droppings are on the eggshell. Any cleaning or disinfection after the eggs have reached ambient temperature will reduce the risk (if done correctly) because it is difficult to totally eliminate all contaminations. Therefore floor eggs should be considered second-grade eggs, even when visually clean, and should be labelled as potentially dirty eggs for the hatchery.

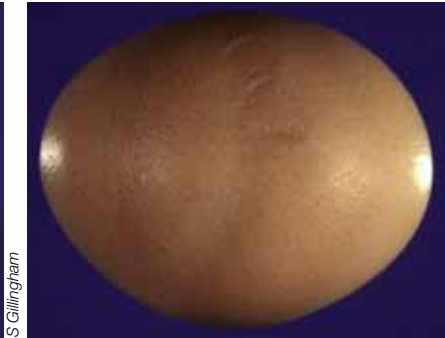
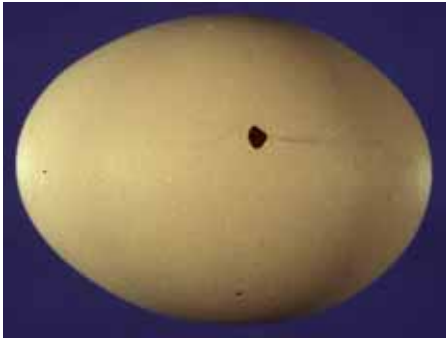
Fig. 5.13: Pinholes, or very small holes in the eggshell, may result from a flaw in the egg shell formation or from pimples being knocked off the shell. Both problems can be associated with older breeders, poor nutrition, strain of bird, damage from toenails or other small sharp projections.

Fig. 5.14 & 5.15: Flat-sided eggs where part of the shell is flattened or indented. Often the adjoining part of the shell is wrinkled. The cause is traditionally linked to infectious bronchitis but it can also be due to stressors, e.g., frights and disturbances, crowding, incorrect (or important changes) in the lighting program.

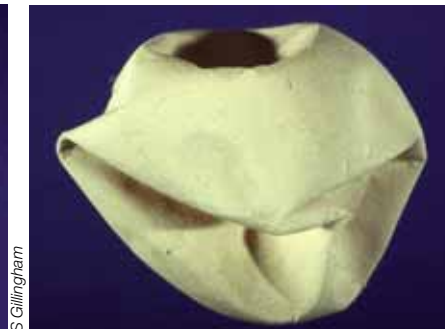

Fig. 5.16, 5.17 & 5.18: Thin shelled eggs and shell-less eggs. They are commonly produced by pullets coming into lay, particularly by birds that have matured early. The causes are immature shell gland, defective shell gland, poor nutrition, saline water, diseases, e.g., infectious bronchitis and egg-drop syndrome.

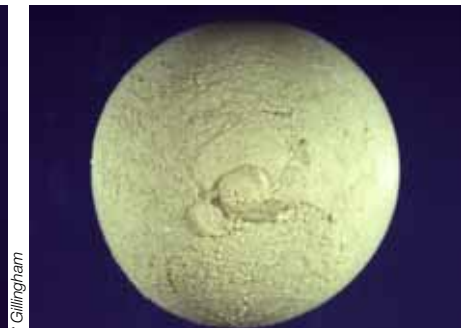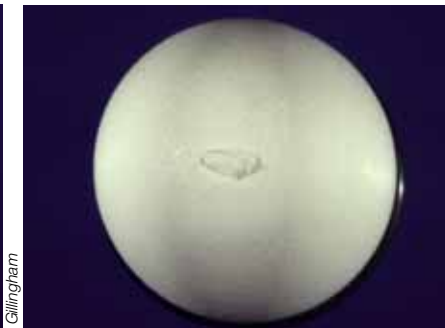
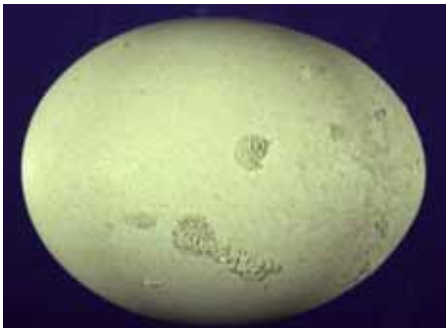


Fig. 5.19, 5.20 & 5.21: Calcified material on eggshells. Pimples are small lumps of calcified material on the eggshell. Some can be easily removed without damage to the shell while others may leave a small hole. This could be caused by foreign material in the oviduct, which may be associated with age (older breeders), poor nutrition and strain of bird.



Fig. 5.22, 5.23 & 5.24: Misshapen eggs are those with shells obviously different from the expected smooth, normal shape. This may occur in hens with an immature or defective shell gland; with diseases, e.g., infectious bronchitis; stresses, e.g., frights and disturbances, overcrowding.

HATCHING EGG SELECTION

Eggshell quality is an important aspect of hatching egg selection, as eggs with poor shell conditions do not hatch as well as eggs with good quality shell. Eggs with moderate or severe shell defects and unclean eggs should be culled during collection rather than be sent to the hatchery for setting. Setting those results in a decrease in chick quality because as they often are more easily penetrated by bacteria, they have an increased risk of contamination and this increases the number of exploders (contaminated eggs that contain gas forming bacteria). As exploders can contaminate hundreds of other eggs and increase dramatically the bacterial load in the hatcher, they should be avoided as much as possible.

Eggs with minor defects or small stains can be used. It is up to the person that does the collecting to decide which eggs are acceptable for setting. As there is often a conflict of interest between the hatchery (wanting to have eggs as clean as possible) and the breeder farm (wanting to deliver as many eggs as possible) good communication between the hatchery and the breeder farm is essential to determine what is acceptable in terms of egg quality. In this context, routine reporting of chick and egg quality from the hatchery to the breeder flock manager is essential. If reporting only occurs when there is a problem, this will not favor constructive discussions between the two parties.

There are many types of egg defects that justify a culling decision. One group of defects has a mechanical origin and obviously occurs after the egg has been laid. The occurrence of cracked, stained, dirty, punctured or in any other way damaged eggs should be prevented by good management practices in the breeder house; other factors should also be considered, namely the health status of the flock and its nutrition.

Biological factors can influence egg quality. Stressors and certain diseases can affect the oviduct and ovaries, and will result in thin or wrinkled egg shells. Infectious bronchitis and the egg-drop syndrome are good examples. Especially in broiler breeders, feeding and lighting programs just prior to the start of the laying period and during early production will influence the maturation of the birds, which can influence egg quality as well. Early maturation and over-stimulation of birds will cause erratic ovulations, which is a major cause of defective eggs. Erratic ovulation results in more than one yolk present in the reproductive tract at the same time, as the frequency of releasing yolks

from the ovary is too high. This means more chance of double and triple yolks, more disturbance during the 20 hour period that is needed for shell deposition in the shell gland, slab sided eggs, wrinkled eggs and in extreme situations internal laying, resulting in a yolk mass in the body cavity. A stressing event may also abruptly stop the egg formation, resulting in breaks during shell formation followed by repair with the deposit of additional shell material. This often happens when the flock is disturbed late in the afternoon.

Nutrition has a big influence on egg shell quality. Not only will an inadequate balance of minerals such as calcium and phosphorus result in poor shell quality, but the diet can also influence feces production, which can result in an increased number of dirty eggs.

The ambient temperature influences shell quality. Low temperatures will increase feed intake and with it the intake of minerals, but high temperatures will result in panting. This will influence the acid-base balance in the blood, which will negatively influence calcium deposition and shell quality.

EGG WASHING & DISINFECTION

Good washing procedures are available for washing dirty eggs, but one should be aware of the limitations of these procedures. They will help removing dirt and may prevent further contamination. However, they cannot completely take away contamination that occurred immediately after lay. In other words, egg washing cannot replace good hatching egg management; it can only be in support of good management.

Washing can potentially cause cross contamination when water and detergent are re-used and not replaced frequently enough. Poor washing procedures may actually increase contamination instead of diminishing it. Good washing procedures require controlled temperature and processing time, detergent and a water replacement protocol. One consequence of egg washing is the removal of the cuticle, the wax-like cover of the egg shell. This cuticle acts as a barrier against microorganisms, especially immediately after lay when the pH of the albumen has not yet increased sufficiently, but it also can limit the conductance of the eggs. If egg conductance is low, for instance when eggshell is very thick or the cuticle is very rigid, removing the cuticle can sometimes have a small beneficial effect. Especially duck eggs and turkey eggs can benefit from washing or rinsing with solutions that take the cuticle off.




Fig.5.25, 5.26 & 5.27: Rough or sand paper shells are seen in eggs with rough-texture areas, often unevenly distributed over the shell. The cause can be infectious (Infectious bronchitis, infectious laryngotracheitis or avian encephalomyelitis) or management related: disturbances at the time a hen is due to lay cause the egg to be held over for another day; incorrect (or important changes) in the lighting program; water shortages.

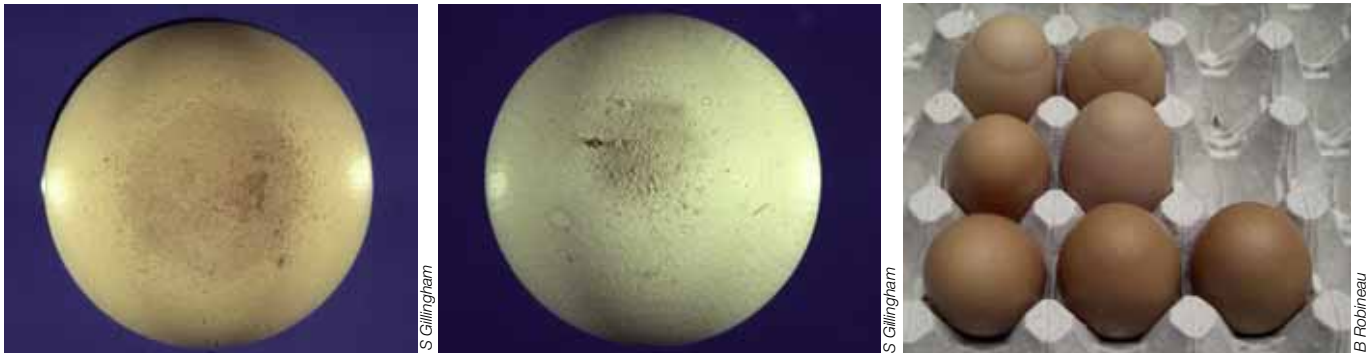


Fig.5.28, 5.29 & 5.30: Eggshell apex abnormalities (EAA) are a novel eggshell pathology characterized by an altered shell surface, thinning, increased translucency, cracks and breaks in the apex of the egg; it is associated with *Mycoplasma synoviae* infection.



Fig.5.31 & 5.32: Dirty eggs. The eggs must be clean to be marketed.

Fig.5.33: Egg with scratches. Egg cleaning should avoid scratching which can eliminate the cuticle serving as a barrier against microorganisms.

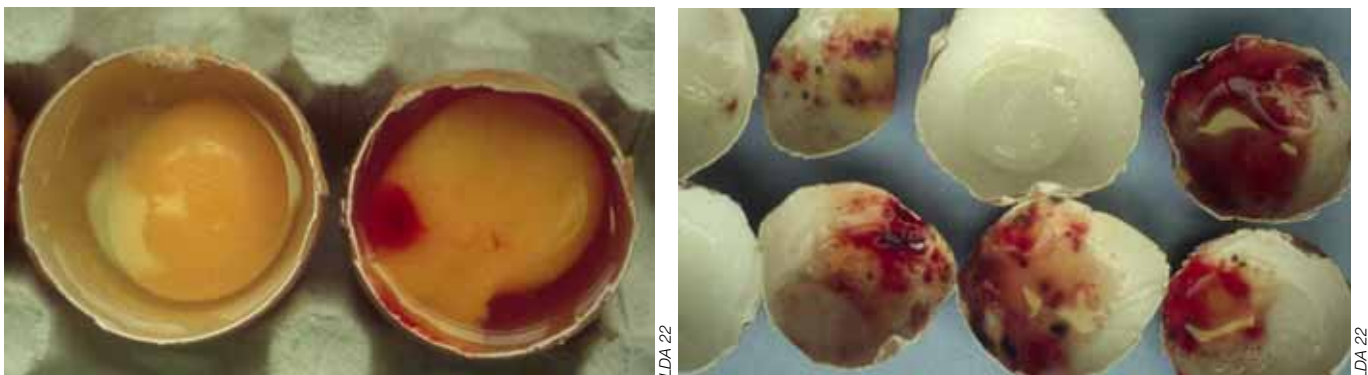

Fig.5.34 & 5.35: Blood spots. The cause is the rupture of blood vessels in the ovary or oviduct. The cause for the case shown here is fungal toxins. Other causes are vitamin K antagonists (e.g., sulfaquinoxaline), avian encephalomyelitis, wrong lighting program etc.

Egg disinfection as soon as possible after collection is recommended to prevent the spreading of any pathogens on the eggs, and to prevent cross-contamination between farms and from farm to hatchery. Disinfection with formaldehyde is the preferred method, but is nowadays recognized as being a health and environmental hazard. Alternative methods of disinfection are often based on spraying a liquid (hydrogen peroxide or quaternary ammonium solutions) which are also effective but requiring more care in their application. The use of liquid methods of disinfection at the farm has not been very successful in commercial broiler operations, although the system by itself can function well.

Farm disinfection should not replace hatchery disinfection, as it is crucial to disinfect at the hatchery as this is a critical control point in terms of biosecurity. There is a potential risk if disinfection is applied both at the farm and at the hatchery, if the time lap between the two disinfections is too short. It is advisable to allow at least 24 hours between two disinfectant applications.

EGG STORAGE

Egg storage reduces hatchability and chick quality, especially when breeder flocks are getting older and egg storage time exceeds 5 to 7 days. Although there are substantial genetic differences between lines and breeds, normally it can be expected that hatchability will go down after 5 to 7 days by approximately 0.5% per extra day. The longer the storage time after 7 days, the greater the impact. Egg storage also adds time needed for the eggs to hatch. The general assumption is that one day of storage adds one hour to the incubation process, probably due to a weaker embryo that needs more time for its development.

Setting the eggs immediately after lay reduces hatchability as well. Although the negative effect on hatchability of a very short storage time is limited to a maximum reduction of 1-2%, it is advisable to store eggs for at least 24 hours but preferably 48 hours before setting. This is probably related to the increase in pH of the albumen needed for optimal embryo development. A rapid increase in the pH of the albumen by exposing the eggs for a short period to ammonium gas reduces the negative influence of a very short egg storage time.

To limit the negative effects of storage, it is advisable to reduce the storage temperature if eggs are to be stored for a long period. If eggs are stored for a maximum of 4-5 days, a storage temperature of

20-22°C is recommended. From 4-5 days up to 8-10 days, eggs should be kept at 18°C; and storage temperature should be reduced to 16 degrees if eggs are stored up to 14 days. If egg storage exceeds 14 days, it is advisable to reduce the temperature even further to 14°C. Keeping eggs at a low temperature during short storage periods is not so much a problem for the egg itself, but it makes it more difficult for the incubators to uniformly warm up the eggs in an adequate period of time. Although this factor seems to be marginal, one should realize that a modern incubator can contain over 100,000 eggs, which means that often the egg load in the machine exceeds 6000 kg. As eggs have thermal properties that can be compared with water, it means that the equivalent of 6000 liters of water have to be uniformly and quickly warmed up by air. Reducing the temperature of the eggs more than needed makes this process more complicated. Another negative effect of reducing the temperature of the eggs more than necessary is the risk of condensation ("sweating") on the eggs. When egg temperature is below the dewpoint of the room in which they are brought, condensation will occur which will lead to an increase in the level of bacterial contamination. This should always be avoided.

Eggs should be stored under the physiological zero. If eggs are not cooled fast enough, or for instance are kept in the sun for a few hours, embryo development will start. If afterwards the embryo is cooled down again, the early mortality rate of these embryos will increase. It is therefore very important to continuously control the temperature during storage, but also to uniformly cool the eggs to reach air temperature. This can be done by creating air velocity in the egg storage room, which will increase heat transfer. Once all eggs are at the desired temperature, no additional air velocity is needed, other than to keep the air temperature uniformly distributed.

Eggs that are stored for periods exceeding 10 days will benefit if they are turned once or twice a day over a 90 degree angle, or if they are stored with the pointed end of the egg facing up. Storing the eggs in this position or turning them daily will prevent that the blastoderm sticks to the shell membrane.

Embryos have an optimal stage of development for storage. If breeder flocks are very young, sometimes this stage of development is not yet achieved. In this case, temporarily warming the eggs is reported to have beneficial effects. However, it is risky as eggs that develop beyond the optimal stage

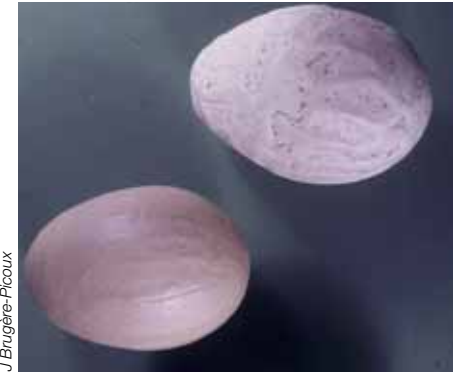

Fig.5.36: Typhosis. Heterogeneity of egg size, small eggs, smaller eggs without vitellus, altered eggshell (soft and easily broken), deformed eggs.

Fig.5.37 & 5.38: Infectious bronchitis affecting eggs. Thin-shelled, rough, and misshapen eggs laid by infected hens.



Fig.5.39: Infectious bronchitis. Eggs are more or less discolored, dirty and bloodstained.

Fig.5.40: Infectious bronchitis. Eggs are discolored, small, deformed and "ringed"; altered eggshell tend to break easily.

Fig.5.41: Infectious bronchitis. From top to bottom: control eggs, bloodstained eggs, smaller eggs, altered eggshell (soft and easily broken), deformed eggs.



Fig.5.42 & 5.43: Infectious bronchitis (on left). The internal quality of eggs may also suffer. In this photograph the light is being reflected from the outer ring of a watery egg white and there is no internal ring of albumen like in normal egg (on right).

Fig.5.44: Osteoporosis (soft eggshell).

will have reduced hatchability, and it is difficult to predict the correct stage of development without extensive examination of the eggs.

MOISTURE LOSS

Often relative humidity levels in storage rooms are increased to prevent the loss of moisture. Excessive moisture loss will decrease egg weight, especially if storage times are extended; it is sometimes assumed to reduce hatchability, although this effect is not clear. However, increasing the relative humidity in a storage room is not without risk, as it requires spraying water in the room, which represents a risk of egg contamination equal to condensation. As storage temperatures are normally reduced when storage times are extended, the level of moisture loss will be reduced as well, due to a reduction in the water vapor pressure deficit, the difference in water vapor pressure between the eggshell and air that is the driving force for the loss of moisture.

To prevent moisture loss, it is advisable to keep the egg storage room closed (no ventilation). This means that the egg storage room should be separated from the egg handling room, and should only be opened when eggs need to be taken in or out. In

this way, the evaporated moisture from the eggs will be kept in the storage room, and no additional spraying is needed to prevent the eggs from losing excessive moisture. Furthermore, it decreases energy costs, as there is less of a need for cooling and heating. Air velocity does not influence moisture loss, as the role of the eggshell in restricting this loss is much larger than the “drying” effect of air velocity.

REFERENCES

- Coutts JA et al. Optimum egg quality. A practical approach. *State of Queensland and DSM Nutritional products Ltd.* Brisbane, Australia, 2007, 63p.
- Meijerhof R & van Beek G. Mathematical modeling of temperature and moisture loss of hatching eggs. *J Theor Biol*, 1993, 165:27-41.
- Meijerhof R et al. Influence of pre-incubation treatment on hatching results of broiler breeder eggs produced at 37 and 59 weeks of age. *Br Poult Sci*, 1994, 35: 249-257.
- Reijrink IAM et al. Influence of egg storage time and preincubation warming profile on embryonic development, hatchability, and chick quality. *Poultry Sci*, 2010, 89: 1225-1238.

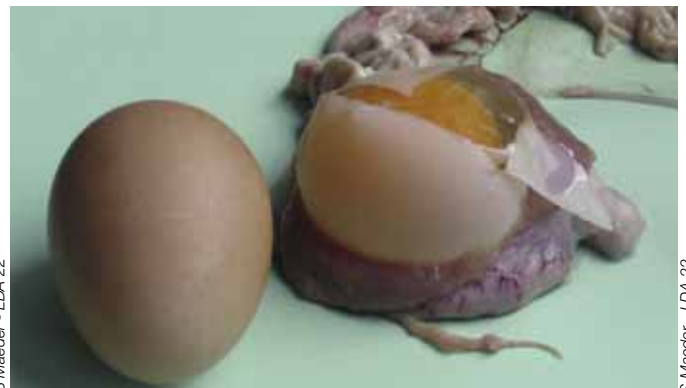
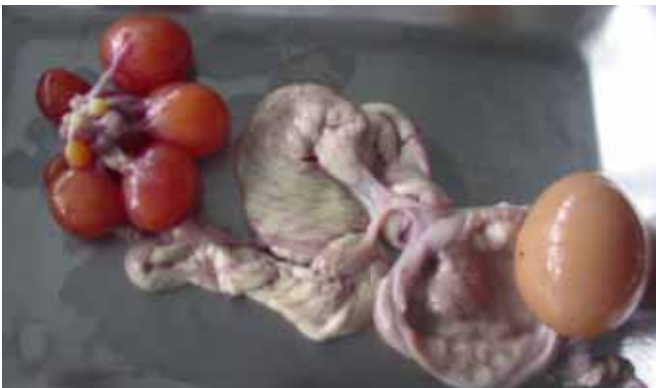
Fig.5.45 & 5.46: The shell of each egg should be smooth, clean and free of cracks. The egg of chickens should be uniform in color, size and shape.

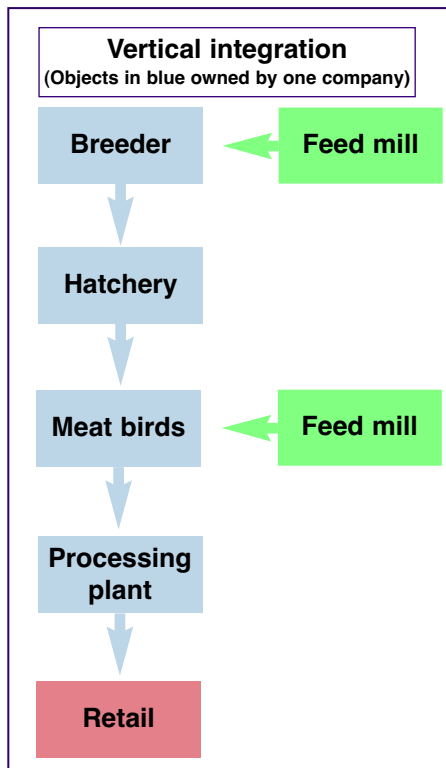


Fig.6.1: Vertical integration.



Fig.6.3: House prepared for poult arrival.

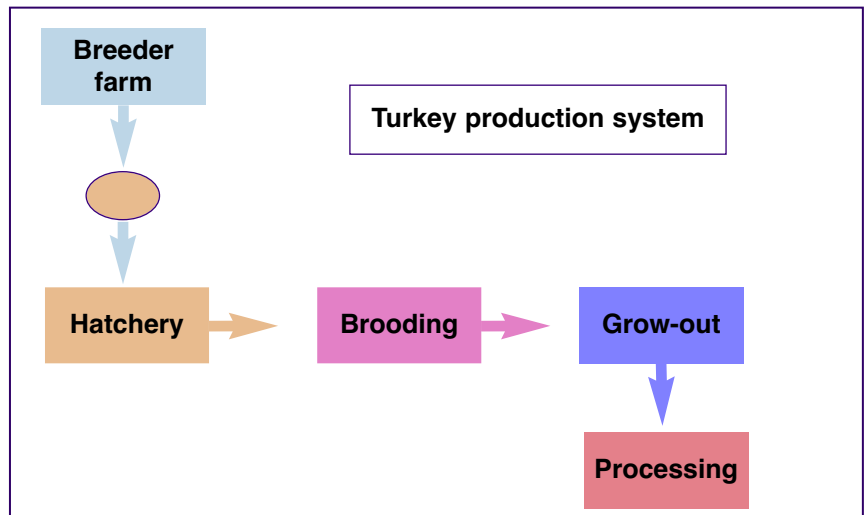


Fig.6.2: Turkey production system.

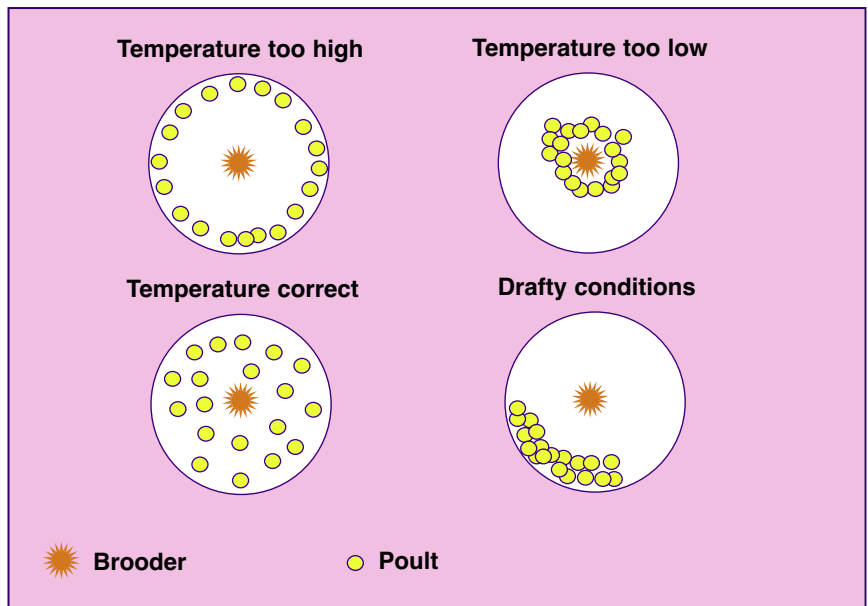


Fig.6.4: Poult distribution by brooder temperature.

Daily Water Consumption (1 000 turkeys) (75°F to 90°F or 24°C to 32°C)		
Age in weeks	Gallons	Liters
1	11	42
2	28	107
3	39	147
4	57	215
5	67	254
6	89	338
19	275	1041
20	277	1049
21	280	1061

Tab.6.1. Water consumption.

Age (Weeks)	Target temperatures (°F)	Target temperatures (°C)
1	84 (77-90)	29 (25-32)
2	81 (75-88)	27 (24-31)
3	78 (73-86)	25 (23-30)
4	75 (71-84)	24 (22-29)
5	72 (69-82)	22 (21-28)
6	70 (67-80)	21 (19-27)

Tab.6.2. Target temperatures for brooding.

6. TURKEY PRODUCTION

INTRODUCTION

Turkey meat is valued as a healthy protein source for humans. It is produced in areas of the world where environmental conditions are conducive to profitability, where a source of feed is readily available, and where a sufficient supply of good quality water is available for growing and processing turkeys.

Turkey production is dependent on growing facilities being in close proximity to feed mills and processing plants. Many turkey companies are vertically integrated, which means that nearly all areas of production are controlled by the company. While growing turkeys is not difficult, there are a number of guidelines that if followed generally result in a more profitable operation.

FEEDING

Modern turkeys have been genetically selected for rapid growth with muscle development primarily on the breast and legs. This efficient protein production depends on a constant supply of high quality feed that is balanced in nutrients, amino acids, and minerals. Modern feed mills produce feed formulated for the growth needs of turkeys during each phase of production. Some turkey flocks will eat 6-7 different diets during the production cycle of 20 weeks or less. The specific feed demands of turkey flocks must be met in order to reach the genetical potential of the birds. Even short periods of decreased feed consumption due to disease or mechanical problems can result in decreased weight gain and increased growing times.

WATER

Clean, good quality water is essential for turkeys. Though surface water and water from shallow wells can be used for turkey production, deep well and municipal water sources are best for turkey production. Turkeys drink large volumes of water each day and even small amounts of bacteria or other contaminants can adversely affect weight gains or in some instances cause death. The drinker type is not as important as the proper adjustment of the drinkers, the sanitation of the drinkers, and the quality of the water flowing through them. Water administration of vaccines and antibiotics is the method of choice for large populations of birds and its effectiveness is dependent on good water quality. Good water quality and availability are essential for efficiency in turkey productions.

POULT PRODUCTION

Turkey production relies on a constant source of poults. Providing poults to turkey meat growers is a complex process of growing turkey breeders which are not grown for meat but for the production of fertile eggs. These breeders are selected as breeding stock and are maintained for as long as they are productive. Fertile eggs are the foundation of turkey production and are transported from breeder farms to hatcheries where they are incubated for 28 days. Once eggs hatch, the poults are sexed (hens and toms are grown on separate farms) and vaccinated before being shipped to the grow-out facilities. Some poults are shipped for long distances in trucks with controlled temperature and humidity. Most poults are placed on farms within a few hours distance from the hatchery.

BROODING

Poults like most birds are unable to maintain their required body temperature for the first few weeks of life. A warm environment must be provided for poults during this period. This is referred to as the brooding period. Poults are placed in a house on new softwood shavings and provided supplemental heat which is lowered by a few degrees weekly. Cardboard rings are set up to keep the poults near the heat source. The goal of the brooding period is to stimulate activity, eating and drinking. Supplemental drinkers and feeders are generally used during the first few weeks in order to assure that poults readily find these resources. Poult behavior is a good indicator of their comfort levels and should be monitored frequently. Chilled poults tend to huddle together underneath the heat source and over-heated poults tend to move away from the heat source. Recommended brooding temperatures are provided to growers so that they can maintain temperatures for optimal growth. Turkey poults are generally brooded for 5-6 weeks.

GROWING

Once the brooding period is complete, turkeys continue to eat and grow until they reach the desired weight for processing. Turkeys that are processed as whole birds are targeted to be processed between 13-15 weeks (depending on rate of gain). Birds grown for further processing are generally scheduled to be processed at or after 20 weeks of age. As the birds grow they become more crowded



Fig.6.5: Brooder house.

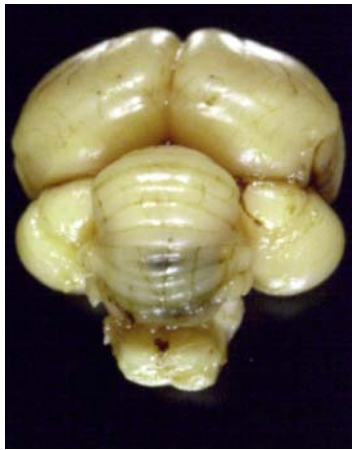

Fig.6.6 & 6.7: Accident vaccination during the first week of life in a poult.

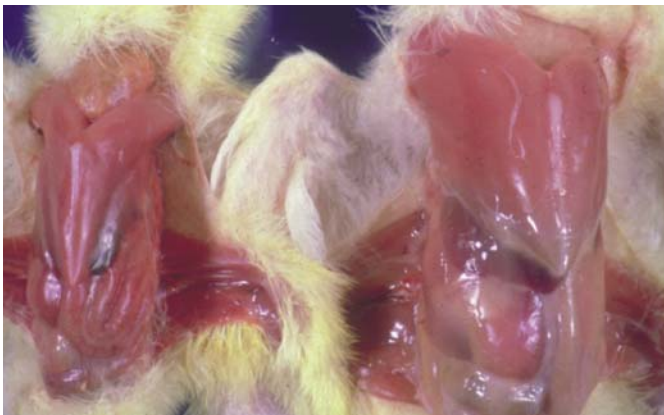
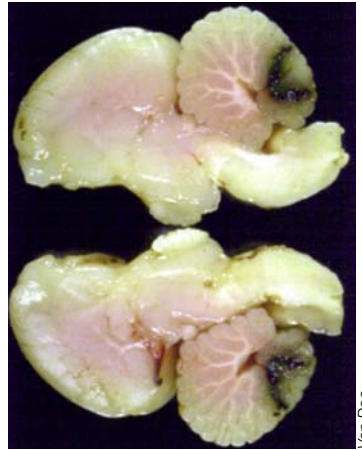

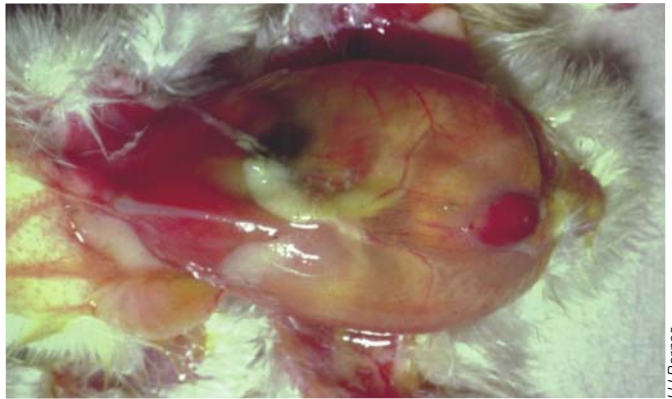
Fig.6.8: Poult on left is a "starve out" exhibiting cachexia, large gall bladder and dehydration.

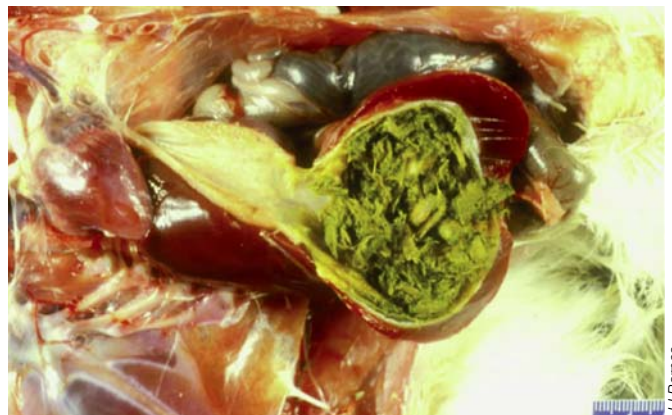

Fig.6.9: Ventriculus contains shavings rather than feed which is a typical finding in poults that starve.



Fig.6.10 & 6.11: Omphalitis with typical distended abdomen and inflamed navel (red disc).



which can result in the development of behavior problems in some birds. Maintaining good animal welfare is important throughout the life of the flock, but can become more difficult to manage as the birds approach processing.

PROCESSING

Processing is the ultimate goal of the turkey production cycle. Birds are scheduled to go to the processing plant when they are within a few

pounds of their target weight. All medications and coccidiostats must be withdrawn from the flocks in order to adhere to all withdrawal times dictated by regulations.

Feed is removed from the flock for a number of hours before processing in order to clear the intestines of feed and feces. Birds are provided water until they are placed on trucks for hauling to the processing plant. Hauling distances and times vary, but are generally no more than an hour or two to

prevent dehydration and subsequent shrinkage of the carcass. Once inside the plant birds are inspected and can be condemned for specific diseases or for fecal contamination. Birds arriving with empty intestines are less likely to be condemned for fecal contamination.

DISEASE

Disease prevention is important throughout the production cycle. Sick birds do not convert feed to muscle very efficiently. Those with disease when processed are at risk of condemnation. Two major management factors related to disease are ventilation and litter management. Maintaining good ventilation while brooding is a challenge because brooding temperatures must be maintained and draftiness minimized. Ventilation benchmarks are dependent on age of birds and ambient environmental conditions. Ventilation equipment should be calibrated often and adjustments made as needed. Litter should be managed to reduce moisture as microorganisms enjoy a moist environment. Keeping litter dry discourages bacteria and survival of parasite eggs. Daily removal of wet litter complemented by raking especially around feeders and drinkers reduces pathogens and maintains litter quality for the well-being of the birds' feet and legs.

While biosecurity plays a major role in disease prevention, vaccines are used extensively to minimize the effects of diseases. Vaccines should be used to prevent or reduce untoward effects of diseases known to occur in areas near turkey farms.

Minimizing risk is the objective of vaccinating so diseases with an already low risk of infecting a given flock should not be the focus of a vaccine program. Diseases known to be high risk for bird exposure should be considered first when establishing a vaccine program. The benefits of a vaccine regimen should outweigh the cost of administering vaccines. Regional variation in vaccine programs reflects this concept of local risk.

Antibiotics are also utilized to minimize disease both prophylactically and therapeutically. While this has been an important tool in reducing production losses in turkey flocks, judicious use of these products is heavily scrutinized in some countries. A number of antimicrobials have been banned or allowed on a limited basis. As antimicrobials are prohibited, diseases once considered rare are re-emerging.

Mortality in poults is largely due to management factors both from the hatchery and on the farm. Poults often die due to a failure to eat and drink which results in dehydration and starvation. This can be due to hatching conditions that result in poults placed with little reserves for exploring their environments. Temperature and humidity in the hatchery can also contribute to poult mortality in the form of omphalitis or infections resulting from poult processing. Poult mortality can also be attributed to management practices such as inferior ventilation and temperatures. While infectious diseases are a cause of poult mortality, most early deaths are related to a difficult transition from the egg to the farm.

CHALLENGES FOR FUTURE TURKEY PRODUCERS

Turkey meat will continue to gain in popularity as consumers demand a healthy source of protein. The challenge will be to maintain the healthy perception of turkey meat through vigilant adherence to production practices that minimize contamination from microbiological and pharmaceutical threats. As antimicrobials become less available or less effective, turkey producers will by necessity develop a more creative approach to disease prevention and treatment.

REFERENCES

- Aviagen: *Management Essentials for Commercial Turkeys*. www.en.aviagen.com
- Diseases of Poultry*, 12th ed. Saif YM Ed. Blackwell Publishing, Ames, Iowa. 2008.
- National Turkey Federation*. http://www.eatturkey.com/foodsrv/pdf/NTF_animal_care.pdf
- Poultry Focus*. Intervet. 2005. http://www.msanimal-health.co.uk/binaries/92_103278.pdf.
- Turkey Care Practices*, University of California Davis. http://www.vetmed.ucdavis.edu/vetext/INF-PO_TurkeyCarePrax.pdf
- USDA: http://www.ars.usda.gov/research/publications/publications.htm?seq_no_115=222670
- Wheeler E et al, P. Litter Management Strategies in Relation to Ammonia Emissions from Floor-Raised Birds in *Mitigating Air Emissions From Animal Feeding Operations Conference*. Iowa State University Extension. 2010. http://www.ag.iastate.edu/wastemgmt/Mitigation_Conference_proceedings/CD_proceedings/Animal_Housing_Amendments/Wheeler-Litter_management_strategies.pdf

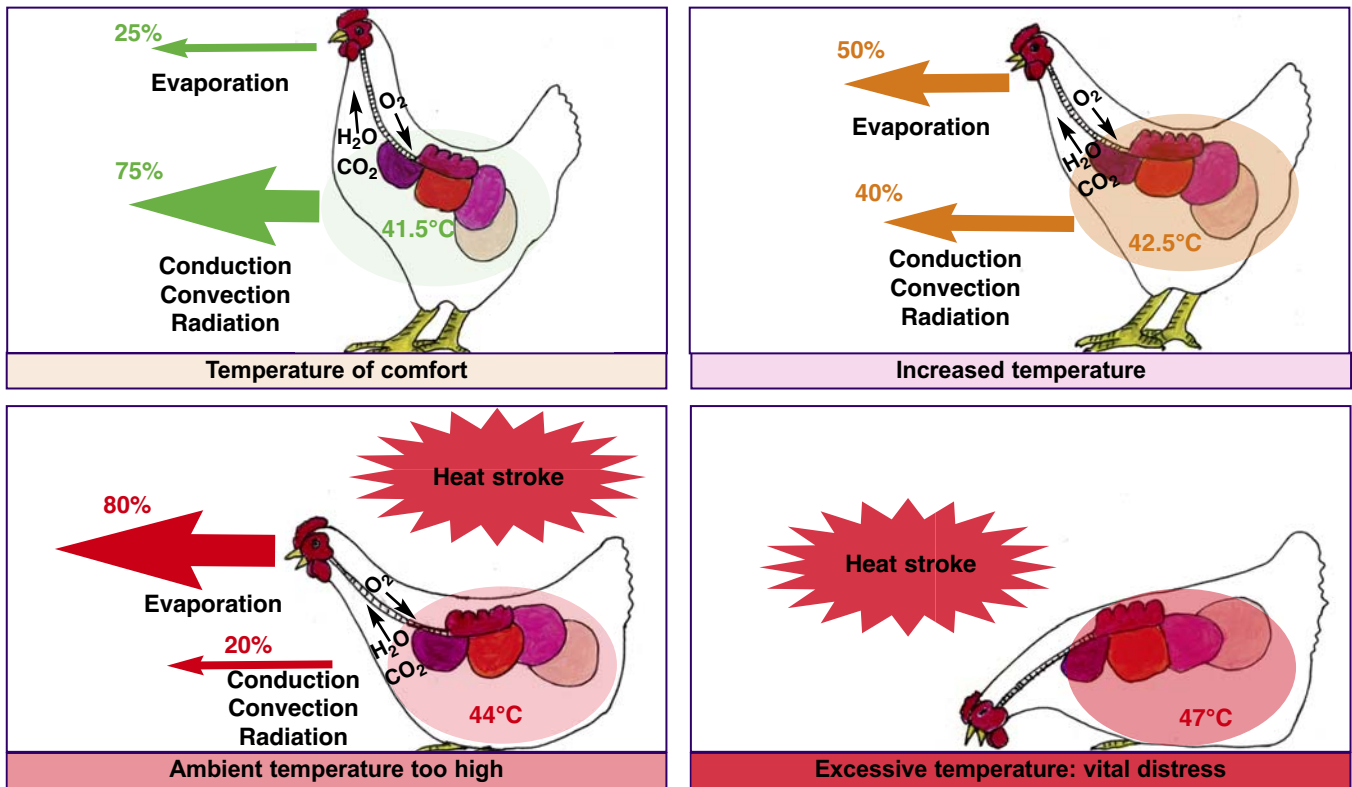


Fig.7.1, 7.2, 7.3 & 7.4: Phases of thermal stress. In the context of a comfortable environment, temperature maintenance is carried out essentially by passive heat loss. When the ambient temperature increases, birds fight against an elevation in body temperature by increasing their heart rate and respiration. If their body temperature is too high, birds lie down with high heart and respiratory rates associated with blood alkalosis and dehydration. Finally, excessive heat causes vital distress with eventually a reduction in the respiratory rate. Evaporation is insufficient if the relative humidity is too high. The increased body temperature causes death.

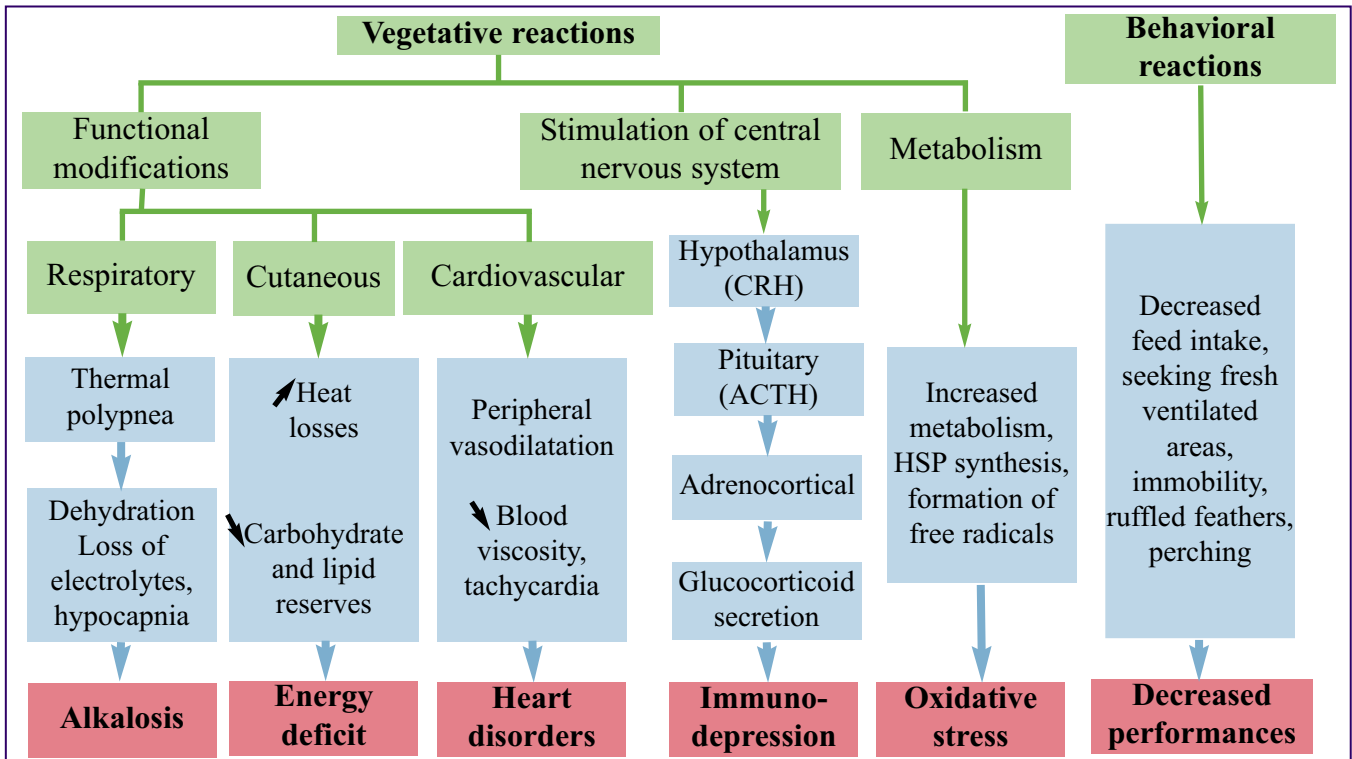


Fig.7.5: Disturbances during heat stress. CRH : corticotropin-releasing hormone ; ACTH: adrenocorticotrophic hormone ; HSP: heat shock proteins.

7. BREEDING IN HOT CLIMATE

INTRODUCTION

Heat can be very costly for the poultry industry. We must distinguish production regions in countries where it is normally warm from regions where heat spikes may occasionally be recorded. In warm countries, measures must be taken to continue to produce and avoid poor flock performances associated with heat, whereas in areas where temperature increases are only occasional, not all mitigating measures can be economically justified.

PHYSIOLOGICAL ASPECTS IN POULTRY

Thermoregulation

Birds are homeotherms. They are able to adapt their metabolism and behavior to maintain constant internal temperature. This adaptation effort is essentially nil when birds are within the thermal neutral zone. Indeed, they do not have to use large amounts of energy to control their temperature within the thermal neutral zone. Birds will respond to excess heat by decreasing thermogenesis and increasing thermolysis.

Reduction of thermogenesis

In a hot environment, the metabolism of birds is very low, movements are very limited and feed consumption decreases.

Increase in thermolysis

Increase in thermolysis comprises sensible heat and latent heat.

Sensible heat is lost in droppings and eggs, but mostly at the surface of the body by three mechanisms:

- 1) **Radiation**: If the surface body temperature is higher than ambient air, heat is lost by radiation;
- 2) **Conduction**: Heat loss by conduction is possible only when the body is in contact with a conductive medium such as a wet building wall or floor of the house;
- 3) **Convection**: The air warming on contact with the body of a bird expands and rises, bringing calories with it; this movement is facilitated by ventilation and heat losses augment as air speed increases.

Heat removal by these three mechanisms is facilitated by the intervention of a set of vegetative and behavioral reactions:

- **Vegetative reactions**. Such reactions can be summarized as an increase in heart rate and vasodilation at the level of the epithelia of the respiratory tract, legs, comb and wattles.
- **Behavioral responses**. The birds avoid their flockmates, seek contact with cold objects, look for ventilated or shaded areas, spread out their wings and lie down on the litter. These behavioral responses are very effective on free-range farms, but less effective in intensive poultry production and are even completely impossible in cages.

Latent heat is expressed as the amount of water evaporated from the bird. Since birds do not have sweat glands, the respiratory tract is the main route of elimination of water vapor. The inhaled air is drawn into the respiratory tract and becomes progressively loaded with water vapor up to saturation. Heat is released with the water vapor. The amount of heat loss will depend on the ambient temperature and relative humidity.

The increase in respiratory rate increases the amount of heat removed. The frequency goes from 30 cycles/min when the body temperature is 41°C to 160 cycles/min at a body temperature of 44°C. This phenomenon, called «panting» or thermal hyperventilation, begins when the ambient temperature is 29°C with normal humidity, or at 27°C with high humidity.

Heat shock proteins

When chickens are exposed to a temperature of 41°C, there is an increase in the synthesis of heat shock proteins (Hot stress protein: HSP) which are of different types. Among them, we find:

- The HSP70 synthesized by hepatocytes which improve the resistance of chickens to heat by accelerating the recovery of nucleolar morphology after heat shock.
- The HSP20 are abundantly expressed in smooth muscles. They serve a significant role in preventing platelet aggregation and in regulating activities of vasodilation.

Environment	Feed intake Consumption (g/hen/day)
Temperate/tropical (24-44 weeks) 20°C 65% RH 30°C 90% RH Variation in %	121 94 -22%
Hot dry/hot humid (21-49 weeks) 20°C 65% RH 20°C 65% RH Variation in %	97.3 86.6 -11%
Cyclic temperature/constant (23-40 weeks) 25°C 30% HR 30°C 65% HR Variation in %	99.4 92.4 -7%

Tabl.7.1: Effects of varying the temperature and relative humidity (RH) on feed intake (according to Uzu, 1989).

Score	Characteristics	Value of e	
		White Strain	Redhead strain
2	Almost complete	735	650
3	Areas partially uncovered	785	700
4	Several areas completely uncovered	875	790

Tabl.7.2: Energy requirement (e) for bird temperature maintenance depending on feathering score.

e = Energy requirement for maintenance depending on feathering

Environment	Laying performances		
	% laying	Mean egg weight (g/egg)	Production (g/hen)
Temperate/tropical (24-44 weeks) 20°C 65% RH 30°C 90% RH Variation in %	93.9 81.2 -14%	59.4 55.2 -7%	55.8 44.9 -20%
Hot dry/hot humid (21-49 weeks) 20°C 65% RH 20°C 65% RH Variation in %	79.3 76.7 -3%	60.4 58.9 -2%	47.9 45.1 -4%
Cyclic temperature/constant (23-40 weeks) 25°C 30% RH 30°C 65% RH Variation in %	79.3 72.9 -8	58.8 58.7 0	46.6 42.8 -8%

Tabl.7.3: Effects of varying temperature and relative humidity (RH) on egg production (according to Uzu, 1989).

EFFECTS CAUSED BY HEAT

Effects of heat on feed consumption

Feed intake

The reduction in feed intake can be estimated to be:

- 1.5 g per °C of temperature increase between 26 and 32°C

- 4.2 g per °C of temperature increase between 32 and 36°C

This decrease in feed intake is more important if the temperature increase is accompanied by an increase in relative humidity.

Energy

In light poultry strains, the regulation of feed intake may be a function of the energy content of the diet, as long as the ambient temperature does not exceed much over 30°C. The change in energy intake depends also on feathering and air velocity as expressed by Emmans' formula that calculates energy intake:

$$(E.M./j) = W^{0.75} (e - 10.5 T) + 8.4 E + 21 dW$$

e = Energy requirement for maintenance depending on feathering

T = Temperature

E = egg production in g/d

dW = body weight gain in g/d

Proteins

Protein requirements remain constant even at high temperatures. Nitrogen retention is highest between 16 and 22°C and decreases on both sides of these two values. Due to the decrease in feed intake and lower nitrogen retention in hot climates, it is necessary to increase dietary protein concentration.

Effects of heat on water consumption

An increase in ambient temperature results in noticeable increase in water consumption once ambient temperature reaches at least 20°C: it is multiplied by two when the temperature rises from 21 to 32°C and it is multiplied by three when it goes from 21 to 37°C. The Water/Feed ratio increases rapidly as the temperature increases, reaching values close to eight at around 37°C.

Effects of heat on growth

In broilers, the decrease in daily weight gain can be explained by the decrease in bird metabolism and intestinal nutrient absorption.

Effects of heat on viability

Mortality from heat stroke is mainly due to heart failure associated with nervous disorders resulting from alkalosis and chronic hypoxia.

Effects of heat on egg laying

High temperatures affect the quality and quantity of egg production. This impact is due to a decrease in energy intake and in various nutrients, and to a disruption of homeostasis and reduction of blood flow in internal organs, including the ovary, in favor of peripheral tissues.

The resulting drop in egg production is more important when the temperature increases in conjunction with an increase in relative humidity. Egg weight reduction comes with greater shell fragility due to alkalosis and calcium leakage.

Effects of temperature cycles

Even in warm countries it is rare that environmental temperatures remain constant during a 24-hour cycle, and temperatures of 35°C can be very well tolerated on the condition that the time of exposure is limited to a few hours, the humidity is low, and each day birds have a period during which the temperature drops to about 25°C. Also, the acclimatization of birds can improve their resistance to heat.

One study compared the effect of exposure of two broiler lots older than 59 days at a temperature of 40.6°C. In the first lot, reared for 56 days at 21°C and then exposed to temperatures of 24, 35 and 24°C during the three days preceding the test, no mortality was recorded, while in the second lot raised for 59 days at a temperature of 21°C (and then exposed to 40.6°C), a 33% mortality was recorded.

Another study compared the behavior of two layer lots in the Sudan and in Britain at different ambient temperatures. The tolerance to heat was evaluated by rectal temperature variation expressed as °C/hour. Poor tolerance corresponded to an increase in rectal temperature of 2°C/hour, while

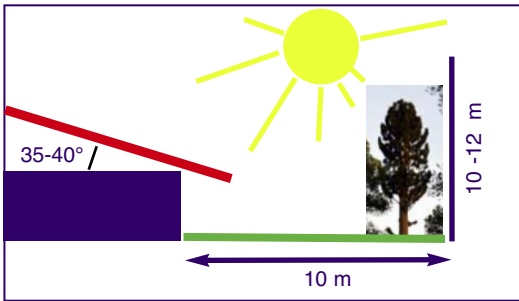


Fig.7.6: Roof edge overhanging to protect the walls. A wall in the shade receives 30% less radiant heat than a wall in the sun.

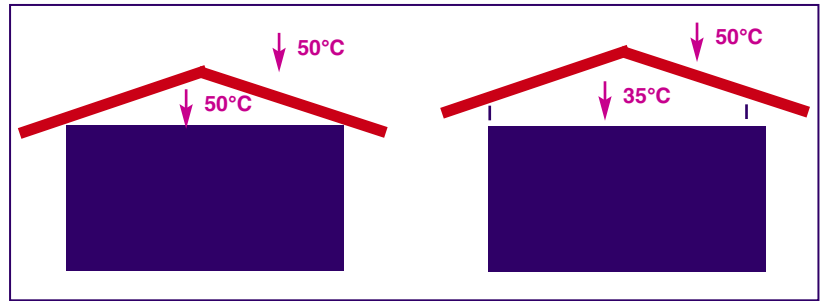


Fig.7.7: Importance of ventilation under the roof. An open ridge-vent placed as high as possible and with a 35 to 40 degree pitch (which increases the draft).

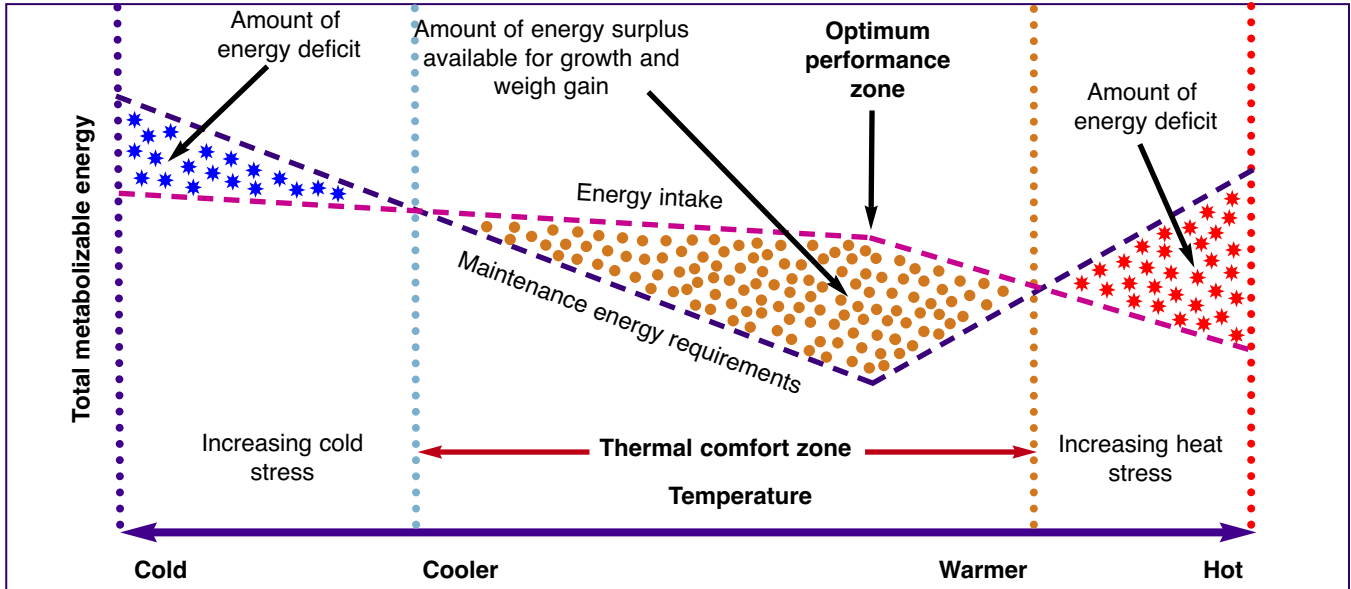


Fig.7.8: Ventilation objectives: except in very young birds and/or very cold time periods, temperature control is one of the main ventilation objectives. At each stage of development, there is an optimum temperature at which birds make better use of the feed energy for growth. Ventilation prevents overheating, maintains birds in this area of optimum performance, and evacuates warm air from the barn. Ventilation is also the only practical way of reducing humidity and the accumulation of ammonia (according to Campbell et al, 2011).

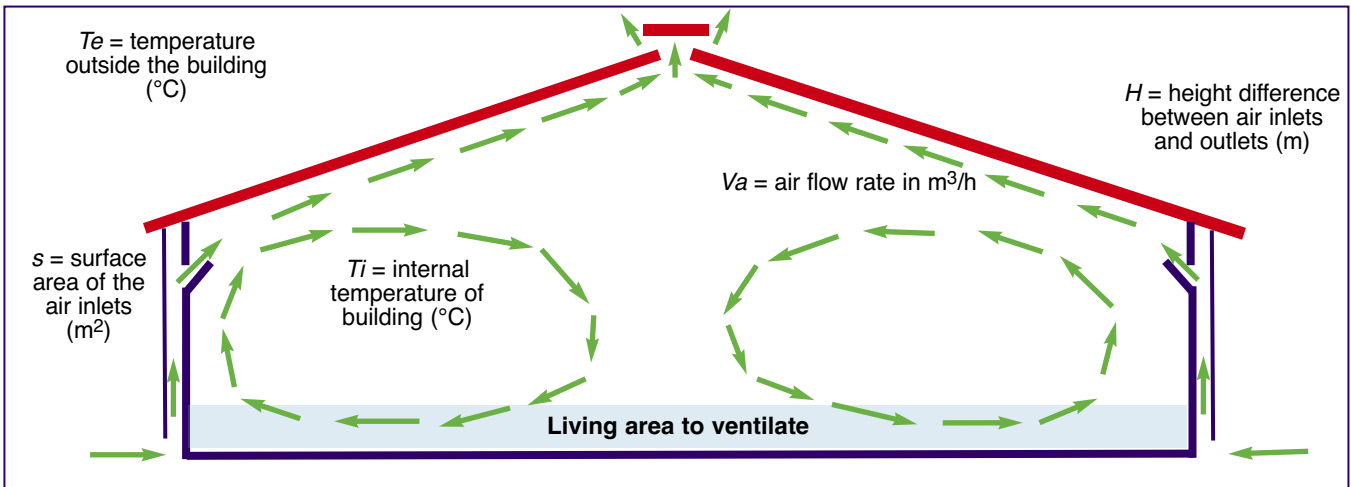


Fig.7.9: Natural ventilation. The flow rates achieved vary depending on the air velocity, the temperature gradient between inside and outside the building, and the height of the surface of the air outlets. They may be calculated using the following equation:

$$Va = 8700s \sqrt{\frac{H(Ti - Te)}{Te + 273}}$$

Va = air flow rate in m³/h, s = surface area of the air inlets in m²; H = height difference between air inlets and outlets in m; Ti = internal temperature of building in °C; Te = temperature outside the building in °C.

rectal temperature of acclimated birds rose only 0.5°C/hour. The ambient temperatures investigated in this study were 38°C, 40°C and 42°C. Poultry reared in the Sudan showed an adaptation to heat which was manifested by an increase in heat tolerance of 4°C compared to birds that were not acclimated.

LIMITING THE IMPACT OF HEAT ON POULTRY PRODUCTION

The following information includes interventions related to facilities, flock management and a certain number of therapeutic measures.

Building

Selection of production site: poultry buildings must be open with a possible protection against dominant winds (with bushes for example), especially against hot winds. Planting vegetation around the building can lower the temperature in the immediate environment by solar radiation absorption.

The orientation of the building will be determined by the characteristics of the field chosen for the location, and the direction of dominant winds which should be at an angle of about 45° to the axis of the building. Finally, and especially in warm countries, buildings should have an east-west orientation. In this case the sun heats only the gables of the building at sunrise and sunset. At mid-day, a projecting ledge of the roof protects the south side wall, the north wall always remaining in the shade.

It is important to take into account the ease of access and proximity to market centers to avoid the transportation of poultry over long distances under hot weather conditions. For biosecurity reasons, it is best to avoid major roads. If several buildings are located on the same farm, these buildings must not be downwind from one another.

The immediate *environment* of the building should prevent the reflection of sunlight on the ground by the maintenance of a vegetation cover. For example, with an air temperature of 32°C, poultry houses with clover as a cover crop around them maintain the air temperature at 32°C, while other poultry houses surrounded by gravel or concrete may see their air temperature rising to 50°C and even 60°C when houses are surrounded by clay.

Building *design* must help fight against the heat.

In order to prevent heat from entering the building, the roof and walls should be isolated, but not the floor. The roof must be covered with reflective materials and an overhang to offer shadow on the walls. For the same reasons, if a ceiling exists there must be ventilation under the roof to prevent heat accumulation in the attic.

To remove heat from the building, large openings (fans) and open ridges placed as high as possible are needed. The width of the building (optimum 12 m) must not exceed 15 m and the height of the side walls must be between 2.50 m to 2.70 m.

Ventilation plays a very important role in warm regions. In addition to its role in supplying birds with oxygen, it removes harmful gases (NH₃, H₂S, CO₂, etc.), dust and humidity. It also helps eliminating excess calories.

Natural ventilation does not use any mechanical device. Air movement is due to high and low pressures caused by wind acting on the building and the natural thermal convection of gaseous masses at different temperatures. The air entering the lower part of the building heats up, its density decreases and it rises into the building to escape through openings located on the roof (ridges or chimney). The rates obtained vary depending on air velocity, the temperature gradient between inside and outside the building, the height and the surface of the air outlets.

Despite its economic benefits, natural ventilation has many disadvantages:

- it only works if there is a difference in temperature or air pressure;
- it does not allow airflow monitoring;
- it does not allow full darkness in buildings;
- it is often insufficient in hot weather, despite the development of automatic control systems that improve efficiency and performance.

With *mechanical ventilation*, air is drawn or forced into the building by fans which have known speeds, are usually adjustable and controlled either manually or automatically. The total power of fans installed in a building (m³/hour/kg) should be calculated taking into account the maximum stocking density and highest temperatures recorded in the region.

Different types of *additional ventilation* may be useful to promote air circulation, increase heat loss, improving bird comfort and thus production. The created air movement increases convection,

Air speed (m/s)	0.10	0.25	0.50	1.25
Cooling effect (°C)	0	0.55	1.60	3.30

Tabl.7.4: Lowering the temperature perceived by the birds as a function of air velocity (according to Sauveur, 1988)



Fig.7.10: Opened building with natural ventilation.



Fig.7.11: Closed building with natural ventilation.



Fig.7.12: Closed building with mechanical ventilation.



Fig.7.13: Closed building with lateral mechanical ventilation.



Fig.7.14: Circulating fans.



Fig.7.15: Low pressure nebulization system.




Fig.7.16: High pressure nebulization system.



Fig.7.17 & 7.18: Cooling pad. Exterior appearance with partial recovery of water and interior view.

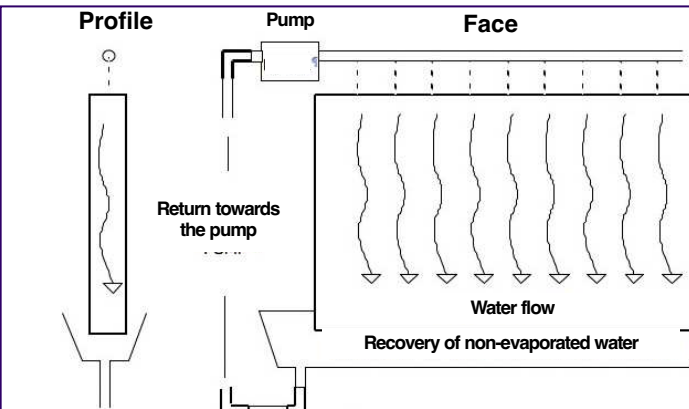


Fig.7.19: Cooling pad flow diagram. Obtaining lower temperature in the barn depends on the temperature and humidity of the air on both sides of the exchanger. The non-evaporated water can be recycled but only partially in order to avoid excessive mineral deposits.

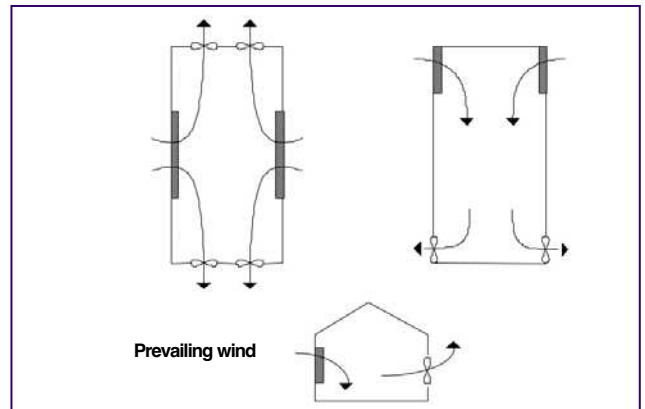


Fig.7.20: Different layout of cooling Pad. Cooling pad layout depends on the size of the poultry house, the desired cooling effect and therefore the total exchanger surface to be installed.

losses in birds, giving them the impression of a lower ambient temperature.

1) Fans are placed vertically in the building and produce a horizontal airflow. This type of installation has many drawbacks (at least 75% of the air flow passes over the area where birds are located and thus have little effect).

2) Tubes with holes provide a rapid air stream which attenuates quickly, thus having no effect on the stratification of air and on the litter.

3) Circulating fans are placed horizontally and provide a vertical air flow which spreads on the floor with the advantages of eliminating heavy toxic gases (NH_3 , CO_2 , CO , SH_2) accumulated at the level of the litter as it dries (thus decreasing the fermentation and production of gas and heat) and eliminating air stratification.

The principle of *complementary cooling systems* is based on the humidification of the air entering the building. The air is cooled when sensible heat is taken out of the air and converted to latent heat via water evaporation leading to air humidity. This approach is less effective in climates (or seasons) with high humidity. To promote evaporation of water the latter must be provided either as a very fine mist or on a very large area. This can be achieved in different ways:

1) Fogging (or nebulizing) either at low pressure (2-13 bars) giving a droplet diameter of about one millimeter (fine rain) and a cooling efficiency of 5 to 15%, or high pressure (33 to 45 bars), where the droplets have a diameter of about one micron (fog) and a cooling efficiency of 50%. The frequency of nebulization is controlled by a thermostat or by a clock adjusted to ensure a spray cycle that takes into account the warmest hours of the day.

2) The hydrophilic disk includes metal disks rotating at high speed and generating fine water droplets.

3) Cooling pads are made of a hygroscopic material, wetted by a ramp and placed in front of the air inlets.

4) Refrigeration units are expensive to acquire and operate. Their installation is justified only in some countries where energy is cheap and particularly during periods of the year when this equipment is considered necessary to save the flock.

Flock management

Nests should be placed in a ventilated area. A nest should be provided for every four hens; egg harvesting should be performed at least five times per day. Eggs left at high temperatures lose CO_2 through their pores, which leads to an increase in pH and faster bacterial multiplication. Stored eggs should be refrigerated in an area between 13 and 15°C.

Limiting stress

Avoid any source of stress: visits, manipulations, etc.

Bird density

Bird density must be reduced at least 20% during very warm periods. This density reduction lowers heat production by birds and the litter, and ensures a better flow of birds to the most ventilated areas and better access to drinkers.

- Broiler breeders: 3.5 to 4.5/m²
- Egg-laying breeders: 4.5 to 5/m²
- Pullets and layers: 4.5 to 5.5/m²
- Broilers: 8 to 11/m²

Drinking water

Water represents 70% of a chicken's body weight. So, water is essential for the bird's metabolism and is an important element for thermoregulation. Access to clean water should be easy, germ-free, and at a temperature lower than the core body temperature. There should be a sufficient number of drinkers:

- Cage: 1 nipple for 1-3 hens and 10 cm linear drinker space per hen.
- On the ground: 14 m linear drinker per 1,000 hens and 12 round drinkers per 1,000 hens.

Feed

Formulation

To offset the reduction in feed intake in broilers, a high energy ration of 3,200 kcal metabolizable energy (ME)/kg should be available with a higher fat content; since digesting fat produces less metabolic heat than carbohydrates. To maintain production performance without increasing protein levels in layers, the diet must be supplemented in amino acids, especially lysine and methionine.

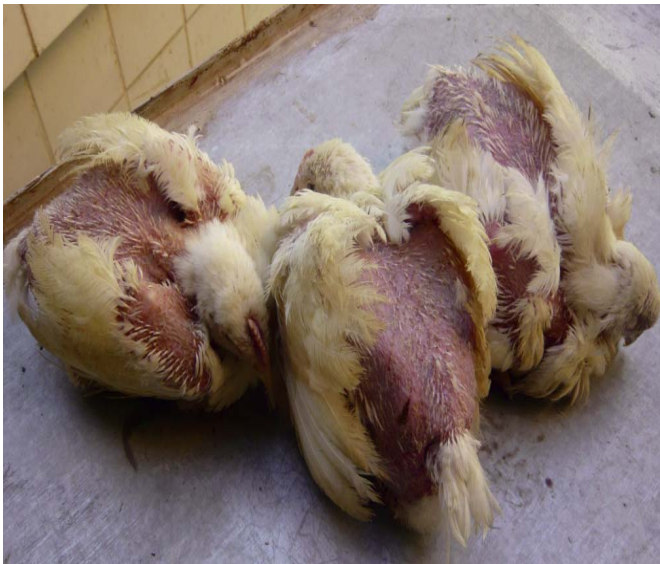

Fig.7.21: Excess heat may cause feather loss.




Fig.7.22: When high mortality suddenly occurs in a flock, it is important to differentiate heat stroke from poisoning, power outage or hyperacute infection.

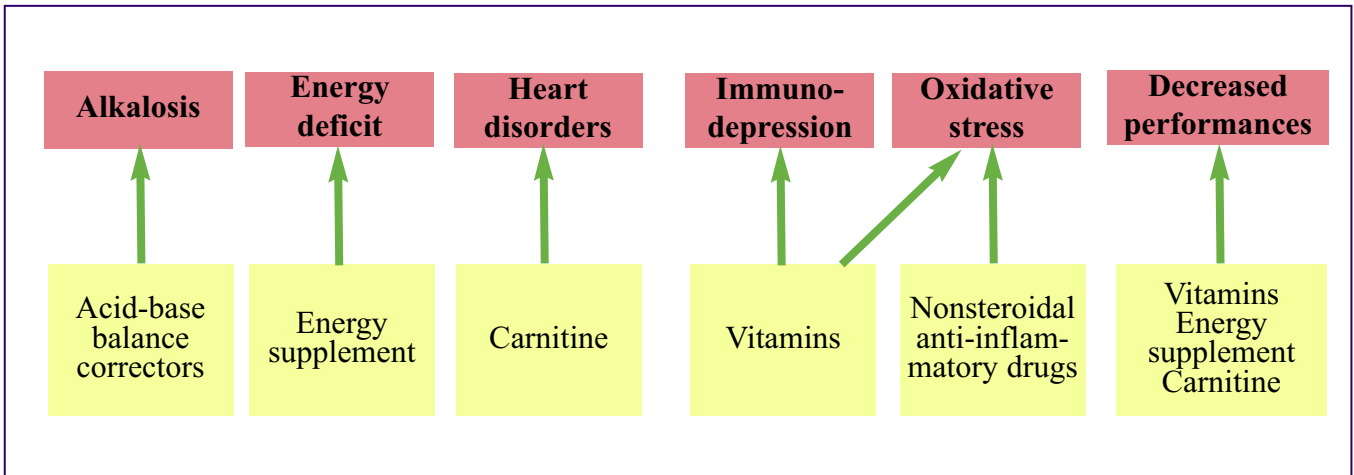


Fig.7.23: Actions to correct disturbances induced by heat stress.

Feed distribution schedule

Digestion is accompanied by secretion of hydrochloric acid in the proventriculus that can exacerbate alkalosis, as well as increasing intestinal motility, which leads to thermogenesis. It is also established that fasting 3-8 hours before a period of high heat is preferable in terms of maintaining feed intake, production performance and viability. Feed distribution must be done very early in the morning. If necessary, the lighting program can be modified to ensure that feed is distributed before daybreak.

Storage

Feed must be ordered in small quantities in order to continually provide fresh feed and limit the proliferation of molds and mycotoxins.

What to do in case of heat stroke

In case of heat stroke, the following measures should be considered:

- 1) Open wide the building by placing awnings over the doors to prevent direct sunlight from entering.
- 2) Favor some bird movement, which encourages

them to drink and facilitates air movement.

3) If ventilation and cooling are inadequate to help birds endure a heat stroke, it may be worth watering them and even immersing them (small flocks) for about two hours.

Therapeutic measures

Some precautions must be taken if medication is needed during a heat stroke. For drugs incorporated in the feed, one should take into account the decrease in feed intake. Whereas when drugs are administered in drinking water, one should be cognisant of increased consumption but also of the evaporation of treated water which may increase drug concentration.

Correcting the acid-base balance

Sodium bicarbonate (NaHCO_3) is administered in drinking water at a concentration of 0.5% or incorporated into the feed at a concentration of 4 kg/ton. *Ammonium chloride* (NH_4Cl) is administered in drinking water at a concentration of 0.3 to 0.5%, with a risk of acidosis beyond 0.6%. The combination of NaHCO_3 and NH_4Cl at recommended doses gives better results than by administering them separately. *Sodium chloride* (NaCl) at a dose of 3 to 5 g/l does not generate alkalosis, but increases the ingestion of water as long as its temperature is relatively low. *Potassium chloride* (KCl) at a concentration of 0.1 to 0.2% may also be used.

Energetic substances

Carbohydrates compensate for energy losses and increase watering. The protection of hepatocytes is provided by sorbitol and choline particularly when using fat (vegetable oils) to increase the feed energy intake.

Carnitine

The consumption of carnitine can increase water consumption and eliminate excess free fatty acids. This treatment can also be recommended as a preventive measure.

Vitamins

Vitamin C (ascorbic acid) and E can be recommended.

Nonsteroidal anti-inflammatory drugs (NSAIDs)

NSAIDs interfere with prostaglandin synthesis acting on the thermoregulatory centers. Two substances may be used:

- Flunixin at a dose of 5 mg/liter of water for three days.

- Acetyl salicylic acid (aspirin), long recommended in the treatment of heat stroke, alone or combined with vitamin C at a dose of 300 mg/liter of water for 1-3 days.

Other substances

Phenothiazine may be incorporated in broiler feed at the dose of 2.5 to 5 g/kg of body weight.

Antibiotics

Erythromycin and oxytetracycline stimulate growth performance and reduce mortality. Bacitracin zinc stimulates the immune response and increases feed consumption at a dose of 55 g/t of feed (continuous feeding during hot season, and at 110 g/t during very hot periods).

REFERENCES

- Amand G et al. La prévention du coup de chaleur en aviculture. *Sciences et techniques avicoles*. Hors série. Mai 2004, 64 p.
- Campbell J et al. Poultry house ventilation guide. In *A practical guide for managing risk in poultry production*, Ed. Owen RL, AAAP, Jacksonville, Emmons GC. 1974. The effects of temperature on the performance of laying hens, pp. 79-90. In T. R. Morris and B. M. Freeman, eds., *Energy Requirements of Poultry*. Br. Poult. Sci. Ltd., Edinburgh. Florida, 2011, pp71-116.
- Reece FN et al. Effects of high temperature and humidity on heat prostration of broiler chickens. *Poultry Sci.*, 1972,51, 2021-2025.
- Sauveur B. *Reproduction des volailles et production d'œufs*. Ed. INRA. Paris 1988, 455 pages.
- Sykes AH & Salih. Acclimatization to intermittent heat stress. *Scientific Reviews on Arid Zone Research* - 1982, 138.
- Uzu G. L'alimentation de la poule pondeuse en climat chaud: deux voies d'amélioration. *L'aviculteur*, 1989,504,p.40-48.

	Layers	Broiler
Fresh droppings	78%	74%
Manure	25%	37%

Tabl.8.1: Moisture content of poultry manure and droppings.

Parameters/season	Summer	Winter
Daily production	7 - 8 m ³	5 - 6 m ³
Annual production	2,400 - 4,000 m ³	1,800 - 3,000 m ³

Tabl.8.2: Amount of methane produced by a tank of 8 m³ of manure depending on the season.

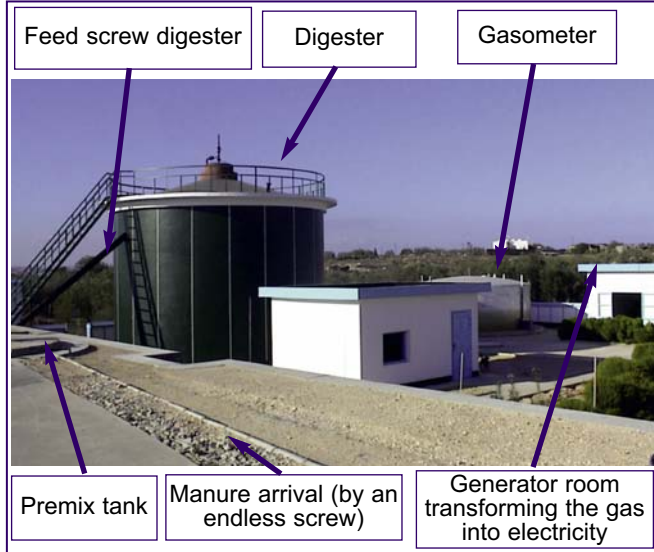


Fig.8.1: Methanization unit in Sousse (Tunisia).



Fig.8.2 & 8.3: Poultry manure storage facility in Canada (inside and outside).



Fig.8.4 & 8.5: Poultry manure composting facility and leachate harvesting in Canada.



Fig.8.6 & 8.7: Poultry manure composting sites in Tunisia.



Fig.8.8 & 8.9: Turning poultry manure during composting.



Fig.8.10: Granulation plant processing laying hen droppings.



Fig.8.11: Plant for the liming of laying hen droppings.

8. POULTRY DROPPINGS & MANURE

INTRODUCTION

The industrialization of poultry production has contributed to the creation of regions of high poultry density in the world. High animal density creates environmental challenges. When not managed properly, it causes different types of pollution (e.g., visual, with drastic changes in landscape; olfactory, noise). It can also contribute to water and soil contamination.

In some regions, waste produced by commercial poultry operations can be very important. Given today's interest in the environment, people living in these regions are more sensitized to potential consequences and poultry managers must not neglect this new reality.

In response to these concerns, different storage solutions, treatments and uses of poultry manure have been developed, among other reasons, to help preserve natural resources. The implementation of these strategies meets several objectives. At the farm level, the main objectives are to preserve water resources and the farmer's quality of life; at the regional level, the goals are to prevent or limit damage to the environment and prevent obstacles to the poultry industry's development while protecting its image.

Definitions

In this chapter, we are referring to manure, slurry and droppings. It is important to understand the meaning of these words. Droppings refer to the waste produced by the birds. Manure, in the context of this chapter, refers to the mix of droppings and litter used for raising flocks. The expression "used litter" is synonymous to manure. Slurry is poultry droppings with added liquid, giving droppings a more liquid consistency.

MANURE PRODUCTION

Quantity

The amount of waste produced varies according to the species, market conditions, feed consumption, bird weight, and length of production cycles. The moisture content and the litter depth at the time the house is cleaned out are the primary factors that affect the amount of litter produced in broiler and turkey houses.

Here are quantities generated according to the main types of poultry production:

- *In broilers*, after 6 weeks, about 1 kg of dry manure has been produced per bird;
- *In pullets*, 12 kg of droppings is produced by 20 weeks of age;
- *In laying hens and breeders*, 150 to 200 grams of droppings per bird per day, with an average annual production of 65 kg;
- *In turkeys*, from 11 to 15 kg of manure on average by 12 to 15 weeks of age.

Quality

The composition of manure depends on several factors. The water content varies with the ambient temperature, the health status of the flock, storage conditions, *etc.* But, the more manure is humid, the more it will tend to lose gaseous nitrogen (mainly ammonia). Poultry manure is characterized by high concentrations in nutrients (nitrogen, phosphorus, potassium, calcium, trace elements), which makes it valuable for agricultural use.

STORAGE OF MANURE & SLURRY

Manure can be stored either directly on the ground or on a specially designed platform, covered or not. Slurry can be stored in deep pits or under slatted floors; storage outside the barn will be in pits, covered or not, made of concrete, geomembrane or vitrified cobalt steel plate sealed with a special sealant to prevent corrosion.

TREATMENT OF MANURE

Odor control

It would be ideal to completely block odors generated by poultry manure. In practice, we can only minimize odors, which may be assessed using the following methods:

- *The olfactory analysis* assesses the concentration and intensity of the odor. The concentration of an odorant mixture is defined as the dilution factor required to reducing the odor to a point that at least 50% of participants representing the general population can no longer smell the substance (K50). The K50 is determined by presenting to each member of a jury (4 to 16 people) the sample taken with different degrees of dilutions, which requires an olfactometer. This device allows diluting a gas

sample with odorless air and the diluted manure samples. The odor intensity is obtained by comparing each sample to reference samples representing a range of odor intensities. The precise measurement method is described in the norm NF X 43-103.

- *The physico-chemical analysis* helps identify the composition of the sample. It is based on demanding techniques using gas chromatography and spectrophotometry. In the field, simple techniques are usually based on colorimetric tubes (Draeger, Gastec, etc.) to assess the concentration of certain gases (NH₃, H₂S, etc.).

Several techniques are available to reduce unpleasant odors:

- *Building ventilation* can partly prevent the production and accumulation of odors.

- *Phase separation of manure* is a process often used for the treatment of cattle and pig manure, but it is more difficult to use for poultry manure because of its pasty consistency. This technique consists in sifting the product to separate it into two phases, a liquid phase and a solid phase consisting of organic material that can then be used as fertilizer.

- *Oxygenation* is a process designed for the treatment of slurry and therefore is applicable only to poultry manure collected in this form. The method consists in blowing air with oxygen promoting aerobic microbial growth and thus stabilizing the organic matter, resulting in a relative deodorization. A trickling filter is used to run off the slurry on porous material, to subject it to aeration. The advantage of this technique is its low demand in energy. A daily aeration easily allows the oxidation of organic matter and prevents fermentation. The equipment used includes either surface aerators, or air-blowers.

- *Additives* are more or less specific and act either immediately or in the long run. Some are masking products (bad odors are masked by a very strong pleasant smell), others are oxidants. Essential oils are also used. Additives can only be used with precaution and in a punctual way and for a limited period of time. They are used in poultry buildings and their application depends on whether they are in liquid or solid form. Solid forms are applied to the entire surface of the building. The liquid forms are often disseminated by spraying or misting. Some of these products can also be put in storage pits or slurry tankers at the time of application. The

effect of these products on the soil and plants is nil, due to the low concentration used and the biodegradability of their components.

From a purely technical point of view, controlling odors remains difficult and all available techniques do not have the same level of effectiveness. Moreover, it is a non-productive expenditure, with no real economic value unlike techniques designed to market manure as fertilizer.

Dehydration & pasteurization

The water content of droppings of caged hens is often between 70 and 80%. Dehydration is a technique designed to reduce the water content and thus the volume of manure to reduce odors and turn droppings into a marketable product.

Methods

Natural dehydration is based on applying negative pressure ventilation into the building, with an air extraction from the pits, which depth is limited to 0.6 m for six-month storage and 1.2 m for 12-month storage. This system has the advantage of requiring no energy other than that required for ventilating the building.

Battery cages with an integrated manure drying system that operates according to the season and the needs to renew air in the building. The air is drawn either from within the building or from outside. Air is forced through polyethylene ducts and is distributed directly on the carpet where droppings are being dehydrated. Substantial energy savings can be achieved by the installation of heat exchangers that can heat the outside air in contact with the ambient air of the building during cold periods of the year.

Dehydration using solar energy is an American technique. Manure from barns is moved to a greenhouse. The manure deposited daily in the greenhouse is raked at an adjustable height to initially spread the humid manure pile; in a second phase of the operation, the dry layer on top of the pile is then removed.

Mechanical dehydration requires the use of a specific machine, called “dehydrator”. The principle of this machine is the use of a flow of hot air in order to lower water content from 75% to 15%. This decrease is considered sufficient for the stability of the dehydrated product. There are two types of dehydrators. One is essentially a rotating oven where droppings are heated to about 900-1,200°C,

which produces a dry product. The second involves the use of an enclosed space for stirring and heating the waste until the water content is completely removed. These fixed dehydrators are simple machines that are not likely to catch on fire. Thermal efficiency and odor reduction are satisfactory and the resulting product is very homogeneous.

Dehydration may also have a negative side, depending on the system: persistence of an unpleasant odor, high energy consumption, cost of equipment and the necessity to have enough manure (production site with at least 50,000 hens) to offer an adequate return on investment, the need to have a special location and ancillary equipment (elevator, screw conveyor, bagging), extra labor, energy cost, etc. Furthermore, various studies have shown that dehydration does not sterilize droppings. To solve this problem, a pasteurization process may be added. The idea is to bring the dehydrated product to a temperature of 100-105°C for 30 minutes, followed by a cooling phase. Samples should be taken daily for analysis.

Incineration

At the farm level, in countries where it is authorized, the incinerator is used to burn droppings, as well as dead farm animals and household waste. The combustion chamber comprises a smoke chamber where the smoke is processed in order to avoid spreading residues and odors in the atmosphere. The incinerator is topped by a heat air exchanger, although most function with water. The hot water produced goes to poultry buildings where it will supply heaters or a network of pipes present in the concrete floor.

This type of incinerator is considered useful because it produces heat that may be used to start a new flock as it gets rid of the manure.

At the industrial level, incineration can be used to generate electricity. The first power plant using poultry manure had a capacity of 12.5 megawatts and was installed in Great Britain. Manure is burned at 850°C to produce steam that spins turbines producing electricity. Ash, representing only 10% of the burned manure, and dust produced with this process are marketed as fertilizer.

The disadvantages of incineration: this approach requires major investments. Due to corrosion problems, the life expectancy of the equipment may be limited; finally, the burning process reduces the fertilizing value of the final product.

Methanization

This process is inexpensive and easy to apply, even on a farm. It consists in storing manure in sealed tanks to induce, by anaerobic fermentation, the emission of gases primarily rich in methane (45-55%) and carbon dioxide (40-50%). Other gases can be emitted in negligible amounts (hydrogen, oxygen, etc.).

The principle of methanization is a breakdown of cellulose in the presence of water. Manure fermentation is preceded for a short duration by a highly exothermic pre-aerobic fermentation. The level of heat produced will keep the reaction at the optimum temperature of 35°C. Indeed, methane production starts only when the temperature is at least 20°C. Then, it increases rapidly and proportionally with higher temperatures until 35-37°C. At more elevated temperatures production stops. Maximum production is reached within days and will eventually weaken after four to six weeks. Under these conditions, it will be possible to collect 60-80 m³ of methane from a ton of manure, and 200-250 m³ from one ton of straw. The difference in gas production is due to the proportion of cellulose in each product. Anaerobic digestion improves the fertilizing value of manure, with only a 10-15% reduction in weight. Methanization also improves the phosphorus and potassium content of the final product.

A methanization unit includes a cylindrical tank, also called digester, connected through a pipe to a gas recovery bell called gasometer. The amount of methane produced by an eight cubic meter tank varies according to the season.

The average annual production of a tank is 2,000-3,000 m³ of methane. Since the calorific value of methane is about 5,500 to 6,000 kcal/m³, the annual energy production is estimated to be 12 to 16 million kcal, equivalent to 2,000 liters of fuel.

Limitations of methanization. Like for any organic material, manure is suitable for anaerobic digestion if in a liquid state (slurry) for easy handling and dilution of other substrates. Despite its low methanogenic potential, it has the advantage of providing a fresh supply of bacteria and of having a strong buffering capacity ensuring environmental stability. Manure is also interesting because it has a high solid content, which is useful to support the bacteria inside the digester. However, this also makes it more difficult to handle and more expensive to use (injection into the digester and energy required for the mixing



Fig.8.12: Spreading of poultry manure.



Fig.8.13: Poultry manure spreader with spreading table.



Fig.8.14: Spreading poultry manure with a drip hose system.

process). Therefore, manure must either be mixed with slurry in a pre-pit and pumped into the digester or introduced by means of a hopper. Manure can be used in a dry methanization process, but very few data are available on this. Finally, unlike other animal waste, poultry manure and droppings are very rich in nitrogen, which inhibits the production of biogas. Similarly, if the slurry is too diluted it will have a low methanogenicity. That is why these products are only allowed in small quantities in digesters.

Composting

Spreading poultry manure on cropland can pollute ground waters, the environment, and produce noticeable odors where it is spread. Composting can reduce these problems by transforming the manure into a stable, smaller product rich in organic matter. Poultry manure compost contains 80 % solids, reducing moisture content by about 50%.

Composting is an exothermic oxidation of organic matter by aerobic microorganisms, which requires the right combination of moisture, pH, temperature, oxygenation and aeration of the composting pile. The composting process consists of four phases:

- 1) The mesophilic phase that allows the bacterial decomposition of easily degradable organic matter. With this process, the temperature rises from 15°C to 45°C.
- 2) The thermophilic phase that provides the decomposition of the more complex organic matter (fat, cellulose...) by actinomycetes and fungi. The temperature rises from 45°C to 70°C.
- 3) The cooling phase which is characterized by a decrease in fermentation and the development of humification (humus production).
- 4) The maturation phase, which completes the humification process and results in a stable dry product with high fertilizing value.

Granulation

Associated with grinding and dehydration, the granulation of poultry manure and droppings provides a homogeneous stabilized and sanitized product generating little nuisance and easier to measure out, sell or use. The system consists of a mill and a press from which the product leaves at a temperature of 70°C. A cooler can return the product to room temperature and a cyclone technology is used to retrieve dust back into the system.

Liming

Liming is a method developed to convert manure into organic-mineral fertilizer by adding calcium oxide. The resulting chemical reaction is exothermic and leads to the destruction of pathogens that could be present in the manure, as well as flies and their larvae, which has the added benefit of saving on larvicides and muscidicides. Lime treatment produces a stable odorless product capable of being marketed. However, this treatment occasionally generates strong ammonia emissions.

Biological treatment (adding bacteria to the litter)

The use of a biological treatment in poultry litter is justified by the microbiological transformations of litters throughout the growing period, leading to the proliferation of harmful flora consisting mainly of facultative aero-anaerobic bacteria. This flora is dominated by enterobacteria and coliforms which, even if not primary pathogens, pose a risk to weaker birds when concentrations exceed 105 organisms per gram of litter. These colonies can also be formed by pathogens such as *Escherichia coli*, *Salmonella* spp. or *Staphylococcus* spp..

The regular input of a specific flora on litter directs the microbial growth and modifies the degradation

of organic matter, leading to a beneficial maturation. Bacterial competition fostered by these inputs results in a drastic reduction of pathogens in the litter. Indeed, the use of a bacterial inoculum containing different strains of *Bacillus subtilis* (or other strains of *B. sphaericus* and *B. thuringiensis* serovar *israelensis*) can be beneficial via competitive exclusion reducing pathogens in the litter.

USE OF POULTRY MANURE & DROPPINGS

Agricultural use

The composition of poultry droppings and manure justifies their use as fertilizers. Their nitrogen content limits their use on some sensitive crops. Forage plants and corn support higher intakes. The loss of nitrogen by the release of ammonia is important during storage and spreading of poultry manure. Phosphorus is used by plants after transformation by the microbial flora of the soil. It is retained by the clay-humus complex of the soil. It can be lost by surface water runoff. Potassium is used by roots as potassium salts. It is lost by soil leaching.

The agricultural use of poultry manure and droppings is economically interesting and it is a natural way of recycling waste. It offers a balanced product

containing all the elements necessary for the growth of many plants; it reduces the need for mineral fertilizers; and it provides organic matter. However, any excess in application risks causing toxicity, pollution, water saturation of the soil and odors.

Spreading & burying

In order to use the right quantity at the right time, it is useful to rely on suitable equipment to properly apply manure. For solid manure, spreaders with horizontal drums and possibly a spreading table are preferred. For slurry, the most common system is the nozzle/flapper, but drip hose or incorporators are also used.

Burial/slurry injection currently remains the most effective solution in terms of solving volatilization and odor problems. However, it requires greater pulling power. This can be done on bare soil or stubble fields. There are three types of distinct stone buriers/injector: stoneburiers for cultivated soils, stoneburiers for grasslands and polyvalent mixed or all-terrain stoneburiers. However, if this type of equipment is not available, it is always possible to bury slurry or manure immediately after application with a tractor with a plow or a disc stone burier.

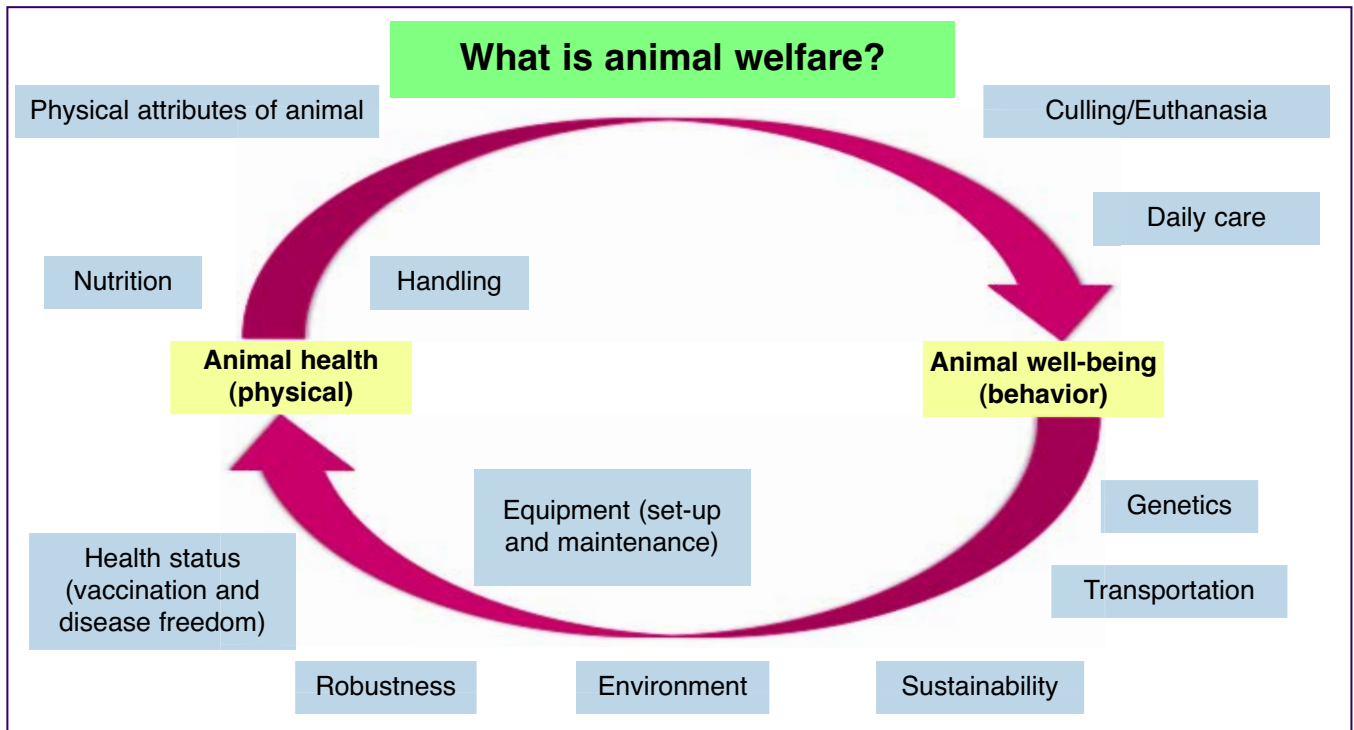


Fig.9.1: What is animal welfare?



Fig.9.2: Evaluation of the physical appearance and behavior of newly hatched poultry should be used to verify health, comfort and the robustness of the birds. In this example, the posture and behavior of the chick on the left highlights a concern with the chick's well-being and quality.

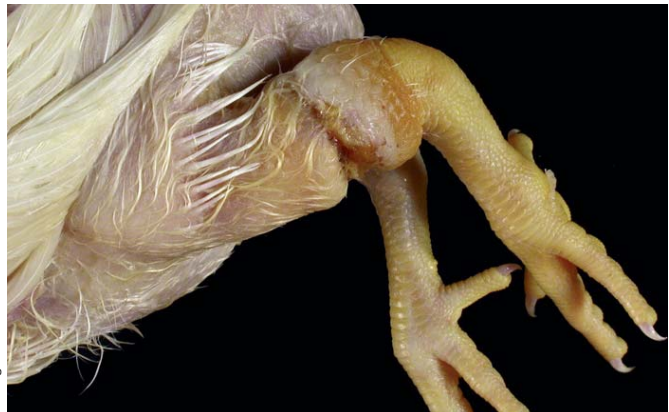

Fig.9.3: Provision of a secure environment is important to limit the potential for injury. Example of a leg string amputation in a broiler chicken.

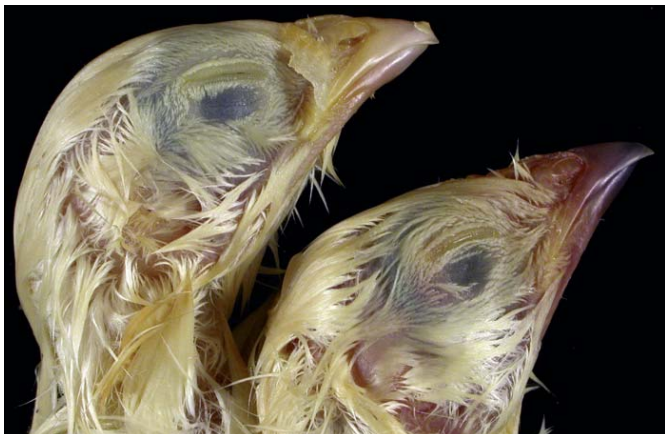

Fig.9.4 & 9.5: Temperature, humidity and air quality are important factors of welfare during incubation period. Examples of dehydration in 3 day-old chicks.

9. POULTRY WELFARE

INTRODUCTION

Animal welfare incorporates the physical health and the mental (behavioral) well-being of the animal. These two major components, physical and behavioral, are interlinked with each other and encompass all of the people, actions, equipment and procedures that are included in the supply chain for the poultry industry. For example, if a bird is injured, the negative impact that the injury has on the bird's physical well-being is often reflected in the bird's behavior as evidenced by changes in posture, social interaction, or activity level, *etc.* Similarly, when a poultry flock has good health, receives quality nutrition and has an appropriate environment, the physical and behavioral well-being of the flock will be reflected positively as supported by good growth, development, good activity level and the expected production outcomes.

In this chapter, various aspects of poultry welfare will be highlighted with the objective of optimizing animal health and well-being during all phases of the poultry supply chain from the breeder farm to the hatchery to the grow-out facility to the slaughter plant. For all of these phases, areas of poultry welfare will be emphasized that can help limit the potential for pain or injury to poultry, limit the introduction of disease that can negatively impact animal health, and optimize the conditions for the growth, performance and well-being of the animal.

In general, to verify optimal conditions for poultry welfare the following items should be included in daily checks and frequent quality assessments: provision of a secure environment to limit the potential for injury, escape or entrapment of birds; use of biosecurity methods and procedures to limit the exposure to or introduction of disease; appropriate handling methods and use of equipment to minimize stress and the potential for injury; programs to evaluate sick or injured birds for culling or recovery, and use of appropriate methods of euthanasia to limit suffering of culled birds.

HATCHERY PRACTICES TO OPTIMIZE POULTRY WELFARE

For all poultry, regardless of species, breed or type, life begins in the hatchery. Therefore, it is critically important that hatchery practices and equipment are optimal to promote good poultry health and welfare. The primary areas that can have the greatest impact on poultry welfare are hygiene, mechanical factors and people. If poultry are compromised in quality, health or well-being by any of these factors, their performance and survivability may be negatively impacted. To incorporate all aspects of the hatchery, consider the following areas and the actions or procedures that can have a direct impact on poultry welfare: incubation period, hatchery hygiene, hatchery equipment and interventions for day-old poultry.

Incubation period

Temperature, humidity, air quality, and manipulation of the eggs are the primary factors in this period to ensure that poultry will hatch and that quality will be optimal for the species. If any one factor, or a combination, is compromised the appearance and characteristics of the new hatchling can be negatively impacted. Examples of this include: embryonic mortality; poor uniformity of hatch within expected time frame; poorly healed navels; anatomical abnormalities; inadequate moisture loss during the incubation procedure; dehydrated and/or weak chicks.

Hatchery hygiene

Hatchery hygiene (eggs, equipment, facility, personnel, *etc.*) is one of the most critical aspects of producing healthy poultry and limiting contamination. Items to include are: egg quality (quality and cleanliness standards of hatching eggs and health status of flocks providing eggs for the facility); use of disinfectants (use and application of approved products to limit bacterial and fungal challenges in the facility and on equipment); cleaning protocols for



K Barger

Fig.9.6: Equipment must be maintained and procedures in the hatchery must be carefully monitored to reduce the risk of damage as seen with this pinch-point injury.

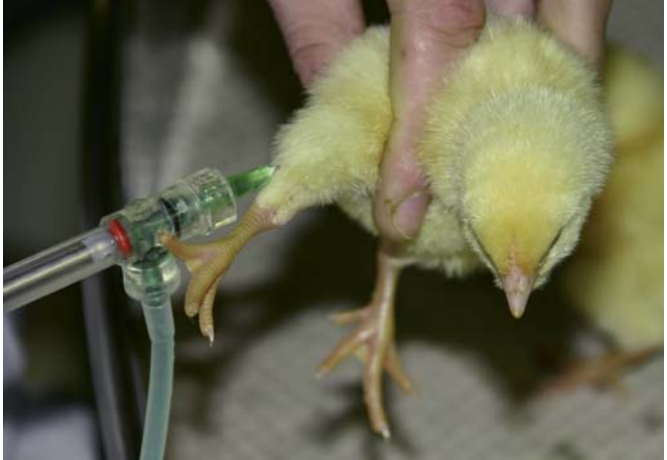

K Barger

Fig.9.7: Minimizing drop distances and providing anti-slip surfaces are important to prevent tumbling and injuries that can have negative consequences for the chick's development and survivability upon arrival at the farm.

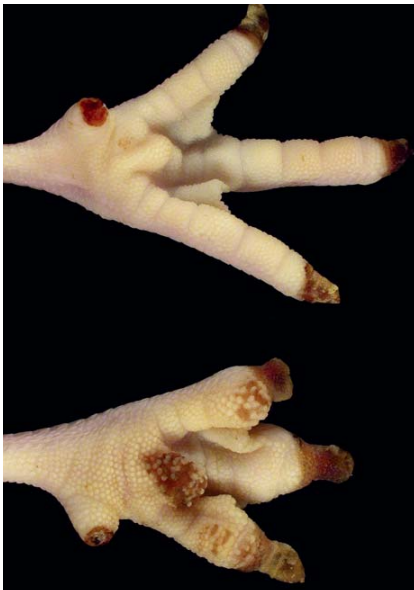

K Barger



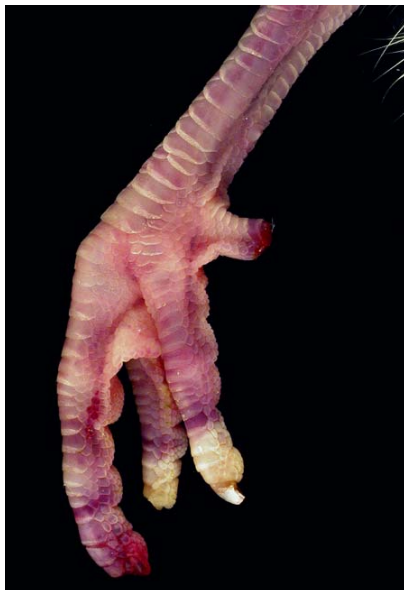K Barger

Fig.9.8 & 9.9: Hatchery interventions (toe-nail trimming for males and vaccination for day-old poultry) provide a net welfare benefit for the bird and the flock but procedures must be conducted to limit chick injury and to guarantee quality and accuracy.



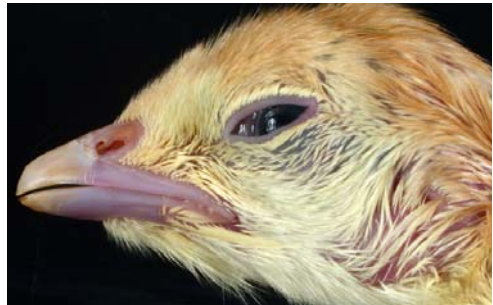HJ Barnes

Fig.9.10: Severe toe trimming (8 day-old turkey). Normal (top) vs affected (bottom) feet.

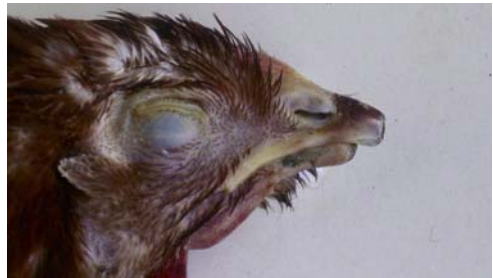

HJ Barnes

Fig.9.11: Severe toe trimming (2 day-old turkey).



HJ Barnes



LDA 22

Fig.9.12 & 9.13: Severe beak trimming in a one day-old poult (top) and in a 18 week-old hen (bottom).

equipment (incubators, hatchers, and all chick and egg processing equipment must be thoroughly cleaned to remove organic matter before disinfectant can be used); biosecurity procedures for entry of personnel and equipment must be adequate to limit the introduction of disease (for example, the use of showers and/or required clothing/shoe change, limiting entry of personal items that may be contaminated, limiting introduction of equipment or tools used with other live poultry).

Hatchery equipment & procedures

Once the poultry have hatched, they must be processed to separate the chick from the egg remnants and to evaluate the chick for quality characteristics. Depending on the species and type of poultry [breeding purpose or commercial (egg/meat) purpose], further processing requirements may be needed. For all of these procedures, the set-up and the maintenance of the equipment and chick handling must be applied in such a manner to minimize injury, to reduce stress, and to optimize bird comfort and well-being. Specifically, the following should be monitored each day when poultry are hatching: handling method(s), surface or flooring, equipment set-up and maintenance, hatchery interventions, ventilation, holding time and dispatch for transport.

Handling method(s)

Newly-hatched poultry should be handled carefully while supporting the body. To prevent injury, they should not be handled by the head, neck or legs (only during feather-sexing should chicks be handled by the wing). When chicks are placed into box or funnel, the drop-distance should be reduced as much as possible to minimize the risk of injury. In many hatcheries, this drop distance is maintained at 6 inches (15 cm), and should not exceed 12 inches (30 cm) to avoid injury to the neonate poultry.

Surface or flooring

The flooring of boxes, ramps, conveyors, *etc.* must be satisfactory for newly hatched poultry to reduce the chance of slipping, tumbling and toe/foot/leg injury as this can result in a negative consequence for the early survivability of the poultry and their capacity to thrive upon arrival at the farm. In many hatcheries, a texturized paper or pad is used in transport boxes to help absorb any moisture or fecal matter from the birds while also providing a stable, non-slip surface.

Equipment set-up & maintenance

While newly-hatched poultry are very resilient, the set-up and the maintenance of equipment are critical to limit injury, stress and disease exposure during the hatching and processing periods. Examples of items to check include: hygiene of equipment before use; elimination of possible pinch-points and areas where chicks can be trapped, fall, escape, or become injured; equipment set-up to limit drop distances, rough movements or possible areas where too many chicks may accumulate leading to suffocation.

Hatchery interventions

An intervention is defined as a modification or measure whose purpose is to improve health. The intervention applied will be directly linked to the type of poultry (species, breed, gender), the end purpose of the bird (breeding, egg-laying, meat), the farm environment where the birds will be raised (housing and equipment type), and the requirements (or limitations) set by the farmer, company or government where the birds will be raised. For poultry in the hatchery, these interventions may include: vaccination, beak-trimming, toe-nail trimming, dubbing, or removal of the spur on a male chick. It is important to realize that each of these interventions can have a net welfare benefit for the future health and physical and mental well-being of the bird and the flock.

Vaccination. This procedure involves the application of a specific vaccine with the goal of stimulating the immune response and preventing disease in the flock. Vaccines may be applied in a variety of methods (*in ovo*, neck injection, leg injection, spray) and care must be taken to optimize handling and vaccination accuracy when the procedure is carried out in the hatchery. For day-old vaccination, quality assessments should be conducted in the hatchery to verify the method of application (amount of vaccine administered, hygiene involved in the preparation of vaccine and application of the vaccination, and the accuracy of equipment utilized) and the welfare results for the bird (lack of injury and limited stress from application).

Beak trimming. This procedure involves the removal of the tip of the beak with precision equipment in the hatchery. The goal of this intervention is to produce an ideal beak length and shape for the bird's longevity. Benefits include avoidance of an uneven or overgrown beak that may inhibit the bird's capability to eat, drink, or mate, and to prevent problems with cannibalism.



Fig.9.14: Newly hatched poultry depend on people and equipment for optimal temperature and ventilation in the hatchery. Evaluation of equipment settings and verification of bird behavior (cold-stress in this example) are both important.

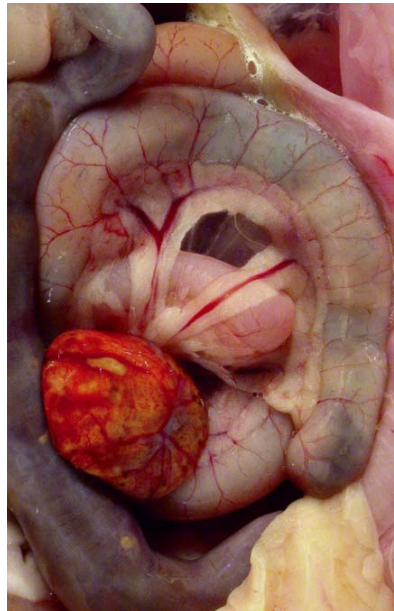


Fig.9.15: If newly-hatched poultry are too hot or too cold, there is a chance of having increased stress that can result in reduced absorption of the yolk sac and the possible death of the chick.



Fig.9.16: It is important to maintain dry bedding for poultry and therefore to minimize pododermatitis due to exposure to moist flooring and high ammonia.

Toe (nail) trimming. This procedure involves the removal of the toe-nail of the bird, with the goal of having a healed toe without the presence of the nail. For breeding poultry, it is normally applied to the back toes of the male bird, but may be applied to other toes depending on the species and the purpose of the bird. Benefits of this intervention include the prevention of problems with the male damaging the females during mating, and reduction of scratches for birds within the flock.

Despurring. This procedure involves the removal of the spur on a male chick with the goal and long-term benefit of preventing injuries to hens and other males if older birds fight while in the production house.

Dubbing. This procedure involves the removal of a portion of the comb on a chick with the goal and long-term benefit of preventing injury if older birds fight while in the production house, and preventing the possibility of males becoming hung or caught on feeding equipment when mature.

Ventilation

Newly-hatched poultry are poikilothermic, meaning that their internal temperature can vary with the temperature of the environment. For this reason, the temperature and the ventilation of the processing room and holding area of the hatchery are very

important to limit stress due to temperature (hot/cold). Adequate ventilation should be provided to maintain the correct temperature for the comfort of the chick at all times. In addition to verifying equipment settings for temperature and ventilation within the hatchery, staff members should also be trained to evaluate bird behavior for signs of thermal stress. For example, if the chicks are cold, they will clump together in a group to avoid the draught or cold air. If they are too hot, open-beak breathing or panting can be observed. In both situations of thermal stress, chicks will be noisy and their behavior will demonstrate their physical discomfort.

Holding time & dispatch for transport

Newly-hatched poultry can survive for 1 to 3 days without feed and water due to the highly nutritious yolk sac present in their abdomen. Nonetheless, time is a serious component and waiting periods must be minimized so that chicks can be quickly and safely dispatched when ready. Both the holding room and the transport vehicle must have adequate ventilation and must maintain the correct temperature to enhance bird comfort and well-being until the birds reach the farm and have ready access to feed and water. If newly-hatched poultry are too hot or too cold, there is a chance of having increased stress that can result in poor uniformity, reduced absorption of the yolk sac, and the possible death of the chick.

FARM PRACTICES TO OPTIMIZE POULTRY WELFARE

Upon arrival at the farm and until the point of departure from the farm, the physical and mental needs of the bird and flock are the responsibility of the farmer or farm caretaker. Specifically for the farm, it is important to realize that welfare requirements may vary according to species, type of operation, purpose or type of flock [breeding or commercial (meat/egg)], and the legislative or customer requirements for poultry in the country where they are being raised. The following general items should be considered to optimize poultry health and well-being on the farm:

Housing or shelter should be secure and provide an environment for poultry that limits exposure to disease, rodents, extremes in temperature and weather. Flock density should be managed in such a way to allow birds to express normal behavior and to minimize the possibility of over-crowding, piling and scratching. The house or shelter must be maintained and in good quality to prevent bird entrapment, escape and injury.

Feeding and drinking equipment should be well-maintained to provide feed/water to the entire flock with minimal stress. Consideration should be given to the distribution, height, location, hygiene, type and maintenance of the feeder and drinker systems so that all birds can freely access feed and water without risk of injury or stress.

Temperature/ventilation should be appropriate for the age and type of poultry to provide optimal comfort (ambient temperature and humidity within housing), introduce fresh air, and to remove noxious gases [ammonia (<25ppm), carbon dioxide (<3000ppm)]. Ventilation and temperature control are also important to maintain dry bedding (litter moisture content should be <30%) for poultry and therefore to minimize pododermatitis and hock burn due to exposure to moist flooring and high ammonia.

Handling & procedures by farm staff

Farm staff or personnel working in the house or environment need to be trained in handling and movement techniques so that stressful procedures can be minimized within the flock. Personnel should avoid loud, sudden or drastic movements that may cause flightiness and nervousness within the flock. Equipment used for procedures (vaccination, selection, movement, sorting, catching, *etc.*) should be well-

maintained and used in a manner that limits the potential for injury, entrapment, stress, disease exposure, and death. When lifting or carrying a bird, the wings or legs can be used and this may vary based on the size, age, type and weight of the bird. Birds should always be kept calm to limit the potential for stress, scratching, bruising, and bone breakage.

Biosecurity & health status

Biosecurity requirements must be enforced for all farm staff and visitors. The reason for the biosecurity measures is to prevent the initial introduction of disease in the flock and to prevent spread of the disease within the farm if present. Specific biosecurity requirements for entry and for movement within the farm will vary based on the type of bird, the disease risk in the immediate and regional area, and the company or farm's requirements. Monitoring the flock's health status via physical observation, collection of samples and diagnostic testing is important to quantify the health and disease status for the birds. Early disease detection and preventing disease spread are important for the well-being of all of the birds in the flock.

SAMPLING PRACTICES TO OPTIMIZE POULTRY WELFARE & HEALTH

The accuracy and the frequency of collection of samples from the flock are important for disease diagnosis. As mentioned previously, early disease detection and preventing disease spread are important for the well-being of all of the birds in the flock. From an animal welfare viewpoint, sampling practices should incorporate the following aspects to enhance bird health: method for sampling birds within the flock and handling of birds for sample collection.

Method for sampling birds within the flock

In the majority of poultry flocks, a set number of samples will be collected from various birds and the result of these samples will indicate the status of the entire population within the flock or farm. For this reason, it is important to obtain samples from a variety of birds (distinct location, distinct status, male and females of the species, different houses or pens within the farm) to ensure that the result is representative of the population sampled. If samples are not taken from a variety of animals, it may be more difficult to detect disease in its early stages.

Handling of birds for sample collection

Various samples can be collected for health

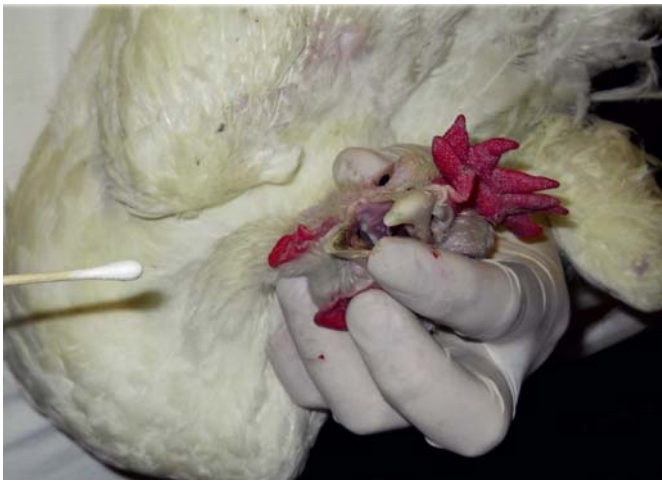

Fig.9.17: Sample collection is needed for monitoring flock health. Personnel should be trained to understand the method required for sampling birds, and should use procedures that minimize bird stress and injury during live bird handling and sample collection. Handling methods should keep the bird calm and secure and result in a good quality sample.



Fig.9.18: Culling should include all birds that have a physical defect or severe injury that prohibits normal movement, cannot access feed and water, are severely debilitated or those that will not likely recover. These birds should be culled and euthanized to limit further pain, distress or suffering.



Fig.9.19: All euthanasia methods should be irreversible, humane, efficient and be performed on a timely basis. As shown in this example, cervical dislocation is a commonly used method of euthanasia for individual poultry.



Fig.9.20: The basics for optimal conditions and poultry welfare on the farm include: feed, water, lighting, temperature, air quality and a safe, secure environment. From the day of bird placement to the day that the birds are removed from the farm, the farmer must verify and adjust for these 6 items on a daily basis as the birds grow and develop. By doing this, the poultry should achieve the 5 Freedoms for Animal Welfare (freedom from hunger/thirst; freedom to express normal behavior; freedom from pain, injury and disease; freedom from fear/distress; freedom from discomfort).

monitoring that requires individual bird handling. From live birds, these samples include blood, cleft palate or tracheal swab, fecal or litter swab, cloacal or rectal swab, and feather samples. Sometimes, it is necessary to collect organs or tissue samples from dead birds (recently euthanized birds or fresh mortality). Depending on the age and species of the bird, the type of test and the disease of concern, the responsible veterinarian should determine the type of sample needed (blood, swab, *etc.*), the amount needed (volume per bird or flock), and the frequency of sampling.

For the live bird sample collection, it is necessary to limit the potential for stress and injury when the bird is selected and handled. Handling should ensure that the bird is kept calm, the body weight is supported, and that minimal stress and injury occurs during the sample collection. Personnel responsible for sample collection must be fully trained in bird handling, sample collection, and sample preservation methods and must dispose of all rubbish in an approved location so that the flock is not exposed to trash that may be ingested or stepped on.

CULLING & EUTHANASIA METHODS

Culling

Culling is defined as the process of removing an animal based on specific criteria. Examples of culling reasons include: birds with abnormal development, birds that cannot get to food/water due to a gait or anatomical defect, birds that are the wrong sex for mating, birds with a severe injury or physical defect, severely debilitated birds (weak, diseased, *etc.*), or birds that do not meet the expected standards (severely underweight, *etc.*). For these culled birds, euthanasia is the most humane outcome as it will end the bird's suffering.

Euthanasia

Euthanasia is defined as the act or practice of killing or permitting the death of animals in a relatively painless way that is not cruel to the animal. It is important to recognize that no method of euthanasia is "pleasant". All staff working with live animals should be trained in the identification of birds for culling and in the approved methods or techniques for euthanasia. Regardless of the technique used, all euthanasia methods should ensure: minimal pain and distress to the bird and the flock, a rapid loss of consciousness, and death should be achieved quickly and consistently. The method should result in a humane, irreversible and efficient death for the bird and be performed on a timely basis with respect to bird(s).

The following is a general list of euthanasia methods that are accepted in many countries with modern poultry industries. However, the method used on a farm or in a hatchery will depend on the species and type of poultry, the age or weight of the bird, the availability of equipment at the facility, and any specific guidelines or regulations that may be enforced by the facility manager, company, or government. *Hatchery euthanasia*: cervical dislocation (individual birds), maceration, gas euthanasia.

Farm euthanasia (individual birds): cervical dislocation (manual or mechanical method), gas euthanasia, electrical euthanasia, captive bolt application, blunt force trauma, injection of approved barbiturates.

Farm euthanasia (whole house or farm): gas euthanasia, foam euthanasia, or other mechanical method (described above for individual birds).

HANDLING & TRANSPORT PRACTICES TO OPTIMIZE POULTRY WELFARE

Poultry need to be handled and transported alive for various reasons including: transfer of birds at the rearing facility to the production facility; transport of birds for slaughter; transport of birds at the end of production period (egg-laying flock); transport of additional male birds for spiking into an existing breeder flock; transport of birds to a laboratory for additional diagnostic testing. In all of these situations, handling and transport practices must be carefully performed to reduce the possibility of broken bones, scratches, bruises, thermal stress and death of the bird(s). Catching and loading may be conducted manually (legs or wings), by machine, or a combination of the two depending on the location and the type of bird. In general, birds raised inside environmentally controlled, enclosed houses are not accustomed to a great deal of external stimulation; therefore the introduction of the various catching crew personnel and equipment will likely be a stressor for the flock, but this stress can be minimized with trained personnel and the use of welfare-oriented techniques. Examples of these techniques that can be incorporated into the handling, catching and transportation practices include lighting reduction, withdrawal of feed and water, maintenance of equipment and transport vehicle, loading and unloading, culling and euthanasia.

Lighting reduction

By reducing the hours of darkness in the days just prior to catch, the birds can be acclimated to a higher level of activity and will be less stressed on the actual day of catching. When the catching crew and employees enter the house or pen, they should walk slowly and continue to use low-level lighting that will avoid piling and flightiness of the flock which can result in bruises or scratches on the birds. Some companies have also found the use of head-lamps and red-lights on mobile equipment to be helpful during the catching process to further reduce stress for the flock.

Withdrawal of feed & water

To minimize injury with equipment, most catching crews and farmers will raise equipment to have it out of the way as this gives the birds and the people more room to move about freely. For birds going to

slaughter, the withdrawal of feed and water is needed to reduce the likelihood of carcass contamination during the slaughter process. For breeding birds being transferred to a separate farm, the withdrawal of feed can also help reduce the chance of crop impaction or choking when birds are handled for the moving process. Depending on the climate, temperature, age and type of the bird being transported, birds should be kept hydrated as long as possible and allowed to rehydrate if there are any serious delays in the catching process.

Maintenance of equipment & transport vehicle

As discussed in the farm and hatchery sections, maintenance is a key aspect of preventing bird injury, entrapment and death. For catching, loading, transportation and unloading procedures, equipment must be well-maintained and cleaned to enhance bird health and well-being, and to limit injury that will result in euthanasia for the bird after transfer. For equipment that is used very intensively (coops, modules, *etc.*), a person should be directly responsible for the evaluation of the equipment before and after use to ensure that no holes or sharp edges are present that can cause injury to the birds, or permit escape. Ideally, this evaluation should be part of a routine quality assurance audit and a maintenance program should be implemented to repair or replace any damaged equipment so that bird well-being will not be negatively impacted.

Transportation

The type of vehicle, distance for transport, and route of transport are important factors to consider when planning the movement of poultry. The transport supervisor and the driver should know the expected stocking rate for the transport vehicle and must take precautions to avoid exceeding the maximum stocking density of their vehicle as this can result in excessive thermal stress and suffocation due to overcrowding in the coop or module. Drivers should try to keep transport times to a minimum and choose a driving route that will limit exposure to disease for the birds. During cold weather, additional protection (boards or tarps) is needed for open vehicles to keep birds from getting too cold due to low temperatures and wind speed when the vehicle is moving. During hot weather, additional measures (use of water or cooling fans) may be used during the loading procedure or during the waiting period at the final destination to limit heat stress and mortality of the birds.

Loading & unloading

Manual or mechanical handling methods may be used to load and to unload birds from the coops or modules during the transfer procedure. For all procedures, it is important to keep the birds calm to reduce the risk of scratches, bruises and broken bones. Equipment and the loading/unloading procedures should be operated to avoid areas where the birds can be caught or hung, and to minimize pinch points. If mechanical methods are used, the belt speeds should be carefully monitored to prevent birds falling on each other and piling that can lead to suffocation if birds are over-crowded.

Culling & euthanasia during catching

While culling is the primary responsibility of the farmer or caretaker, the catching crew should not load or transport any sick or injured birds. If transported, birds that are debilitated (sick, injured, *etc.*) are more likely to suffer and be less able to cope with their environment during the transportation process. Thus, cull birds should be humanely euthanized on the farm and disposed of in accordance with the farm's mortality method.

SLAUGHTER FACILITY PRACTICES TO OPTIMIZE POULTRY WELFARE

For poultry, slaughter is a viable option for economic and sustainability features of the industry and is also a humane method to end the life of the bird. Depending on the country, culture and the type of the bird, the method used for slaughter may vary. For all methods, birds should be handled calmly and safely during the unloading and shackling procedures to minimize scratches, bruises, stress, and broken bones. All personnel should be fully trained in bird handling and euthanasia methods so that they can act quickly and appropriately when evaluating and handling the birds. For all methods (gas stunning, electrical stunning, controlled atmosphere stunning, and religious slaughter), it is also important for the personnel involved to understand and to recognize normal bird behavior and attributes of good health within the flock. With this knowledge, if there are any abnormal characteristics noted, slaughter personnel should immediately inform their manager and/or veterinarian so that a decision can be made for optimizing the well-being and health of the flock. Equipment should also be maintained and set-up in a manner to promote a calm environment for the birds and to ensure that death is achieved quickly and efficiently.

Examples of items to monitor in a slaughter facility that can enhance bird well-being include lairage area, unloading and shackling area, shackling methods, method and consistency of stunning method, technique and consistency of slaughter methods and monitoring for bird welfare.

Lairage area

The holding or lairage area is a critical area at all slaughter facilities as it can have an important impact on the yield (shrinkage of carcass) of the bird as well as the overall well-being and livability of the flock. Time spent in the lairage area should be kept to a minimum and provisions should be made to keep the birds within the thermo-neutral temperature zone so that heat/cold stress do not negatively influence the outcome of the flock. Provisions may include the use of a covered area, use of fans and/or misters, and a vehicle rotation system to guarantee that loads are processed in order to reduce waiting times.

Unloading & shackling area

The manual or mechanical methods used to unload the birds should be carried out to limit over-crowding and injury. Lighting in shackling area should be kept to a minimum so that live birds will remain calm. Some facilities may use a 'black light' in an enclosed room or a curtain to limit the exposure to natural light as bright light can increase the activity level of birds. Adequate ventilation is important for shackling personnel and for birds to optimize comfort within this busy and dusty environment.

Shackling methods

For shackling of live birds and previously stunned (stunned due to exposure to gas or controlled atmosphere) birds, the handling of the bird and the accuracy of shackling is important to reduce bone breakage and bruising before slaughter. All birds should be shackled by both legs and conducted in a manner that does not cause increased stress or physical damage to the thigh, hock, foot or hip of the bird. The use of a breast (rub) bar is ideal in this area to keep the birds calm after shackling and to prevent excessive wing flapping and physical damage.

Method & consistency of stunning method

The protocol and technique(s) used for stunning will vary depending on the species of bird, the size of the bird and the mechanical system utilized by the slaughter facility. However, the method should provide accurate and consistent stunning for all poultry and be regularly monitored for efficiency and precision.

Technique & consistency of slaughter methods

The equipment and protocol used for the primary and secondary (backup) slaughter method are directly linked to the type of slaughter and the species involved. All methods should result in the complete and irreversible death of the bird with an accurate and quick method that limits the potential for missed birds and bird suffering. Regardless of the primary method used, a secondary or back-up method should be incorporated to guarantee that 100% of the birds have been killed before the line moves the bird to the next area in the slaughter plant. For meat quality and for animal welfare requirements, it is necessary that the carcass had an adequate time for bleeding before the carcass enters the scalding.

Monitoring for bird welfare

Audits or monitoring procedures are most frequently applied at the slaughter facility as a measure of bird care and handling (farm and transport) and methods used at the plant to optimize bird well-being and health. Items to evaluate at the slaughter plant include: skin integrity (hock burn and pododermatitis), bone integrity (broken wings, keel, legs), general body appearance (scratches, bruises, cleanliness of feathers), removal and appropriate method of euthanasia for injured, debilitated or sick birds that should not enter the slaughter facility. In addition to monitoring the physical attributes of the bird, a monitoring system should also be in place to frequently verify correct handling techniques by all staff involved in the process and to authenticate the function and maintenance of equipment and vehicles used for the process. Daily results and trends should be used to substantiate the welfare outcome for the system and to identify any areas (training, equipment, *etc.*) that require improvement to improve the care and handling of the birds.

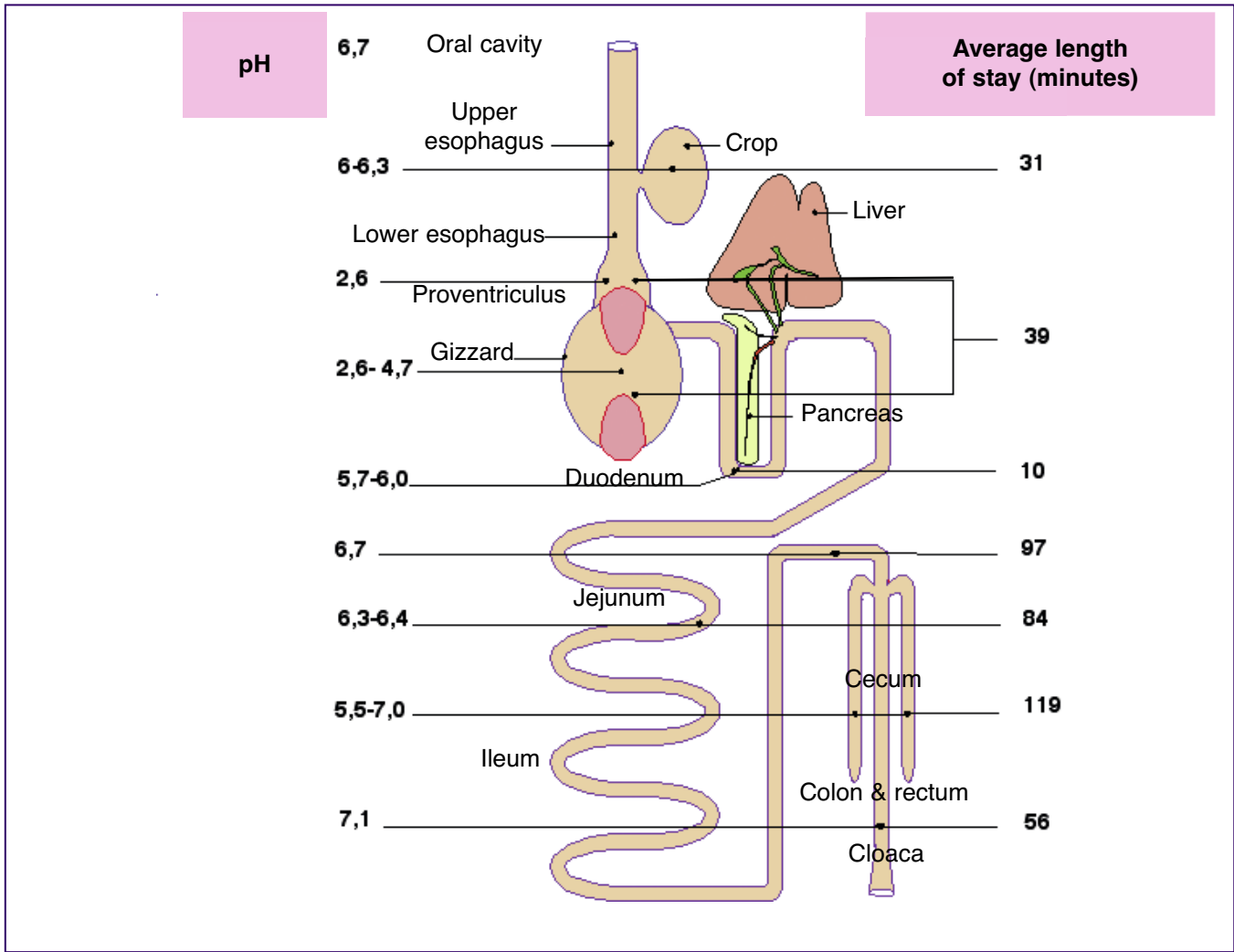


Fig.10.1: The chicken digestive tract, pH and time spent in the main segments.

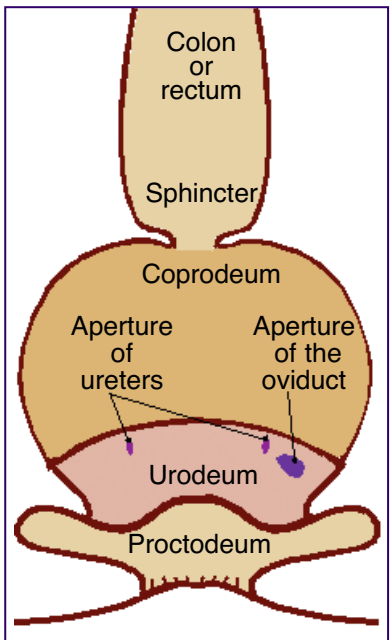


Fig.10.2: The cloaca and its components.

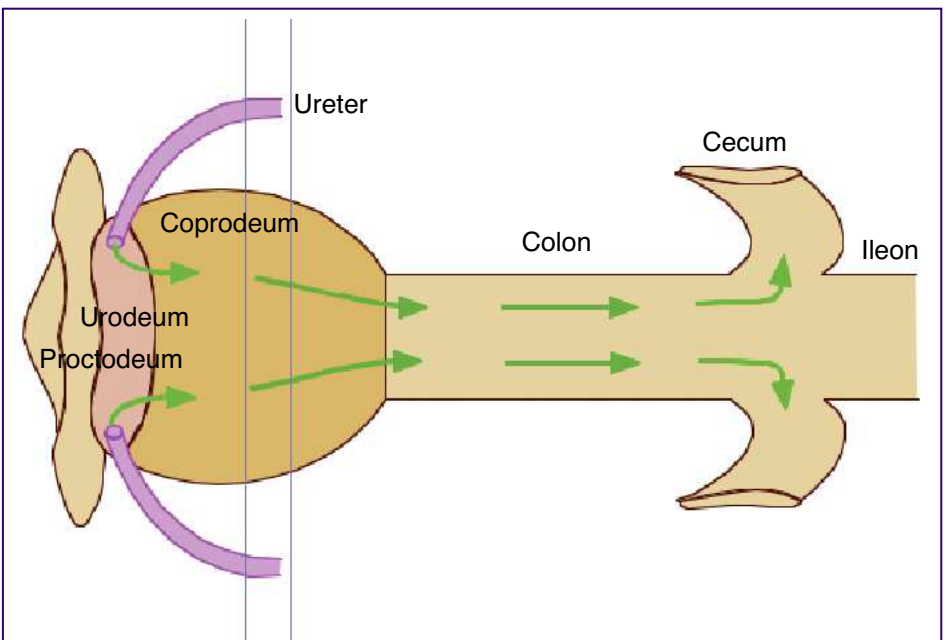


Fig.10.3: Relationship between the digestive and urinary systems: reflux of cloacal urine into the ceca.

10. PECULIARITIES OF AVIAN PHYSIOLOGY

The brief notions of avian physiology presented in this chapter are devoted essentially to the functions most directly related to poultry rearing conditions and to pathology.

Galliformes are the best known group of birds, and even if data are not generalizable to all birds, they form the basis for understanding all of this Order.

DIGESTION

The digestive system of birds has unique features:

- A toothless mouth;
- Esophagus with a diverticulum, the crop, with some functions normally found in a stomach;
- A stomach where the two main functions, mechanical and secretory, are allocated in two separate pockets, the proventriculus and the gizzard;
- A very short intestine, reaching the cloaca where the genital and urinary systems also converge.

Oral cavity, esophagus, crop

Grasping feed is performed by the beak. Its morphology varies between species depending on the nature of the diet (granivorous species, raptors, piscivorous, *etc.*).

Following ingestion, the feed is gathered to form a bolus under the influence of hyobranchio-lingual muscles and is moistened with saliva (7-30 ml/24h). However, there is no in-depth insalivation, but only surface lubrication. In addition to the muscles of the mouth, birds use upward and forward head movements to facilitate the progression of the feed to the back of the mouth and into the pharynx, which marks the beginning of the esophageal transit.

The esophagus is very extensible. It has many mucous glands that complement the lubricant role of saliva. Feed transit involves a peristalsis much slower than in mammals. At the entrance of the thorax, the feed can either continue its transit to the proventriculus or first go to the crop. This depends on the state of repletion of the proventriculus and gizzard, which determines the tone of the lower esophagus and the degree of opening of the orifice of the crop. When the gizzard is empty, feed passes into the proventriculus. If it is full, it gathers in the crop.

The crop, which is essentially a pouch derived from the esophagus, provides the following functions:

- Setting aside feed, it allows the ingestion of large meals, whereas the capacity of the proventriculus and gizzard is limited. Storage in the crop «covers» the absence of feed intake during the dark period of the day (NB: external palpation of the crop allows determining whether the bird has just been fed or whether it is fasting).
- Soaking feed in water and fragmenting its most brittle components.
- Microbial digestion of a portion of the starch with lactic acid formation. The responsible bacterial flora (*lactobacilli*) is absent from the feed. Besides lactic acid, acetic acid and ethanol are the usual constituents of the crop content. The presence of pepsin is due to a reflux from the proventriculus.

Stomach: proventriculus and gizzard

The proventriculus is the secretory pouch producing gastric juice responsible for «chemical» digestion. Because of rapid transit and low capacity of this reservoir, the effect of the gastric secretion occurs primarily in the subsequent two segments of the digestive tract, the gizzard and duodenum, with the assistance of back and forth movements of digesta between the three segments.

Secretion, as in mammals, contains hydrochloric acid and pepsin, but these components are present in greater quantity in birds. The flow is almost continuous in the case of *ad libitum* feeding. Stimulating factors are both nervous (influence of the vagus nerve) and humoral (gastrin). Gastric secretion (proventriculus) may cause erosions (from weak erosions to ulcers) in the gizzard rather than in the proventriculus. Similarly, hypersecretion can be induced by histamine, some of which is found in the feed.

The gizzard is designed to grind feed. In fact, it combines the functions of mastication absent in birds and mixing of ingesta with gastric juice. From a histological point of view, it is a huge smooth muscle. Its color is dark red due to myoglobin, which characterizes the strong and sustained muscle contractions. The nature of the diet is the main determinant of this motor activity: switching

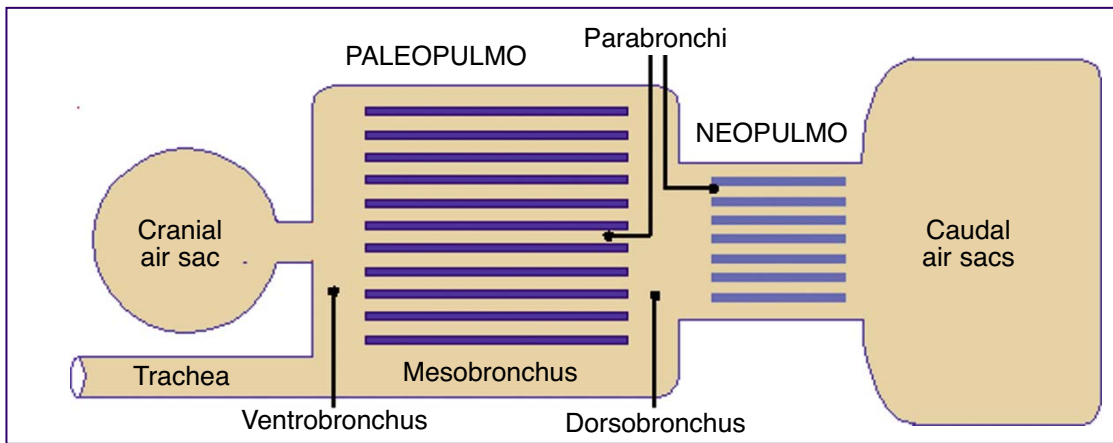


Fig.10.4: Schematic representation of the respiratory tract.

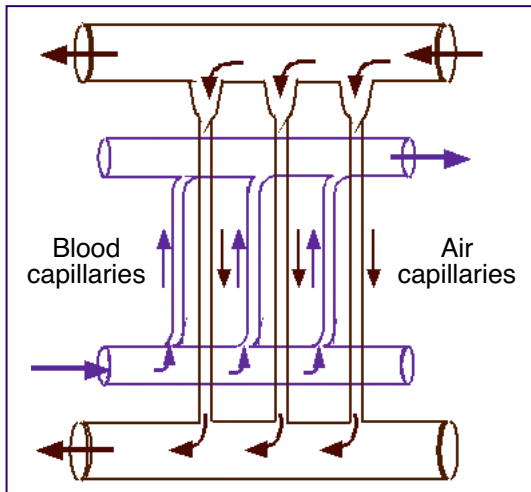


Fig.10.5: Air capillaries and counter-current pulmonary gas exchange.

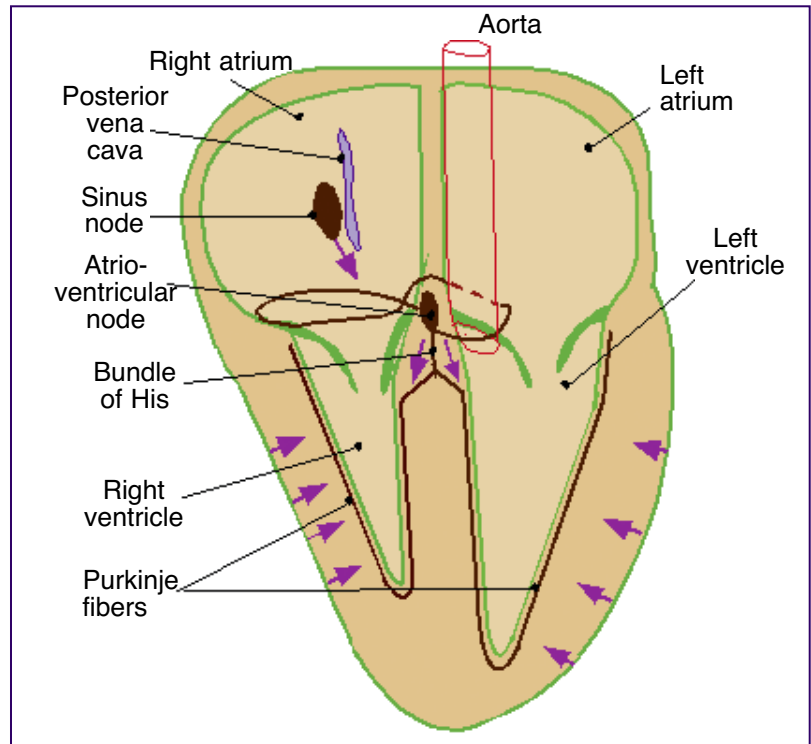


Fig.10.6: Heart of a chicken, excitomotor and driving tissues, and myocardial activation.

from a flour diet to unmilled cereals produces an 85% increase in electromyography burst activity. Over time, this difference in activity affects the development of the organ. It is not as developed in chickens raised under conventional commercial conditions compared to organic production.

The mechanical action produced by the grinding gizzard is a trituration that splits cereal grains. In birds raised on the ground and having access to gravel, their gizzard contains gravel to support the milling process, although it is not indispensable. Instinctively, chickens will ingest gravel, and this

behavior is strongly stimulated if they are deprived of gravel for a period of time. Calcareous gravel dissolves under the combined action of friction and hydrochloric acid, which contributes to calcium absorption.

Proventriculus and gizzard motility is inhibited by various stimuli from duodenal origin, such as distention, the presence of acid, oil or saline solution, which are factors similar to those identified in mammals. Note that there are refluxes from the duodenum in the gizzard during normal duodenal motility.

Intestine

Digestion begins in the small intestine under the influence of gastric juice: in chickens, the junction of the pancreatic and bile ducts is located at the end of the duodenum, leaving the entire duodenal loop to prolong the action of gastric juice.

Pancreatic and biliary secretions provide the same components as in mammals: bicarbonates, enzymes, bile salts. The enzymatic components of the pancreatic juice contain amylase, lipase and proteolytic enzymes.

During fetal development, the intestine is at the end of its ontogeny at day 16. The enzymatic activities of digestion are low in the newborn chick, but the ability to digest carbohydrates (maltase and sucrase), present at birth, develops during the first few days and peaks at 8 days of age. Lactase is not present at any time in the gastrointestinal tract. The digestibility of fat is low at birth, and in the first few weeks (4-8 weeks) only unsaturated fats are used. Thereafter, the digestion of highly saturated fat becomes possible. Finally, the development of enzyme activities is very rapid compared to mammals that have two critical periods (birth and weaning). In birds, the adaptation of enzymatic activity is almost immediate.

The characteristics of the large intestine are the relative simplicity of the colon, slightly different from the small intestine, and the existence of two ceca. These two ceca are highly variable depending on the species: absent in the pigeon, they are usually well developed in granivores and atrophied in raptors. The filling of the ceca does not come from the small intestine (a barium test meal does not enter the ceca), but from the colon (a radiological opacifier of the urinary tract injected intravenously reaches the cloaca after passing through the kidneys and ureters and finally opacifying the ceca, indicating that they are filled in a retrograde way from the colon and cloaca). The ceca do not empty frequently (1-2 times per 24 hours). It does not occur during the dark period, but rather at the end of the lighting period.

The digestive functions of the ceca are: digestion by microorganisms of the part of the meal remaining after chemical digestion (including a fraction of the cellulose), the synthesis of B vitamins, the absorption of water from the digesta and urine. Water reabsorption is enhanced when the fluid balance is difficult to adjust, for example in case of heat exposure.

BREATHING

Mechanics of respiratory exchange

The main peculiarities of the respiratory function are the structure and mechanisms of gas exchange. Indeed, in mammals, the lungs have a cul-de-sac structure which involves a tidal air movement (air flowing in and out of the lungs) and mechanical properties ensuring the necessary volume changes required during inspiration and expiration. By contrast, birds have a rigid thoracic cage and lung parenchyma. The diaphragm, which limits the thorax caudally and plays a significant role during inspiration in mammals, is absent in birds. It is replaced by a thin bronchopleural membrane attached to the ribs by fascicles of muscle fibers (costopulmonary muscles) that actually contract during expiration. The lungs, which occupy only the upper part of the thorax, are permanently deployed and their volume does not vary during respiration. The gas exchange areas and air capillaries are permanently maintained in an open state. The flow of the gas stream is only possible thanks to auxiliary devices, air sacs, which store and distribute the air during the respiratory cycle.

Exchanges between air capillaries and blood vessels that surround them are continuous and their efficiency benefits from their cross-current flow. The gas exchange performance in birds is superior to the one in mammals: for the same body size, with smaller lungs, birds have a lower respiratory rate.

The trachea extends within each lung by an axial channel, the mesobronchus. It dispatches a first set of branches, the four ventrobronchi and later a group of seven to ten dorsobronchi. The ramifications between dorso- and ventrobronchi are the parabronchi of the paleopulmo, a set of ducts parallel to each other and also parallel to the mesobronchus. Towards the back, a network of parabronchi in series with the mesobronchus comes between the latter and the caudal air sacs (abdominal sac and caudal thoracic sac). This second network of parabronchi constitutes the neopulmo.

Breathing and thermolysis

Birds have no sweat glands, so the only possible thermolysis mechanism is the evaporation of water via the airways by temperature induced polypnea (panting). As in mammals that use this mechanism, evaporation occurs in the upper respiratory tract (oral and/or pituitary mucosa) and

in the tracheobronchial airways. The air sacs provide an additional outlet to remove excess heat. Their value stems from the fact that they surround all the thoracic and abdominal organs, collecting heat from them and serving as areas of evaporation.

When panting occurs, ventilation is significantly increased, because in parallel with the increase in respiratory rate, the tidal volume is not proportionally reduced, especially at lower frequencies. Panting increases the release of CO₂ and tends to produce respiratory alkalosis: in chickens, the pH can rise up to 7.7, while PCO₂ (carbon dioxide partial pressure) can drop well below 10 mmHg. In some species (pigeon, owl, duck, pelican, etc.), panting comes along with a throat tremor referred to as gular flutter. It is a vibration of the floor of the buccal cavity with the beak remaining open, which promotes water evaporation. This vibration may occur at a frequency identical to that of the polypnea (680/mn in pigeons) or at a different rate (230 to 290/mn in pelicans, while their respiratory rate is only 135/mn).

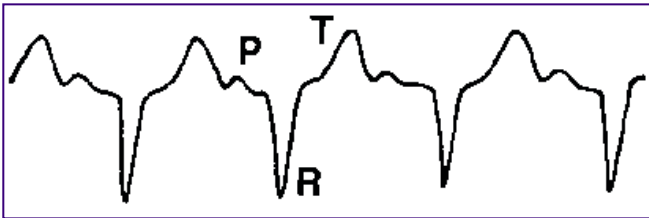


Fig.10.7: Bird electrocardiogram.

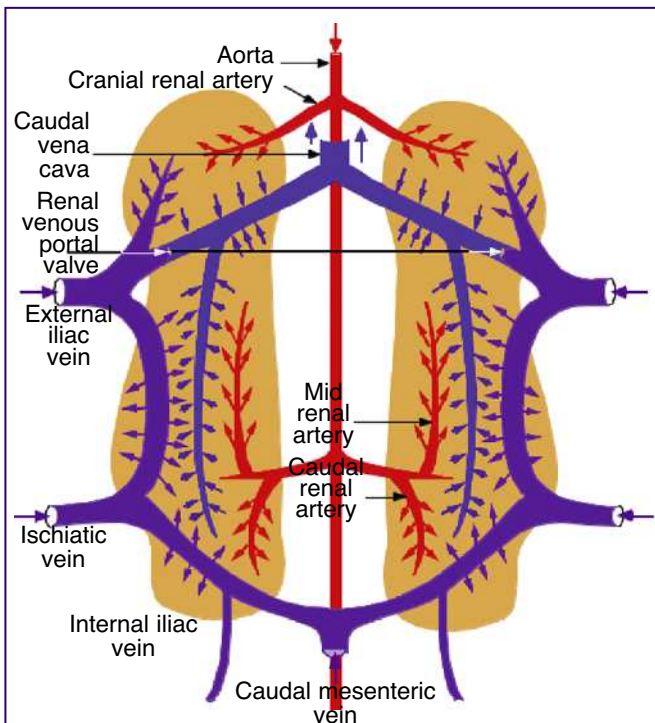


Fig.10.8: Vascularization of the kidney and renal portal system.

CIRCULATION

The heart of birds, like that of mammals, has four chambers. There are still some physiological aspects of heart contractions that are poorly understood in birds. There is an excitatory and conductive system similar to that of mammals (sinoatrial node, atrioventricular node, bundle of His) but this nodal system has additional elements such as rings around the right atrioventricular orifice and the opening of the aorta. The electric activation occurs first in the subepicardial region and then reaches the subendocardial region. Initially explained by the existence of pathways (Purkinje's network) following the direction of coronary arterial distribution, this fact is hardly compatible with the image of a Purkinje's network being distributed exclusively from the subendocardial region.

In general, the heart rate in birds is much higher than in mammals of similar size. In all species, however, the principle holds that for a smaller body size, the heart rate is more elevated (200/min in ducks, 1000/min in canaries). Also, species with a significant capacity for physical exercise have a lower heart rate (250-450/min in chickens, 200/min in pigeons).

The electrocardiogram shows a P wave (sometimes not easily visible when the heart rate is elevated, e.g., above 200/min) and two waves of depolarization (R) and repolarization (T) in alternate positions.

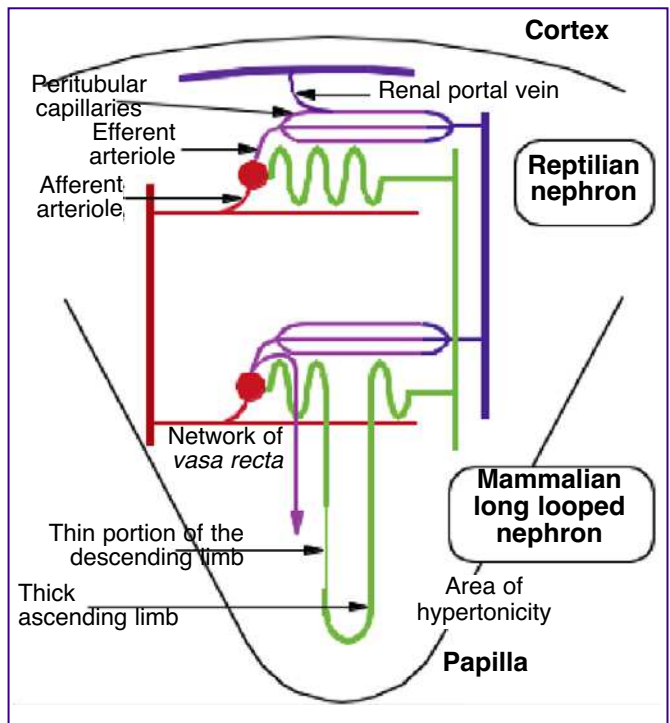


Fig.10.9: Microscopic organization of the kidney of birds, disposal of nephrons and vascular relationships.

The blood pressure of birds is significantly higher than in mammals. There are also significant differences depending on species, age and sex. In chickens, the systolic pressure approaches or even exceeds 200 mm Hg. In turkeys, it is the same order of magnitude and it may reach or even exceed 250 mm Hg. In *Gallus gallus*, the blood pressure is more elevated in males than in females (20 to 30 mm Hg) and a similar difference is also often found in turkeys.

Although it has not been decidedly proven, this high blood pressure may be related to the blood perfusion of the brain, which occurs under difficult conditions (because of the length of the neck and of the small diameter of the carotids) and the structure of the kidney (particular renal portal system).

URINARY SYSTEM

Morphologically, the kidney presents features that raise issues regarding the mechanisms of urine formation.

These features are:

- *The preservation of a marked lobulation*, such that each lobule is a sub-unit showing a cortex and a medulla completed by the "medullary cones" counterparts of the renal pyramids found in mammals. Within each medullary cone, the arrangement of the nephrons is typical: most nephrons are located in the cortex where they originate from a glomerulus rather remote from the surface. Tubules whose convolutions remain in the cortex do not have loops of Henle. These nephrons are called «reptilians». A portion of the nephrons located in a deeper region produces loops of Henle. They are called «mammalian». Some referred to as «long loop», sink deeply into the medulla. They are a numerical minority (15 to 30% of all nephrons). Only nephrons with long loops are involved in the creation of an osmotic pressure gradient. Their low numbers, the poor development of the renal papilla and the low availability of urea explain why most birds have a limited capacity to concentrate urine. The maximum capacity to concentrate urine is usually by a factor of 2. It is sometimes superior in birds living in specific habitats, such as quails in the desert (x 2.5) and swamp sparrows found in brackish marshes (x 5).

- The existence of a *particular portal system*, as the veins draining the hind limbs, pelvis, the terminal portion of the intestine and the rump join

the ipsilateral kidney. The iliac veins are divided as they approach the kidney and form a portal network at its surface. These veins join the peritubular capillaries of the cortex, that is to say, those surrounding the reptilian nephrons. The system diverts into the kidney a variable portion of the blood from the hind limbs, pelvis and rump region and from the posterior part of the intestine. A valve, which when opened allows a direct passage to the posterior vena cava, adjusts the flow that will be directed to the kidney.

- *Channels collecting urine* are distributed in two areas, perilobular or medullary, before joining the renal pelvises.

Birds do not metabolize uric acid and nitrogenous wastes into urea and so they have a significant amount of this acid to eliminate (urea accounts for only 1-10% of nitrogen removal). Circulating uric acid is removed by a complex renal process that includes:

- glomerular filtration (quantitatively 10% of the elimination rate),
- tubular secretion (a concurrent reabsorption process exists).

The portal system is the main conveyor of circulating urates, since under normal conditions it contributes to nearly 60% of total urate elimination.

Urate concentration in urine is between 0.1 and 1 mol/L, which exceeds the solubility limit. In urine, urates are not in the form of solutes, but rather in colloidal suspension visible as white threads. This particular form allows increasing the amount of urates without augmenting the osmotic pressure, as only the dissolved form is responsible for the osmotic pressure. This mechanism makes possible the elimination of these salts by a kidney unsuitable for the production of hyperosmotic urine. Below 25 mmol/L, only 10 to 20% of uric acid is in a precipitated form; this proportion rises to 95% when the concentration exceeds 200 mmol/L.

- *The urine produced by the kidney reaches the cloaca* where it can flow back into the colon and ceca. Additional water reabsorption may take place, depending on physiological conditions. Only about 2-3% of available water may be recovered. This proportion is greater in cases of hyponatremia or when there is a loss of salt. Reabsorption of water in the cloaca or rectum is very minimal.

The water balance is thus more precarious than in most mammals.



S Maeder - LDA 22



S Maeder - LDA 22



S Maeder - LDA 22

Fig.10.10, 10.11 & 10.12: The formation of the egg lasts 25 hours 30 minutes.

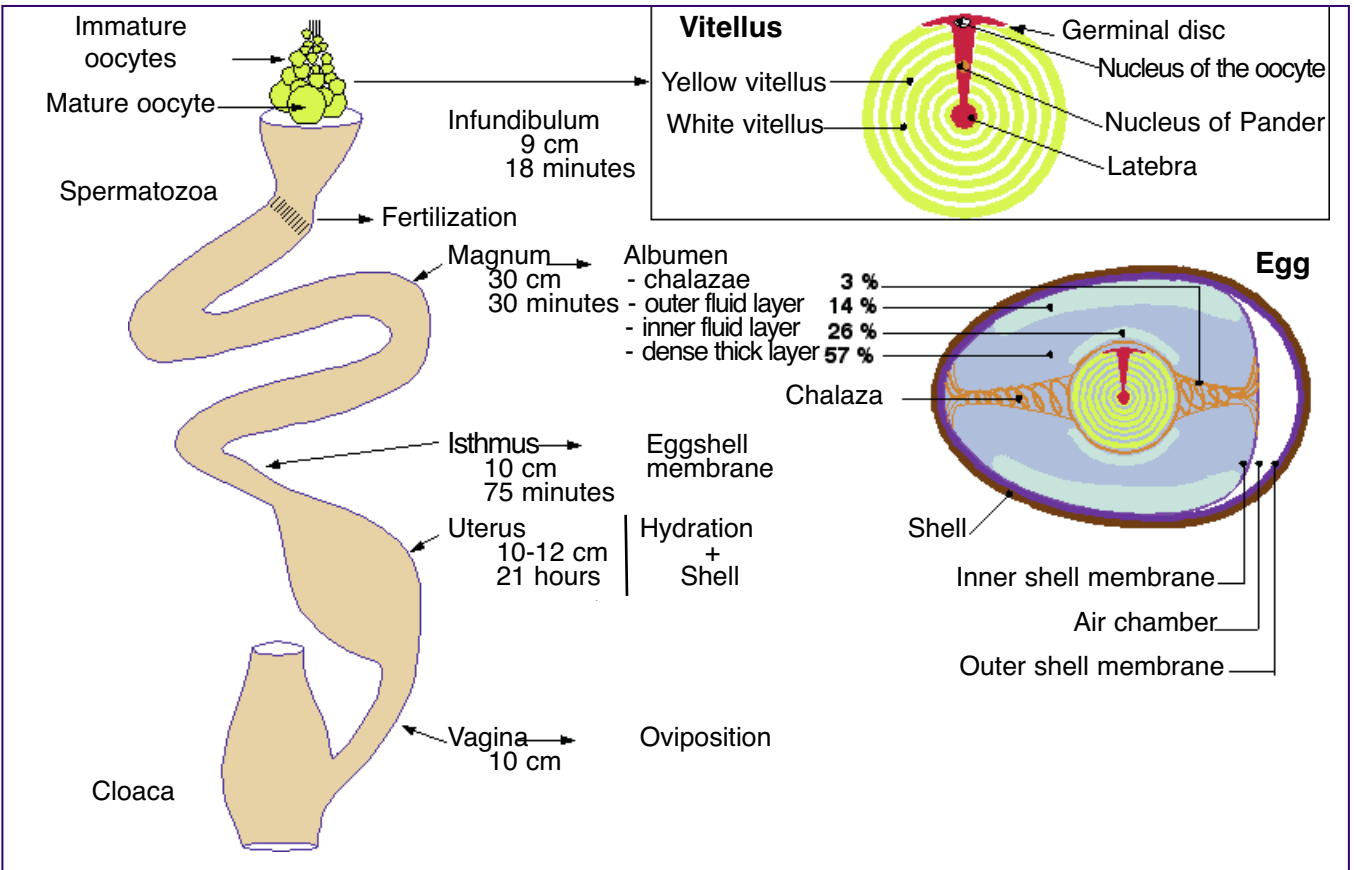


Fig.10.13: Egg formation in birds.

REPRODUCTION

Formation of the egg

The female reproductive tract of birds is asymmetric: only the left ovary and oviduct are developed and functional. In pullets, the ovary presents the appearance of a grape, where each sphere is a follicle containing an oocyte which has accumulated white vitellus during the prepubertal period. At onset of lay, some of these oocytes begin a growth phase which, in 8-10 days, enables the storage of large quantities of vitellus in concentric layers: this is the formation of the yolk, which has, on its surface, the germ cells. Each day brings a new layer of vitellus, where white vitellus (thin film formed at night) alternates with yellow vitellus (thick layer formed during the day).

The growth of the follicle is accompanied by structural changes: the growth pushes the germinal disc to the periphery, leaving a trace in the center: the latebra. The intermediate portion located beneath the germinal disc and having the appearance of a pad is called «nucleus of Pander». A group of 8 follicles undergoes this phase of rapid growth at the same time. There is a 24-hour gap between each yolk. During this phase, the weight of each one of them increases from 200 mg to 15-18 g.

When ovulation occurs, the infundibulum actively approaches the ovarian grape and tightly fits on the oocyte. If this movement is disrupted for pathological reasons, the result is an «abdominal laying». The oocyte enters the oviduct and if it encounters spermatozoa, fertilization occurs.

The passage in each segment of the oviduct contributes to the formation of the egg. In the magnum, the albumen, or egg white, is formed. This begins with the deposition of viscous proteins which, as the egg descends due to rotation movements, will produce a spiral arrangement: the chalazae (two spiral bands of tissue that suspend the yolk in the center of the albumen). Following this process, several layers of not very hydrated albumen are added. In the next portion, the isthmus, which has a small diameter, shell membranes consisting of keratin are added and attached over their entire surface with the exception of the air chamber. At the end of the isthmus, these membranes are still folded. In the uterus, successive changes occur: first, a saline solution is supplied to hydrate the albumen, giving it its final volume, followed by the formation of the shell which proceeds from three dif-

ferent layers: mammillary, spongy, and cuticular. The latter can eventually fix pigments.

The completed egg leaves the uterus and passes through the vagina which provides the outward transit during egg laying. The evagination of the latter portion of the vagina avoids direct contact between the egg and the walls of the cloaca and any fecal matter.

The shell formation requires calcium carbonate. The carbonate ion is formed from blood CO₂ under the influence of carbonic anhydrase. If CO₂ is not much available, for example during panting, the contribution of carbonate is insufficient, resulting in the formation of a more fragile shell. The polypnea that occurs under hot conditions may be responsible for a lack of carbonate formation, but this is usually limited because the shell is formed at night when the temperature is lower than during the day. Calcium is another indispensable element. The amount exported by the shell exceeds the amount provided by the feed. The 10-30% missing is obtained from the bone marrow. The latter is constituted before the coming into lay. It is mobilized by estrogen.

Oviposition = egg laying

Oviposition is the act by which the hen expels the completed egg. This term is used to distinguish this action from ovulation (release from the ovary of the ovum: an oocyte surrounded by vitellus). Oviposition follows a determinism which ensures that it occurs only during the illuminated phase of the nycthemeron and within a limited window of time. This determinism is also closely coordinated with ovulation.

Chronology of oviposition

In hens exposed to light from 6:00 a.m. to 9:00 p.m., most eggs are laid between 7:30 a.m. and 4:00 p.m. The largest number is laid around 11:00 in the morning.

The time of oviposition depends essentially on the time of ovulation and on the time taken for the ovum to pass through the female genital tract.

A new ovulation takes place only after oviposition and it normally occurs around 20 to 30 minutes later. Therefore, there are never two eggs at different stages of formation at the same time in the genital tract. The transfer time of the egg in the female genital tract being a bit over 24 hours (25 to 26 hrs), there is a daily variation of about 0.5 to 2 hours between two successive ovipositions.

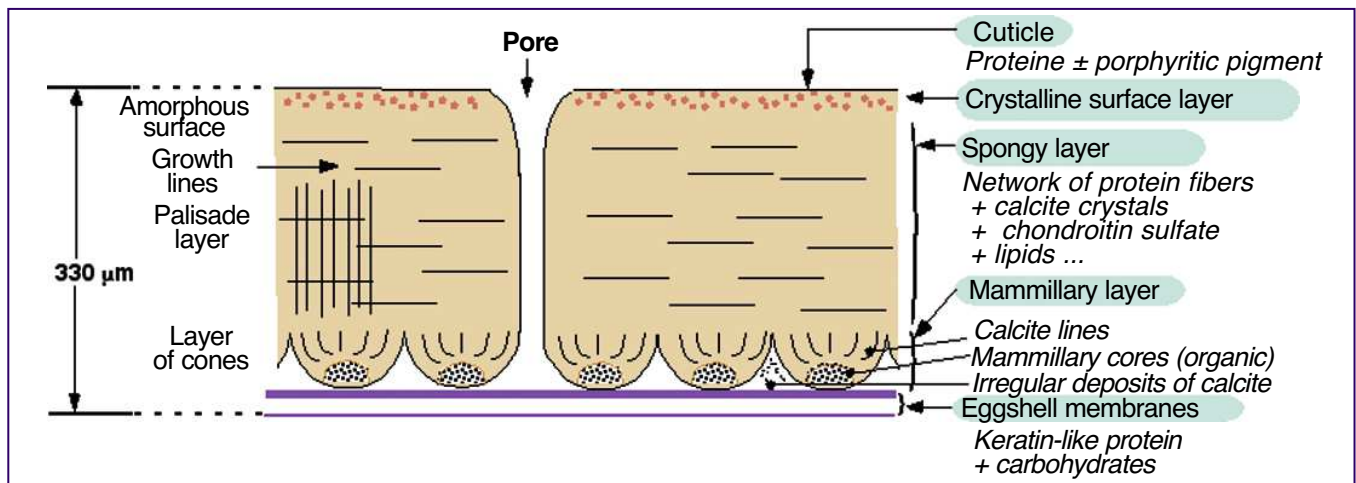


Fig.10.14: Structure of the eggshell.

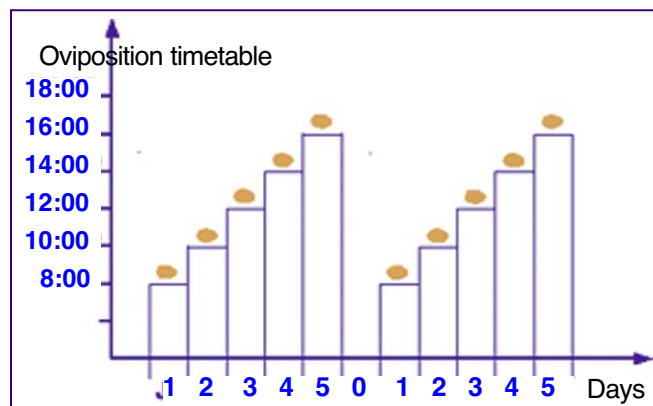


Fig.10.15: Oviposition timetable and egg-laying sequence.

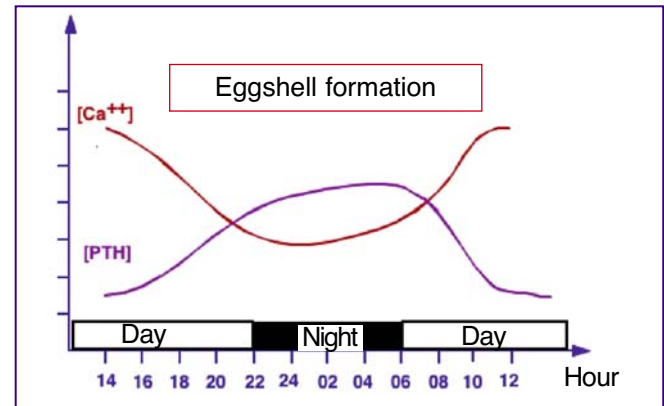


Fig.10.16: Chronology of the formation of the eggshell and corollaries.

Hence, a series or sequence of egg laying, lasting three to five days, and during which an egg is laid every day is followed by a pause (a day without egg laying) with resumption of another sequence starting with the next oviposition early in the morning and so on. Thus, the element determining the interval between two ovipositions is essentially the duration of egg transfer in the female tract. The shorter it is (closer to 24 hours), the shorter the gap between two successive ovipositions and the longer the egg laying sequence will be (at the beginning of the laying period for egg layer strains, one can observe sequences of 20 to 30 consecutive days with an egg laid each day).

Determinism

This concerns the determinism of both phenomena, ovulation and oviposition, and the setting of their respective timelines.

Role of the luteinizing hormone (LH)

One can validate that LH is the ovulation trigger, as in mammals. The injection of LH in hypophysectomized hens causes ovulation within 5 to 6 hours, similar to the observed delay between the spontaneous LH peak and ovulation. The LH surge depends on the hypothalamo-pituitary system and on the gonadotropin-releasing hormone (GnRH). The main issue is the nature of the signal activating the system and how it may vary according to the nycthemeron.

Role of progesterone

Actually, the triggering event is a release of progesterone. In birds, there is a positive feedback produced by progesterone on the release of LH. In the ovary (=ovarian grape), the follicles undergo their maturation, hierarchically delayed by one day

between each one of them. Their endocrine cells secrete estrogen and testosterone. The most advanced follicle secretes progesterone. The ability to secrete progesterone appears only on the last day of maturation. So it is the matured follicle that triggers its own release. There cannot be more than one egg per day. If two follicles reach maturity at the same time, giving an egg with double yolk, progesterone secretion is doubled.

During the laying cycle, the sequence of events is as follows: a small LH peak depending on the light-dark rhythm (micro-discharge) constitutes the initial event. This LH micro-peak stimulates the secretion of progesterone, which, by positive feedback, causes the release of LH which in turn triggers ovulation. A micro-LH surge occurs systematically during the dark period. If oviposition occurs late in the day, follicular maturation is not completed when the peak occurs and there is no progesterone response. The LH microdischarge occurs at nearly the same time for all the hens in the flock, which explains the synchronizing effect of LH on ovipositions.

REFERENCES

- Akester AR et al. A radiographic study of urine flow in the domestic fowl. *Brit Poult Sci*, 1967, 8: 209-215.
- Dantzler WH. Significance of comparative studies for renal physiology. *Am. J. Physiol.*, 1980, 23g: F437-F444.
- Duke GE. Gastrointestinal motility and its regulation. *Poultry Science*, 1982, 61: 1245-1256
- Fedde MR. Structure and gas-flow pattern in the avian respiratory system. *Poultry Science*, 1979, 59: 2642-2653.
- Hill KJ. Physiology of the digestive tract, in Freeman BM. *Physiology and biochemistry of the domestic fowl*, vol. 4, p. 31-49. Academic Press, New York, 1983.
- Le Bars H. Digestion chez les oiseaux, in Jacquot R et al, *Nutrition Animale*, vol I, p.353-363. Baillière, Paris, 1958.
- Mather FB et al. The influence of alkalosis on panting. *Comp Bioch Physiol A*, 1980, 67: 265-68.
- McNab JM. The avian caeca: a review. *World's Poultry Sci J*, 1973, 29: 251-263.
- Mongin P. Role of acid-base balance in the physiology of egg shell formation *World Poultry Sci J*, 1968, 24: 200-230.
- Moran E. Digestion and absorption of carbohydrates in fowl and events through perinatal development. *J Nutr*, 1985, 115: 665-674.
- Richards SA. Physiology of thermal panting in birds. *Ann Biol Anim Biochem Biophys*, 1970, 10 (suppl. n°2): 151-168.
- Roche M & Ruckebusch Y. A basic relationship between gastric and duodenal motilities in chickens. *Am J Physiol*, 1978, 2, 5 (6): E670-E677
- Sauveur B. Reproduction des volailles et production d'œufs. 1 vol 449p, INRA Paris 1988.
- Sturkie PD. *Avian Physiology*, 2ème ed., Comstock Cornell University, Ithaca New York, 1965.
- Smith Wst Jones in Sturkie's *Avian Physiology* Academic Press 2000.
- Wideman RF. Avian renal plasma flow autoregulation: contribution of the renal portal system. *J Comp Physiol B* (1991), 160: 663-669.

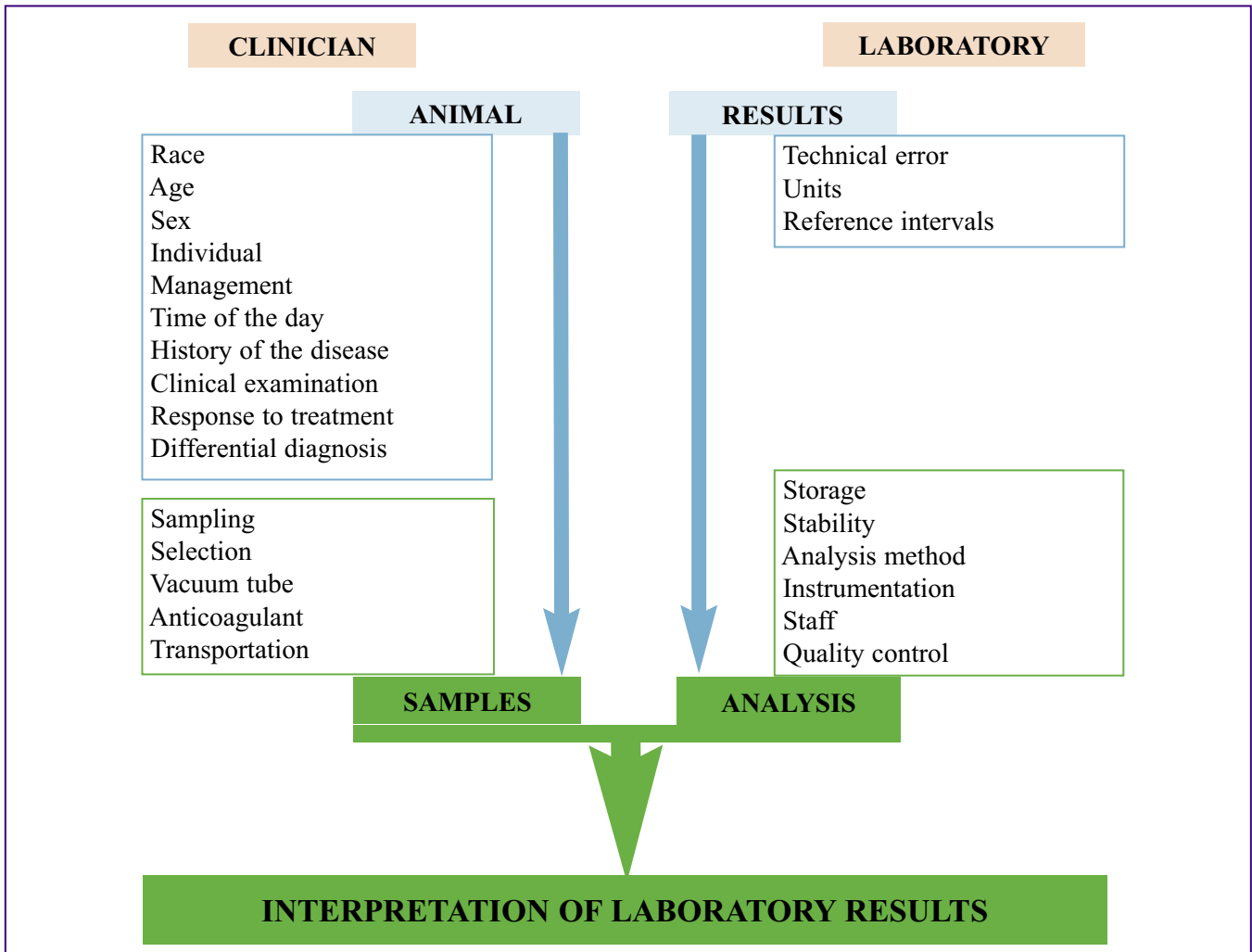


Fig.11.1: Interpretation of laboratory results and factors of variation.

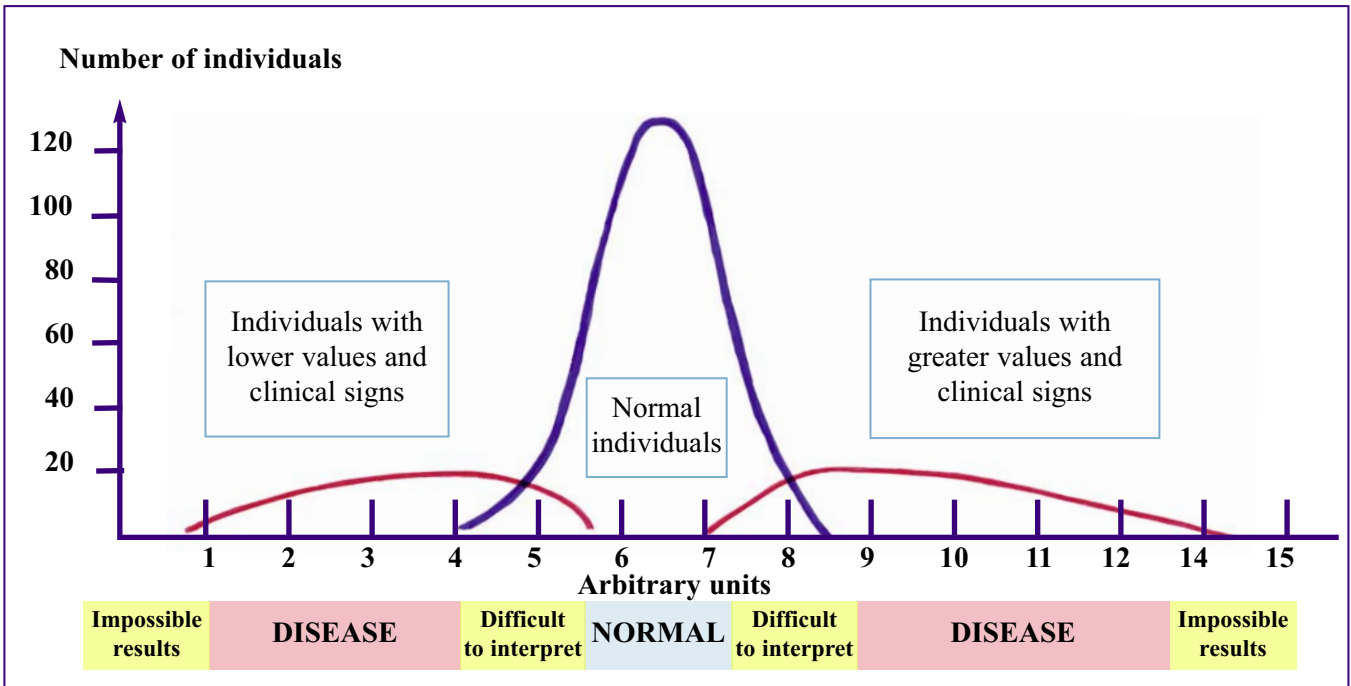


Fig.11.2: Graphical representation of the distribution of the results of a blood parameter.

11. BLOOD BIOCHEMISTRY IN BIRDS

INTRODUCTION

In avian medicine, blood biochemistry is frequently used to define the bird's metabolic status or to diagnose metabolic diseases. Blood samples should be sent to a veterinary clinical pathology laboratory. Interpretation of the results requires the use of reference values. The fundamental principle underlying veterinary clinical biochemistry is that any pathological disorder begins with variations in the blood biochemical parameters. These variations in reference values can be used as indicator of metabolic equilibrium, cellular integrity or nutritional status.

CHANGES IN BIOCHEMICAL BLOOD PARAMETERS

Biochemical blood results may be influenced by how samples are collected. It is important to minimize this by using adequate and consistent blood sampling procedures with the appropriate anticoagulant (e.g., lithium heparin is preferred for electrolyte analysis). Samples should be transported quickly (within two hours) to the laboratory and stored at 4°C or centrifuged to collect serum or plasma. For example, potassium has been shown to vary significantly after blood collection within 40 minutes in chickens and 20 minutes in pigeons. Analytical variations can be controlled by referring samples systematically to the same laboratory (state run laboratory or, when tests can be performed by the veterinary practitioner, in the clinic's laboratory). Today, veterinary practitioners may also use portable biochemistry analyzers that reduce variations due to sampling and transportation, and offer the advantage of generating immediate on-farm results.

Biological variations are very difficult to assess for a given individual. This is why it is difficult to define normal values. However, reference values can be defined for a specific population. The interpretation of blood parameter values implies knowing about how samples were collected and analyzed. It also implies having reference values to determine the range of normality for each parameter. Figure 11.1 shows various elements that need to be considered for the correct interpretation of laboratory results. In general, meat type birds will have higher normal values for enzymes associated with muscle cells such as creatinine kinase (CK),

aspartate aminotransaminase (AST) and alanine aminotransferase (ALT). Age differences are also important to consider especially as birds get older and their lung volume in relation to body weight decreases. This contributes to higher PCO₂ values, and increases in total protein and globulin levels as the immune system matures.

Several measures exist to identify and control or reduce the risk of errors during the sample testing process. A control serum or standard solution is used as part of several tests in order to assess the precision and accuracy of measurements.

SAMPLING & ANALYSIS OF BLOOD PARAMETERS

A 32 day-old chicken weighting 1800 g has a blood volume of about 120 mL. An adult chicken has 65 mL of blood per kg of body weight (BW) and an adult turkey has a blood volume of 70 mL/kg of BW.

Samples are taken by intracardiac puncture in growing chickens before euthanasia, with needle 20G X 50 mm. Blood sample (5 mL) are drawn in a tube without anticoagulant for biochemistry. In laying hens, sampling is done by wing vein puncture using needle 21G X 37.5 mm. Samples should be centrifuged at 3000 rpm for 10 minutes, one hour after blood collection and kept at 4°C until laboratory analysis.

For most blood test results obtained using laboratory analyzers, the procedure is essentially the same: for a given parameter, the biological sample is mixed with a specific reagent. This "sample-reagent" interaction directly or indirectly produces an absorbent compound that is measured by photometry. This specific absorption is proportional to the concentration of the parameter in the blood sample. Total protein measurement with Biuret reagent can be used to illustrate how it works. Under alkaline conditions, substances containing two or more peptide bonds form a purple complex with copper salts in the reagent. This approach is used to assess all parameters except electrolytes. A biochemical automated analyzer may be used to measure most serum parameters: glucose, total cholesterol, triglycerides, albumin, total protein, calcium, inorganic phosphorus, serum enzymes [AST, alkaline

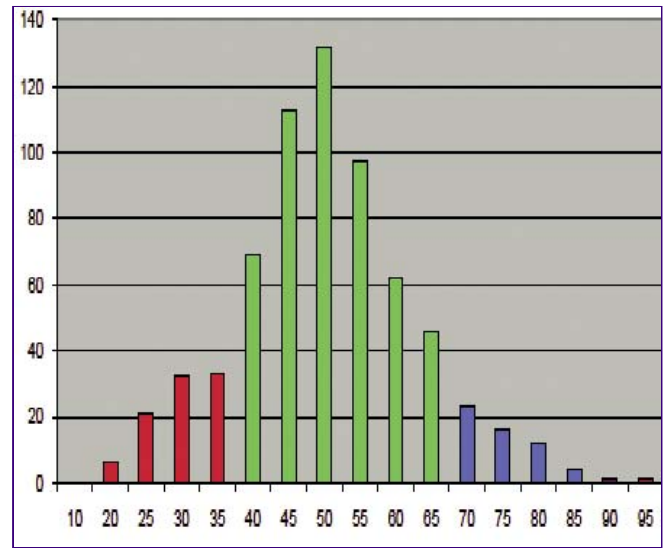
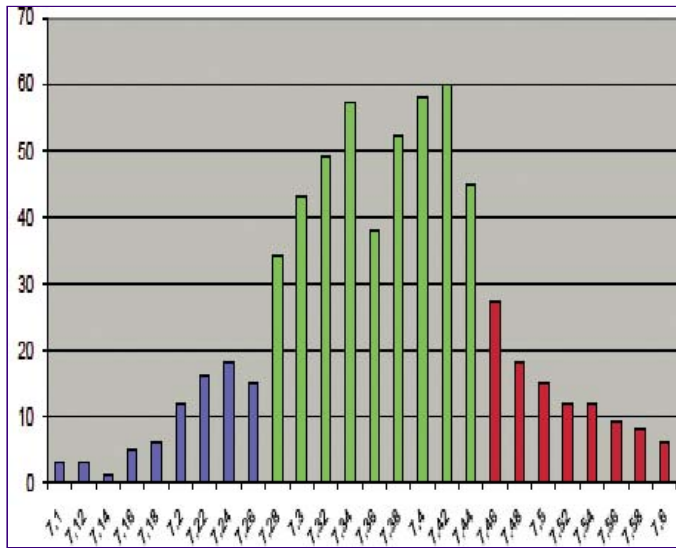


Fig.11.3: Blood pH represents the amount of H⁺ in the blood and is controlled by pCO₂ and HCO₃. It has a very narrow range for normal cell function 7.35 to 7.45 for humans. We use 7.28 to 7.45 in broiler type chickens.

Fig.11.4: Distribution of PvCO₂ in chickens.

	Normal pH (Homeostasis)	Metabolic acidosis	Respiratory acidosis	Metabolic alkalosis	Respiratory alkalosis
pH	7.28-7.44	↓	↓	↑	↑
pCO₂	40-65	↓	↑	↑	↓
HCO₃	24-33	↓	↑	↑	↓
Correlations between pCO₂ and HCO₃					
Examples		Diarrhea Lactic acidosis Ammonium chloride Excess HCl and amino acids	Respiratory disease Diaphragm paralysis Muscular dystrophy Encephalitis Bronchitis	Diuretics Vomiting or regurgitation feeding Hypokalemia Hypomagnesemia Sodium bicarbonate Laxative abuse Hypochloremia High soja content in diet	Heat stress Fever Pain High altitude Severe anemia Hepatic failure

Tabl.11.1: Acid-Base Disorders. Correlation between pCO₂ and HCO₃ for birds in acidosis in blue (pH<7.29) and birds in alkalosis in red (pH>7.45) and birds with a normal pH in green (pH between 7.29 and 7.45).

phosphatase (ALP), CK, gamma glutamyltransferase (GGT), glutamate dehydrogenase (GLDH) and lactate dehydrogenase (LDH)], creatinine and uric acid. Other blood parameters are calculated from those previously measured, such as Ca/P ratio, total globulin, albumin/globulin ratio (alb/glob) and anion gap.

Electrolyte concentrations are determined using a potentiometric method. The activity of any ion in an unknown solution can be determined using specific electrodes. The electrolyte analyzer measures sodium (Na), potassium (K), chloride (Cl) and carbon dioxide (bicarbonate or total carbon dioxide) in the sera.

REFERENCE VALUES

Obtaining reference values requires a rigorous process; reference individuals must be carefully selected. These individuals must meet specific criteria (such as age and type of production) and must look

healthy. Assuming that serum parameter values have a statistically normal distribution, about 95% of these values lie within two standard deviations of the mean. This provides the range of normal reference values. The interpretation of laboratory results is based on a comparison between these results and the reference values available for a defined population.

METABOLIC CHANGES

Until recently, blood biochemistry was mostly carried out in order to better understand the pathophysiology of poultry diseases. This was especially the case for disorders of lipid metabolism (fatty liver of chickens, layers, or geese; hyperlipidemia; hypercholesterolemia and atherosclerosis in layers). Now, biochemical blood parameters are also used to evaluate the metabolic state of a group of birds (hydration, electrolyte balance, renal function, nutritional status, liver function, immune system function) in relation to flock performances.

Parameters	Unit	Reference interval
Glucose	mmol/L	11.1 - 20.5
Total protein	g/L	26.0 - 46.0
Albumin	g/L	10.8 - 20.0
Total globulins	g/L	14.0 - 31.0
Alb/Glo		0.60 - 1.00
Calcium	mmol/L	1.80 - 3.00
Phosphorus	mmol/L	1.50 - 2.90
Ca/P		0.70 - 1.80
Cholesterol	mmol/L	2.90 - 4.50
Triglycerides	mmol/L	0.35 - 1.85
Sodium	mmol/L	137.8 - 157
Chlorides	mmol/L	98.5 - 120
Potassium	mmol/L	4.20 - 9.00
Bicarbonates	mmol/L	15.0 - 30.8
Anion gap	mmol/L	14.0 - 30.5
Creatinine	mmol/L	15 - 37
Uric acid	µmol/L	180 - 650
Total bilirubin	µmol/L	0.1 - 2.2
AST	U/L	70 - 315
GGT	U/L	8.0 - 25.0
LDH	U/L	200 - 600
ALP	U/L	600 - 15000
CK	U/L	650 - 7300

Tabl.11.2: Database of serum parameters obtained from blood samples performed in a group of 99 broiler chickens, aged 35 to 45 days. Reference intervals correspond to 2.5% and 97.5% percentiles. (Laboratory of Biochemistry, Faculty of Veterinary Medicine, University of Montreal).

Parameters	Unit	Reference interval
Glucose	mmol/L	10.6 - 19.0
Total protein	g/L	43.8 - 68.6
Albumin	g/L	22.3 - 28.0
Total globulin	g/L	21.5 - 42.0
Alb/Glo		0.64 - 1.1
Calcium	mmol/L	3.30 - 9.0
Phosphorus	mmol/L	1.50 - 2.80
Ca/P		1.60 - 4.90
Cholesterol	mmol/L	2.80 - 7.60
Triglycerides	mmol/L	3.6 - 36.4
Sodium	mmol/L	141 - 160
Chlorides	mmol/L	110 - 122
Potassium	mmol/L	3.9 - 8.10
Bicarbonates	mmol/L	14.5 - 27.5
Anion gap	mmol/L	10.5 - 31.0
Creatinine	mmol/L	19 - 37
Uric acid	µmol/L	180 - 650
Total bilirubin	µmol/L	0.6 - 31.0
AST	U/L	130 - 270
GGT	U/L	5 - 25
LDH	U/L	150 - 600
ALP	U/L	155 - 990
CK	U/L	35 - 1100

Tabl.11.3: Database of serum parameters obtained from blood samples performed in a group of 41 laying hens. Percentiles 2.5% and 97.5% correspond to the reference values of each group (Laboratory of Biochemistry, Faculty of Veterinary Medicine, University of Montreal).

Parameters	Normal values	Interpretation of a decrease	Interpretation of an increase
Glucose	11-16 mmol/L	Malnutrition, fasting High protein diet Hepatic disease, spiking mortality	Stress, diabetes mellitus Hyperthermia Corticotherapy
Total protein Albumin	30-60 g/L 23-33 g/L	Decreased albumin Protein deficiency (malnutrition, parasitism) Chronic infection, nephritis, hemorrhagic syndrome	Dehydration, chronic infection
Globulins	6-30 g/L	Malnutrition	Chronic or acute inflammatory reaction
Calcium Ionized Ca	2,25-5.93 mmol/L 4-6 mmol/L (layers) 1.35-1.55 mmol/L	Ca or vitamin D deficiency Calcium tetany Severe renal deficiency Hypoalbuminemia, apathy	Hypervitaminosis D Osteomyelitis Acidosis High Ca layer feed
Inorganic phosphorus	2.00-3.49 mmol/L	Rickets, anorexia, enteritis	Renal disease, hypervitaminosis D, hemoconcentration
Cholesterol	2.2-3.4 mmol/L		Obesity with hepatic steatosis Excess of lipids in the diet Fasting
Sodium	146-169 mmol/L	Fasting, diarrhea, adrenal insufficiency	Excess salt in the diet
Chlorides	105-118 mmol/L	Ataxia	Dehydration
Potassium	4.6-6.5 mmol/L	Diuretic therapy (Duck)	Kidney disease, adrenal insufficiency, dehydration
Anion gap	6-16 mmol/L	Chloride responsive	Metabolic acidosis
Base excess	-6 to +6	Metabolic alkalosis	Metabolic acidosis
Creatinine	80-164 μ mol/L		Kidney infection High protein diet
Uric acid	200-650 μ mol/L		Fasting, gouty arthritis, visceral gout, kidney disease (nephrocalcinosis, amyloidosis, nephritis), high protein diet
Total bilirubin*	0-3.42 μ mol/L		Severe hemolytic syndrome
AST	88-208 U/L 77-157 U/L ^a 30-170 U/L ^b 68 U/L ^c		Liver damage (non-specific), muscle damage (myopathy, intramuscular injection, trauma), sepsis
GGT	9-22 U/L ^a 7.1-21.9 U/L ^b 14,4 U/L ^c		Liver disease (cholestasis, hepatitis, steatosis), pancreatitis
LDH	99-281 U/L 7,699-885 U/L ^a 729-2,047 U/L ^b		Acute liver disease, hemolysis, muscle injury
ALP	24,5-44,4 200-1,060 U/L ^a 353-813 U/L ^b	Zinc deficiency	Increased activity of osteoblasts and osteoclasts (bone growth, spawning, rickets or osteomalacia), liver disease
CK	240-810 U/L 101-253 U/L 1,000-4,000 U/L ^b 4,5 U/L ^c		Myopathy, lead poisoning, neuropathy, ionophore intoxication
ALT*	353-813 U/L ^b		Liver or muscle damage
GLDH	0-6.6 U/L ^b 4.5 U/L ^c		Acute hepatic necrosis
α-amylase	296-638 U/L 196-638 U/L ^b		Pancreatitis

Tabl.11.4: Clinical biochemistry in poultry. Literature review of normal values and interpretation of variations. * Limited interest for diagnostic. a) Laying hens (bibliographic data); b) values in 20 hens (test at 30°C); c) Results in 3 flocks of laying hens (119 sera) (adapted from J Brugère-Picoux et al, 1987).

State of hydration, electrolyte & acid-base balance

Total proteins, hemoglobin and hematocrit values are useful to assess the degree of hydration. Mean values for sodium, potassium, chloride, bicarbonate and anion gap are used to evaluate electrolytes and the acid-base balance.

Renal function

The mean values of creatinine, uric acid, phosphorus and potassium provide an assessment of the rate of blood perfusion in the kidneys and the integrity of the nephrons.

Nutritional status

The nutritional status is evaluated based on the average values for glucose, cholesterol, triglycerides, albumin, hemoglobin, calcium, inorganic phosphorus, the Ca/P ratio and alkaline phosphatase.

Glycemia is very high in birds compared to mammals. Serum glucose reflects dietary carbohydrates and hepatic gluconeogenesis from amino acids.

Serum cholesterol and triglycerides values are closely related to dietary fat in growing birds and clinically healthy laying hens. However, moderate hypercholesterolemia can be physiological (up to 10.5 mmol/L) in hens in the early and late production periods.

The values for serum calcium, phosphorus and ALP are associated with mineral balance and bone mineral metabolism and blood pH.

Variations in the albumin and uric acid values are associated with the availability of amino acids in the diet. Purines and mycotoxins may also affect uric acid levels.

CK values are indicative of the integrity of muscle cells. A degenerative process in muscle tissues (myopathy) causes an increase in CK serum activity. Deficiencies in vitamin E or selenium, toxemia, or exposure to certain drugs are possible causes of myopathy.

Changes in serum ALT, GLDH and α -amylase have limited diagnostic value.

Liver function

Three aspects of the liver function are determined by assessing ALP for biliary excretion; the level of albumin as indicator of hepatocellular enzyme activities; and serum AST, LDH and GGT for the integrity of hepatocytes and their membranes.

Assessing bilirubin levels has a limited diagnostic value since birds are deficient in bilirubin reductase: bilirubin, greenish in color, is the main bile pigment. Measurement of bile acids is preferred in birds.

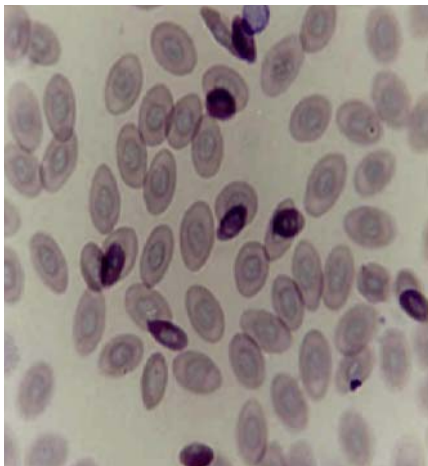
Hepatic steatosis reflects the accumulation of fat in the liver. In birds, this accumulation is a physiological adaptation to preserve energy but it could also be pathological.

Immune function

Immune function is assessed using average values for total globulins and albumin/globulins (Alb/Glo) ratio. Globulin values are lower in young birds than adults. There is a relationship between total globulin levels and immune system activities.

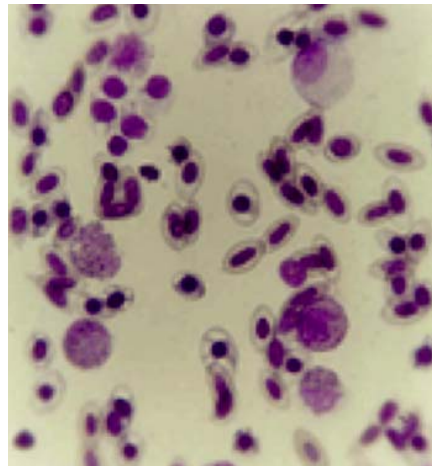
REFERENCES

- Brugère-Picoux J et al. Biochimie clinique en pathologie aviaire. Intérêt et limites des dosages enzymatiques chez la Poule. *Rec Méd Vét*, 1987,163 :1091-1099.
- Echols S. Collecting diagnostic samples in avian patients. *Vet. Clin North Am Exot Anim Pract*,1999,2:621-649.
- Gascoyne SC et al. Guidelines for the interpretation of laboratory findings in birds and mammals with unknown reference ranges: plasma biochemistry. *Vet Rec*,1994,134:7-11.
- Hrubec TC et al. Plasma versus serum: specific differences in biochemical analyte values. *J Avian Med Surg*. 2002,16:101-105.
- Tremblay A & Bernier G. Maladies d'origine nutritionnelle et métabolique. In «*Manuel de pathologie aviaire*». Ed. Brugère-Picoux J & Silim A, Ed. Pathologie médicale du bétail et des animaux de basse-cour, ENVA, Maisons-Alfort 1992, p343-354.



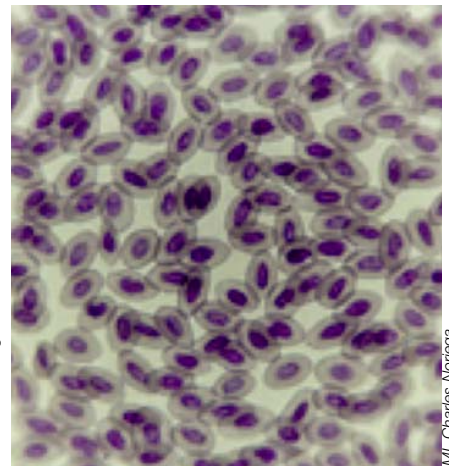
ML Charles Noriega

Fig.12.1: Microcytosis. Erythrocytes are small. This may be associated with Fe⁺⁺, Cu, Co and pyridoxine deficiencies. Microcytosis may also be found due to severe chronic conditions.



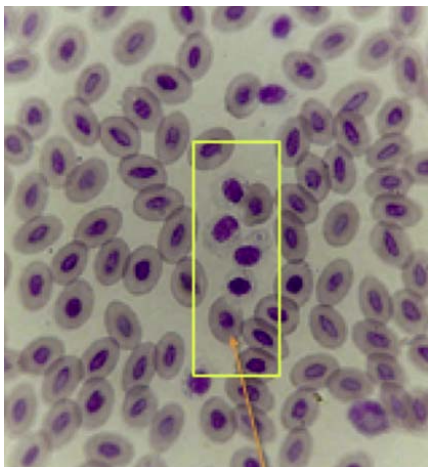
ML Charles Noriega

Fig.12.2: Leukocytosis is characteristic of inflammatory diseases.



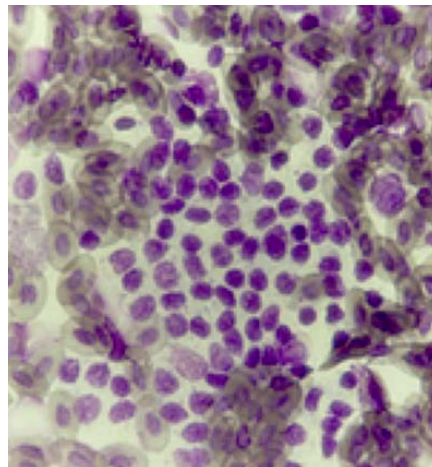
ML Charles Noriega

Fig.12.3: Leukopenia is associated with viral or severe chronic diseases, and in cases of immunodeficiency.



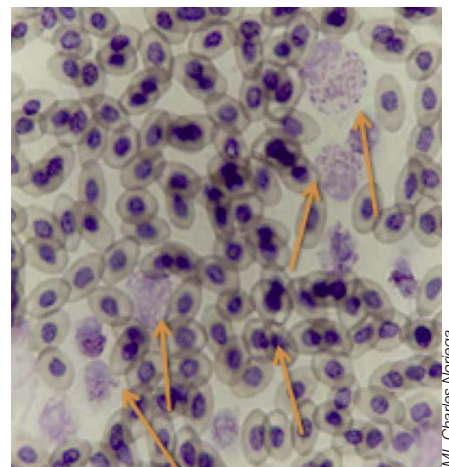
ML Charles Noriega

Fig.12.4: Trombocytes.



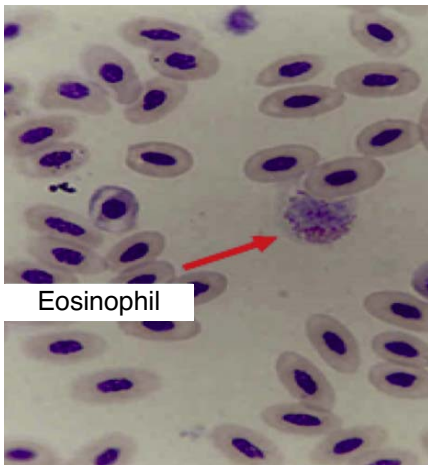ML Charles Noriega

Fig.12.5: Thrombocytosis is observed with acute severe inflammatory processes.



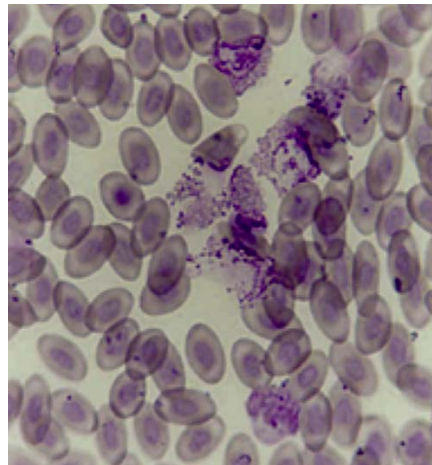
ML Charles Noriega

Fig.12.6: Leukocytosis with left shift (when the immature leukocytes proportion is greater than the mature leukocytes) is characteristic of a severe acute bacterial process such as peritonitis or septicemia.



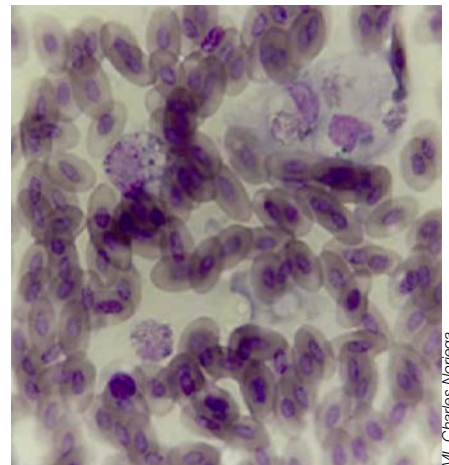
ML Charles Noriega

Fig.12.7: Eosinophils are often observed in cases of toxic and parasitic processes.



ML Charles Noriega

Fig.12.8: Basophilia. An increase in basophils is observed when birds are experiencing a stressful situation.



ML Charles Noriega

Fig.12.9: Leukocytes showing toxic changes: basophilia, vacuolization and toxic granulation. These changes are characteristic of severe chronic septic diseases.

12. AVIAN HEMATOLOGY

INTRODUCTION

Avian hematology is an important discipline for the diagnosis of avian diseases.

In some cases, subclinical diseases are not easy to diagnose by veterinarians. Avian hematology offers important tools for a complete diagnostic approach of certain pathological processes. Indeed, it may prevent reaching empirical conclusions that could lead to incorrect treatments.

Clinical laboratory tests, as for mammalians, can be applied to birds, keeping in mind that there are several differences to be considered, such as cell morphology.

Avian erythrocytes and thrombocytes are nucleated and the interpretation of hematology results must take into account the species and age of the individuals under investigation. Fortunately, reference parameters are readily available in the scientific literature to assist poultry specialists and diagnosticians.

Hematological findings must be viewed as part of an integral diagnostic approach, because they are often a very useful complement, but rarely a definitive diagnostic result. They assist veterinarians in recognizing the presence of several conditions, may they be inflammatory, viral, toxic, or myeloproliferative. They are also useful when investigating nutritional deficiencies and stress related conditions. They allow assessing the severity of these conditions via the observation of cell morphology and the measurement of parameters such as plasma protein concentration, hematocrit, and cell count. If necessary, these findings can be completed with coagulation and biochemical tests.

Hematological tests must be performed in a serial fashion. Indeed, the results obtained from a single sampling are not as useful as when these are collected over time for a given clinical case. Therefore, it is best to sample at two or three different times in order to facilitate data interpretation.

SAMPLING

To obtain optimal results and facilitate interpretation, it is very important to follow proper procedures for blood sampling. Usually, blood samples are obtained from the jugular or the brachial (wing)

vein. Cardiac puncture may be the method of choice when larger volumes of blood are required. When a single individual is studied, only one sample is collected. When a flock is investigated, it is best to bleed a representative sample of about 10 birds per poultry house. Sampling should normally be random, unless there is interest in targeting a specific sub-group, such as birds showing clinical signs.

Two cubic centimeters (cm³) of blood are usually enough. The blood has to be mixed with EDTA (ethylene diamine tetra-acetic acid) in a proportion of one cm³ of blood and 0.1 cm³ of anticoagulant.

The next step is to make a thin smear of blood. A glass slide is needed to obtain a good smear which should be stained with Wright or Giemsa dye. The smear is then covered with a coverslip glass. This will ensure that the smear lasts for a long time. However, it is best to examine the smear within the first two hours, avoiding heat, because cells will suffer damage and their morphology will change.

HEMOGRAM

An hemogram includes the following tests:

1. Hematocrit - Packed cell volume (PCV)
2. Plasma protein concentration
3. Hemoglobin concentration
4. Erythrocyte count
5. Total leukocyte count
6. Thrombocyte count
7. Differential leukocyte count
8. Leukocyte morphology

Hematocrit - Packed cell volume (PCV)

The hematocrit (PCV) is the way of measuring the proportion of blood composed of red blood cells. It is the measurement of the percentage of erythrocytes in a blood sample. A normal avian hematocrit/PCV ranges from 35 to 55%, with the percentage varying depending on the species of bird. This is an important measure to detect anemia. For example, values below 27% have been seen with infectious anemia. It is very useful to show dehydration or the presence of leukocytosis (excessive amount of leukocytes) occurring with inflammation associated with septicemia.

The hematocrit is normally obtained from automated hematology analyzers. It can also be ascertained by calculating the PCV. To achieve this, the blood sample is placed in a capillary tube and centrifugated at 10,000 rpm during 3 minutes to obtain the volume occupied by the packed cells and the one occupied by the plasma.

Plasma protein concentration

This test is important to detect nutritional deficiencies, chronic diseases, gut disorders or dehydration.

To obtain the plasma protein concentration, a Goldberg refractometer is needed.

After centrifugating the sample, a drop of plasma is placed on the glass slide of the refractometer. It is possible to directly read the plasma protein concentration from the refractometer's scale. A value between 3.0-6.0 g/dl is considered within reference values.

Hypoproteinemia may indicate a severe chronic disease, a gut disease or a nutritional deficiency. When the concentration is over 70 g/dl, dehydration is present.

Hemoglobin concentration

The hemoglobin concentration can be obtained by using a Spencer hemoglobinometer. Hemolysis of the blood is needed to liberate the hemoglobin contained in the erythrocytes. A concentration of 11-13 g/dl is considered normal.

The hemoglobin concentration is useful to classify anemia. Depending on the content of hemoglobin in erythrocytes, an anemia can be classified as normochromic or hypochromic. An assessment of erythrocyte morphology can also allow one to classify an anemia as normocytic, microcytic and macrocytic.

The most common situation is a microcytic hypochromic anemia. It is present in most chronic and severe diseases in which birds loose or cannot synthesize hemoglobin.

Erythrocyte count

The erythrocyte count is important to detect anemia. It is a complement to the PCV assessment. It

is obtained with a Neubauer chamber cell counting, a Hayer diluent and a Thoma pipette. Birds have 2-3 million erythrocytes per microliter (μl).

Total leukocyte count

Counting leukocytes is very important to detect leukopenia or leukocytosis.

The normal amount of leukocytes in birds varies depending on the bird species. Poultry has around 20,000-30,000 leukocytes/ μl . The Neubauer chamber is also used to count leukocytes.

Leukocytosis is observed with inflammatory processes. Because of this, a heterophilia (increase in heterophils) is usually present as well. During stressful situations, it is common to find a mild increase in the leukocyte count. By contrast, leukopenia may occur in cases of severe chronic diseases.

Thrombocyte count

Thrombocytes in birds are small cells with a round nucleus, very condensed chromatin, and a tiny rim of cytoplasm. They play an important role in the coagulation process. Thrombocytes in chickens have been shown to phagocytose bacteria, but are less phagocytic than heterophils. Therefore, when an inflammatory or septicemic process is present, the amount of thrombocytes increases. Under stressful situations, a mild rise in the number of these cells can also be observed.

Differential leukocyte count

This is the most important part of the hemogram because leukocytes are key cells of the immune system. They include: heterophils, lymphocytes, eosinophils, monocytes and basophils.

Heterophilia

This is characteristic of inflammatory and septicemic processes. Indeed, heterophils are the predominant leukocytes in the acute inflammatory response in poultry. They are highly phagocytic and are capable of a wide range of antimicrobial activities.

Lymphocytosis & lymphopenia

These conditions are usually present with viral diseases.

Lymphocytes provide humoral and cellular immunity. Therefore, with an acute viral disease, it is common to first find lymphocytosis followed, during the chronic stage of the disease, by a lymphopenia.

Eosinophilia

Eosinophils are mediators of the inflammatory response. An eosinophilia is often a relative change that is an increase in the proportion but not necessarily in the absolute number of eosinophils present in the blood. Eosinophilia occurs in cases of toxic diseases and in some birds affected by parasites, such as in cases of alimentary tract parasitism including giardiasis, ascaridiasis, and cestodiasis.

Monocytosis

This is detected in chronic processes with tissue destruction, like septicemic and inflammatory conditions.

Basophilia

Basophils are uncommon in avian peripheral blood. Basophilia is observed with avian respiratory infections, toxic diseases, stressful situations, and resolving tissue damage.

Leukocytes & erythrocytes morphology

Leukocytes and erythrocyte morphology can change depending on several factors. For example,

in cases of anemia, erythrocytes can be seen as small well stained red cells or as pink unstained ones. The former indicates microcytic normochromic anemia and the latter, a hypochromic anemia. Microcytosis and hypochromia are found in Fe⁺⁺, Cu, Co and pyridoxine deficiencies.

During toxic processes, leukocytes and thrombocytes can show cytoplasm basophilia, karyolysis (complete dissolution of the chromatin of a dying cell), karyorrhexis (fragmentation of the nucleus of a dying cell whereby its chromatin is distributed irregularly throughout the cytoplasm) and vacuolization.

REFERENCES

- Campbell, W. *Avian Hematology and Cytology*. Iowa U.S.A. University Press Ames. 1992
- Charles NL. *Manual de Hematologia aviar*. Departamento de Produccion Animal: Aves. Division de Educacion Continua. FMVZ UNAM. 2003.
- Maxwell MH. The fine structure of chicken blood cells with particular reference to basophils after severe heat stress. *Comparative Hematology International*, 1992,2:190-200.
- Ritchie, BW et al. *Avian Medicine, principles and application*. Lake Worth, Fl. W Publishing Inc. 1997.
- Roskopf WJ. Hematologic and Blood Chemistry values for common pet avian species. *Veterinary small animal clinician*, 1982,77:1233-1239.

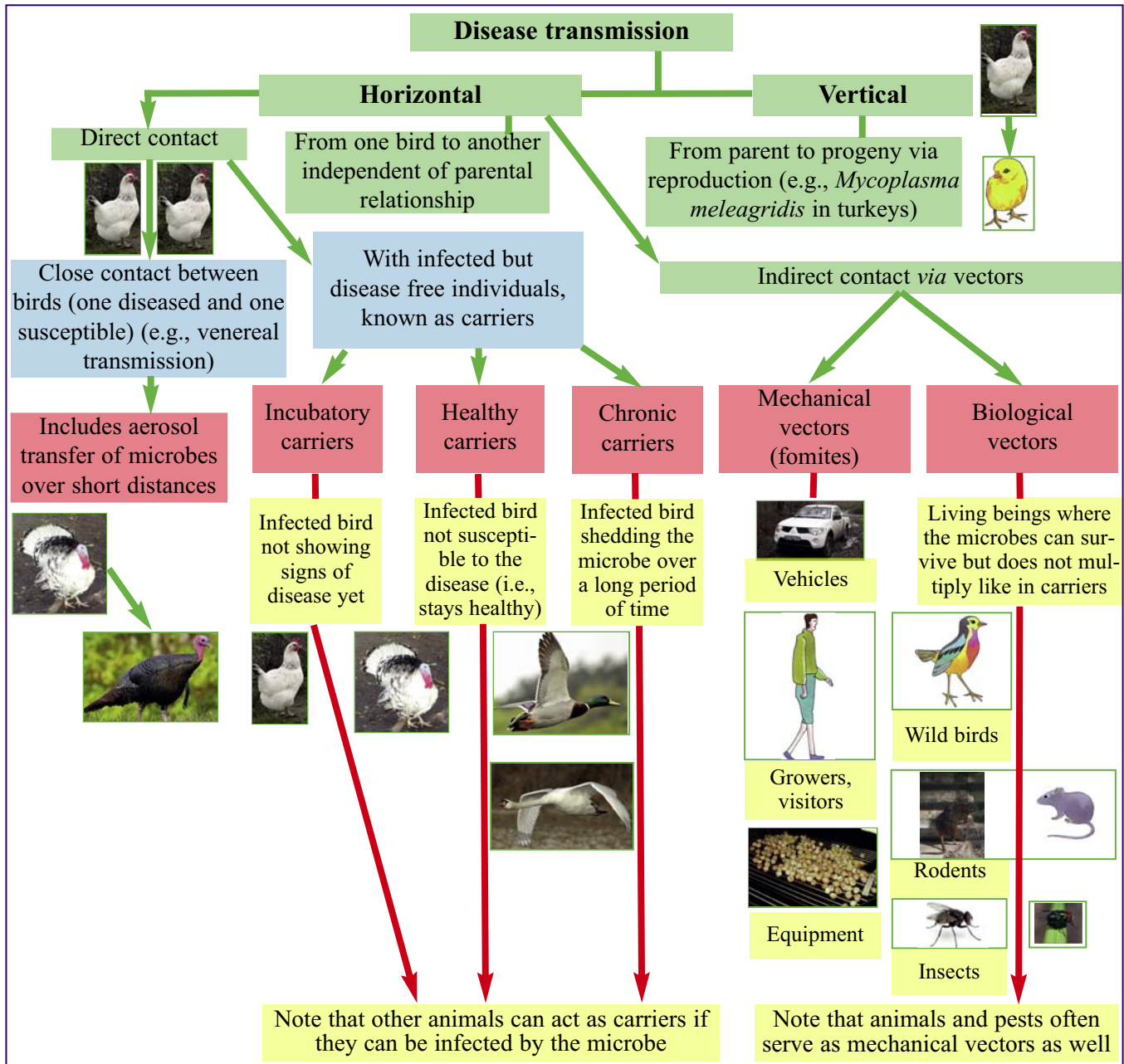


Fig.13.1: Disease transmission.

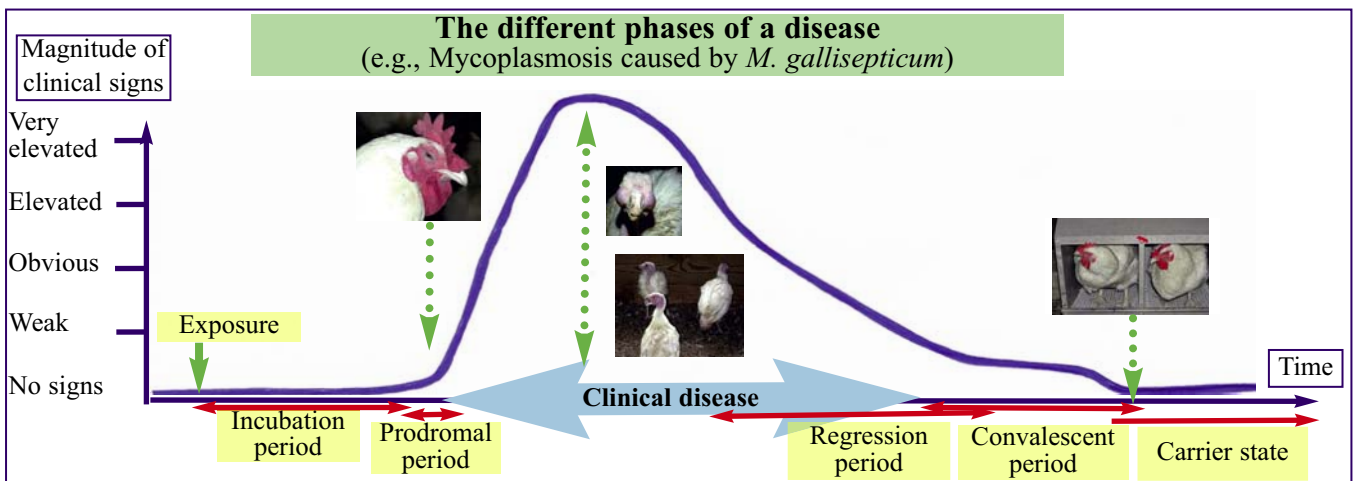


Fig.13.2: The different phases of a disease (adapted from Le Glossaire d'Epidémiologie Animale, 1999).

13. EPIDEMIOLOGIC CONCEPTS & ANALYSIS OF FIELD STUDIES IN POULTRY

INTRODUCTION

A good understanding of possible interactions between pathogenic agents, the environment and management, and their impact on flock productivity is a prerequisite to developing effective disease control strategies. Epidemiological investigations for the identification and quantification of risk factors related to a disease or health condition often requires relatively sophisticated biostatistical procedures for data analysis. Many times, however, simple study designs and analyses can provide precious information. Nonetheless, existing statistical techniques cannot accommodate for faulty experimental design, insufficient observations or poor data quality.

The aim of this chapter is to present epidemiologic concepts and the necessary conditions for obtaining valid and meaningful data. Information is presented on observational studies and, more specifically, field trials. Also included is pertinent information on data analysis that may be of value to field veterinarians.

EPIDEMIOLOGIC CONCEPTS

Disease transmission

Infectious agents, or microbes, need to go from one susceptible bird to another in order to survive. For this to occur in a flock, a sufficient number of the disease

causing microbes must be able to gain access to susceptible birds. This is called the chain of infection.

Susceptible birds are those that have no immune protection against the microbes or whose defense mechanisms are compromised or overwhelmed at the time of infection.

To infect the birds, the microbes must have adequate contact with them. Adequacy is dependent on the type of microorganism. For example, an agent causing respiratory problems must get by all of the bird's defense mechanisms to reach the site of infection (for example: airsacs for aspergillosis). To enter the bird, the microbes must first be transmitted. This can occur via direct (bird-to-bird) contact, indirect contact (*via* contaminated equipment, people, the environment, *etc.*) or by vectors (flies, darkling beetles, *etc.*). Finally, to persist in a region, microbes need a «home base». This is the reservoir. It could be rodents, other birds or animals, or any organic material acting as life support for these microbes. We can divide reservoirs in 4 categories: living animals, dead animals, animal by-products (e.g., animal protein [blood, plasma, viscera], meat and bone meal), and the environment (e.g., soil, equipment, and buildings).

Microbes can be transmitted in two broad directions: vertically and horizontally. Vertical transmission occurs when the pathogen is passed on from parent to progeny through reproduction (e.g., mycoplasmosis due to *Mycoplasma meleagridis*). All other forms of transmission are said to be horizontal because they go from one individual to the next independently of parental relationship. This includes transmission via direct and indirect contact.

Direct contact occurs when one bird touches another or when both birds are in so close proximity that the infected bird can transmit the microbe, for example, via droplets after coughing. In commercial poultry, this is the usual form of transmission within a poultry house for a respiratory disease. Between poultry houses and between farms, indirect transmission is more likely. This type of transmission involves a third party. It can be an object (e.g., equipment, drinkers, truck, *etc.*), it can be people going from farm to farm, contaminating their boots or clothes; it can also be vectors such as insects, rodents, or dogs.

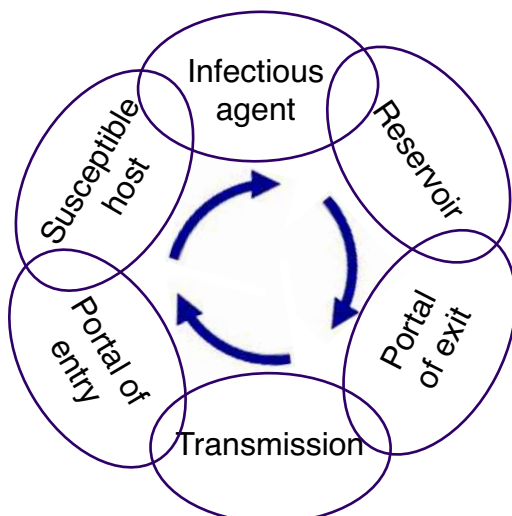


Fig.13.3: Schematic representation of the chain of infection. The arrows indicate the sequence of events required to achieve infection.

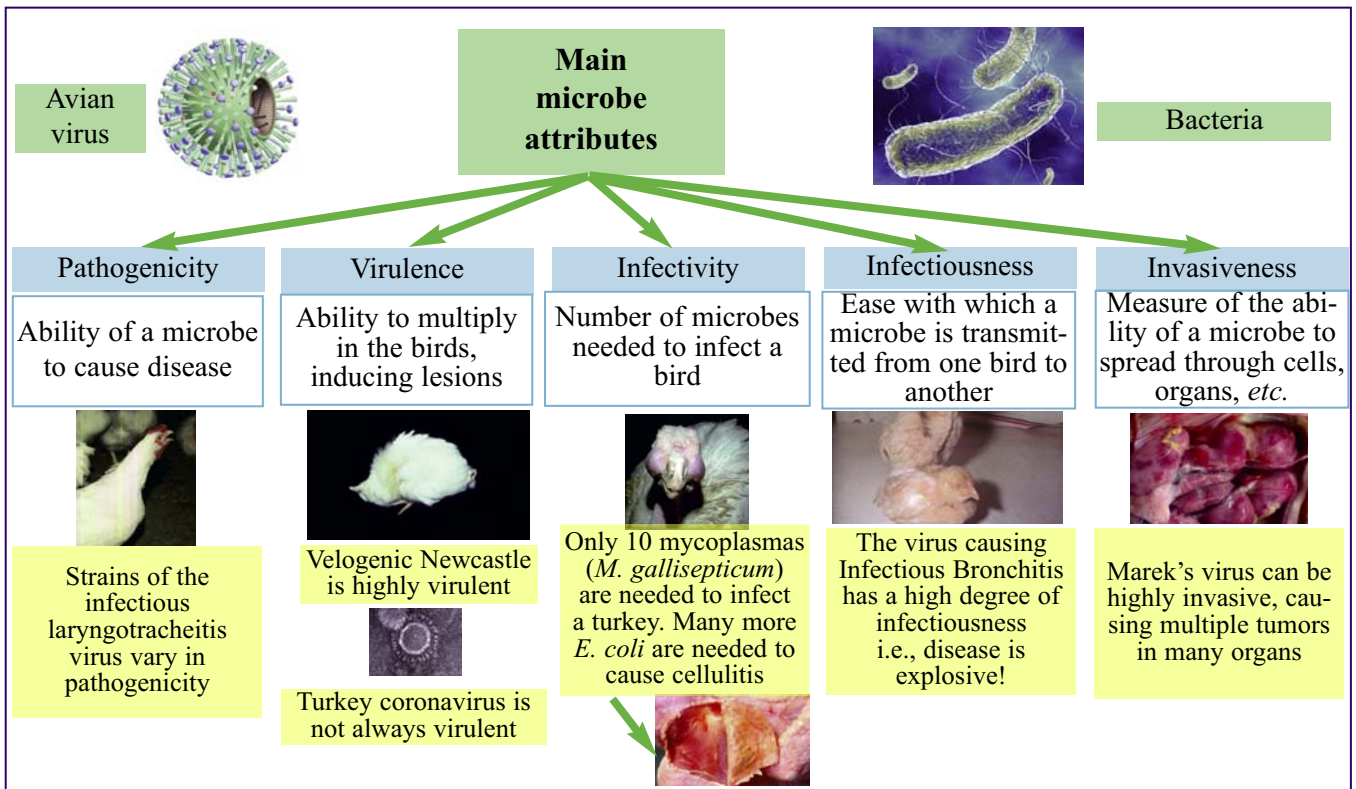


Fig.13.4: Characteristics of pathogens.

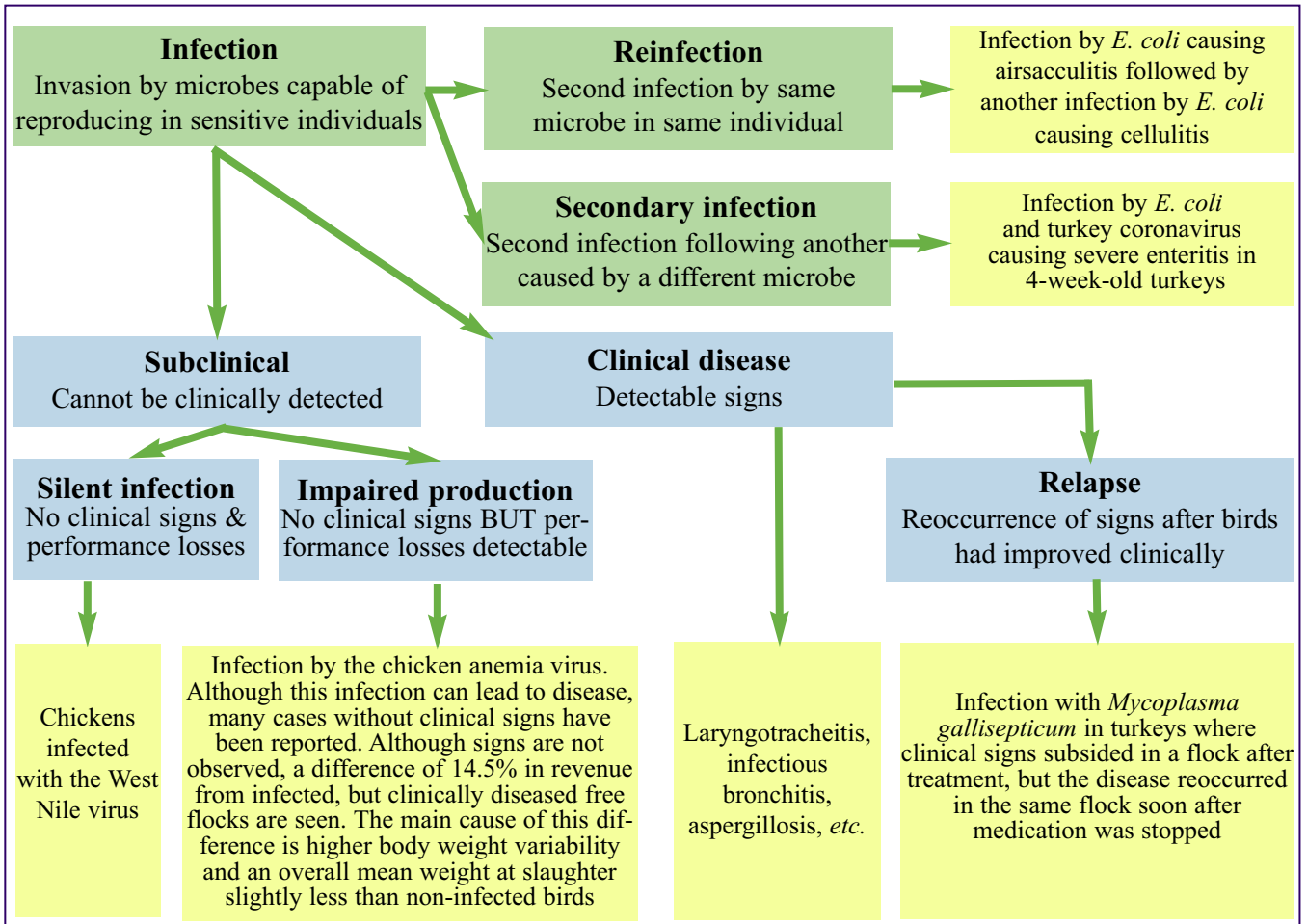


Fig.13.5: Different aspects of infection.

Birds are susceptible, or at risk of becoming sick, when their defense mechanisms are not adequate to control the microorganisms. This happens when the birds' immune system is compromised. Many factors may be responsible for this. The main culprits are deficient environments (stressful to the birds), poor nutrition, and the presence of so many pathogens, that the system is overwhelmed. For example, a dusty environment with high ammonia levels in the barn will affect the birds' ability to prevent the entry of *Aspergillus* all the way to the lungs and airsacs. These birds will be much more likely to develop aspergillosis.

Infection Pressure

In general, the more microbes a bird is exposed to, the more likely the infection is to occur (i.e., the more likely the chain of infection will be intact).

This is called the «infection pressure» or «pressure of infection».

Some microbes will also team-up to cause disease. They will, indeed, «merge their chains of infection» and, together, will be much more dangerous to the birds. For example, in turkeys, it was shown that a coronavirus and a specific type of *Escherichia coli* can «join forces» to produce a more severe disease than they could separately.

The infection pressure concept also applies to regions. The more farms in an area, presumably the more microbes and the more birds at risk. Also, a high regional density offers more opportunities for disease transmission. Using a geographical information system, it was shown that the higher the regional density of farms, the lower the average productivity performance.

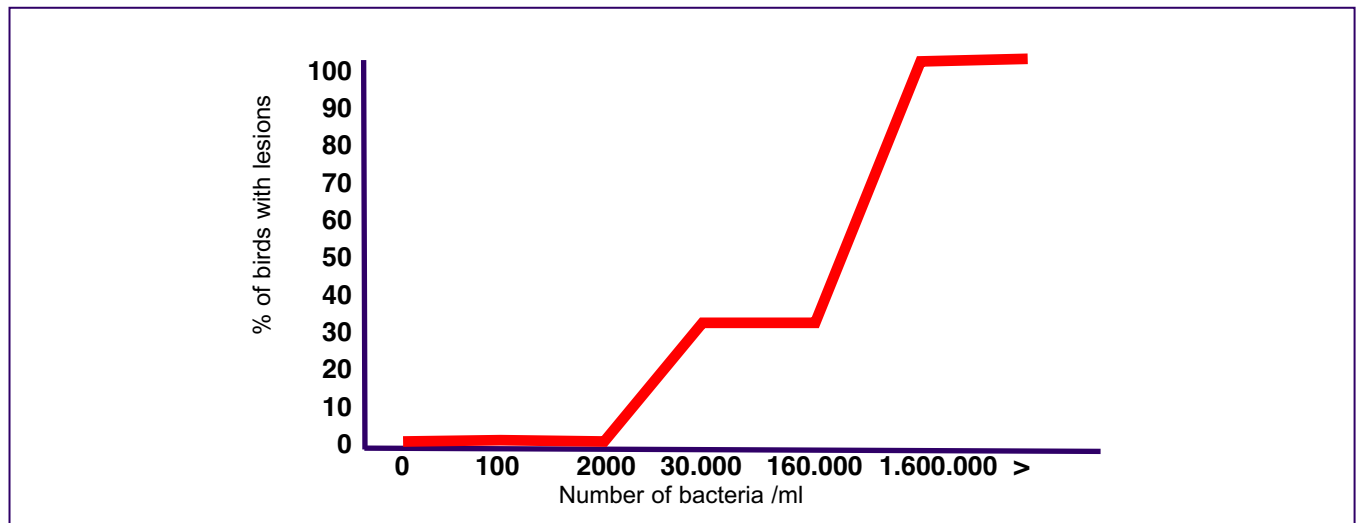


Fig.13.6: Example of «infection pressure». Relationship between the incidence of birds with cellulitis lesions and the number of bacteria applied on the skin of birds with standardized cuts or scratches on their abdomen. In this study conducted in France by Etteradossi et al (1989), it was demonstrated that a certain number of *Escherichia coli* (the main bacteria associated with cellulitis) was necessary to reproduce the disease; and the greater the number of bacteria, the higher the incidence of the disease in a group of birds.

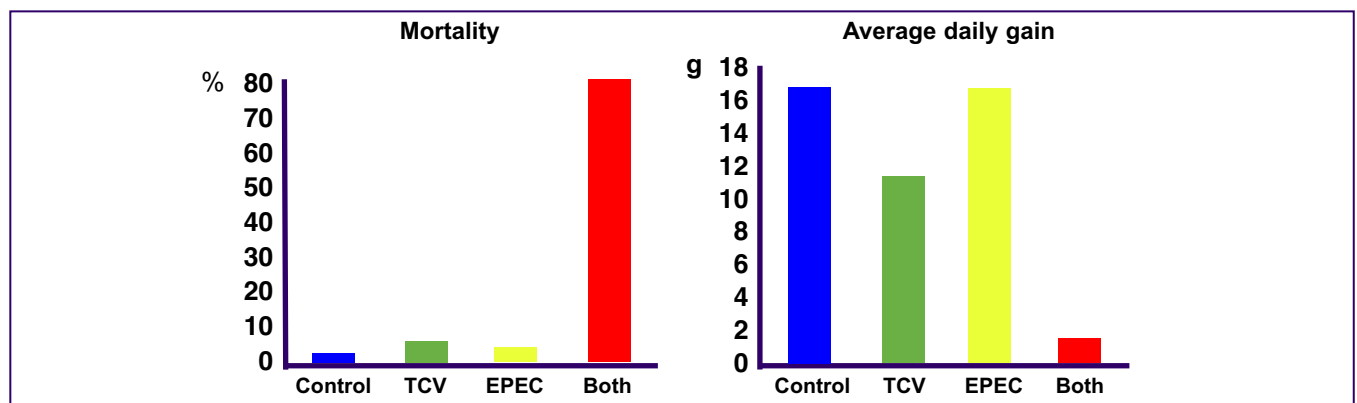


Fig.13.7: Impact of turkey coronavirus (TCV) and an *Escherichia coli* (EPEC), separately or together, on 3 week-old bird mortality and average daily gain (Guy et al, 2000).

Disease spread

When many birds are susceptible to a disease on a farm, and these birds are exposed to a pathogenic agent, we normally get an outbreak. The outbreak will last as long as enough birds are susceptible; in other words, as long as the flock on the farm does not develop immunity against the microbe.

Some birds or lines of birds can be resistant to a specific disease. For example, there are leucosis-resistant strains of chickens that are not affected by the virus causing the disease. In this example, the birds have an innate ability to avoid getting sick by this specific agent. But in most cases, birds need to gain immunity against a microbe in order to stay healthy when challenged. When an infectious disease affects a flock, you normally notice a progression of the clinical signs in individual birds.

You will also notice that the number of affected birds will increase to a certain point and then decrease. The speed at which the disease spreads and expresses itself varies with the disease. It can show up and disappear quickly, or it can move slowly within the flock and cause problems for the duration of the production life of this flock (for example: enteric problems caused by turkey coronavirus).

When many flocks on different farms are affected, we say that we have an epidemic. An epidemic occurs when the occurrence of a disease is affecting a number of flocks in clear excess of what would

be expected for a specific region and period of time. For example, in the Niagara Peninsula (Ontario) in 1994, 38 outbreaks (flocks) of infectious laryngotracheitis (ILT) were recorded over a four month period in broiler chickens. Although outbreaks of ILT have been reported in this area in the past, only up to three ILT flocks are expected per month in this region during the spring, which corresponds to the peak season for this disease. In this example, ILT is said to be sporadic under normal conditions in this area. If a few cases would always be around, we would say that the disease is endemic in this region (see Fig.13.8).

The way a disease spreads over time and space will vary depending on the microbe's characteristics, its original distribution in the area before the epidemic occurs (i.e., where it is at the moment that it exits its reservoir), and its mode of transmission (horizontal, vertical, direct, indirect).

Clustering occurs when many cases are found in a limited area over time. This often happens with transmissible diseases that have a common source of infection (i.e., when all cases are coming from the same origin, like an infected flock. We then talk of having a disease cluster.

The agent-animal-environment relationship

To understand a disease, one must know the relationship between the cause of the disease, the birds and their environment.

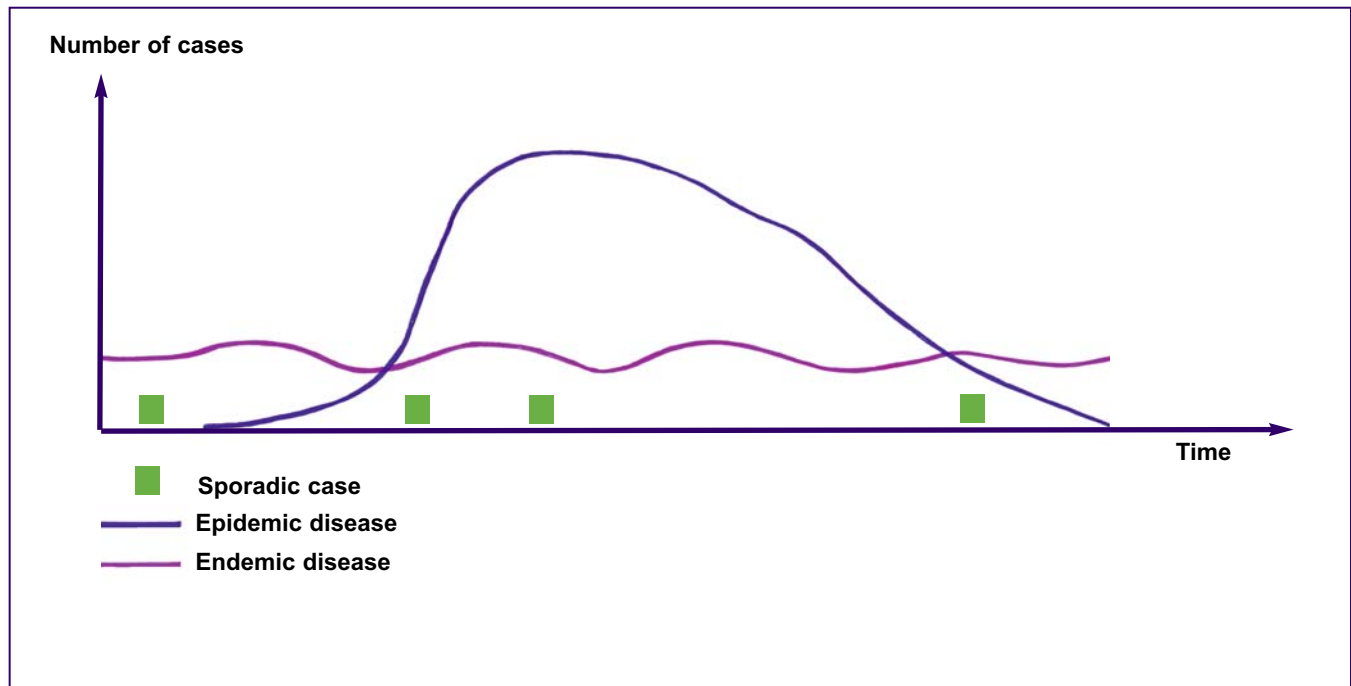


Fig.13.8: Graphic representation of the difference between epidemic, endemic and sporadic diseases (adapted from Dictionary of Veterinary Epidemiology, 1999).

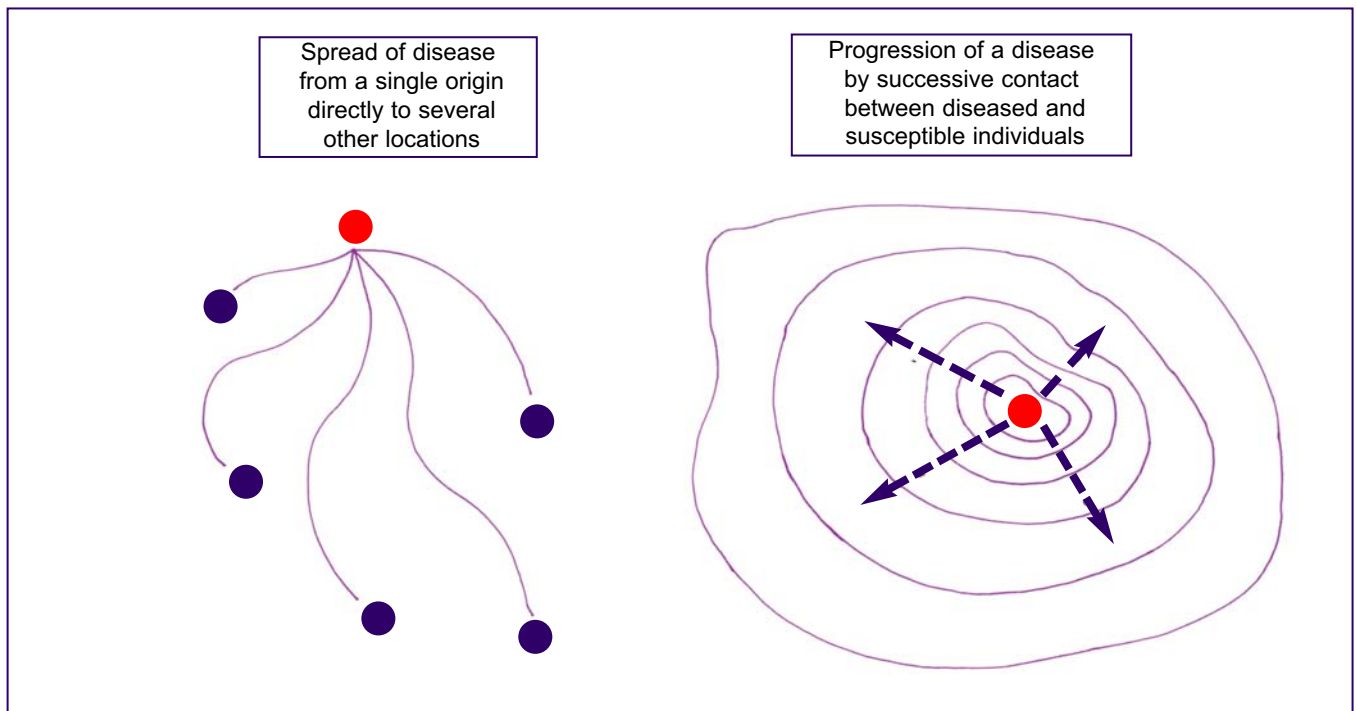


Fig.13.9: Schematic representation of two different patterns of spread of disease (adapted from Dictionary of Veterinary Epidemiology, 1999).

Causality

Historically, causality was defined by Koch's postulates, a series of four postulates proposed by a German bacteriologist, Robert Koch, (1843-1910) regarding the ideal conditions required to demonstrate causality for an infectious agent (the agent must be present in every case of the disease by isolation in pure culture; the agent must not be found in cases of other conditions; once isolated, the disease must be reproducible experimentally with the agent; and this agent must be recovered from the experimental disease). But this series of postulates is not adequate for diseases with multifactorial etiology, not to mention non-infectious diseases as well! In epidemiology, Alfred Evans (1976) proposed postulates that better reflect reality:

- 1) Prevalence of the disease should be significantly higher in those exposed to the putative cause than in those not so exposed.
- 2) Exposure to the putative cause should be present more commonly in those with the disease than in controls without the disease when all risk factors are held constant.
- 3) Incidence of the disease should be significantly higher in those exposed to the putative cause than in those not so exposed as shown in prospective

studies.

- 4) Temporally, the disease should follow exposure to the putative agent with a distribution of incubation periods on a bell shaped curve.
- 5) A spectrum of host responses should follow exposure to the putative agent along a logical biologic gradient from mild to severe.
- 6) A measurable host response following exposure to the putative cause should regularly appear in those lacking this before exposure (i.e., antibody, cancer cells) or should increase in magnitude if present before exposure; this pattern should not occur in persons so exposed.
- 7) Experimental reproduction of the disease should occur in higher incidence in animals or man appropriately exposed to the putative cause than in those not so exposed; this exposure may be deliberate in volunteers, experimentally induced in the laboratory, or demonstrated in a controlled regulation of natural exposure.
- 8) Elimination or modification of the putative cause or of the vector carrying it should decrease the incidence of the disease (control of polluted water or smoke or removal of the specific agent).
- 9) Prevention or modification of the host's

response on exposure to the putative cause should decrease or eliminate the disease (immunization, drug to lower cholesterol, specific lymphocyte transfer factor in cancer).

10) The whole thing should make biologic and epidemiologic sense.

Risks

In the context of poultry diseases, a risk is the probability that a disease will occur in a flock at a given moment or over a given time period. A risk can be modified by factors internal or external to the flock and its immediate environment. Factors associated with an increase in the probability of occurrence of disease are known as risk factors. For example, poor barn ventilation may lead to high levels of ammonia that will trigger respiratory problems. Excessive temperature variation over a few hours can also stress birds and lead to clinical problems such as diarrhea in turkeys. If the factor is associated with a reduction in the incidence of disease, it may be called protective factor. For example, a slow growth rate will be associated with a lower incidence of tibial dyschondroplasia in broiler chickens.

The epidemiological measure of the strength of the relationship between a risk factor and disease is the relative risk. It is expressed as the ratio of the incidence of disease in flocks exposed to the risk, to the incidence in flocks not so exposed. The relative risk ranges from 0 to infinity. If the relative risk is less than 1, the factor is protective (reduced incidence); but if it exceeds 1, the factor is a risk (increased incidence). If the ratio is equal to 1, there is no association between the disease and the factor. For example, in a study on cellulitis in chickens, the relative risk for duration of downtime was 0.9. This means that the longer the downtime, the lower the incidence of cellulitis. By contrast, using straw as litter (*versus* wood shavings) was associated with an increased incidence with a relative risk of 2.8.

ASSESSING TREATMENTS, RISK FACTORS, AND DISEASES: KEY STEPS AND CONSIDERATIONS FOR CLINICAL AND FIELD TRIALS

Objectives, outcomes (diseases) and treatments (or risk factors)

The objectives of a study must be clearly stated. Disease measurement, unit(s) of interest (i.e., birds, flocks) and risk factors should also be selected

wisely. For example, in a study on cellulitis in chickens, a statistical association was found between the rate of condemnation at slaughter for valgus varus deformity and cellulitis. Although the association was very significant ($p = 0.0004$) and could make sense biologically (affected birds may spend more time on the floor, leading to prolonged contact with contaminated litter), controlling for this risk factor would likely not be economically doable. Other factors, such as litter characteristics (also found associated with cellulitis), are more likely to contribute to the development of cost-effective control strategies.

For field trials, it is recommended to have at least two outcomes: one to determine productivity and one concerned with morbidity, mortality, or welfare. It is possible for a treatment to lower morbidity or mortality rates but to have little impact on growth rate or feed efficiency. Field work on *Poult Enteritis Mortality Syndrome* (PEMS) is a good example. Intervention strategies for this disease that have resulted in higher survival rates have had a more negligible impact on growth performances.

The study should be designed so that the collection of data is based on biologically significant and, most importantly in field studies, on economically significant parameters. It is recommended to select, as much as possible, parameters that not only measure biological production, but that also may be used as economic indicators, which are valuable for on-farm decision making. For example, parameters such as feed efficiency, average daily gain, percent mortality, carcass grades, condemnation rates, average weight at slaughter, and weight variance are meaningful parameters for studying grow-out performances, whereas morbidity indices may not be accurate indicators of financial performance.

Study design for observational studies and clinical trials

Only after the objective(s), the outcome(s) and the risk factors (or treatments for a classic clinical trial) have been defined, can the study design be determined.

A detailed presentation of the most frequent study designs is beyond the scope of this chapter. Objectives and designs commonly encountered in the veterinary literature are presented in Tabl.13.1 along with frequently used statistical procedures. The analysis depends upon the type (continuous or categorical) of outcomes (i.e., disease, growth

performance) and risk factors. For example, an investigation of risk factors associated with growth performance, such as average daily gain, could be designed as a case-control or a cohort study. If the outcome were categorical (i.e., 5 levels of average daily gain), chi-square or logistic regression would be valid options, whereas if the outcome were continuous, analysis of variance (ANOVA), analysis of covariance, or multiple regression would be considered, assuming normality of distribution. For any of the above, the use of confidence intervals rather than p-values is recommended, being more descriptive of the magnitude of effect and of the precision of measurement. For any projects, it is also highly recommended to seek assistance from a statistician with a practical knowledge of epidemiology.

Validity of data

The validity of an epidemiologic study is defined as the ability of an examination or study to measure what it is supposed to measure, without being influenced by other sources of errors. Valid data avoids biases introduced by the observer or recorder.

The issue of data validity is not new. However, it is more critical than ever. The advent of computerization, record keeping systems, and electronic sensors has made it easy, if not trendy, to gather information. Integration also facilitates the gathering and processing of data covering the full spectrum of poultry production. This information is mainly utilized for day-to-day managerial decisions. It may also be used for field trials. However, before doing so, one should first appreciate the validity of such data.

Data quality is assessed in terms of reliability and validity. Reliability is a measure of the closeness of agreement between values obtained from repeated measurements collected or performed on samples or individuals under specific conditions, usually by the same person or laboratory. It is essentially a measure of data consistency. Validity is the extent to which the measurement reflects the truth. Reliability and validity of data recording depend largely on the people and/or on the test(s) used to obtain the information. It is also dependent on the type of data being collected. For all practical purposes, data can be divided into two groups: soft and hard.

Hard data are information requiring little interpretation (as part of the recording process), such as

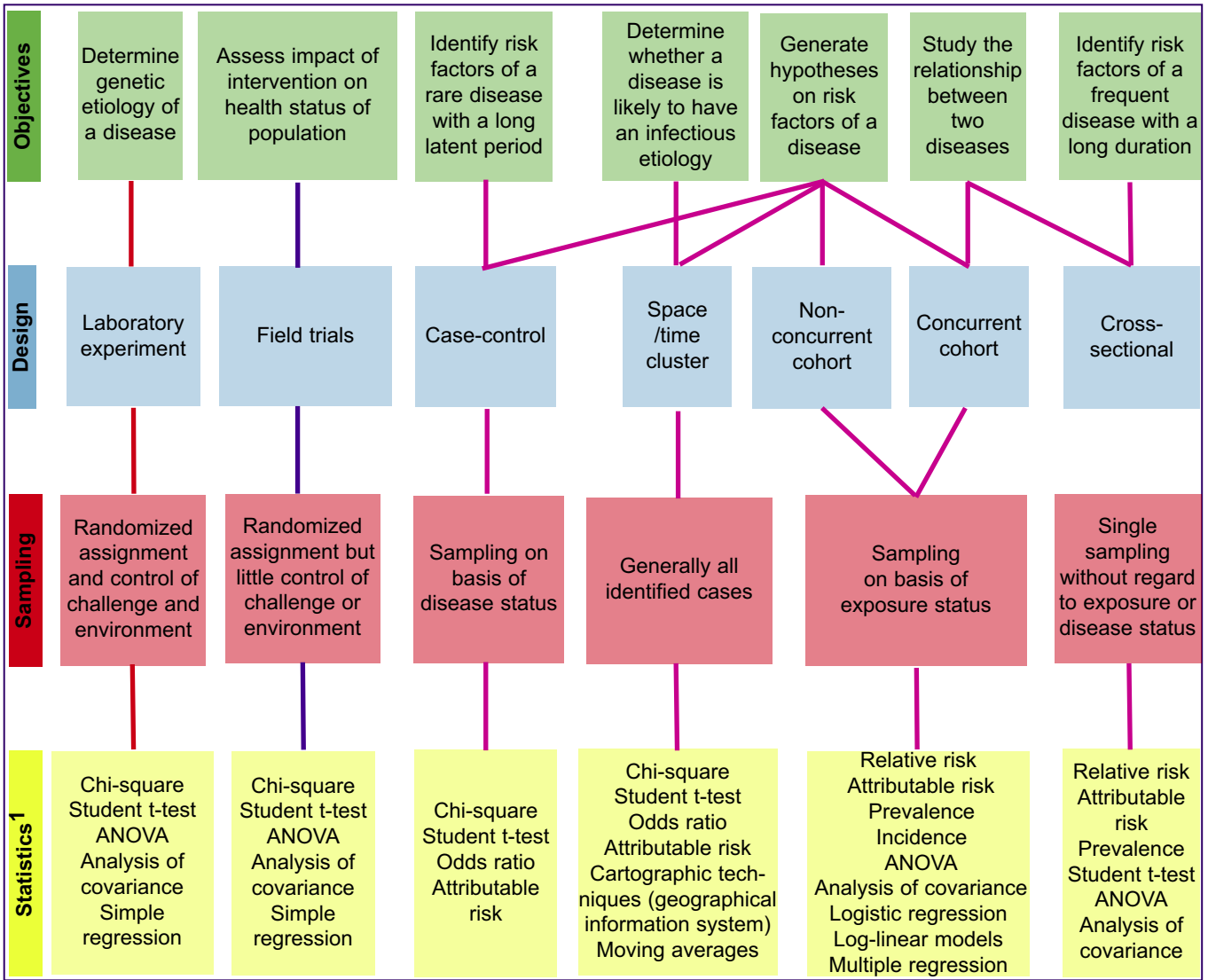
daily mortality, number of birds culled, breed, sex, and breeder flock identification. It may be biased (systematic deviation from the truth) when it is not consistently recorded. Soft data represent subjective information based on one's interpretation of an event (causes of death, clinical signs, culling category, category of condemnation, etc.). We rely mostly on hard data to assess productivity. However, we often have to base our judgment on soft data when investigating problems. For example, studies using producer diagnoses of causes of mortality or culling are likely to be subjected to biases that limit or prevent interpretation. Therefore, steps to validate producer or serviceman observations should be included in on-farm studies.

Precision of data - sample size

Precision is characterized as the quality of being sharply defined through exact details. A more statistically oriented definition would be: measure of dispersion or variance associated with the use of a random sample to obtain the estimated population statistics. The larger the variance, the lower the precision. Therefore, precision is inversely proportional to the variance of the measure. This is determined by sample size and sampling methodology. Note that there is no relationship between the precision of the estimate (measure) and the population size as long as the sample size is negligible compared to the population. For example, measurements obtained from a sample of 30 birds will have the same precision whether the sampled flock comprises 10,000, 100,000, or 1,000,000 birds.

One should not confuse precision and accuracy. If one seeks to estimate the average weight of a group of turkeys whose real value is 16.5 kg, the estimation can be varied (see Fig.13.10).

If adequate estimates are to be achieved at the population level, the sample units selected (birds, flocks) for the study must be representative of the target population and non-biased in terms of which unit is selected. The most important factors influencing the necessary sample size are the questions being asked (such as minimum prevalence of disease requiring detection or the accuracy of the estimated prevalence), and the degree of uncertainty (or level of confidence) that one is willing to accept. Indeed, for cost purposes (and other practicality issues), it is essential to limit sample size and yet have sufficient numbers so that measurement variation can be estimated and the sampling error can be calculated. Calculation of the degree of confidence in the error rate should be



Tabl.13.1: Common objectives, study designs and biostatistical procedures.

¹Non-parametric statistics such as Kruskal Wallis one way ANOVA, Friedman two way ANOVA, Spearman's rank correlation, Sign Test and Rank Sum Test are also used when the distribution for the studied variables is not normal.

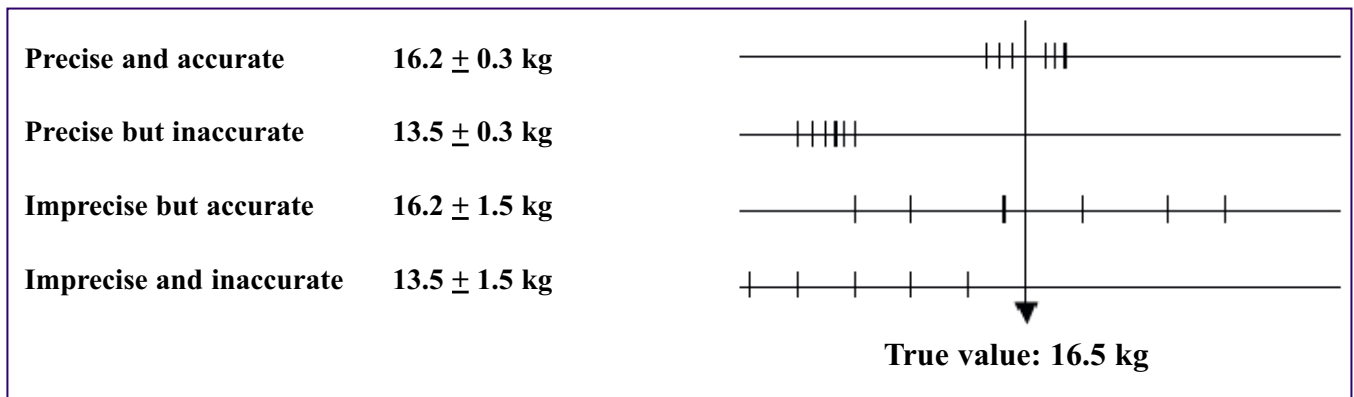


Fig.13.10: Graphic representation of the degree of precision and accuracy of an estimate (adapted from Dictionary of Veterinary Epidemiology, 1999).

done if any meaningful interpretation of the data is to be made.

If one wishes to estimate a prevalence or an average, then it is crucial that the selection of birds to be sampled be unbiased (random sampling). An unbiased sample is one in which every individual in the group has an equal chance of being selected. Of course, in practice, we all know that this rarely occurs like under laboratory conditions. However, every effort should be made in the field to minimize bias. However, if one wants only to establish whether a condition or an agent is present in a flock, birds most likely to be affected should be sampled. Here, veterinarians can utilize their knowledge of the expected epidemiology and clinical observations to select the appropriate birds for testing. For example, in order to identify PEMS agents, it is best to focus on turkeys between 2 and 5 weeks of age showing early signs of enteritis.

If one wants to estimate the morbidity of affected birds in a flock, practical targets could be a sample size allowing disease detection at a 10% prevalence (with a 95% level of confidence) (i.e., a sample size allowing to detect the presence of a disease affecting 10% of a population). For this purpose, a sample size of 30 is recommended (see Tabl.13.2). If prevalence is expected to be high, like for a case of infectious bronchitis, 5 to 10 samples are sufficient. Note that, in commercial poultry productions where flocks normally exceed 3000 birds, sample size is not dependent on population size. Calculations for sample size can be found in any biostatistics textbook. Epi-Info, a free software package from the CDC (Center for Disease Control and Prevention) of Atlanta includes a sample size calculator (www.cdc.gov/epiinfo/).

Sample size is critical because if it is too low and the study has already been completed, there is no way to correct the situation. Tabl 13.3 offers such data where a three fold difference in mortality means little when each treatment includes only 10 birds. Although one would think that there is a difference between 10% (1/10) and 30% (3/10) mortality, because of the small sample size, the observed difference is not statistically significant (p -value = 0.58).

Statistical methods

Descriptive statistics are very useful to help assess the relative value or importance of variables and their distribution. The most popular descriptive statistics are the mean, the median, the mode, the range, the standard deviation, and the 95% confidence interval for the mean. It is best to use several of them together in order to provide an adequate description. For example, in Tabl.13.3, the ratio bursa weight/body weight seems lower for treatment 2 compared to treatment 1. However, additional descriptors such as the standard deviation and the 95% confidence interval provide enough information about data variability to show that the two means are not likely to be statistically different. This is confirmed using parametric and non-parametric tests (these tests are preferred when the sample size is small or the distribution of the variable has an unusual shape).

Another example of descriptive statistics often presented is the percentage or proportion of individuals or flocks positive to a given condition. Tabl.13.4 reveals that a high percentage of turkey flocks in two regions of North Carolina were affected with PEMS in 1996. However, if a similar percentage were positive for coronavirus in the West, this was not the case in the East. But it appears that there are more cases of PEMS and Corona positive flocks in the West than in the East. Some have even concluded that this was proof that Coronavirus was the cause of PEMS. However, in order to learn more about the possible association between PEMS and Coronavirus in the field, a contingency table was created (Tabl.13.5). The analysis, using Fisher's Exact test, shows the lack of a strong association between PEMS and Coronavirus for this study. This does not mean that Coronavirus cannot be associated with PEMS (in fact, PEMS has been reproduced under controlled conditions using Coronavirus and *E. coli*; it is now also accepted that the severity of the disease will likely increase when Coronavirus is present); but it does indicate that Coronavirus is not essential to PEMS (i.e., it is not THE cause of PEMS). Here, the region acted as a confounder (i.e., a factor that leads to a distortion in the observed effect between another variable (e.g., coronavirus) and an outcome (e.g., PEMS).

Population size	Prevalence of disease			
	1%	5%	10%	50%
30	29	23	19	5
60	57	38	23	5
100	95	45	25	5
300	189	54	28	5
500	225	56	28	5
1,000	258	58	29	5
5,000	289	58	29	5
100,000	298	58	29	5

Tabl.13.2: Sample size for 95% confidence in disease detection (adapted from Martin et al, 1987).

	Mortality ¹	Bursa/body weight ratio		
		Mean ²	Standard Deviation	95% Confidence Interval
Treatment 1	1/10	0.162	0.03	0.141 – 0.183
Treatment 2	3/10	0.132	0.04	0.102 – 0.162

¹Fisher's exact test (two-sided test): p = 0.58
²Parametric analysis: Student-t test: p = 0.16; Non-parametric analysis: Wilcoxon rank sum test: p = 0.11

Tabl.13.3: Example of lack of statistical significance because of small sample size and wide variability of data. Hypothetical data with 10 birds per treatment.

Flock status	Western North Carolina		Eastern North Carolina	
	Number of flocks	Percentage	Number of flocks	Percentage
PEMS positive¹	39	78	17	59
PEMS negative	11	22	12	41
Total	50	100	29	100
Corona positive ¹	35	70	5	17
Corona negative	15	30	24	83

¹ PEMS status based on the definition included in the text
 Corona status based on direct immunofluorescence test

Tabl.13.4: Distribution of Poult Enteritis Mortality Syndrome (PEMS) and Coronavirus positive (Corona) flocks in Western and Eastern North Carolina in 1996. Data are shown considering the PEMS and Corona flock status separately.

	Western North Carolina		Eastern North Carolina	
	PEMS Pos ¹	PEMS Neg	PEMS Pos ¹	PEMS Neg
Corona positive ¹	28 (80%)	7 (20%)	4 (80%)	1 (20%)
Corona negative	11 (73%)	4 (27%)	13 (54%)	11 (46%)
Fisher's exact test ²	p-value = 0.71		p-value = 0.37	

¹ PEMS status based on the definition included in the text
 Corona status based on direct immunofluorescence test
² p-values from Fisher exact tests performed on the two 2x2 tables

Tabl.13.5: Distribution of Poult Enteritis Mortality Syndrome (PEMS) flock status according to their Coronavirus status by North Carolina region in 1996.

Of course, this interpretation assumes that the data collected was valid (i.e., no misclassification of flocks).

CONCLUSION

Practicing veterinarians will increasingly require an understanding of epidemiologic and statistical methods in order for them to meaningfully provide a preventive medicine service to poultry producers. Proper health monitoring and analysis are of paramount importance. Indeed, flock health management involves an accurate assessment of a flock's health status as well as the identification of related bird, environmental and management factors. An increased understanding of the types of studies suited to investigating and solving problems will encourage practitioners to use these epidemiological tools as part of their work. To learn more about veterinary epidemiology, books by Thrusfield (2007) and Smith (2006) are good reference texts.

REFERENCES

Elbers ARW & Schukken YH . Critical features of veterinary field trials. *Vet Rec*,1995,136:187-192.
Elfadil AA et al. A prospective study of cellulitis in

broiler chickens in Southern Ontario. *Avian Diseases*, 1996,40:677-689.

Etteradossi NP et al. Necrotic dermatitis in broiler chickens: pathological epidemiological findings and experimental reproduction. *Proceedings of the World Veterinary Poultry Association Meeting*, 1989, Brighton, UK, 87-88.

Evans, A.S. Causation and disease: the Henle-Koch postulates revisited. *Yale J. Biol. Med.* 1976,49: 175-195.

Guy JS et al. High mortality and growth depression experimentally produced in young turkeys by dual infection with enteropathogenic *Escherichia coli* and turkey coronavirus. *Avian Dis*, 2000,44:105-113.

Martin SW et al. *Veterinary epidemiology. Principles and methods*. Iowa State University Press, Ames, 1987.

Smith RD. *Veterinary Clinical epidemiology*. 3rd edition. CRC presse; Boca Raton, 2006, Florida; 259 pages.

Thrusfield M. *Veterinary epidemiology*. 3rd edition, Blackwell Science, Oxford, England 2005; 600 pages.

Toma B, Vaillancourt J-P, et al. *Dictionary of veterinary epidemiology*. Iowa State University Press, Ames 1999.

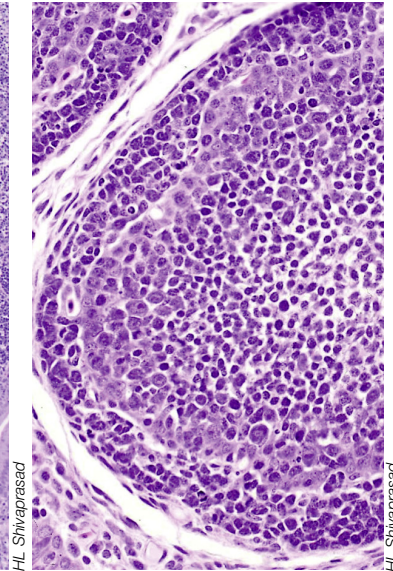
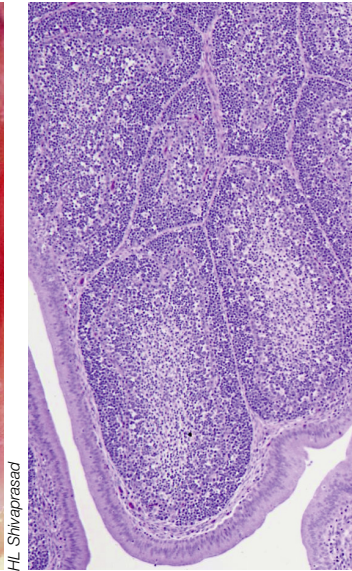
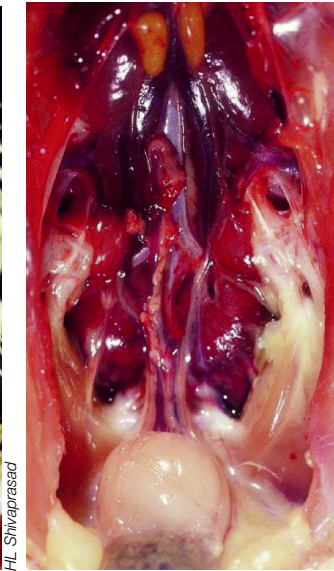
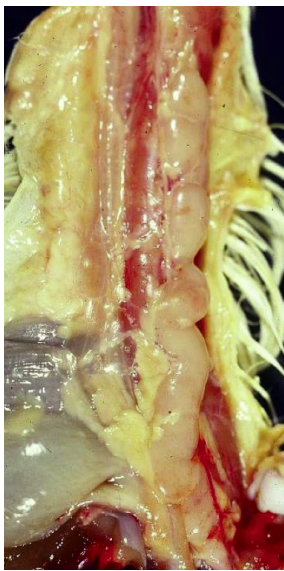

Fig.14.1: Thymus (Chicken). It is an elongated, multi-lobular structure (7 lobes in the chicken) located along the length of both sides of trachea with some lobes extending into the anterior thoracic cavity.

Fig.14.2, 14.3 & 14.4: Bursa of Fabricius (Chicken). In the chicken, the bursa is detectable around the 5th day of incubation and becomes functional the 10th to 12th day. Like the thymus, the bursal lymphocytes originate from the yolk sack and migrate via the blood vessels. The structure of the bursa is composed of villus-like folds or *plicae*, which are directed towards a central lumen. The epithelium of the intestine covers the bursal lumen, but lacks mucous cells. Each bursa may have 8,000 to 12,000 lymphoid follicles, embedded in connective tissue and surrounded by lymphatic vessels. Like the thymus, bursal follicles are organized into a cortex and a medulla.

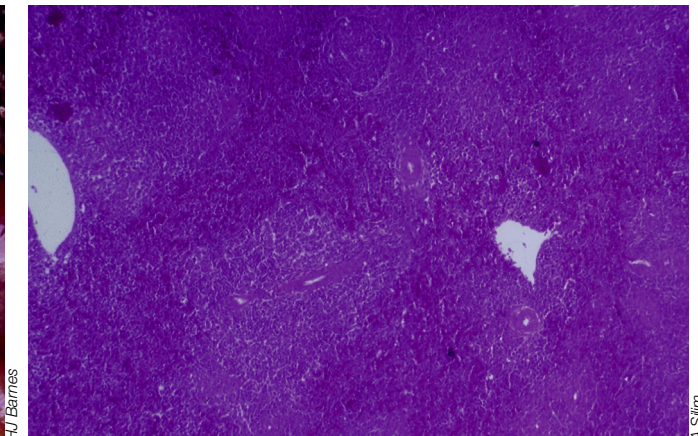
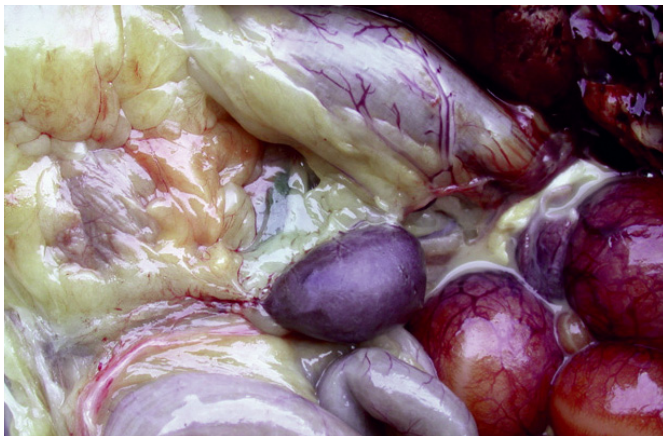

Fig.14.5 & 14.6: Normal spleen (Turkey). Like in the mammals, the encapsulated spleen is divided into white and red pulps. The white pulp, which is the real lymphoid part of the spleen, is composed of more densely packed lymphoid cells surrounding the vascular tree of the spleen.

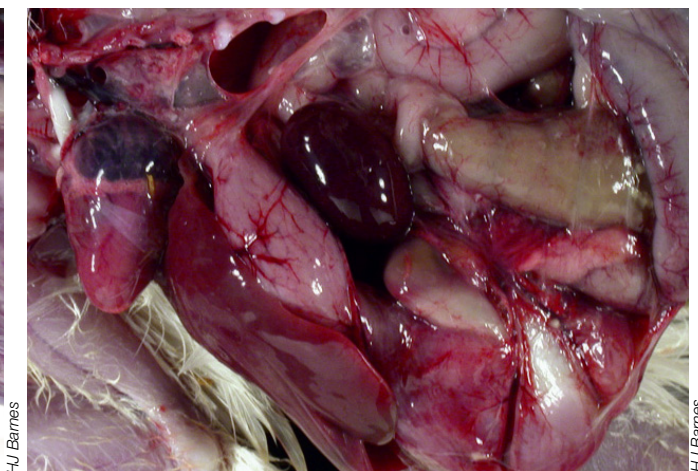
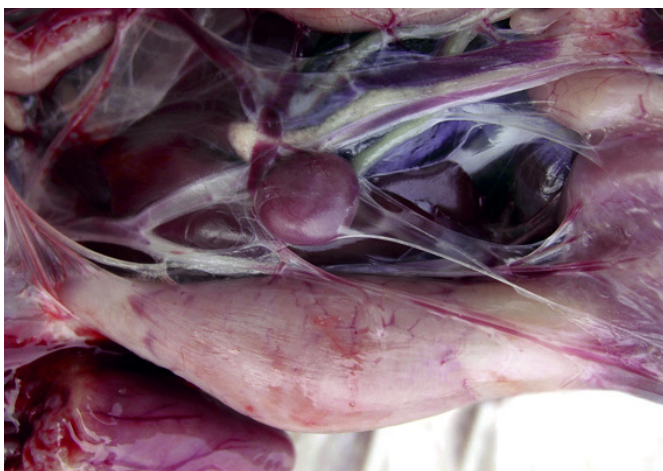

Fig.14.7: Atrophy of the spleen (Chicken). Emaciation of the spleen following stress.

Fig.14.8: Splenomegaly (Turkey 4 weeks old). Colibacillosis.

14. AVIAN IMMUNOLOGY

INTRODUCTION

Over the years, the chicken immune system has provided an invaluable model for studying basic immunology and has made seminal contributions to fundamental principles of immunology, from the accidental invention of attenuated vaccine against fowl cholera by Louis Pasteur to the first description of graft-*versus*-host reaction: first definitive association of specific major histocompatibility complex (MHC) haplotype with resistance and susceptibility to pathogens, discovery of the dichotomy of lymphocytes into B cells (BC) and T cells (TC), discovery of interferon, first successful vaccines against a cancer and first vaccines administered *in ovo*.

Although the chicken is an excellent biomedical model, the main objective for poultry immunologist is the improvement of health, production and welfare of commercial birds. Because commercial flocks are raised under intensive rearing conditions, they are vulnerable to disease outbreaks and to rapid spread of infectious agents. Therefore, intensive vaccination is critical in maintaining bird health and this is likely to become even more important because of reduced use of antibiotics as a growth promoter. In addition, the poultry industry is afflicted with immunosuppressive agents such as chicken infectious anemia virus, infectious bursal disease virus, Marek's disease virus, avian reovirus, and mycotoxins. Following immunosuppression, most birds respond poorly to vaccines thus putting the flock health in jeopardy. The overall organization and mechanisms of immunity in birds are quite similar to those in mammals, although there are some differences in anatomic, cellular, genetic and molecular features.

ORGANS OF THE IMMUNE SYSTEM

The organs of the immune system are classified into primary or central lymphoid organs and secondary or peripheral lymphoid organs. In birds, the primary lymphoid organs are the thymus and the bursa of Fabricius where T and B cell precursors differentiate respectively and undergo maturation. Mature lymphocytes leave the primary organs and populate the secondary lymphoid organs, the principal site of antigen-induced immune response. The peripheral lymphoid organs and tissues, characterized by aggregates of lymphocytes and antigen-presenting cells (APC), are scattered throughout the body. They

include the spleen, the bone marrow and the Harderian gland. In addition, birds have clusters of lymphoid tissues that are named according to their location such as head-associated lymphoid tissues (HALT), bronchus-associated lymphoid tissues (BALT), and gut-associated lymphoid tissues (GALT). Examples of GALT include esophageal tonsils, Meckel's diverticulum, Peyer's patches, cecal tonsils as well as annular bands ducks.

Thymus

The thymus is the site of production of TC, responsible for the cell-mediated immunity. It is an elongated, multi-lobular structure (7-8 lobes in the chicken) located along the length of both sides of trachea with some lobes extending into the anterior thoracic cavity. Each lobe is encapsulated in connective tissue and divided into multiple lobules. Each lobule consists of a cortex where lymphocytes are densely packed and a medulla with fewer lymphocytes. TC that arrive in the cortex are double negative (CD4-CD8-) and as they migrate towards the cortex/medulla junction they become double positive. Once they enter the medulla, they become either CD4 or CD8 cells. At hatch, the thymus is predominantly filled with TC with antigen receptors called TCR, although some dendritic cells and macrophages are also present. Some BC migrate also to the thymus after hatch.

Bursa of Fabricius

In birds, BC differentiate and develop in the bursa of Fabricius (BF), hence the term "B" lymphocytes, whereas in mammals the cells develop in the bone marrow.

Each follicle is filled with BC, and as in the thymus, the lymphocytes are arranged into peripheral cortex and central medulla. Besides B cells, the BF contains some T cells, plasma cells, macrophages, dendritic cells and reticulocytes. The presence of TC and plasma cells show that although the bursa is a primary lymphoid organ, it can also trap antigen and undertake some limited antibody production, probably as a self-protection measure. The bursa produces a few hormones and the most important of these is bursin, a tripeptide that has a regulatory role in BC development and differentiation. In the chicken, the bursa is well developed at birth and

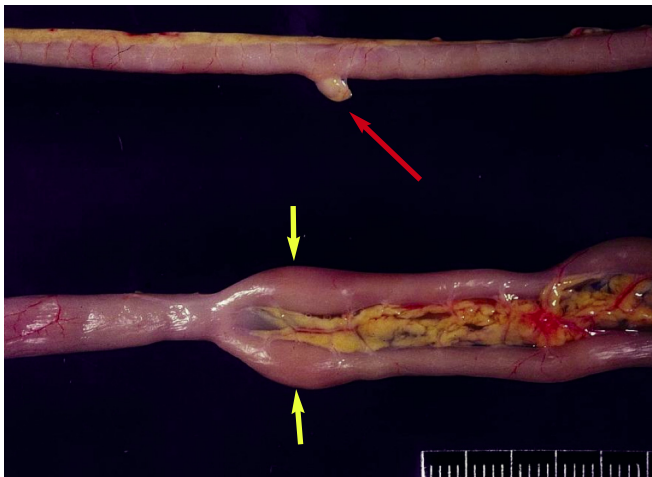


Fig.14.9: Cecal tonsil (yellow arrows) and Meckel's diverticulum (red arrow).

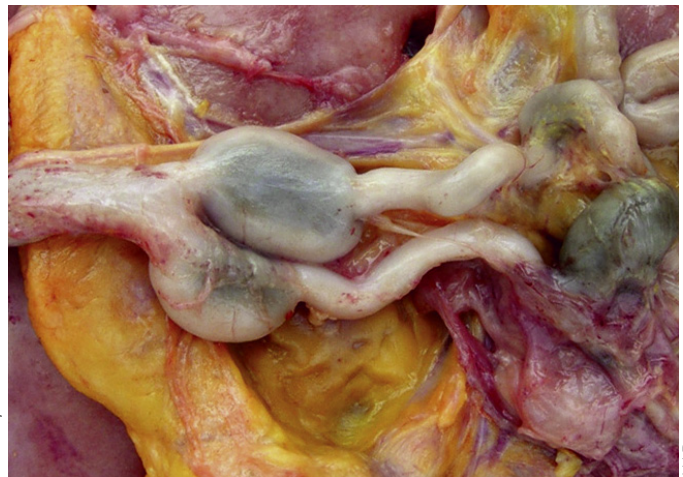

Fig.14.10: Lymphoid leucosis. Lymphomas of cecal tonsils (Chicken broiler breeder 67 weeks old).

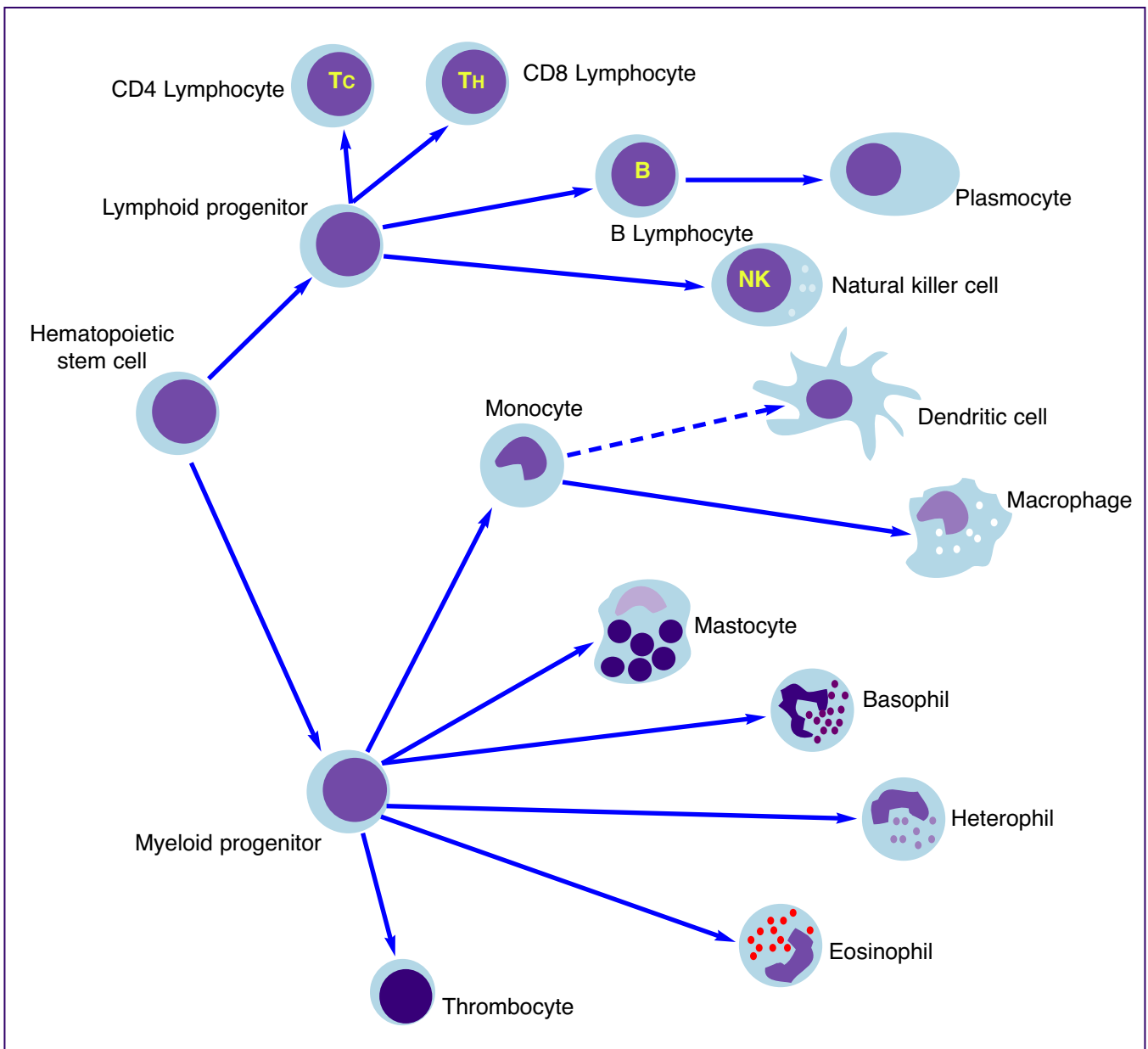


Fig.14.11: Origin and diversification of cells involved in the immune response.

reaches its maximum size around 4-12 weeks of age after which involution begins and is complete at about sexual maturation. Bursectomy before the 17th day of incubation induces complete absence of immunoglobulins (agammaglobulinemia), with the absence of germinal centers and plasma cells in peripheral lymphoid organs.

Spleen

The chicken spleen is the first secondary lymphoid organ to be colonized by lymphoid cells at around 10 to 11 days of embryonic development. Like in the mammals, the encapsulated spleen is divided into white and red pulps. The white pulp, which is the real lymphoid part of the spleen, is composed of more densely packed lymphoid cells surrounding the vascular tree of the spleen. It is located around a central arteriole, forming the periarterial lymphoid sheath. The sheath has a T zone and a B zone. TC are located around the arteriole, while BC are outside this area, organized in primary and secondary lymphoid follicles. Following stimulation by antigens, the follicles develop BC-rich germinal centers, with some APC such as dendritic cells and macrophages. The increase in the number of germinal centers after vaccination or infection, requires cooperation between the BC, the TC and the APC. The red pulp consists of sinusoid venules surrounded by macrophages, thrombocytes, lymphocytes and many plasma cells. The spleen is also a reservoir of thrombocytes, erythrocytes and granulocytes.

The spleen responds mainly to antigens in blood. Antigens that enter the spleen are taken up by dendritic cells in the marginal zone and in the sinusoids of the red pulp. The cells then carry the trapped antigens to the primary lymphoid follicles where germinal centers develop quickly to accommodate the influx of the antigens. Within a few days, antibody-producing plasma cells are formed and start to migrate into the marginal zone and the red pulp of the spleen. It is also in these regions that antibody production is first detected.

CELLS OF THE IMMUNE SYSTEM

Macrophages

Macrophages are one of the most important cells in the innate or nonspecific immune response. They are derived from blood monocytes which, based upon size alone, are indistinguishable from lymphocytes. They mature once they migrate into tissues

and they differ in morphology and function depending upon what tissue they are in and their level of activation. Macrophages are able to recognize targets via different cell-surface receptors including Toll-like receptors. Macrophages also remove aged red blood cells by recognition of subtle changes on cell surface glycoproteins and they destroy aged granulocytes at inflammation sites. Macrophages can be identified by their ability to adhere to substrates such as glass, by their phagocytic and chemical properties and by cell-surface receptors. Nonspecific esterase staining can be used to identify avian macrophages, but since the staining levels vary and it is unknown whether it is a characteristic of all avian macrophages, this method is not as certain as it is for mammals. Unlike mammals, birds do not have resident peritoneal macrophages that can be harvested for experimental purpose, nor do birds have a true peritoneum. All avian macrophages must thus be chemically elicited and as such, they become activated before harvest. Macrophages respond sequentially to inflammation by inducing the expression of adhesion molecules, chemotaxis to the site of chemoattractant and, once there, initiation of a respiratory burst. The respiratory burst is the result of the production of chemicals that are responsible for killing bacteria and other microorganisms. Macrophages can also kill tumor cells by secreting tumor necrosis factor (TNF-alpha), by antibody-dependent cell-mediated cytotoxicity (ADCC) and by direct contact.

Natural Killer (NK) cells

NK cell activity has been primarily researched in the chicken and the Japanese quail. NK cells are extremely important as the initial immune response to tumors and, to a lesser extent, to virus-infected cells. They are identified as large granular lymphocytes with an absence of T-cell receptor (TCR) or B-cell receptor (BCR) and they do not adhere to glass like the macrophage. The chicken NK cells are CD8+CD3-. NK cells possess receptors for interleukin 2 (IL-2) and interferon (IFN) especially IFN-gamma, which is responsible for its activation and greatly increasing NK cell activity. Unlike in humans where NK activity is detected in fetuses and remains high after birth, NK activity is low in chicks and increases only with age. The degree of NK cell-mediated cytotoxicity and the timing of developmental acquisition of NK cell activity are influenced by genetic lineage. Some disease-resistant lines acquire NK activity at a younger age than do susceptible lines. NK cell activity is also enhanced by antibodies in ADCC process.

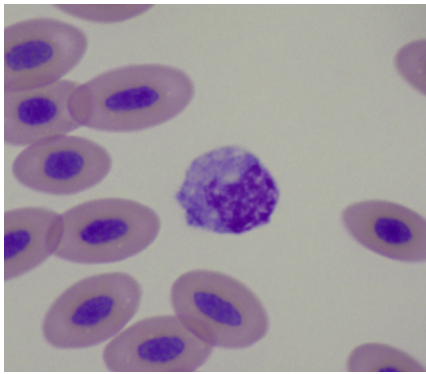


Fig.14.12: Monocyte (chicken). Monocytes are indistinguishable from lymphocytes (cf. figure 14.13).

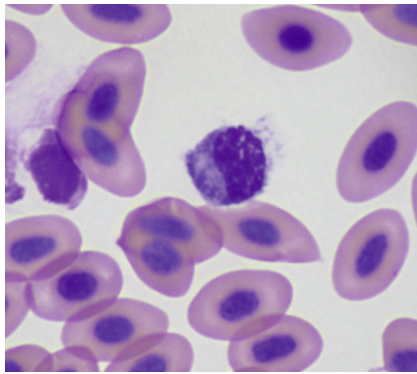


Fig.14.13: Lymphocyte (chicken).

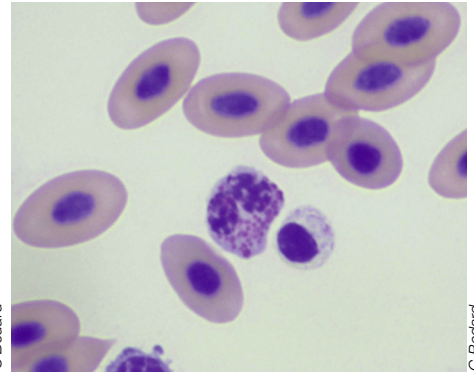


Fig.14.14: Heterophil (chicken).

Heterophils

The chicken heterophil is considered to be the equivalent of the mammalian neutrophil and has a similar principal role, that is, protection by phagocytizing invading microorganisms such as bacteria. Heterophils have multilobulated nucleus with two or three lobes, and lysosomal granules that stain brightly with eosin. Mature heterophils lack peroxidase and alkaline phosphatase that are present in neutrophils, but they contain beta-glucuronidase and acid phosphatase. In general, birds have a caseous rather than purulent response to most antigens, which may be partially explained by the reported lack of lysozymes and other enzymes in heterophils. Like neutrophils, heterophils are the predominant (approximately 50%) phagocytic cells involved in acute inflammatory reactions. Granular leukocytes can also play some part in anticoccidial immunity. Both primary and secondary coccidial infections elicit an increase in heterophil numbers, although the response is much more rapid in secondary infections in which it coincides with a rapid infiltration of heterophils and lymphocytes into the lamina propria. Avian heterophils have also been shown to participate in ADCC.

Stress has been found to have a detrimental effect on heterophil and lymphocyte numbers, and the blood heterophil to lymphocyte ratio can be used as a measure of stress in chickens. The hormone melatonin, secreted from the pineal gland, appears to influence nonspecific immune responsiveness, particularly heterophil activities. Production of melatonin is inhibited by light and permitted by darkness. While it is clear that melatonin interacts with the immune system, the details of those interactions are unclear. Immunological effect of melatonin is thought to result from melatonin acting on high affinity receptors expressed on immune cells and enhan-

cement of cytokine production. It is thus logical to assume that raising chickens on continuous light regimen can cause stress and a reduced immune response to vaccines and pathogens because of insufficient melatonin due to lack darkness.

Eosinophils

Mature eosinophils have granules containing peroxidase, aryl sulfatase, and some acid phosphatase, suggesting that the granules are lysosomal in nature. Eosinophilia in mammals is associated with helminthic infections, allergic reactions, and some neoplastic diseases. This is not clearly so in birds although prolonged eosinophilia was observed in birds affected with dermatitis of the head. Passive cutaneous anaphylaxis reactions in young chickens and acute inflammatory reactions in chicken skin are notable for the lack of involvement of eosinophils, suggesting that avian eosinophils do not respond to inflammatory stimuli in the same way as mammalian eosinophils.

Basophils, mast cells & thrombocytes

Basophils and mast cells belong to distinct cell lineages, although they have many functional similarities, and possess secretory granules for the synthesis and storage of histamine, heparin and other vasoactive substances. Basophils are very weakly phagocytic and lack significant amounts of bacteriocidal and lysosomal enzymes. Basophils may have some part in the early acute inflammatory response and the induction of immediate hypersensitivity reactions in chickens.

Mast cells are involved in the initiation of inflammation by releasing pharmacologically active mediators, which facilitate the migration of heterophils and monocytes to the site of injury. Mast cells

have been found in tumors in the chicken. They occur in nerves from normal birds and are increased in nerves affected with Marek's disease. In Rous sarcoma, basophils from the blood stream invade tumors where they release their heparin-containing granules into the tumor. This basophilic response may be a factor in resistance to Rous sarcoma in the resistant strains of chickens to the virus. In mammals, a prominent feature of intestinal helminthic infections is associated with a large increase in the numbers of intestinal mast cells. A similar increase in mast cell numbers has been described in chickens infested with the cestode *Railletina cesticillus* suggesting a similar role for mast cells in avian helminthic infections, although this does not appear to be the case for immunity to coccidia.

Avian thrombocytes are mononuclear cells that function in the same way as the mammalian platelets in causing blood coagulation. They are spherical or elliptical in shape and are smaller in size than lymphocytes. They are also capable of phagocytosis although the phagocytic mechanism appears to be independent of complement, thus differing from that of heterophils and monocytes. They also have lysosome-like cytoplasmic inclusions and acid phosphatase-containing granules, and like the mammalian thrombocytes, they participate in inflammation.

LYMPHOID CELLS AND THEIR INTERACTIONS

If all the foreign particles entering the body were completely ingested, digested and destroyed by phagocytic cells, there would be no stimulation of the specific immune response. To trigger such a reaction, a certain amount of antigen has to persist. On the other hand, if all foreign materials that enter the body were to trigger a specific immune reaction, the immune system could become exhausted in trying to react to every foreign stimulus. The processing or treatment of antigen is thus used to regulate the amount and size of antigens presented to the lymphocytes stimulated by these fragments. These cells require that the antigen be correctly processed by the APCs in order for them to specifically react and also to respond to the appropriate cytokines secreted by the APCs. Antigen fragments must be detected and identified by the TC via their TCR receptors, before they can trigger the appropriate immune response. Foreign antigens that trigger immune reactions are of two distinct types: exogenous antigens in the extracellular environment such as bacteria, and endogenous antigens that are usually synthesized by cells themselves such as viral antigens and

tumor antigens.

Processing of endogenous antigens

Endogenous antigens are antigens that originate from the cell itself. Such antigens include the viral antigen in infected cells, tumor antigens, bacterial antigens such as facultative intracellular bacteria like *Mycobacterium* spp, and some intracellular protozoan antigens. These antigens are processed in a different manner from exogenous antigens. After their synthesis or their fragmentation within the affected cell, they are bound to MHC-I molecules and transported to the cell surface. Antigenic peptides attached to these molecules trigger a cell-mediated immune response via cytotoxic T lymphocytes (CTL). Once activated by cytokines secreted by T helper-1 (TH-1) cells, the CTL destroy cells with the same antigens on their surface. For example, to control a viral infection, the CTL attach to the viral proteins expressed on the surface of infected cells in association with MHC-I molecules *via* their TCR and destroy the infected cells. The CTL do not respond to soluble antigens that are not attached to MHC-I molecules.

Processing exogenous antigen

The presentation of exogenous antigen is the function of the MHC-II molecules. These molecules can bind fragments of ingested antigens and present them to the TH-2 cells, only if they are physically linked to the MHC-II molecules. There are several steps involved in the processing of exogenous antigen. First, the antigen must be phagocytosed or pinocytosed into phagosomes. Phagosomes fuse with lysosomes containing proteases, which cleave the proteins into peptides. Following the cleavage, the endosomes containing the peptides merge with other endosomes containing MHC-II molecules that are newly synthesized by the APC such as macrophages and dendritic cells. The fused vesicles move to the surface of the cell and during this time, the peptides bind to the MHC-II molecules. Once the vesicles have reached the surface of the cell, they fuse with the cell membrane and the MHC-II-peptide complex is exposed on the surface of the cell. It is possible that an APC presents several different epitopes simultaneously, since it has thousands of MHC-II molecules. The MHC-II-antigen complexes bind to the CTR-CD4 complexes on the TH-2 causing stimulation of the latter. The activated TH-II in turn stimulates BC, which produce antibodies involved in humoral immune response.

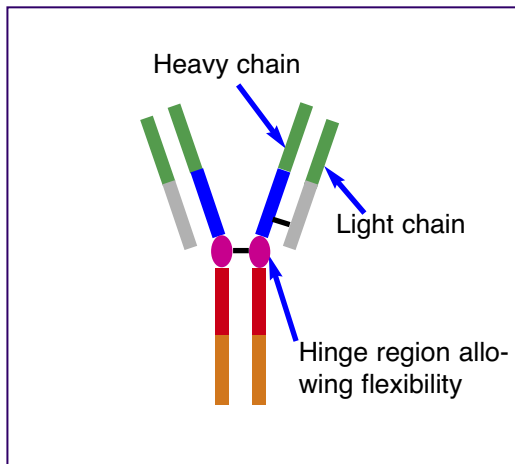


Fig.14.15: Mammalian IgG.

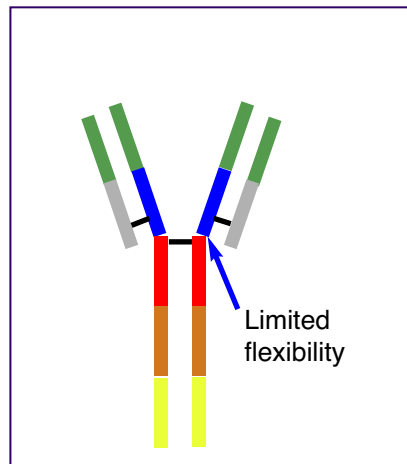


Fig.14.16: IgY molecule.

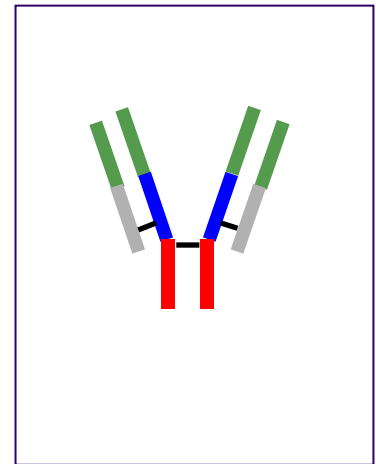


Fig.14.17: Truncated IgY(ΔFc) molecule.

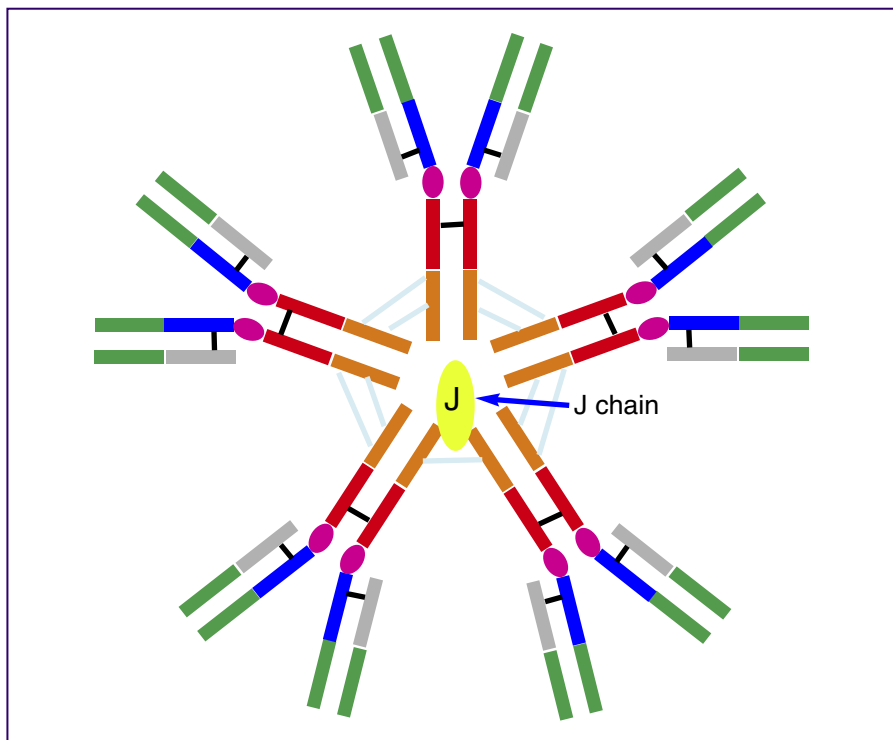


Fig.14.18: IgM molecule in pentamer form.

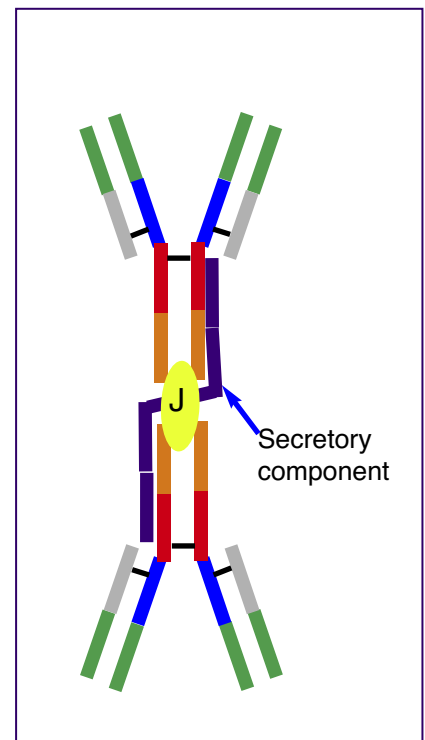


Fig.14.19: Secretory IgA (sIgA).

AVIAN IMMUNOGLOBULINS

The B-cell receptor (BCR) is a specific antigen receptor exclusively found on the surface of B cells and is an immunoglobulin. Antibodies are the soluble form of immunoglobulins produced by the B cells in response to antigens. Thus, the BCR on a particular B cell has the same binding specificity to the antigen, as are the antibodies that are produced by the same B cell. Antibodies have the ability to act in various environments such as blood, mucous fluids and other bodily secretions, which explains in part, the existence of several immunoglobulin classes such as IgG, IgA, IgM and IgE.

In fact, each immunoglobulin class has optimal activities according to the environment in which it is located, and also according to the stimulating antigen. In mammals, IgG is secreted mostly in the spleen, lymph nodes and bone marrow by B cells. This immunoglobulin class is the highest in blood concentration in both mammals and birds and plays the most important role in humoral immunity such as agglutination of bacteria, neutralization of viruses and toxins, opsonisation of antigens to facilitate their phagocytosis and complement activation. It is also the immunoglobulin with the longest half-life of 3-5 days in chickens, which can make it interfere with vaccination in the presence of maternal antibodies.

IgY

In the avian species as well as in reptiles and fishes, the IgG equivalent is known as IgY and is the immunoglobulin with the smallest molecular weight in these species. It is also most often referred to as IgG rather than IgY in chickens. As in IgG, the IgY structure is composed of two light chains and two heavy chains. The heavy chain known as epsilon consists of a variable antigen-binding region (domain) and four constant domains. However, there exists a truncated IgY isoform (ΔFc) with only two constant domains. Some species of birds such as ducks and geese, as well as some turtles and fishes, have the two isoforms, but chickens have only complete isoform while some turtles have only the truncated isoform. There are two missing domains in the Fc region of the truncated IgY, which influences the effector function of the molecule, such as complement activation and opsonisation of antigens. The small molecular weight of truncated IgY may offer some advantages to the birds compared to a full IgY. For example, because they are not capable of activating complement, they do not have the potential of participating in type III hypersensitivity reaction. The two isoforms of IgY molecules do not have the hinge region found in mammalian IgG, which makes IgY heavy chain less flexible. However, the avian IgY is able to participate in antigen precipitation and agglutination in the presence of high concentrations of salt compared to the mammalian IgG. Chickens have not so far been shown to have IgE, responsible for allergic reaction, but studies have shown that avian IgY fulfills the dual roles of IgG and IgE in mammals. It is therefore likely that IgY is an evolutionary precursor of these two immunoglobulin classes.

IgM

IgM is secreted at the same sites as IgG. When acting as BCR on a BC membrane, it is in a monomeric form, whereas when it is secreted as an antibody, it has a pentamer form, which consists of 5 subunits linked by two disulfide bonds, giving it a circular shape. A small polypeptide, called the J piece, binds the last two subunits to complete the circular structure. IgM is the major immunoglobulin produced during primary immune response and can be detected 1-2 weeks after infection or vaccination. It is also produced in the secondary immune response, but the predominant class of immunoglobulin at this phase is IgG. It is more effective than IgG in complement

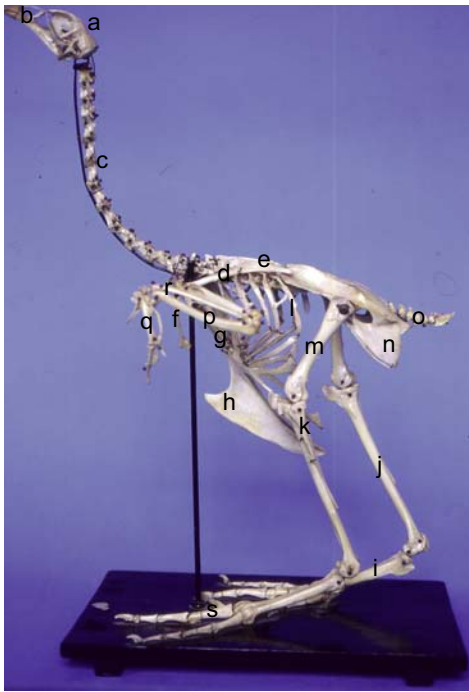
activation, bacterial agglutination and virus neutralization. Because of its large size, IgM is confined to the bloodstream and is thus less abundant in tissues, bodily secretions and even in inflammatory sites.

IgA

IgA is primarily secreted in the mucous membranes, the bile, the intestine, the oviduct and the upper respiratory tract. It is the dominant immunoglobulin in these sites and its serum concentration is normally less than that of IgM. In the serum, IgA exists in both monomeric and dimeric forms. In its dimeric form, two heavy chain subunits are joined by a J piece. Following its synthesis, the dimeric IgA passes across the epithelial cells into bodily secretions and it is at this time that the secretory piece, synthesized by epithelial cells, is incorporated to form secretory sIgA. The secretory piece also facilitates the transport of IgA into bodily secretions and protects the IgA against proteolytic enzymes such as trypsin found in secretions. The main function of the sIgA is to prevent the adhesion of microorganisms to mucous membranes. For this reason, several vaccines in poultry industry are administered by aerosol or nebulization in order to locally stimulate a high sIgA production. IgA does not participate in opsonization or complement fixation, but it can cause bacterial agglutination and virus neutralization. IgA is distinguished by the fact that it is the predominant immunoglobulin in the upper airways and digestive tract.

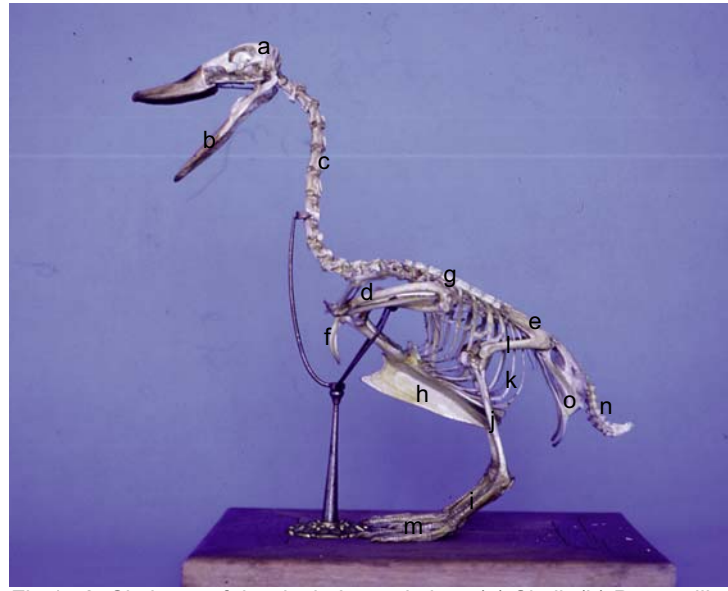REFERENCES

- Davison F et al. *Avian immunology*. Acad.Press - Elsevier ed., 2008. San Diego.Ca, 481 pp.
- Halliwel REW & Gorman NT. *Veterinary Clinical Immunology*, WB Saunders Company 1989, Philadelphia, Pa.
- Schijns VECJ & Horzinek MC. *Cytokines in Veterinary Medicine*, CAB Int. 1997, Wallingford, UK, 324 pp.
- Tizard I. *Veterinary Immunology. An Introduction*, Saunders Company, 2004. Philadelphia, Pa, USA.
- Wood PR et al. *Vaccines in Agriculture, Immunological Application to Animal Health*. CSIRO Information Service, 1994, Melbourne, Australia.
- Weber WT & Ewart DL. *Avian Immunology: Progress in Clinical and Biological Research*. Liss AR ed., 1987, Volume 238, New York, USA.



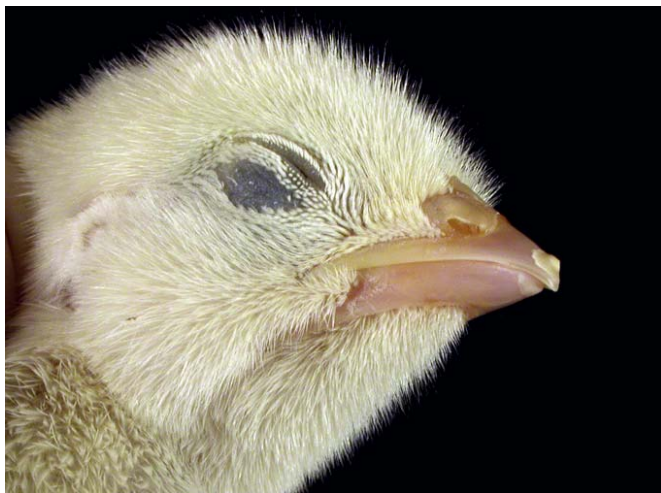
C. Degueurce

Fig.15.1: Skeleton of the hen. Lateral view. (a) Skull; (b) Premaxilla; (c) Cervical vertebrae; (d) Humerus; (e) Scapula; (f) Clavicle; (g) Coracoid; (h) Sternum; (i) Tarso-metatarsus; (j) Tibiotarsus; (k) Fibula; (l) Rib; (m) Femur; (n) Coxal; (o) Caudal vertebra; (p) Ulna; (q) Carpometacarpus; (r) Radius; (s) Digits.



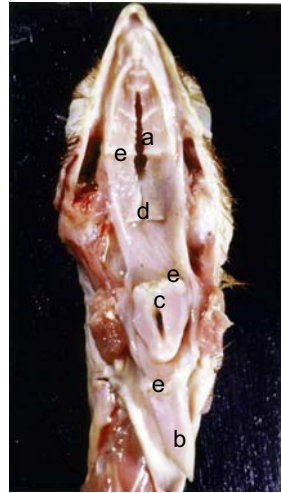
C. Degueurce

Fig.15.2: Skeleton of the duck. Lateral view. (a) Skull; (b) Premaxilla; (c) Cervical vertebrae; (d) Humerus; (e) Ilium; (f) Clavicle; (g) Thoracic vertebrae; (h) Sternum; (i) Tarso-metatarsus; (j) Tibio-tarsus; (k) Rib; (l) Femur; (m) Digits; (n) Caudal vertebrae; (o) Ischium.



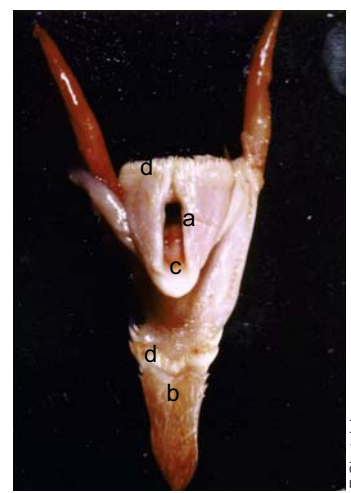
HJ Barnes

Fig.15.3: Egg tooth of a chick. It is a small cranial protuberance used to break the shell of the egg during hatching.



E. Chatelain

Fig.15.4: Oral cavity and pharynx of the hen after section of the corners of the mouth. (a) Choana; (b) Tongue; (c) Glottis (entrance to the larynx); (d) Infundibulum; (e) Papillae.



E. Chatelain

Fig.15.5: Larynx and tongue of the hen. (a) Larynx; (b) Tongue; (c) Glottis; (d) Papillae. There is no epiglottis.

15. AVIAN ANATOMY

INTRODUCTION

Birds are an important zoological group that includes about 10,000 species. They show physical adaptations radically different from those of mammals and directly related to their ecological status. They are vertebrates, amniotes, homeotherms covered with feathers and have wings. Three subclasses can be distinguished:

The *Ratites*, lacking a keel, are unable to fly (ostrich).

The *Impennes* have a keel but their wings are like fins and not suited for flight (penguin).

The *Carinatae*, equipped with a keel, are adapted to fly and grouped into three orders: Galliformes (e.g., chickens, guinea fowl, turkeys), columbiformes (e.g., pigeons) and anseriformes (e.g., ducks, geese, swans).

Some of the specificities of birds include:

- *the skin*, devoid of subcutaneous glands apart from the uropygial gland and with scales on the pelvic limbs;

- *the splanchnic serous membranes* are characterized by the absence of pleura and diaphragm and the presence of five peritoneal cavities.

SKELETON

All the anatomical features are geared towards the ability to fly and this remains clear even in species that have lost this ability. The skeleton is particularly adapted for flight. Many bones are lighter due to pneumatization, which is the penetration into the medullary cavity of long bones of air sac diverticula. Compared to mammals, the skeleton of birds has a higher concentration of calcium phosphate.

The avian skull includes a vaulted bulbous brain case, large bony orbits, and a toothless horny beak. The S-shaped cervical region of the vertebral column of a chicken usually contains 16 vertebrae (varies depending on the breed). The flexibility of the vertebral column and mobility of the atlanto-occipital joint allow the bird to use its beak in many situations, replacing the forelimbs of mammals. Certain thoracic, lumbar and sacral vertebrae are fused together and called synsacrum, which is itself joint to the pelvis. In chickens six free caudal vertebrae facilitate tail movements, while the 4-6 last caudal vertebrae form the fused pygostyle which is the site of attachment for the long tail feathers.

The sternum is prominent with large attachment surfaces for very large pectoral muscles. The center of gravity varies depending on the species, but it is generally located under the wing attachment to provide greater stability in flight. The thorax of birds is deformable, allowing some movement caused by air sacs.

The thoracic limbs, turned into wings, provide strong support for feathers which helps sustain flight.

The pelvic limbs are characterized by their development and strength thanks to the fact that several bones are joined together. The pelvis is much different than in mammals, with a large ilium fused to the synsacrum.

The bones of the hand are significantly simplified and the «hand» of the bird is proportionally longer as the bird is more adapted to flight.

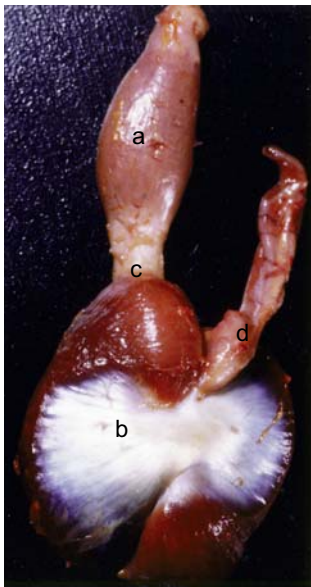
DIGESTIVE SYSTEM

Oral cavity & pharynx

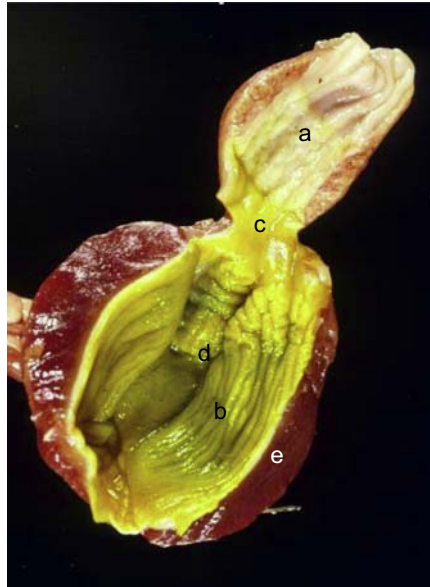
Because birds do not have a soft palate and isthmus, the oral and pharyngeal cavities together form a common cavity which is referred to as oropharynx. The choana is a median fissure in the palate connecting the oropharynx to the nasal cavity. Many backward-pointing, thickly keratinized papillae are distributed on the roof of the oropharynx, on the tongue and on the larynx.

The **esophagus** is thin and very distensible. It is located to the right of the trachea. It becomes enlarged ventrally in the thoracic inlet to form the crop below the skin and the trachea. When full, the crop distorts the base of the neck on the right and can easily be palpated on live birds.

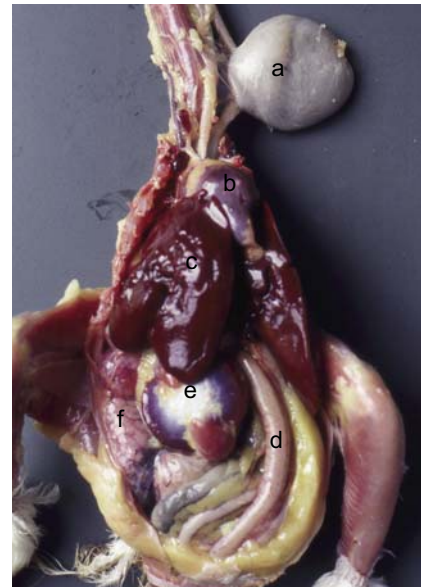
The **stomach** comprises two compartments, a glandular stomach (*proventriculus*, chemical stomach with papillae releasing gastric juices soaking the feed bowl) and a mechanical stomach (*gizzard* for grinding feed). They are separated by an intermediate zone, the isthmus, visible on the outside by a constriction. The shape and development of these stomachs are strongly related to the bird's diet.



E Chatelein



HL Shivaprasad

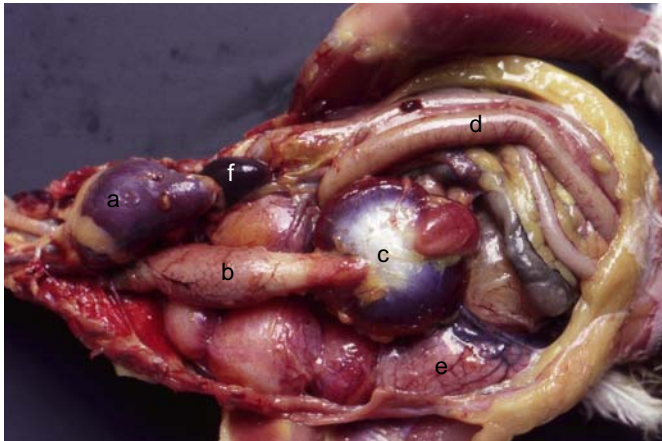


C Degreure

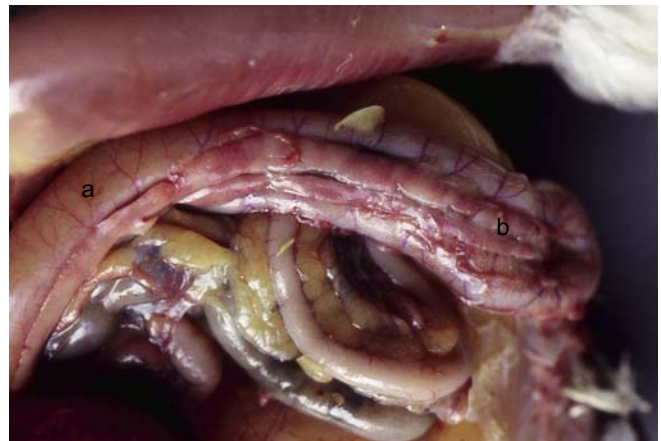Fig.15.6: Lateral view of the stomach of the hen. (a) Proventriculus; (b) Gizzard; (c) Isthmus; (d) Duodenum.

Fig.15.7: Interior of the stomach of the hen. (a) Proventriculus; (b) Gizzard; (c) Intermediate zone; (d) Pyloric orifice; (e) Muscle.

Fig.15.8: Ventral view of the viscera of the hen. (a) Crop; (b) Heart; (c) Liver; (d) Duodenum; (e) Gizzard (f) Uterus.



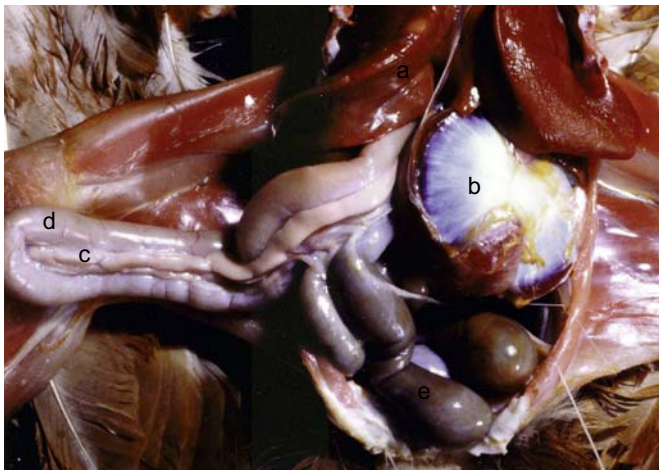C Degreure



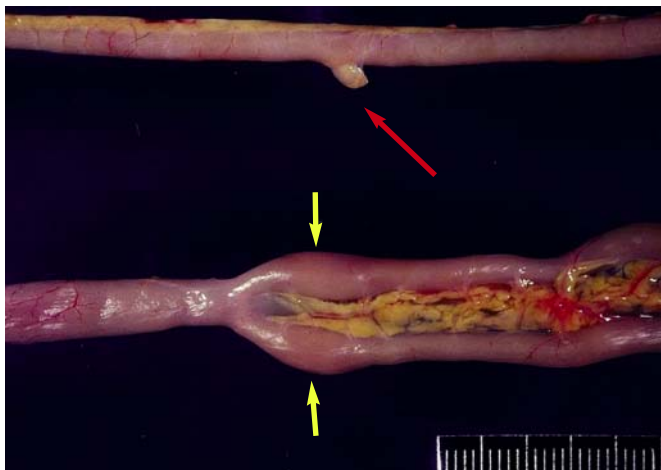
C Degreure

Fig.15.9: View after removal of the liver (Hen). (a) Heart; (b) Proventriculus; (c) Gizzard; (d) Duodenum; (e) Uterus; (f) Spleen.

Fig.15.10: Pancreas (Hen). (a) Duodenum; (b) Pancreas. The normal appearance of the pancreas is pale red or slightly yellow. Its normal location is between the loops of the duodenum and its glandular nature is evident macroscopically.



E Chatelein



HL Shivaprasad

Fig.15.11: Topography of ceca (Hen) (a) Liver; (b) Gizzard; (c) Pancreas; (d) Duodenum; (e) Cecum.

Fig.15.12: Important lymphoid structures of the intestinal tract. Meckel's diverticulum (red arrow), at the junction between the jejunum and the ileum, and cecal tonsils (yellow arrows), at the base of the ceca.

The **intestine** includes

- the *duodenum*, the duodenal loop encloses the pancreas, the whole duodenum/pancreas being always the most ventral part of the digestive tract;
- the *jejunum* forming numerous loops suspended by the mesentery;
- the *ileum*, relatively short, follows the jejunum at the level of Merckel's diverticulum, which is the only remnant of the yolk sac;
- the *ceca*, consisting of two symmetrical cul-de-sac 10 to 25 cm long, are connected to the intestine at the junction between the ileum and the rectum and contain at their base the cecal tonsils;
- the rectum;
- the *cloaca*, which is the crossroad of the digestive, urinary and genital tracts, with on its dorsal wall a lymphoid diverticulum, the bursa of Fabricius.

The **accessory glands of the digestive tract** are the *liver* and the *pancreas*. The liver is very large in birds and is positioned in the cranial portion of the thoracoabdominal cavity. The gallbladder is located on the visceral surface of the right lobe. It does not exist in pigeons. The pancreatic and biliary ducts open into the distal portion of the ascending loop of the duodenum.

RESPIRATORY SYSTEM

The nostrils of the bird lead into the nasal cavity. In each nasal cavity, three nasal conchae (rostral, middle, caudal) are found. The rostral conchae are scroll-like and are lined with a stratified squamous epithelium (this concha is absent in quails). The

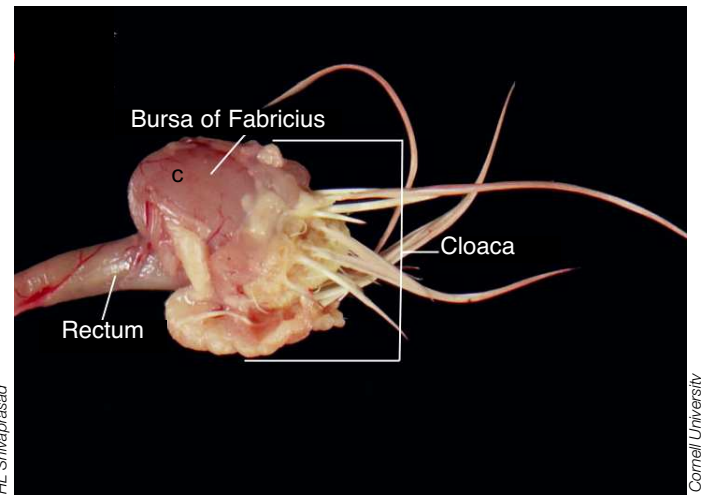
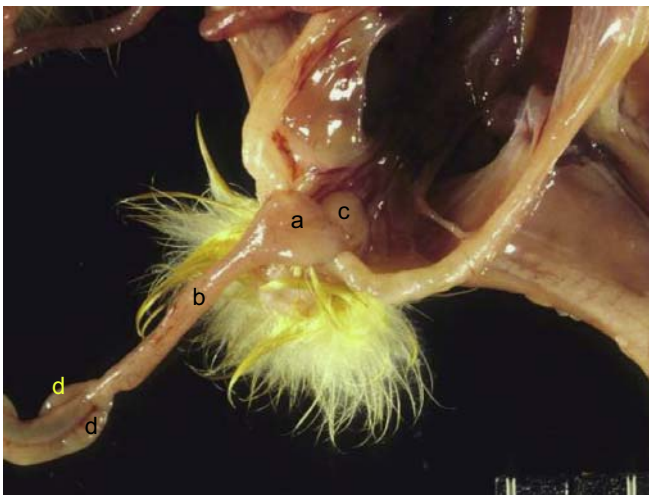

Fig. 15.13 & 15.14. The cloaca (a) consist of three parts: the coprodæum that collects excrement and is separated from the rectum (b) by a sphincter, the urodeum, which receives the ureters and deferent ducts in males or oviduct in females, and the proctodeum, sort of a reservoir that opens externally through the anus. On the dorsal part of the cloaca is a diverticulum, the bursa of Fabricius (c). Cecal tonsils (d).

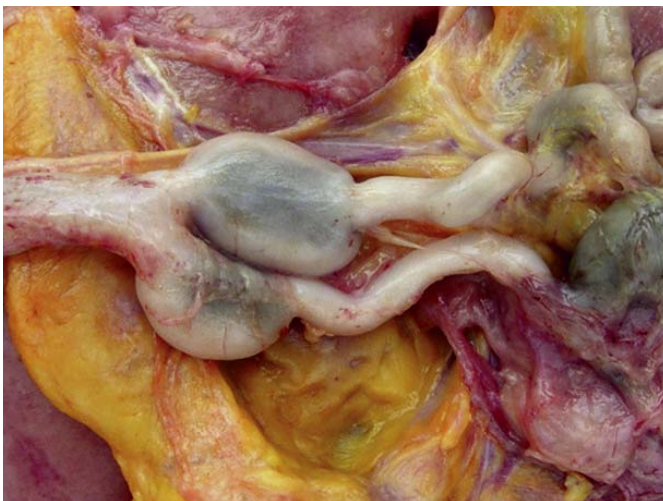

Fig. 15.15: Lymphoid leucosis. Cecal tonsil lymphoma (67 week-old chicken broiler breeder).

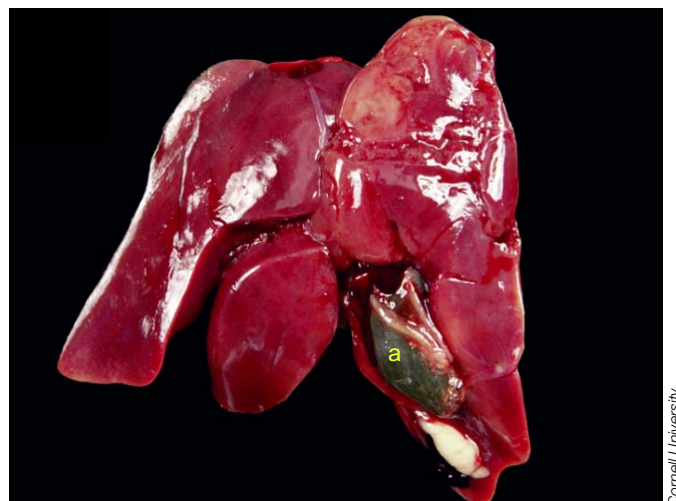

Fig. 15.16: Liver. Visceral face. The gallbladder (a) is located on the visceral surface of the right hepatic lobe. Its size is variable and may be enlarged in birds that are off-feed.

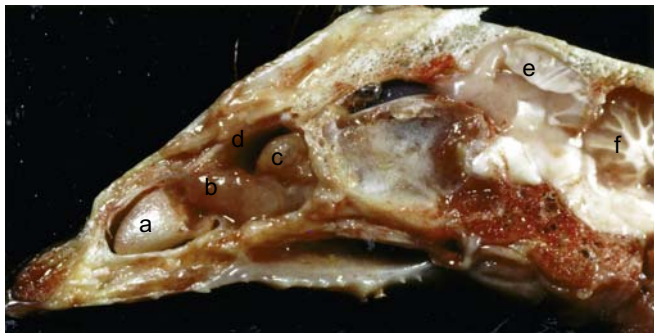


Fig.15.17. Median section of the head of a hen. (a) Rostral nasal concha; (b) Middle nasal concha; (c) Caudal nasal concha; (d) Nasal cavity; (e) Telencephalon; (f) Cerebellum.

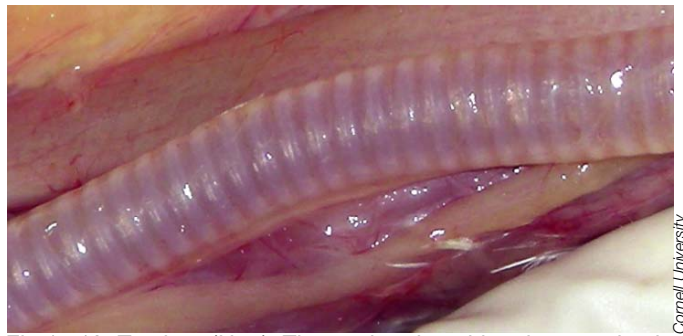

Fig.15.18. Trachea (Hen). The trachea is a thin tube completely encircled by cartilagenous rings, uniform in color, ranging from pale pink to tan or white and with a smooth external surface.

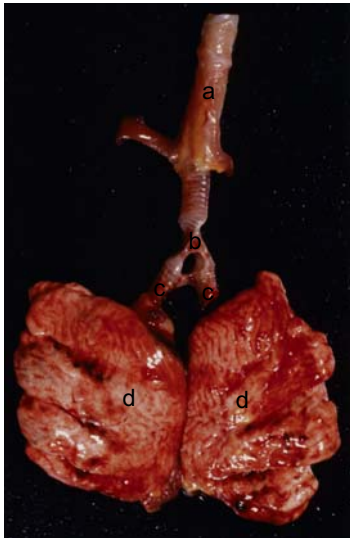


Fig.15.19: Syrinx and lungs in chickens (dorsal view). The pharyngeal organ or syrinx is located facing the tracheal bifurcation, forming a bulge on the caudal part of the trachea. (a) Trachea; (b) Syrinx; (c) Primary bronchi; (d) Lungs.

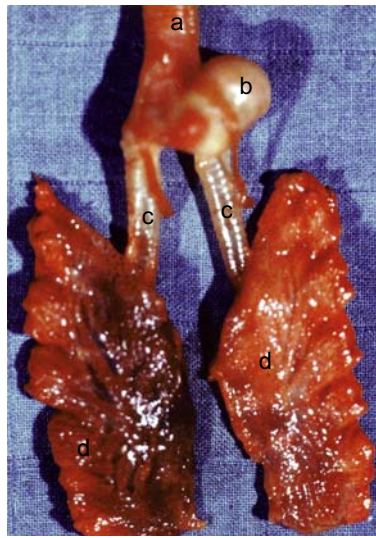

Fig.15.20: Lungs and syrinx (Duck). (a) Trachea; (b) Syrinx; (c) Primary bronchi; (d) Lungs. Trachea usually with bony, asymmetrical bulla on left side of syrinx.

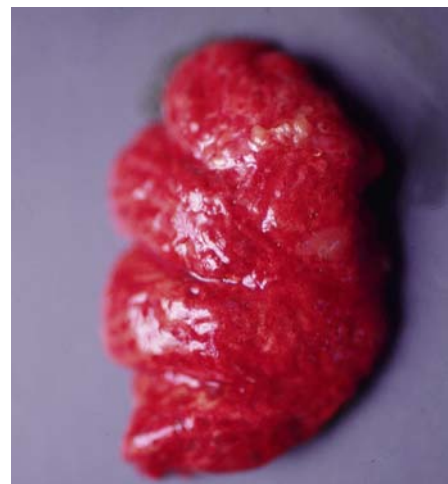

Fig.15.21: Lung (Hen). The color should be bright pink but will become increasingly more congested, wet, and dark red with autolysis.

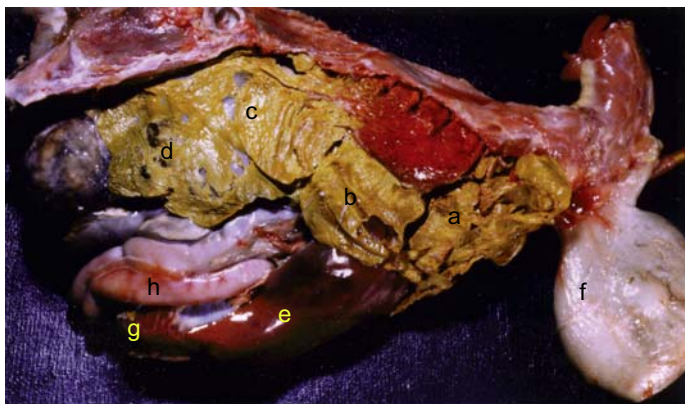


Fig.15.22 & 15.23: Air sacs of an adult chicken. Large extrapulmonary cul-de-sac. The topography of the air sacs is highlighted after latex injection in fig.15.22. (a) Clavicular air sac; (b) Cranial thoracic air sac; (c) Caudal thoracic air sac; (d) Abdominal air sac; (e) Liver; (f) Proventriculus; (g) Gizzard; (h) Duodenum.

middle conchae are also scroll-like and have a mucociliary epithelium. The caudal conchae are lined with olfactory epithelium and are connected to the infraorbital sinus, which is a cavity rostroventral to the eye. The nasal cavities are connected to the pharynx via the cleft palate.

Following the larynx, the trachea is composed of complete cartilaginous rings which can occasionally become ossified.

At the terminal end of the trachea is the syrinx, a flattened area at the junction of the trachea and the primary bronchi. The syrinx, or "tracheobronchial larynx", is the organ of phonation. It is responsible for generating vocal sounds because there is no vocal cords in birds. Since the diameter of the syrinx is significantly smaller than that of the trachea, it may be a site of occlusion in cases of respiratory disease. In ducks and geese, the syrinx has a large bony dilation on the left side known as the syringeal bulla.

In birds, the lungs are practically inextensible. The pleural cavity is limited to connective tissues uniting the parietal pleura covering the ribs to the visceral pleura covering the lungs. The lungs represent a relatively small volume and they occupy only a small part of the thoracic cage (1/8th to 1/6th). The lungs are red, with grooves at the costovertebral borders giving them a lobulated appearance.

The air passages of the lungs consist of two primary bronchi extending from the syrinx to the caudal border of the lung (intrapulmonary primary bronchi called mesobronchi) with three groups of collateral bronchi (ventral, dorsal and lateral secondary bronchi). These bronchi run through the lung ending up in the abdominal air sacs. Parabronchi, which arise from the secondary bronchi, anastomose freely with each other. Their walls contain small air capillaries where cross-current

gas exchange occurs. The bronchi extend outside the lung in the form of thin-walled transparent chambers (air sacs) spreading into the thoracoabdominal cavity, some muscle gaps and bones. They permit a unidirectional flow of air through the lungs, lighten the body and help regulate body temperature. They are involved in phonation and implicated in respiratory diseases (airsacculitis).

URINARY SYSTEM

The kidneys are relatively more developed than in mammals. Each kidney, dark red to mahogany brown in color and with a slightly granular texture, is made up of three lobes: cranial (the larger), middle (the smallest) and caudal. They fill depressions on the ventral surface of the synsacrum and hip bones. Blood circulation is complex and includes a distinctive portal system (see Chap. I.10). There is no urea accumulation in the renal medulla. The ureters open into the urodeum except in *Struthionidae* which have a bladder (this is the bursa of Fabricius which, once regressed, serves as a storage organ). The urine flowing into the urodeum is clear and whitened due to fluid absorption and urate precipitation.

REPRODUCTIVE SYSTEM

Male genital tract

The testes are located in the abdominal cavity on either side of the caudal aorta under the cranial pole of the kidney. They are bean-shaped, milky white in color, the right testicle being slightly more cranial than the left. The epididymis is less developed than in mammals. Their volume and weight vary depending on season. The testes of roosters can go from 1 cm long and 0.5 cm wide at rest to 5 cm x 2.5 cm during the period of sexual activity. In ducks, they may increase from 1 cm x 0.5 cm at rest to 8 cm x 4.5 cm in periods of sexual activity. The copulatory organ is very small. Some birds have a phallus (ratites, anseriformes).

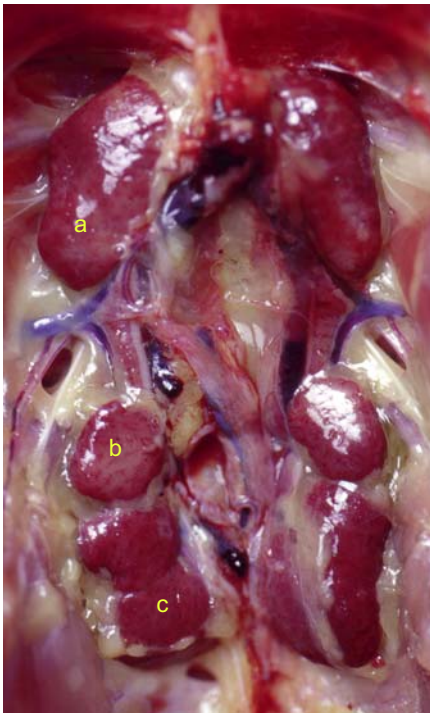


Fig.15.24: Kidney (Hen). Each kidney comprises three lobes: (a) cranial, (b) middle (c) caudal.

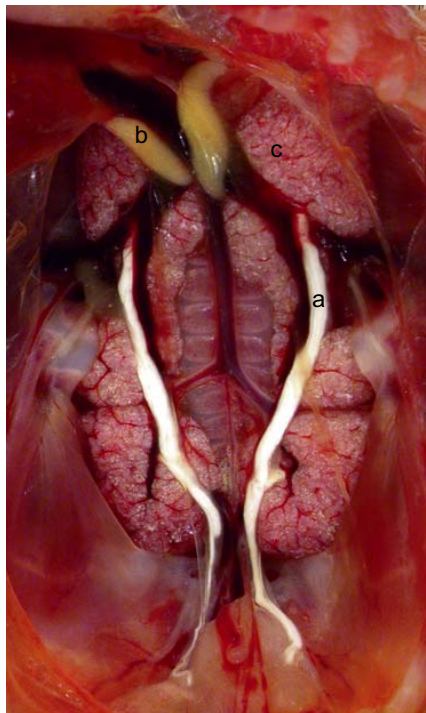


Fig.15.25: Visceral gout affecting the kidneys (enlarged and with urates). Note the ureters filled with urates (a) in a young chicken. Right and left juvenile testes (b) are bean-shaped and overlying the cranial ends of the kidneys (c).

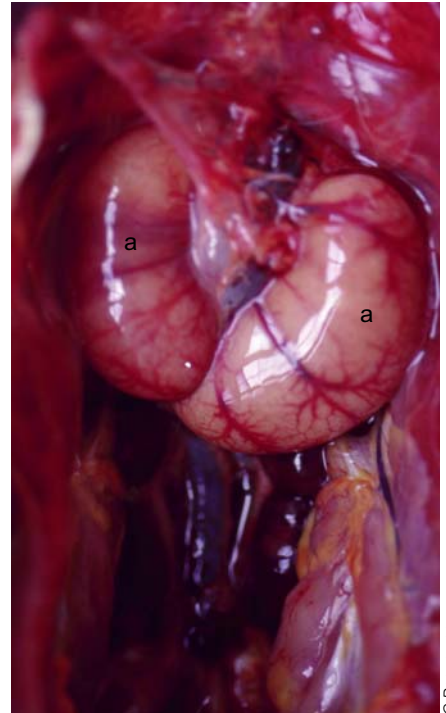


Fig.15.26 : Testes of a sexually active chicken. Ventral view. The surface of the sexually active testis is highly vascularized. The epididymis lies dorsal to the testis and is therefore not visible here.

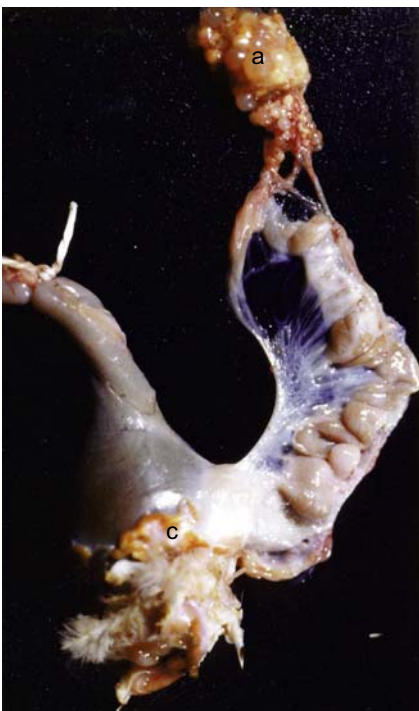

Fig.15.27: Genital tract of a pullet. (a) Ovary (b) Magnum (c) Cloaca.

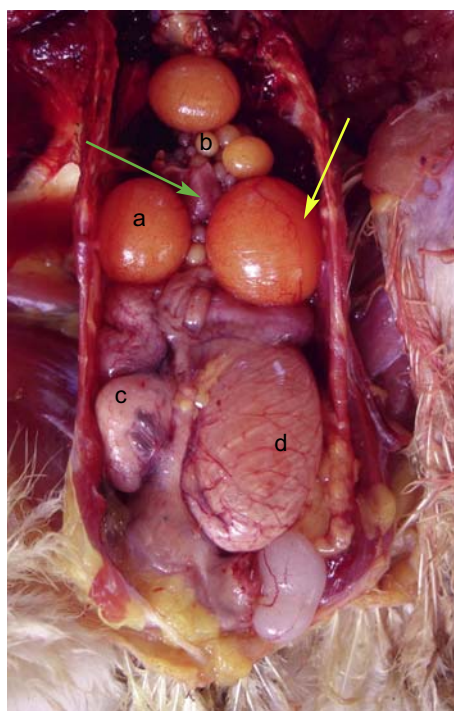
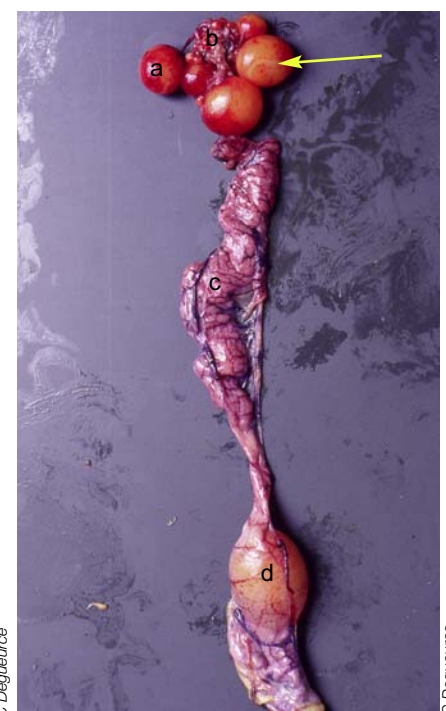

Fig.15.28 & 15.29: Ovary and oviduct of a laying hen. Ovary: (a) mature follicles; (b) smaller immature follicles. On the surface of the follicles is a white avascular band, the stigma (yellow arrow) where at ovulation the wall of the follicles splits to release the oocyte. Post ovulatory follicle (green arrow): thin-walled sac in regression. (c) Oviduct. An egg is present in the uterus (d).



Femelle genital tract

The ovary of the chicken is very different from that of mammals. It is present only on the left side, the right forming an atrophied testicle inhibited by hormones secreted by the left. The left ovary resembles a bunch of grapes with four or five large, mature follicles and thousands of smaller immature follicles. The yellow color of the mature follicles is related to the presence of yolk, with proteins and lipids produced in the liver and provided by blood circulation. On the surface of mature follicles is a white avascular band, the stigma, where during ovulation the wall of the follicle splits to release the yolk and oocyte. Immediately after ovulation the follicle becomes a thin-walled sac, the post-ovulatory follicle, regressing in about 10 days. The oviduct receives the egg and is involved in its formation (see Chap.I.10). Unlike in mammals there is no *corpus luteum*.

IMMUNE SYSTEM (see Chap.I.14)

The organs of the immune system are classified into primary or central lymphoid organs and secondary or peripheral lymphoid organs. In birds, the primary lymphoid organs are the thymus and the bursa of Fabricius where lymphocytes precursors differentiate and undergo maturation. Mature lymphocytes leave the primary organs and populate the secondary lymphoid organs. The peripheral lymphoid organs and tissues, characterized by aggregates of lymphocytes and antigen-presenting cells (APC), are scattered throughout the body. They include the spleen, the bone marrow and the Harderian gland. In addition, birds have clusters of lymphoid tissues that are named according to their location such as head-associated lymphoid tissues (HALT), bronchus-associated lymphoid tissues (BALT), and gut-associated lymphoid tissues (GALT). Examples of

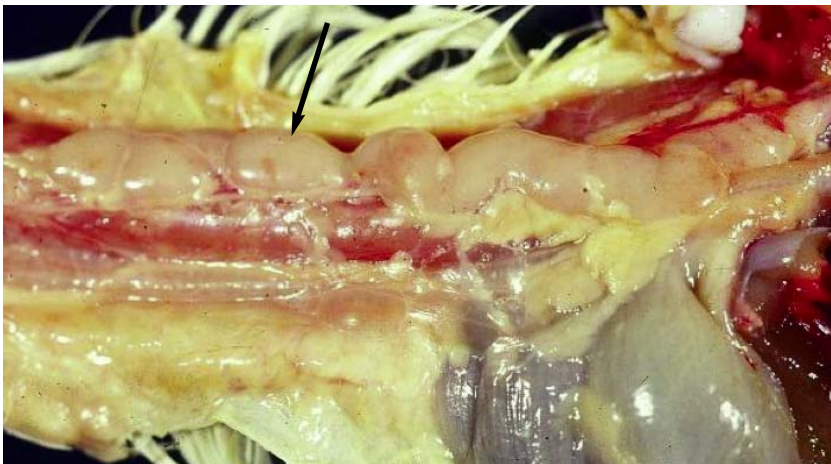

Fig.15.30: Thymus (Chicken). It is an elongated, multi-lobular structure (7 lobes in the chicken) located along the length of both sides of the trachea with some lobes extending into the anterior thoracic cavity.

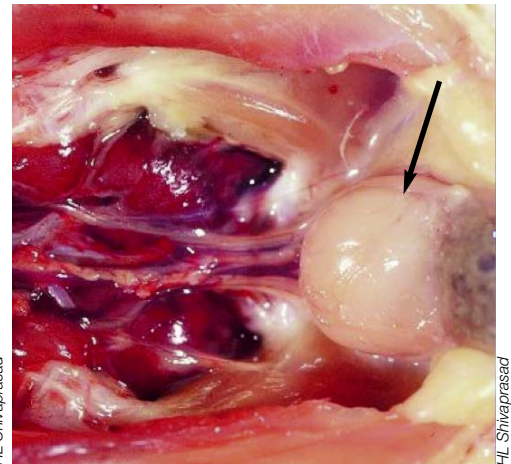


Fig.15.31: Bursa of Fabricius (Chicken). In the chicken, the bursa is detectable on around the 5th day of incubation and becomes functional between the 10th and 12th day.

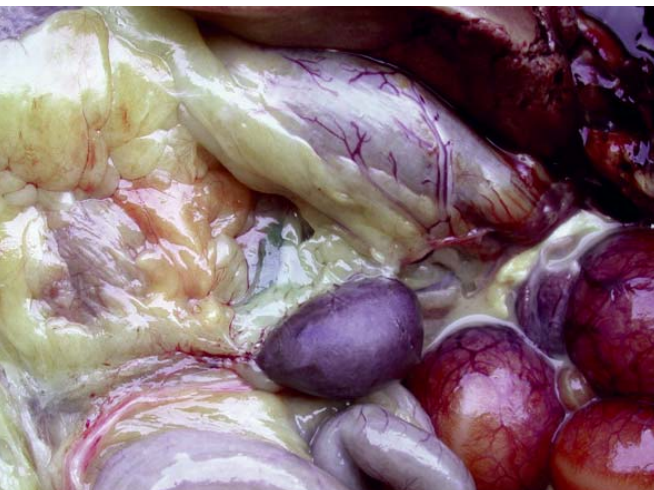

Fig.15.32: Normal spleen (65 week-old turkey breeder hen).

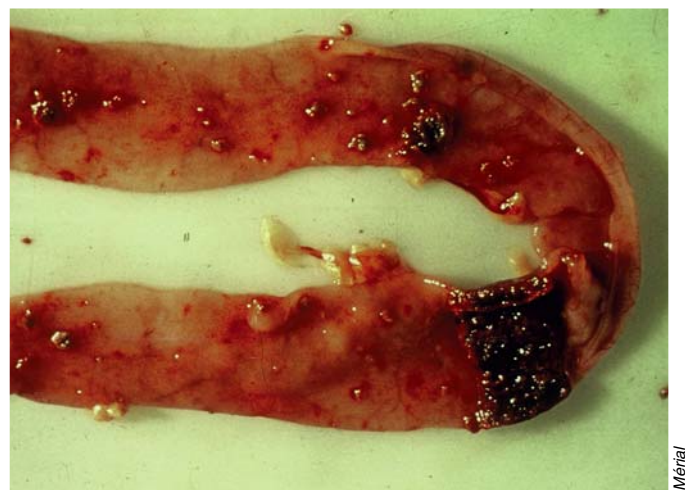

Fig.15.33: Annular bands of the small intestine (Duck). These lymphoid patches are highlighted macroscopically due to severe congestion and hemorrhage following infection by the duck enteritis virus.

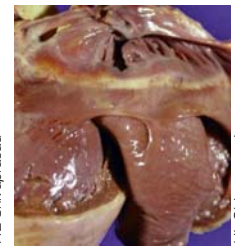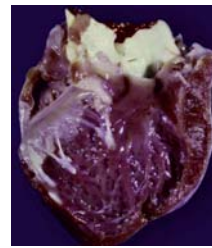
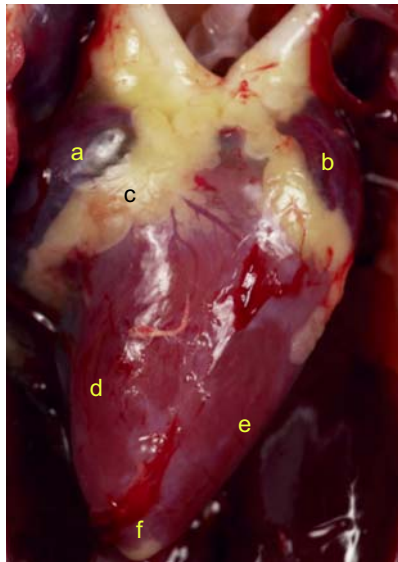
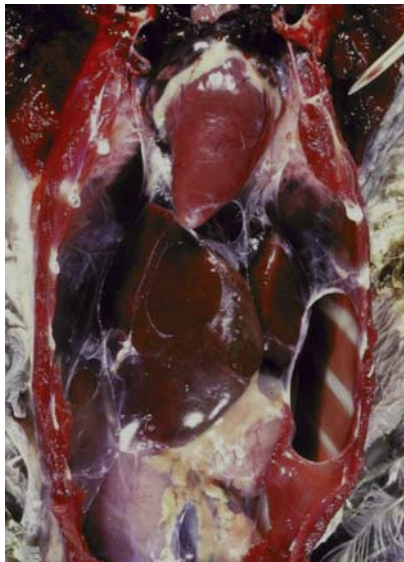


Fig.15.36 & 15.37: Left (Fig.15.36) and right (Fig.15.37) atrioventricular valves.

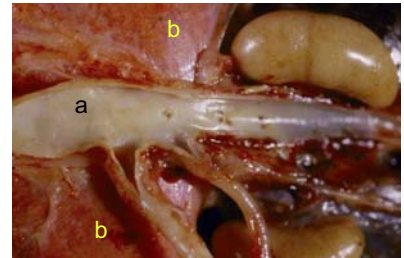


Fig.15.38: (a) Aorta; (b) Lungs.

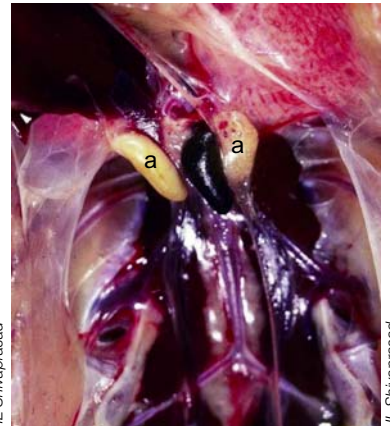
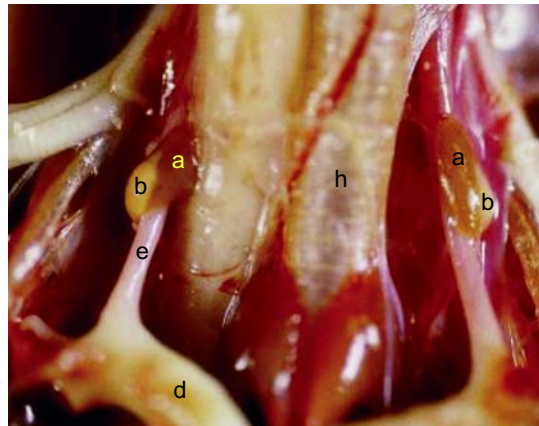
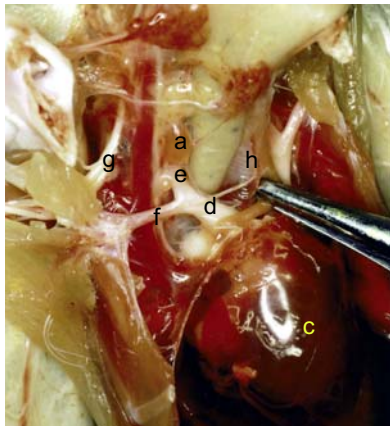


Fig. 15.39 & 15.40: The thyroid and parathyroid glands are located on either side of the neck, medial to the jugular vein and cranial to the origin of the subclavian and common carotid arteries. The parathyroid gland is slightly separated from the thyroid gland. (a) Thyroids; (b) Parathyroids; (c) Heart; (d) Brachiocephalic trunk; (e) Common carotid artery; (f) subclavian artery; (g) Brachial plexus; (h) Trachea.

Fig.15.41. Adrenal glands (a) are yellow structures lying on either side of the kidneys and dorsal to the testes or the ovary.

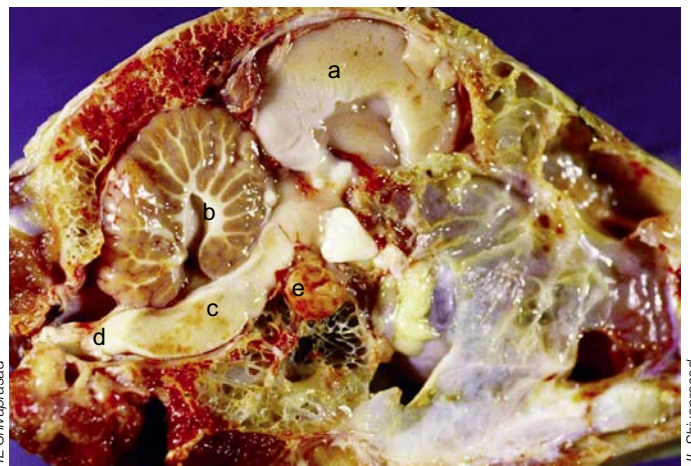
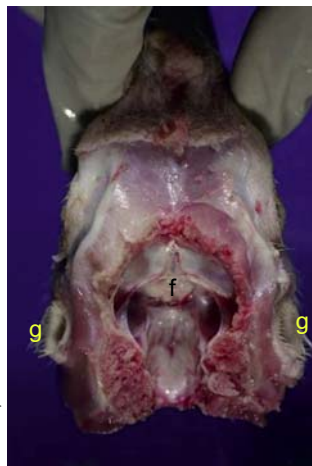
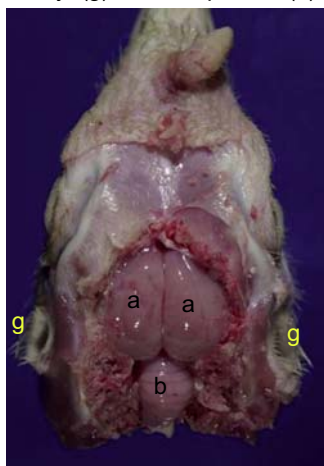


Fig.15.42, 15.43 & 15.44: The brain completely fills the cranial cavity. The front part is narrow; the posterior part is wider. The top of the skull must be cut to show the brain. (a) Cerebral hemispheres; (b) Cerebellum; (c) Pons; (d) *Medulla oblongata*; (e) Pituitary (hypophysis); (f) Optic chiasm; (g) External ears.

GALT include esophageal tonsils, Meckel's diverticulum, Peyer's patches, cecal tonsils as well as annular bands in ducks.

CIRCULATORY SYSTEM

The avian heart on a body weight basis is much larger than that of mammals because of its very high rate of contraction and its high blood pressure (see Chap.I.10). It lies in the ventral part of the thorax under the lungs and is surrounded by the lobes of the liver. Three vena cavae open in the right atrium (the right cranial vena cava, the left vena cava, and the caudal vena cava). The left atrium receives the two pulmonary veins. Usually a variable amount of fat will be present in the coronary groove. When birds are emaciated, this fat may be absent or have a gelatinous, wet appearance.

The arterial system of birds includes mainly the right and left brachiocephalic trunks, the common carotid arteries, the pulmonary arteries and the aorta. Unlike in mammals, the aorta in birds develops from the right arterial arch and consequently bends to the right.

THYROID, PARATYROID & ADRENAL GLANDS

The thyroid and parathyroid glands are small. They are located on either side of the neck, medial to the jugular vein and cranial to the origin of the subclavian and common carotid arteries.

The parathyroid gland is slightly separated from the thyroid gland.

Adrenal glands are yellow structures lying on either side of the midline at the cranial end of the kidneys and dorsal to the testes or the ovary. Unlike mammals, the cortical and medullary cells do not form two distinct regions.

NERVOUS SYSTEM

The nervous system of birds is characterized by the slow development of the brain, devoid of gyri or sulci and the importance of the spinal cord that extends into the caudal vertebrae. The cortex (grey matter) is relatively thin. The peripheral nerves should have a creamy-white color and a slightly striated texture. A careful inspection of these nerves is performed when Marek's disease is suspected.

REFERENCES

- Alamargot J. *Manuel d'Anatomie et d'autopsie aviaires*, Ed. Point Vétérinaire, Maisons Alfort 1982, 136 pp.
- Chatelain E. L'anatomie des oiseaux. In "*Manuel de pathologie aviaire*". Ed. J Brugère-Picoux & A Silim. Publ. Chaire de pathologie du bétail et des animaux de basse-cour, Maisons-Alfort, 1992, p25-36.
- Baumel JJ et al.: *Nomina Anatomica Avium*, Acad. Press, New York 1979.
- King AS & McLelland J. *Form and function in Birds*, vol. 1, Academic Press, London, New York, 1979.
- Koch T. *Anatomy of the chicken and Domestic birds*, Iowa State University Press, Ames, Iowa, 1973.
- McLelland J. *A colour atlas of avian anatomy*. Wolfe Publ. London 1990, 127 pp.
- Nickel R et al. *Anatomy of the domestic birds*, Verlag Paul Parey, Berlin, Hamburg, 1977.

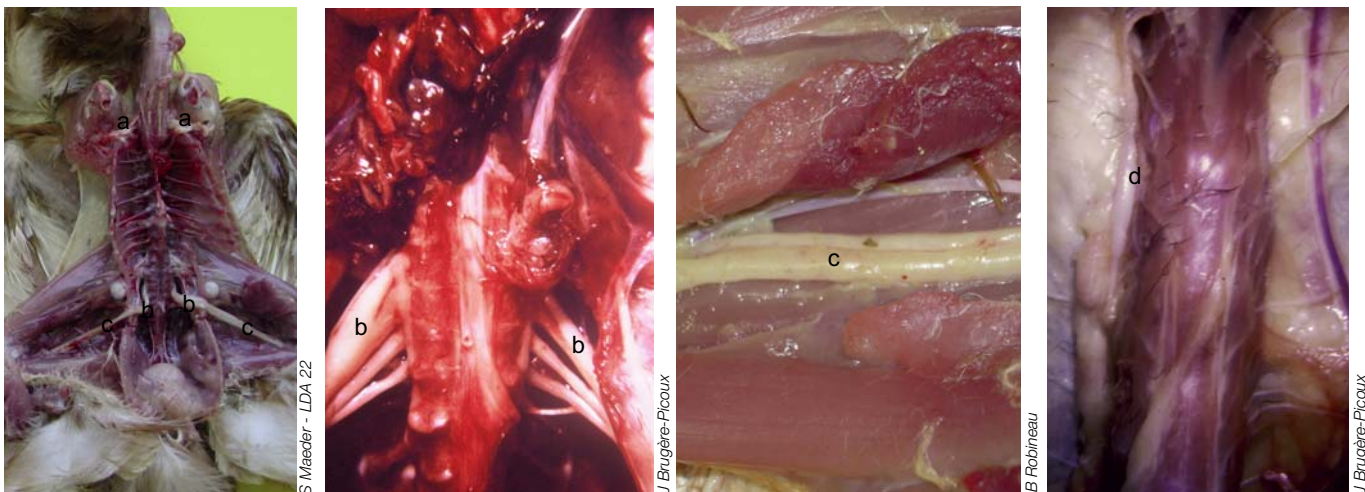


Fig.15.45, 15.46, 15.47 & 15.48: Peripheral nerves become enlarged and loose their pearly white color and striation in case of Marek's disease. The lesions are not always symmetrical, allowing a comparison. (a) Brachial plexus (b) Sciatic plexus (c) Sciatic nerve (d) Pneumogastric nerve.

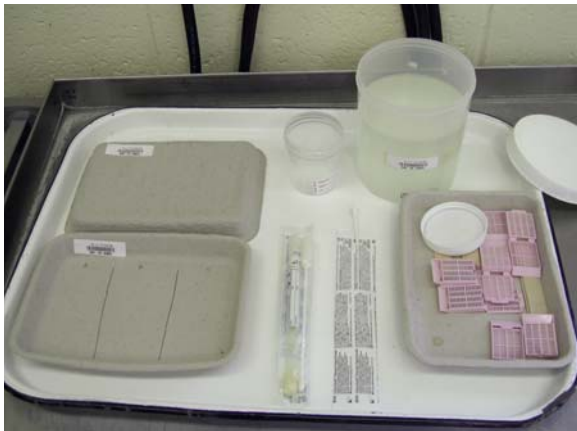

Fig.16.1: Equipment needed for sampling: jar of formaldehyde, cassettes for the fixation of small tissues, tongue depressors for fixing the nerves and muscles, box and swabs with transport medium for bacteriology, dry swab and container for PCR, virology, and parasitology.

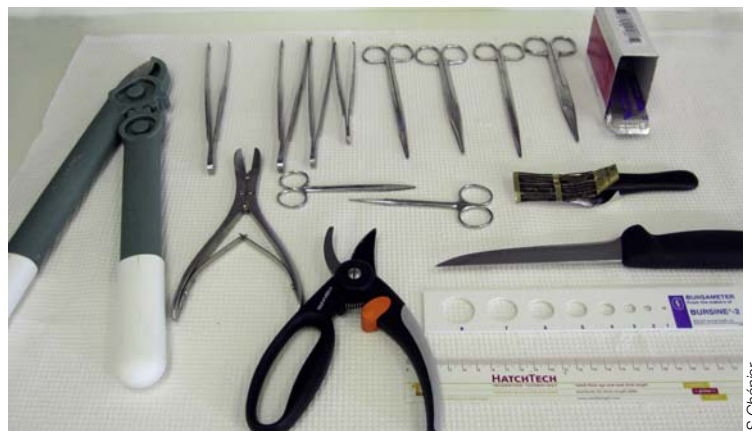

Fig.16.2: Basic necropsy instruments. Different scissors (enterotome, scissors, shears), a rib cutter (costotome), toothed forceps, blunt-sharp scissors (to cut the skull), necropsy knife, bistoury and blades and a ruler. On this picture you also find a "bursameter", a tool designed to quickly assess and compare the size of the bursa of Fabricius in broiler chickens.



Fig.16.3: *Ante mortem* examination. In this case, the bird does not put any weight on one leg; necropsy showed that it suffered from arthritis and osteomyelitis.

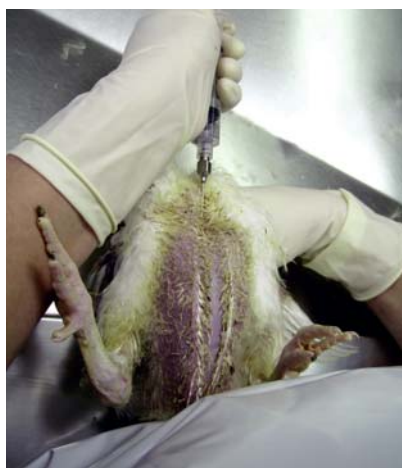

Fig.16.4: Intra-cardiac blood sampling. The bird is maintained on its back and the crop is pushed on the side. The needle penetrates the skin just below the junction of the clavicles. It is then directed posteriorly while following the midline of the sternum.

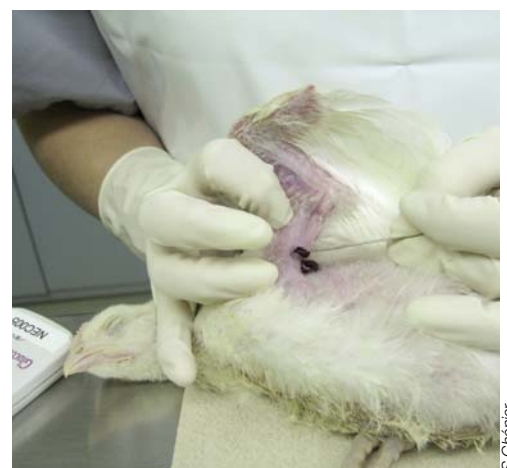

Fig.16.5: Blood collection by incision of the wing vein with a scalpel blade. The blood that flows can be taken directly with a glucometer or a capillary tube for microhematocrit.

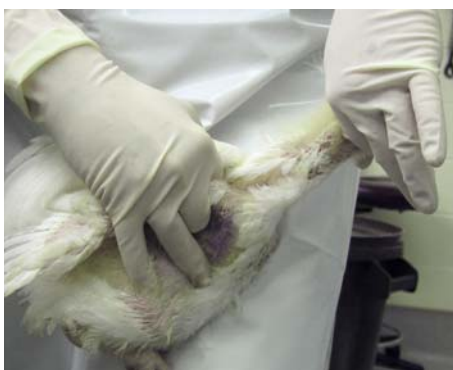

Fig.16.6: Positioning for euthanasia by atlanto-occipital dislocation. The bird is resting on the operator's thigh, firmly held by one hand at the base of the wings and the other hand at the base of the head. Then, a quick firm and continuous traction must be applied on the column while raising the head upwards.

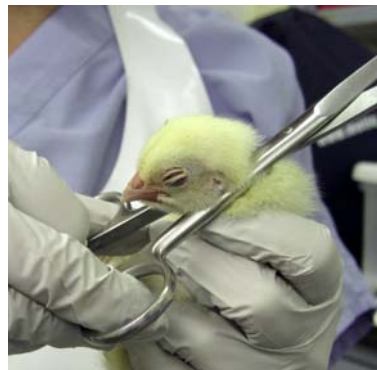

Fig.16.7: Euthanasia by crushing the cervical vertebrae in a chick. The non-cutting side of scissors is used.



Fig.16.8: External examination. The bird is put in a supine position, wings and legs extended. Examine the body conformation, feathering (quality, parasites), skin (nodules, inflammation), joints, foot pads, the head.

16. AVIAN NECROPSY

The purpose of a necropsy is to be able to formulate a differential diagnosis based on macroscopic lesions, as well as to take relevant samples for tests which will help to confirm the diagnosis. Different approaches may be used to perform a necropsy on a bird. The one proposed in this chapter is only one among many. What matters is to adopt and consistently repeat the necropsy procedures in the same way in order to develop a mental image of the usual aspect of the bird's anatomy and to avoid forgetting anything in the process.

Before beginning the necropsy, it is necessary to make sure to have basic equipment on hand: buffered formalin solution 10%, sterile swabs and containers for bacteriology, dry swabs and containers for molecular tests (PCR) and/or virology and/or parasitology. The instruments normally used during a necropsy are small scissors (enterotome), shears or rib cutter, toothed forceps, knife, bistoury or scalpel. To prevent transmission of zoonotic agents such as erysipelas, it is important to wear gloves during all stages of the necropsy.

If the birds are alive, it is important to observe their behavior and gait prior to euthanasia, especially if they have a history of locomotor problems. Observation of clinical signs may provide clues regarding which system to prioritize. It may also be useful to obtain blood from live birds. These samples may be useful for serology, hematology, biochemistry, or toxicological tests. Venipuncture of the wing vein is usually done in adult birds, with cardiac puncture as a possible option in young birds. It is also possible to obtain blood for glucose or hematocrit assessment by incision of the wing

vein and direct collection of the blood or using a capillary tube.

Euthanasia of birds can be performed: 1) by atlanto-occipital dislocation or compression of the cervical spine by the non-cutting side of surgical scissors in young birds; 2) by electrocution for heavy weight birds (older turkeys, ducks, geese); 3) by administration of CO₂ in a container designed for this purpose; 4) by intravenous administration of barbiturates; 5) by intracardiac injection of air.

It may be useful in some cases to weigh the dead birds to determine their degree of homogeneity. However, note that, unless the birds were selected at random, the weight variation may not reflect the situation in the flock.

Following euthanasia, put the birds on their back. They have to be the object of a careful external examination. Assess: body conformation, feathering, parasites, the navel (for newly hatched birds), *etc.* When examining the head pay particular attention to the eyes and the conjunctiva. It is then recommended (but not essential) to wet the feathers with a solution of soap and water to minimize airborne dust and feathers. If chlamydophilosis is suspected, it is strongly suggested to do the necropsy under a biological hood, or to wet the bird with a disinfectant solution and wear a mask against fine particles (respirator).

Incise the hips with a knife and dislocate the hip joint firmly but carefully (to avoid creating an artifact by rupturing the femoral head). Incise and lift

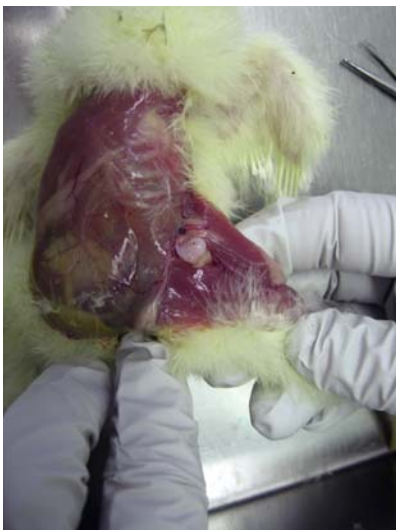

Fig.16.9: Opening the coxofemoral joints. The skin and the connective tissue are incised (internal portion of both thighs) and the femoral heads are dislocated and exposed.

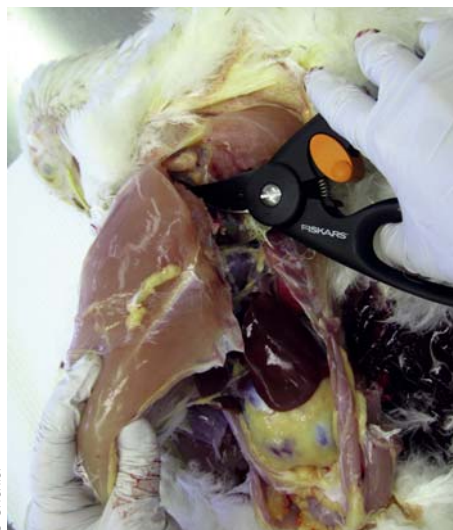

Fig.16.10: Opening of the thorax. Once the abdominal wall is opened, an incision is made in the muscles of the thorax with a knife to expose the bones that are then cut using a scissor or costotome.

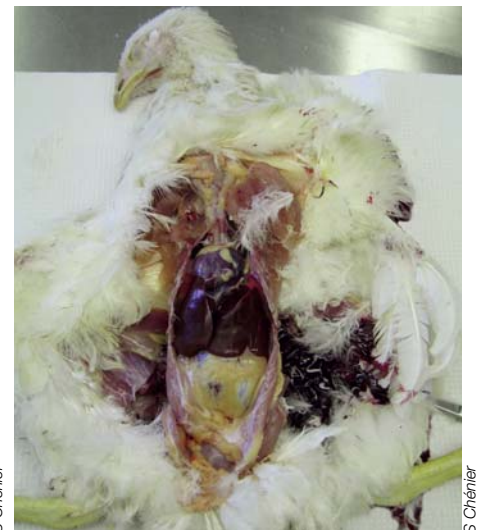

Fig.16.11: Coelomic cavity exposed. The heart, air sacs and liver can be observed *in situ*. The amount of fat in the post-hepatic septum is useful to assess the body condition (for adults).

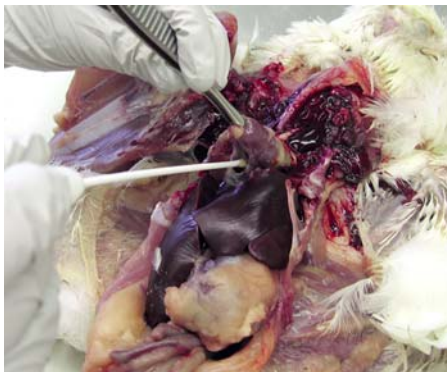

Fig.16.12: Swabbing. If there is an effusion in a cavity (e.g., the pericardial sac), the wall is incised with a scalpel or clean scissors and a sterile swab is used without touching the border of the opening.

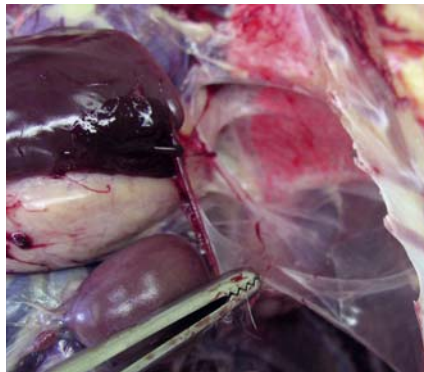

Fig.16.13: Normal air sac. These are the left thoracic sacs. Note in the background the normal salmon pink color of the lung.

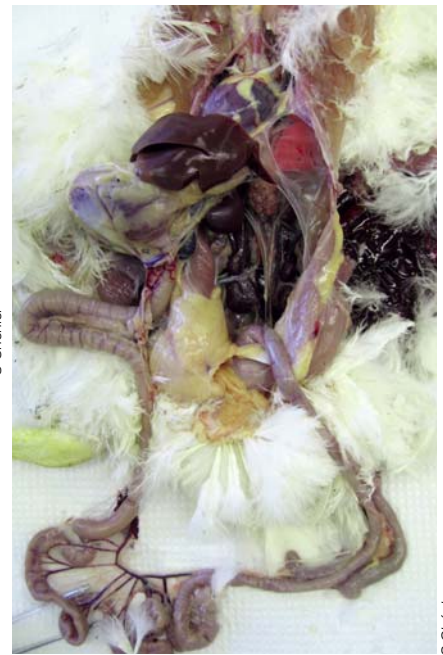

Fig.16.14: Coelomic cavity exposed. The post-hepatic *septum* is undone, as well as the mesentery, allowing the examination of the spleen, kidneys, stomach, pancreas and intestines. An immature ovary can also be observed in this bird.

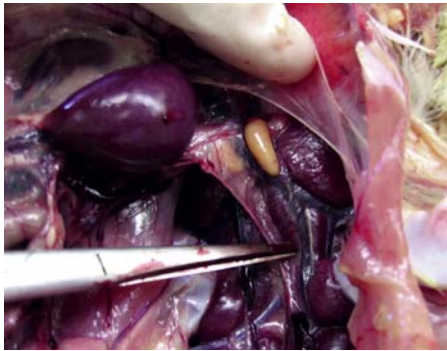

Fig.16.15: Kidney. The thin white line at the edge of the scissor is the left ureter filled with a small amount of urate (mild dehydration). Also present in this picture are the left and, under the mesentery, the right testicles.

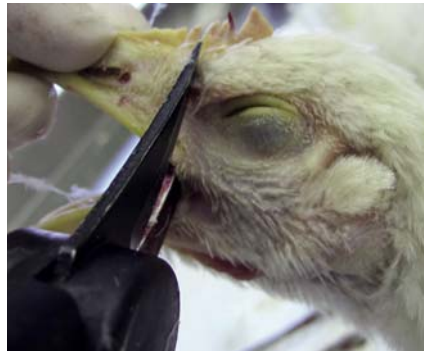

Fig.16.16: Section of the maxillary portion of the beak, caudal to the nostrils.

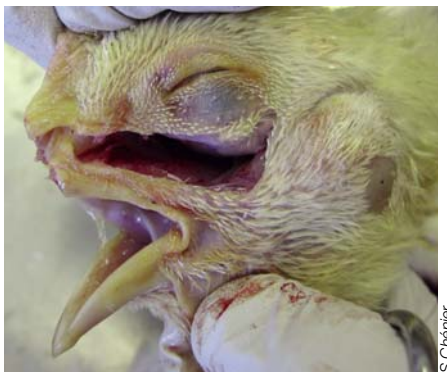

Fig.16.17: Left suborbital sinus.

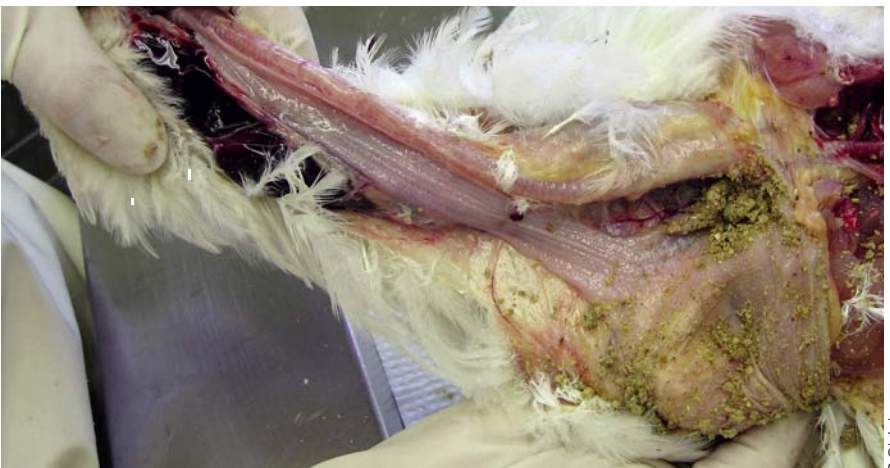

Fig.16.18: Esophagus and crop.

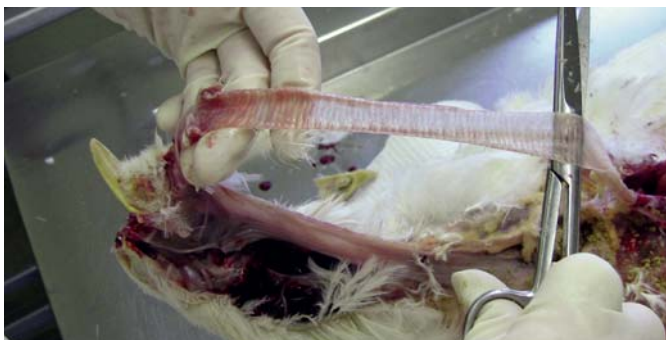

Fig.16.19: Trachea. Do not forget to examine the bifurcation of the bronchi in chicks (frequent localization of aspergillosis lesions).

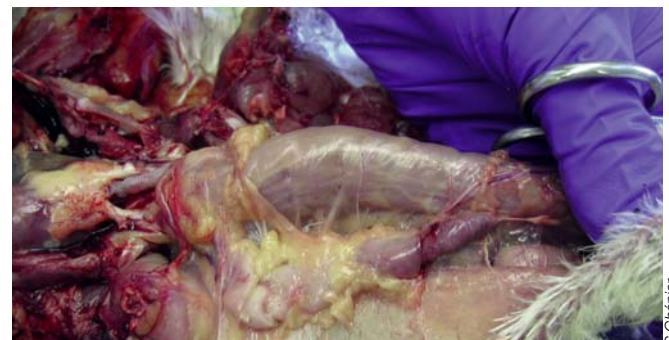

Fig.16.20: Thymus. It is located in the subcutaneous tissue of the neck.

the skin over the abdomen and pectoral muscles. Examine the muscles and, if necessary, cut them in order to gain access to and examine the deep pectoral muscle. The size of the pectoral muscles also serves as an indicator of the bird's body condition.

Open the abdominal wall with scissors and enlarge this opening to expose the liver, the post-hepatic septum and the intestines. With a knife and a rib cutter (or coarse scissors), incise the muscles, then cut the ribs on one side, cut the coracoid and clavicle and reflect the sternum to the other side to gain full access to the entire coelomic cavity.

Examine the pericardial sac and air sacs, which should normally be completely transparent. If this is not the case, incise and aseptically swab their content. Take a section of air sac and put it into a cassette for fixation in formalin. Examine the heart *in situ* then remove it; open and examine the various cardiac chambers and finally put it in formalin. Examine the lungs: they should normally be salmon pink and rather dry. Peel them carefully from the ribs, cut along the midline and remove them from the cavity. Take a section for histology and, if necessary, for other diagnostic tests.

Examine the liver. Incise or tear up the post-hepatic septum. Reflect the liver and stomachs on the right side of the bird to expose and examine the spleen. In newly hatched birds, also look at the yolk sac. Remove it carefully from the coelomic cavity so as not to break it and put it aside to examine its content. Swab aseptically the inside if necessary; empty most of the yolk and then put it in formalin.

Undo the mesentery to examine the intestines throughout their length before opening them. Except when enteritis is suspected (dilated bowel,

congestion or abnormal color), the intestines are only opened at the end of the necropsy, in order to avoid contamination of other organs. If there is evidence of enteritis, externalize the intestinal segments and take the sections needed to be fixed in formalin or frozen as soon as possible to avoid autolytic changes and *post mortem* microbial growth.

Examine the kidneys. The thin and quite translucent white line over each kidney is the ureter. If this line is very visible and chalky white in color, this indicates dehydration (ureters dilated with urate). If there is a history of leg paralysis, especially in chickens, consider the sciatic plexus located underneath each kidney. You will need to carefully remove the kidneys. In adult birds, also examine the testicles or the female genital tract. Finally take samples from all abdominal organs needed for histology (liver, spleen and kidneys are routinely sampled) and various diagnostic tests.

Cut the maxillary portion of the beak transversely just in front of the eyes to evaluate the nasal cavity. Open the suborbital sinuses from the nasal cavity with sterile scissors to evaluate their content and swab any exudate if present. Open the esophagus from the commissure of the beak by cutting through the skin down to the crop. Examine the mouth and the esophageal mucosa. Evaluate the content of the crop and the mucosa. Take samples if necessary. Separate the trachea from the esophagus by tearing up the connective tissues that connect them. Open the trachea from the larynx to the bifurcation of the bronchi; evaluate its content and the mucosa. Take a section for histology and, if necessary, for other diagnostic tests. If this is a young bird, look at the size of the thymus located along the jugular vein in the subcutaneous tissue of the neck, and collect a sample if necessary.

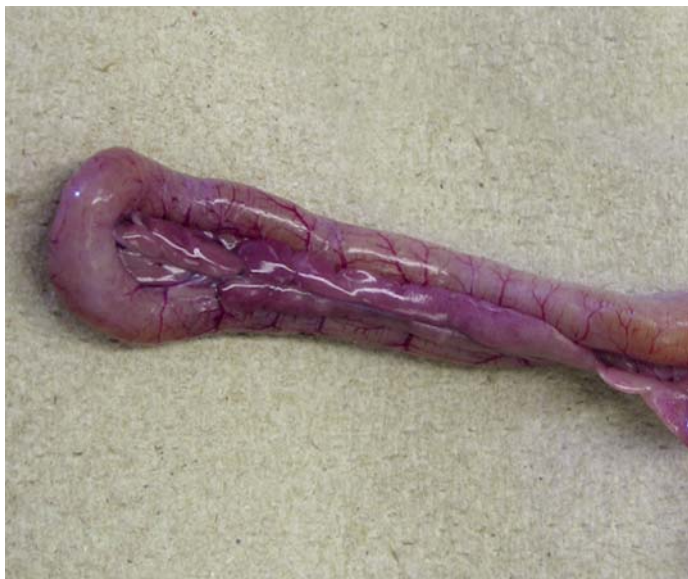

Fig.16.21: Duodenal loop and pancreas in the center.

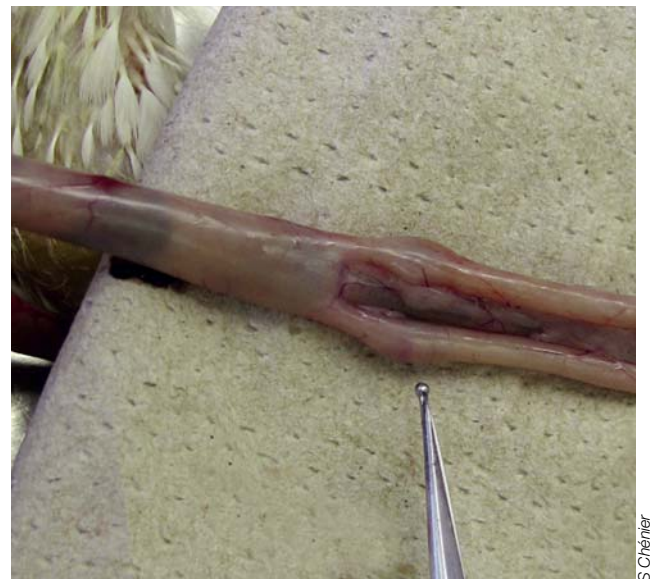

Fig.16.22: Ileocecal junction. The bulge indicated by the scissor is one of the cecal tonsils.

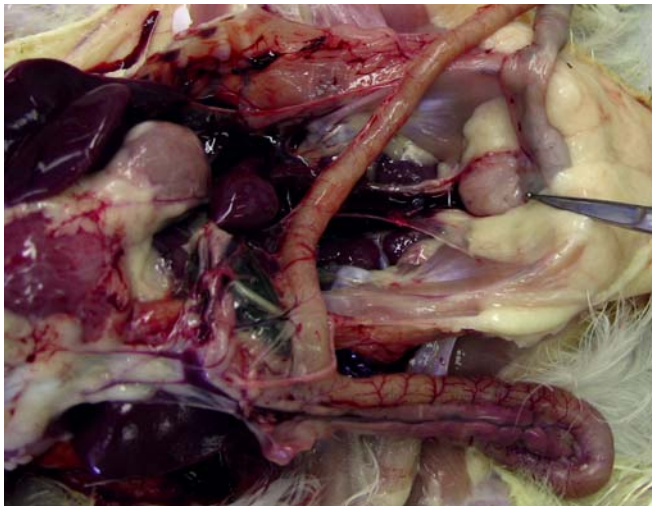


Fig.16.23: Bursa of Fabricius (cloacal bursa). It is located dorsally to the rectum at its junction with the cloaca.

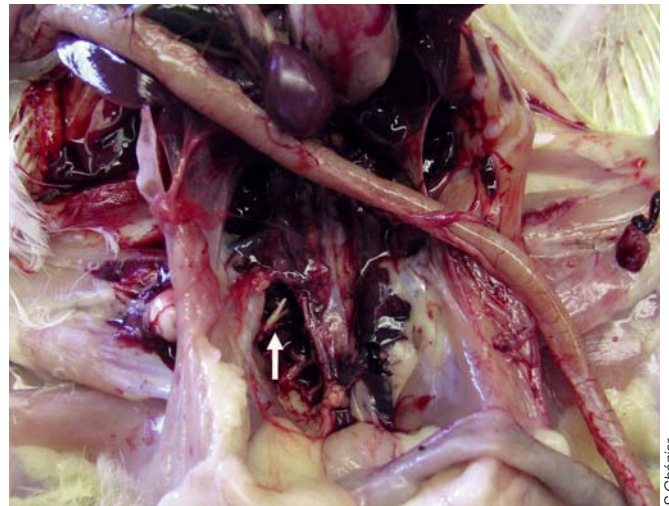


Fig.16.24: Sciatic plexuses (only the right one is visible in this picture and indicated by an arrow). The kidneys must be carefully removed to visualize them.

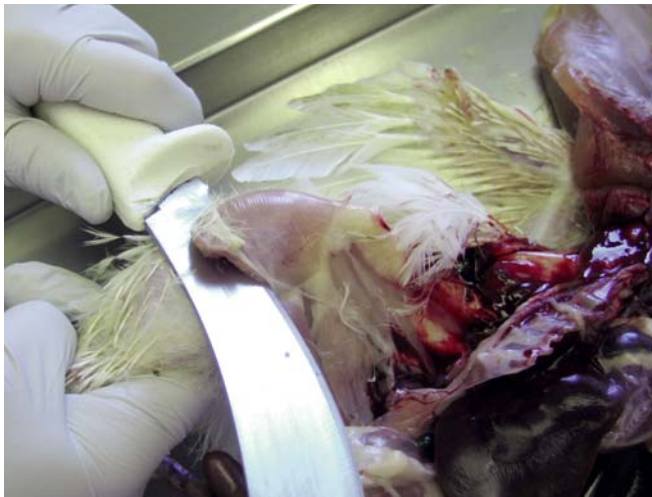

Fig.16.25: Opening of the knee joint. The knife should be positioned in a 45 degree angle with the head of the tibiotarsus.

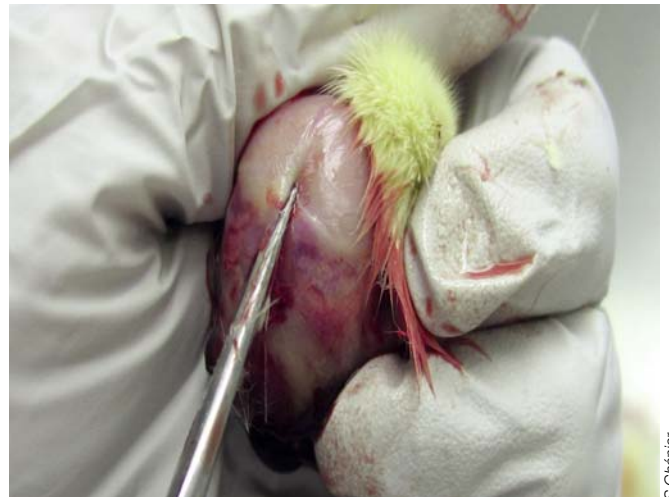

Fig.16.26: Opening of the skull. Cut and gently remove bone fragments with a scissor and forceps.

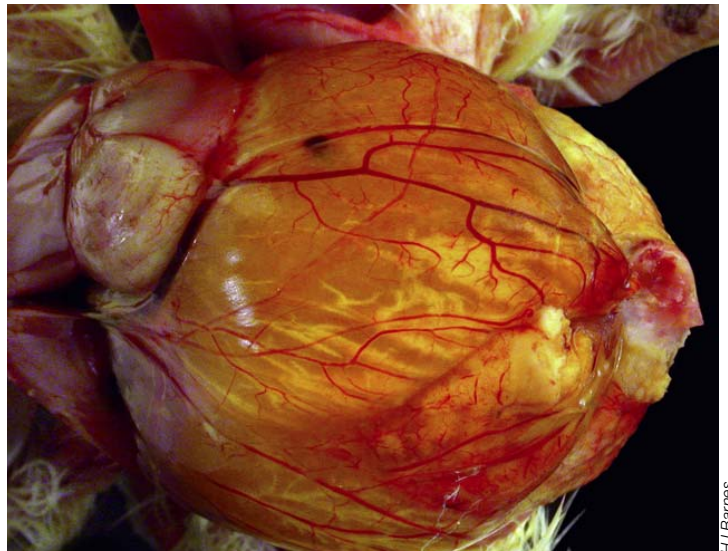
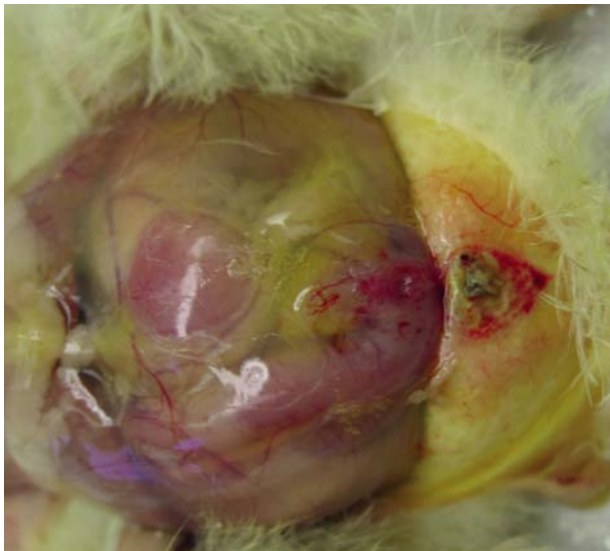

Fig.16.27 & 16.28: Navel. The navel must be examined routinely in young birds because it may be a point of entry for some bacterial infections when the umbilicus is not closed at birth (immature at hatching). On the right, a 3 day-old chick with omphalitis associated with a yolk sacculitis.

Open the proventriculus and the gizzard, and evaluate their content and their mucosa. Take a longitudinal section including both stomachs for histology. If not already done, examine the content of the intestines and take at least a section of the duodenal loop with the pancreas for histology. Examine the bursa of Fabricius (cloacal bursa) located dorsally at the junction between the rectum and cloaca. Evaluate its size and then fix one-half in formalin and, if necessary, keep the other half for other diagnostic tests. Open and examine the cloaca.

Separate the head from the neck and lift the skin of the head forwards. Open gradually the cranium with forceps or scissors, starting at the foramen magnum. Examine the brain *in situ* and then remove it. Cut it longitudinally in two parts and put one-half in formalin and, if necessary, use the other half for other diagnostic tests.

Then examine the myoarthroskeletal system. Try to break a femur to assess its solidity: except for a young bird less than a week-old, it should resist and break sharply. In a very young or a juvenile bird, bevel the proximal tibiotarsus with a sharp knife or scalpel to evaluate at the same time the knee joint, the metaphysis and the color of the bone marrow. If an exudate is present in the joint, swab it as aseptically as possible. Put the piece of the proximal tibiotarsus that was cut in formalin

for histology. Look at the other joints as well as the footpads and take samples if necessary. Examine the leg muscles and take samples if necessary. If a locomotor problem is reported, especially in chickens, examine the sciatic nerve located caudally to the femur, between the two adductor muscles. If necessary, take it and stretch it carefully on a piece of a tongue depressor or cardboard, let it dry for one minute then put both in formalin (to keep the nerve straight during fixation).

Other systems may be examined more closely for signs of disease, according to the history provided with the birds. Each case submitted for necropsy is unique and samples should be collected based on clinical signs and lesions. However, we must routinely find the following organs in formalin: brain, trachea, lung, air sac, heart, liver, spleen, kidney, pancreas/duodenum, bursa of Fabricius. In adult females, add the ovary and a portion of the oviduct. In a young bird, add the yolk sac, the thymus and the proximal tibiotarsus.

REFERENCES

Charlton BR et al. Necropsy of the fowl. In "*Avian Diseases*", American Association of Avian Pathologists, Athens 2006, pp.232-233.
Bermudez AJ & Stewart-Brown B. Disease prevention and diagnosis. In "*Diseases of poultry*", Blackwell Publishing, Ames Iowa 2008, pp.35-42.

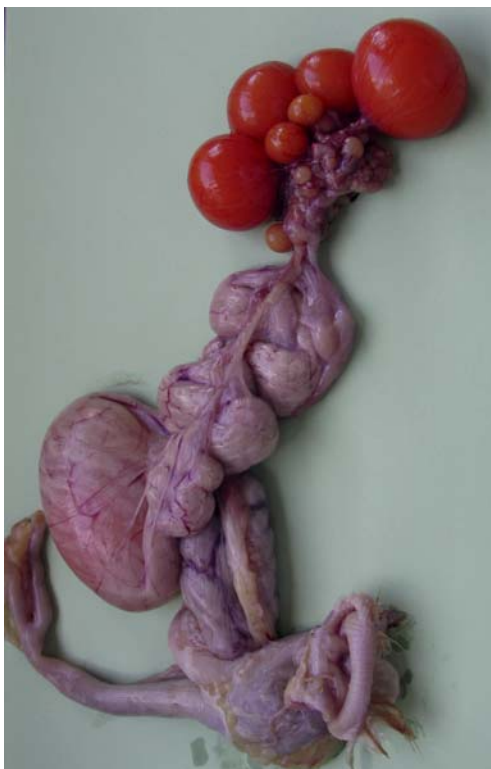

Fig.16.29: In adult females, observe ovarian and genital tract.

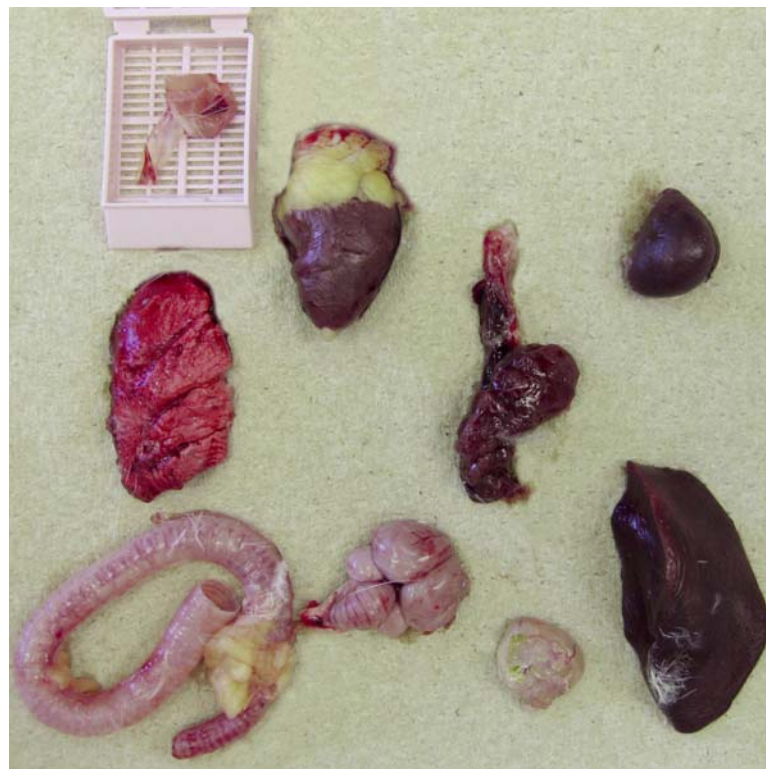
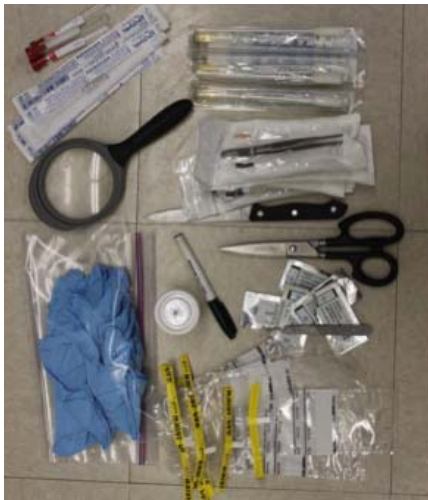
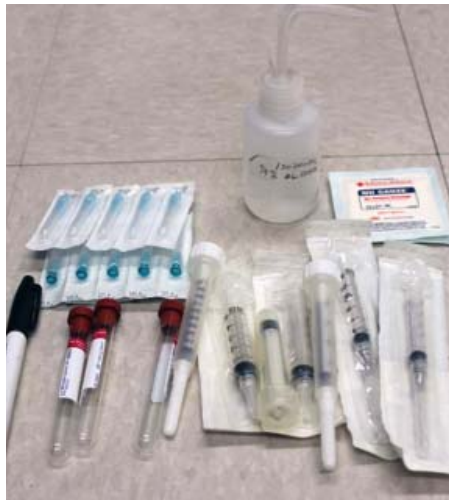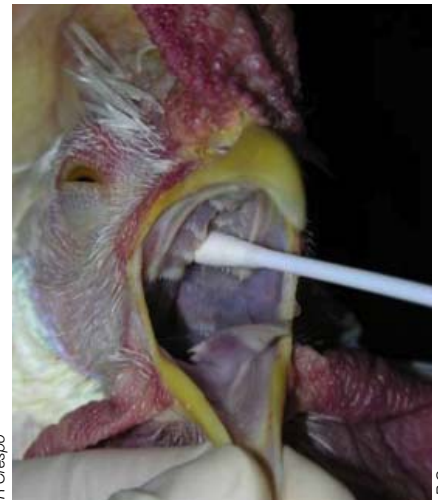Fig.16.30: Tissue taken for routine microscopic examination: brain, heart, trachea, lung, air sac (in a casket), liver, kidney, spleen, bursa.



R Crespo



R Crespo

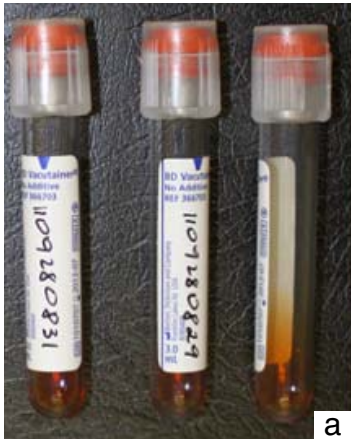

R Crespo

Fig.17.1: Recommended supplies for tissue collection include swabs, tubes with media (e.g., Stuart's Medium without additives, brain heart infusion or BHI broth), disposable Q-tips, knives, forceps, knife, scalpel blade, 10% formalin, sealable plastic bags or screwed top-lid jars, magnifying lens.

Fig.17.2: Recommended supplies for blood collection include different size syringes (e.g., 1, 3, 6 ml), needles (21-25 gauge), blood collection tubes, gauze, 70% alcohol, and marker.

Fig.17.3: Sampling the choanal slit.

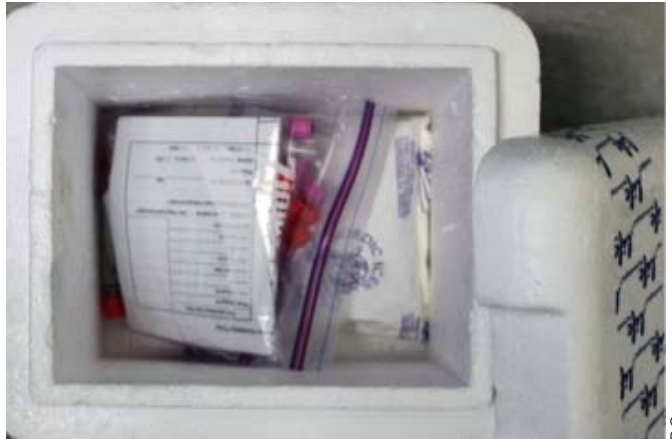

a

b

R Crespo

Fig.17.4: Blood samples for immunologic test are collected in tubes that have no anticoagulants, such as red top (a) or conical snap-top (b) tubes.



R Crespo

Fig.17.5: Place samples in a leaked proofed bag. Then place it in a secondary container with ice packs. It is also recommended that the secondary container is in an outer box. Include laboratory submission with appropriate information such as farm name, flock id, history, test(s) requested and a list of it samples submitted.

Procedure Title	
Procedure Version/Revision	
Procedure Author	
Name of responsible person	
Location of Procedure	
Purpose	
Materials and Equipment	
Safety / Precautions	
Storage and disposal of Samples	
Step-by-Step Procedure	
Calculations and Interpretation of results	
Limitations	
References and additional documentation	

R Crespo

Fig.17.6. Template for a testing standard operating procedure.

17. DIAGNOSTIC LABORATORY

INTRODUCTION

Diseases that affect birds have a wide range of overlapping clinical signs and visible lesions. In most cases, samples need to be submitted to a diagnostic laboratory in order to provide a definitive diagnosis and identify the causative agent. This is especially important when a foreign or notifiable disease, such as avian influenza, Newcastle disease, or infectious laryngotracheitis is suspected.

Laboratory techniques and instruments used by the avian diagnostician are numerous and can be quite sophisticated. Accuracy of the results often depends on the quality of the samples submitted. An avian diagnostician interprets the clinical and laboratory results to determine the cause of disease. Once the cause of disease is determined, a clinician can provide recommendations about treatment and prevention of other birds at risk. This chapter provides basic guidelines for sample collection, packing, and laboratory techniques for diagnosis of avian diseases.

SAMPLE COLLECTION

In the field a variety of samples may be collected, including blood, swabs, and tissues samples. Ideally, live and freshly deceased birds should be submitted to the laboratory. In most cases live birds would have to be hand delivered, as most commercial couriers only accept carcasses. In order to slow down decomposition of dead birds, wet all the feathers on the body with soapy water. Place the carcass in a sealed bag and refrigerate as soon as possible. Do not freeze the carcasses unless it is going to take longer than 5 days after death to be delivered. Freezing produces some artifacts, but a decomposed carcass is worse.

If the necropsy is performed in the field the examination should be done away from housed birds to reduce the risk of spreading infection. The selected location also should have easy access to water for cleaning and disinfection after the necropsy is completed.

In commercial poultry, it is common to perform postmortem examinations on 5-10 birds that have been randomly selected from the flock for health monitoring. A standard set of samples submitted for health monitoring may include blood serum samples

for serologic testing, oropharyngeal or cloacal swabs for viral and bacterial detection, swabs and fresh tissues from trachea, air sac, lung, liver, and/or spleen for viral and bacterial detection, and fixed in 10% formalin tissues for histopathology.

In sick flocks, it is important to select birds with typical clinical signs. If the main problem is increased mortality, without any other sign, choose birds that have died recently for the necropsy examination. In disease investigations, it is important to examine tissues with gross lesions and to test other samples without lesions, blood and swabs to confirm the diagnosis and rule out other possible problems.

Blood samples for immunologic tests are collected aseptically in sterile, red top, vacutainer® tubes, separator tubes, or other non-EDTA/heparin tubes. For maximum serum yield, do not fill the tubes to more than one third their capacity, and lay the tubes containing freshly drawn blood on their sides. Once the blood has clotted, the serum can be processed from the clot and sent to the laboratory, or the tubes containing clotted blood can be sent to the laboratory. Submit a minimum of 0.3 ml (300 µl) of serum per test, or 1-3 ml of clotted blood depending on the number of tests requested. Refrigerate the serum or clotted blood until shipment. Do not freeze serum or clotted blood.

Swabs from choana, oropharynx, and cloaca may be submitted for the detection of pathogens by molecular methods or isolation of microorganisms.

PACKING

The second step for a successful diagnosis is to ensure that adequate plans and arrangements are made for the packing, transport and submission of samples to the lab. It is critical to limit leaking, cross contamination and potential confusion of sample identity and integrity.

All submitted specimens must be properly packaged and shipped according to the shipping regulations, including labels to indicate hazardous materials, dangerous goods or potentially infectious materials. As the shipper, it is your responsibility to adhere to these regulations. Following these regulations also helps that the specimens arrive to the laboratory in good condition optimizing diagnostic results.

TRAINING RECORD												
Trainee Name				Hire date								
Laboratory section				Laboratory								
SOP number, Job task, Skill or equipment Operation	Review of SOP or Work Instructions Complete?				Performance Under Direct Supervision				Verification of Final Competence to Perform Procedure			
	Date	Trainee Initials	Trainer's Initials	Date	Satisfactory (check one)	Unsatisfactory	Trainer's Initials	Date Completed	Approved to Perform Procedure (check)	Date	Verified By	Competency Level (A,B,C or D)
					<input type="checkbox"/>	<input type="checkbox"/>			<input type="checkbox"/>			<input type="checkbox"/>
					<input type="checkbox"/>	<input type="checkbox"/>			<input type="checkbox"/>			<input type="checkbox"/>
					<input type="checkbox"/>	<input type="checkbox"/>			<input type="checkbox"/>			<input type="checkbox"/>
					<input type="checkbox"/>	<input type="checkbox"/>			<input type="checkbox"/>			<input type="checkbox"/>
					<input type="checkbox"/>	<input type="checkbox"/>			<input type="checkbox"/>			<input type="checkbox"/>

Competency rating
 A = Competent and authorized to train, assess other's competency, release results to clients and verify test in VADDS
 B = Competent and authorized to train, assess other's competency
 C = Competent and can perform independently
 D = May require review of procedure or assistance

R Crespo

Fig.17.7. Records are part of the quality assurance program. Example of training form.

Equipment Temperature Record Log										Year:
Equipment:			Equipment ID No:							
Location:			Desired Temperature Range*:							
Month	January		February		March		April		May	
Day	Record	Initials	Record	Initials	Record	Initials	Record	Initials	Record	Initials
1										
2										
3										
4										
5										
6										
7										
8										
9										
10										
11										
12										
13										
14										
15										
16										
17										
18										
19										
20										
21										
22										
23										
24										
25										
26										
27										
28										
29										
30										
31										
Weekly Supervisor Review										

R Crespo

* If temperature is outside required range, notify Laboratory Manager

Fig.17.8. Records are part of the quality assurance program. Example of temperature records.

Place sample(s) in a sealed primary container (e.g., plastic bag). Wrap the primary container in sufficient dry absorbent material (e.g., cotton) to absorb liquid contents in case of breakage and place enough cushion to avoid breakage. Formalin fixed specimens may be shipped in a plastic specimen jar containing a 10:1 (liquid to tissue) volume of formalin. Alternatively, adequately fixed specimens may be removed from formalin; wrapped with formalin saturated gauze or paper towels; then placed in a leak-proof plastic bag.

Place the primary container in a secondary container (e.g., styrofoam box) with refrigerated or frozen commercial coolant packs to keep specimen(s) cool and minimize bacterial overgrowth. Include a completed laboratory submission form (e.g., submitter's name, farm name and address, flock id, history, test(s) requested, and itemized list of contents) between the secondary container and the outer box. Place submission forms in separate sealed bag to prevent it from being contaminated.

LABORATORY QUALITY STANDARD

Quality standards are being required to ensure that the laboratory information is accurate, reliable and reproducible, with the goal of standardization of test and to limit variation of results within and between laboratories. The International Standards Organization (ISO) develops and publishes international standards of laboratory quality management. ISO document 17025 is the

main standard for diagnostic laboratories worldwide. These standards are reflected in the essential requirements for accreditation by the American Association of Veterinary Laboratory Diagnosticians (AAVLD), which accredits diagnostics laboratories in the United States and Canada.

The accreditation requirements are available at <http://www.aavld.org/assets/Website/aavld%20requirements%20v6%2010-10-11.pdf>.

The quality programs consist of two parts: Standard Operating Procedures (SOP) and Quality Assurance (QA). The SOPs include not only the testing procedures, but also the media/reagent and equipment used for the analyses. Media/reagent SOPs include instructions in how to prepare and how to perform quality control (e.g., sterility and support of growth). Equipment SOPs comprise instructions for the use the equipment, its regular maintenance and calibration. Maintenance of records for all the activities performed in the lab is part of the QA. These records include personnel training, maintenance and calibration of equipment, validation of tests and materials used, as well as preventive and corrective procedures. Maintain temperature records of all incubators, refrigerators, and freezers to prevent spoilage of reagents, media, and samples. Check temperature at least once daily. An electronic temperature data tracker may be use to collect temperatures throughout the day.

Department	Serology	Type	kit
Product	Lot number	Start date	End Use Expiration Date
IBD (bursal) ELISA	09260-Dg048	9/21/2011	4/1/2012
IBV (bronchitis) ELISA	09262-DG044	5/11/2011	3/15/2012
NDV ELISA	09263-CG816	9/21/2011	3/7/2012
PRV IgB	09732-EG223	9/1/2011	5/2/2012
PRV IgI	06121-FG450	9/1/2011	11/8/2012
Tecra-Listeria ELISA	17210002A	6/1/2011	1/12/2012
Tecra-Salmonella ELISA	18211055	1/26/2012	1/30/2014
Type	media		
Product	Lot number	Start date	End Use Expiration Date
AGID BASE	020M0075	2/3/2011	2/3/2016
Sodium Chloride	TH21AZEMS	9/29/2011	9/1/2021
Type	reagent		
Product	Lot number	Start date	End Use Expiration Date
AE antigen	1E080930	10/7/2008	
AE antiserum	E0115	10/7/2008	
AI antigen (AGID)	300-1103	4/6/2011	
AI antiserum (AGID)	305-1103	4/6/2011	
AI negative (AGID)	905 ADV 1002	2/15/2011	
AI pos serum (AGID strong)	902 ADV 1002	2/15/2011	
AI pos serum (AGID weak)	903 ADV 1201	12/2/2011	12/30/2013
MG aggl. Antigen-HI	100-	1/19/2011	

Reagent	Lot # and expiration date	Date Start Use	Date End Use	Manufacturer
LSB	0A0014 07-30-11	12/2/11	12/4/11	BioRad
XLT4 Agar	0118647, 4/2015-131	12-7-10		Difco
R/Broth	Vm08560003 01/04/15	05-24-10	12/13/10	EMD
LSB	0A0014 07-30-11	12/14/10	12/27/10	Bio Rad
BPW	Vm14932017 04-16-15	12/15/10	12/16/10	EMD
BPW	Vm14932017 04-16-15	12/16/10	12/24/10	EMD
BPW	Vm14932017 04-16-15	12/24/10	02/10/11	EMD
LSB	0A0014 07-30-11	12/22/10	01/07/11	BioRad
LSB	0A0014 07-30-11	01/07/11	01/20/11	BioRad
T, Hama	0118412 09-30-14	01/20/11	03/04/11	Difco
LSB	0A0014 07-30-11	01/24/11	02/01/11	Bio Rad
R. ceram Agar	101914 FEB 2012	1-26-11		Acumedia
LSB	0A0014 07-30-11	02/01/11	02/24/11	BioRad
LSB	0A0014 07-30-11	02/07/11	02/17/11	Bio Rad

Fig. 17.9. Records are part of the quality assurance program. Example of media/reagent tracking.



Fig.17.10: Label all reagents made in house and perform quality testing.

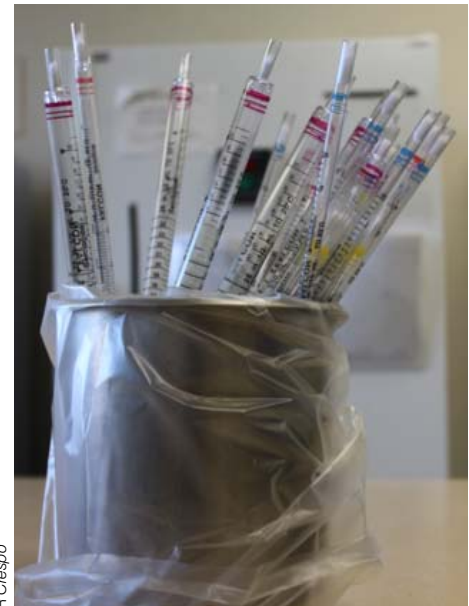

Fig.17.11: Dispose of pipettes and used material properly to avoid contaminations.

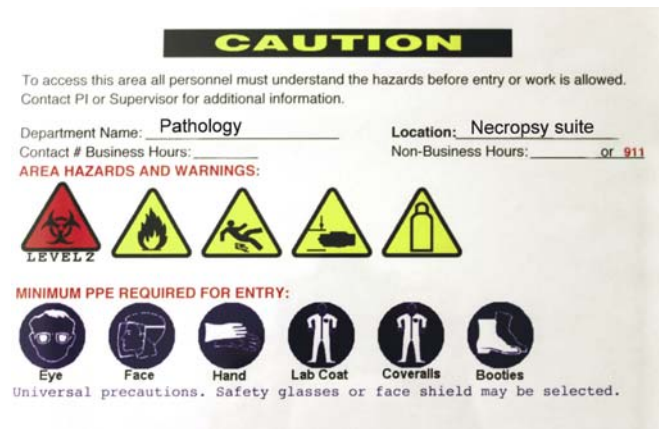

Fig.17.12: Laboratories should post warnings of hazardous areas as well as hazardous substances or conditions and recommended personal protective equipment.



Fig.17.13: Maintain the working area clean to prevent contamination of samples.




Fig.17.14: A biosafety cabinet (BSC) removes particles from the environment, protecting materials in the work area of the cabinet from environmental contamination. BSCs also contain potentially infectious particles within the cabinet to prevent contamination of workers, material or samples kept outside this area. Maintain the working area uncluttered to optimize airflow. All BSCs need to be inspected periodically to assure of proper airflow and particle filtration.




Fig.17.15: Prevent cross-contamination of reagents and controls by maintaining them in different holding spaces.

LABORATORY BIOSECURITY & BIOSAFETY

The avian diagnostic laboratory should operate under standard biosafety criteria. Although some avian procedures can be conducted at biosafety level 1, biosafety level 2 is desirable because some avian pathogens may cause disease in humans. Biosafety level 3 may be required for some pathogens that may have lethal consequences in humans; in some countries level 3 may be required if the disease has devastating consequences in animals and may be used as biological weapons (e.g., velogenic Newcastle disease virus, highly pathogenic avian influenza). Laboratory workers should be informed about the risks and trained in proper procedures performed in the laboratories. Display warnings of hazardous areas and recommended personal protective equipment to wear.

Manage each step of the process to prevent contamination. Follow biosecurity protocols to prevent contamination of samples. Maintain clean working areas, such as tabletops and biosafety cabinets. Do not mix clean materials with samples. Biosafety cabinets of adequate rating and other specialized cabinets or hoods should be maintained and fully functional. Dispose of dirty materials properly to avoid contamination of working surfaces or samples. Decontaminate working areas with suitable disinfectant at the end of each work period.

TESTING METHODS

Detection and characterization of infectious pathogens have advanced substantially in the recent years. Classical methods include isolation and characterization of the pathogen and immunologic assays such as agglutination. Today some diagnostic assays take advantages of technology to detect organisms without the need of isolation. This diagnostic technology in addition to be sensitive and specific allow to process a large number of samples in a short time.

When setting up a test, plan ahead as much as possible. If specific media or reagents are needed to perform the test, make sure that they are the correct type and that sufficient amounts are available.

Make sure that any equipment needed is in proper working conditions and with qualified personnel to perform the test. Also know how soon test results are required.

Screening assays provide presence or absence of specific pathogen, but normally they do not fully characterize the microorganism or presence of other potentially pathogenic microorganisms.

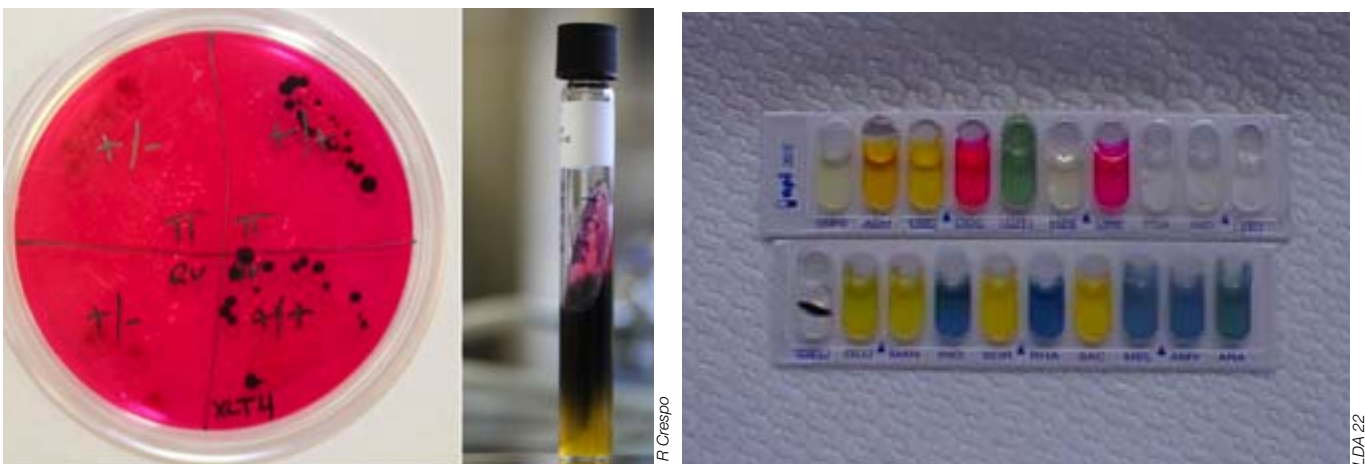


Fig.17.16 & 17.17: Classical methods include isolation and characterization of bacteria.




Fig.17.18: Classical methods include also immunologic assays such as agglutination test.



Fig.17.19: Many modern diagnostic assays are used as screening test to provide information of the presence or absence of specific pathogens, but normally they do not fully characterize the microorganism or presence of other pathogenic microorganisms. Some need little equipment investment, such as lateral flow.

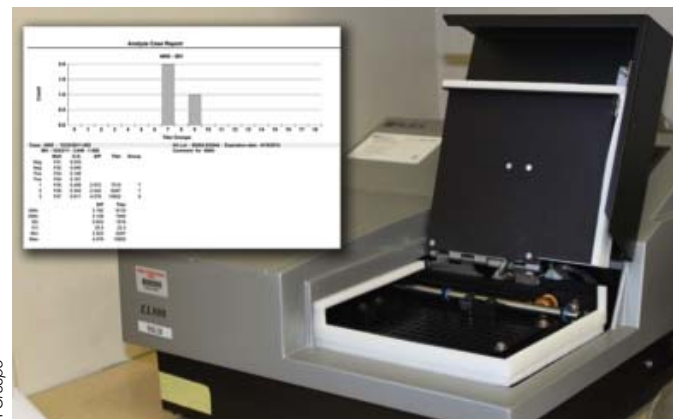


Fig. 17.20 & 17.21: Other modern diagnostic assays require expensive equipment, such as polymerase chain reaction or PCR (Fig.17.20) or enzyme linked immune assay or ELISA (Fig.17.21).

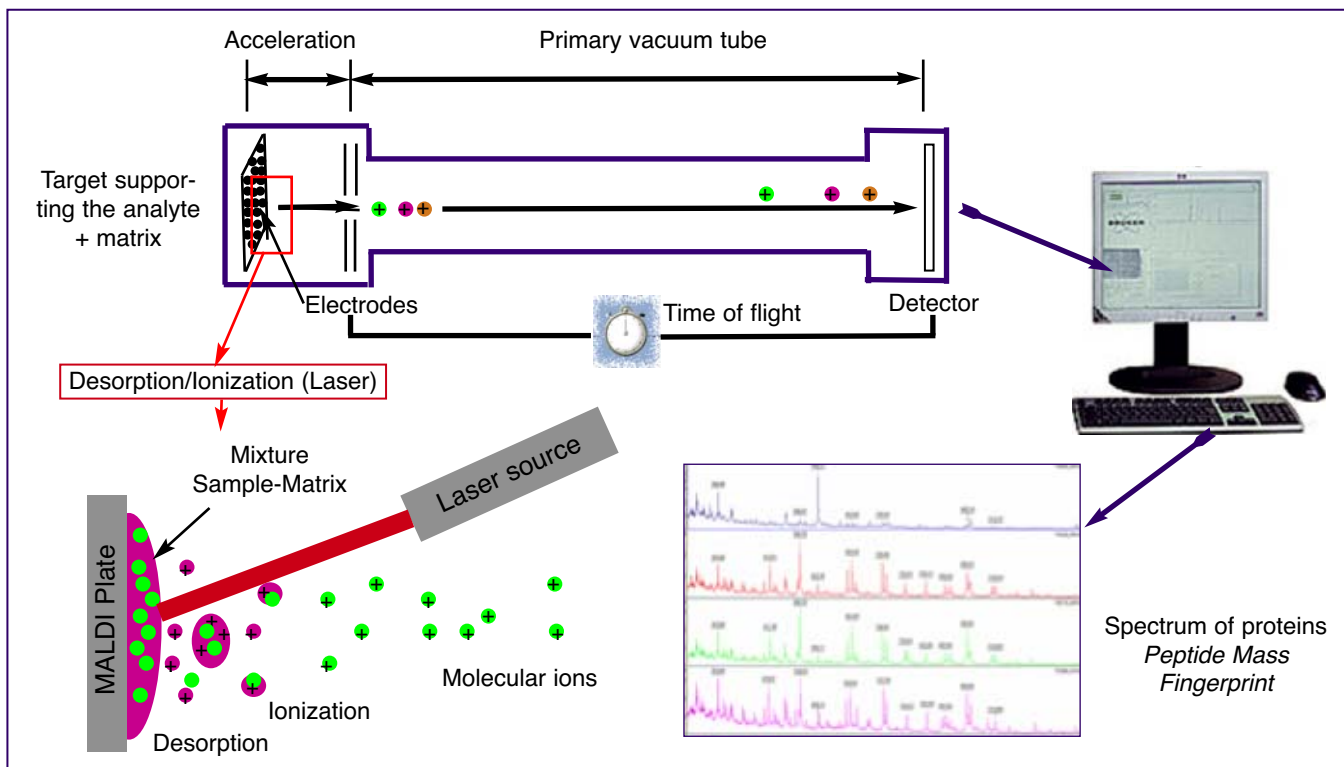


Fig.17.22: Matrix-Assisted Laser Desorption Ionization Time-of-Flight Mass (Maldi-Tof) Spectrometry requires expensive equipment but with the advantage of a large database, a quick test requiring minimal consumables and low waste (according to LDA 22).

DISEASE REPORTING

The isolation and identification of certain pathogens carries the responsibility of reporting to regulatory official (local, state/provincial, or federal). Some diseases need to be reported internationally to the World Organization for animal Health (OIE). The OIE has established guidelines for disease reporting in order to facilitate international trade in animals and animal products. A list of current reportable diseases is kept on the OIE web site at <http://www.oie.int/animal-health-in-the-world/>. Laboratory diagnosticians usually report to the next level of authority in their organization. Erroneous reporting, misidentification or failure to identify an agent may carry serious consequences. When needed, consult with the appropriate reference laboratory about agent identification.

REFERENCES

Barger K. A guide for poultry sample collection and lab submission. In: *A Practical Guide for Managing Risk in Poultry Production*. Owen, RL Ed. American Association of Poultry Pathologists, OmmiPress, Madison, WI. p199-211.

Hoerr FJ. Diagnostic principles. In: *A Laboratory Manual for the Isolation Identification, and Characterization of Avian Pathogens*. 2011, 5th edition. Dufour-Zavala L et al (Eds). American Association of Poultry Pathologists, 2008, OmmiPress, Madison, WI. p1-2.

Miller JM et al. *Guidelines for safe work practices in human and animal medical diagnostic laboratories*. MMWR, 2012,61:1-103. Available online: <http://www.cdc.gov/mmwr/pdf/other/su6101.pdf>

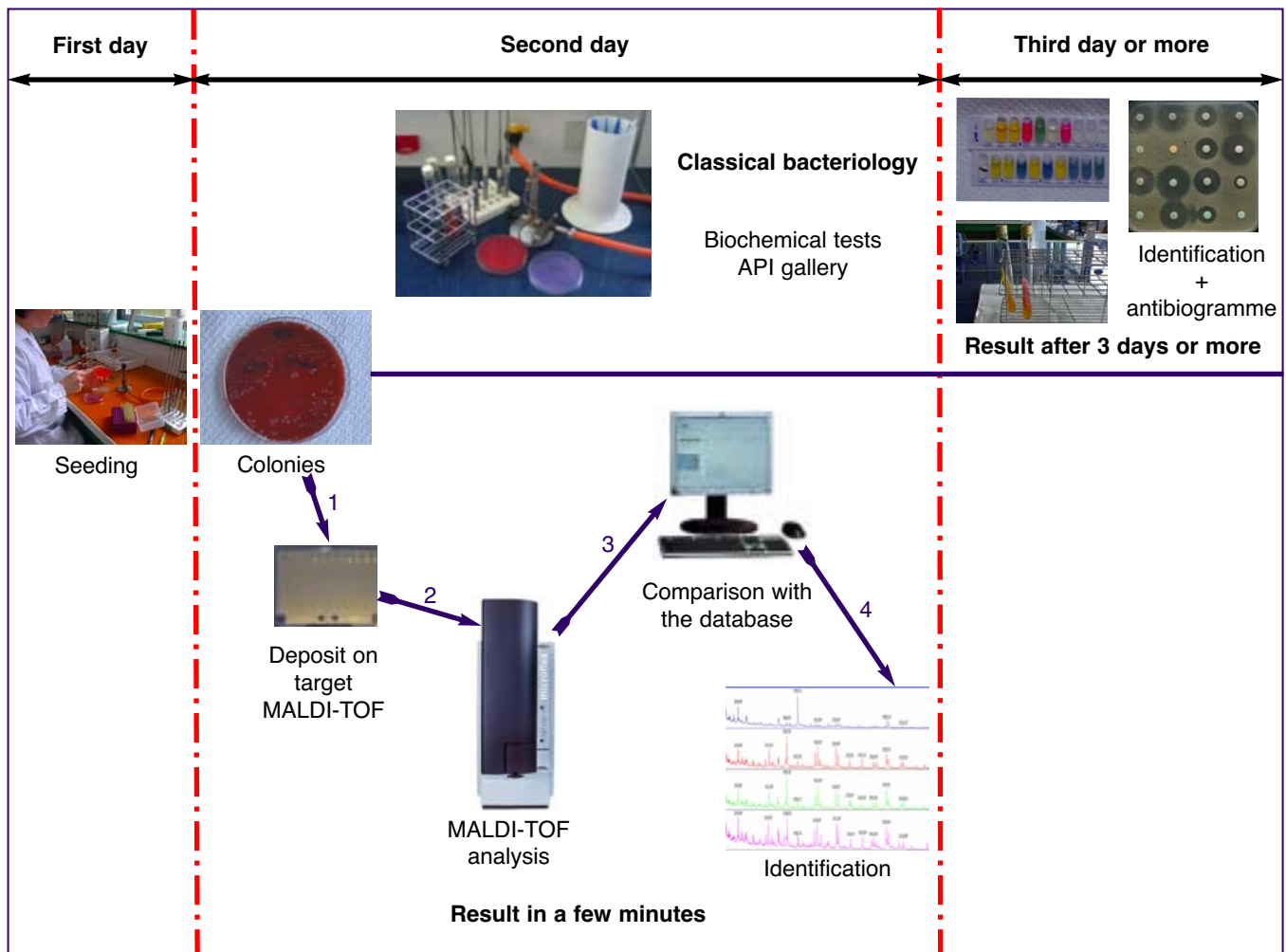
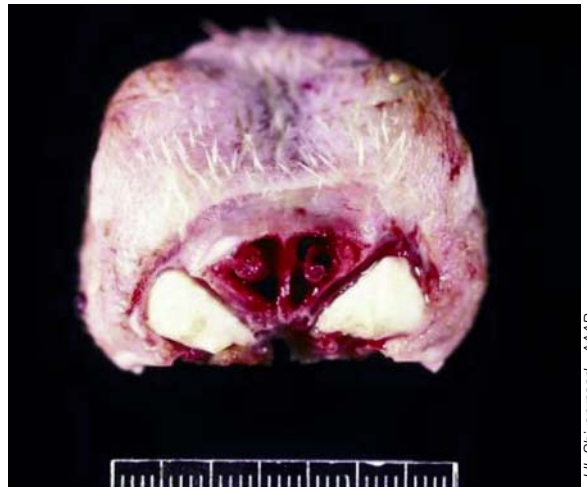

Fig.17.23: Bacterial identification. Comparison between test MALDI-TOF and classical bacteriology: with analysis by MALDI-TOF spectrometry bacterial identification requires a few minutes on the second day (according to LDA 22).

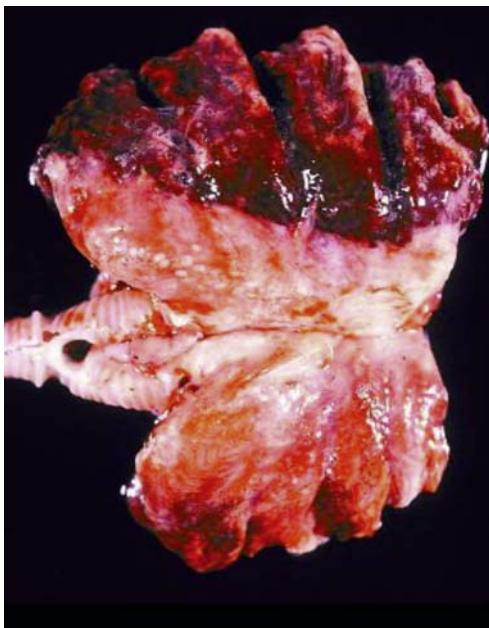


HL Shivaprasad - AAAP

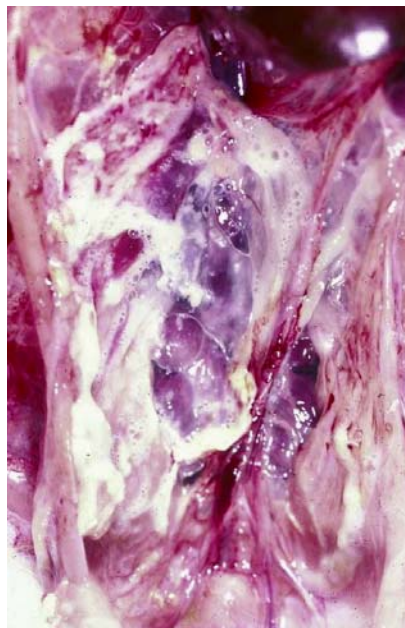


HL Shivaprasad - AAAP


Fig.18.1 & 18.2: LPAI virus (Turkey). Sinusitis.



HL Shivaprasad - AAAP



HL Shivaprasad - AAAP



H.J Barnes

Fig.18.3: LPAI virus (Turkey). Pneumonia.

Fig.18.4: LPAI virus (Turkey). Airsacculitis.

Fig.18.5: LPAI virus (Turkey). Decreased egg production and abnormal eggshell.



HL Shivaprasad

Fig.18.6: Spread of influenza from wild birds to poultry have included the mixing of domesticated and wild ducks in the same pond or ricefield.



Canadian Poultry Consultants Ltd.

Fig.18.7: Often the first sign of HPAI virus in chicken or turkey is the sudden onset of high flock mortality.

18. AVIAN INFLUENZA VIRUS

INTRODUCTION

Avian influenza virus is a problem for poultry around the world. The virus is unusual in that it can cause a range of disease symptoms from causing a subclinical infection to being highly virulent with 100% mortality. The difference between mildly pathogenic viruses and highly pathogenic viruses can be as small as a single amino acid change in the hemagglutinin gene. Therefore it is important not only to assess the ability of avian influenza viruses to cause disease in poultry, but also to assess the potential for avian influenza to cause disease in poultry. Avian influenza viruses are also unusual because the main reservoir for the virus is in wildlife, therefore complete eradication is not possible. Also, influenza, because of its broad host range, can represent a zoonotic risk. All these factors make avian influenza an important but difficult pathogen to control in our poultry population.

ETIOLOGY & EPIDEMIOLOGY

Influenza viruses are negative sense segmented RNA viruses in the family *Orthomyxoviridae*. Influenza viruses can be subdivided into three different antigenic types, A, B and C. However, only type A influenza viruses are of veterinary importance, since type B and C influenza viruses are human pathogens that rarely infects other species. Type A influenza viruses (referred to only as influenza for the rest of the chapter) have eight different gene segments that encode ten different viral proteins. They can be divided into the surface glycoproteins, the hemagglutinin (HA) and neuraminidase (NA) proteins, the membrane ion channel (M2), and the internal proteins including the polymerase complex comprised of the nucleoprotein (NP), PA, PB1, and PB2 proteins, the matrix protein (M1), and the two nonstructural proteins, NS1 and NS2. The surface glycoproteins are known to be important proteins in regard to virulence of the virus, and the antibody response to the HA and NA proteins are the most important aspect of protection from disease. The HA and NA genes also have the most sequence and antigenic variation of all the influenza proteins. The HA protein has 16 defined antigenic subtypes, H1-H16, and the NA has 9 antigenic subtypes, N1-N9. The definition of an antigenic subtype is that antibody raised against one subtype will neutralize all other viruses in that subtype, but it will not neutralize viruses from other influenza subtypes.

The nomenclature for describing influenza viruses has been standardized to be consistent for all influenza viruses. The features used to describe all new influenza viruses are 1) Antigenic type, A, B or C; 2) Host animal which the virus was isolated from. For human isolates this may be omitted and is simply implied; 3) Geographic location which the isolate came from. This can be a city, state, province or country designation; 4) laboratory or other reference ID number (since a single lab often makes multiple isolations in a year, a unique identifier number is often included for each isolate); 5) The year of isolation; 6 & 7) The hemagglutinin and neuraminidase subtypes are often included in parenthesis at the end. For example the turkey influenza virus in 1999 from Missouri would be A/Turkey/Missouri/24093/99 (H1N2).

Influenza infections in poultry, primarily chickens and turkeys, can cause clinical disease or losses in production for the affected flocks. The virus can be generally divided into viruses that cause a localized infection, often primarily restricted to the respiratory or enteric tract, and viruses that cause systemic infections. The viruses that cause localized infections are usually referred to as low pathogenic avian influenza (LPAI) viruses, and typically these viruses do not cause high mortality in affected flocks. The viruses that cause systemic infections usually cause high mortality and are referred to as highly pathogenic avian influenza (HPAI) viruses, or historically as fowl plague virus. The LPAI viruses can cause asymptomatic infections, but typically they cause mild to severe respiratory disease, that in conjunction with secondary pathogens can on rare occasions cause high mortality in a flock. The LPAI viruses can be of many different hemagglutinin and neuraminidase subtypes. The HPAI viruses, for unknown reasons, are restricted to the H5 and H7 subtypes, but most H5 and H7 influenza viruses are low pathogenic. It is only a rare occurrence that these low pathogenic viruses mutate into the highly pathogenic forms of the virus. It is generally believed that HPAI viruses arise from low pathogenic H5 and H7 viruses that have been allowed to widely circulate in poultry for extended periods of time. For example LPAI viruses circulated for over six months in many poultry flocks in both the H5 outbreak in Pennsylvania in 1983, Mexico in 1994 and the H7 outbreak in Italy in 1999 that resulted in outbreaks of HPAI that necessitated a large eradication and control effort. HPAI is not believed to be normally present in the natural wild bird host reservoir.



D Baroux- LDA 01

Fig.18.8: HPAI virus H5N1 (France, 2006) Swan with nervous signs (lateral deviation of the neck).



I Capua & F Mutinelli, Peppi éd.

Fig.18.9: HPAI virus. Nervous signs.



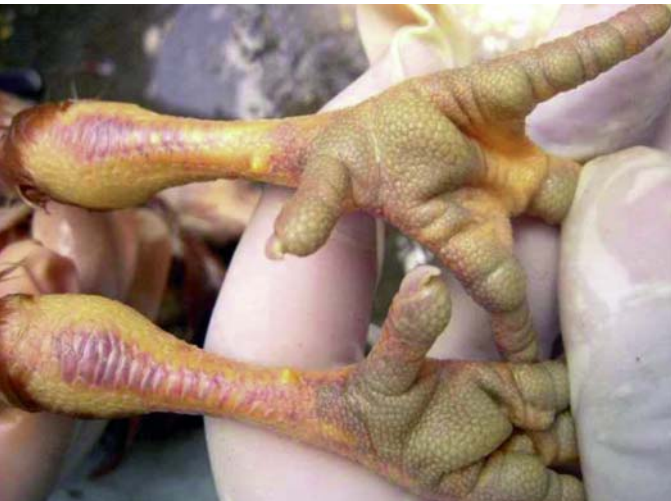MT Casaubon Huguenin

Fig.18.10: HPAI virus H5N2 (Mexico, 1994). Necrosis of comb and wattles and apathy.



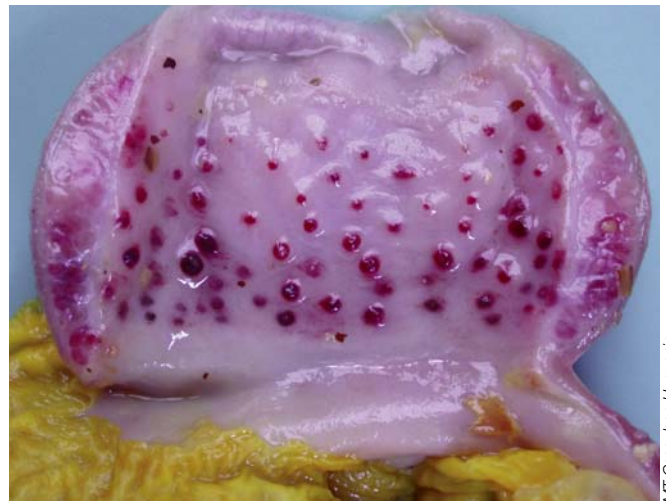
MT Casaubon Huguenin

Fig.18.11: HPAI virus H5N2 (Mexico, 1994). Conjunctivitis and edema of the head.



Ceva Santé Animale Indonésie

Fig.18.12: HPAI virus (Chicken). Sub-cutaneous necrosis of the foot pad.



MT Casaubon Huguenin

Fig.18.13: HPAI virus H5N2 (Mexico, 1994) Necrosis or hemorrhage in the mucosa of the proventriculus.

The primary virulence characteristic that separates the LPAI and the HPAI viruses is the ability of HPAI viruses to be cleaved by ubiquitous proteases on the inside of the host cell. Influenza viruses must have the HA protein cleaved into the HA1 and HA2 subunits before it can become infectious. This cleavage is necessary for the fusion domain to be activated during the uncoating step of virus replication. Normally trypsin-like proteases can cleave the hemagglutinin protein in the extracellular environment, and trypsin-like proteases are found in the lung and enteric tract. This is the primary reason that virus replication is restricted to these locations. However, when multiple basic amino acids (lysine and arginine) are present at the HA cleavage site, particularly by the insertion of multiple basic amino acids, the cleavage site becomes accessible to ubiquitous proteases, that are found in most cells of the body. The HPAI viruses' HA protein is cleaved during the assembly stage of virus replication, and therefore is infectious when it is released from the cell. This allows the virus to greatly increase the number of cell types it can infect, including cells in the brain, heart, pancreas, and skeletal muscle. The damage to critical organs or to endothelial cells lining blood vessels can cause a variety of disease symptoms that often leads to the death of the bird. Other viral genes are also thought to be important in the virulence of the virus, but the hemagglutinin cleavage site is by far the most important virulence trait.

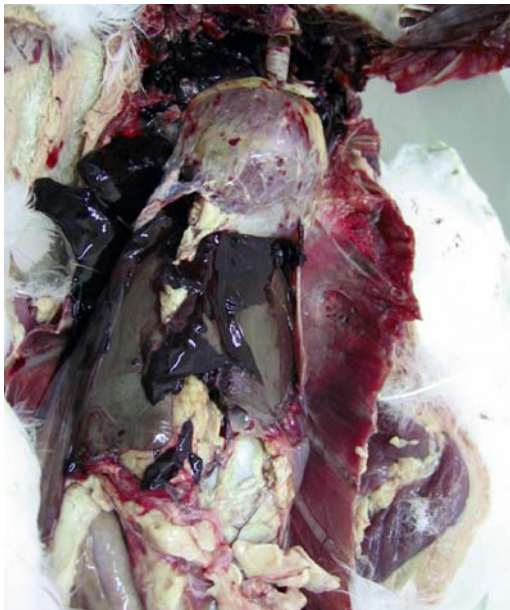Influenza viruses have a wide host range and routinely infects humans, swine, horses, chickens, turkeys and wild birds. Although influenza viruses can become endemic in all these populations, the natural host and reservoir for the virus is in wild ducks, gulls, and shorebirds. In the wild bird reservoir the virus typically causes an asymptomatic infection, and the virus appears to be well adapted to and genetically stable in this group. However, when influenza viruses cross into aberrant species, including humans, swine, horses, chickens and turkeys, the virus changes rapidly to adapt to the new host for more efficient replication and transmission. Once a particular strain of influenza circulates in a particular species for an extended period of time (years), the virus becomes increasingly species specific. So human influenza viruses do not usually infect swine, equine influenza viruses don't infect turkeys, and poultry viruses do not infect humans. However, this general rule of host adapted influenza viruses staying within a single species can be broken. For example, North American classical swine H1N1 influenza viruses

routinely cross from swine to turkeys causing costly disease outbreaks. The spread of avian influenza (H5N1 and H9N2) viruses from poultry to humans has also been observed, and therefore avian influenza viruses do present a public health threat as a zoonotic pathogen, although the risk is considered to be small.

The influenza reservoir, as previously mentioned, is in wild birds including ducks, gulls and shorebirds. All 16 HA and 9 NA subtypes of viral genes are found in wild birds, with certain types of ducks, like pintails and mallards, having the highest prevalence of infection. Some of the best documented cases of migratory waterfowl spreading influenza to commercial poultry has been in turkeys in Minnesota. In Minnesota, multiple outbreaks of avian influenza were observed every year. The viruses were of many different HA and NA subtypes and infections often corresponded to when wild ducks were migrating to or from their summer breeding grounds. The turkeys were raised outside during this migratory period, and wild ducks could fly over or actually land in the turkey pens. During the 1990's the management was changed so that Minnesota turkeys were confinement reared for their entire lives, and the incidence of influenza greatly decreased. Other examples of spread of influenza from wild birds to poultry have included the mixing of domesticated and wild ducks in the same pond, and having mixed poultry farms where one of the farmed species has access to wild birds. Therefore, many influenza outbreaks can be prevented by reducing the exposure of poultry to wild birds.

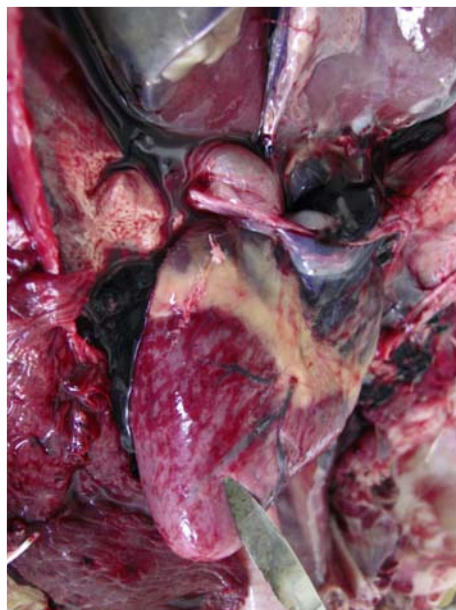CLINICAL SIGNS & LESIONS

The disease lesions with avian influenza in poultry can be extremely variable depending on the viral isolate as well as the species of the infected bird. Other factors include the presence of other pathogens, immune status of the host, age of the bird, and environmental factors. In general for LPAI viruses the disease symptoms are restricted to the respiratory and enteric tract and can include lesions in the sinuses, trachea, bronchi, lungs, airsacs, and intestines. Lesions can include mucopurulent or caseous inflammation, thickening of airsacs, edema of the serosa and other localized lesions. Evidence of enteritis may also be seen with some strains of virus. Internal lesions are rare but can include peritonitis, pancreatitis, lesions in the reproductive tract, and in the kidney. Decreases in egg production without other clinical signs are common in layers or breeders in production.



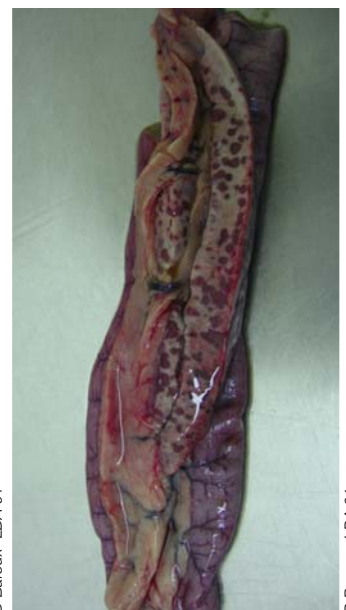D Baroux- LDA 01

Fig.18.14: HPAI virus H5N1 (France, 2006). Congestive and hemorrhagic pleuropneumonitis with blood clots in the thoracoabdominal cavity without associated traumatic lesion (Pochard).



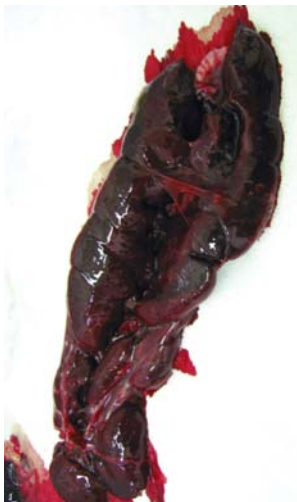D Baroux- LDA 01

Fig.18.15: HPAI virus H5N1 (France, 2006). Hemorrhagic suffusions in heart (Swan).



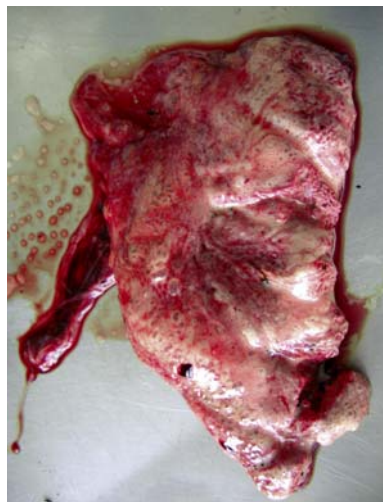D Baroux- LDA 01

Fig.18.16: HPAI virus H5N1 (France, 2006). Pancreatitis with necrosis (H5N1 positive Swan).



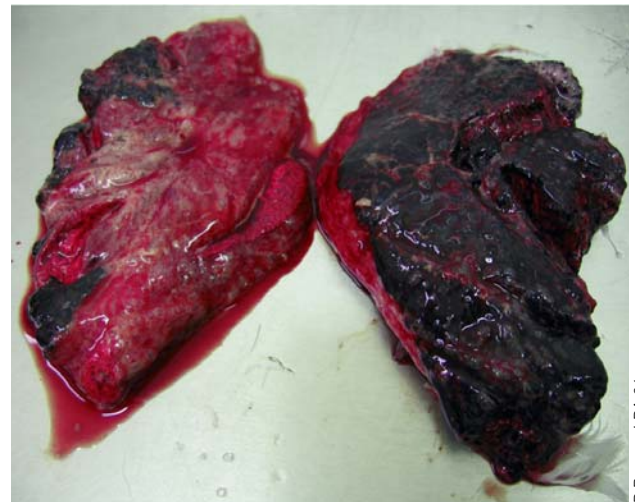D Baroux- LDA 01

Fig.18.17: HPAI virus H5N1 (France, 2006) Kidneys with hypertrophy and hemorrhages (H5N1 positive Swan).



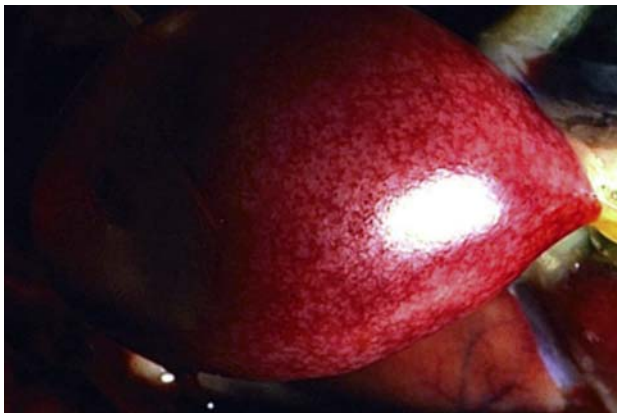D Baroux- LDA 01

Fig.18.18: HPAI virus H5N1 (France, 2006) Emphysematous and edematous lung (H5N1 positive Swan).



D Baroux- LDA 01

Fig.18.19: HPAI virus H5N1 (France, 2006). Pulmonary hemorrhages (H5N1 positive Swan).



/ Capua & F Mutinelli, Papi éd.

Fig.18.20: HPAI virus. Necrotic foci in spleen.



/ Capua & F Mutinelli, Papi éd.

Fig.18.21: HPAI virus. Hemorrhages of the ovarian follicles.

For HPAI viruses a number of different lesions can be observed depending on the viral strain. For some viruses that experimentally kill rapidly (less than 24 hours in I.V. inoculated birds) few lesions are often observed. For example the rapid killing virus, A/Chicken/Hong Kong/97, causes primarily edema in the lungs leading to hypoxia and eventually death. Most HPAI viruses kill the birds slower and produce a variety of disease lesion. The most obvious external lesions are hemorrhage and necrosis in the combs and wattles, hemorrhage in the legs and feet, swelling in the sinuses, conjunctiva and periorbital lesions. Other gross pathology lesions with HPAI viruses include petechial hemorrhages in a number of different organs and necrotic foci in the liver, spleen, kidneys, pancreas and lung. Histologically, replication of influenza virus with direct cellular damage and apoptosis, particularly in lymphoid organs, are observed throughout the body. No lesions are pathognomonic for HPAI, and other pathogens need to be considered, particularly velogenic Newcastle disease virus.

DIAGNOSIS

Virus isolation is often necessary to fully characterize an influenza virus outbreak in poultry. The virus is typically cultured in embryonated chicken eggs, but it can also be grown in several cell culture systems. Virus is typically first tested for the ability to hemagglutinate chicken red blood cells. If the virus hemagglutinates, it must be differentiated from other hemagglutinating viruses, including Newcastle disease virus, and typically is confirmed by an agar gel immunodiffusion test (AGID). The influenza virus is then further characterized by the subtyping of the hemagglutinin and neuraminidase proteins using inhibition tests using defined antibodies. Currently, animal testing is also required to determine if a virus is to be considered highly pathogenic. The standard pathotyping test for influenza is to inoculate 8 specific pathogen free chickens, 4-6 weeks of age, by I.V. inoculation and observe for death of the birds within 10 days postinoculation. If 75% or more of the birds die within 10 days, the virus is considered highly pathogenic. If the virus is an H5 or an H7 virus, the hemagglutinin cleavage site is also sequenced to determine how many basic amino acids are present. If a virus is highly pathogenic by standard pathotyping or has extra basic amino acids at the cleavage site it usually will be considered for eradication.

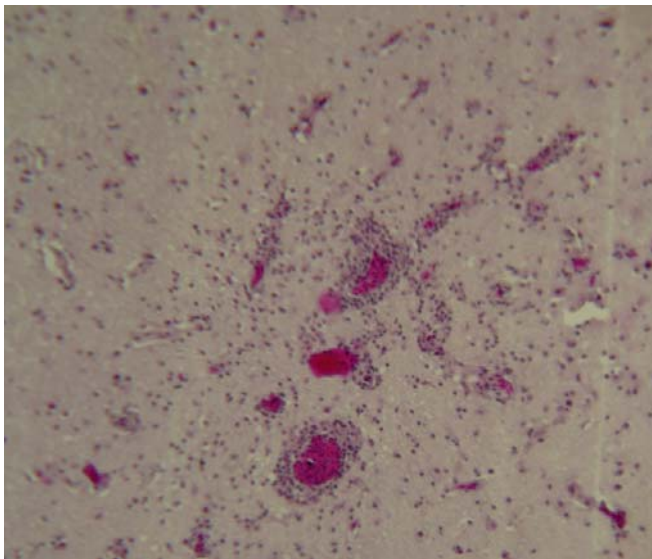
Serology can also be used to identify flocks that have been exposed to avian influenza virus. The most common tests are the agar gel immunodiffu-

sion (AGID) tests and the commercial ELISA tests. The AGID test detects antibody to both the nucleoprotein and matrix 1 (M1) proteins that are conserved for all type A influenza viruses. The commercial ELISA tests detect only antibody to the nucleoprotein. Both tests are commonly used in diagnostic laboratories and can usually detect infection in a flock within a week of the initial infection. Serum samples can also be used to determine the HA and NA subtypes of the virus by using the hemagglutination and neuraminidase inhibition tests. Both tests require testing the samples against a bank of reagents for all 16 hemagglutinin and 9 neuraminidase subtypes, and therefore it is only commonly done at large regional or national reference centers.

TREATMENT & CONTROL

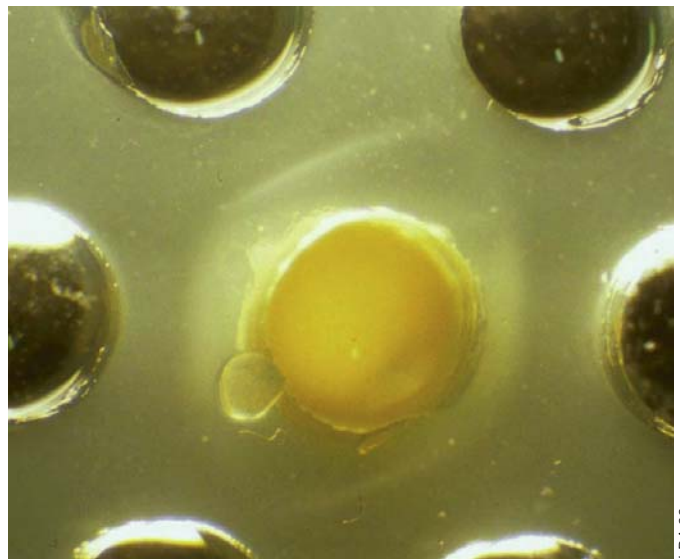
Control strategies for avian influenza virus infections in poultry are dictated by whether the virus is highly pathogenic or likely to become highly pathogenic or if it is a low pathogenic virus. Standard control measures for any AI outbreak include quarantine of the infected flocks and usually a quarantine zone around the infected flocks. Secondly, increased biosecurity by greatly restricting access of personnel and equipment to and from farms in the quarantine zone. Third, increased surveillance on surrounding farms to monitor for evidence of spread of influenza infections. For outbreaks of HPAI, infected flocks are depopulated, often with disposal of the birds by burning or burial on the farm. For LPAI outbreaks, the outcome of the infected flocks varies, but often the infected birds are allowed to recover from infection and then are marketed with special precautions. The majority of a flock will often become infected in the first few weeks after the virus is introduced, and movement of birds during this time of peak viral shedding, even to slaughter, carries a high risk of spreading the infection to susceptible flocks. Currently, vaccination is not a part of the control efforts for HPAI outbreaks. One of the primary concerns is that birds that are naturally infected with influenza and birds that are vaccinated with killed whole virus vaccines cannot be distinguished based on standard serologic tests, because both the AGID and the ELISA tests rely on detection of nucleoprotein antibodies, and birds vaccinated with killed vaccines will have high NP antibody levels.

For LPAI outbreaks in the United States, the control of the outbreak is left to the individual states. Control of LPAI outbreaks uses the standard control measures, but vaccines are often used to



D Baroux- LDA 01

Fig.18.22: HPAI virus H5N1 (France, 2006). Non suppurated meningoencephalitis in PCR negative swans: the standard protocol can be inadequate for the detection of infected but not excreting birds.



LDA 22

Fig.18.23: Avian influenza virus is confirmed by an agar gel immunodiffusion test (AGID).



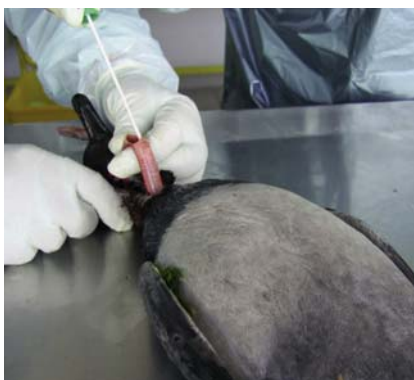Canadian Poultry Consultants Ltd.

Fig.18.24: HPIA virus H7N3 (Canada, 2004). After identification of infected flocks, elimination of infected birds is essential to preventing future transmission.



Canadian Poultry Consultants Ltd.

Fig.18.25: HPIA virus H7N3 (Canada, 2004). Control policies require legislative enforcement to be effective.



D Baroux- LDA 01

Fig.18.26: Surveillance of tracheal and cloacal HPAI or LPAI virus excretion in wild birds is important for the control of avian influenza.



FAO

Fig.18.27: Net for protection against contact with wild birds is necessary for backyard flocks.



FAO

Fig.18.28. IAHP: Live birds markets are important in the epidemiology of AIHP virus.

supplement these control efforts for non-H5 or non-H7 viruses. Because of the potential for H5 and H7 viruses becoming highly pathogenic, vaccination for these subtypes of viruses have been restricted so as not to interfere with surveillance efforts. To overcome the inability to distinguish vaccinated and naturally infected birds, sentinel birds are usually placed with the vaccinated flocks to monitor for virus circulation. The vaccines, which are subtype specific, are often effective at preventing or reducing the disease symptoms within a flock and vaccination is believed to reduce transmission of the virus by decreasing the amount of virus replication in the birds. Influenza vaccines, however, do not prevent birds from being infected with avian influenza, but they usually are effective at preventing or reducing clinical disease. Influenza vaccines must be subtype specific, since little or no cross protection is observed between influenza subtypes. Protection from influenza infections is primarily from neutralizing antibody to the hemagglutinin gene. Antibodies to the neuraminidase protein can also be protective against viral challenge, but it usually provides less protection than antibody to the hemagglutinin gene. Cell mediated immunity can also provide some protection against avian influenza virus infections including some protection between subtypes, but the cell mediated immune response usually is not rapid enough to be consistently protective, particularly against a HPAI challenge.

Currently only two types of vaccines are available for use in poultry, a killed whole virus adjuvanted vaccine and a live vectored recombinant vaccine. The killed whole virus recombinant vaccine uses embryonated-egg grown virus that is adjuvanted with an oil-emulsion and administered either intramuscularly or subcutaneously. This vaccine produces good humoral immunity, but no cellular immunity. Because of the adjuvants used, the vaccines usually have a long withdrawal period, which can severely limit how they can be used. The whole virus killed vaccines are available for most hemagglutinin subtypes. The recombinant vaccines are vaccines using a *Fowlpox virus* vaccine strain or the *Herpesvirus* turkey (HVT) as a vector in which the hemagglutinin gene from influenza virus is inserted. When the vaccine is administered the fowlpox virus or the herpes virus will produce both fowlpox proteins or herpes protein and influenza hemagglutinin proteins that the host mounts an immune response to. The host will therefore develop protection against both influenza and the vector. This vaccine has several potential advantages. First, it produces both cellular and humoral immunity. Second vaccinated birds can be

distinguished from naturally infected birds since vaccinated birds will not have NP antibody because the vector only contains the hemagglutinin gene. One drawback for the fowlpox vectored vaccine is that birds previously exposed to the fowlpox virus will not develop antibodies to influenza. Finally, only the H5 subtype of influenza is currently available with the fowlpox vectored vaccine. But there may be problems if birds have immunity to the vector vaccine.

For human influenza vaccinations, the vaccine must be updated on a yearly basis because antigenic drift of the virus reduces the effectiveness of the vaccine. Although avian influenza viruses have a similar antigenic drift and independent influenza poultry outbreaks can be extremely variable in amino acid sequence, this variability does not affect vaccine efficacy like it does with human influenza vaccines. In general, the closer the amino acid similarity of the vaccine strain is to the challenge strain, the greater the reduction in virus replication and viral shed. The protection from disease is still high, even for divergent vaccine and challenge strains, but a greater reduction in virus replication should provide better protection from the virus spreading to uninfected birds or flocks.

REFERENCES

- Halvorson DA et al. Epizootiology of avian influenza: Effect of season on incidence in sentinel ducks and domestic turkeys in Minnesota. *Applied Environ Microbiol*, 1985,49:914-919.
- Horimoto T & Kawaoka Y. Pandemic threat posed by avian influenza A viruses. *Clin Microbiol Rev*. 2001,14:129-149.
- Lamb RA & Krug R. Orthomyxoviridae: the viruses and their replication. In: Fields, Knipe, & Howley (eds) *Fields Virology* 3rd ed. Philadelphia, PA. Lippincott-Raven Publishers 1996.
- Perdue ML et al. Avian Influenza in the 90's. *Poultry Avian Biol Rev*, 2000,11:1-20.
- Steinhauer D. Role of hemagglutinin cleavage for the pathogenicity of influenza viruses. *Virology* 1999,258:1-20.
- Suarez D.L. Evolution of avian influenza viruses. *Vet Microbiol*, 2000,74:15-27.
- Suarez DL & Schultz-Cherry S. Immunology of avian influenza: a review. *Develop Comp Immunol*, 2000,24:269-283.
- Swayne, DE et al. Influenza. In: Swayne DE, et al. (eds.), *Isolation and identification of avian pathogens*, pp.150-155. Kennett Square, PA, AAAP 1998.
- Swayne DE et al. Vaccines protect chickens against H5 highly pathogenic avian influenza in the face of genetic changes in field viruses over multiple years. *Vet Microbiol*. 2000,74:165-72.

Prototype virus strain	Usual natural hosts	Disease produced in poultry
APMV-1 (<i>Newcastle disease virus</i>)	Numerous	Very variable, from mild to severe disease depending on the strain and the infected host
APMV-2/chicken/California/Yucaipa/56	Turkey, chicken, passererines	Moderate respiratory infection and mild egg drop ; aggravation of the disease is possible
1.APMV-3*/turkey/Wisconsin/68	Turkey	Moderate respiratory infection but severe egg drop; aggravation of the disease is possible
2.APMV-3*/parakeet/Netherlands/449/75	Psittacines, passerines	None described
APMV-4/duck/HongKong/D3/75	Duck, geese	None described
APMV-5/budgerigar/Japan/Kunitachi/74	Budgerigars and birds related	None described in poultry
APMV-6/duck/HongKong/199/77	Duck, geese, turkey	Moderate respiratory infection and slight increase in mortality in turkeys; no clinical signs in ducks and geese
APMV-7/dove/Tennessee/4/75	Pigeon, dove	Moderate respiratory infection in turkeys; infection recorded in ostriches
APMV-8/goose/Delaware/1053/76	Duck, geese	None described in poultry
APMV-9/domestic duck/New York/22/78	Duck	None described

Tabl.19.1: The avian paramyxoviruses (APMV) (*adapted from Alexander & Jones, 2008*).
 *Serological tests may distinguish between turkey and psittacines isolates.

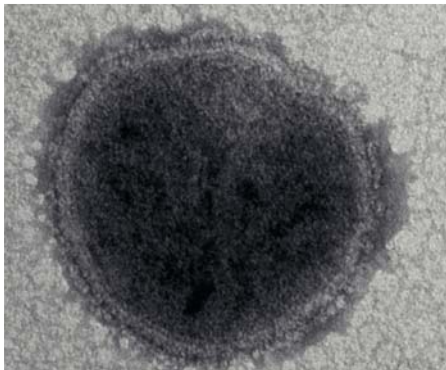


Fig.19.1: Newcastle disease virus: electronic microscopy, negative coloration.

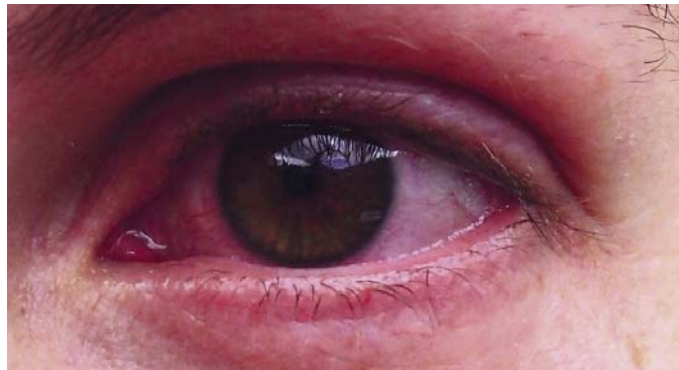

Fig.19.2: Newcastle disease is a minor zoonosis generally resulting in conjunctivitis.



Fig.19.3, 19.4. & 19.5: Respiratory disorders may be serious as is the case of velogenic strains. Notice the dyspnea of the bird in Fig.19.4.

19. NEWCASTLE DISEASE & OTHER AVIAN PARAMYXOVIRUSES

INTRODUCTION

Newcastle disease (ND) or pseudo-plague is a viral disease affecting wild and domestic birds. It is characterized by a high variability in morbidity, mortality, clinical signs and lesions. Newcastle disease primarily affects chickens and turkeys, but most poultry and many wild and domestic birds are susceptible. Since its initial isolation in 1926, the ND virus (Newcastle disease virus or NDV) has been isolated from poultry and wild birds in most countries. In addition, many isolates were originating from a very large variety of birds comprising 117 species belonging to 17 of 24 Orders of the Class Aves. Although the virus has been isolated from many different bird species, there is, at present, no evidence of the existence of natural reservoirs. Ducks, both domestic and wild, may carry viral strains but these are generally nonpathogenic for chickens. Based on epidemiological data collected from exotic birds in quarantine, it appears that highly pathogenic strains are endemic in South American psittacine birds.

The economic impact of ND is huge and should not be measured solely in terms of direct losses (mortality). In developed countries free of the disease, control measures such as vaccination and repeated testing to maintain their free status represents a huge loss for the poultry industry. In developing countries where eggs and poultry meat constitute the main source of food proteins, the endemic presence of NDV constitutes a significant impediment to the development of their poultry industry.

In terms of public health, along with its contribution to malnutrition (by limiting access to animal proteins), ND is considered a minor zoonosis. Transmission to humans is anecdotic and results in ocular infection, such as conjunctivitis, eyelid edema and watery eyes. Headache and fever are sometimes observed, with or without conjunctivitis.

ETIOLOGY & EPIDEMIOLOGY

Newcastle disease virus is an enveloped virus which is part of the recently described genus *Avulavirus* belonging to the family *Paramyxoviridae*. This family of viruses is characterized by an unsegmented single-stranded RNA of negative polarity and a nucleocapsid showing a helical symmetry surrounded by an envelope derived from the plasma membrane of infected cells. This envelope is spiked with spicules of two different glycoproteins: hemagglutinin-neuraminidase (HN) responsible for the attachment of the virus on cellular receptors and F glycoprotein inducing fusion of the viral envelope with the cell membrane and allowing penetration of the nucleocapsid and viral RNA into the cell. All avian paramyxoviruses agglutinate red blood cells of birds and most easily replicate in the allantoic or amniotic compartments of embryonated eggs. Nine different serotypes of avian paramyxovirus, designated PMV-1 to PMV-9, can be distinguished on the basis of hemagglutination inhibition tests (HI tests).

The nomenclature used to describe them is similar to that of influenza virus (e.g., PMV-2/chicken/California/Yucaipa/56). Different strains of NDV belong to serotype PMV-1 but antigenic variations can be identified within the group, mainly by using monoclonal antibodies. Similarly, a large genetic diversity is associated with the spatio-temporal origin as well as host species of different strains. So, the sequencing of the fusion F protein gene has identified at least six distinct lineages of NDV (lineages 1 → 6) while the complete genetic analysis of the genome revealed the existence of two major divisions, namely Class I and II, which second class can then be subdivided into eight genotypes (genotype I → VIII). These genetic variations could affect the antigenicity and thus the effectiveness of vaccination campaigns.

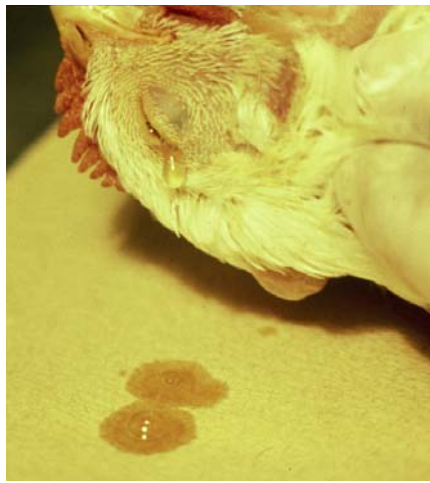

Fig.19.6 & 19.7: Newcastle disease. Facial edema and conjunctivitis with ocular exsudate.

Fig.19.8: Infected chickens often have signs of cyanosis with dark, discolored combs.

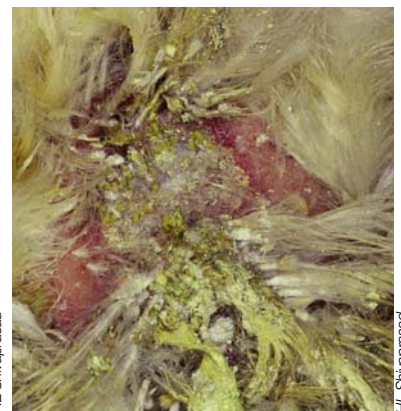
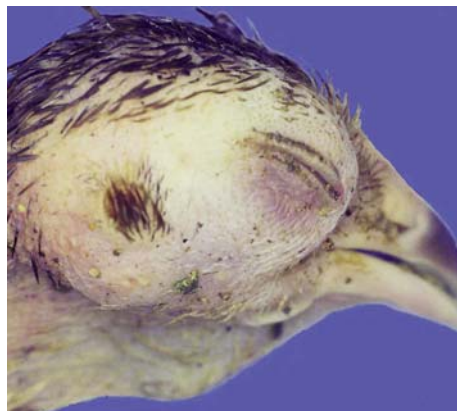
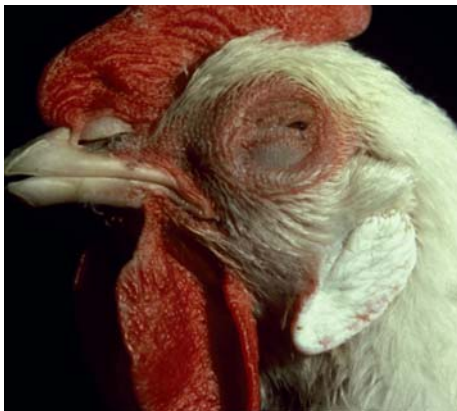
Fig.19.9 & 19.10: Facial edema associated with periocular swelling.

Fig.19.11: Diarrhea, pasting of feces on and around the cloaca.

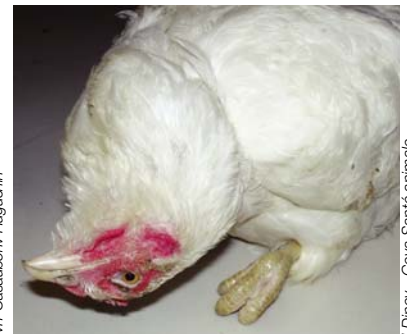

Fig.19.12, 19.13, 19.14 & 19.15: Clinical aspects of encephalitis found in Newcastle disease. Nervous disorders result in a stiff neck.



Fig.19.16, 19.17 & 19.18: Newcastle disease (Pigeon, chicken). Paralysis. Note the clenched fingers in Fig. 19.16.

Newcastle disease virus transmission between poultry occurs through fecal-oral route. Following replication of NDV in their respiratory and/or digestive tract, infected birds shed the virus through aerosol and/or droppings. Droplets and contaminated aerosol can then be inhaled by healthy birds and affect the mucosa of their upper respiratory tract, while droppings can contaminate feed and drinking water and thus be eaten by other birds in the house. The dispersion of the virus may also be from farm to farm via the transportation of contaminated material (soil, litter, equipment). Indeed, although it is an enveloped virus, NDV is relatively stable outside the host and can survive for several days or even months, in the presence of organic material, depending on temperature and surrounding moisture. This mode of transmission explains why a case of ND can quickly develop into an epidemic.

Newcastle disease is endemic across most parts of Africa, the Middle East, Asia, Central America and northern South America. In more developed regions, such as Western Europe and the USA, sporadic outbreaks are still observed, despite the widespread use of vaccines. Epidemiological studies have shown that several outbreaks of ND have occurred since the first described cases of the disease. Firstly, genotypes II, III and IV have been endemic in North America, Asia and Europe, respectively, during the 30s and 40s. Genotype VI strains then emerged as epidemic in the Middle East and Asia during the 60s while those of the genotype V have arisen in North America and Europe in the early 70s. The fourth epidemic occurred during the 90s in the Middle East following the prevalence of genotype VII. Genotype VIII has been endemic in South Africa during the last decade. Newcastle disease virus strains currently circulating worldwide are essentially viscerotropic.

CLINICAL SIGNS & LESIONS

Clinical signs depend on the pathogenesis of the disease. This results from the complex interaction of numerous factors influenced by the biological, biochemical and genetic characteristics of the viral strain and by the susceptibility of the host. The disease follows the multiplication of the virus, its spread throughout the body, its replication in cells carrying out vital functions and the destruction of these cells. The different strains of PMV-1 are classified into five pathotypes based on the clinical signs observed in susceptible chickens:

- Velogenic viscerotropic strains cause high mortality (up to 100%) associated with characteristic intestinal damage.
- Velogenic neurotropic strains also cause very high mortality (up to 100%) associated with respiratory and nervous disorders.
- Mesogenic strains are responsible for respiratory and nervous disorders associated with a low mortality rate in adults but a high mortality rate among young birds (up to 50%).
- Lentogenic strains cause only respiratory disorders without mortality neither in young nor adult birds.
- Lentogenic asymptomatic strains cause no clinical signs. These viruses are identified only by isolation from droppings and are often isolated from wild ducks.

This classification into pathotypes is not always clearly established and considerable variations in clinical signs can be observed for representatives of each group. In addition, viruses responsible for some outbreaks may not be clearly classified in any of the pathotypes. For example, the virus responsible for ND in pigeons in Europe since 1981 causes neurological signs without respiratory signs and is excreted in high titers in the droppings of infected chickens.

Besides the differences in pathogenicity between viral strains, variations in susceptibility are also responsible for variable clinical pictures. For example, ducks and geese are resistant to infection by the most pathogenic viruses for chickens. On the other hand, the adaptation of NDV to a particular host may affect its pathogenicity for another. Thus, PMV-1 viruses isolated from pigeons are pathogenic in chickens after several serial passages in this species. Psittacines are also frequently infected by NDV. Their susceptibility to disease varies widely. During experimental infection with a pathogenic PMV-1 strain, the observed mortality rates vary according to the species: 55 % for conures, 29 % for parrots, 25 % for canaries, 22 % for parakeets and 21 % for mynas. Parakeets, conures and mynas surviving the infection may shed intermittently the virus during several weeks while parrots sheds up to one year after infection while remaining apparently clinically healthy. In conclusion, given the wide variability of the clinical signs in infected birds, we cannot define the pathogenicity of the viruses according to the observed clinical signs but they are indicative of the gravity of the infection.

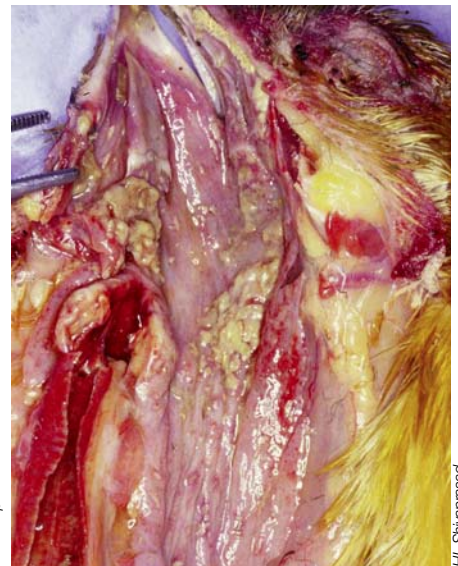
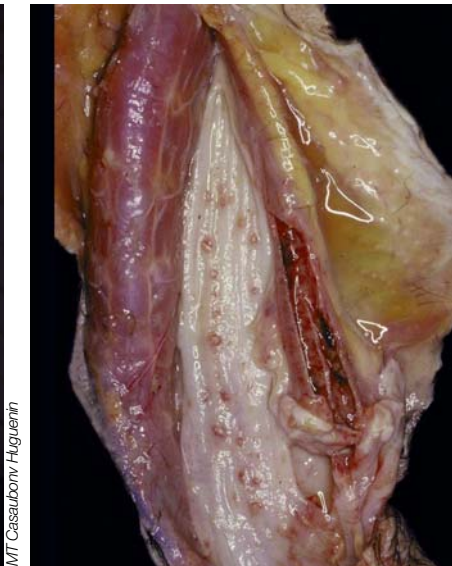

Fig.19.19: The mortality rate is important during a velogenic Newcastle disease outbreak.

Fig.19.20 & 19.21: Newcastle disease. Subcutaneous edema, fibrinonecrotic ulcers in esophagus and hemorrhage in the trachea.

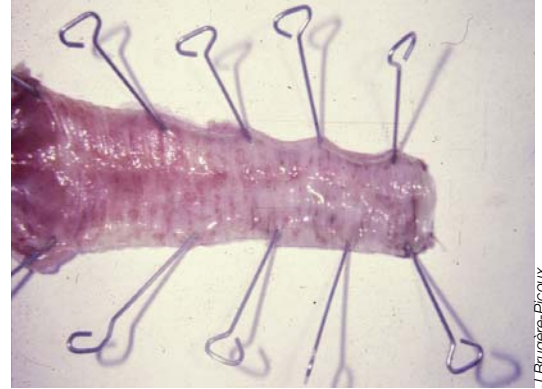
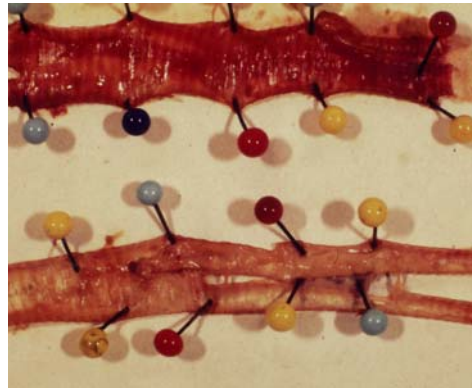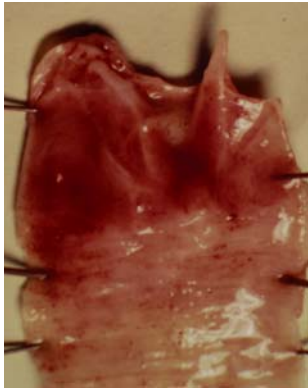


Fig.19.22: Lentogenic strain of Newcastle disease. Congestion of the larynx and petechiae in the tracheal mucosa.

Fig.19.23 & 19.24: Newcastle disease (velogenic). Hemorrhagic tracheitis.

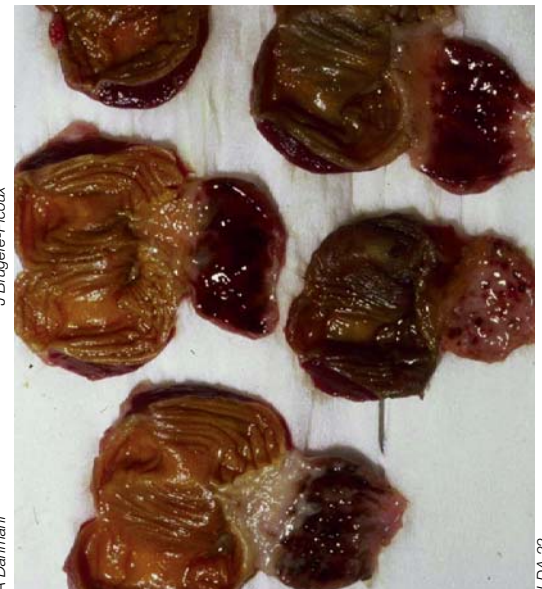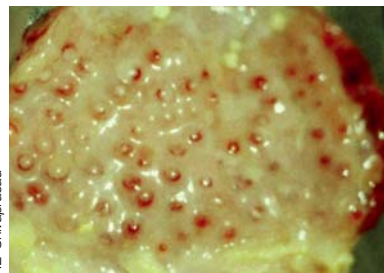
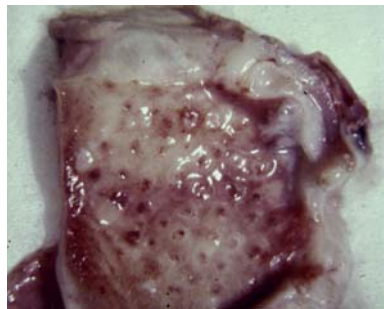
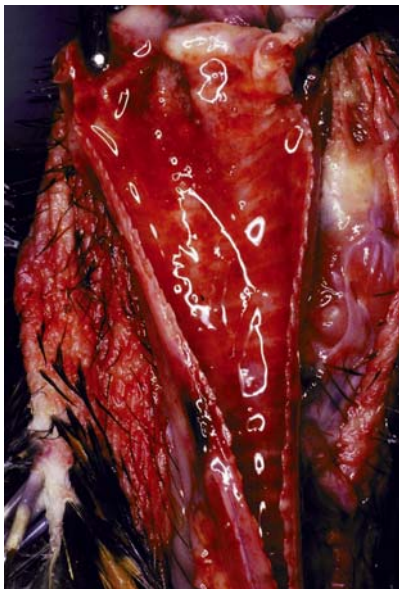


Fig.19.25: Newcastle disease (velogenic strain). Severe hemorrhage in the larynx and trachea.

Fig.19.26, 19.27 & 19.28: Hemorrhage in the proventriculus is a frequent lesion of velogenic strains of ND. But it may be absent. Hemorrhagic lesions can also be observed in the gizzard.

Different strains of PMV-1 not only vary in their tropism and pathogenicity but also in their mode of transmission. The virus causing the European epidemic of 1970-1972 had a very pronounced respiratory tropism and significant amounts of virus could be detected in the air of infected flocks, which probably caused the rapid and explosive spread of this virus. On the other hand, the virus strain responsible for 22 outbreaks in England in 1984 was mainly excreted in droppings. The absence of airborne contamination limited the spread of the virus. Excretions from infected birds (droppings, nasal discharge) can contaminate feed, water, clothes and shoes of personnel, objects and equipment. The whole environment becomes a source of infection for susceptible poultry. The eggs laid by infected breeders may occasionally contain the virus. These eggs rarely hatch. However, if they accidentally break in the hatchery, all hatched chicks could then be contaminated. These chicks are sometimes placed into different flocks allowing the spread of the virus before the disease becomes apparent. The live viruses used for vaccination are also a reservoir because vaccinated poultry can replicate and disseminate them. Finally, the import of exotic birds, in particular psittacines acting as healthy carriers of PMV-1 virus, represents a significant source of contamination. The clinical significance and pathogenicity of other avian paramyxovirus serotypes are less well known.

As the cell tropism of a virus depends on the interaction between proteins on the surface of the virus and cellular receptors, it is clearly evident that these proteins play an essential role in the pathogenicity of the pathogen. The infectivity, spread and pathogenicity of the PMV-1 viruses depend on the cleavage and activation of viral glycoproteins in many different cell types. Indeed, the rapid multiplication and dissemination of the virus in the host are the determining factors of the systemic infection caused by the pathogenic strains of PMV-1. They all have a F glycoprotein which cleavage site, consisting of several basic residues (R-X-K/R-R-F), is recognized by cellular proteases present in all the cell types of the host. On the other hand, the cleavage site of the F protein of lentogenic strains is monobasic and is cleaved only by trypsin-type proteases present in certain cell types, including epithelial cells. So, the multiplication of lentogenic strains is limited to these cells and stopped as soon as the virus reaches non permissive cells. This results in a mild disease condition. Clinical signs depend on both the pathogenicity of the infecting strains and age of infected poultry.

Lentogenic strains cause mild and transient respiratory disorders associated with growth retardation.

Mesogenic strains cause a sudden depression and anorexia in adult hens. Respiratory and nervous signs are usually observed in a small number of poultry. In layers, one notices an almost complete stop in egg-laying. Mortality is low or inexistent. On the other hand, in young chickens and chicks, mortality can be high and sometimes reaches 50%. It is preceded by severe respiratory and central nervous disorders.

Velogenic strains cause up to 100% mortality in poultry of all ages. Clinical signs depend on the tropism of the infecting viral strain. Dyspnea, diarrhea, conjunctivitis and paralysis followed by death in two to three days are often noticed. Cyanosis of the comb and wattles and periocular swelling are sometimes observed. In cases of infection by lentogenic or mesogenic strains, airsacculitis, conjunctivitis and tracheitis are occasionally observed. With velogenic strains, tracheitis lesions may be hemorrhagic. Also observed are intestinal lesions consisting of hemorrhagic or necrotic areas mainly located in lymphoid formations such as cecal tonsils and hemorrhages in the mucosa of the proventriculus and gizzard. Wild and pet birds usually do not show any specific lesion.

DIAGNOSIS

Clinical signs, lesions and the general epidemic context can often lead one to suspect ND. However, the diagnosis should be confirmed by isolation and identification of the virus. The pathogenicity of the isolated virus must then be evaluated. Paramyxoviruses are isolated by inoculation of samples (obtained from droppings/intestinal content, trachea, lungs, air sacs, spleen, brain, liver, heart and blood from dead birds) into the allantoic cavity of 9 to 11 day-old specific pathogen free (SPF) embryonated eggs. In live poultry, cloacal and tracheal swabs can be analyzed. The inoculated eggs are incubated for a maximum of 7 days and then killed. The allantoic fluid is then tested in the presence of a suspension of red blood cells (1%) in order to investigate the presence of hemagglutinin. In case of a positive reaction, it is necessary to identify the agent by a hemagglutination-inhibition test, because the hemagglutination may result from the presence of bacteria or viruses (Paramyxovirus and Orthomyxovirus). For Newcastle disease, the hemagglutination inhibition test is performed in the presence of a polyclonal

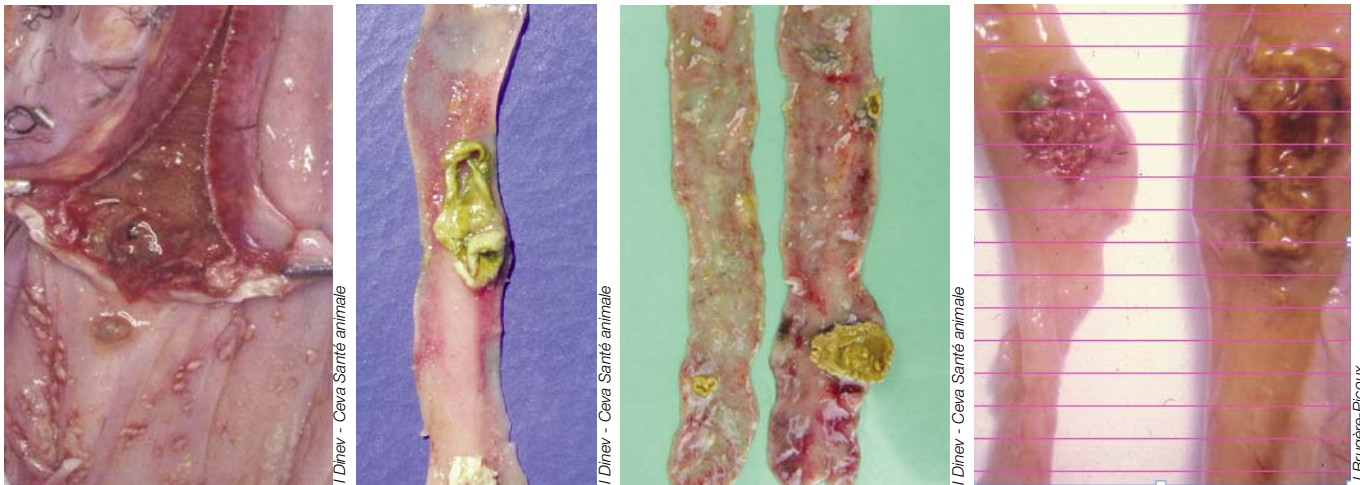


Fig.19.29, 19.30, 19.31 & 19.32: In the necro-hemorrhagic form of Newcastle disease, involvement of the gastrointestinal tract may begin in the mouth and then reach the oesophagus, stomach and intestines. Note the focal diphtheroid lesions.

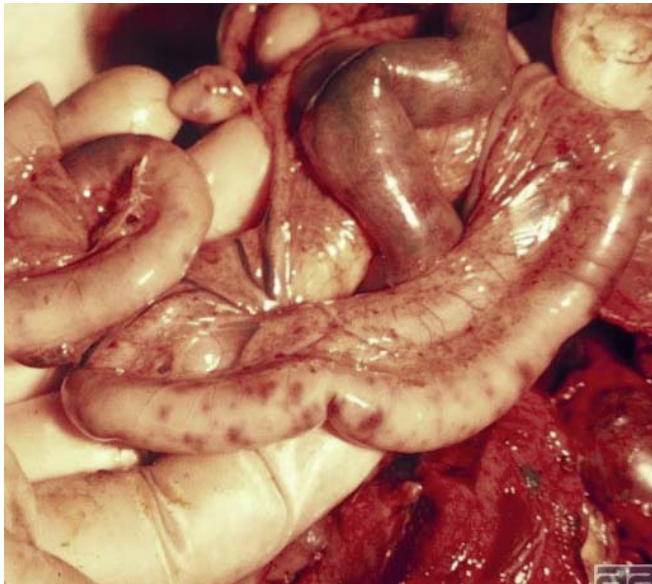

Fig.19.33 & 19.34: The intestines, such as duodenum, may show hemorrhages of variable size, mainly affecting lymphoid structures.

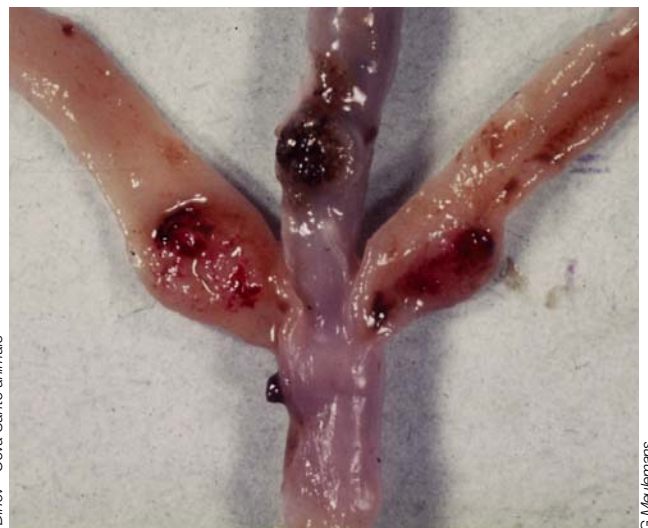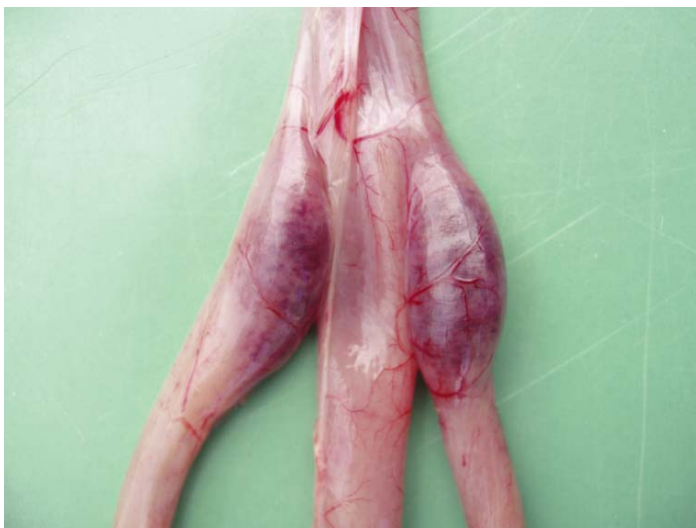


Fig.19.35 & 19.36: A variable degree of hemorrhage in cecal tonsils is frequently observed in Newcastle disease. This lesion can be seen without opening the ceca.

serum specific for PMV-1 viruses. However, cross-reactions exist between PMV-1 viruses and other avian paramyxoviruses. These antigenic relationships are particularly evident between PMV-1 and PMV-3 viruses isolated from turkeys and psittacines. The use of monoclonal antibodies inhibiting only the hemagglutination from all PMV-1 strains prevents any error in serological typing. Serological identification of other avian paramyxoviruses is based on hemagglutination inhibition tests performed in the presence of antisera specific for each serotype. These tests are performed in specialized laboratories. The pathogenicity of any isolated PMV-1 virus must necessarily be assessed either by an *in vivo* or an *in vitro* test. The European Union (EU) has made the *in vivo* test intracerebral pathogenicity index (ICPI) compulsory. It consists in inoculating by this route one day-old SPF chicks and observing them for eight days. Any strain with an IPIC above 0.7 is considered pathogenic. An *in vitro* technique, the sequencing of the cleavage site of F protein and demonstration of the presence of a specific sequence (R-X-K/R-R-F) for mesogenic and velogenic strains, is also recognized by the EU to demonstrate the degree of pathogenicity of a viral strain. Serological diagnosis of PMV-1 viral infections is done by searching for specific antibodies with the hemagglutination inhibition test. In unvaccinated or infection free birds, serological titers are lower than 1/8 when the reaction is performed with 4 viral hemagglutinating units. Higher titers mean that the birds have been vaccinated or infected. However, in psittacines and caged birds, the serological response to infection by PMV-1 is extremely variable and the absence of antibodies does not necessarily indicate the absence of infection.

TREATMENT & CONTROL

Pathogenic PMV-1 infections are classified as notifiable diseases. The isolation of PMV-1 virus with an ICPI greater than 0.7 or for which the analysis of the cleavage site of the F protein showed the presence of multiple basic residues (velogenic or mesogenic strains) must be reported to the national and international veterinary authorities. In accordance with the new definition of notifiable diseases, any isolation of these strains should be reported to the World Organization for Animal Health (OIE). The infected flocks must be destroyed and all sanitary measures required by law must be applied. Only bacterial complications seen in birds infected with low pathogenic strains can be treated with antibiotics.

Prevention of ND is based on biosecurity measures and, when necessary, the application of a vaccination program. The objectives of the various prevention strategies are to prevent the infection and to reduce the number of susceptible birds through vaccination. Biosecurity, including sanitation, is considered the first line of protection against the introduction of any pathogenic agent and in particular against ND. Thus, movement of personnel (farmers, veterinarians, technicians, etc.) and vehicles must be limited and accompanied by disinfection procedures and, in the case of people, a change of clothing and footwear, even in the absence of disease. A good biosecurity program must also prevent the direct and indirect contact of poultry with wild birds such as pigeons and waterfowl. Because of their costs, air filtration and overpressure to limit the entry of airborne pathogens in the barn are reserved for high value genetic stock.

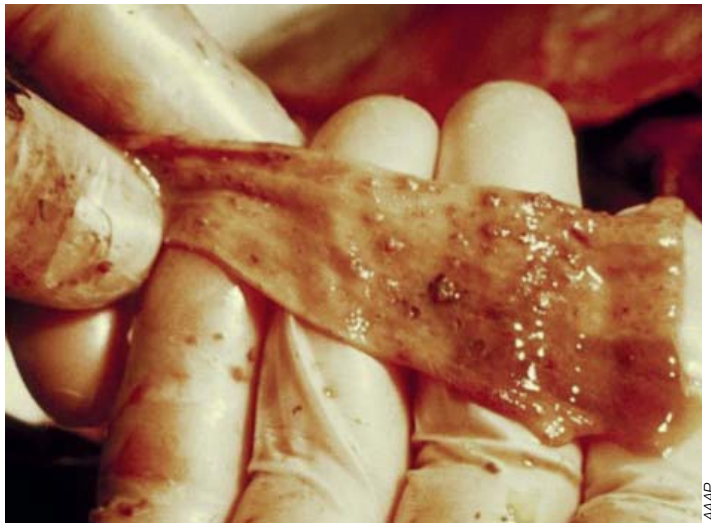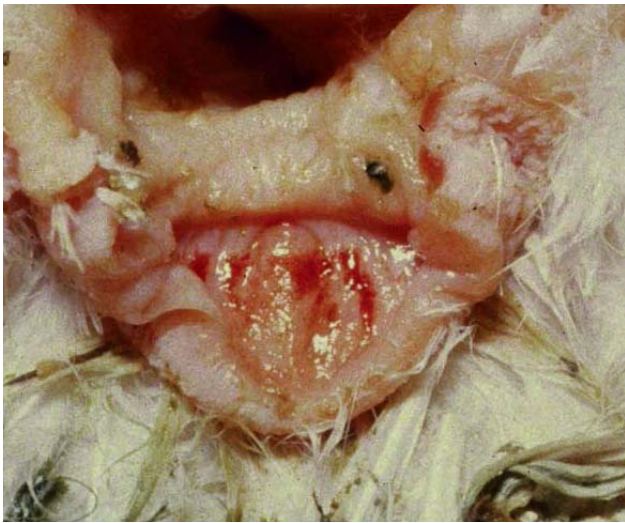


Fig.19.37 & 19.38: Newcastle disease (velogenic). Hemorrhagic cloacitis.

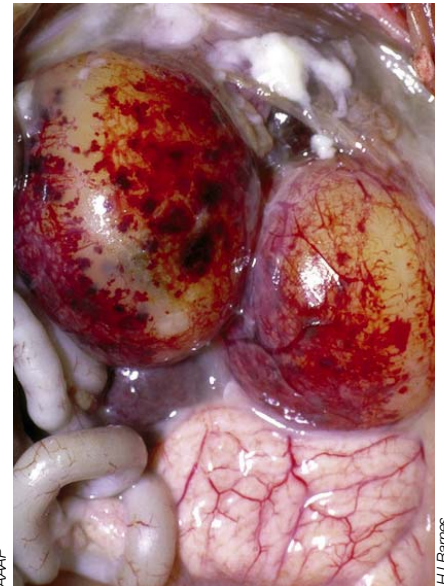
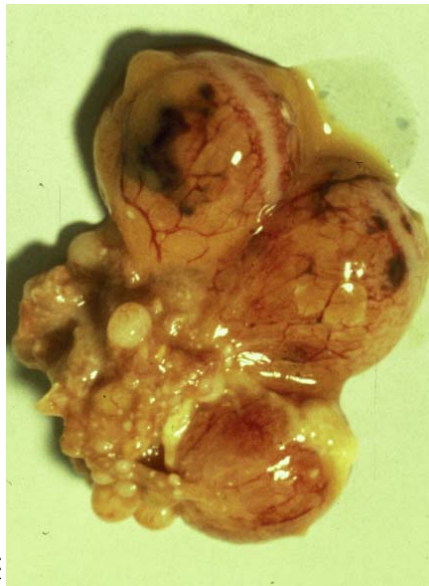
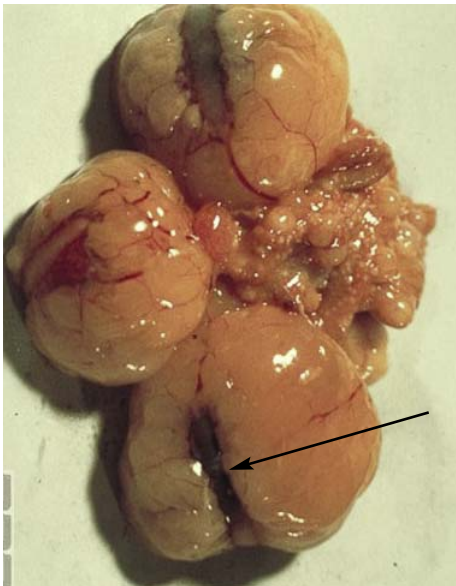

Fig.19.39: Ovaries of infected hens are often shrunken. The stigmata may be hemorrhagic. The stigmata appears as a constriction, cutting down into the ovum.

Fig.19.40 & 19.41: Some ovaries have ova with areas of hemorrhage and necrosis.

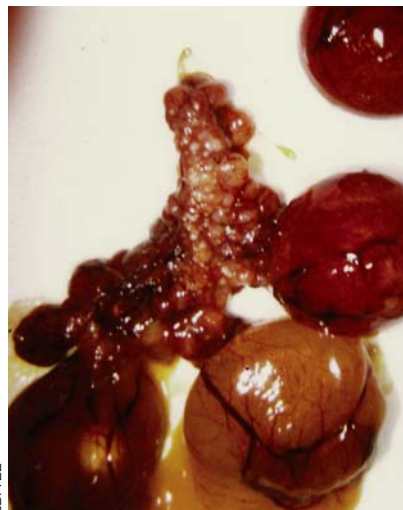
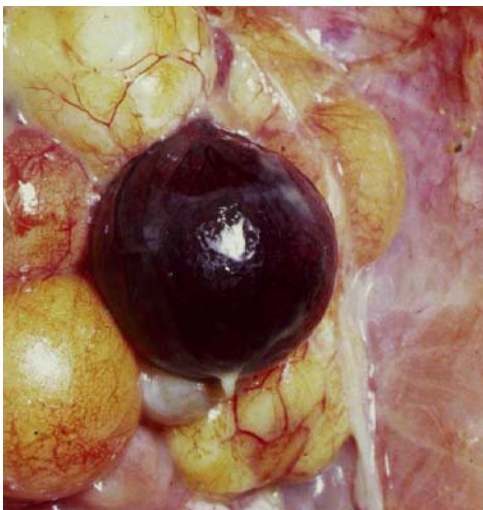
Fig.19.42, 19.43 & 19.44: Peracute Newcastle disease. Hemorrhagic ovaries.

Although biosecurity could be sufficient, vaccination is considered an extra precaution, especially in high poultry density areas. Newcastle disease vaccination in commercial poultry production is designed to reduce the risk of infection and viral transmission, in order to prevent clinical signs and mortality. A vaccination strategy will depend on the status of the region (ND endemic or not) and the perspective of the emergence of ND in this region. For example, in countries where NDV is absent but is considered a threat, vaccination is applied to ensure maximum protection against ND. This is the case in Europe with Belgium, the Netherlands and Germany, where ND epidemics in the 90s have led to mandatory vaccination of all types of poultry production. In other countries like France, only layers and breeders are vaccinated. In countries where NDV is endemic, vaccination will contribute to decreasing the infection pressure. Therefore, the disease may not be apparent because of the vaccination campaign. Finally, countries like Sweden, Finland and Estonia do not vaccinate at all. Currently, in Europe and the United States, only the use of lentogenic strains (Hitchner, La Sota, Ulster) is authorized and the virulence of mesogenic strains is not considered acceptable.

The immunity to NDV results from the presence of antibodies against the two viral glycoproteins, HN and F. These antibodies can be induced by vaccination. This can be done using live, inactivated vaccines or vectorised vaccines. Live vaccines have been used for over 30 years. In general, the La Sota vaccines provide better immunity than those prepared from the Hitchner strain, although variations depending on the origin of commercial vaccines have been reported. Live vaccines are administered by nasal or eye drop, dipping of the beak, spray, aerosol or drinking water. The choice between these different methods of vaccination depends on the labor cost, individual immunization being the most effective but also the most expensive, and the type of poultry production (meat birds, breeders, layers). The aerosol and spray techniques are usually reserved for the vaccination of laying hens and breeders while vaccination via drinking water is mostly practiced in broilers. Whatever the method of vaccination and the vaccine strain used, we always face homologous antibody interference. The importance of this interference will determine the level of antibody response induced by vaccination and the duration of post-vaccinal immunity. In all cases, however, vaccine induced antibodies appear in local secretions and serum six to ten days after vaccination. Furthermore, early protection due to cellular

immunity has been observed within two days after vaccination. For nearly 20 years, inactivated oil adjuvant vaccines have been used mainly for booster vaccination before egg laying. The resulting immunity protects the layers and breeders throughout the production period. These vaccines can be inoculated to day old chicks simultaneously with a live vaccine administered by eye or nasal drop, spray or beak dipping. This method of vaccination is particularly effective in regions where ND is endemic because protects chickens until 11 weeks of age. Inactivated vaccines are also commonly used in turkeys, guinea fowl and partridge for booster vaccination after administration of the La Sota vaccine. The administration of an inactivated vaccine in aqueous suspension is particularly effective and harmless to pigeons, caged and exotic birds.

The advent of biogenetics will most likely change the way we vaccinate against ND in the next decades. The expected advantages of vaccines derived from recombinant DNA techniques are the lack of pathogenicity and virulence reversion potential, of interference of maternally derived antibodies and the ability to differentiate a serological response due to vaccination from that induced by infection. The implementation of molecular biology techniques in the field of vaccination has for objective to improve the efficacy and safety of conventional vaccines. Research can also be directed towards the development of new types of vaccines, either vectorized or subunit (developed from the only immunogenic components of the virus, mainly surface proteins or viral envelope). Finally, new adjuvants are being considered.

Thus, the main disadvantage of attenuated vaccines is the residual pathogenicity and its adverse effects, especially in young birds. This is why vector vaccines containing one or more NDV are therefore proposed as an alternative, namely with the vectors as the avian poxvirus (fowl pox virus or FPV) and herpesvirus of turkeys (HVT). This type of vaccine has the advantage of being bivalent, because it induces immunity against the specific disease (ND) from the gene that has been inserted into the vector but it also offers immunity against fowl pox (FPV vector) or Marek's disease (HVT vector). Moreover, these vector vaccines make possible the adaptation of the insert based on circulating strains of NDV. The recombinant fowlpox vaccines are injected subcutaneously, or by the technique of wing web transfixion (scarification or wing-web stab) and therefore require individual bird handling, which may be considered a disadvantage. Their other potential disadvantage

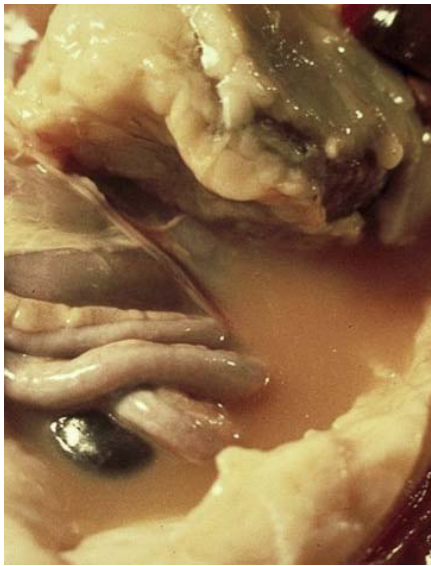

Fig.19.45: Excessive yolk-like fluid is often observed in hens that died of very velogenic ND.

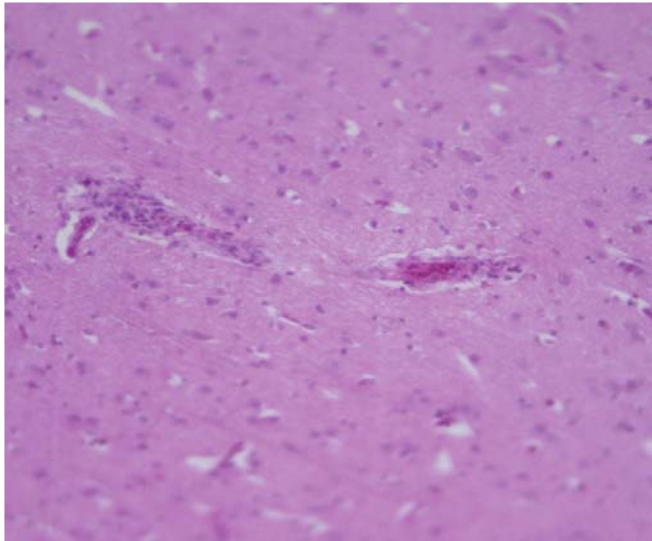


Cornell University

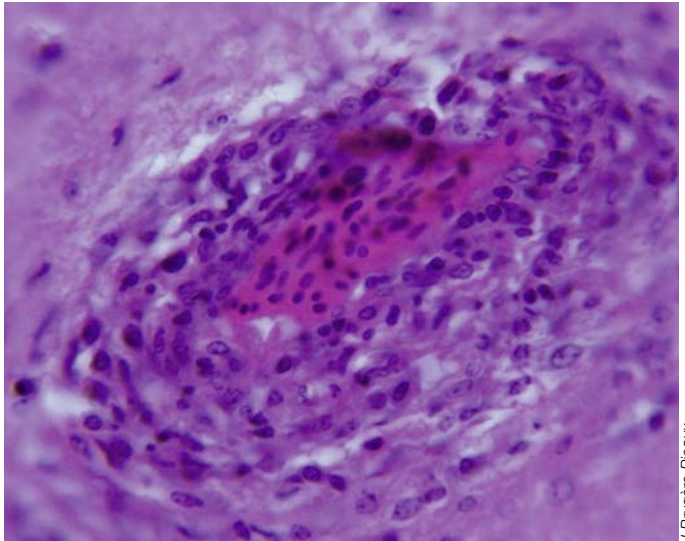


J Ruiz - Cornell University

Fig.19.46 & 19.47: Velogenic viscerotropic Newcastle disease. Many of the eggs shown here are rough, misshapen, and thin-shelled. These findings are often present in viscerotropic velogenic Newcastle and infectious bronchitis infections, where fever stalls the normal movement of the egg through the oviduct, causing deformed and defective shells.

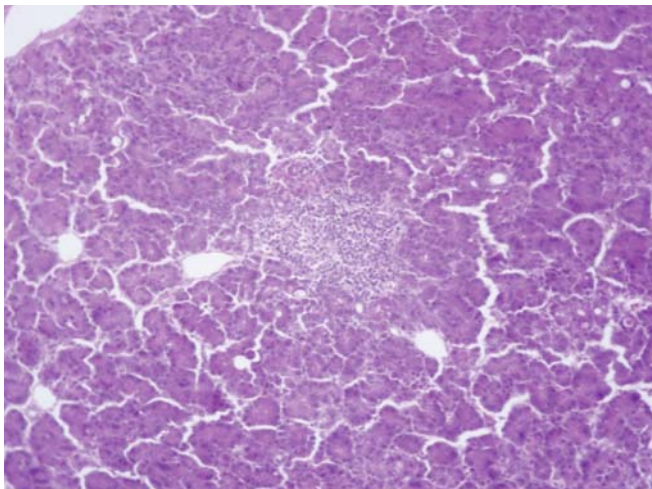


J Brugère-Picoux




J Brugère-Picoux

Fig.19.48 & 19.49: Encephalitis (Newcastle disease). Perivascular cuffing are seen in the brain of the hen (to the left) and the pheasant (to the right).



J Brugère-Picoux

Fig.19.50: Newcastle disease. Pancreatitis associated is characterized by a lymphocytic infiltration (Pheasant).



LDA 22

Fig.19.51: Newcastle disease. Hemagglutination and inhibition of hemagglutination.

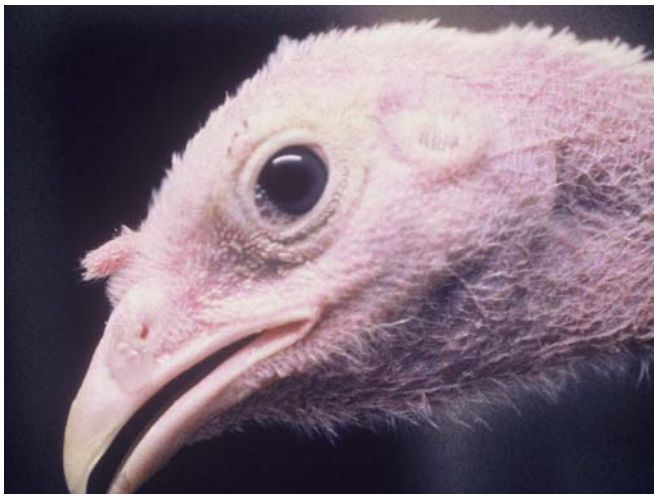is their sensitivity to maternal antibodies directed against the vector itself and therefore the difficulty of using such vectors in birds vaccinated against fowl pox. Herpesvirus vectors are much less sensitive to this interference and also have the major advantage of being administered *in ovo*. However, the current NDV vaccine strains may kill or weaken embryos, which may impact hatchability. So, less pathogenic vaccine strains have been selected for *in ovo* vaccination. These vaccines have been efficacious, including in the presence of maternal antibodies.

In conclusion, although the need has been demonstrated (and it may even be compulsory in some regions), farmers are often reluctant to vaccinate against ND because of the additional workload and of the potentially negative impact on flock performances. In addition, vaccination according to current programs does not prevent infection of vaccinated poultry or field virus excretion. In the context of ND eradication, it is therefore necessary to develop an "ideal vaccine" capable of protecting birds from disease and inhibiting the spread of the virus, while limiting the workload for farmers. An *in ovo* vaccine less sensitive to maternal antibodies would certainly have a determining advantage.

Furthermore, as serology alone does not explain the level of protection induced by vaccination, research is currently conducted under laboratory conditions to assess more thoroughly the cell-mediated immunity and local immune response (at the level of the respiratory and digestive tract) specific to NDV and their role in the protection against clinical signs and virus shedding. These new techniques should provide better knowledge of the mechanisms of immunity induced by vaccination, which should help in developing the "ideal vaccine" against ND.


REFERENCES

- Alexander DJ. Newcastle disease and other avian paramyxoviruses. *Rev Sci Tech*. 2000 19:443-62.
- Alexander DJ. Newcastle Disease, other avian paramyxoviruses, and pneumovirus Infections, In: Saif YM et al ed. *Diseases of Poultry*. Iowa State University Press, 2003, pp 63-87.
- Alexander DJ & Jones RC. *Paramyxoviridae*. In Pattison M et al, *Poultry diseases*, 6th ed., Saunders Elsevier 2008, pp 294-316.
- Aldous EW et al. A molecular epidemiological study of avian paramyxovirus type 1 (Newcastle disease virus) isolates by phylogenetic analysis of a partial nucleotide sequence of the fusion protein gene. *Avian Pathol*, 2003, 32:239-256.
- Czegledi A et al. Third genome size category of avian paramyxovirus serotype 1 (Newcastle disease virus) and evolutionary implications. *Virus Res*, 2006, 120:36-48.
- Marangon S & Busani L. The use of vaccination in poultry production. *Rev Sci Tech OIE*, 2006, 26:265-274.
- Mast J et al. Vaccination of chickens embryos with escape mutants of La Sota Newcastle disease virus induces a protective immune response. *Vaccine*, 2006, 24:1756-1765.
- Miller PJ et al. Antigenic differences among Newcastle disease virus strains of different genotypes used in vaccine formulation affect viral shedding after a virulent challenge. *Vaccine*, 2007, 27:7238-7246.
- Official Journal of the European Community, Council Directive 92/66/EEC of 14 July 1992 introducing Community measures for the control of Newcastle disease*, No L 260, pp 1-17.



D Toquin, Anses - Ploufragan

Fig.20.1: TRT (Poult). Breathing difficulties, mucoid nasal discharge and foamy ocular discharge, experimental infection.



JY Ferré

Fig.20.2: TRT (Turkey). Peri- and infraorbital edema.



P Drouin, Anses Ploufragan

Fig.20.3: SHS (Chicken). A mild blepharitis and prolapse of the nictitating membrane are early clinical signs remaining mild.



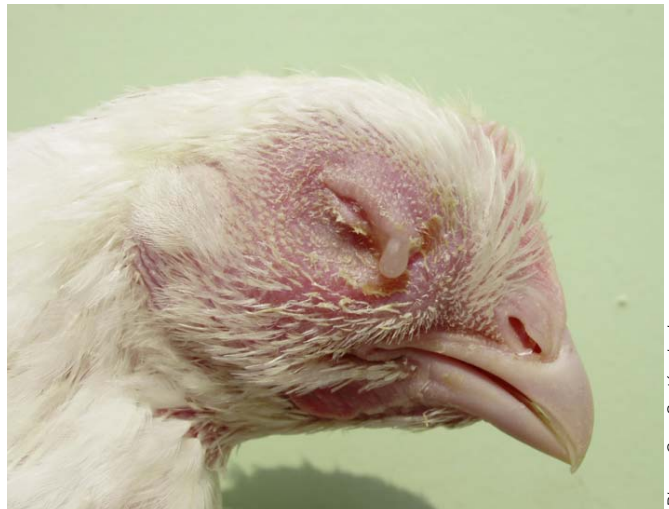P Drouin, Anses Ploufragan

Fig.20.4: SHS (Chicken). Blepharitis, peri-ocular swelling, edema of infraorbital sinus and under-mandibular area. Breathing difficulties.



I Dinev - Ceva Santé animale

Fig.20.5 & 20.6: SHS (Chicken). Blepharitis, periocular swelling, edema of infraorbital sinus and under-mandibular area. Breathing difficulties. Note characteristic elongated almond-shaped eye.



I Dinev - Ceva Santé animale

20. AVIAN METAPNEUMOVIRUS

INTRODUCTION

Over the past 20 years, avian metapneumoviruses (aMPV) have been identified as causing infections of the upper respiratory and reproductive tracts in several species of domestic poultry (turkeys, chickens, guinea fowl and ducks). Whatever the clinical form and age of affected birds, pneumovirus is causing significant economic losses. Respiratory clinical forms were first recognized. Avian metapneumoviruses are especially common in young chickens and turkeys, but their importance in ducks is not known. Respiratory clinical signs are found in turkeys [known as avian (ART) or turkey rhinotracheitis (TRT)] and chickens [“swollen head syndrome” (SHS)]. Both forms exist in guinea fowl. Only experimentally inoculated ducks show signs of rhinotracheitis. The viral respiratory infection does not last long. In chickens and turkeys, it is frequently followed by secondary bacterial infections that complicate the diagnosis and that may result in elevated mortality rates. These bacterial infections, in particular *Escherichia coli*, are an essential etiological component of SHS. In turkey, chicken and duck breeders, the respiratory phase of the aMPV infection can be subtle and the drop in egg production that follows may be the only observed clinical sign.

ETIOLOGY

Isolated for the first time in 1986, aMPV belongs to the genus *Metapneumovirus* in the *Pneumovirinae* subfamily, *Paramyxoviridae* family. The name *Metapneumovirus* reflects both the relationship and differences between aMPV and the true pneumoviruses (respiratory syncytial virus in cattle and humans). The viral particles of aMPV are enveloped, rounded or elongated, varying in size between 150 and 800 nm. The viral genome consists of a single-stranded RNA monocatenary molecule of negative polarity. It contains eight genes in the order 3'-N-P-M-F-M2-SH-G-L-5'. The entire genome sequence was determined for the aMPV subgroup A (aMPV-A) and C (see below the notion of sub-group). Unlike other *Paramyxoviridae*, *Pneumovirinae* do not possess hemagglutinating activity. Envelope glycoproteins called fusion (F) and attachment (G) are the main proteins inducing antibodies. In infected birds, aMPV replicate mainly in ciliated cells of the upper respiratory tract (nasal turbinates, sinuses, trachea).

For a long time considered a homogeneous group, aMPV are currently divided into four subgroups called A, B, C (Colorado virus identified in the United States in 1996) and D (isolates obtained in 1985 in France, current prevalence unknown). The subgroups can be differentiated based on antigenic cross-reactivity tests conducted according to the ELISA or seroneutralization techniques, as well as reactivity towards some monoclonal antibodies. The subgroups also differ genetically; glycoproteins G of aMPV-A, -B and -D have at most 38% of amino acid identity, other viral proteins being (except for SH) much more preserved. Antigenic and genetic approaches suggest that aMPV-C are the most divergent aMPV, so much so that the Colorado virus (aMPV C-type) was suggested as a possible representative of a new aMPV serotype. Antigenic and genetic differences between subgroups are important to consider when evaluating serological or molecular tests. Despite the differences between subgroups, clinical cross-protection may however exist between some of them (see below, treatment & control).

A human metapneumovirus (hMPV) was identified in 2001. It is responsible for respiratory infections in young children and weakened or immunocompromised adults. This virus presents (with the exception of its SH and G proteins) strong similarities with aMPV-C, suggesting that both viruses share a common ancestor.

EPIDEMIOLOGY

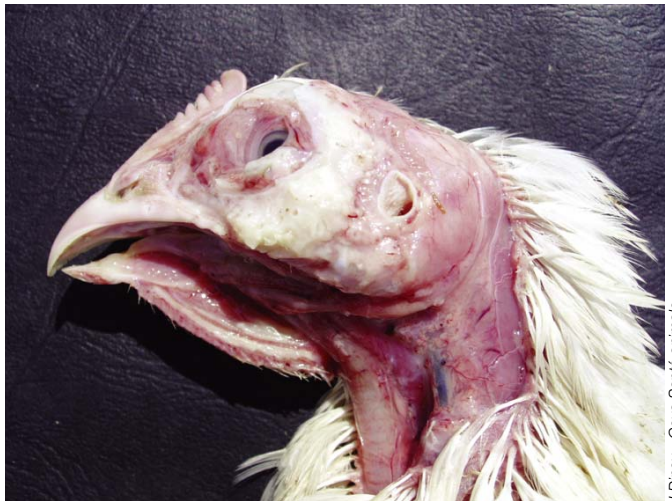The first observations of the disease date back to 1979 when SHS was described in South Africa. Turkey rhinotracheitis then appeared in France and the United Kingdom in the early 1980s. The aMPV have been identified in most countries in Europe, South America, North Africa, the Middle and Far East, and since 1996 in the United States. Only Australia and Canada are currently considered free of the disease.

Besides turkeys, chickens, guinea fowl and ducks, serological and/or virological data suggest that aMPV can also infect pheasants (*Phasianus colchicus*) ostriches (*Struthio camelus*), herring gulls (*Larus argentatus*) and some geese in the United States. The infection of migratory species may explain the spread of the disease, but this hypothesis remains to be demonstrated.



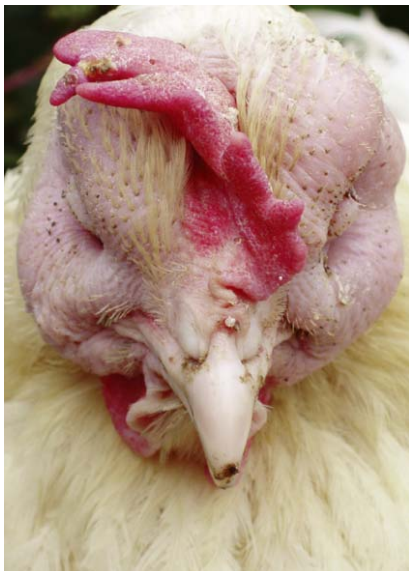I Dinev - Ceva Santé animale

Fig.20.7: SHS (Chicken). Subcutaneous edema of the head region, involving unilaterally or bilaterally the periorbital sinus and the mandibular space.




I Dinev - Ceva Santé animale

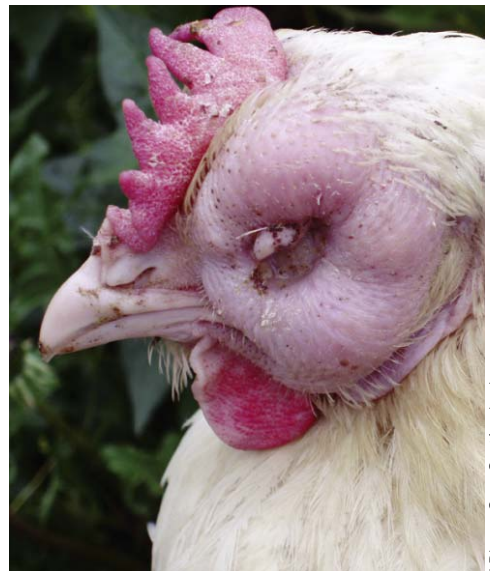
Fig.20.8: SHS (Chicken). After reflecting the skin, note serofibrinous exudates.



I Dinev - Ceva Santé animale



I Dinev - Ceva Santé animale



I Dinev - Ceva Santé animale

Fig.20.9, 20.10 & 20.11: SHS in broiler breeders is usually encountered around the peak egg laying period. Periorbital swelling of sinus, mandibular region and wattles associated with superinfection with *E. coli*.



P Drouin, Anses Ploufragan

Fig.20.12: SHS (Hen). Lethargy. Sick hens sleep in the nests.



P Drouin, Anses Ploufragan

Fig.20.13: SHS (Hen). Torticollis due to middle ear lesion.

Current data do not allow defining possible host specificity for the different aMPV strains. Until now, viruses of the four subgroups have been identified in turkeys, aMPV-A and -B in chickens, aMPV-B in guinea fowl, aMPV-C in waterfowl (in France and USA) and aMPV-A (UK) and -C (Korea) in pheasants. Viruses isolated in ducks in France (subgroup C) have not shown to be pathogenic in turkeys, suggesting that pathogenic aMPV in ducks are different from those affecting other species. However, some aMPV-A or -B isolated from chickens or turkeys can be pathogenic in both species. The aMPV-C isolated in turkeys in the USA do not seem to be circulating in chickens in this country.

The aMPV are fragile in the environment and easily inactivated by common disinfectants. Their horizontal transmission is very effective during the week following the infection. Transmission is by air and by direct contact. The airborne route brings the viral particles directly in contact with their target cells, but close contact with sick birds is necessary under experimental conditions to reproduce all the clinical signs of TRT among contact birds. Despite the genital tropism of aMPV, no vertical or horizontal transmission *via* semen has been described, although this mode of transmission has been suspected in ducks. Experimentally induced immunosuppression using cyclosporin A failed to demonstrate re-excretion of the virus in chickens or poult infected 3-4 weeks previously.

Factors contributing to or aggravating avian metapneumovirus are age (young birds are more susceptible to respiratory forms), rearing conditions (poor ventilation, excess ammonia and dust in the atmosphere, an insufficient heating are all aggravating factors) and intercurrent diseases with respiratory tropism [*Escherichia coli*, *Avibacterium paragallinarum* (*Haemophilus paragallinarum*), *Ornithobacterium rhinotracheale*, *Bordetella avium*, *Riemerella anatipestifer*, *Mycoplasma gallisepticum*, *etc.*] or genital tropism (*Mycoplasma* spp. *Escherichia coli*, infectious bronchitis virus, paramyxovirus types 1 or 3, egg drop syndrome 76, *etc.*) or that are immunosuppressive (hemorrhagic enteritis in turkeys, infectious bursal disease in chickens, *etc.*).

CLINICAL SIGNS & LESIONS

In poults, respiratory signs occur mostly between 3 and 12 weeks of age, two to three days after infection. They consist of a facial pruritus, then sneezing accompanied by serous nasal and eye discharges becoming mucoid. Tracheal cough then

appears. The signs peak with swelling of the infra-orbital sinuses and periocular tissues. In the absence of bacterial complications, clinical signs disappear within 7-10 days. Morbidity is close to 100%. Mortality, due to complications, can reach 60%. In turkey breeders, infections occurring prior to egg production are often benign because of generally superior management and environmental conditions. During egg production, a respiratory episode lasting five days (sometimes going unnoticed) is followed by a drop in egg production between 10 to 30%, accompanied by an inconsistent discoloration of eggshell. The egg production rate returns to normal within 10 to 21 days.

In chickens and guinea fowl, the first sign of disease is a prolapse of the third eyelid, followed by discreet rales accompanied by nasal and eye discharges. Next, the most obvious sign is the "swollen head" caused by an inflammatory edema that affects the eyelids, the periocular region, infra-orbital sinuses and even the lower jaw or neck. Some birds are drowsy and may lose balance or have a torticollis due to an inflammation of the middle ear. Reproductive signs appear in laying hens after a respiratory phase that may be subtle. The drop in egg production (5-30%) is not accompanied by changes in egg quality. It affects a highly variable proportion of the flock, depending on whether predisposing factors are present. Mortality may reach 10%.

In ducks less than three weeks of age, congested airways accompanied by a serous nasal discharge peaks 4-5 days after experimental inoculation and disappears within a week. In infected duck breeders, coughing is followed by a drop in egg production, usually around 30%, sometimes accompanied by an increase in mortality, but below 5%.

Early respiratory lesions consist of a congestion of the mucous membranes (nasal, sinus and/or trachea) with presence of more or less profuse mucus. Histological examination performed within three days following the onset of clinical signs reveals edema and inflammatory infiltration of the mucosa which contains eosinophilic cytoplasmic inclusion bodies in the apex of ciliated epithelial cells, especially in the trachea or turbinate. These lesions are transitory. In chickens and turkeys, they are quickly masked by bacterial complications, marked by the extension of the inflammation to sinuses and the lower respiratory tract (lungs, air sacs) with the possible occurrence of sinusitis, pneumonia, airsacculitis, pericarditis or perihepatitis accompanied by splenomegaly. Characteristic lesions of edema seen in SHS are not necessarily

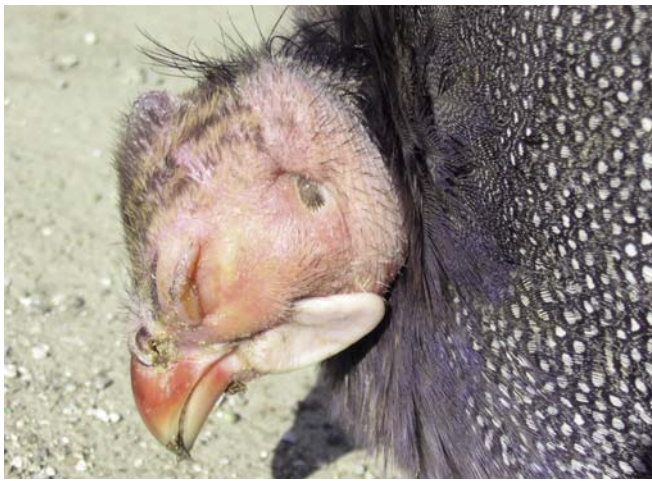

Fig.20.14 & 20.15: SHS (Guinea fowl). Blepharitis and swelling of infraorbital sinuses, often accompanied by watery eyes. A secondary bacterial infection (often *E. coli*) produces a purulent exudate.

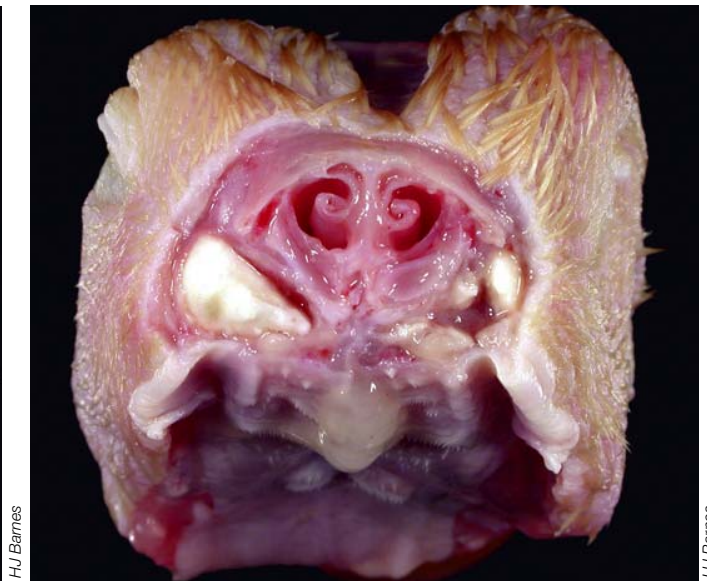
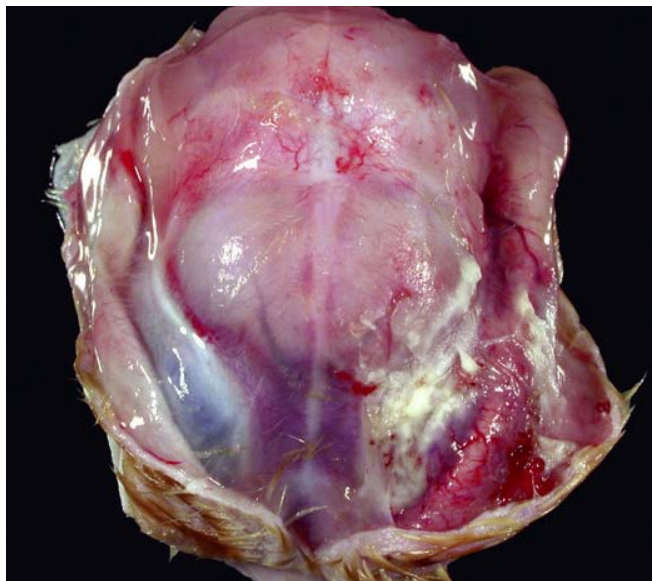

Fig.20.16 & 20.17: RTI (Turkey). Secondary bacterial infections, particularly *E. coli*, are an essential component of the development of SHS in chickens or TRT in turkeys. They trigger an inflammatory response producing an exudate in the subcutaneous tissues and sinuses.

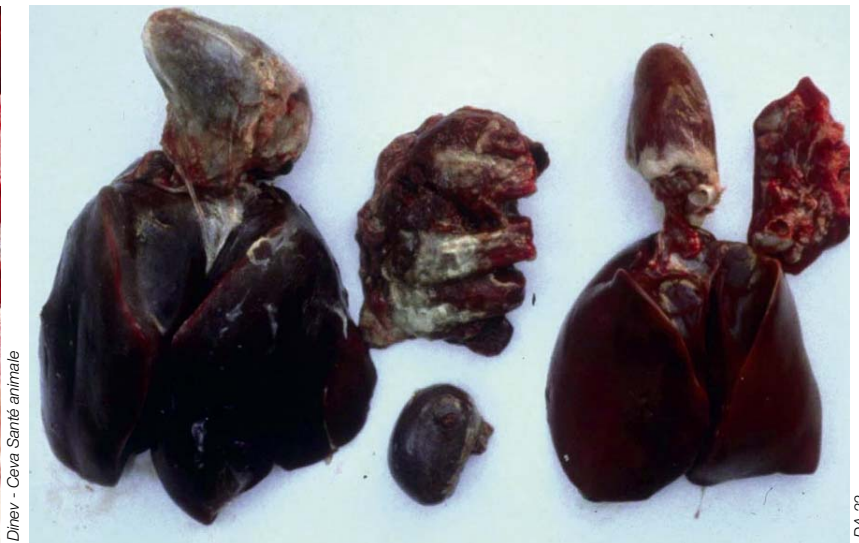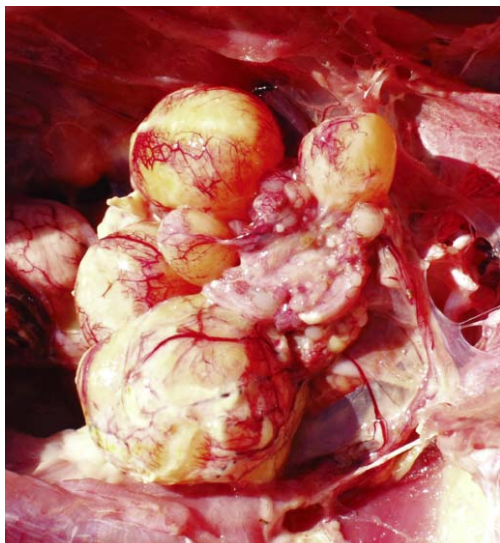


Fig.20.18: SHS (Hen). Fibrinous oophoritis in laying hens resulting in lower egg production.

Fig.20.19: Turkey infectious rhinotracheitis (Poults). Localized bacterial complications in liver and lungs (pneumonia and hepatitis).

accompanied by significant respiratory lesions. The periocular subcutaneous edema sometimes evolves towards fibrinocaseous swelling. Depending on the extension of the lesions, blepharitis and conjunctivitis, but also caseous otitis, maxillary arthritis, periostitis or osteomyelitis may be observed, possibly accompanied by the systemic complications mentioned above.

In laying hens and turkeys, the most frequent reproductive tract lesion consists of an involution of the ovary. In laying ducks, oophoritis and salpingitis are frequently observed.

DIAGNOSIS

The diagnosis of aMPV infections should not be based solely on clinical signs, since these can also be observed as a result of infections caused by various bacteria (*E. coli*, *O. rhinotracheale*, *Mycoplasma gallisepticum*, *B. avium*, *A. paragallinarum*, *Chlamydia psittaci*, *Riemerella anatipestifer*, etc.) or viruses (Influenza virus, PMV1, PMV3, adenovirus, infectious bronchitis coronavirus, etc.) alone or in combination with other pathogens.

Anti-aMPV antibodies can be detected by ELISA, neutralization or indirect immunofluorescence tests. The ELISA is the most common. It detects the most persistent antibodies. Two batches of 15 to 20 sera collected two to three weeks (turkeys) or three to four weeks (hens) apart must be tested, with the first batch being taken at the onset of the first clinical signs. Conjugated chicken anti-Ig is suitable for ELISA tests in chickens, turkeys and guinea fowl, but the testing of duck sera requires a specific conjugate.

The use of an ELISA antigen belonging to a subgroup different from the infecting virus can lead to reduced sensitivity of the test (many false negatives). For example, the use of the ELISA test with conventional antigens derived from viruses of subgroups A or B does not allow the detection of aMPV-C induced antibodies. Commercial ELISA kits can also present different levels of sensitivity. It should be noted that the initial respiratory signs are often mild; so it is not uncommon to detect aMPV antibodies in blood samples collected soon after the first observation of the disease.

Virological diagnosis, which is rarely done in practice, must be made within seven days after infection (in chickens when head edema appears, it is usually too late to isolate the virus). The samples of choice are the tissues and mucus from the upper respiratory tract (sinuses, turbinates, palatine crack, upper half of the trachea) or swabs of the same origin.

Samples must be refrigerated until testing, and kept frozen as cold as possible in cases when they cannot be tested within 48 hours after being collected. The swabs are placed in a transport medium (peptoned water or cell culture medium) supplemented with antibiotics.

Viral isolation and propagation media include embryonated eggs (intravitelline inoculation), embryonic tracheal organ cultures and cell cultures also used for virus neutralization tests (chicken embryo fibroblasts, or monkey kidney cell lines). The embryonic tracheal organ cultures show the ciliostatic character of the virus, except for the Colorado virus. Cell cultures show a cytopathic effect characterized by the detachment of rounded refringent cells and the formation of syncytia. Whatever the medium, several passages may be necessary for isolation. The isolated virus must be identified by immunofluorescence, immuno-electron microscopy or neutralization using anti-aMPV reference sera.

Molecular diagnosis of the disease is achieved by reverse transcription-polymerase chain reaction (RT-PCR) of a portion of the viral genome. The same samples as those intended to be used for isolation, or alternatively, dry swabs of the same origin or of esophageal origin may be transported without cooling if they are intended solely for molecular diagnostic procedures. The sensitivity of RT-PCR is usually superior to viral isolation and aMPV can be detected until 21 days after infection. The protocols provide either for the detection of all aMPV (nucleotide primers specific to conserved portions of M and N genes) or the identification of a viral subgroup (primers specific to gene G).

A commercial kit for real time RT-PCR has been developed for the detection of the four aMPV subgroups and can be used to quantify the virus in samples submitted for analysis.

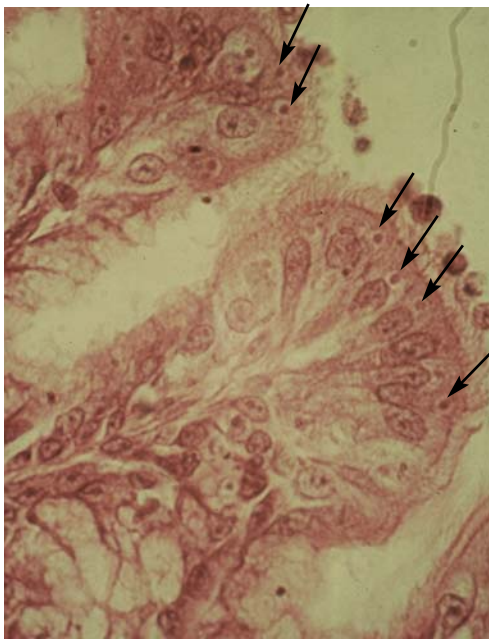
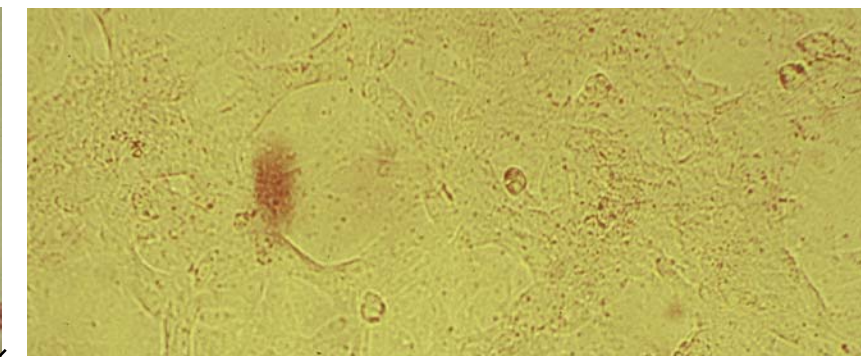
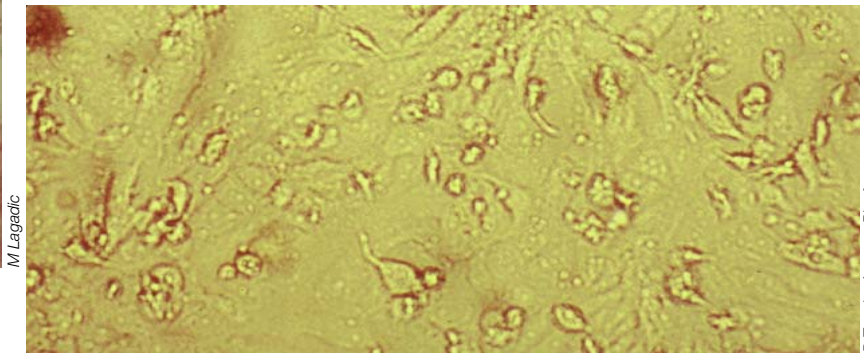


Fig.20.20: RTI. Viral acidophilic inclusion bodies (arrows) in the apex of ciliated epithelial cells in the sinus of an experimentally infected pout. These early lesions are quickly masked by secondary bacterial infections.

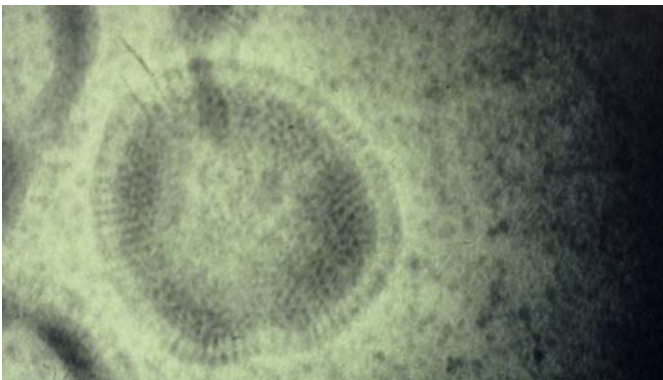


D Toquin, Anses – Ploufragan



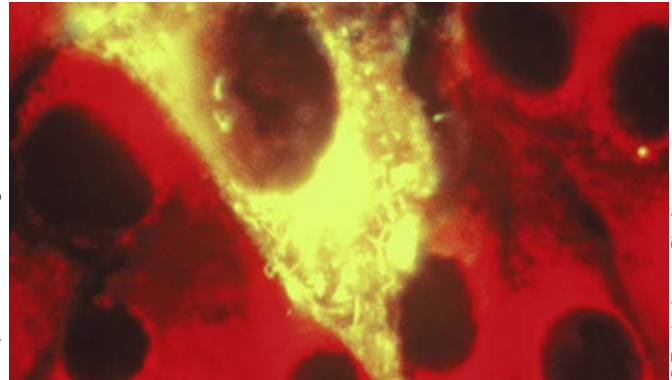
D Toquin, Anses – Ploufragan

Fig.20.21 & 20.22: Cytopathic effect of aMPV. Vero cells infected at the bottom. Presence of refractile and round infected cells being destroyed and detaching from the cell layer. Top: normal cells.



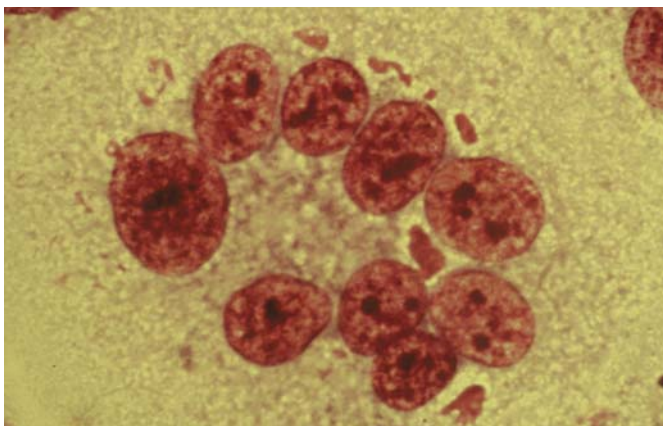
D Toquin, Anses – Ploufragan

Fig.20.23: Avian metapneumovirus. Enveloped virus particles, fringed and polymorphic characteristics of *Myxoviridae*. Transmission electron microscopy, negative staining with phosphotungstic acid.



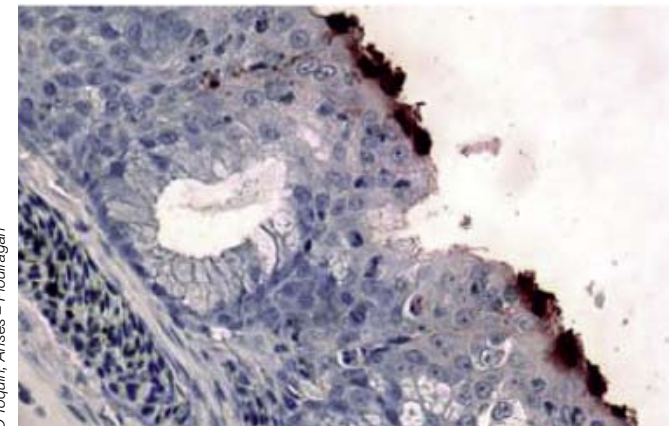
D Toquin, Anses – Ploufragan

Fig.20.24: Indirect immunofluorescence. Intracytoplasmic fluorescent granules (yellow) associated with the presence of proteins of aMPV, in contrast with uninfected Vero cells stained red (Evans blue staining).



D Toquin, Anses – Ploufragan

Fig.20.25: Cytopathic effect of aMPV. Formation of syncytia containing acidophilic intracytoplasmic inclusion bodies. Monkey kidney cells BGM70 (May-Grünwald & Giemsa stain).



K Nagaraja

Fig.20.26: Nasal turbinates of turkey poults exposed to avian pneumovirus. Immunohistochemistry shows staining of epithelial cells by peroxidase revealing the specific viral antigen.

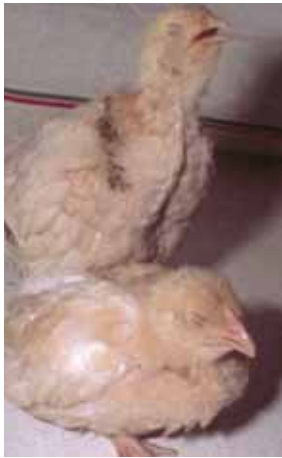TREATMENT & CONTROL

There is no specific antiviral treatment and bacterial complications must be controlled, if necessary with antibiotics. Strict sanitation, good flock management, in particular ensuring adequate ventilation and ambient temperature, are critical to minimize complications from the infection.

The prevention of disease requires proper flock management and control of predisposing or aggravating factors. Prophylactic vaccination is possible in turkeys and chickens from vaccines developed from aMPV subgroups A or B in Europe or from aMPV subgroup C in the United States. Live attenuated vaccines can be administered to young birds by nebulization or by drinking water. Adjuvanted inactivated viral vaccines can then be given by injection to breeders before the start of egg production. The combination of the two types of vaccine provides a higher and more homogeneous immunity level, and a better protection against a drop in egg production. The presence of maternal antibodies does not appear to interfere with the use of most live vaccines during the first week of age. In turkeys, attenuated vaccines developed from aMPV-A or -B provide good clinical protection against aMPV-A, -B, -C or -D. On the other hand, prior immunization with aMPV-C does not protect turkeys nor chickens against aMPV-A or -B challenge. The immunity induced by attenuated vaccines may prove to be short-lived and most manufacturers recommend repeated administration every few weeks. One should ensure that conditions of administration of these vaccines are optimal (reduced heating, diluent free of disinfectant residues, sufficient quantity of vaccine considering flock size, size of nebulized droplets), and to administer them only to healthy birds. Cellular immune response probably plays an important role in the bird's protection. For ELISA tests, the antibodies induced by vaccination are better detected by using an antigen of the same subgroup as the vaccinal virus.

REFERENCES

- Bäyon-Auboyer et al. Nucleotide sequences of the F, L and G protein genes of two non-A/non-B avian pneumoviruses (APV) reveal a novel APV subgroup. *J Gen Virol*, 2000,81:2723-2733.
- Bäyon-Auboyer et al. Comparison of the F-, G- and N based RT-PCR protocols with conventional virological procedures for the detection and typing of turkey rhinotracheitis virus. *Arch Virol*,1999, 144:1091-1109.
- Cook JKA & Cavanagh D. Detection and differentiation of avian pneumoviruses (metapneumoviruses) (review). *Avian Pathol*, 2002,31:117-132.
- Gough RE & Jones RC. Avian Metapneumovirus. In “*Diseases of Poultry*”, Blackwell Publishing, Ames, Iowa, USA, 2008, p100-110.
- Guionie et al. Laboratory evaluation of a quantitative real time RT-PCR assay for the detection and identification of the four aMPV subgroups. *J Vir Meth*, 2007,139:150-158.
- Jestin V et al. The new duck pneumovirus : experimental assessment of the pathogenicity for the respiratory tract of muscovy ducklings. *Proceedings of the 5th Int. Congress of the Eur. Soc. for Vet. Virol.*, Brescia, Italy, 27-30 Aug. 2000, p 341.
- Seal BS. Avian pneumovirus and emergence of a new type in the United States of America (review). *Animal Health Research Reviews*, 2000,1:67-72.
- Toquin et al. Isolation of a pneumovirus from a Muscovy duck. *Vet Rec*, 1999, 145:23, 680.
- Toquin et al. Subgroup C avian metapneumovirus (MPV) and the recently isolated human MPV exhibit a common organization but have extensive sequence divergence in their putative SH and G genes. *J Gen Virol*, 2003,84:2169-2178.



LDA 22



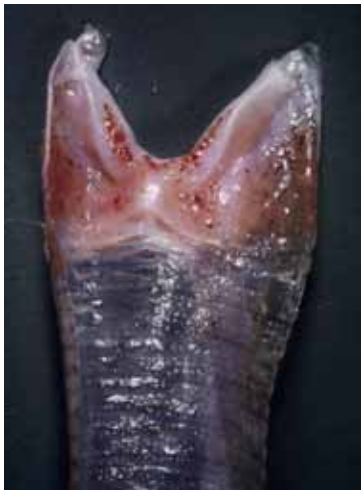A. Darmani



J. Ruiz - Cornell University

Fig.21.1 & 21.2: IB. Pullets with dyspnea and conjunctivitis.


Fig.21.3: IB. Mature chicken with mucopurulent ocular and nasal discharge associated with conjunctivitis.



Sanders



Sanders




J. Berfin

Fig.21.4: IB. Tracheitis.

Fig.21.5 & 21.6: IB. Thin-shelled, rough, and misshapen eggs laid by infected hens.



J. Brugère-Picoux



J. Brugère-Picoux

Fig.21.7 & 21.8: IB (left). The internal quality of eggs may also suffer. In this photograph the light is being reflected from the outer ring of a watery egg white and there is no internal ring of albumen like in the normal egg (right).



HJ Barnes

Fig.21.9: "False layers" infected by IB with watery cysts may present a "penguin posture" like in cases of ascites.

Viral diseases

21. INFECTIOUS BRONCHITIS

INTRODUCTION

“Infectious bronchitis” (IB) is the common name of a highly contagious viral disease which was first observed during the early 1930s in the United States of America in young chicks suffering from severe bronchial respiratory distress. Already the first description of clinical signs, gross and microscopic lesions differentiated this apparently new disease from Newcastle disease, avian influenza, infectious laryngotracheitis, and pasteurellosis. Filtration experiments at that time established the viral etiology. Transmission experiments in the 1940s confirmed the contagiousness but also the rather broad range of pathological lesions. Indeed, in addition to tracheal and lung lesions, the kidney, oviduct, egg-shell and egg albumen were also affected. Although the infectious bronchitis virus (IBV) is now known as the cause of a large number of clinical and pathological disease entities, the name “infectious bronchitis” was retained. More recently, it was demonstrated that IBV-like viruses also cause lesions in other galliform birds such as quails, pheasants and turkeys.

Currently, IB in layer and meat-type chickens is considered a major cause of economic losses around the world. Attempts to control virus spread and to maintain health and productivity of chicks and adult birds by various forms of vaccination have been made for over half a century. However, due to the large number of serotypes, these modified live and inactivated vaccines have not been able to completely control the disease.

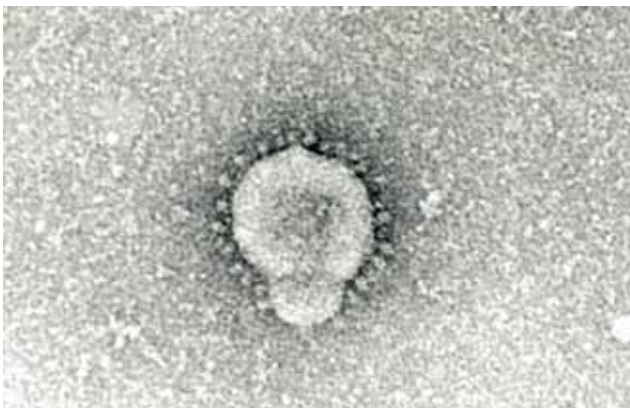

Fig.21.10: Infectious bronchitis coronavirus (electron microscopy).

JP. Picault-Anses-Ploufragan

Today, IB is defined as a rapidly transmissible disease caused by coronaviruses affecting the respiratory, urogenital, and intestinal tracts of hybrid layer, meat type, and fancy chickens of all age groups. Lateral spread of IBV may also affect quails, ring-necked pheasants, domestic turkeys and other gallinaceous birds. The IBV is not identical with the coronaviruses causing enteric lesions in domestic turkeys.

ETIOLOGY

The coronaviruses of gallinaceous birds are presently placed in the Genus *Coronavirus* of the Family *Coronaviridae* of the Order *Nidovirales*. Coronaviruses contain a single molecule of linear, single-stranded, positive sense RNA of an extremely large size. Morphologically, the diameter of IBV's virions has been estimated at 120-160 nm with an internal, possibly icosahedral core shell of around 65 nm and a helical capsid. Large projections are visible on the surface of the virions which account for the hemagglutination of red blood cells. The projections contain the peplomer spike precursor protein S0 which is cleaved by a serine protease into spike glycoproteins S1 and S2. Physically, the virions are easily destroyed by heat, lipid solvents, nonionic detergents, formaldehyde, oxidizing agents, and UV irradiation.

On the basis of clinical signs and gross pathology, the field strains of IBV are differentiated into respiratory, nephropathogenic, and enterotropic pathotypes. Neutralization tests with convalescent sera and various field strains yielded a large number of serotypes (more than 11). Various vaccinal strains can be grouped on the basis of cross-immunisation studies into protectotypes. Genomic analysis of the ssRNA made it possible to establish several genotypes.

EPIDEMIOLOGY

The predominant ways of virus entry into susceptible birds are the respiratory and conjunctival routes. After replication in various internal organs, the newly synthesized virions leave the body with mucous secretions from the upper respiratory tract and with fecal droppings. Also, IBV is present in the egg during the early viremic phase of the disease. Within a chicken house, IBV spreads with dust, contaminated drinking water, and litter. The virus may circulate within large



Fig.21.11: IB. Eggs are more or less discolored, dirty and bloodstained.

Fig.21.12: IB. Eggs are discolored, small, deformed and "ringed"; altered eggshell tend to break easily.

Fig.21.13: IB. From top to bottom: control eggs, bloodstained eggs, smaller eggs, altered eggs-hell (soft and easily broken), deformed eggs.

JP Picault Anses-Ploufragan

JP Picault Anses-Ploufragan

JP Picault Anses-Ploufragan

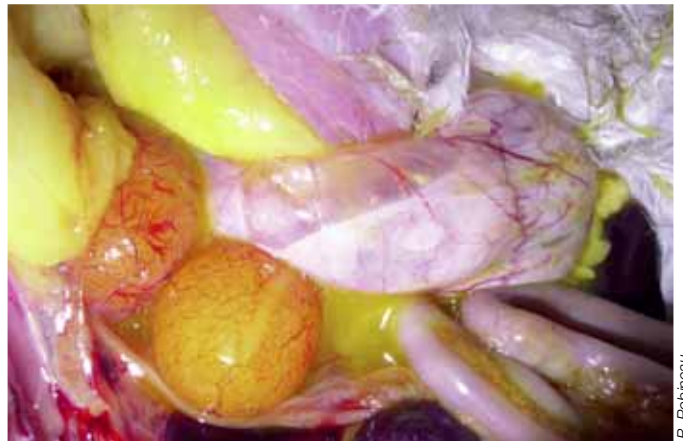
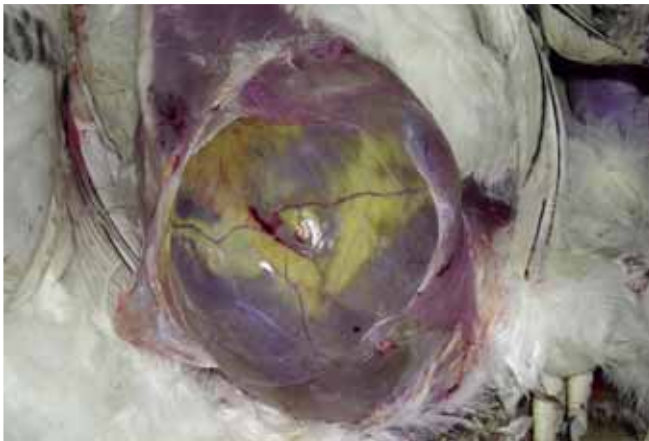

Fig.21.14 & 21.15: IB. "False layer" hens may present a pendulous abdomen. At maturity affected birds ovulate normally, with the ova then being shed into the body cavity.

B Robineau

B Robineau

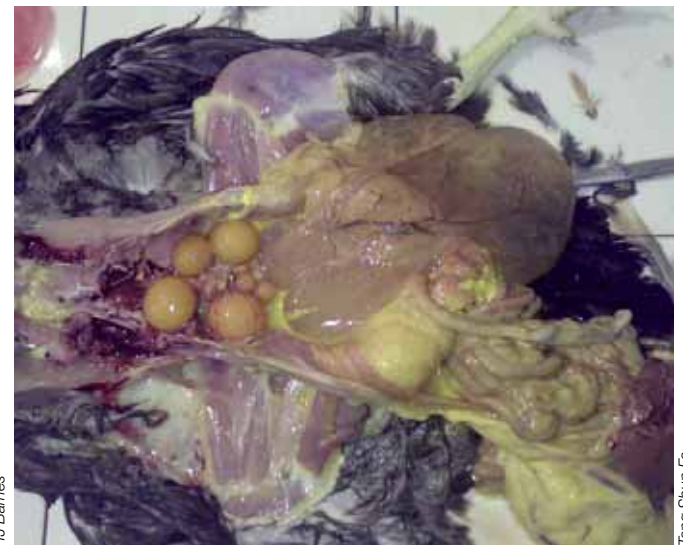
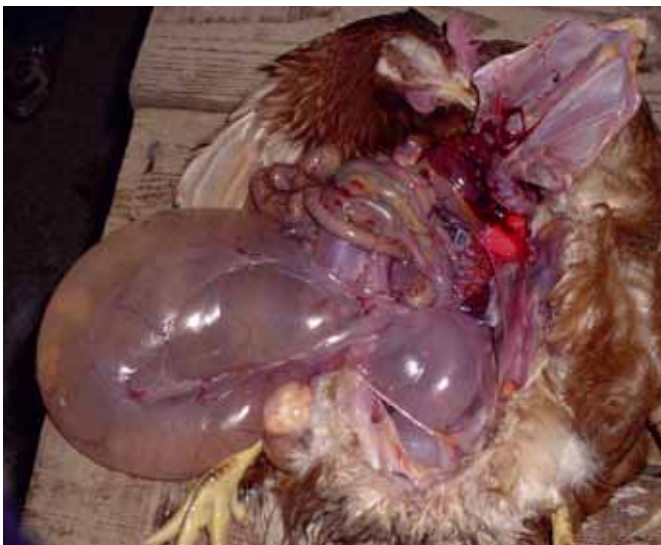
Fig.21.16: IB. "False layer": very large watery cyst can be observed in the oviduct.

Fig.21.17: IB. Since 1998 in Asia and 2004 in Europe, a novel IB variant (designated QX) has been detected with many "false layers" where ovaries appear to be normal and functional whereas the oviduct is thin-walled and frequently contain large, watery cysts.

HJ Barnes

Tang Shun Fa

flocks for prolonged times by bird to bird passage. From building to building the IBV is easily disseminated by dust which is derived from dried mucosal secretions and feces. The airborne spread of IBV is the most common and most significant mode of transmission in areas with a dense chicken population. Long distance, even intercontinental, spread of IBV is possible by trade in infected chicks, pullets, and adult chickens and also by contaminated eggs and multiple-use packing material. Birds other than chickens may contract the disease by airborne spread from nearby infected chickens or contaminated premises. Insects (e.g., darkling beetle, *Alphitobius diaperinus*) and spiders can serve as mechanical vectors and contribute to the lateral spread within farms and between successive flocks. It is likely that several serotypes or pathotypes of IBV can circulate simultaneously in the same flock. In European countries, the IBV types consist mainly of the serotypes Massachusetts, the so-called variant viruses D274 and 1466, and more recently 793/B and B1648.

The infectivity of IBV in dust, secretions or droppings is destroyed within 30 minutes by exposure to 1 % formalin, 0.5 % peracetic acid, and various nonionic detergents. Cooking and frying table eggs completely destroys the infectivity of IBV on the outer egg-shell and in the albumen.

CLINICAL SIGNS

Types and severity of clinical signs depend on the particular strain of IBV, acquired or age-related host resistance, sex, levels of dust and noxious gases (ammonia, carbon dioxide, hydrogen sulfide) in the air, and types and levels of secondary bacterial and/or fungal infections. The following clinical manifestations are commonly differentiated in susceptible birds:

Signs in antibody-free young chicks following exposure by respiratory strains of IBV: After an incubation period of 18 to 36 hours difficulties to breath develop. At the beginning of the disease, serous nasal discharge is observed. Subsequently, secondary bacterial infections result in purulent discharge and aggravation of the disease. As late sequelae, chicks that have recovered and reached egg-laying age may turn out to be “false layers” which is the result of an acute inflammation of the epithelium of the infundibulum and subsequent obstruction.

Signs in antibody-free young chicks following exposure to nephropathogenic strains of IBV: It

appears that more broiler than layer chicks are affected. Signs consist of retarded growth, enteritis and nephritis. The latter produces an increased amount of urates in the droppings.

The protective role of maternal antibodies which circulate in the blood stream is of minor importance. Almost all maternal antibodies consist of immunoglobulin G (IgG) which is not transferred from the blood stream to respiratory, genital or kidney mucosae. Therefore, epithelial surfaces – the dominant site of virus entry – are not protected by maternal antibodies.

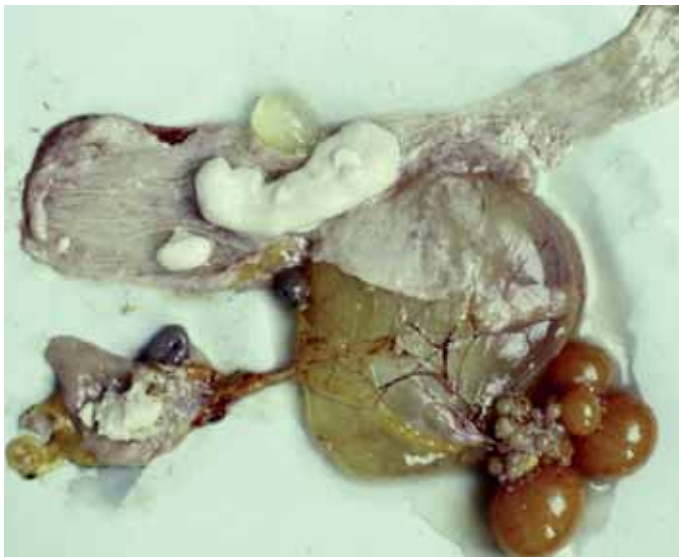
Signs in antibody-free pullets are generally less severe. Nephropathogenic, respiratory and enteric strains have been isolated from pullets displaying growth retardation, respiratory or other non-specific signs.

In addition to respiratory and nephritic lesions, layers and broiler breeders also suffer from affections of the uterus and shell-gland. Eggs laid during the acute phase of the disease contain watery egg white. The color, thickness, and stability of these eggs vary enormously within an affected flock. Usually brown-shelled eggs are white in color due to premature egg laying. Some of these eggs have additional calcium deposits on their surface. Other eggs are completely devoid of shells and have only the inner shell-membranes as an outer layer. Eggs displaying altered eggshells tend to break easily; they are not suitable for incubation and sale as table eggs. Remnants of broken eggs cause additional problems on conveyor-belts, egg-sorting and egg-grading equipment, and egg-trays.

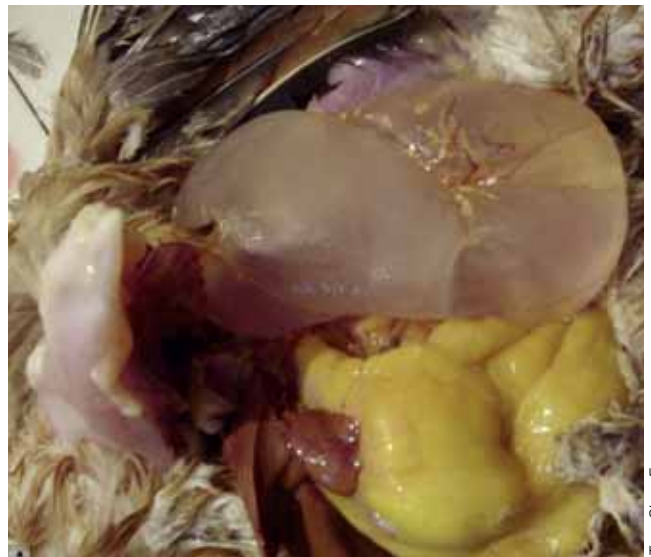
Adult male chickens might contract the disease due to infections by respiratory, enteric, and nephropathogenic strains. The gonads and the quality of semen are not severely affected.

LESIONS

Types, severity and organ manifestations are influenced by the strain of IBV involved, age, maternal or acquired immunity and kind and duration of bacterial or fungal secondary invasions. The acute mono-infection by IBV is characterized by impairment of the epithelium of the respiratory, urinary, genital, and enteric tracts. This includes edema of the epithelium, mucosa and submucosa, and almost complete loss of the ciliated epithelium in the trachea, bronchi, and uterus. Large numbers of inflammatory cells can be seen in histological sections. The recovery time from the acute phase and the transition of the disease into a chronic

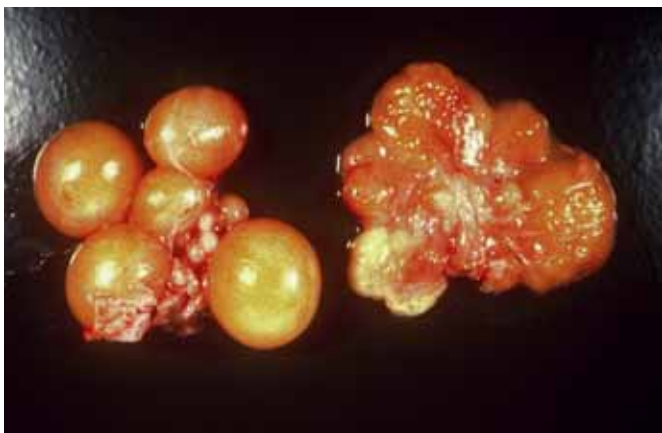


Tang Shun Fa

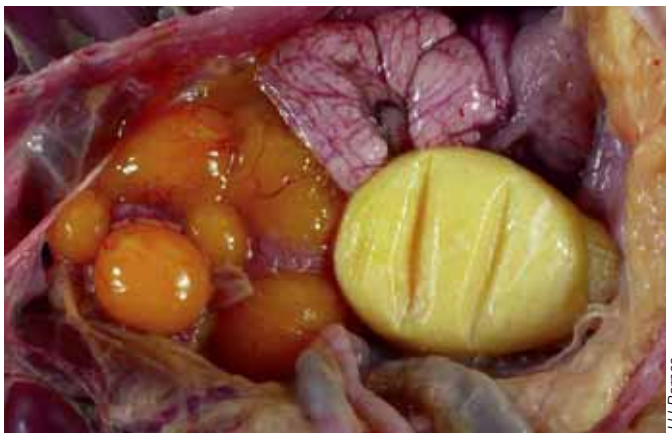

Tang Shun Fa

Fig.21.18 & 21.19: IB. "False layer" with large watery cyst in the oviduct (variant QX).



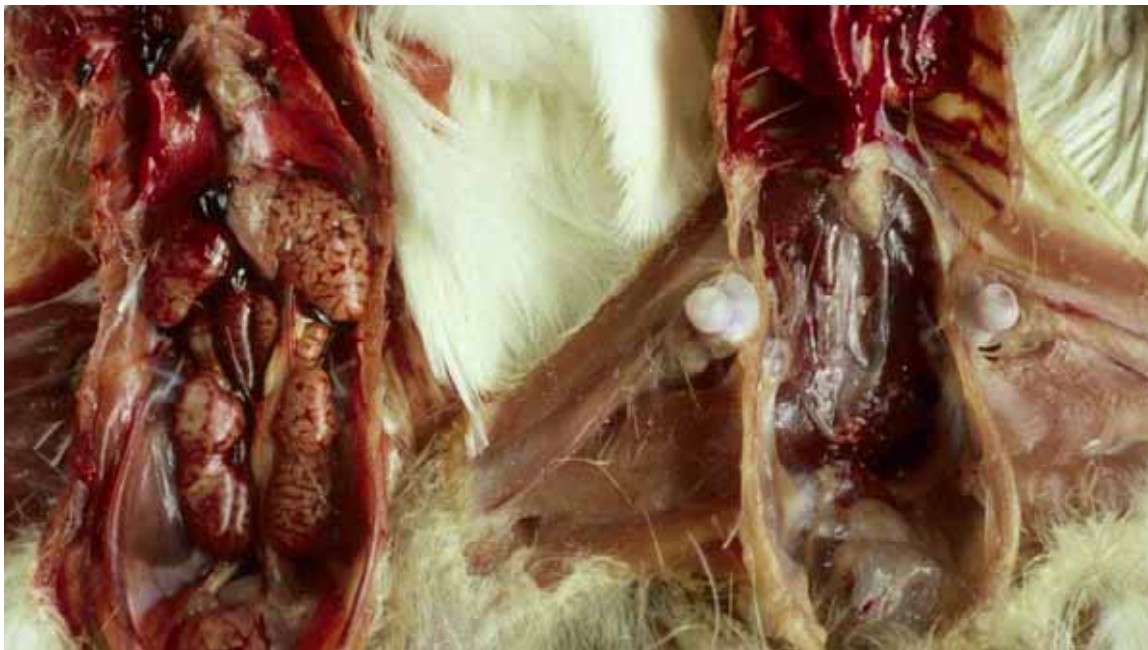
Sanders



H.J Barnes

Fig.21.20: IB. Comparison of normal ovary (on the left) and infected ovary (on the right).

Fig.21.21: IB. Abdominal laying can be seen in infected hens.



JP Picault Anses-Ploufragan

Fig.21.22: IB. On left, nephritis with renal hypertrophy. Compare with normal kidney on right (Chicken).

phase depend on a number of internal and external factors. Internal factors include immunocompetence which is influenced by age, maternal or acquired immunity, presence or absence of immunosuppressive viruses such as infectious bursal disease and chicken infectious anemia viruses and the type of secondary infections, especially *E. coli*. External factors include air quality, especially dust content, bacterial and fungal loads, ammonia and other noxious gases. Low air humidity and extremely high or low ambient temperatures tend to aggravate the disease and extend the duration of the chronic phase.

DIAGNOSIS

Clinical signs and gross pathological lesions are suggestive but not pathognomonic for the presence of IB. Histological examination of hematoxylin & eosine stained sections from respiratory organs, kidneys or small intestine are of supportive diagnostic value. Immunohistochemical examination of sections using a FITC-conjugated hyperimmune serum confirms the presence of IBV. Of paramount importance for the diagnosis is the virus isolation and characterization.

The IBV was one of the first avian viruses that were successfully propagated in embryonated fowl eggs. The chicken embryo remains the first choice for isolation of IBV. The objectives of virus isolation are (i) confirmation of the presence of IBV, (ii) determination of the serotype, and (iii) detection of concurrent avian viruses. Primary isolation of all known strains/types of IBV is equally possible in embryonated chicken eggs by inoculation of the allantoic cavity of 9 to 11 day-old eggs. Specific lesions and embryo mortality do not develop during the first three passages. Further passages of infectious allantoic fluids result in curling and dwarfing of infected embryos after five to nine days of incubation.

Confirmation of the presence of IBV has been traditionally obtained by agar gel diffusion tests using homogenized chorioallantoic membranes and precipitating chicken sera. A more advanced and more sensitive technique is serotype-specific immunofluorescence on allantoic cells obtained from infected embryos.

More recently, a highly sensitive reverse transcriptase polymerase chain reaction (RT-PCR) has been developed. Sequencing of PCR products permits differentiation of vaccine and field strains of the same serotype. The five amino acids at the cleavage site sequence are in most cases “Arg-Arg-Ser-

Arg-Arg”. The pattern of amino acid sequences is not related to pathogenicity and organ tropisms. A particular cleavage pattern may prevail in certain geographical regions.

Infectious bronchitis viruses can be adapted to multiply and to induce cytopathic changes in primary kidney cell cultures prepared from 18-20 day-old specific pathogen-free (SPF) chicken embryos or young SPF chicks. Cytopathic changes in chicken kidney cells (CKC) consist of rounding and subsequent lysis of cultured kidney epithelial cells. Neutralization tests on field sera and chessboard neutralization tests for serotyping of new IBV isolates in CKC cultures are much more economic and more sensitive than similar tests in embryonated SPF embryos.

The serodiagnosis using the neutralization test and CKC-adapted IBV strains in primary CKC cultures has two main objectives: (i) retrospective detection of field exposure within the framework of epidemiological studies and (ii) quantitative assessment of antibody levels following vaccination.

The formerly widely used agar gel precipitin test in a high salt solution cannot be recommended due to its low sensitivity as compared with the neutralization test. In addition, precipitating antibodies can be detected in reconvalescent sera only for a short period of time following field exposure of chickens.

TREATMENT

The primary effects of IBV on the epithelial surface cannot effectively be treated by any available drugs. Secondary effects due to concurrent bacterial or fungal infections can be reduced by sanitation and therapeutic measures. These include in particular optimizing the air quality by constant fresh air supply and by adjusting the ambient temperature to 15-25°C. Frequently occurring secondary infections (especially by *Escherichia coli*) require treatment after antibiotic sensitivity testing. If *Mycoplasma* spp. are present, treatment with appropriate antibiotics are recommended. The flock of chickens should be obtained from *Mycoplasma*-free breeders.

CONTROL

Due to the highly contagious nature of all strains of IBV, sanitation measures met in the past with little success. For the same reason, IBV eradication from commercial flocks was never attempted. Major emphasis has been placed for more than a half cen-

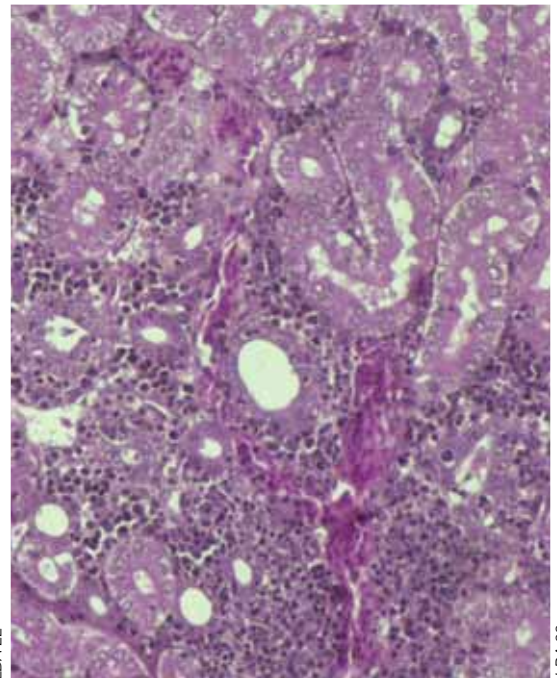
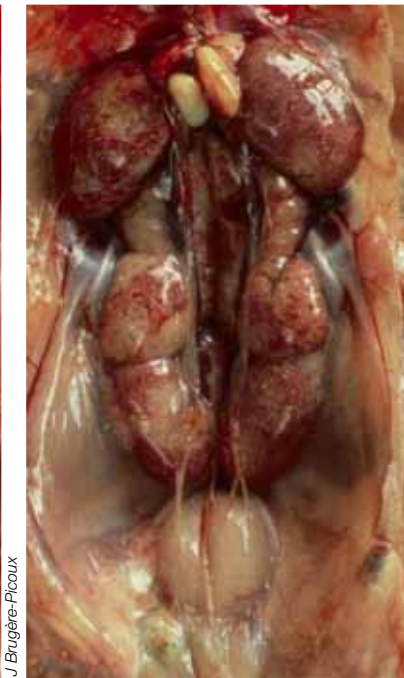
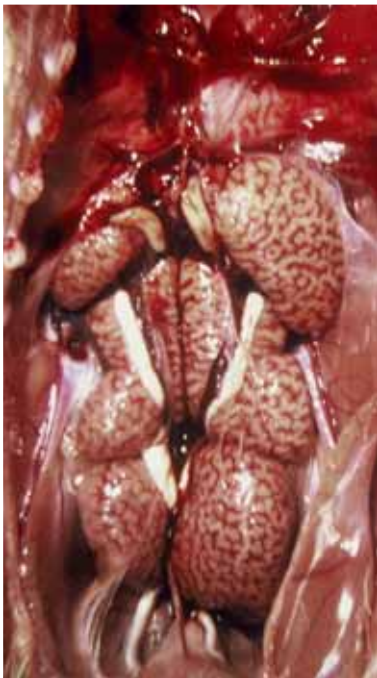

Fig.21.23 & 21.24: IB. Severe nephritis with gross swelling of the kidney and urolithiasis (left) or urate deposits (visceral gout) (right).

Fig.21.25: IB. Interstitial nephritis (hematoxylin & eosin, x 200) (Chicken).

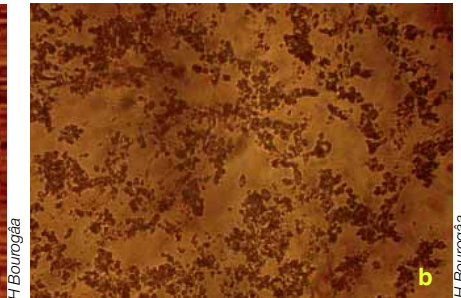
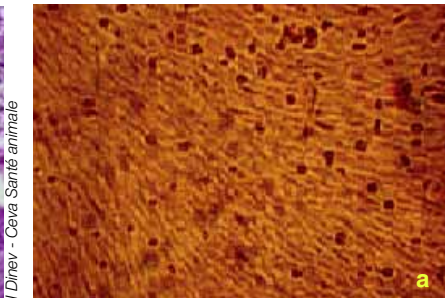
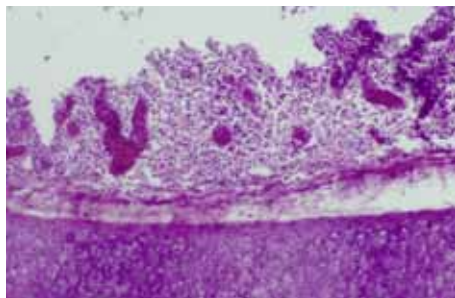


Fig.21.26: IB. Moderate to severe inflammatory cell infiltration is seen in the upper respiratory tract mucosa.

Fig.21.27 & 21.28: IB. Cytopathic effect of IBV on chick embryo fibroblasts (X100). (a) Non inoculated control; (b) Cytopathic effect with IBV.

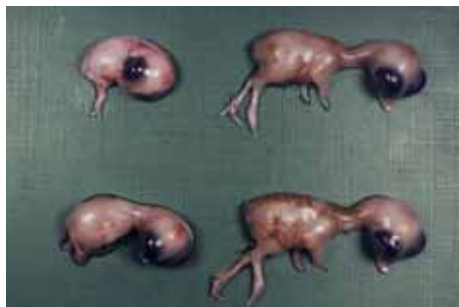

Fig.21.29 & 21.30: IB (Beaudette strain). Comparison of normal embryos (right) and curled, dwarfed and infected embryo of the same age (left) in Fig.21.29. In fig.21.30 normal embryo (b) is compared with infected embryo of the same age, seven days post-inoculation (a).

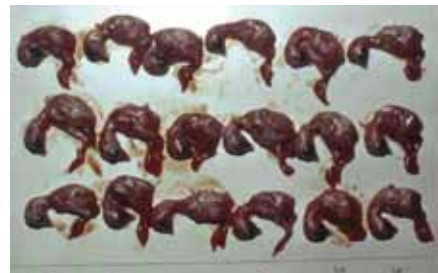

Fig.21.31 & 21.32: IB. Serodiagnosis using the neutralization test in embryonated chicken eggs (inoculation of the allantoic cavity). On top, positive serum with neutralizing antibodies that protect embryos from the virus. At bottom, negative serum without neutralizing antibodies: mortality, curling and dwarfing of infected embryos.

ture on the development of attenuated (egg-adapted) live vaccines or oil emulsion vaccines. An important prerequisite of a successful vaccination program is reliable information on the serotypes involved in a given region. Such information is usually obtained by constant and long-term flock monitoring for sero- and pathotypes of IBV. The amino acid sequence at the cleavage site may also be useful for epidemiological investigations.

In high density poultry areas, broiler and layer chicks are usually vaccinated with highly attenuated Massachusetts serotype IBV (H 120). The vaccine is administered at the hatchery by spray application. Pullets are re-vaccinated once or twice during the rearing period by less attenuated Massachusetts virus (H 52).

If one of the newly emerged serotypes is diagnosed, the attenuated virus of these strains should be used as a live vaccine. It is also common practice to apply an oil emulsion vaccine containing formalin-inactivated IBV by intramuscular injection prior to the point of lay. Such vaccines may contain additional inactivated viruses as well, e.g., Newcastle disease virus, egg-drop syndrome virus, and infectious bursal disease virus.

The duration of immunity following application of live and inactivated IB vaccines is estimated to be one year. All presently available IB vaccines protect well against clinical signs and production losses. However, these vaccines cannot prevent superinfection by IB viruses of the same and by unrelated sero- or pathotypes. Also, differentiation between antibodies due to vaccine versus field viruses is presently not possible.

REFERENCES

- Capua I et al. Co-circulation of four types of infectious bronchitis virus (793/B, 624/I, B1648 and Massachusetts). *Avian Pathol*, 1999,28:587-592
- Cavanagh D, Naqi SA. Infectious bronchitis. In "Diseases of Poultry" 10th ed. Iowa State University Press, Ames 1997, p. 511-526.
- Cavanagh D. Commentary. A nomenclature for avian coronavirus isolates and the question of species status. *Avian Pathol*, 2001,29:109-115.
- Cavanagh D et al. Detection of coronavirus from turkey poult in Europe genetically related to infectious bronchitis virus of chickens. *Avian Pathol*, 2001,30:355-368.
- Cook JKA et al. Breadth of protection of the respiratory tract provided by different live-attenuated infectious bronchitis vaccines against challenge with infectious bronchitis viruses of heterologous serotypes. *Avian Pathol*, 1999, 28:477-485
- Gough R & Alexander DJ. Avian infectious bronchitis. In "Manual for diagnostic tests and vaccines" Fourth ed. OIE, Paris, p.700-710
- Jackwood MW et al. Spike glycoprotein cleavage site recognition site analysis of infectious bronchitis virus. *Avian Dis*, 2001, 45:366-372
- Keeler CL et al. Serotype identification of avian infectious bronchitis virus by RT PCR of the peplomer (S 1) gene. *Avian Dis*, 1998, 42:275-284
- Meulemans G et al. Epidemiology of infectious bronchitis virus in broilers: a retrospective study, 1986 to 1995. *Avian Pathol*, 2001, 30: 411-421.
- Proc. of the First (1988) and Second (1998) Int. Symposium on infectious bronchitis. Eds. Kaleta EF, Heffels-Redmann U. Self Press, Giessen, Germany.
- Van Regenmortel MHV et al. Nidovirales. In "Virus taxonomy. Seventh Report of the International Committee on Taxonomy of Viruses" Academic Press, San Diego, p.827-857.

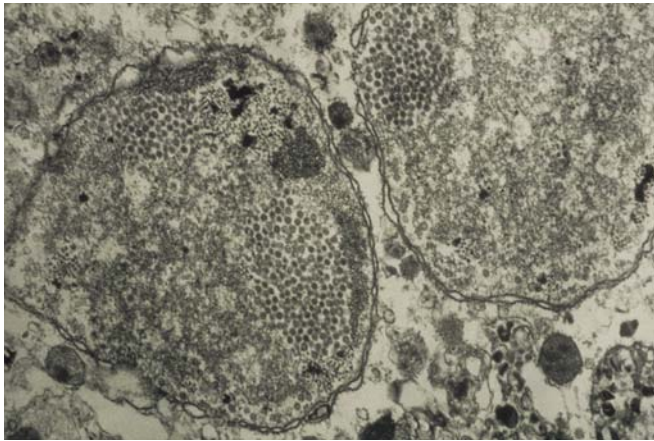


Fig.22.1: Negative stained ILT viral particles in infected tracheal cells taken by electromicroscopy.

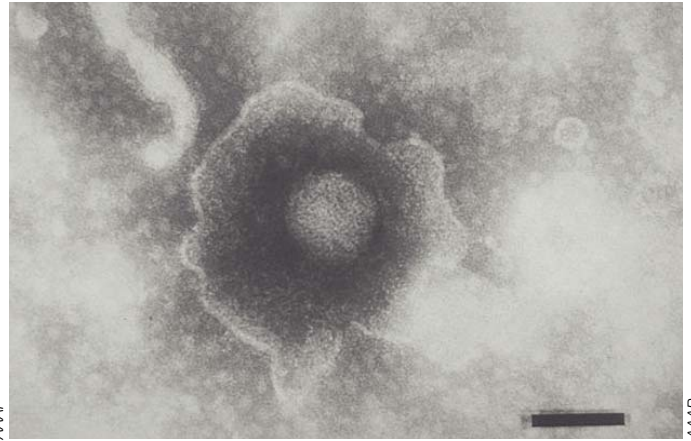


Fig.22.2: Negative stained ILTV taken by electron microscopy. The stain was 2% phosphotungstic acid at pH 7.0. The magnification bar on the slide is 100 nm. The total magnification is x180,000. The figure depicts an icosahedral tubular nucleocapsid enclosed within an envelope.



Fig.22.3 & 22.4: Chickens having difficulty breathing due to infection with laryngotracheitis.

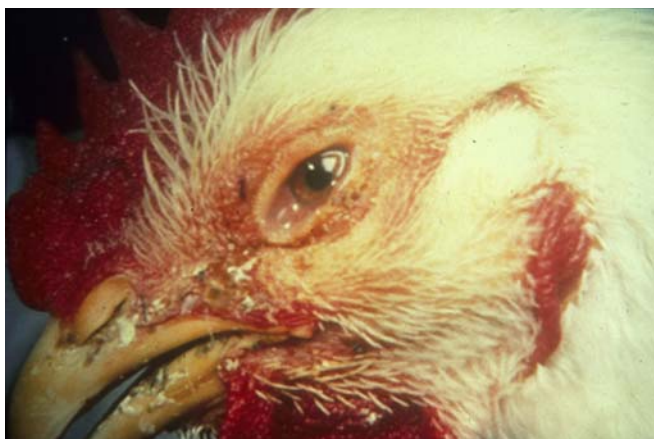

Fig.22.5 & 22.6: Chickens with conjunctivitis related to laryngotracheitis infection.

22. INFECTIOUS LARYNGOTRACHEITIS

INTRODUCTION

Infectious laryngotracheitis (ILT) is an acute viral respiratory disease primarily of chickens. Economic losses attributable to ILT have been important in many poultry producing areas throughout the United States and the world. In addition to chickens, pheasants and peafowl are susceptible to ILT infection.

ETIOLOGY & EPIDEMIOLOGY

ILT is caused by a *Gallidherpesvirus type 1* (GaHV-1) virus of the genus *Iltovirus*, subfamily *alphaherpesviridae* within the order *Herpesvirales*. Carriers are produced by previous exposure to field virus or vaccine virus. The main site of latency for ILT virus has been shown to be the trigeminal ganglion and the trachea. Inoculated birds will intermittently shed virus between 7 and 20 weeks post inoculation.

Clinical disease may be related to lapses in vaccination programs and biosecurity or the reactivation of latent virus. A PCR-Restriction Fragment Length Polymorphism (RFLP) assay of the glycoprotein E (gE) gene has been developed. Epidemiological data generated using this technique indicated that ILT outbreaks in non-vaccinated flocks originated from vaccine-derived viral subpopulations. Additionally, a recently developed nested-PCR has been developed to detect ILT DNA from formalin-fixed paraffin-embedded tissue. ILT virus was detected in respiratory cases where ILT virus was not suspected. It has been suggested that the nested PCR may be detecting low-level persistent infections or latently infected birds.

Transmission between flocks has primarily been associated with their geographical proximity and a breakdown in biosecurity. Movement of personnel, improper dead bird and manure disposal and exchanging of farm equipment have all been associated with ILT outbreaks.

CLINICAL SIGNS & LESIONS

Clinically, most flocks exhibit severe respiratory disease including difficulty in breathing and expectoration of blood from the trachea. Other flocks have only a mild respiratory disease and conjunctivitis. In some layer flocks there may be no change

in egg production, while in other cases there may be a decrease in production of 5-15% with no change in eggshell quality.

Mortality varies greatly between flocks. In broilers, this mortality has ranged from 0.7% to 50%. In pullets, the mortality ranged from 1.3% to 16%. In layers, the mortality associated with disease has ranged from 0% to 12%. Daily mortality in pullet and layer flocks does not follow a pattern, but daily mortality in unvaccinated broiler flocks characteristically doubles each day after the onset of clinical signs.

Postmortem lesions are primarily confined to the trachea. Occasionally, pneumonitis and airsacculitis are seen. The most common postmortem lesions are hemorrhage and/or caseous material in the trachea; however some flocks do not show the classical form of the disease. In these flocks, conjunctivitis, sinusitis and mucoid tracheitis may be the only lesions. Although experimentally, pulmonary and airsac lesions were consistent findings in birds affected by the aerosol route. Secondary bacterial infections are seldom seen in conjunction with ILT. Although, in broilers that break with ILT at 3 to 4 weeks of age and stay in the field for additional 3 to 4 weeks prior to processing severe *Escherichia coli*, airsacculitis has been seen. Concurrent viral infections are also uncommon.

DIFFERENTIAL DIAGNOSIS

Differential diagnosis for the mild form of the disease must include respiratory diseases such as avian influenza, infectious bronchitis, Newcastle disease and mycoplasmosis. The more severe form of the disease should be differentiated from the diphtheritic form of avian pox.

DIAGNOSIS

Historically, rapid diagnosis of GaHV-1 has been based upon postmortem lesions, histopathology, virus isolation, or immunofluorescent antibody. Additional procedures, which have been used for the diagnosis of ILT virus, include a non-isotopically labeled DNA probe, immunoperoxidase, ELISA, electronmicroscopy, and PCR. More recently, a nested-PCR has been developed to detect ILT DNA from formalin-fixed paraffin-embedded tissue. There is a high correlation between histopathology and the nested-PCR in detection of GaHV-1 cases and this test is considered an

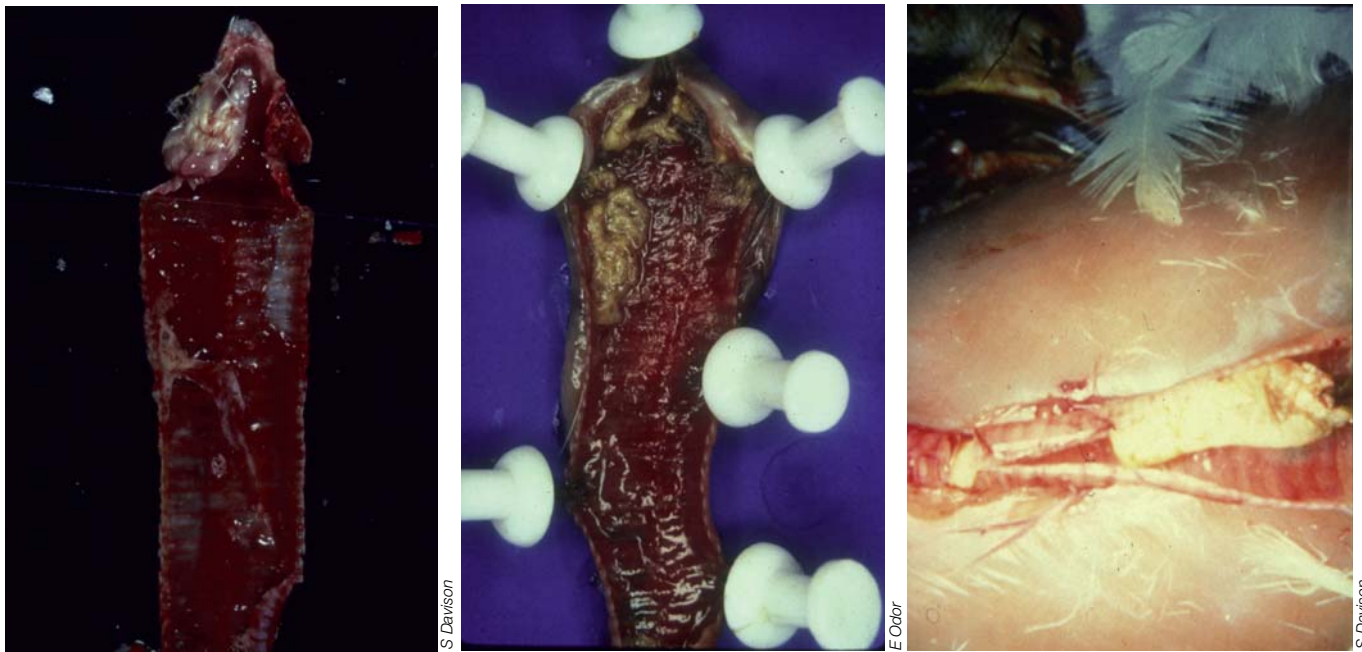


Fig.22.7, 22.8 & 22.9: Gross pathologic tracheal lesions associated with various stages of laryngotracheitis infection. Fig 22.7: Hemorrhage in the trachea. Fig 22.8 : Fibrinohemorrhagic tracheitis. Fig 22.9: Caseous plug in the trachea.

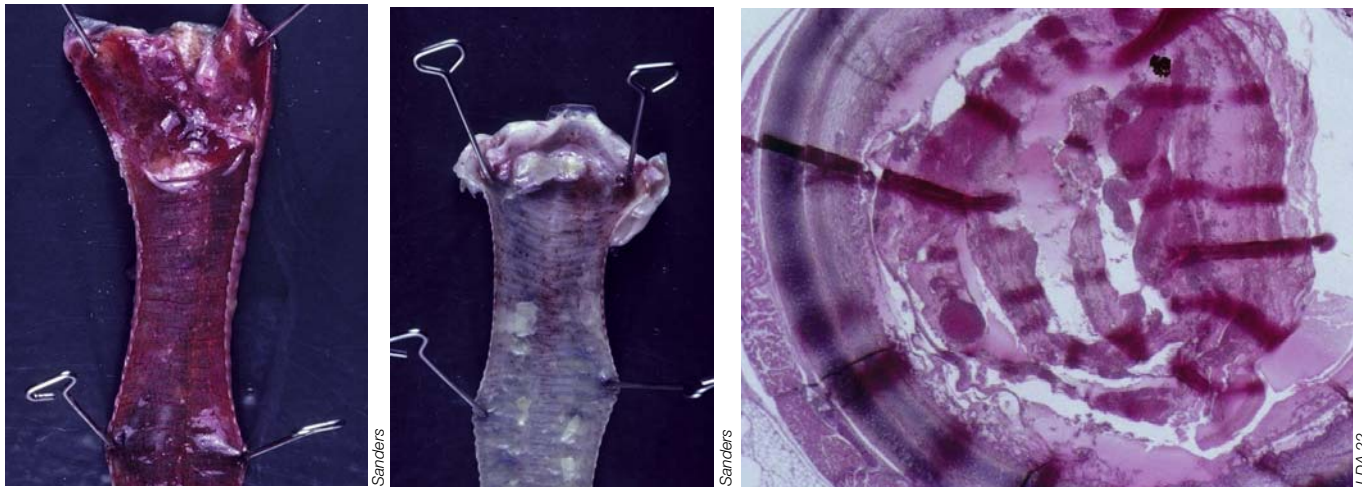

Fig.22.10 & 22.11: ILT. Other lesions of trachea with severe hemorrhagic tracheitis (on the left) and petechia and mucus in milder laryngotracheitis (on the right). Fig.22.12: ILT (histology). Blood clot in the tracheal lumen of a chicken (HES, x 25).

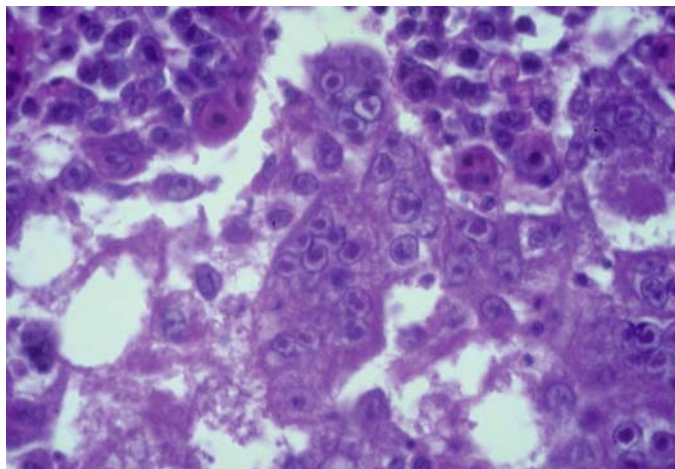


Fig 22.13: High power (x 40) micrograph of the tracheal lumen debris from a case of laryngotracheitis. Note the numerous intranuclear inclusion bodies in sloughed epithelial cells and syncytia formation.

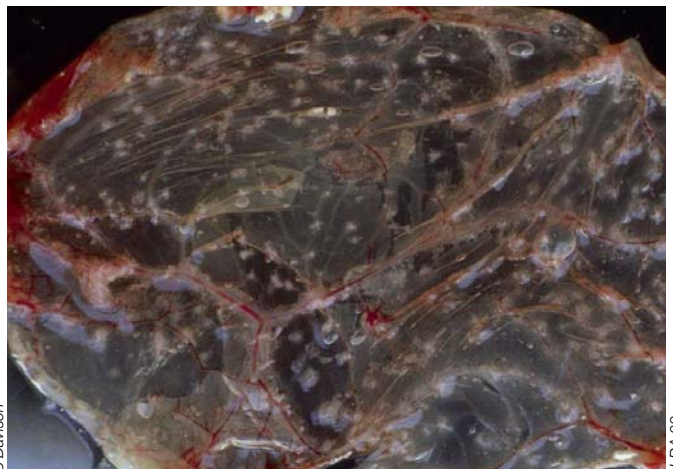


Fig 22.14: Plaques on the chorioallantoic membrane after inoculation of chicken embryos with laryngotracheitis virus.

additional tool for rapid diagnosis for GaHV-1. Serology is not a primary diagnostic tool for ILT viral infection. Immunity to ILT viral infection is due to cellular immunity rather than humoral immunity. This conclusion was based on studies where birds were bursectomized surgically at day of age, subsequently treated with cyclophosphamide therapy and then vaccinated for ILT. Birds challenged with GaHV-1 did not produce antibody but were immune to GaHV-1.

Histopathology

Microscopic lesions of the trachea include degeneration and necrosis of epithelial cells with syncytia containing the intranuclear inclusion bodies, usually found in the tracheal lumen. The inclusion bodies may be difficult to find 5 days post infection. At this time, hyperplastic non-ciliated epithelial cells line the trachea. Lesions can also be seen in the bronchi, lungs and airsacs. Pneumonia may be present in the ventral lung and surrounding primary bronchi. Fibrin, heterophils and syncytia containing intranuclear inclusion bodies may be seen in the tertiary bronchi. Airsac lesions, in experimentally infected birds, may include hyperplasia of the epithelium and syncytia with intranuclear inclusion bodies and fibrosis.

Virus Isolation

The best samples for isolation of ILT virus are tracheal exudate, tracheal tissues or lung tissues. Isolation for LT virus is by the chorioallantoic membrane (CAM) route of inoculation in 9-to-12-day-old chicken embryos. Plaques are produced on the CAM and the size of the embryo may be reduced. Cell culture in chicken embryo liver and chicken embryo kidney monolayer cultures may also be used for isolation. Cytopathic changes include the development of multinucleated polykaryocytes or giant cells with a few cells having intranuclear inclusion bodies.

TREATMENT & CONTROL

Control and prevention is through vaccination with either chicken embryo vaccines or a tissue culture vaccine. Although the manufacturer recommends eyedrop administration, the poultry industry often administers chicken embryo products by spray or water. Commercial layers and breeders are usually vaccinated twice prior to the onset of lay by eyedrop, water or spray. Broilers are usually not vaccinated unless they are in the vicinity of an outbreak or a previous outbreak has occurred on the farm. When this occurs, they are then vaccinated at 10-12 days of age in the water. New viral vectors vaccines utilizing on fowlpox virus and herpesvirus of turkey expressing GaHV-1 antigens provide

a safer vaccination alternative against ILT.

There is no antimicrobial treatment for ILT viral infection. Vaccination may be used in the face of an outbreak. Both water and spray vaccination have been used with success in reducing the spread of the disease within a flock.

REFERENCES

- Bagust TJ. Laryngotracheitis (gallid-1) herpesvirus infection in the chicken. 4. Latency establishment by wild and vaccine strains of ILT virus. *Avian Path.* 1986,15:581-595.
- Bagust TJ et al. Gallid-1 herpesvirus infection in chickens. 3. Reinvestigation of the pathogenesis of infectious laryngotracheitis in acute and early post-acute respiratory disease. *Avian Dis.* 1986,30:179-190.
- Ficken MD. Respiratory System. In: *Avian Histopathology*, 2nd ed. C. Riddell, ed. American Association of Avian Pathologists, Kennett Square, Pennsylvania. 1996, p.95-96.
- Garcia M. Update on Laryngotracheitis Research, *Proc. of the U.S. Animal Health Assoc. Transmissible Diseases of Poultry Committee*. Birmingham, Alabama. 2001, p.627-630.
- Garcia M. Tracking Infectious Laryngotracheitis (ILT) in the Field. AAAP Respiratory Disease Symposium, Boston, Massachusetts. 2001.
- Guy JS et al. Rapid diagnosis of infectious laryngotracheitis using monoclonal antibody-based immunoperoxidase procedure. *Avian Path.* 1992,21:77-86.
- Hanson, LE & Bagust TJ. Laryngotracheitis. In: *Diseases of Poultry*, 9th ed, B.W. Calnek, ed. Iowa State University Press, Ames, Iowa. 1991 p. 485-495.
- Hughes CS et al. Demonstration in live chickens of the carrier state in infectious laryngotracheitis. *Res Vet Sci*, 1987,42:407-410.
- Keam L et al. Detection of infectious laryngotracheitis virus in chickens using a non-radioactive DNA probe. *Avian Dis.*, 1991,35:257-262.
- Purcell, DA & McFerran JB. Influence of method of infection on the pathogenesis of infectious laryngotracheitis. *J. Comp Path.* 1969,79:285-291.
- Roberston GM. The role of bursa-dependent responses in immunity to infectious laryngotracheitis. *Res Vet Sci*. 1977,22:281-284.
- Tripathy DN & Hanson LE. Laryngotracheitis. In: *Isolation and Identification of Avian Pathogens*, 3rd ed. H.G. Purchase, ed. Kendall/Hunt Publishing Company, Dubuque, Iowa. 1989, p.85-86.
- Williams RA et al. Demonstration of sites of latency of infectious laryngotracheitis virus using the polymerase chain reaction. *J Gen Virol.* 1992, 73:2415-2420.
- Williams RA et al. A comparison of direct electron microscopy, virus isolation, and a DNA amplification method for the detection of avian infectious laryngotracheitis virus in field material. *Avian Path.* 1994, 23:709-720.
- York JJ & Fahey KJ. Diagnosis of infectious laryngotracheitis using a monoclonal antibody ELISA. *Avian Path.*, 1988,17:173-182.



Fig.23.1: AE. Clinical signs of ataxia and inability to stand.

HL Shivaprasad - AAAP

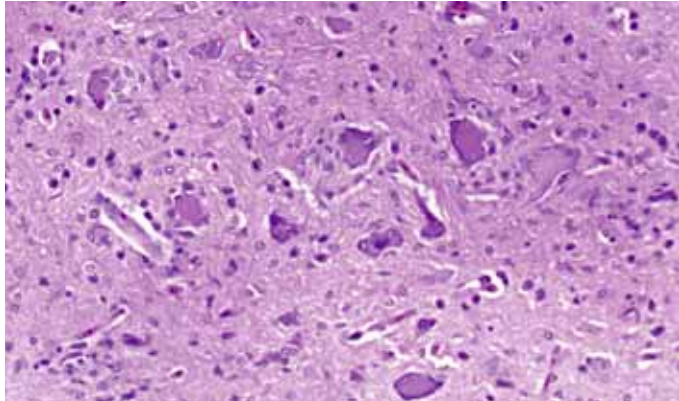


Fig.23.3: AE (brain). Neuronal swelling and mild increase in glial cells.

HL Shivaprasad

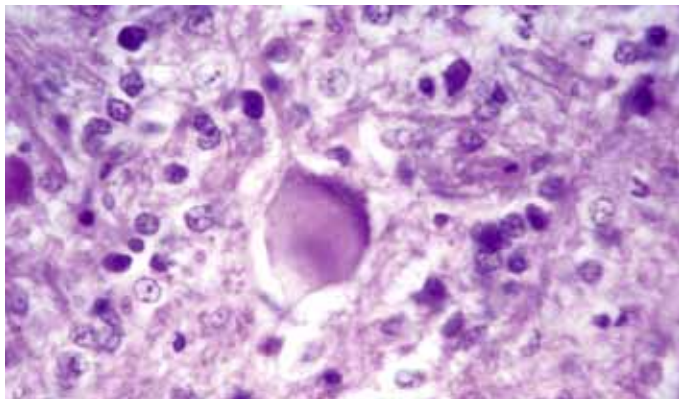


Fig.23.5: AE (brain). Central chromatolysis of the neuron.

HL Shivaprasad - AAAP

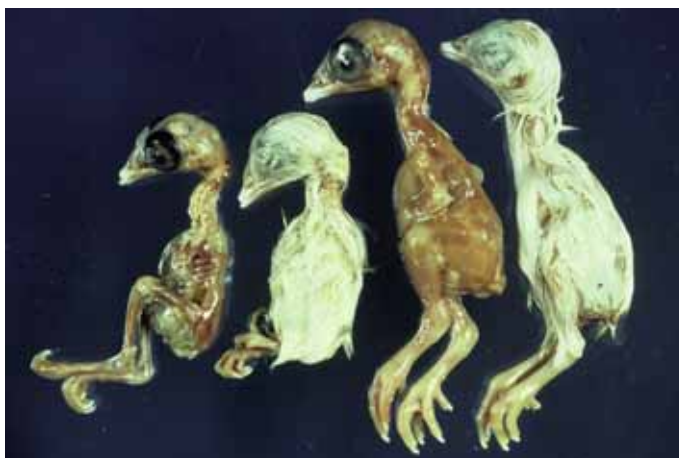

Fig.23.7: AE (21 day-old embryos). Severe stunted birds on the left inoculated with AE virus at 5 days of incubation. Birds on the right are normal control birds.

HL Shivaprasad - AAAP

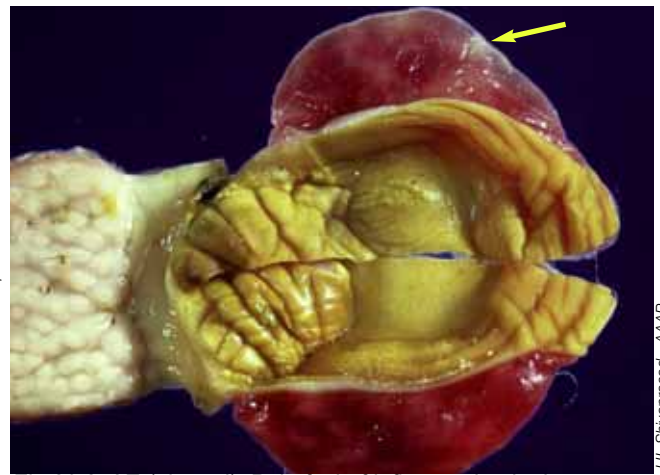


Fig.23.2: AE (gizzard). Pale foci of inflammation in the musculature (arrow).

HL Shivaprasad - AAAP

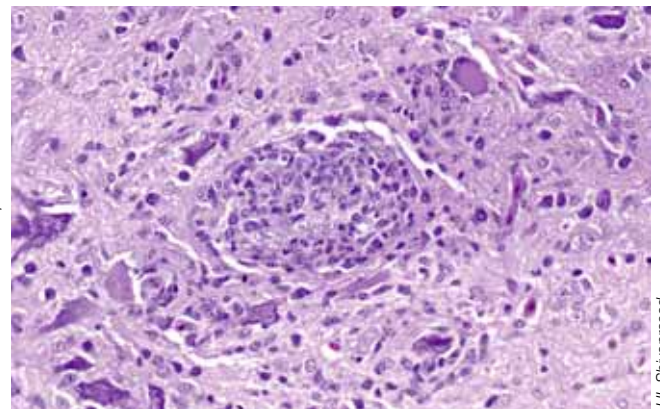


Fig.23.4: AE (brain). Severe perivascular cuffing and a swollen neuron.

HL Shivaprasad

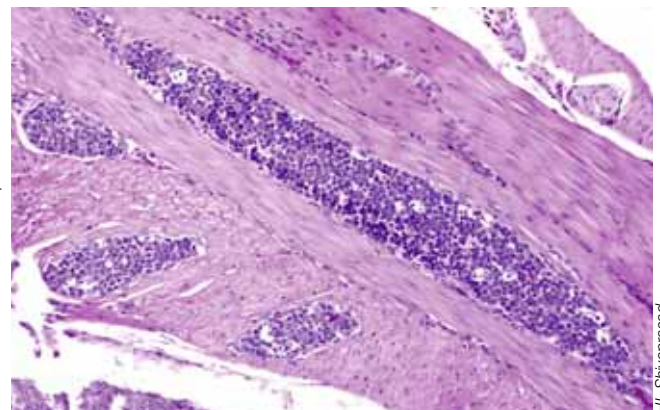


Fig.23.6: AE (proventriculus). Multifocal severe infiltration of lymphocytes in the muscular layer.

HL Shivaprasad

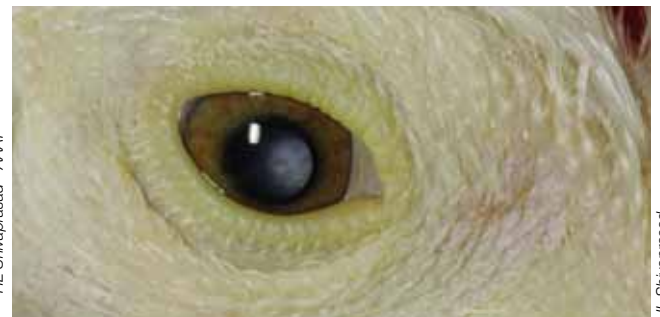

Fig.23.8: AE (eye). Cataract in a white Leghorn pullet that had AE when young.

HL Shivaprasad

23. AVIAN ENCEPHALOMYELITIS

INTRODUCTION

Avian Encephalomyelitis (AE) is an infectious viral disease of chickens, turkeys, quails and pheasants. AE is characterized by neurological signs such as ataxia and paralysis in young chickens and transient drop in egg production in layers. The disease is often called “epidemic tremor” because of the characteristic head movements in young chickens. Survivors often develop cataracts later in life.

ETIOLOGY & EPIDEMIOLOGY

AE is caused by a member of the *Picornaviridae* family. The virus, distantly related to Hepatitis A virus, is placed in the *Tremorvirus* genus. Isolates of AE are enterotropic but some show tropism to the nervous system. But there are no serological differences among the isolates of AE. The virus is shed in the feces during infection and the virus can be transmitted orally. The virus can survive in the environment for long periods of time. The disease can spread from flock to flock by various means including fomites. AE occurs worldwide and it is most common in chicks 1 to 3 weeks of age. Turkey poults, pheasants and quails can also be infected naturally. AE is rare now in most countries due to vaccination.

Adult non vaccinated chickens if exposed during egg production can produce a number of eggs that may be infected and hatch as infected chicks. These chicks can shed virus and transmit the disease to hatch mates and brood mates resulting in clinical signs by 7 days of age. Chicks exposed to AE virus after 3 or more weeks of age do not develop neurologic signs but can have characteristic histopathologic lesions. Chicks with maternal antibody are protected from AE.

CLINICAL SIGNS & LESIONS

In 1-3 week-old chicks, clinical signs can range from inappetance, weakness, ataxia, paralysis, and opisthotonus to prostration and death. Fine head and neck tremors can also be observed. Morbidity can range from 40 to 60% and mortality from 25 to 50% depending on whether the chicks came from immune birds or not. Those that survive may not grow well and produce eggs normally. Some of the survivors develop cataracts and have impaired vision. If mature birds become infected they can experience a temporary drop in egg production of 5 to 10% lasting from one to two weeks.

There are no significant gross lesions seen except for pale areas in the muscular layer of the gizzard. Microscopically there is often disseminated non-suppurative encephalomyelitis characterized by multifocal severe perivascular cuffing by lymphocytes and gliosis randomly scattered throughout. Swelling and chromatolysis of neurons in *nuclei* of the *nucleus rotundus* and *nucleus ovoidalis* in the mid brain and cerebellum and in combination with mild to severe infiltration and aggregation of lymphocytes in the muscular layers of the proventriculus have been considered as pathognomonic lesions of AE. Other microscopic lesions that have been associated with AE include lymphocytic inflammation of the pancreas, myocardium, skeletal muscles, nerves and muscular layers of the gizzard, crop and esophagus.

DIAGNOSIS

A presumptive diagnosis of AE can be made based on typical clinical signs of neurological signs in young chicks. Microscopic lesions in the brain and proventriculus coupled with immunohistochemistry (IHC) should help confirm the diagnosis. Other tests such as serological test (ELISA), Fluorescent Antibody (FA) test on the brain smears and Polymerase Chain Reaction (PCR) on the brain are also useful if reagents are available.

Virus isolation is best performed in 5 to 6 day-old embryos by inoculating brain material into the yolk sacs. The chicks are hatched and observed for typical clinical signs during the first 7 to 10 days of life. This test is expensive and time consuming.

When AE is suspected in layers experiencing drop in egg production, serologic tests are suitable for diagnosis. However, history of vaccination should be taken into consideration while interpreting serologic titers.

TREATMENT & CONTROL

A permanent immunity to AE develops within 10 to 14 days in immunologically competent chicks, i.e., after 3-4 weeks of age.

To provide maximum protection in chicks, breeding flocks can be vaccinated after 8 weeks of age and at least one month before egg production.

Genus	Species	Disease
Aviadenovirus (Group I Adenoviruses)		
Chicken, quail	Fowl adenovirus (FAvV) 5 species A-E 1-12 serotypes	Inclusion body hepatitis, hydropericardium syndrome, gizzard erosions, quail bronchitis, <i>etc.</i>
Goose	Goose adenovirus (GoAdV) 1-3 serotypes	Aviadenovirus infection in geese
Duck	Duck adenovirus B (DAdV 2)	Aviadenovirus infection in duck
Pigeon	Pigeon adenovirus B (PiAdV 2)	Aviadenovirus infection in pigeon
Turkey	Turkey adenovirus B (TAdV) 1-2	Aviadenovirus infection in turkey
Siadenovirus (Group II Adenoviruses)		
Turkey	Turkey adenovirus A (TAdV 3)	Hemorrhagic enteritis (turkey)
Pheasant		Marble spleen disease (pheasant)
Chicken		Avian adenovirus splenomegaly (chicken)
Atadenovirus (Group III Adenoviruses)		
Chicken	Duck adenovirus A (DAdV-1)	Egg drop syndrome

Tabl.24.1: Classification of adenoviruses in poultry.

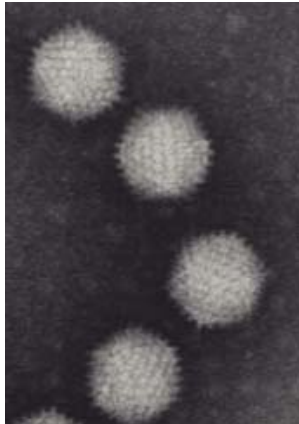


Fig.24.1: Negatively stained *Aviadenovirus* particles.



Fig.24.2 & 24.3: IBH. Birds showed lethargy, huddling with ruffled feathers and lack of appetite.




Fig.24.4: IBH. Yellow mucoid droppings may be seen.

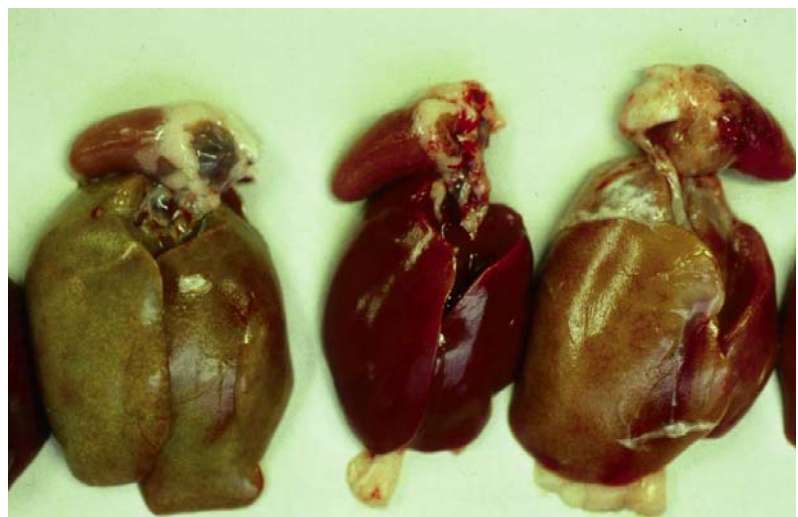

Fig.24.5: IBH. Enlarged pale and friable livers. Compare with the normal liver in the middle.

24. AVIADENOVIRUS (INCLUSION BODY HEPATITIS)

INTRODUCTION

The first recognized adenoviral infections of birds were quail bronchitis and chicken embryo lethal orphan (CELO) viruses, which were known in 1949 and 1957, respectively. Later, inclusion bodies in chicken livers were described in 1963, followed by the isolation of a “new agent” of a disease called “inclusion body hepatitis (IBH)” in 1973. However, for many years the exact role of adenoviruses in causing avian diseases was unclear. Adenoviruses are suspected of playing a secondary role in causing many syndromes. For instance, the presence of immunosuppressive viruses, such as chicken anemia virus (CAV) or infectious bursal disease virus (IBDV) has been reported to enhance the pathogenicity of some adenoviruses to cause IBH. However, there is evidence that adenoviruses cause IBH without a requirement for other pathogens. Today, IBH has a worldwide distribution, affecting domestic species of all ages, and with indication that the incidence of the disease is increasing.

ETIOLOGY & EPIDEMIOLOGY

The adenoviruses are members of the family *Adenoviridae*, which is divided in four genera namely *Mastadenovirus* infecting mammals, and *Aviadenovirus*, *Siadenovirus*, and *Atadenovirus* infecting birds. The latter three genera are classified as Group I, II and III avian adenoviruses respectively (see Tabl.24.1).

Adenoviruses are icosahedral, non-enveloped double-stranded DNA viruses that range in size from 70 to 100 nm and have 252 capsomeres surrounding a core. Adenoviruses replicate in the nucleus, producing characteristic inclusion bodies. With respect to several characteristics of the virion, such as virus morphology or genome organization, which are relevant for diagnostic purposes, the avian adenoviruses are very heterogeneous. Consequently, the diagnosis of avian adenoviruses differs significantly among the three different groups (see Chap.II.25 and II.26 for groups II and III).

Avian adenoviruses show remarkable resistance to heat inactivation although differences in sensitivity between strains have been recorded. Some strains survive 60°C or even 70°C for 30 minutes. The stability of these viruses to heat is greater when they are sus-

pending in monovalent cations compared to divalent cations, as with other DNA viruses. They are resistant to lipid solvents and to pH 3 to 9. However, adenoviruses are sensitive to formaldehyde.

At least 12 serotypes of fowl *Aviadenovirus* have been recognized on the basis of virus neutralization tests (with several strains in each serotype). These serotypes and the other aviadenoviruses share a common group antigen. Under a new classification scheme, which considers additional criteria, such as calculated phylogenetic distance and restriction fragment length polymorphism analysis of the genome, the 12 serotypes were assigned to one of five virus species i.e., Fowl adenovirus (FAdV) A-E. Only serotype 1 (Fowl adenovirus A or FAdV-A) has haemagglutination activity, but it agglutinates only rat red blood cells. Exposure to one serotype confers no immunity to other serotypes within the group I. Similarly, infections with a strain of the group I will not protect against infections with viruses from the group II or III. For these reasons it is not uncommon to isolate two serotypes from the same bird and a broiler flock may have four or more serotypes present. There is also little protection between the 12 serotypes of aviadenoviruses. Considerable exchange of serotypes may occur when commercial flocks are made up of the progeny of several parent flocks. At sexual maturity a bird may have been infected with the majority of the 12 recognized serotypes.

Following experimental infection of specific-pathogen-free (SPF) chicks in the first days of life, using natural routes of exposure, initial growth of fowl adenoviruses occurs mainly in the intestinal epithelium, followed by a viraemia, and the presence of the virus in many organs (liver, kidney, respiratory tract, bursa of Fabricius, spleen and bone marrow). However, in the field, infections with aviadenovirus are not normally detected during the first few days of life although isolations from 3 weeks onwards are common. In naturally occurring infections, aviadenovirus is excreted in the feces for about 3 weeks, with the peak excretion occurring between 4 to 7 days after infection. Certainly, birds can excrete one serotype in spite of high levels of neutralizing antibody to other serotypes.

The isolation of an adenovirus from the appropriate organ (e.g., the trachea of a bird suffering from tracheitis) does not necessarily mean that it is the etio-

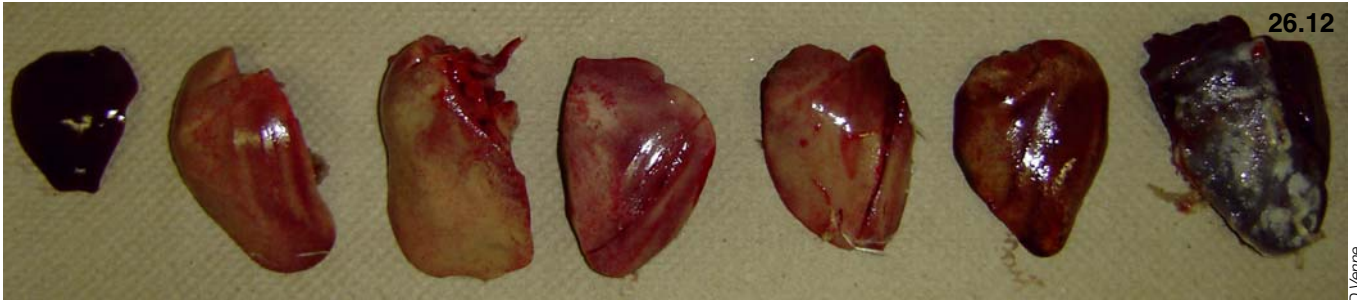
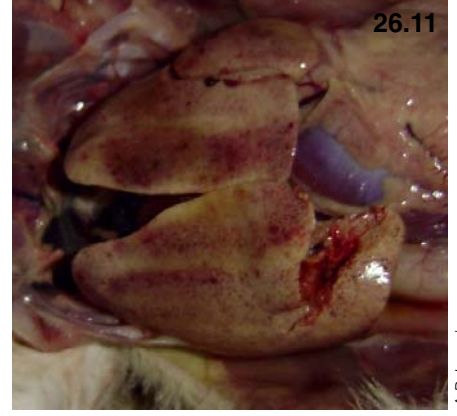
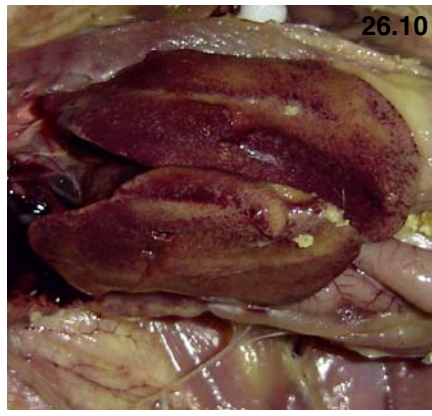
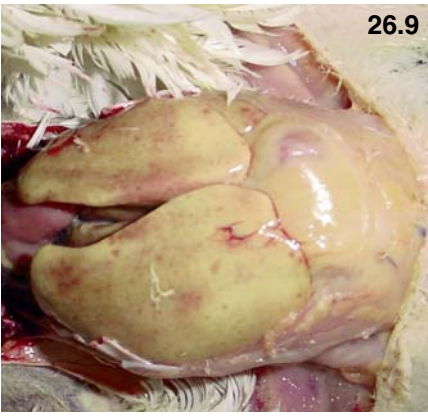
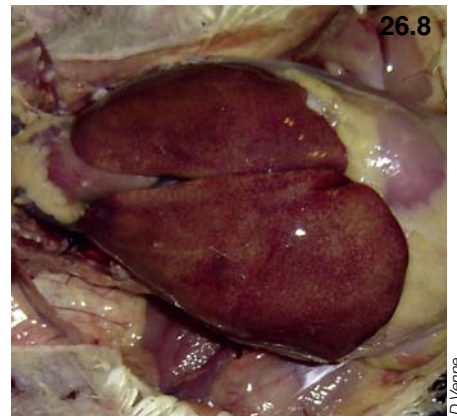
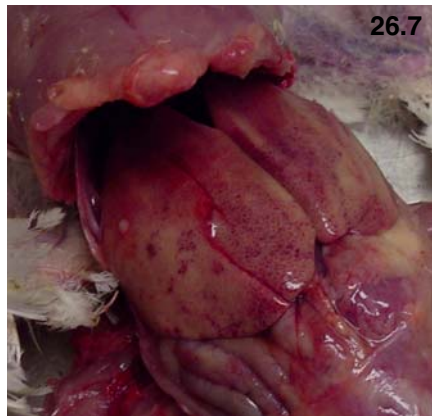
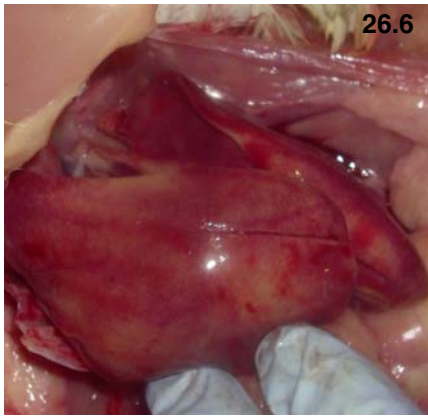


Fig.24.6, 24.7, 24.8, 24.9, 24.10, 24.11 & 24.12: IBH. A variety of liver lesions can be seen, with hemorrhages of various intensity and size. Compare with normal liver on the left in Fig.24.12.

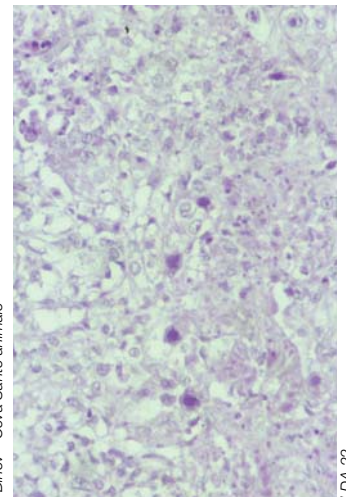
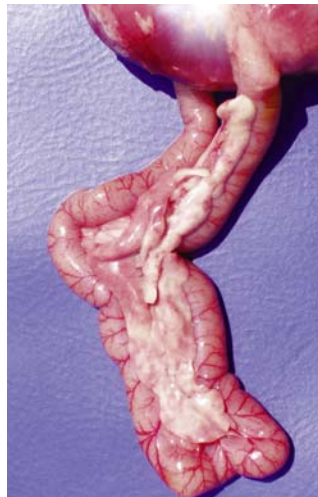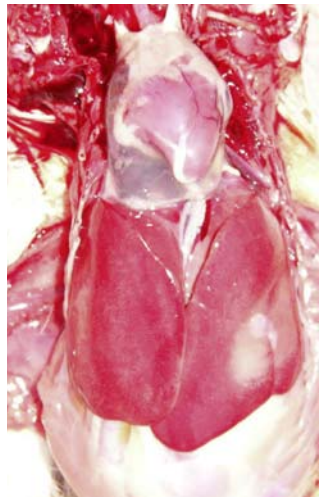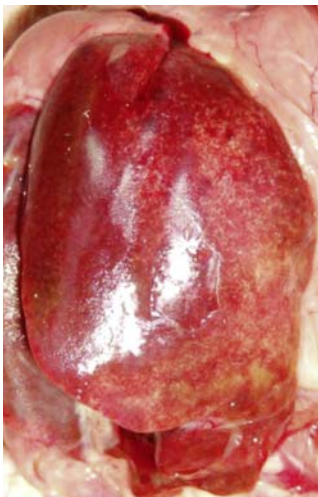


Fig.24.13: IBH. More rarely, macroscopically visible necrotic foci could be detected in the liver.

Fig.24.14: Hydropericardium syndrome is frequently associated with IBH.

Fig.24.15 & 24.16: Necrotic pancreatitis with focal necroses can be observed in aviadenovirus outbreaks.

logical agent of the disease. Such an isolate may be also a latent virus reactivated by the disease process. Birds can be carriers during all their life. In laying hens, aviadenoviruses may be transmitted through the egg, particularly around the time of peak egg production. Presumably, the stress associated with egg production or the increased level of sex hormones at this time causes reactivation of the virus. Chicks hatching from infected eggs may excrete the virus in feces from hatching although virus excretion is often detected in the flock at 2-4 weeks of age.

Horizontal spread of virus through all excretions is possible with the highest titers being in feces. Aerial spread between farms occurs when cleaning of depopulated houses takes place and the dust created transmits infection between farms. Spread by fomites, such as egg trays and egg trolleys, personnel, and transport can also occur. Following natural infection the incubation period of the virus ranges from 24 to 48 hours.

CLINICAL SIGNS & LESIONS

Although aviadenoviruses have been isolated from a number of clinical conditions, there is no clear evidence for a primary role in disease causation. However, aviadenoviruses have been most commonly associated with IBH (mainly types D and E), hydropericardium syndrome (type C), gizzard erosions (type A), and respiratory diseases. Aviadenoviruses have also been suspected as a cause of egg production problems in laying hens and viral arthritis/tenosynovitis. However, poor success has been achieved in experimental reproduction to confirm these hypotheses.

Inclusion body hepatitis (IBH)

Inclusion body hepatitis of chickens was first described in the U.S. in 1963. Since then, the disease has been reported worldwide, including Canada, the U.K., Australia, Italy, France, and Ireland. A sharp rise in severity and occurrence of IBH has been reported. This disease is usually seen in 2 to 3 week-old broilers (sometimes as young as 4 days to 7 weeks of age). Other species, such as pigeon, guinea-fowl, psittacines, or turkey may be affected. Naturally occurring outbreaks have been associated with a wide spectrum of serotypes. Aviadenoviruses are primary pathogens for IBH although co-infection with IBDV or CAV has been reported to increase pathogenicity.

IBH is characterized by a sudden increase of mortality that generally peaks within 3 to 4 days and ceases within 9 to 14 days. Mortality normally ranges from 2 to 10%. However, there have been outbreaks in which mortality has reached 30% depending of the pathogenicity of the virus, immune status of the affected birds,

and concurrent secondary infections. Clinically, the birds show lethargy, huddling with ruffled feathers, stooping, inappetence, and yellow and mucoid droppings may be seen. Overall feed conversion and weight gain are usually depressed.

Gross lesions in dead birds include an enlarged, pale, and friable liver sometimes with necrotic foci. Hemorrhages are frequently seen in the liver and sometimes in leg and breast muscles. The kidneys are enlarged, pale, and mottled with multiple hemorrhages. In some cases, hydropericardium can be observed. Necrotizing pancreatitis and intranuclear inclusion bodies have also been reported in some outbreaks, particularly in guinea fowl. In addition, enlarged spleens and thymus atrophy can be seen in most dead birds. Anemia, icterus of the skin and subcutaneous fat, hemorrhages in various organs, and bone marrow degeneration are usually present, but vary in severity. In some cases, gizzard erosions can be seen. Microscopically, there are necrotic focal lesions in the gizzard. In the liver, eosinophilic (or basophilic) inclusion bodies are present in the hepatocytes.

Hydropericardium syndrome

This condition was first recognized from the village of Angara near Karachi in Pakistan in 1987 hence named "Angara" disease. The disease is similar to IBH with higher mortality ranging from 20 to 80% in broilers. Hydropericardium syndrome is characterized by the accumulation of up to 10 ml of fluid in the pericardium. Aviadenoviruses belonging mostly to serotype 4 have been implicated in the causation of this condition.

Hydropericardium syndrome affects mainly broiler chicks 3 to 6 weeks of age and is caused by FAdV-4. With a course of 7 to 15 days, Hydropericardium syndrome is mainly characterized by rapidly increasing mortality. During the last stages of disease, affected birds exhibit dullness, depression, ruffled feathers, huddling, ventral recumbency, and closed eyes.

A build-up of clear or yellowish brown, thin fluid in the pericardium is the major post-mortem finding of Hydropericardium syndrome. Changes observed in other body organs include discolored and enlarged liver with zones of focal necrosis and hemorrhage, edematous and congested lungs, and pale kidneys with enlarged tubules due to urate deposits. Histological section of the liver shows minute multifocal areas of coagulative necrosis, mononuclear cell infiltration, and the presence of basophilic intranuclear inclusion bodies in the hepatocytes. Other histopathological changes include lymphocytolysis and cyst formation in the bursa of Fabricius, thymus, and spleen.

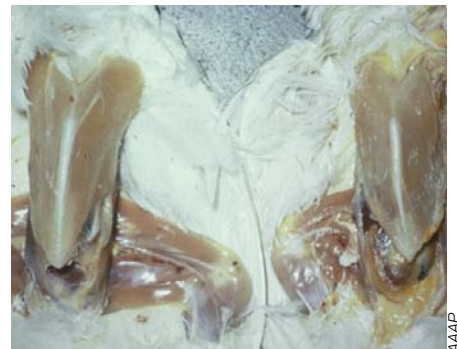
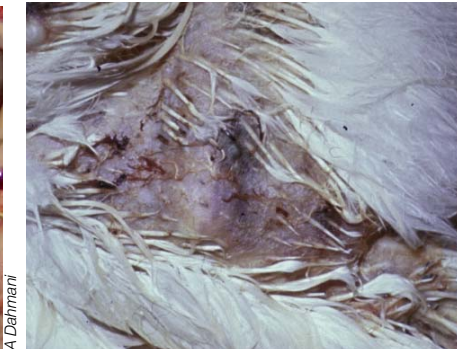
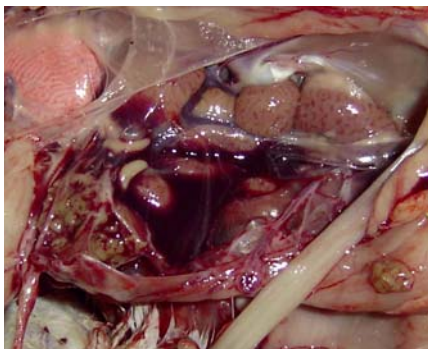


Fig.24.17: IBH. The kidney frequently are swollen, pale and mottled with multiple hemorrhages.

Fig.24.18: IBH. Anemia is attributable to hemorrhage, evident even in the subcutis of the intact chickens.

Fig.24.19: IBH. Icteric musculature and fat deposits.

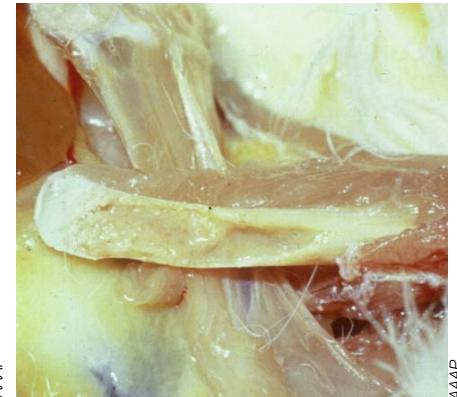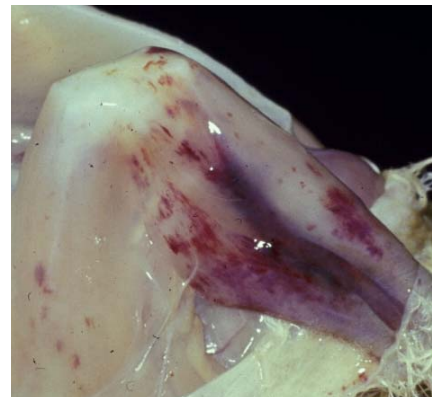

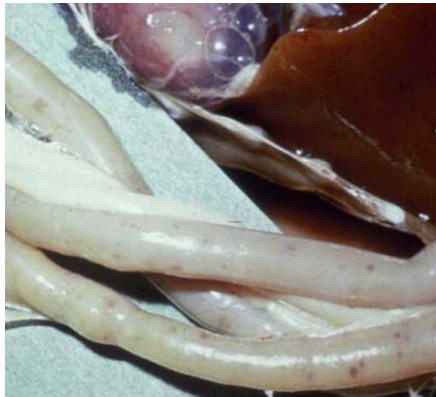
Fig.24.20, 24.21 & 24.22: IBH. The hemorrhages observed in many organs (e.g., intestines with numerous petechiae in Fig.24.20) and muscles (Fig.24.21) are the result of aplastic anemia which is likely related to co-infection with CIA virus. This aplasia is clearly visible in the proximal part of the femur (Fig.24.22). The discoloration of the bone marrow is due to replacement of hematopoietic elements by adipose tissue.

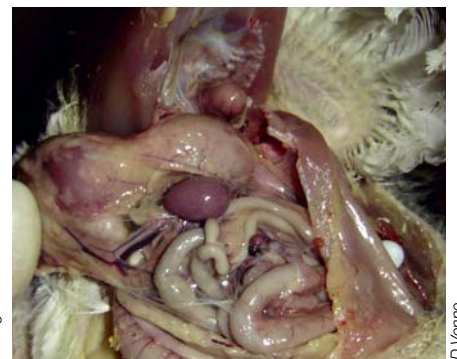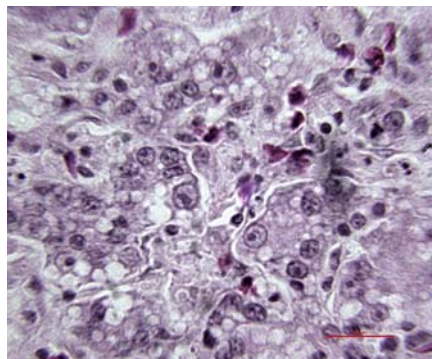
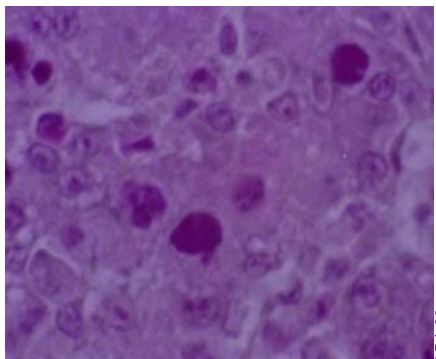


Fig.24.23 & 24.24: IBH. In the nuclei of hepatocytes basophilic or eosinophilic inclusion bodies are typical in IBH. These inclusion bodies are usually dense and can occupy the entire nuclear inner space (on the left, in pigeon). Other are round or irregularly shaped and surrounded by a light halo (on the right, in chicken).

Fig.24.25: HCl. Splenomegaly.

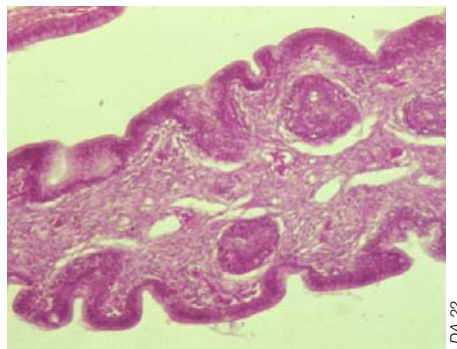
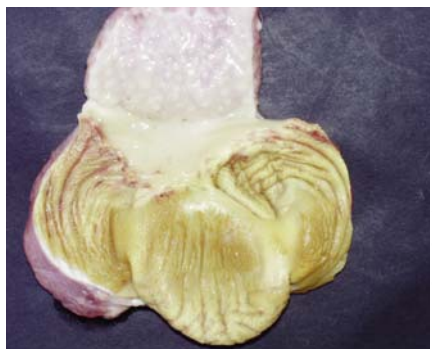
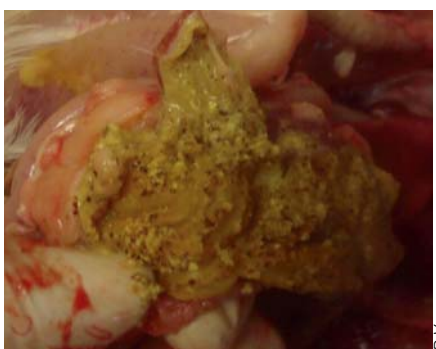
Fig.24.26 & 24.27: IBH. In some cases, gizzard erosions can be seen.

Fig.24.28: HCl. Lymphocytic depletion without inflammatory reaction is consistently seen in the bursa of Fabricius.

Gizzard erosions

There have been several reports describing outbreaks with gizzard erosions in broilers infected with FAdV-1 and FAdV-8 strains. The striking feature of the disease is that affected birds die with no evident clinical signs. At necropsy, the gizzard shows several black areas, and is filled with blood stained fluid.

Respiratory disease

Aviadenoviruses are frequently isolated from the respiratory tract of chickens with respiratory disease. But, with the exception of Quail bronchitis virus (an FAdV-1 strain) (see Chap. VI.96), it is unlikely that most aviadenoviruses are significant causes of respiratory disease.

Tenosynovitis

Although experimental reproduction of tenosynovitis has not been successful, isolates of adenoviruses have been recovered from chickens with tenosynovitis.

DIAGNOSIS

The diagnosis of adenovirus infections in poultry is in most cases based on histological investigations and detection of intranuclear inclusion bodies in hepatocytes or detection of the antigen or virus particles using immunofluorescence test or electron microscopy. More recently, polymerase chain reactions (PCR) has been used to diagnose all three groups of avian adenoviruses. In fact, PCR is the method of choice for direct identification of FAdVs, whereas serological methods are of negligible importance for diagnosis due to the extensive occurrence of antibodies to the viruses in most birds. However, the double immunodiffusion test and neutralization test can be used to differentiate FAdV subgroups and serotypes, respectively, based on adenovirus group-specific, and type-specific, antigenic determinants.

The isolation of the aviadenoviruses using chicken embryo liver (CEL) cell culture and chicken embryo fibroblast cell culture with further identification and determination of the pathogenicity seems to be very important, since the pathogenicity of the isolates within the same serotype can widely differ. Chicken embryo liver cells are preferred for diagnostic purposes because of their greater sensitivity than other cells. Then, cross neutralization tests and/or molecular biological tools are necessary to serotype the isolated virus.

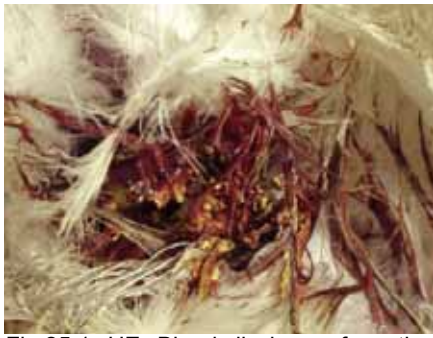TREATMENT & CONTROL

Adenovirus infection can be prevented through appropriate disinfection of the barn and equipment,

tight biosecurity measures, and good ventilation. Biosecurity practices are the primary and essential step to prevent the infection. To avoid vertical transmission, eggs from primary breeding flocks whose progeny have consistently been affected by IBH should not be used for hatching. However, in countries with high infection pressure (e.g., Australia, India, Pakistan and Mexico) the disease has been brought under control by formalin-inactivated vaccines prepared from liver homogenates from infected birds or by inactivated cell culture. Killed vaccines are used in breeders to interrupt vertical transmission of the virus and to deliver maternal antibodies to progenies. Protection is serotype specific. Vaccination against FAdV-8 and FAdV-4 is performed in Australia and the USA, and Asia and South America, respectively. Autogenous vaccines are also used in different parts of the world. Control of IBDV and CAV is necessary for preventing severe outbreaks of IBH.

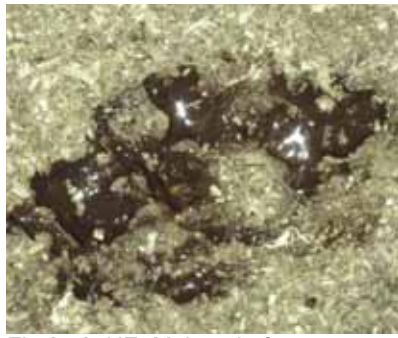
REFERENCES

- Adair BM & Fitzgerald SD. Group I adenovirus infections. In *Diseases of poultry*, Ed. Saif YM, 12th ed., Blackwell Publ. 2008, pp 252-266.
- Bickford AA et al. Inclusion body hepatitis in chickens. Slide study set #2 AAAP, 1977, 12p.
- Brugère-Picoux J. Les adénovirus en pathologie aviaire. *Rec Méd Vét*, 1978,154,1015-1021.
- Dinev I. *Diseases of poultry. A colour atlas*. Ed. CEVA Santé Animale, 2007, 212 p.
- Gomis S et al. Inclusion body hepatitis as a primary disease in broilers in Saskatchewan, Canada. *Avian Dis*, 2006,50:550-555.
- Hafez MH. Avian adenoviruses infections with special attention to inclusion body hepatitis/hydropericardium syndrome and egg drop syndrome. *Pak Vet J*, 2011,31:85-92.
- Hess M. Detection and differentiation of avian adenoviruses. A review. *Avian Pathol*,2000,29,195-206.
- McFerran JB & Adair BM. Avian adenoviruses – a review. *Avian pathol*,1977,6,189-217.
- Schonewille EE et al. Fowl adenovirus (FAdV) serotype 4 causes depletion of B and T cells in lymphoid organs in specific pathogen-free chickens following experimental infection. *Vet Immunol Immunopathol*, 2008,121:130-9.
- Senties-Cué CG et al. Epidemiology and effect on production parameters of an outbreak of inclusion body hepatitis in broilers. *Avian Dis*, 2010,54:74-78.
- Smyth JA & McNulty MS. *Adenoviridae*. In "Poultry diseases" sixth edition, Ed Pattison M et al. Saunders Elsevier p 367-381.
- Steer PA et al. Application of high-resolution melting curve analysis for typing of fowl adenoviruses in field cases of inclusion body hepatitis. *Aus Vet J*, 2011,89 :184-192.
- Toro H et al. Chicken anemia virus and fowl adenoviruses: Association to induce the inclusion body hepatitis/hydropericardium syndrome. *Avian Dis*, 2000,44:51-58.



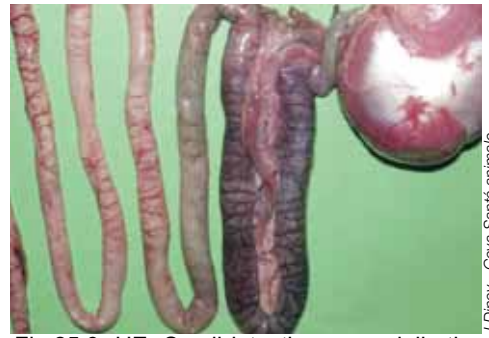I Dinev - Ceva Santé animale

Fig.25.1: HE. Blood discharge from the vent.



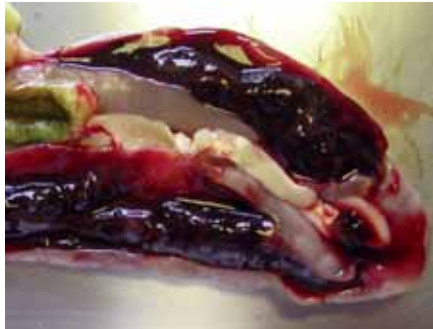I Dinev - Ceva Santé animale

Fig.25.2: HE. Melena in feces.



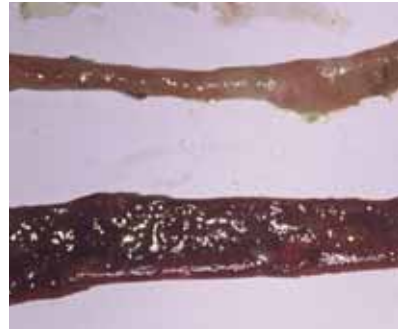I Dinev - Ceva Santé animale

Fig.25.3: HE. Small intestine, especially the duodenum, are distended and dark purple.



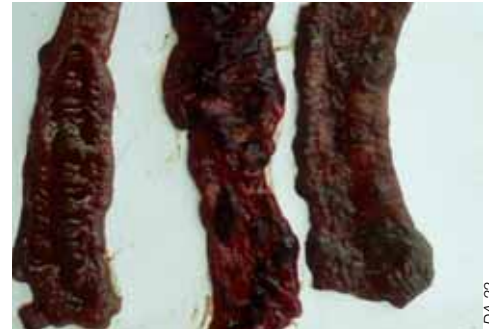JY Ferré

Fig.25.4: HE (Guinea fowl). Duodenum is filled with bloody material.

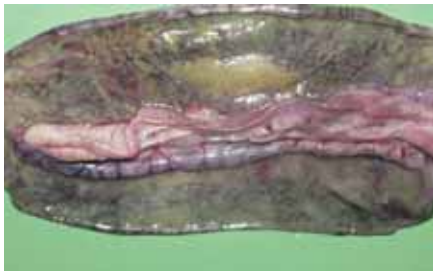

A Sillim

Fig.25.5 & 25.6: HE. The intestinal mucosa of the duodenum has a velvety appearance and may show occasional necrotic areas.

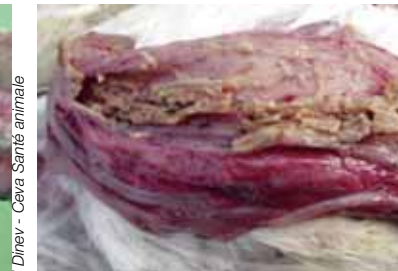

LDA 22

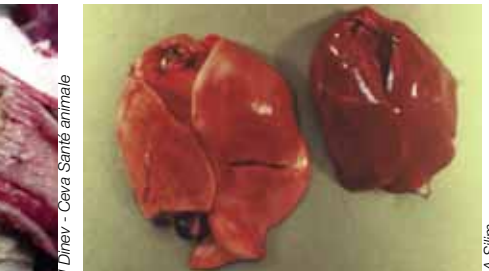

I Dinev - Ceva Santé animale

Fig.25.7 & 25.8: HE. Sometimes the mucosa of the duodenum is covered with a yellow fibrinonecrotic membrane.

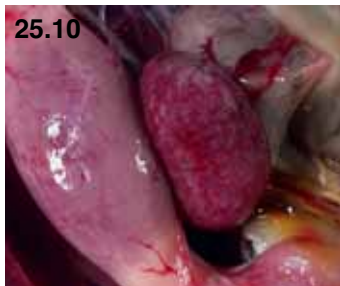

I Dinev - Ceva Santé animale

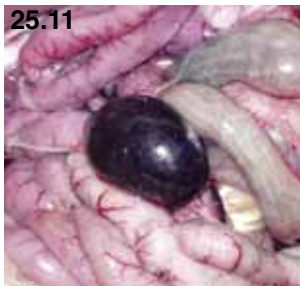

A Sillim

Fig.25.9: HE. Sometimes hypertrophy of the liver (on the left) can be seen.



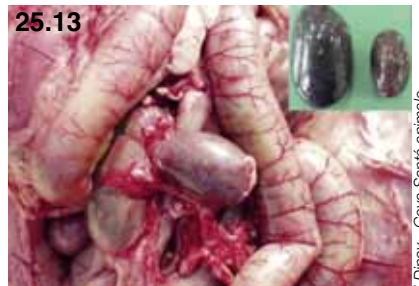HU Barnes



I Dinev - Ceva Santé animale

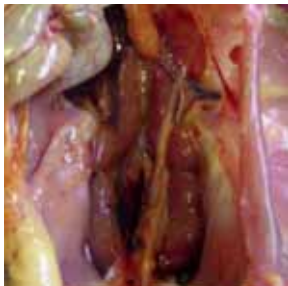


D Verne



I Dinev - Ceva Santé animale

Fig.25.10, 25.11, 25.12 & 25.13: HE. Splens of infected birds are enlarged, friable and mottled in appearance. Some are hemorrhagic (Fig.25.11). There is a splenomegaly (compare with normal spleen on the left in Fig.25.12). Afterwards, the spleen reduces its size 2-3 times and acquires a specific silvery-grey color (Fig.25.13).

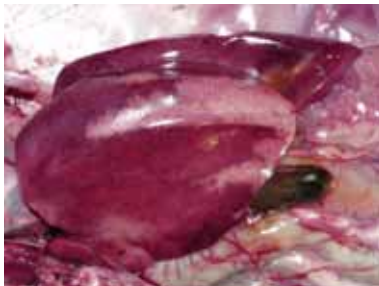


JY Ferré

Fig.25.14: HE (Guinea fowl). Kidney are enlarged.

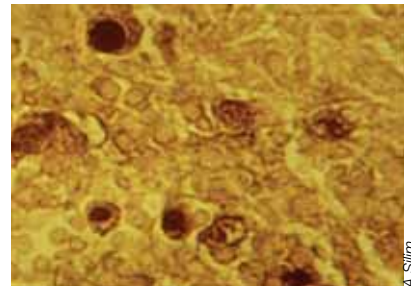


I Dinev - Ceva Santé animale



I Dinev - Ceva Santé animale

Fig.25.15 & 25.16: HE. The liver is enlarged, crumbly and mottled with multiple hemorrhages. Sometimes, extensive necrotic foci is observed.



A Sillim

Fig.25.17: HE (spleen). Intranuclear inclusion bodies with viral antigen highlighted by immunoperoxidase technique.

25. SIADENOVIRUS (HEMORRHAGIC ENTERITIS)

INTRODUCTION

Siadenoviruses have been isolated from turkeys, pheasants and chickens throughout the world. These viruses have been implicated in the causation of turkey hemorrhagic enteritis (HE), marble spleen disease (MSD) (see Chap.VI.97), and avian adenovirus splenomegaly (AAS) in turkeys, pheasants, and chickens respectively (see Tabl.24.1). These viruses were previously called "Group II avian adenoviruses" because they share a common group antigen distinct from that of aviadenoviruses. However, they are currently grouped as one species called *Turkey Adenovirus A* (TAdV 3) within the genus *Siadenovirus*. Infections by these viruses produce different manifestations in each of the three bird species affected, and thus the disease in each species has its own name. Other species can be naturally affected like guinea fowl, psittacines, and bustard.

TURKEY HEMORRHAGIC ENTERITIS (HE)

Turkey hemorrhagic enteritis (HE) affects turkeys of 4 weeks of age and older. The common clinical signs of the disease include depression, bloody droppings, and death. It is rare in turkeys less than 4 weeks presumably due to protection from maternal antibodies.

Etiology & pathogeny

Hemorrhagic enteritis is likely transmitted through the fecal-oral/ cloacal route. Infection frequently reoccurs on the same farm in successive flocks. Vertical transmission through the egg and biological vectors is not documented. Infection of turkeys with HE virus results in a transient immunosuppression, often resulting in colibacillosis.

Clinical signs & lesions

Clinical signs of HE include depression, bloody droppings, and decreased feed and water consumption in affected birds. Sudden deaths are often the first sign of HE in a flock. Feces containing blood are frequently present on the skin and feathers of moribund and dead birds. Bloody feces may also be forced from the vent of affected birds when moderate pressure is applied to the abdomen. The disease runs its course in a flock in 6-14 days. Mortality may exceed 60% but averages 10-15%. Outbreaks of colisepticemia often follow clinical and subclinical infections with HE 12-14 days later.

On postmortem examination, dead poult appear pale as a result of blood loss. At the level of the duodenum, the small intestine appears swollen, dark purple, and is filled with bloody content. A yellow fibrinonecrotic membrane usually covers the intestinal mucosa in some cases. Internal abdominal organs, such as the spleen and the liver are enlarged. In addition, the spleen appears friable and mottled. Petechial hemorrhages may also be seen in several tissues of dead poults. Microscopic examination of the spleen shows white pulp hyperplasia and lymphoid necrosis. Intranuclear inclusion bodies can be found in the macrophages and lymphocytes of the spleen and other tissues, such as the intestines and liver.

Diagnosis

Typical history and gross lesions strongly suggest HE. Observation of intranuclear inclusions in reticuloendothelial cells in the spleen or the intestine confirms the diagnosis. Viral identification of HE can be done using agar gel immunodiffusion (AGID) test and polymerase chain reaction (PCR). Antigen-capture ELISA and *in situ* DNA hybridization can also be used.

Control

Horizontal spread of infection between flocks can be prevented using best management practices and biosecurity protocols. Use of live vaccine by water administration can prevent HE (and MSP). For good results in the field, it is recommended that vaccination of turkeys be done between 3.5 to 6 weeks of age. In order to prevent secondary colisepticemia following infection of birds with HE, antibiotic therapy should be considered within one week post infection.

REFERENCES

- Brugère-Picoux J. Les adénovirus en pathologie aviaire. *Rec Méd Vét*, 1978,154,1015-1021.
- Charlton BR et al. *Avian disease manual*. 6th ed., ed.AAAP, 2006, 235p.
- Dinev I. *Diseases of poultry. A colour atlas*. Ed. CEVA Santé Animale, 2007, 212 p.
- McFerran JB & Adair BM. Avian adenoviruses - a review. *Avian pathol*,1977,6,189-217.
- Pierson FW & Fitzgerald SD. Hemorrhagic enteritis and related infections. In *Diseases of poultry*, Ed. Swayne DE, 13th ed., Blackwell Publ. 2013, pp 309-316.
- Smyth JA & McNulty MS. *Adenoviridae*. In "Poultry diseases" sixth edition, Ed Pattison M et al. Saunders Elsevier p 367-381.

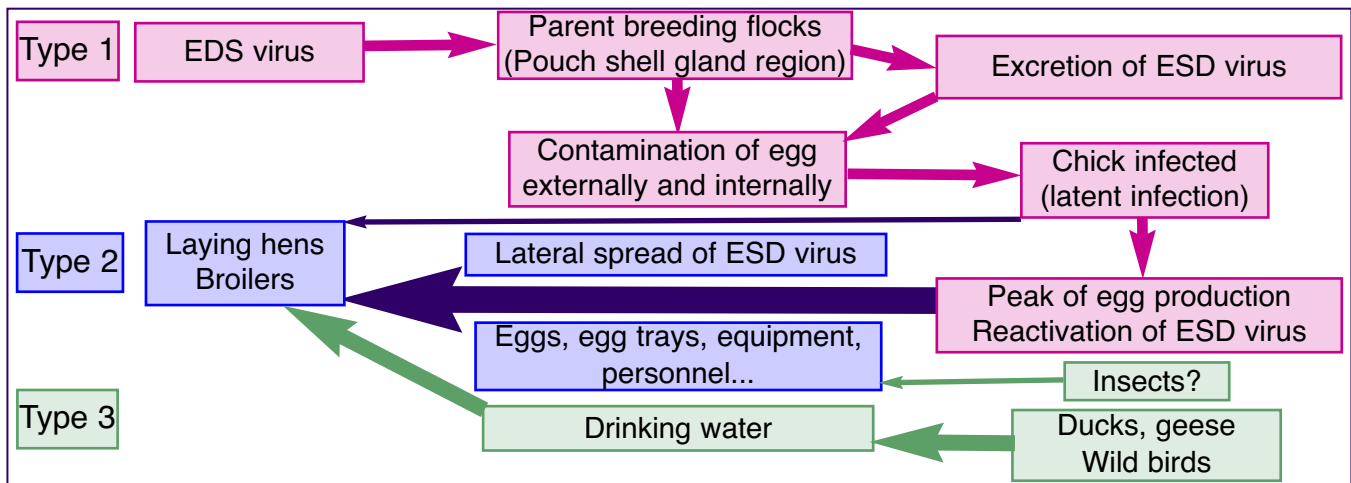


Fig.26.1: Transmission of EDS virus.

Following experimental infection in laying hens, the virus grows to a limited extent in the nasal mucosa. After a transient viremia, with virus growth in lymphoid tissue, there is a massive growth in the pouch shell gland region of the oviduct, coincident with the occurrence of eggshell changes, 8 days after infection. Both eggs with normal and affected shells contain virus, externally and internally, for the next 2-3 weeks. Viral antigen is not detected at the surface of the epithelium of the intestinal tract. Chicks hatching from these infected eggs often do not develop antibodies but they may be latently infected. At around peak egg production, the virus is reactivated and horizontal spread occurs. Horizontal spread is also possible between birds during the growing period, but as the amount of virus excreted is small, this spread is limited.

EDS outbreaks are divided into three types. 1) An initial outbreak probably caused by a contaminated vaccine grown in duck embryo fibroblasts. *Classical EDS* follows the introduction of EDS virus into primary breeding stock, and the main method of spread is vertically through embryonated eggs. 2) The second type (*endemic form*) is a lateral spread between flocks. Spread is essentially associated with contaminated eggs or egg trays but also during transportation in inadequately cleaned trucks or when unused feed has been moved between sites. Needles or blades used for vaccination or bleeding, if not properly sterilized and reused, can also transmit infection. 3) The third type of spread of EDS virus (*sporadic form*) results from the introduction of infection by domestic or wild ducks, geese, through direct contact or indirectly through contaminated drinking water. Transmission via insects may be possible but is unproven.



Fig.26.2, 26.3, 26.4 & 26.5: EDS. The first sign is the loss of color in pigmented eggs. Eggshells may have focal thickenings. If abnormal eggs are discarded, there is no effect on fertility and hatchability for the non-affected eggs. The fall in egg production is very rapid or extended over several weeks. EDS outbreaks usually last 4-10 weeks and egg production is reduced by up to 40%.

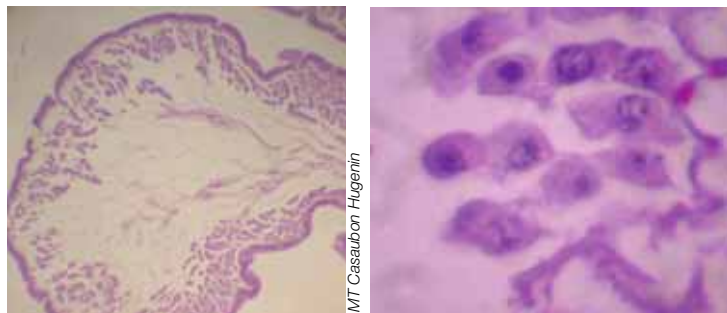


Fig.26.6 & 26.7: EDS. In natural outbreaks of EDS, inactive ovaries and atrophied oviducts are often the only recognizable lesions, and these are not consistently present. Microscopically, major pathologic changes occur in the pouch shell gland. Virus replication occurs in the nuclei of surface epithelial cells and intranuclear inclusion antibodies are detectable from 7 days post-infection onward. There is also a rapid and severe inflammatory response. The transient nature of these lesions explains the difficulty in finding affected birds among the thousands of birds that may be present in an affected flock.

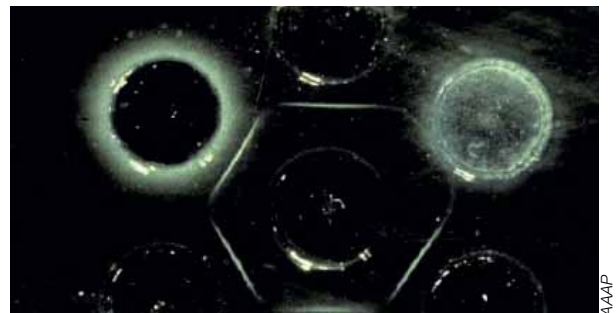


Fig.26.8: EDS. The most common serologic test is the immunodiffusion test that detects the group specific antigen. However, this test is not sensitive enough. Detection of antibodies to EDS by the haemagglutination-inhibition test using fowl red blood cells is sensitive and easy, and is a good choice in unvaccinated flocks. ELISA can also be used. But in general the interpretation of serologic tests is difficult because birds infected *in ovo* do not develop antibodies during the growing period; it only becomes apparent immediately following the occurrence of clinical signs.

Viral diseases

26. ATADENOVIRUS (EGG DROP SYNDROME)

INTRODUCTION

Egg drop syndrome (EDS) is a disease characterized by a drastic drop in egg production as well as the production of abnormal eggs in apparently healthy hens and quails. Since its initial description in 1976 in The Netherlands, EDS has become a major cause of low egg production throughout the world.

ETIOLOGY & PATHOGENY

Egg drop syndrome is caused by Duck *Adenovirus* 1 or egg drop syndrome strain of species Duck *Adenovirus* A (DAdV-1) and genus *Atadenovirus*. The virus was initially classified as the only member of group III avian *Adenovirus* A (DAdV-1). It differs from aviadenoviruses and siadenoviruses in that it agglutinates avian but not mammalian red blood cells. It is likely that the natural hosts for EDS virus are ducks, geese, and other waterfowls. However, disease outbreaks have been reported mostly in laying hens.

The EDS virus is mainly spread vertically through the embryonated eggs. Horizontal spread of the virus has also been reported. Following oral infection of adult hens with EDS virus, viral replication occurs in lymphoid tissues, such as the spleen and the thymus. The infection spreads to the oviduct and the pouch shell gland resulting in production of eggs with abnormal shells. Experimentally, the virus replicates to reach high titers in duck kidney cells, duck embryo liver cells and duck embryo fibroblasts, not as well in chick kidney cells, and poorly in chicken embryo fibroblast cells. No growth occurs in embryonated chicken eggs. The disease is severe in broiler breeders and Brown egg layers. Quails have also been shown to be susceptible to infection and to develop classic signs of EDS. Turkeys can also be affected. DAdV-1 was thought to be avirulent in ducks and geese; however, in 2001, the virus was isolated from an outbreak of respiratory disease in young goslings, and the disease was reproduced by experimental infection of 1 day-old birds.

CLINICAL SIGNS & LESIONS

The first sign is the loss of eggshell color. This is quickly followed by a series of signs including production of thin-shelled, soft-shelled, or shell-less eggs. Shell-less eggs are not always found, as they may be eaten by the birds. There is a quick decrease in egg production for several weeks. Other clinical signs that might be observed in the affected birds include production of small eggs, watery albumen, delay in the onset of lay, dullness, inappetence, and transient diarrhea.

Gross lesions in the affected birds include edema of the uterine folds, presence of exudate in the pouch shell gland, mild splenomegaly, flaccid ovules, and eggs in

various stages of formation in the abdominal cavity, inactive ovaries, and atrophied oviducts. Microscopically, surface epithelial cells of the pouch shell glands show intranuclear inclusion bodies. The *lamina propria* and the epithelium are inflamed with increased presence of heterophils and mucosal edema. There is also infiltration of the *lamina propria* by macrophages, plasma cells, and lymphocytes.

DIAGNOSIS

Although signs of EDS are quite characteristic, differential diagnosis should be made with other infectious and non-infectious causes of drop in egg production. EDS virus can be isolated from cloacal swabs but virus recovery can be challenging in the field because excretion is momentary and it is often difficult to identify the correct bird to sample. Therefore, the easiest method is to feed affected eggs to antibody-negative adult laying hens. Following production of abnormal eggs, the virus can be isolated from the pouch shell glands of the affected hens. Serological diagnosis can be attempted by sampling blood from birds housed where abnormal eggs are observed. The presence of antibodies can be detected using hemagglutination inhibition (HI), enzyme linked immunosorbent assay (ELISA), serum neutralization (SN), double immunodiffusion (DID), and indirect fluorescent antibody (IFA) tests.

CONTROL

The classical form of EDS has apparently been eliminated from all primary breeders. Endemic EDS can be controlled by vaccinating birds between 14 and 16 weeks of age using oil-adjuvant inactivated vaccine.

Strict adherence to biosecurity and hygienic measures are required to avoid horizontal spread by infected eggs and contaminated egg trays. In a situation where infected and uninfected breeding flocks are kept on the same farm, separate hatcheries, staff, and transport should be used. Equipment, such as bleeding and vaccine inoculation needles should be sterilized or changed between flocks to avoid spreading infection. Using water from dams, lakes or wells has been associated with EDS infection. Therefore, treated water sources (e.g., chlorinated water) should be used to avoid this mode of viral transmission. Wild ducks and geese have also been linked to EDS infection. Therefore, minimizing contact between wild waterfowls and domesticated flocks using wild-bird proof housing is recommended. Also, on production sites where ducks or geese are raised, these species should be physically separated from chickens.

REFERENCES (see Chap.II.24 & II.25)

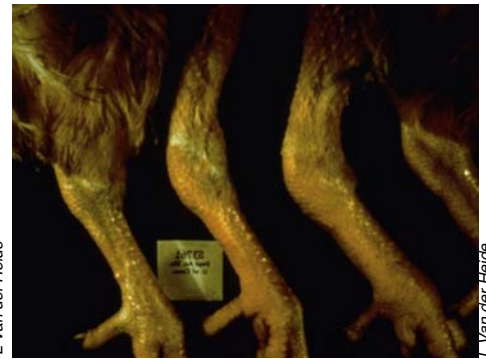
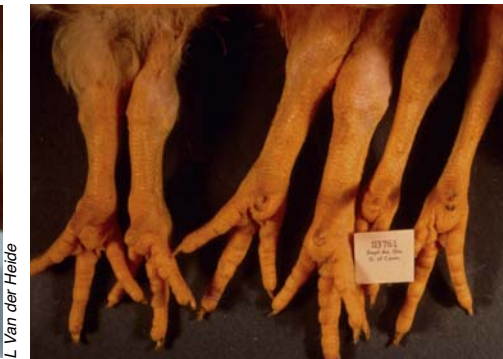
Fig.27.1: Broiler chicken with painful legs.

Fig.27.2: Left and center pair of legs with swollen hock joints and metatarsus. Right pair of legs normal.

Fig.27.3: Swelling of hock joint and metatarsus.

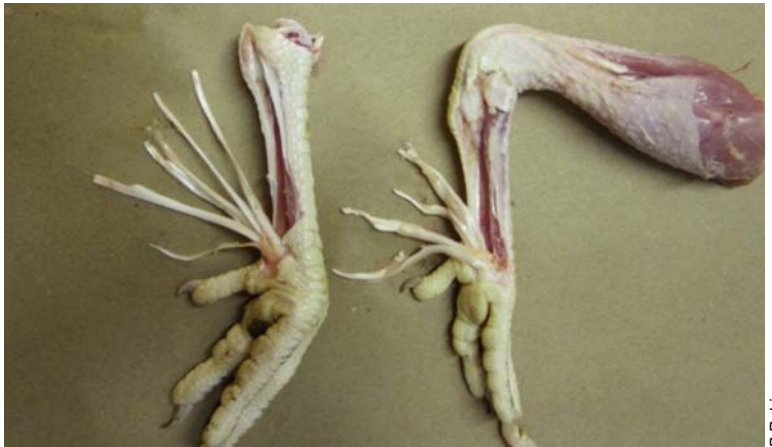

Fig.27.4 & 27.5: Tendinitis of the tarsometatarsal joint observed in an 81-day-old chicken due to a variant strain of reovirus. Compared with a normal chicken (Fig.27.4, left) and tendon (Fig.27.5, left), note the emaciation (weight loss of 343 g) and swelling of the leg resulting from the edema of the tendon (right in Fig.27.4 & 27.5).

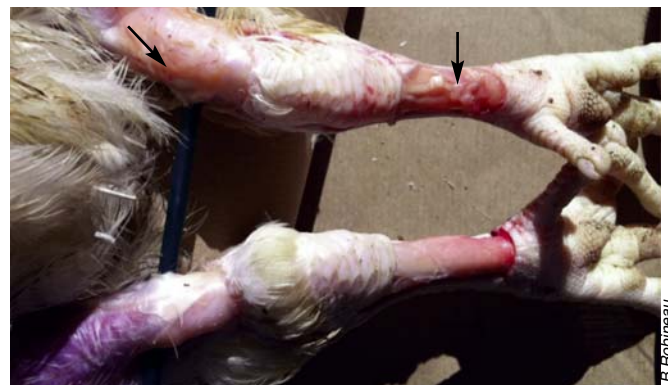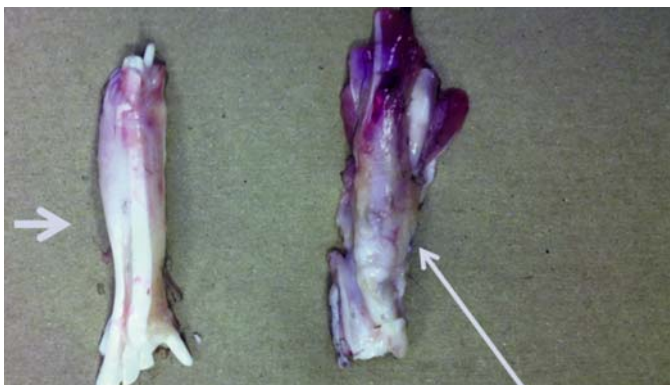


Fig.27.6 & 27.7: Viral tenosynovitis. Fig.27.6 shows an enlargement of the tarsometatarsal tendon (short arrow) and degeneration of the gastrocnemius tendon (long arrow). Fig.27.7 shows a marked edema of the gastrocnemius tendon (arrows).

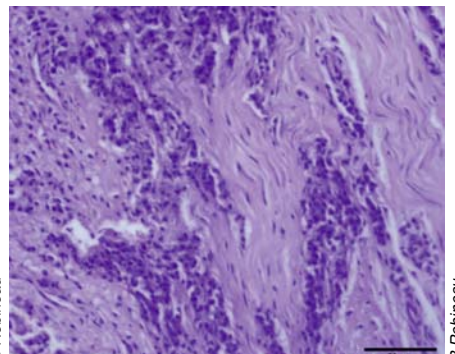
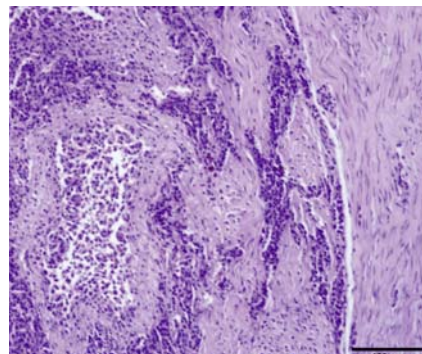
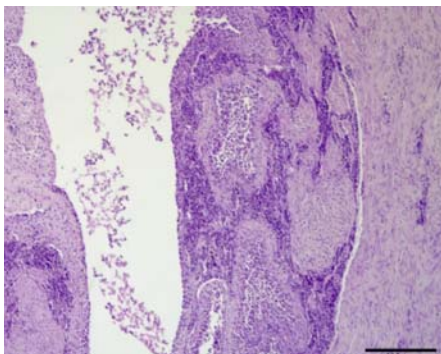


Fig.27.8, 27.9 & 27.10: Viral tenosynovitis. Multifocal accumulation of lymphocytes and plasmacells. The synovial space is filled with cell debris, the epithelium is detached. Normal structure of fibrocytes is destroyed by inflammatory processes (Hematoxylin & eosin).

Viral diseases

27. REOVIRUS INFECTIONS

INTRODUCTION

Viral arthritis/tenosynovitis is one of the clinical manifestations of avian reovirus infection in chickens, particularly in meat-type chickens. Other manifestations are hepatitis, myocarditis and hydropericardium.

Enteric problems, such as enteritis and proventriculitis that are commonly described as malabsorption syndrome, have been found to be sometimes caused by avian reovirus. However, other viruses such as enteroviruses, parvoviruses, caliciviruses as well as some bacteria have been implicated as possible causative or contributing agents in malabsorption syndrome.

In 1998, a reovirus was isolated in Poland (prototype 238/98 - polish strain) in broilers (some were from breeders that had been vaccinated with currently available reovirus vaccines) with malabsorption syndrome, hepatitis, myocarditis, pancreatitis, proventriculitis, tenosynovitis, enteritis and neurological signs (and also in layers with decreased production). Increased mortality was associated with concurrent infections (*Escherichia coli*, adenovirus). This virus was classified as *enteric reovirus strain* (ERS). A series of variants, much different from vaccine strains and associated with leg problems in broilers, has also been identified in different regions of North America and other countries like France since 2012. The emergence and reemergence of reovirus-related diseases over the years in poultry make this virus a pathogen of interest as primary or secondary agent.

ETIOLOGY & EPIDEMIOLOGY

Avian reovirus has been a known cause of viral arthritis/tenosynovitis in chickens since 1969 and, more recently, in turkeys as well. It is occasionally seen in commercial layers. It is important to note that this virus is often isolated from clinically normal birds.

The fowl reoviruses are double-stranded RNA non enveloped viruses, with a common group antigen. The viral particle is proximally 75-80 nm in diameter. The name «reovirus» comes from «respiratory, enteric orphan», being first isolated from these sites in humans who were not showing clinical signs. This virus is resistant to heat (it withstands 60°C for 8-10 hours) and to pH 3. It has been shown to survive at least 10 days on feathers, wood

shavings, egg shells and feed; and over 10 weeks in drinking water.

Although primarily a disease concern of chickens, reoviruses have been isolated from other avian species (turkeys, geese, ducks, pigeons, psittacines, etc.). Based on sequence analysis of selected genes, turkey and duck reoviruses are classified in different subgroups from chicken reoviruses. Chickens are most susceptible to pathogenic reoviruses at 1 day of age.

Avian reovirus can be transmitted horizontally by infected chickens or turkeys. Reoviruses can be excreted from both the intestinal and the respiratory tracts for at least 10 days post-infection, with newly hatched chicks being more susceptible to the respiratory route. Transmission through broken skin in the foot has been shown experimentally. When done this way, the incubation period is very short (1 day); but it is normally between 9 and 13 days. The vertical transmission through the eggs of reovirus-infected breeders can be important in the epidemiology of the infection. Vertically infected chicks can easily become a nucleus of infection for hatchmates. Replication of the virus may occur in several tissues, but the intestine, the tibio-tarsometatarsal joint, and the liver are the main sites.

When breeder chickens get infected with reovirus during production, they will not have any clinical signs themselves, but some of the progeny broilers will have viral arthritis/tenosynovitis, while hatchability will also decrease for several weeks, until the breeders become immune to the reovirus. Different studies suggest that vertical transmission occurs principally between 5 and 19 days post-infection in breeders.

Morbidity is normally high, but mortality rarely exceeds 6%. Lesions of arthritis take a long time to be observed macroscopically. This may explain why they are usually not seen before four weeks of age. In turkeys, lesions have been seen mainly in males at least 14 weeks old, although it has been seen as well in poult only five weeks of age.

CLINICAL SIGNS & LESIONS

Viral arthritis

Avian reovirus infections cause symptoms of lameness and reluctance to move with visible swelling of the tarsal and metatarsal tendons. Sometimes the hock joint are also swollen, but not as severe as when secondary staphylococcus arthritis exists.

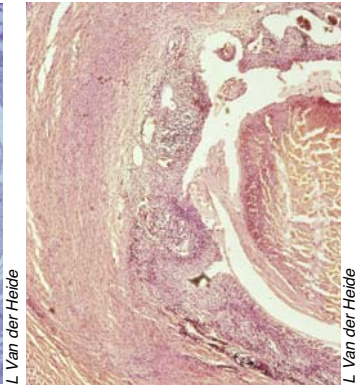
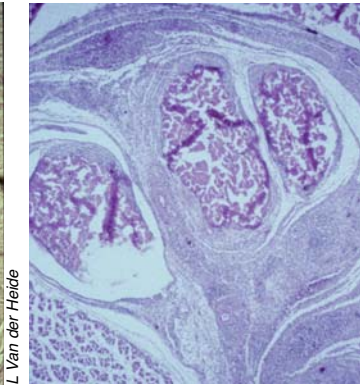
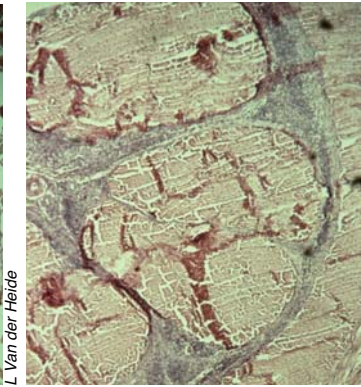
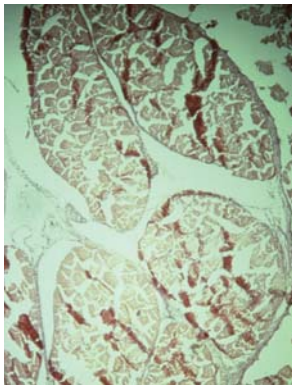


Fig.27.11: Cross-section of normal metatarsal flexor tendons.

Fig.27.12: Cross-section of tenosynovitis infected flexor tendons: tendon sheaths have infiltration of lymphocytes primarily.

Fig.27.13: Cross-section of more advanced tenosynovitis infected flexor tendons: granulomatous tissue and beginning fibrosis.

Fig.27.14: Cross-section of chronic tenosynovitis: marked fibrosis with some mononuclear cells.

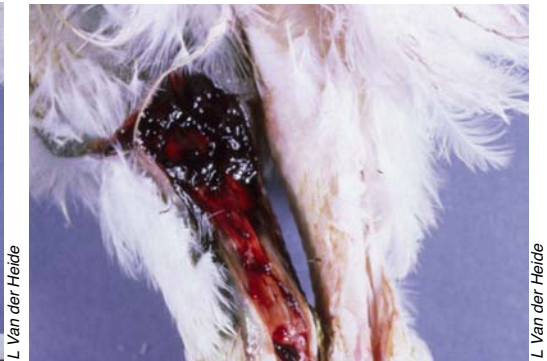
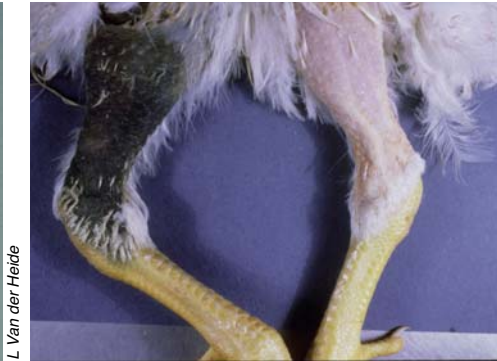
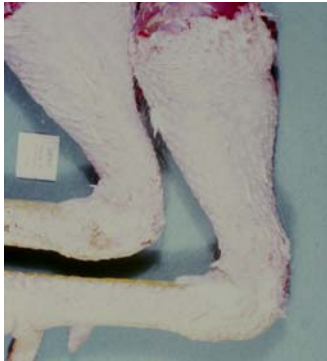Fig.27.15: Chronic gastrocnemius tendon fibrosis.

Fig.27.16 & 27.17: Acute gastrocnemius tendon rupture, with subcutaneous hemorrhage.

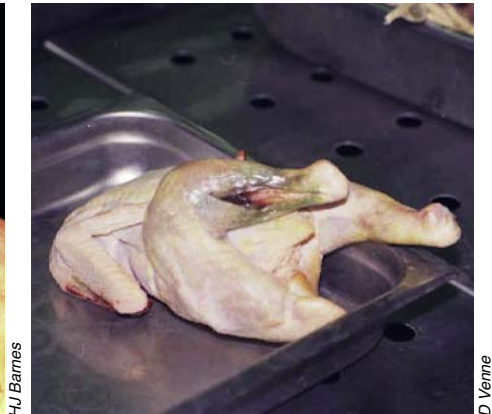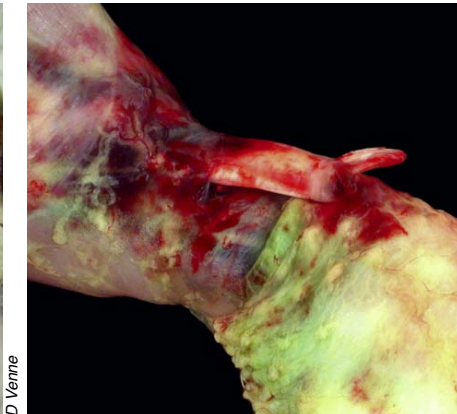
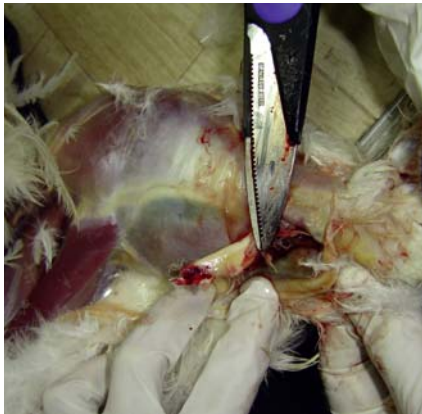


Fig.27.18, 27.19 & 27.20: Acute gastrocnemius tendon rupture with green discoloration of the skin over the site of tendon rupture.

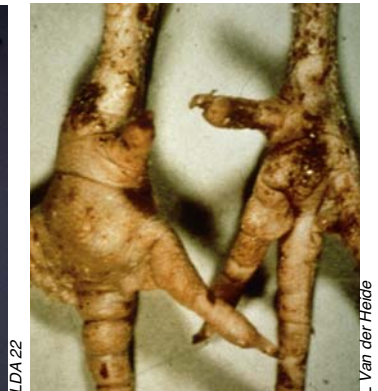
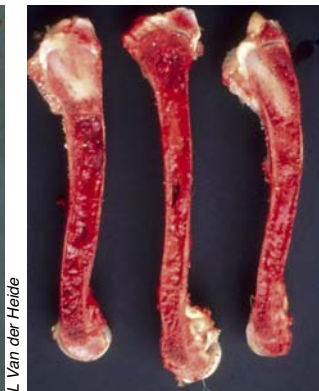
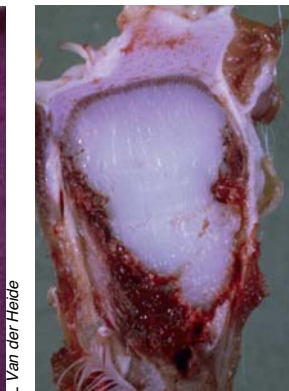


Fig.27.21: Differential diagnosis of leg problems: twisted legs (*Varus valgus*).

Fig.27.22 & 27.23: Differential diagnosis: tibial dyschondroplasia: cartilage plug. Normal tibia at the center of Fig.27.23.

Fig.27.24: Differential diagnosis: Staphylococcal arthritis.

Later, fibrosis of the tarsal and metatarsal tendons will develop. This can develop into rupture of the gastrocnemius tendon and subsequent subcutaneous hemorrhage followed by a fibrotic lump above the hock joint.

Much of the tendon sheath tissue will be granulomatous and eventually replaced by fibrous connective tissue. Infiltration with mononuclear cells, plasma cells and macrophages of the tendon sheath area is common in the more acute stage with the presence of serous fluid in these tissues. The synovial surface of the tarso-metatarsal (hock) joint can have a typical granulation (pannus) formation, very similar to rheumatoid arthritis in humans. Inflammation degrades the quality of the synovial fluid and breaks down tendon and cartilage.

Secondary infections with bacteria such as *Staphylococcus* will aggravate the lesions with formation of a more purulent exudate and extensive hock joint swelling. If the birds are *Mycoplasma synoviae* (MS) positive, the synovitis can also be caused by MS as a co-factor. Reovirus may also exacerbate clinical signs caused by pathogens such as chicken anemia virus, *Escherichia coli*, and some respiratory viruses.

When the infection is acute, stunting may be observed, while lameness is more pronounced. Lesions at slaughter (enlargement of gastrocnemius/digital flexor tendon area; green discoloration of the skin over the site of tendon rupture) may involve only a low percentage of birds, but flocks with over 10% of affected carcasses have been reported.

Arthritis, with epicarditis and tenosynovitis, have been reported in young geese, usually 2-3 weeks of age.

Enteric problems

If reovirus is involved in a malabsorption syndrome, diarrhea can be observed usually at 8-10 days of age. Pale birds and growth retardation (runting and stunting), abnormal feathering (helicopter wings) and/or femoral head fractures (osteoporosis) can be observed.

The fecal matter frequently has an orange color and contains undigested feed. The intestines frequently have a pale, "cement" colored appearance and an enlarged proventriculus can be found. Tenosynovitis also occurs in such chickens.

In turkeys, some studies have suggested that reoviruses could play a role in the poult enteritis mortality syndrome (PEMS) (see Chap.IV.72). A reovirus has been shown, experimentally, to produce intestinal lesions. The authors also proposed that this virus could as well increase the susceptibility of poults to other pathogens associated with PEMS. However, an epidemiological study conducted in three states in the USA could not demonstrate any relationship between the presence of reoviruses and PEMS.

Muscovy duck reovirus has been associated with diarrhea, high morbidity and mortality in 2-4 week-old ducklings (see Chap.VI.85).

Myocarditis associated with reovirus (see Chap.II.39)

DIAGNOSIS

Sample collection

It is highly recommended to collect intact legs, including shanks and feet, from six birds per flock. Younger flocks (10 to 35 days) are preferred because they provide a higher probability of isolating viable virus. Legs must be placed on ice immediately at time of collection and then frozen in ziplock bags. It must be shipped frozen to the diagnostic laboratory.

Histopathology

Cross-sections of the metatarsal tendons will show typical microscopic tenosynovitis lesions, as described above.

Virus isolation

Demonstration of virus from tissues of clinically affected birds is useful to confirm causality. Ground tendon tissue can be used for virus isolation by inoculation of embryonating SPF chicken eggs, either by yolk-sac inoculation of 6-day-old embryonated eggs or by chorio-allantoic-membrane (CAM) inoculation of 9-day-old embryonated eggs. Chicken kidney cells (CKC) can also be used for reovirus isolation. Cytopathic effect (CPE) of reovirus in CKC consists of syncytia formation.

PCR

Molecular methods are more rapid than virus isolation and are now frequently used. Traditional or

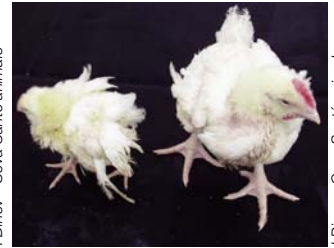


Fig.27.25, 27.26 & 27.27: Abnormal wing feathering in malabsorption syndrome (helicopter wings).

Fig.27.28: Important reduced live weight in affected bird (left).

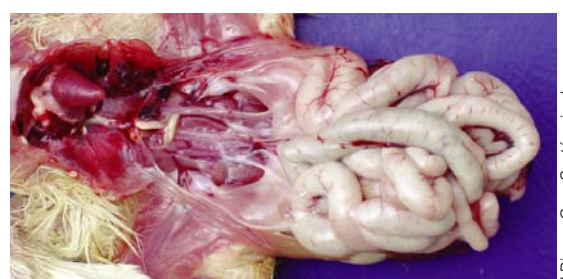
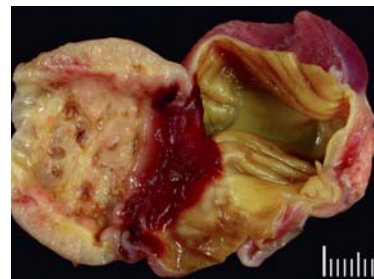
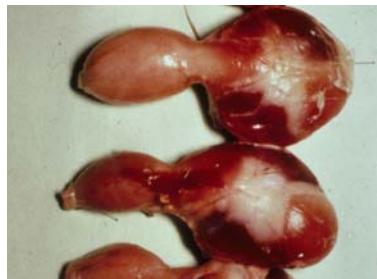
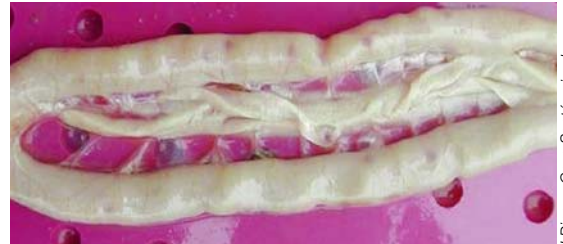
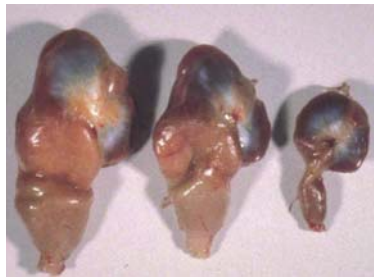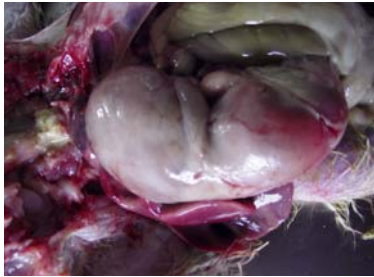Fig.27.29, 27.30, 27.31 & 27.32: Enlarged proventriculus in chickens after reovirus infection.

Fig.27.33: Atrophy of the pancreas can be observed.

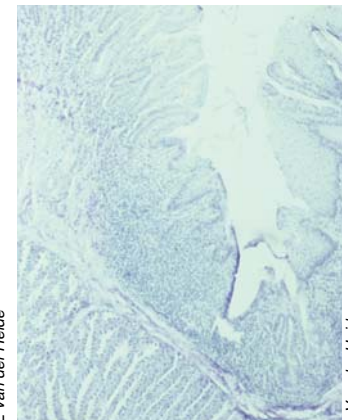
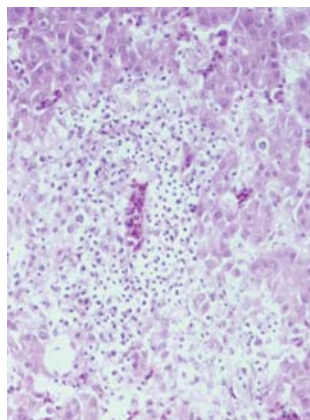
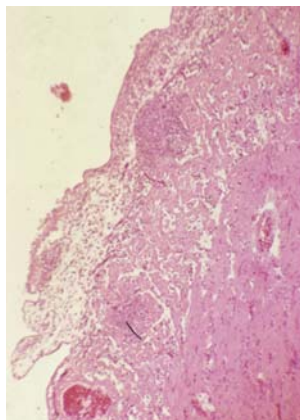
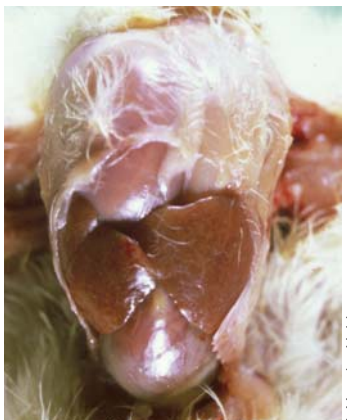

Fig.27.35: Hepatitis and myocarditis/hydropericardium in chick, after day-old infection with reovirus.

Fig.27.36: Myocarditis, lymphoid cell infiltration.

Fig.27.37: Hepatitis, lymphocyte infiltration.

Fig.27.38: Proventriculitis: massive infiltration of lymphocytes in mucosa.

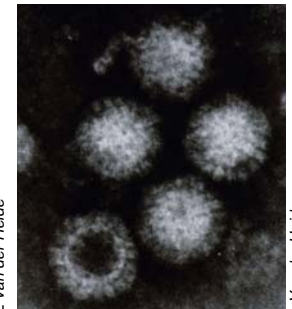
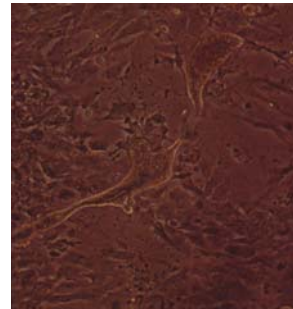
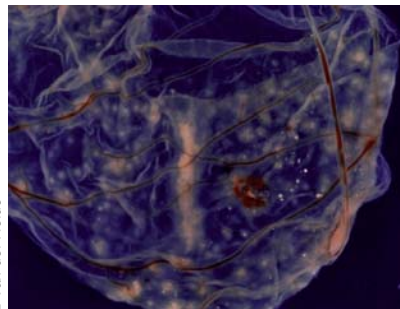
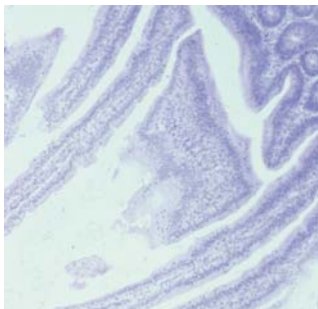


Fig.27.39: Enteritis: fusion of villi.

Fig.27.40: Infected chorioallantoic membrane with whitish plaques.

Fig.27.41: Reovirus infected cell culture (chicken embryo): syncytia formation.

Fig.27.42: Reovirus, electron microscopic picture.

real-time RT PCR followed by restriction enzyme fragment length polymorphism is available and useful to characterize reovirus strains.

Serology

Since reovirus vaccination is used widely, especially in broiler breeders (protective role of maternal antibody), it is important to check reovirus antibody titers in vaccinated breeder chickens. Enzyme Linked Immunosorbent Assay (ELISA) titers in breeders should be at least 6000-8000, and can be as high as 10,000 after 2 live and 2 killed vaccine applications. It is possible to develop an ELISA to differentiate between infected and vaccinated birds.

Agar gel precipitation (AGP) testing is useful if non-vaccinated birds are tested for antibody presence, but many non-pathogenic reoviruses may give also positive AGP-reactions that can be misinterpreted.

Reovirus isolates can be serotyped with virus neutralization (VN) testing. Most reovirus isolates from chickens are of the same or similar serotype as the commercially available vaccines. However, variant reovirus serotypes have been found in Europe and the Middle Eastern countries (ERS virus). In those cases, autogenous vaccines have been used. At least three different variant strains have been associated with tenosynovitis since 2011 in Eastern United States and Canada (Ontario and Quebec). In the United States, an autogenous vaccine has also been part of the control protocol because antigenically different reoviruses have been able to break through commercial vaccinal immunity.

TREATMENT & CONTROL

Although reovirus infections cannot be treated with antibiotics, in the case of co-existing secondary infections with *Staphylococcus* spp. and/or *Mycoplasma synoviae*, antibiotic treatment can be useful.

Preventive vaccination of breeders is the most common procedure. Generally live reovirus vaccines are given at 7 days and 5 weeks of age, followed by 2 applications of killed reovirus vaccine at 10 and 20 weeks of age, resulting in adequate antibody titers. Progeny chicks are protected by maternal antibodies for approximately 3 weeks, after which age resistance against lesion development following infection is usually the case. It should be noted that protection is effective against

homologous serotypes only.

If needed, broiler progeny will have to be vaccinated at 7-10 days of age, but this is not a common procedure. The numerous outbreaks of reovirus related tenosynovitis in Eastern United States have been controlled by the concerted application of autogenous vaccines and enhanced biosecurity and sanitation procedures (longer downtime, at least two weeks; complete washing and disinfection of infected premises and control of darkling beetles).

Viral arthritis/tenosynovitis has rarely been found in commercial layer chickens. If it occurs, reovirus vaccination of parent breeders is advisable.

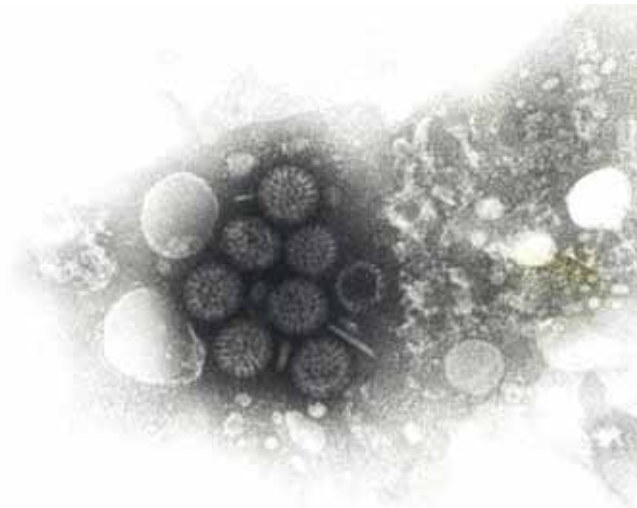REFERENCES

- Decaesstecker M et al. Significance of parvoviruses, entero-like viruses and reoviruses in the aetiology of the chicken malabsorption syndrome. *Avian Pathol*, 1986,15:769-782.
- Deshmulch DR et al. Characterization of pathogenic filtrate and viruses isolated from turkeys with blue comb. *Am J Vet Res*, 1969,30:1019-1025.
- Jones RC. 2013. Reovirus Infections. In *Diseases of Poultry*, 13th ed. Swayne D, et al. eds. John Wiley & Sons Inc. pages 351-370.
- Kerr KM & Olson NO. Pathology of chickens experimentally inoculated or contact-infected with an arthritis-producing virus. *Avian Dis*, 1969,13:729-745.
- Kisary J et al. Presence of parvovirus in the intestine of chickens showing stunting syndrome. *Avian Pathol*, 1984,13:339-343.
- Rosenberger JK et al. Viral arthritis. In: *Diseases of Poultry*, 10th Ed., Calnek B. et al. eds. Iowa State Univ. Press, Ames, Iowa. 1997, pp. 711-720.
- Rosenberger JK et al. Viral arthritis/tenosynovitis and other reovirus infections. In *Lab. Manual for the Isolation and Identification of Avian pathogens*. 4th Ed. Publ. AAAP. 1998:207-210.
- Rosenberger J.K. et al. 2013. Novel reovirus in broilers associated with arthritis/tenosynovitis : viral characterization and research. *Proc. National Meeting Poultry Health, Processing and Live Production*. Ocean City, October 2013.
- Tritts J et al. Reovirus and turkey tenosynovitis. *Proc. North Carolina Industry days 'NCSU*, Oct 5-6, Wilmington North Carolina.
- Van der Heide, L. Viral arthritis/tenosynovitis: a review. *Avian Pathol*, 1977,6: 271-284.
- Van der Heide L et al. Isolation of avian reovirus as a possible etiologic agent of osteoporosis "brittle bone disease", "femoral head necrosis" in broiler chickens. *Avian Dis*, 1981,25: 847-856.
- Wyeth PJ et al. Avian calicivirus. *Vet Rec*, 1981, 109:477.



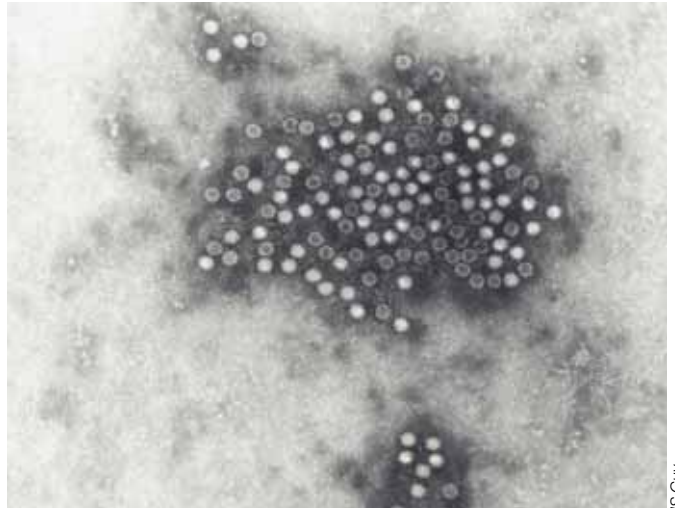LDA 22

Fig.28.1: Rotavirus infection (Guinea fowl). Enteritis and typhlitis.



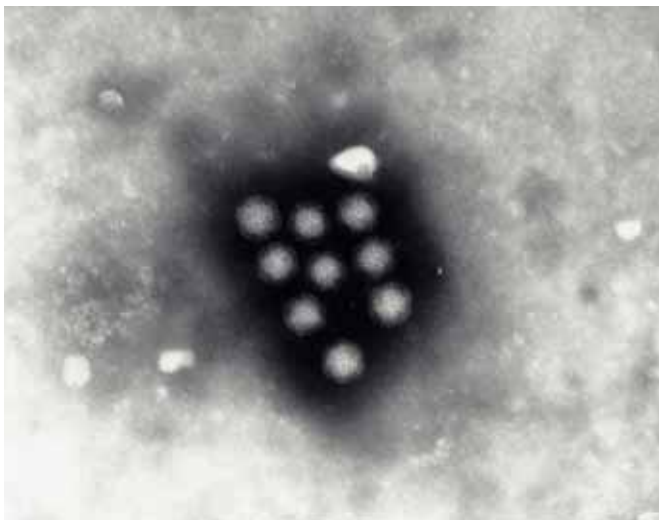
J.S. Guy

Fig.28.2: Rotavirus, with a diameter of approximately 100 nm and containing 10-12 double stranded RNA segments.



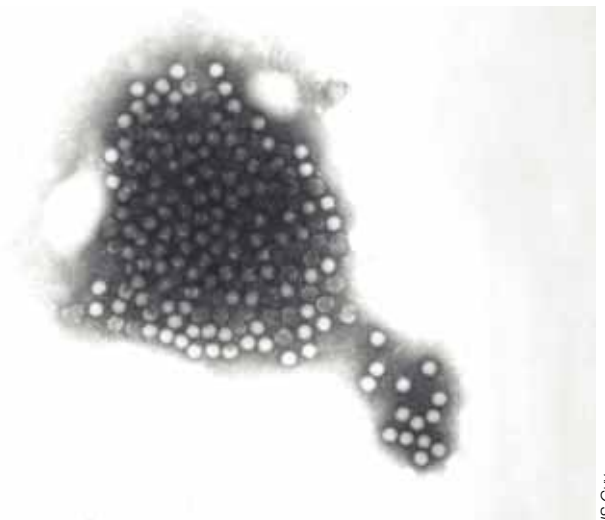
J.S. Guy

Fig.28.3: Parvovirus is a small icosahedral nonenveloped single-stranded DNA virus with a diameter of about 25 nm.



J.S. Guy

Fig.28.4: Reovirus is an icosahedral nonenveloped virus with a diameter of 70-80nm and containing 10 segments of double-stranded RNA.



J.S. Guy

Fig.28.5: Turkey enterovirus is an icosahedral nonenveloped single-stranded RNA virus that measures about 22-30 nm.

28. OTHER VIRAL ENTERIC INFECTIONS

INTRODUCTION

In the last decades, many enteric syndromes such as runting-stunting syndrome (RSS), poult enteritis and mortality syndrome (PEMS) (see Chap.IV.72), poult malabsorption syndrome or maldigestion syndrome have been described in commercial poultry. Most of these syndromes are clinically similar. However, very few relate to a specific etiology. A variety of viral agents have been detected, by themselves or in different combinations with other pathogens (bacteria, protozoa, viruses). Moreover, other factors such as bird, environmental and management factors may play a significant role in the clinical expression of enteric diseases.

Here, we briefly review the information regarding different viruses detected in the gastrointestinal tract of commercial poultry, other than the ones being the object of separate chapters [i.e., coronavirus (see Chap.II.36) and astrovirus (see Chap.II.29)], and that may be associated with enteric problems.

ROTAVIRUS INFECTIONS

Rotaviruses have been isolated from many avian species. Although they are often found in clinically sound flocks, they have also been associated with non-specific enteric disease such as diarrhea outbreaks and general depression in turkeys and chickens.

Etiology & epidemiology

Rotaviruses are members of the *Reoviridae* family. The virions are non-enveloped and contain 10-12 double stranded RNA segments. Therefore, co-infection of a cell with two different rotaviruses may result in genetic reassortant viruses.

There are 7 recognized serogroups (groups A-G), where groups A, D, F and G have been described in birds. A potentially new rotavirus, group H, has been reported.

Rotaviruses have been isolated from numerous avian species such as ducks, turkeys, chicken, pheasants, pigeons and various wild birds. They have a worldwide distribution. Usually, enteric disease signs associated with rotaviruses are seen in birds less than six weeks old.

Rotaviruses are shed in feces. Therefore, the main route of transmission is horizontal via fecal-oral infection and indirect transmission by contaminated objects such as boots and equipment. Where litter is reused for several flocks, infection may build up. Also, larvae of darkling beetles can act as mechanical vectors. Interspecies transmission has been reported in the field between turkeys and chickens. Bovine-origin rotaviruses have also been detected in diarrheic turkeys. The virus can be detected in birds without clinical manifestations of enteric disease.

Clinical signs & lesions

Experimentally infected 3-day-old turkeys have shown depression, loss of appetite, watery-to-soft droppings with pasting of vent. Following experimental infection of chicks, mild diarrhea or increased cecal droppings have been observed. These clinical findings coincided with peak viral excretion at 3 days post-infection. In laying hens infected experimentally, a drop in egg production was noticed 4-9 days post-infection. In the majority of studies, no or very low mortality followed infection of chickens or turkeys with an avian rotavirus. In pheasant chicks, studies have reported mortality rates of 20-30%.

Under field conditions, morbidity and mortality may vary. Although subclinical infections are reported, depression, loss of appetite, watery droppings, dehydration, pasted vents, wet litter and poor weight gain are consistent findings in rotavirus-associated outbreaks.

The intestinal tract may be pale, distended with watery frothy content. Diarrhea appears to be a consequence of the decreased absorption of D-xylose and other carbohydrates, which would permit bacterial growth and fermentation and would ultimately attract water into the gastrointestinal tract. However, rotavirus proteins acting as enterotoxins are also suspected to be the cause of diarrhea. Other gross lesions may include dehydration, stunted growth and pasted and inflamed vents.

The principal site of replication is the mature villous epithelial cells of the small intestine. Different strains may have different preferential sites of replication throughout the small intestine.

The main findings include various degrees of villous atrophy and infiltration of *lamina propria* with mononuclear and polymorphonuclear cells. Other microscopic lesions such as increased crypt depth, vacuolation of enterocytes, fusion of villi, separation and desquamation of enterocytes from the *lamina propria* have also been reported.

Diagnosis

Electron microscopy on feces or intestinal content is sensitive and it has the advantage of being able to identify all serogroups. Electrophoresis on polyacrylamide gel is also proven to be sensitive and is able to identify the different patterns of migration of the viral RNA segments. Several reverse-transcriptase polymerase reaction chain (RT-PCR) have been designed for rotavirus detection. Some are included in multiplex RT-PCR assays for the simultaneous detection of enteric viruses of chicken and turkeys.

Treatment & control

There are no existing vaccines or treatments for the control of rotavirus infections. Proper management strategies and biosecurity measures are recommended. Increasing ventilation and temperature, regularly walking through the flock to encourage the birds to feed and drink and adding new litter may be good ways to help minimize the effects of a rotavirus infection. Changing the litter, fumigating

and cleaning house and equipment may also prevent infection build up between flocks.

PARVOVIRUS INFECTIONS

Chicken parvoviruses (ChPV) and turkey parvoviruses (TuPV) are suspected to play a significant part in the runting-stunting syndrome (RSS) in broilers and poult enteritis complex (PEC), respectively.

Etiology & epidemiology

The *Parvoviridae* family is composed of two subfamilies; *Parvovirinae* and *Desovirinae*. ChPV and TuPV are a part of the *Parvovirinae* subfamily which infects vertebrates. ChPV and TuPV are very similar to each other and are genetically and phylogenetically distinct from the goose parvoviruses.

Parvoviruses are non-enveloped single-stranded DNA viruses. They are known to be very stable, structurally and antigenically simple.

Parvoviruses are widely prevalent in flocks, clinically sound or not, across the United States and Europe.

High concentrations of parvoviruses are shed through the feces of infected birds. The virus is very resistant in the environment. Therefore, direct



Fig.28.6: Severe stunting seen in PEMS survivors. Both poults have the same age. Chicken parvoviruses (ChPV) and turkey parvoviruses (TuPV) are suspected to play a significant part in the runting-stunting syndrome (RSS) in broilers and poult enteritis complex (PEC), respectively.

and indirect horizontal transmissions are the main route of infection. If the litter is reused between flocks, infection may build up and cause a more severe disease in the newly placed birds than in the previous batch. Wild birds are suspected to be potential carriers. Analysis of wild turkey fecal samples has revealed the presence of parvovirus-like particles.

Clinical signs & lesions

Most infections occur during the first week of life and clinical manifestations of the disease appear between 7 and 28 days. Older birds will not show signs of enteric disease, but will produce virus-specific serum antibodies.

Under field conditions, it is difficult to determine what part parvoviruses play in enteric diseases since they are often isolated concomitantly with other agents such as rotaviruses, reoviruses and astroviruses. Loss of appetite, depression, impaired growth, poor feathering, watery diarrhea, higher mortality, osteoporosis and bone deformation are some of the clinical signs associated with syndromes such as RSS and PEC, in which parvoviruses may play a role.

The small intestines, and occasionally the ceca, are pale and distended with mucus, gas and fluid feces. Other secondary lesions such as stunted growth, bad feathering, large quantities of litter in the gizzards and soft and flexible bones can be observed.

Microscopically, moderate to severe enlargement of crypts and acute catarrhal enteritis in the duodenum and jejunum can be seen. Intranuclear inclusion bodies have also been reported within the absorptive epithelial cells of the ileum. Positive staining by indirect immunohistochemistry has been detected in the epithelial and inflammatory cells of the *lamina propria* of the duodenum and jejunum, in follicles of the bursa of Fabricius, in the liver and in the exocrine pancreas.

Diagnosis

A conventional polymerase chain reaction (PCR) has been developed and found to be highly specific and sensitive. A real time PCR assay has also been developed for quick detection of parvoviruses in chickens. It proved to be more sensitive and less arduous than the conventional PCR. Serologic assays (ELISA) are also frequently used to confirm

the presence of infection or to assess the immune status of the birds. Electron microscopy may also be used for diagnostic purposes.

Treatment & control

Although passive immunity may play a crucial protective role in the first weeks of life, there are no vaccines available. There is also no treatment available. Therefore, good management and biosecurity measures are recommended as for rotavirus infections.

TURKEY TOROVIRUS INFECTION

Toroviruses have been reported in cases of enteritis in many species such as humans, dogs, cattle and pigs. In turkeys, the virus formerly known as stunting syndrome agent has now been identified as a turkey torovirus.

Etiology & epidemiology

Toroviruses are a part of the *Coronaviridae* family and are classified in the *Nidovirales* order. They are enveloped single stranded RNA viruses.

The prevalence of turkey toroviruses is unknown. However, antitorovirus serum antibodies were detected in turkey flocks in Israel and a study in the United States has shown that about 30% of turkeys experiencing enteric disease were positive for the virus. Therefore, turkey toroviruses may be widely distributed.

The possible carrier state and transmission patterns are currently unknown. Chickens and chicken embryos are resistant to the infection.

Clinical signs & lesions

The infection usually occurs during the first three weeks of life. Older turkeys are also susceptible to infection. However, clinical manifestations may be mild or absent. Clinical signs have a mean duration of seven to ten days and include diarrhea, depression and litter eating, leading to flock unevenness. Morbidity may be high, but mortality is usually low.

The intestines are pale, seem thin-walled and contain watery and undigested feed material. The ceca may be dilated with watery, frothy and brownish contents. Histological changes are subtle. Little to no loss of mature epithelial cells is observed.

Diagnosis

A RT-PCR assay has been developed and used under experimental conditions to detect turkey toroviruses. Indirect fluorescence antibody (IFA) assay, direct electron microscopy on fecal contents and isolation by inoculation of turkey embryos are also possible means of diagnosis.

Treatment & control

No vaccines or treatments are currently available. However, passive immunity has proven to help control the severity and duration of the disease. Like for other enteric conditions, good management and biosecurity measures must be emphasized.

REOVIRUS INFECTIONS

Reoviruses have been isolated from many tissues of chickens and turkeys showing different pathologies such as arthritis, respiratory disease, immunosuppression and enteric diseases (see Chap.II.27 & Chap.II.39). They have also proven to cause synergistic effects and enhanced pathogenicity with other agents including chicken anemia virus, *Escherichia coli* and infectious bursal disease virus.

Etiology & epidemiology

Reoviruses belong to the *Reoviridae* family and are a part of the *Orthoreovirus* genera. They are non-enveloped double-stranded RNA viruses. Chicken reoviruses differ from turkey reoviruses. Genetically, the enteric reoviruses are the same as those implicated in tenosynovitis in turkeys.

There exists a great variation in reovirus virulence, with about 80-90% of strains being non-pathogenic and others being moderately to highly pathogenic.

Reoviruses seem widely distributed among healthy and clinically affected flocks. The common route of contamination is direct and indirect horizontal transmission. Reoviruses are resistant in the environment.

Clinical signs & lesions

The virus alone has not been shown to cause disease experimentally, but will cause enteric disease when associated with other viruses.

Affected birds showed diarrhea, ruffled feathers and depression.

Gross lesions are non-specific. The most common lesions are watery and frothy intestinal contents. In some cases, atrophy of the bursa of Fabricius has been described.

Microscopic lesions consist of mild crypt hyperplasia, infiltration of *lamina propria* and moderate to severe lymphoid depletion in the bursa of Fabricius. Mild lymphoid depletion in spleen and lymphocytic infiltration of liver, heart, proventricule and pancreas may also be seen.

Diagnosis

Several RT-PCR assays exist. However, the most sensitive is a real time RT-PCR in which viral load can be quantified. Virions can also be detected by electron microscopy. Some ELISAs are commercially available for easy detection of reovirus specific antibodies in chickens.

Treatment & control

There are no effective vaccines or treatments. Due to its ubiquitous nature, good management and biosecurity measures may currently be the best mean of control.

AVIAN ENTEROVIRUS-LIKE VIRUS INFECTIONS

The term enterovirus-like applies to viruses found in the gut of poultry that have not yet been fully characterized.

Etiology & epidemiology

Enteroviruses are a part of the *Picornaviridae* family, which are non-enveloped single-stranded RNA viruses. Due to antigenic similarities with avian nephritis virus, several enterovirus-like viruses (ELV) may be reclassified among astroviruses in the future.

Enteroviruses have been detected in a number of avian species. They have been identified in commercial birds such as turkeys, chickens, pheasants, guinea fowls and partridges, and in wild birds such as cockatoos, galahs and ostriches. Enterovirus-like infections have been described in many countries and continents.

The most common route of transmission seems to be horizontal, through ingestion of infected fecal material. Indirect transmission through contaminated objects and mechanical vectors such as darkling beetles may also be a possibility. Vertical transmission is suspected since the detection of an ELV from meconium of a dead-in-shell chicken embryo.

Clinical signs & lesions

The disease usually occurs in the first week of life. Under field conditions, ELVs are often found in mixed infections. Diarrhea, decreased feed conversion, and stunting of growth lead to uneven flocks. Higher mortality may also be observed.

In one study, co-infection of turkeys with an ELV and a rotavirus produced more severe clinical signs and lesions than those observed in poults that received either inoculum alone.

Experimentally, the ceca were thin-walled, dilated and filled with yellowish frothy fluid. The serosa of the gastrointestinal tract was pale and catarrhal secretions were found in the small intestines. In addition of various degrees of villous atrophy, crypt elongation was observed in the small intestine. These lesions suggest that diarrhea is caused by nutrient malabsorption which leads to osmotic attraction of water into the small intestine.

Diagnosis

Avian ELVs are mainly diagnosed by direct or immune transmission electron microscopy (TEM) of fecal or intestinal samples. Also, an ELISA has been used for the detection of turkey ELVs. It is reported to be sensitive and specific.

Treatment & control

There are currently no effective treatments or vaccines available. Control of infection may be effective by applying basic biosecurity measures and good management strategies.

REFERENCES

- Day J M. Rotavirus Infections. In *Diseases of Poultry*, 13th ed., DE Swayne et al. John Willey and Sons Inc, Ames, Iowa. 2013, pp. 381-391.
- Day JM & Zsak L. Recent progress in the characterization of avian enteric viruses. *Avian dis.* 2013,57:573-580.
- Hayhow CS. Avian Enterovirus-Like Infections. In *Diseases of Poultry*, 13th ed., DE Swayne et al. John Willey and Sons Inc, Ames, Iowa. 2013, pp. 395-399.
- Jindal, N and al. Enteric viruses in turkey enteritis. *Virus Dis.* 2014 DOI 10.1007/s13337-014-0198-8 (published online 19 February 2014)
- Mettifogo E et al. Emergence of Enteric Viruses in Production Chickens Is a Concern for Avian Health. *Scientific World J*, 2014, , Article ID 450423, 8 pages.
- Nunez LFN & Piantino Ferreira AJ. Viral agents related to enteric disease in commercial chicken flocks, with special reference to Latin America. *World's Poultry Sci J*, 2013,69:853-864.
- Reynolds DL. Turkey Torovirus Infection. In *Diseases of Poultry*, 12th ed., Saif YM et al. Blackwell/Iowa State University Press, Ames, Iowa. 2008, pp. 361-364.
- Zsak L. Enteric Parvovirus Infections of Chickens and Turkeys. In *Diseases of Poultry*, 13th ed., DE Swayne et al. John Willey and Sons Inc, Ames, Iowa. 2013, pp. 399-405.

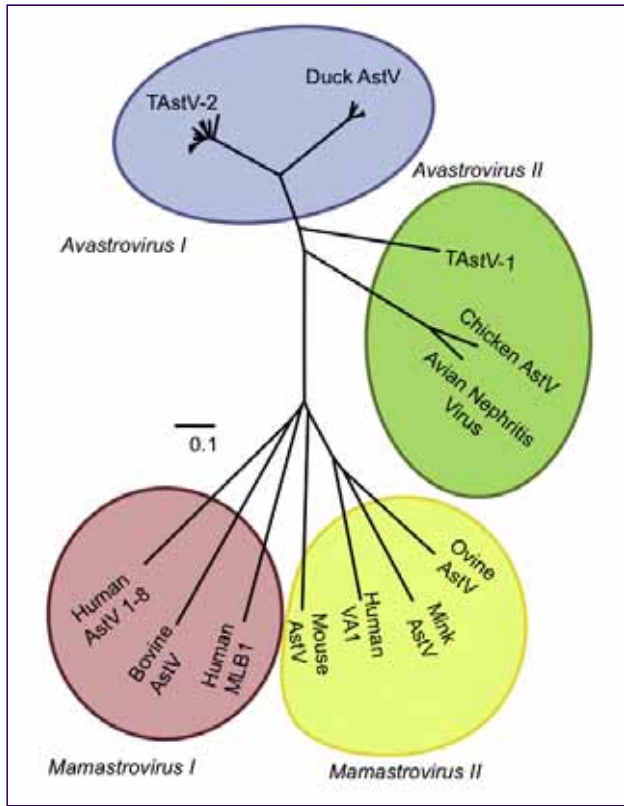


Fig.29.1: Phylogenetic tree of astrovirus whole genomes from selected mammalian and avian species.

	PEMS +	PEMS -
Astrovirus +	8	12
Astrovirus -	3	21

Tabl.29.1: Cross-tabulation of PEMS and astrovirus status (determined using RT-PCR) for 44 turkey flocks (11 PEMS positive and 20 Astrovirus positive). Fisher's Exact Test - p = 0.078.

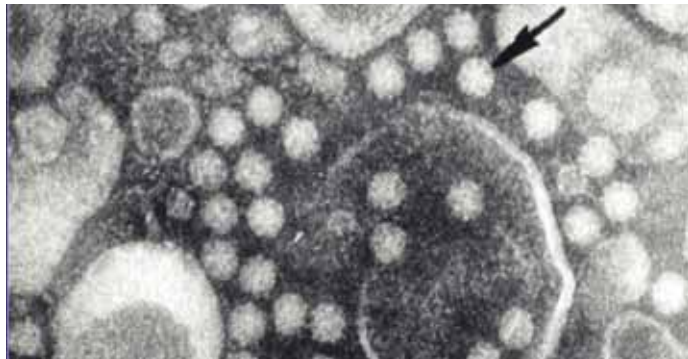

Fig.29.2: Turkey Astrovirus.

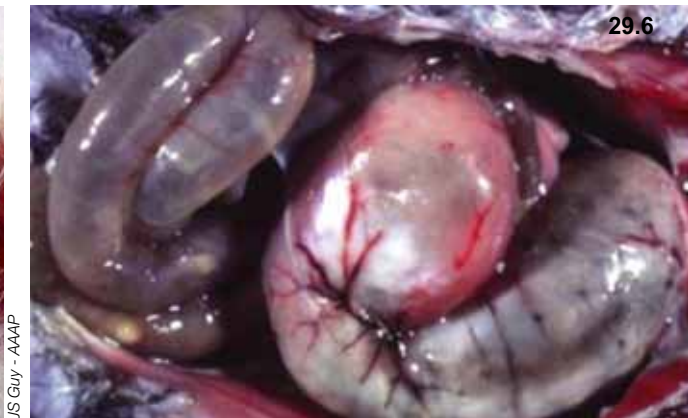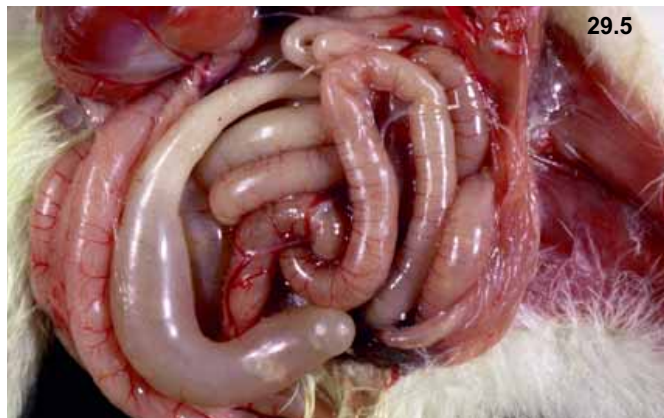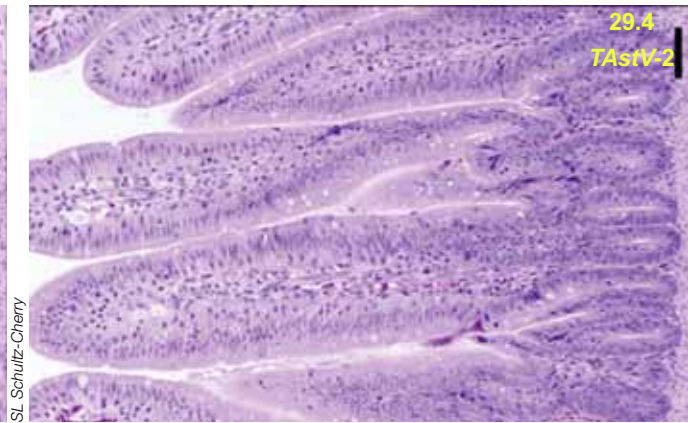
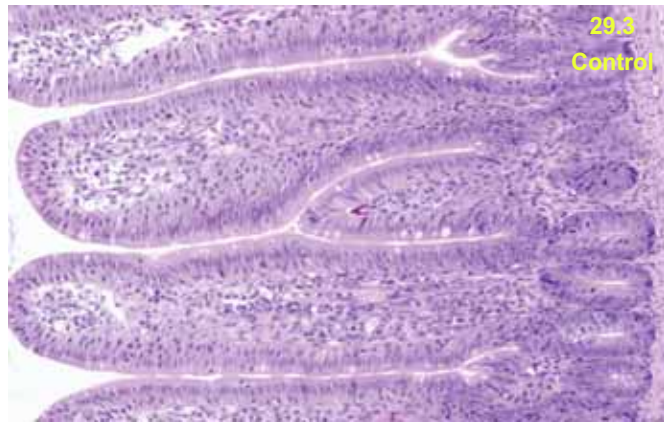


Fig.29.3, 29.4, 29.5 & 29.6: Intestines from control or turkey astrovirus-2 (TAstV-2) infected poults at 3 days post-infection as visualized microscopically by hematoxylin & eosin (Fig.29.3 & Fig.29.4) or grossly (Fig.29.5 & Fig.29.6). Although only minor histological lesions are seen, the intestines from TAstV-2-infected birds are clearly thin-walled, distended, and fluid filled.

29. ASTROVIRUS INFECTIONS

INTRODUCTION

Astroviruses are a family of viruses affecting many avian and mammalian species. In birds, the avastroviruses fall into two genogroups, *Avastrovirus* I and II that have been associated with enteritis, hepatitis, and nephritis. But it is their possible role in the poult enteritis complex (PEC), in particular the poult enteritis mortality syndrome (PEMS), that has drawn the most attention over the last 18 years; although the first report of astroviruses linked to intestinal problems in young turkeys actually dates back to 1980.

ETIOLOGY & EPIDEMIOLOGY

Astroviruses, as the name implies, are small star-shaped viruses with five to six pointed surface projections. However, this morphology is only observed in a small percentage of particles by immune electron microscopy. Astroviruses are non-enveloped RNA viruses found in many parts of the world, mainly in young birds less than five weeks old. Although more prevalent in poults with enteritis, it can be isolated from healthy birds. In fact, recent studies have shown that, at the flock level, the vast majority of chicken flocks, and up to 100% of turkey flocks in a given region may be infected with astroviruses. They are commonly associated with the runting-stunting syndrome of broilers (although a recent study indicates that a parvovirus may also be linked to this syndrome), and enteritis in guinea fowl. Astroviruses have also been associated with stunting and pre-hatching mortality in duck and goose embryos.

To date, six different avian astroviruses have been confirmed: two of turkey-origin (TAsV-1 TAsV-2); two of chicken-origin [Avian Nephritis Virus (ANV) and Chicken Astrovirus (CAstV)]; and two of duck-origin (DAstV-1 and -2). The molecular characterization of these viruses shows wide genetic variability among each type, and this variability influences the ability to detect them by molecular and serological techniques (see the phylogenetic tree of fig.29.1).

Astroviruses are transmitted horizontally via the fecal-oral route. Vertical transmission is suggested based on field observations for the astrovirus associated with avian nephritis. Morbidity can be elevated, while mortality is normally low unless other pathogens are present. Indeed, it is not unusual to simultaneously detect astroviruses with rotaviruses,

reoviruses, coronaviruses and adenoviruses type I in broiler chicken flocks. The same has been observed in turkeys affected with PEC.

In a study conducted in three different American states, diagnostic investigations compared PEMS positive turkey flocks to PEMS-free flocks raised at the same time and in the same regions. Although not significant at p -value < 0.05 , there seems to be an association between PEMS and astrovirus status (see Tabl.29.1). Figure 29.7 also shows that flocks found to be infected with astrovirus had, on average, about double the mortality rate.

Astroviruses are extremely environmentally stable and resistant to most disinfectants. They are not inactivated by phenolics, acidic pH, detergents, ambient temperature, quaternary ammonia, and most alcohols. Only a few disinfectants, such as formaldehyde, β -propiolactone, 90% methanol, and potassium peroxymonosulfate can destroy this virus.

CLINICAL SIGNS & LESIONS

In turkeys, clinical signs are normally noted before six weeks of age (mainly 1 to 3 weeks) and may last up to 12-14 days. They include diarrhea, listlessness and nervousness. In turkeys, growth depression often follows the initial clinical signs. It is, at least in part, a consequence of decreased intestinal absorption in infected poults.

Astroviruses in chickens have been mainly associated with mild stunting. An exception would be avian nephritis, a rare acute condition. Normally, chickens infected with the avian nephritis virus (ANV) remain subclinical (detected by RT-PCR mainly in Japan, China, Africa, Europe, and the United States). Under field conditions, the clinical expression will vary from a runting syndrome to death caused by nephropathy and visceral gout.

In ducks, astroviruses have been associated with hepatitis, which can be fatal. They have been confirmed in what is called Duck Hepatitis Virus (DHV) type II [to differentiate this condition from Type I caused by picornaviruses (see Chap.VI.90)]. DHV type II is an astrovirus also known as duck astrovirus-1, (DAstV-1). To date, this disease has only been reported sporadically in England and China. It occurs in ducklings from 10 days to 6 weeks of age (mature ducks are not affected), and

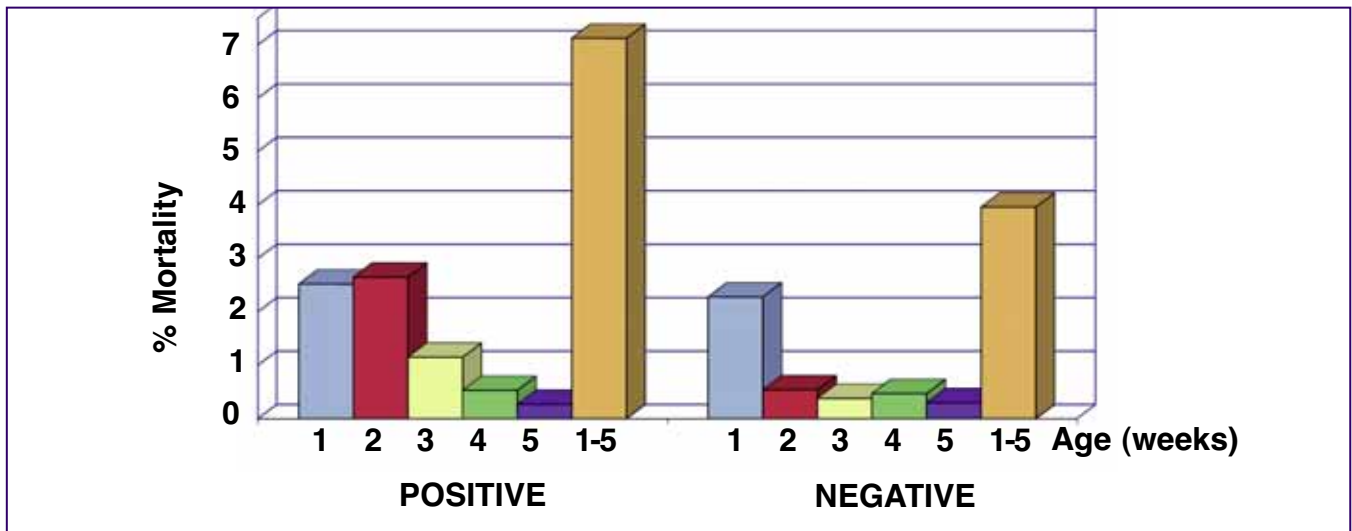


Fig.29.7: Weekly mortality comparison based on astrovirus status determined by RT-PCR. Average % mortality for 11 astrovirus positive flocks versus 33 astrovirus negative flocks. Note elevated mortality for astrovirus positive flocks at 2 and 3 weeks of age.



SL Schultz-Cherry

Fig.29.8: Age-matched poults 12 days post TAstV-2 (left) or saline (right) inoculation.



JY Ferré

Fig.29.9: Observations of PEMS in the field in France.



SL Schultz-Cherry



SL Schultz-Cherry

Fig.29.10 & 29.11: Commercial turkey flocks with poult enteritis mortality syndrome. Note the severe stunting in some birds.

causes lesions similar to those of DHV type I. Death may occur in an hour to four days after the onset of clinical signs, including loose droppings, polydypsia, excessive urate excretion and nervous signs (convulsions, opisthotonos). Recent studies have shown that another astrovirus, reported to date only in the United States, and different from DHV type II astrovirus, can also cause hepatitis. It is named Duck Astrovirus type 2 (DAstV-2).

In turkeys at necropsy, typical observations are dilated ceca with yellowish frothy content and gaseous fluid. The overall intestinal track shows a loss of tone (intestinal wall is thinner than normal). Diarrhea is partly attributed to the osmotic effect of undigested and unabsorbed nutrients drawing water to the lumen of the intestine. Microscopically, a crypt hyperplasia is noted in the small intestine, but no villous atrophy; although a mild shortening of the villi has been noted in some experiments. Changes occur as early as one day post-infection. Viral replication is limited to the intestine. But a transient viremia has been observed three days post-infection under experimental conditions. There is a lack of inflammatory response and overt tissue damage to this pathogen. It seems that peripheral blood lymphocytes are much less responsive in infected compared to control birds.

Chickens affected with the ANV show lesions largely limited to the kidney. Epithelial cells of the proximal convoluted tubules are necrotic. Granulocytes are present, as well as a lymphocytic infiltration in the interstitium with some fibrosis. Visceral urate deposits are generalized in chicks dying from this condition.

In ducks, lesions are mainly observed in the liver and kidneys. The liver is pale with small hemorrhages that may form bands. The spleen is enlarged with pale foci. Kidneys are often swollen with a prominent vascularization. Small hemorrhages may be noticed in the intestinal wall and on the heart fat.

DIAGNOSIS

Diagnosis can be made by observing aggregates of typical astrovirus particles by immune electron microscopy. Other diagnostic tools include antigen capture enzyme-linked immunosorbent assays (AC-ELISA) and reverse transcriptase polymerase chain reaction (RT-PCR) or real-time RT-PCR. The latter procedure is typically used on a pool of feces from three to five birds per flock. The RT-PCR is a very sensitive and specific test. However, given that most chicken and turkey flocks become infected, unless a specific strain is found to be associated with clinical signs, and assays

can be developed to identify it, confirming the presence of the infection may be of little value. Although testing for astroviruses in the context of trying to identify all pathogen combinations that might be associated with a repeat PEC on a given site may have merit.

Confirmation of diagnosis in cases of avian nephritis requires demonstrating the presence of ANV antigens by immunohistochemistry or viral RNA by *in situ* hybridization.

For duck hepatitis, an indirect ELISA has been developed. Electron microscopy is also used.

TREATMENT & CONTROL

No vaccine or treatment exists for chicken broilers or poults. Some recent reports suggest that vaccinating chicken breeders may offer some protection from the runting syndrome for progeny. Like for any other enteric conditions, good management practices (good ambient temperature, litter management, *etc.*) may reduce the impact of the infection on flock performances (see Chap.IV.72 on the PEMS). Emphasis should be placed on thorough cleaning and disinfection with a downtime of at least two weeks between flocks.

It seems that DHV type II and III infections could be controlled by the use of live attenuated vaccines given to breeder ducks to confer passive immunity to progeny. However, although tested experimentally, these vaccines have yet to be commercially available. None have been developed against ANV in chickens, largely due to the high level of antigenic diversity.

REFERENCES

- Koci MD & Schultz-Cherry SL. Avian astroviruses. Review article. *Av Pathol*, 2002;31:213-227.
- Pantin-Jackwood MJ et al. Enteric viruses detected by molecular methods in commercial chicken and turkey flocks in the United States between 2005 and 2006. *Av Diseases*, 2008,52:235-244.
- Night P.K et al. Astrovirus infection induces sodium malabsorption and redistributes sodium hydrogen exchanger expression. *Virology* (2010) 401; 146-154.
- Schultz-Cherry S.L. Astrovirus Infections. In *Diseases of Poultry*, 13th Ed., Ed. DE. Swayne, Wiley-Blackwell, 2013, pp 391-395.
- Pantin-Jackwood MJ et al. Avian Astroviruses. In *Astrovirus Research. Essential Ideas*, Everyday Impacts, Future Directions. Ed. S Schultz-Cherry. Springer; ISBN: 978-1-4614-4734-4 (Print) 978-1-4614-4735-1 (Online); pp151-180.



Fig.30.1: Chick with dermatitis naturally infected with CIAV.

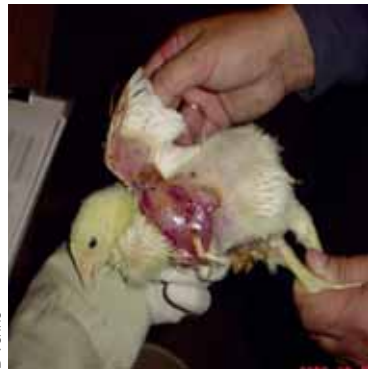

Fig.30.2 & 30.3: Gangrenous dermatitis resulting from secondary bacterial infections is often observed. Skin lesions usually develop on the wings as seen in "blue wing disease".

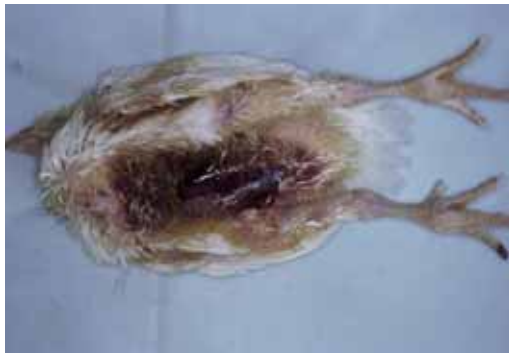

Fig.30.4, 30.5 & 30.6: Skin lesions may also appear on other parts of the body.

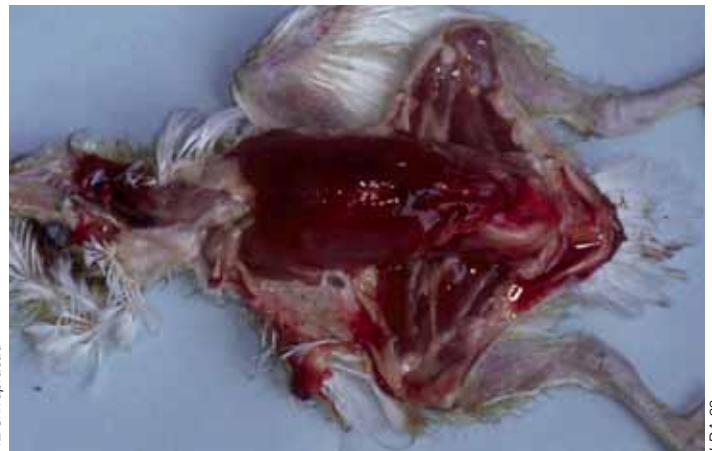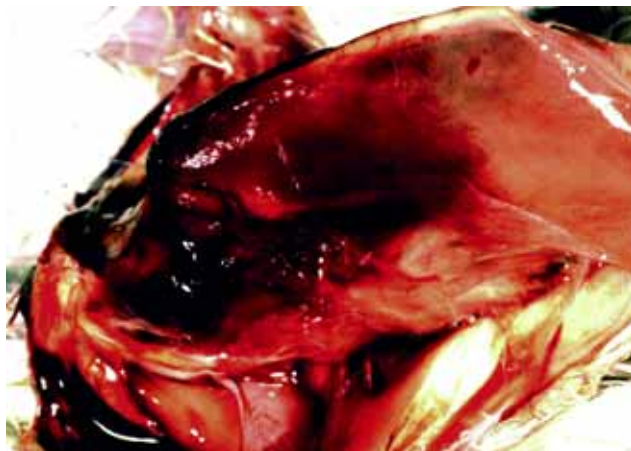


Fig.30.7 & 30.8: Intramuscular hemorrhages in chicks with CIAV.

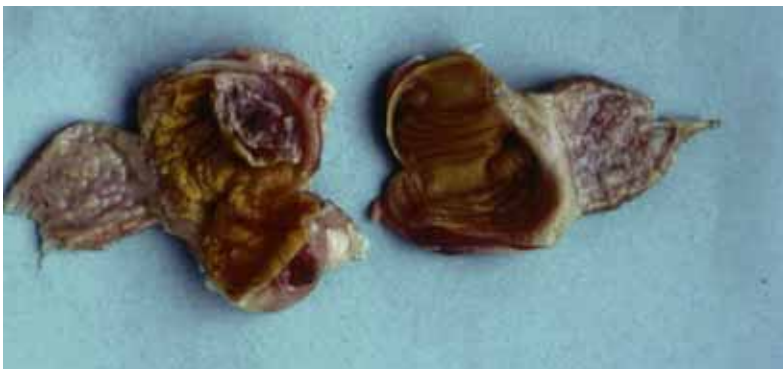

Fig.30.9: Hemorrhages in the gizzard with CIAV.

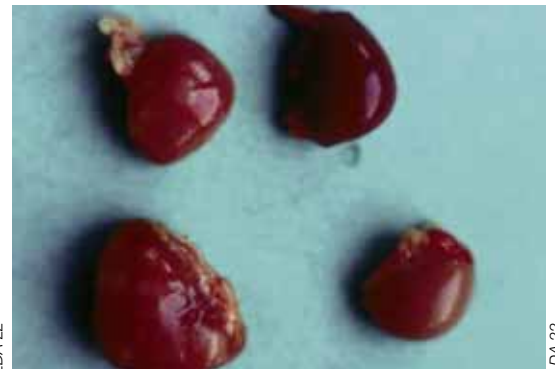

Fig.30.10: 3 spleens decolorized by anemia with CIAV. Compare with the normal spleen at the top on the right.

Viral diseases

30. CHICKEN INFECTIOUS ANEMIA

INTRODUCTION

Chicken infectious anemia virus (CIAV) was first isolated in 1979 and since then, it has been detected in chickens all over the world. CIAV is classified in the family of *Circoviridae*, genus *Gyrovirus* based on its size and genomic features.

ETIOLOGY & EPIDEMIOLOGY

Chickens are the target hosts for CIAV and the virus has not been identified in other avian species although antibodies have been detected in Japanese quail. Outbreaks of chicken infectious anemia (CIA) are limited to the progeny of breeder flocks that lack immunity at the onset of egg production because maternal antibodies are protective against the development of anemia in chicks.

Although antibodies prevent the development of clinical disease, they reduce but do not prevent either vertical or horizontal transmission of CIAV. Horizontal transmission of CIAV occurs directly *via* oral or respiratory inoculation and vertical transmission can be by either infected dams or sires.

CIAV is extremely resistant to inactivation by drying and chemical disinfectants and can persist in poultry environments for weeks to months and possibly years.

CLINICAL SIGNS & LESIONS

Clinical disease occurs in chicks infected before they reach 3 weeks of age or in immunosuppressed chickens. Infection in immunocompetent chickens does not result in detectable lesions although immune dysfunction, decreased weight gain, feed conversion, and livability can be measured. Chicks with CIA develop severe anemia (hematocrit less than 27%), pancytopenia, and immunosuppression that may result in secondary infections. Atrophy of the thymus, and pale bone marrow are the most characteristic lesions of CIA although bursal atrophy is often observed in

clinical cases. Both the medulla and cortex of the thymus are typically atrophied and cells of all hematopoietic lineages in the bone marrow are depleted resulting in the pale bone marrow observed in the clinical presentation of CIA.

Cutaneous, intramuscular, and mucosal hemorrhages are often, but not always, seen in affected chicks. The cause of the clotting disorder associated with CIAV infections is at least partially explained by a thrombocytopenia after the destruction of hemocytoblasts in the bone marrow. Damage to endothelial cells and diminished liver function may be important in the pathogenesis of the hemorrhagic syndrome.

CIAV is a lymphotropic virus and infected lymphocytes have been detected in virtually all organs. Small, eosinophilic, intranuclear inclusion bodies have been observed in lymphocytes in the thymus, bursa of Fabricius, spleen, and other organs and in lymphocytes and hemocytoblasts in the bone marrow of infected chicks.

CIAV infections are an important part of several multifactorial disease complexes. One example, blue wing disease causes mortality in chickens between 12 and 20 days of age. Gangrenous dermatitis of the skin and underlying muscles and severe depletion of thymic and bursal lymphocytes are the characteristic lesions of this disease. This syndrome has been experimentally reproduced with agents isolated from field cases, including CIAV, avian reovirus, and bacterial pathogens. CIAV may play a similar role in the pathogenesis of gangrenous dermatitis, inclusion body hepatitis, chondronecrosis, and amyloid arthropathy.

CIAV interferes with vaccinal immune responses and has been implicated in acting synergistically with other disease agents including Marek's disease virus, cryptosporidiosis, avian reovirus, infectious bursal disease virus and others. The mechanisms of these interactions have not been determined.

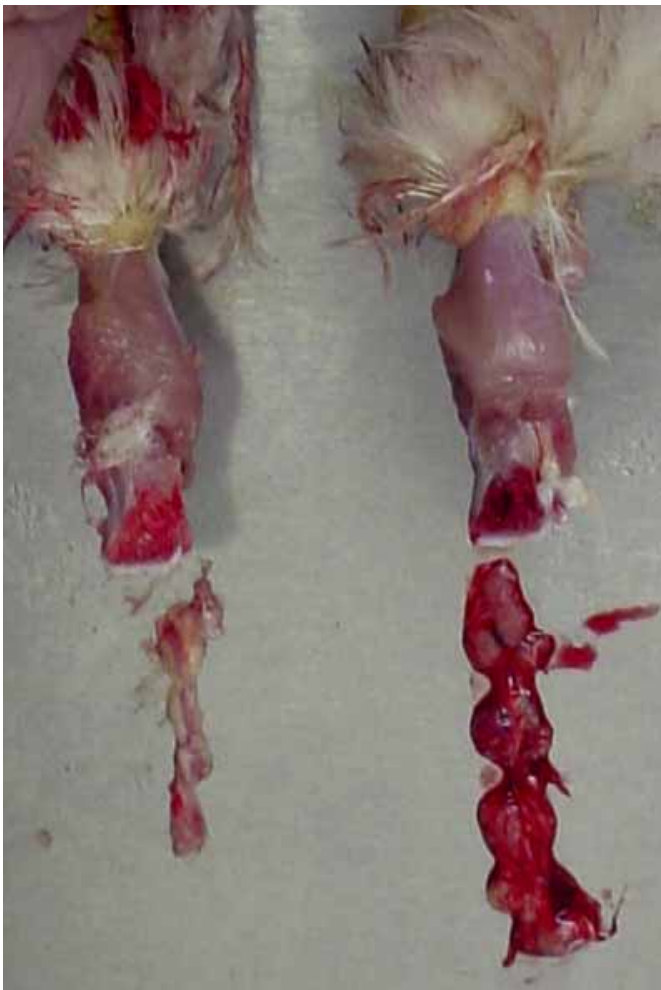

Fig.30.11: In the field, the diagnosis of CIA is made by observation of the atrophy of thymus and of bone marrow. Compare the infected chick on the left with the normal chick on the right.

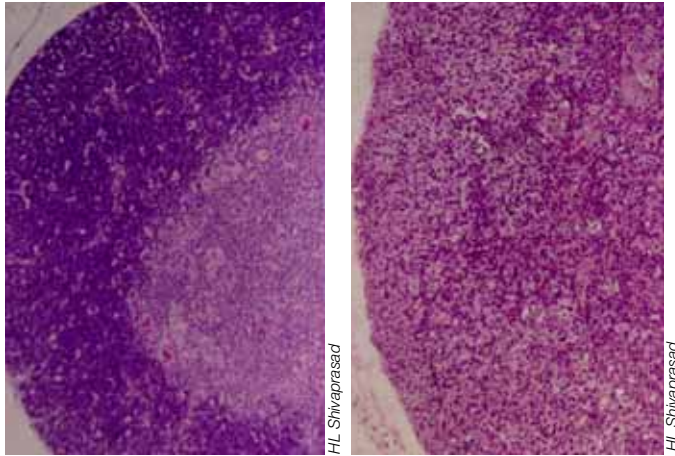


Fig.30.12 & 30.13: Thymic atrophy, histology. Normal thymus on the left, cortical and medullary depletion of lymphocytes in the thymus of a CIAV-infected bird on the right.

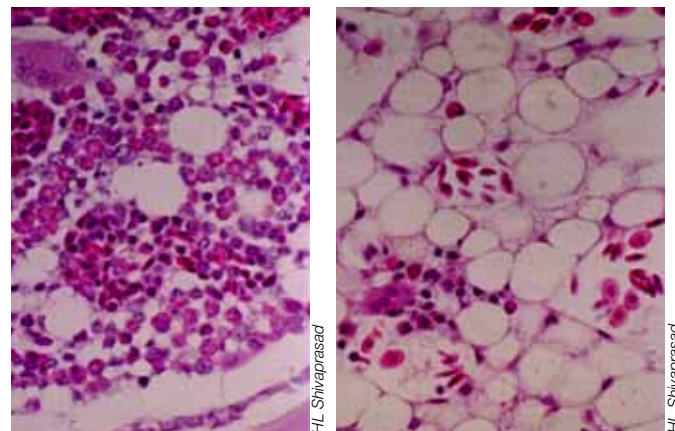


Fig.30.14 & 30.15: Bone marrow atrophy, histology. Normal bone marrow on the left and atrophy of bone marrow with hypoplasia of both erythroid and myeloid series cells in a CIAV-infected chick on the right.

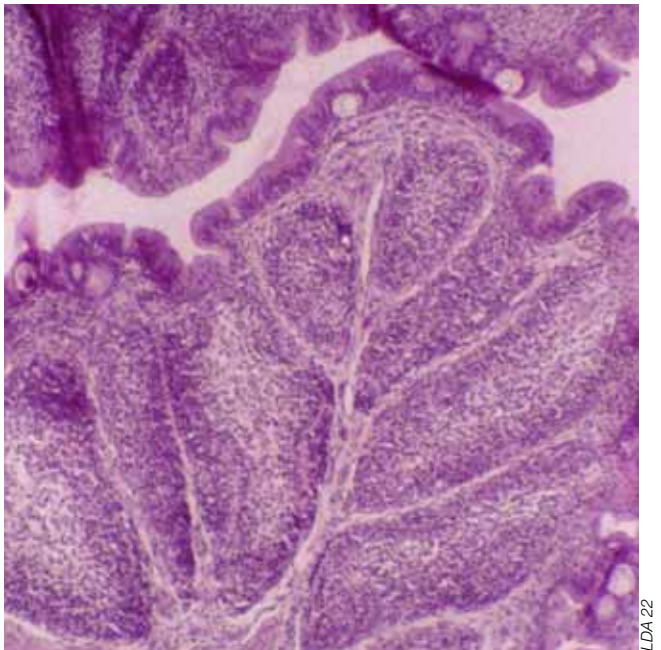


Fig.30.16: CIAV (Chicken). Lymphoid depletion in the bursa of Fabricius.

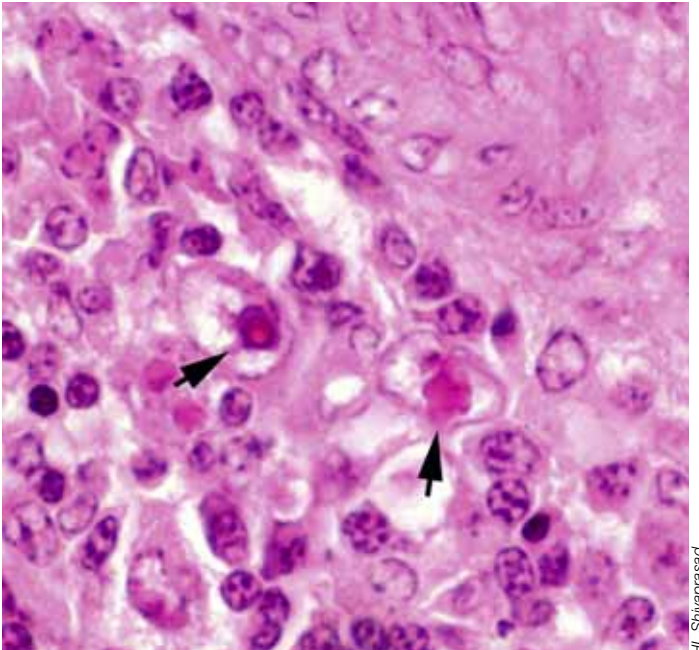


Fig.30.17: Splenic intranuclear inclusions. Eosinophilic, intranuclear inclusions typical of CIAV in lymphocytes (arrows).

DIAGNOSIS

CIAV is ubiquitous and can be detected in most chickens so infection and disease must be differentiated when making a diagnosis. CIA can be tentatively diagnosed on the appearance of clinical disease in chicks less than 3 weeks of age although the signs can be misleading and a concrete diagnosis should be made by correlating clinical disease in chicks with breeder antibody titers. Lesions similar to those seen with CIA can be observed in cases of Marek's disease, reticuloendotheliosis and in some cases of infectious bursal disease and these diseases should be considered in a differential diagnosis.

Antibodies to CIAV can be detected with indirect immunofluorescent or immunoperoxidase assays on cell cultures infected with CIAV. Virus neutralization studies have also been described and are widely used. Unfortunately, not all strains of chickens develop measurable antibodies in response to infection with all CIAV strains. And not all infections result in seroconversion at all ages. CIAV can be directly detected in infected tissues with electron microscopy, PCR on lymphocytes, *in situ* hybridization on blood smears and formalin-fixed tissues. Several methods of isolating CIAV have been described

including embryo inoculation, *in vitro* inoculation of chicken mononuclear cells, and isolation in cell culture.

TREATMENT & CONTROL

Many breeders are vaccinated with a live, attenuated vaccine, to ensure adequate antibody titers will be passed to progeny to prevent clinical CIA. Modified live vaccines cause subclinical infections and, therefore, cannot be used for all flocks. Prevention is the best approach to reducing CIAV prevalence since there are no known strategies to eliminate the virus from infected flocks. Specific pathogen-free chicken flocks attempt to remain free of CIAV infection through the use of strict biosecurity procedures.

REFERENCES

- Adair BM. Immunopathogenesis of chicken anemia virus infection. *Dev Comp Immunol*, 2000, 24:247-55.
- Cardona C. L'anémie infectieuse du poulet. *Médecin Vét. Québec*, 2000, 30:202-205.
- Schat KA & van Santern VL. Chicken infectious anemia, In "*Diseases of Poultry*", Ed DE Swayne, 13th ed. Wiley-Blackwell, 2013, Pp. 248-264.



Fig.30.18: It is possible to confirm the anemia with hematocrit tubes showing low Packed Cell Volume (15% to 22%) in 2 naturally infected birds with CIAV compared to a normal (35%) on right.

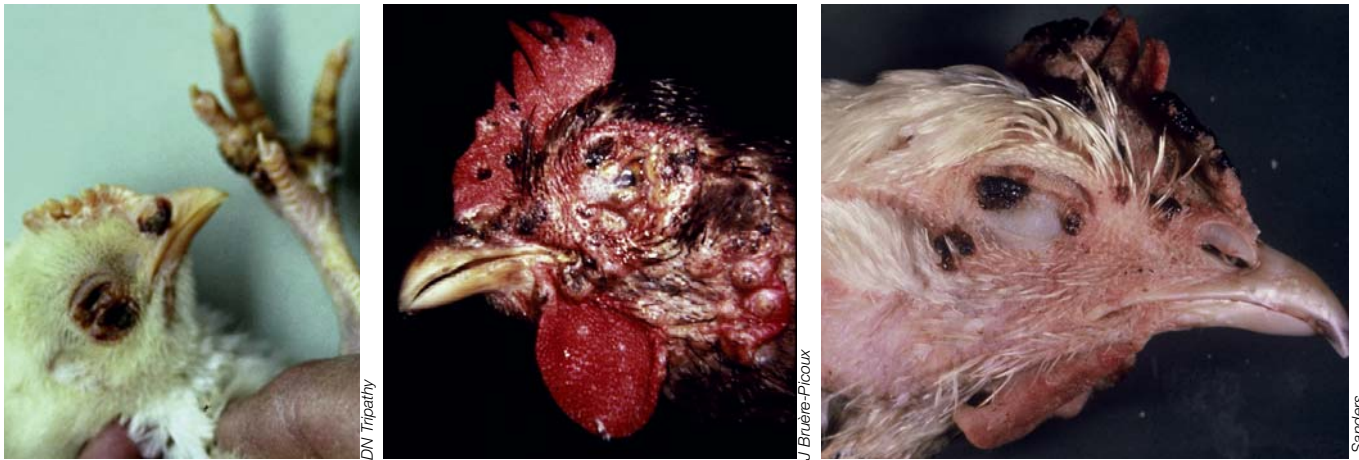


Fig.31.1, 31.2 & 31.3: Cutaneous lesions of fowlpox. The lesions vary according to the stage of development: papules, vesicles, pustules or crusts.

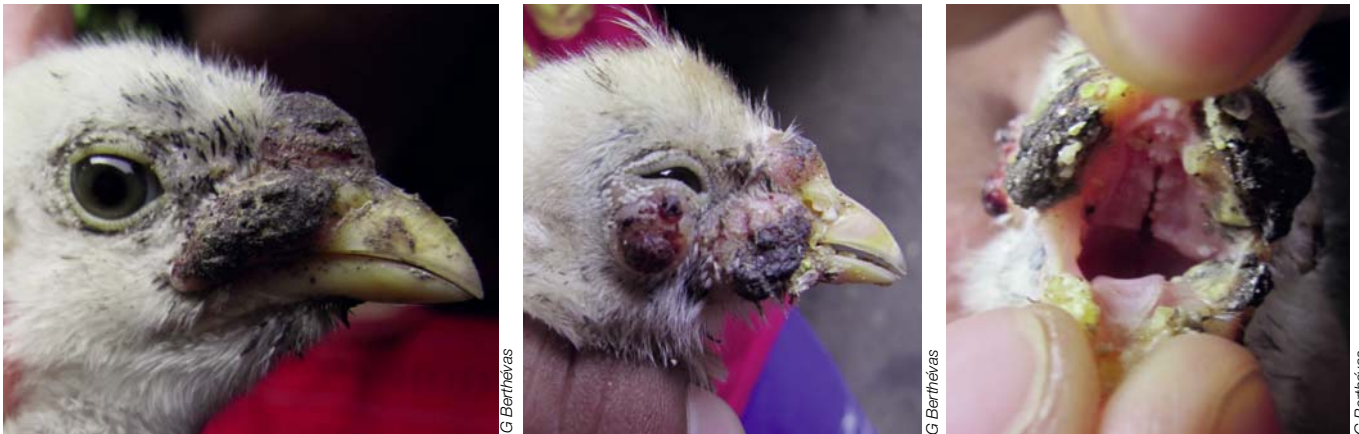

Fig.31.4, 31.5 & 31.6: Cutaneous lesions of fowlpox finally form crusty scabs (fowls).

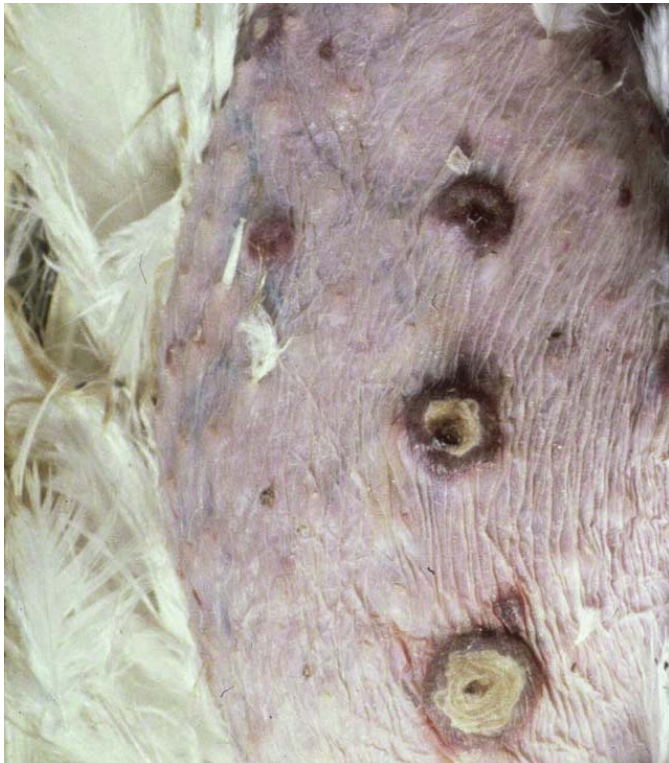

Fig.31.7: Cutaneous lesions of fowlpox can be seen on the featherskin (Chicken).

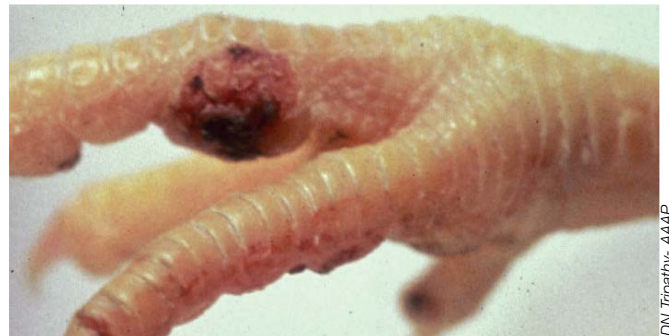

Fig.31.8: Cutaneous lesions of fowlpox on the foot.

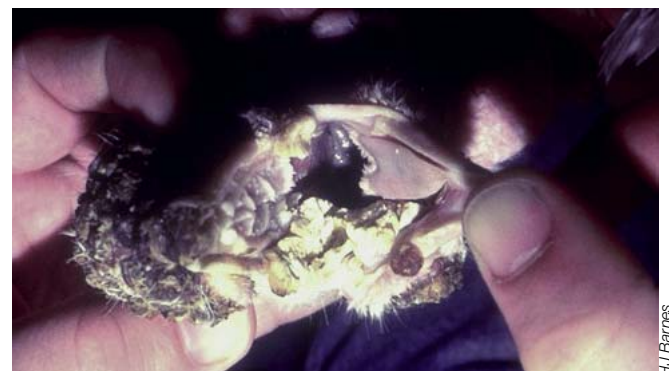

Fig.31.9: Lesions of wet pox in oral cavity (Turkey).

Viral diseases

31. FOWLPOX

INTRODUCTION

Avian pox is a common viral disease of domestic birds (chickens, turkeys, pigeons, and canaries). It is a slow spreading disease characterized by the development of proliferative skin lesions (cutaneous form) and/or upper digestive and respiratory tract lesions (diphtheritic form). The causative agent is a double-stranded DNA virus of the genus *Avipoxvirus* of the family *Poxviridae*. Fowlpox virus is the type species of the genus *Avipoxvirus*. Other members of this genus are canarypox, junco-pox, mynahpox, pigeonpox, psittacinepox, quailpox, peacockpox, penguinpox, sparrowpox, starlingpox and turkeypox viruses. Avianpox viruses have a restricted host range, infecting only avian species.

ETIOLOGY & EPIDEMIOLOGY

Avianpox viruses are distributed worldwide in poultry, pet birds, and wild birds. In some areas the disease is usually more common during summer months when the mosquito population is high. However, in large poultry operations, especially in multiple age complexes, fowlpox may occur during any time of the year. In recent years the epidemiology of fowlpox in many areas has changed because of an increasing concentration of poultry in large complexes, retention of layer flocks for a second cycle of production, and maintenance of multiple age birds.

Overall, poxviruses can withstand extreme environmental conditions and remain viable in dried scabs for extended periods. Scabs shed by the recovered birds may contaminate soil, food and water.

Small abrasions in the skin or mucous membranes allow the entry of the virus since it is unable to penetrate unbroken tissue. Skin lacerations as a result of cannibalism, fighting or preening may assist in the entry of the virus. Insects such as mosquitoes act as mechanical vectors to transfer the virus from infected to susceptible birds. In addition, oral and respiratory infections may occur by exposure to aerosols present in contaminated environments especially in concentrated housing. In this regard, inhalation of virus-laden dust which may contain particles of feathers, skin, or scabs provides an important route for virus exposure.

Transmission is facilitated by the housing of a large number of birds in close quarters. Since the disease spreads slowly, the virus may circulate in the susceptible population for a considerable time. This is a common occurrence where multiple age chicken flocks are maintained.

CLINICAL SIGNS & LESIONS

Generally, the disease occurs in two forms, cutaneous and diphtheritic, although a systemic form of infection may occur. Systemic infections in canaries caused by canarypox virus are common with high mortality.

The cutaneous form is characterized by the development of lesions on the comb, wattles, angle of the beak, feet, vent and other areas of the skin. The lesions on the eyelids or around the beak may interfere with vision and feeding. In such birds productivity is reduced. There is poor feathering in young birds and a transient drop in egg production may also occur in layers.

In the diphtheritic form of the disease clinical signs vary depending upon the location and severity of the lesions. Lesions in the trachea, pharynx, and sinuses interfere with breathing. High mortality occurs due to suffocation resulting from blockage by tracheal lesions. Clinically, respiratory tract lesions simulate signs caused by other respiratory pathogens, especially infectious laryngotracheitis virus in chickens.

Cutaneous, diphtheritic and/or systemic forms of the disease may be present in a single bird. Flock mortality due to cutaneous infections alone is usually low and those flocks generally return to normal productivity upon recovery. Among pet birds, infections often occur in large aviaries of canaries and the disease is likely to be enzootic.

DIAGNOSIS

The most commonly used method for diagnosis of avianpox virus infections is the histopathologic examination of the lesion for the presence of cytoplasmic inclusion bodies. Since similar clinical signs involving the respiratory tract in chickens can be caused by infectious laryngotracheitis virus, rapid differential diagnosis of the disease becomes

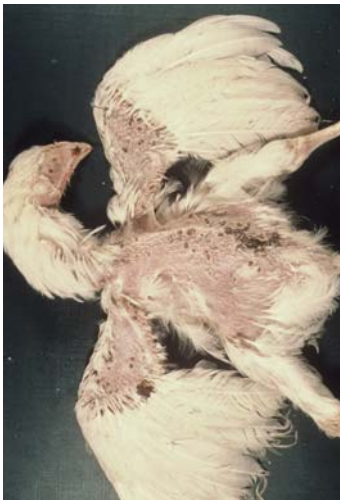
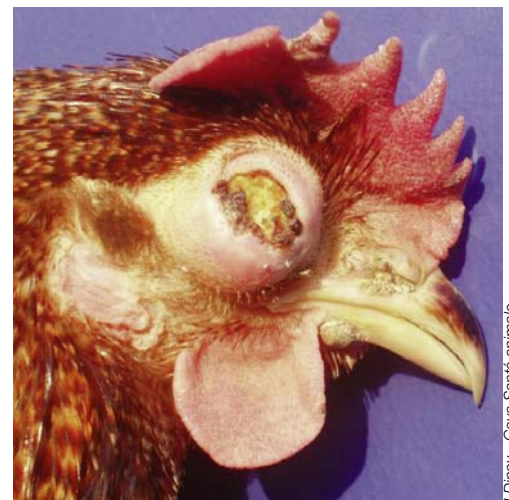
Fig.31.10: Cutaneous lesions of fowlpox can be generalized.

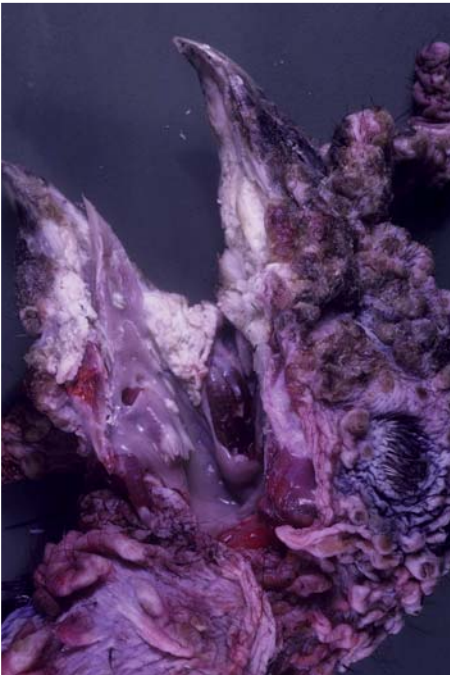

/Dinev - Ceva Santé animale

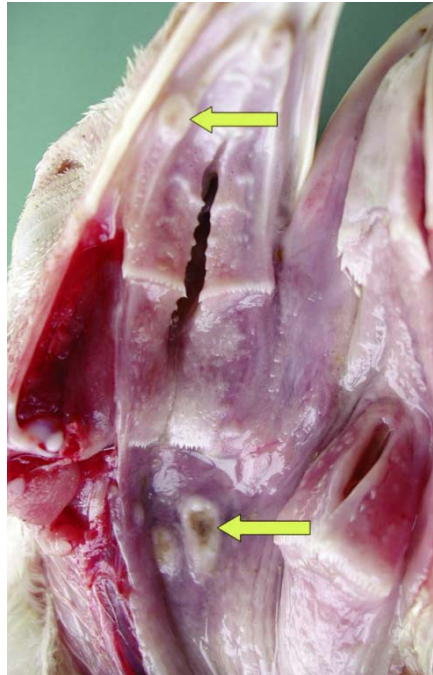


/Dinev - Ceva Santé animale

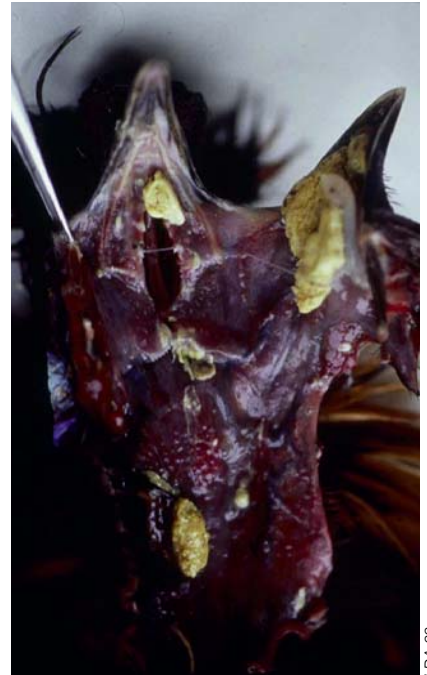Fig.31.11 & 31.12: The conjunctival mucosa, affected by the pox virus, is often the gateway for further contamination (*Escherichia coli*, *Staphylococcus* spp., etc.) and development of complications.



Sanders

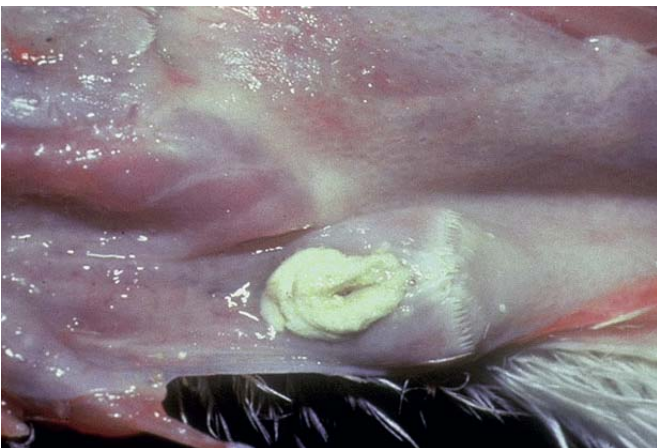

/Dinev - Ceva Santé animale



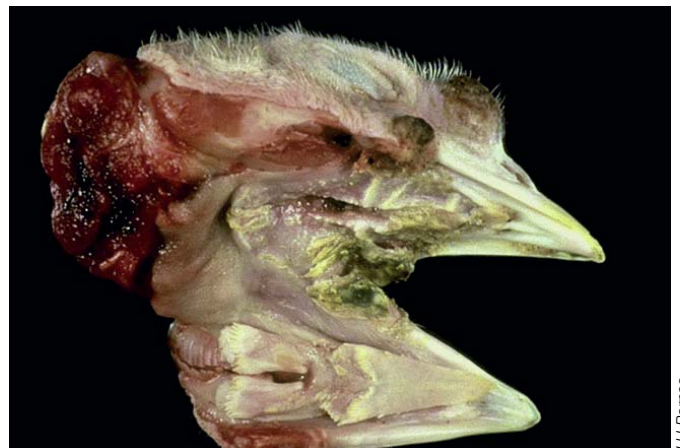LDA 22

Fig.31.13, 31.14 & 31.15: Diptheritic fowlpox lesions are pale colored plaques growing on the mucous coats of the upper respiratory tract (buccal and nasal cavities, the sinuses, the larynx, the trachea) or the esophagus.



HJ Barnes

Fig.31.16: Fowlpox on the trachea.



HJ Barnes

Fig.31.17: Pox. Diptheritic lesions in a breeder turkey.

very important. Infection by infectious laryngotracheitis virus is characterized by the histopathological demonstration of intranuclear inclusion bodies in the respiratory tract epithelium.

Localized proliferations of epithelial cells characterized by hyperplasia and hypertrophy is an important feature of avianpox virus infections. The basal germinal layer of cells in the epithelium shows an increased rate of multiplication. Histopathological examination of the affected dermal and mucous membrane epithelium shows marked hyperplasia with enlargement of the cells and associated inflammatory changes. The infected cells reveal presence of eosinophilic cytoplasmic inclusion bodies when stained with hematoxylin and eosin. These inclusion bodies are often referred to as Bollinger bodies and contain the viral particles or elementary bodies also known as Borel bodies.

Viral particles exhibiting typical poxvirus morphology can be detected by electron microscopic examination of negatively stained lesion suspensions or in ultra thin sections of the lesions. They consist of an electron-dense, centrally located biconcave dumbbell-shaped core or nucleoid containing the viral genome and two lateral bodies in each concavity which are enveloped by one or more membranes.

Avian pox viruses can be propagated on the chorioallantoic membranes (CAM) of 9-12 day-old developing chicken embryos. Virus inoculated embryos are incubated at 37°C in a humidified atmosphere for 5 to 7 days. The CAMs are examined for lesions. The lesions are characterized either by marked thickening of the membrane or by individual pocks of various sizes. Primary or secondary cells of avian origin will support growth of some avianpox viruses. In this regard, chicken liver (LMH), quail fibroblasts (QT-35) and quail liver (IQ1A) have been used for propagation of these viruses.

Cloned genomic fragments of fowl poxvirus can be used effectively as nucleic acid probes for diagnosis. In this procedure, viral DNA isolated from lesions is hybridized either with ³²P-labeled or nonradioactive-labeled genomic probes. This method is especially useful for differentiation of the diphtheritic form of fowl pox from infectious laryngotracheitis when tracheal lesions are present.

While cloned genomic fragments as probes and specific primers for amplification of genomic fragments by polymerase chain reaction (PCR) can be used for diagnosis, these procedures are not routinely performed.

IMMUNE RESPONSE

Cross protection among avianpox viruses is variable although these viruses exhibit an extensive degree of serologic cross-reactivity. Attenuated fowlpox virus vaccines of chicken embryo or cell culture origin have been used extensively for prevention of fowlpox in chickens and turkeys.

Canarypox virus vaccine is used exclusively in canaries and quailpox virus vaccine is required for quails. Birds recovered from natural pox infection are immune to reinfection with that strain.

A natural infection or vaccination is followed by both cell-mediated and humoral antibody responses.

Cell mediated immune responses are detected earlier than the humoral responses. Although not commonly practiced, serologic detection of infection may be important in experimental studies and for measuring the immune responses following vaccination.

Antibody response can be measured by agar gel precipitation (AGP), passive hemagglutination, immunoperoxidase (IP) and enzyme-linked immunosorbant assays (ELISA). ELISA has become the most common method for evaluation of immune responses. Some tests, e.g., IP, indirect immunofluorescence (IFA) and AGP, can also be used to detect viral antigen in the lesion(s). Antigenic differences among isolates can be determined by immunoblotting, cross-protection tests and virus neutralization assays.

TREATMENT & CONTROL

Actively acquired immunity against avian poxviruses results after recovery from natural infection or vaccination. Live modified vaccines of fowlpox and pigeonpox virus origin are used for the immunization of commercial poultry. The vaccine is administered by wing-web stab or by rubbing the vaccine on the thigh after pulling a few feathers. Similarly, modified live vaccines of pigeonpox and turkeypox origin are also available commercially.

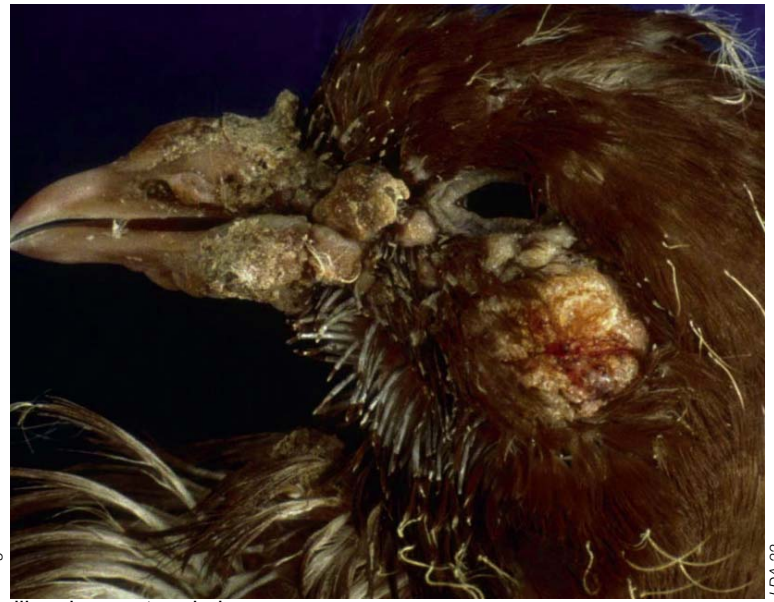
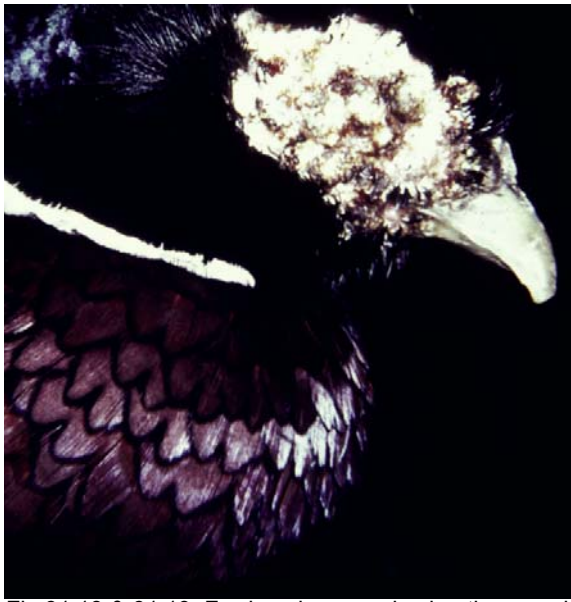
Fig.31.18 & 31.19: Fowlpox is seen also in other species like pheasant and pigeon.

J Brugère-Picoux

LDA 22

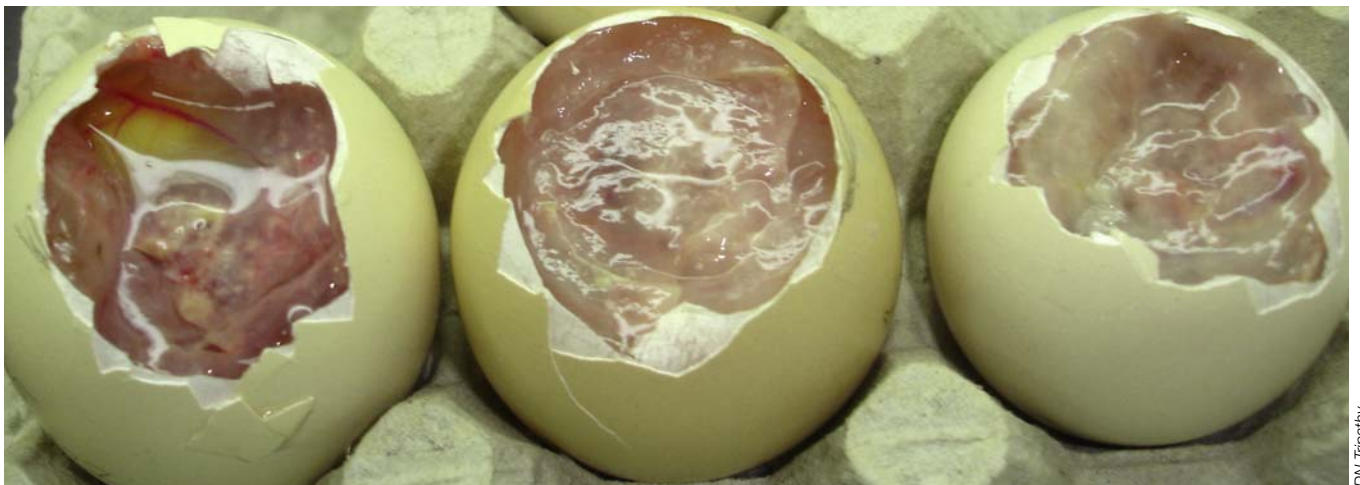

Fig.31.20: Virus may be passaged and amplified *in vivo* through embryonated eggs via chorioallantoic membrane (CAM) infection.

DN Tripathy

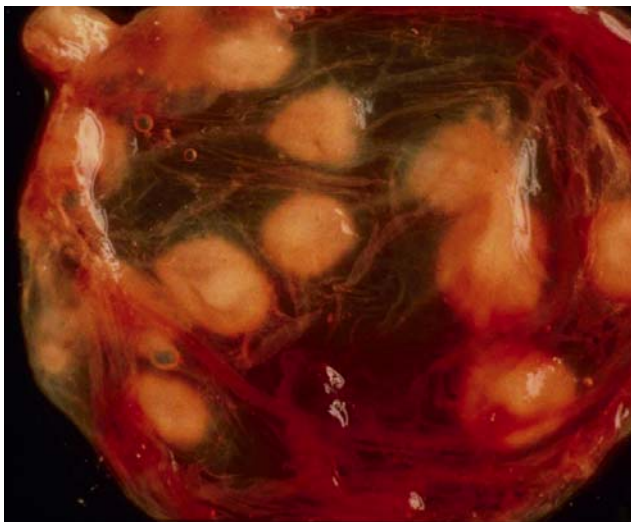


Fig.31.21: Pocks are seen on the CAM.

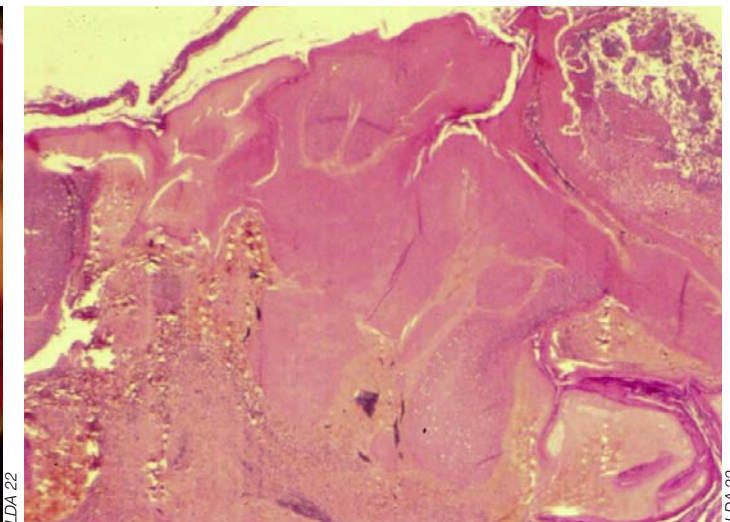


Fig.31.22: Pox (Pigeon). Hyperplasia and necrosis of the epithelium.

LDA 22

LDA 22

The viruses are propagated either in CAMs or primary chicken embryonic or secondary avian cell cultures. If the vaccine is properly applied to susceptible birds, immunity will normally develop within 10 to 14 days after vaccination. Vaccination is also indicated for young birds and those introduced on premises where an infection was diagnosed during the previous year. In areas where pox is prevalent, vaccination may be required to protect birds from virus present in outside sources such as neighboring flocks.

REFERENCES

Tripathy DN. & Reed WM. Pox. In *Diseases of Poultry*, 12th edition, Eds Y.M. Saif et al, Blackwell Publishing, pp. 291-307, 2008.
 Tripathy DN & Reed WM. Pox: In *A Laboratory Manual for the Isolation and Identification, and characterization of Avian Pathogens*. Fifth Edition, Eds. LD Zavala et al, American Association of Avian Pathologists, Inc. Athens, Georgia, pp. 116-119, 2008.

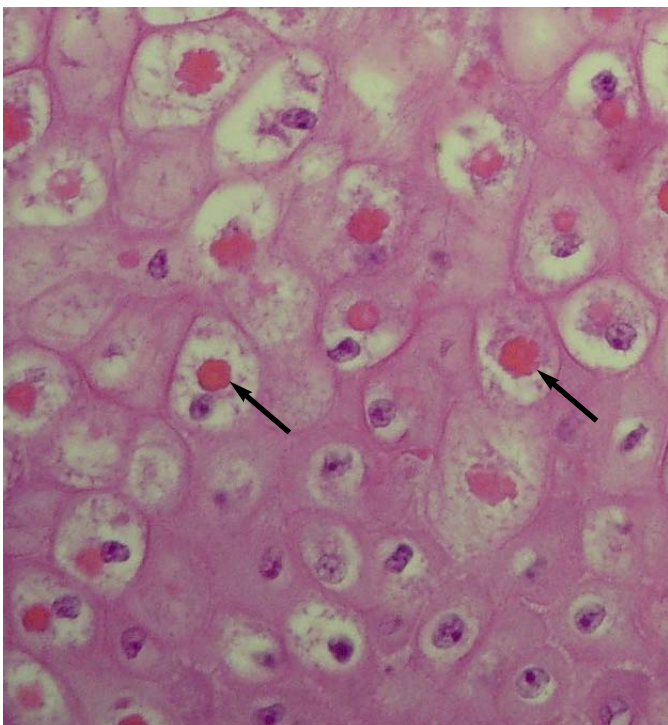


Fig.31.23: Microscopic lesion of the skin showing cytoplasmic inclusion bodies (arrows).

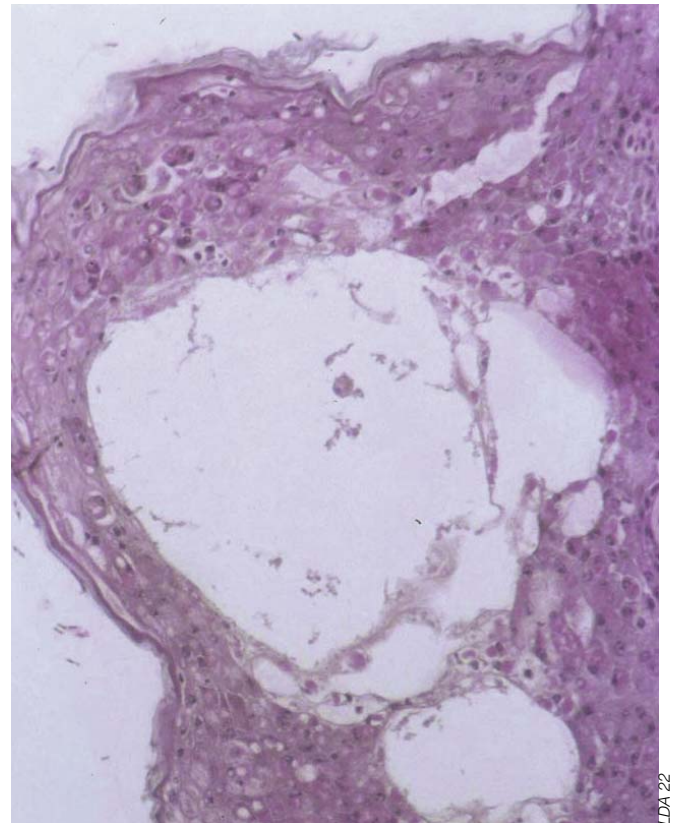


Fig.31.24: Microscopic lesion of the skin showing the formation of a vesicle on the eyelid of a canary.

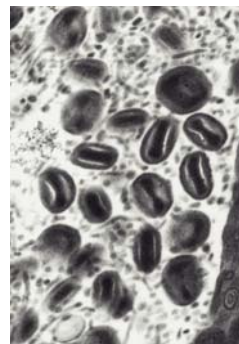

Fig.31.25: Ultrathin section of diphtheritic lesion showing fowlpox virus particles.

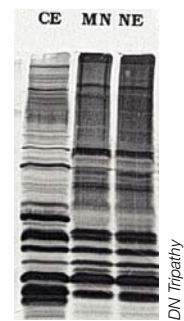


Fig.31.26: Antigenic differences among fowlpox virus strains by Immunoblotting.

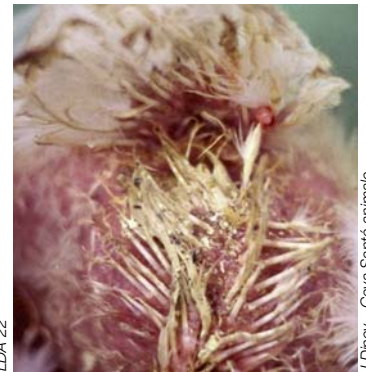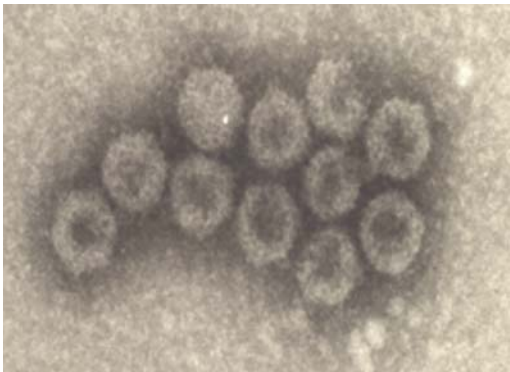


Fig.32.1: Infectious bursal disease virus is the etiologic agent of infectious bursal disease. The virus contains a double-stranded RNA genome and two major structural proteins, VP2 and VP3.

Fig.32.2: Clinical signs during the acute phase of IBD. Depression, prostration, anorexia, ruffled feathers and reluctance to move.

Fig.32.3: IBD. The feathers around the vent are usually stained with feces containing plenty of urates.

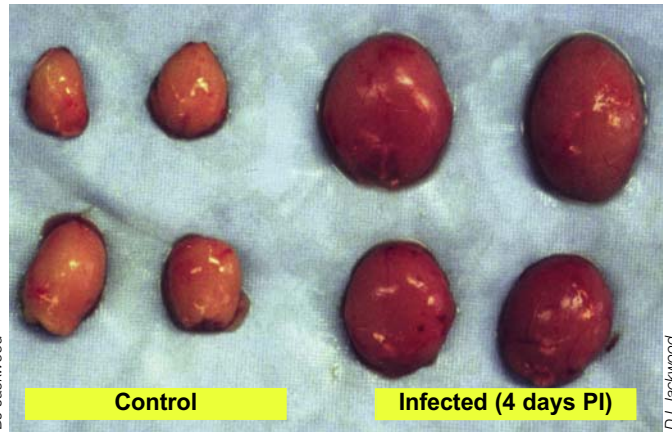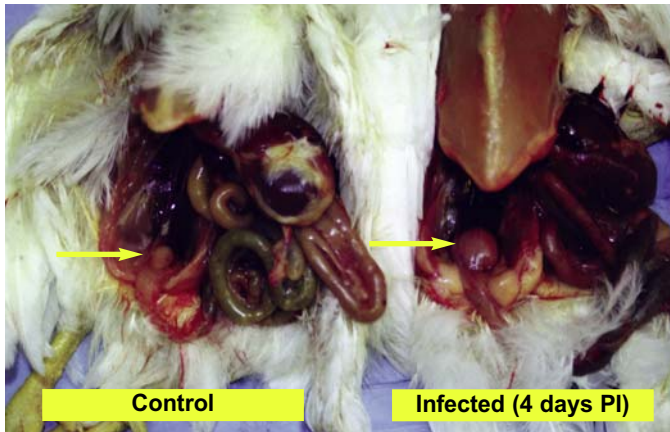


Fig.32.4 & 32.5: IBD. Bursa from chickens infected with a variant strain of IBDV at four days post-exposure compared to bursa from un-infected control chickens.

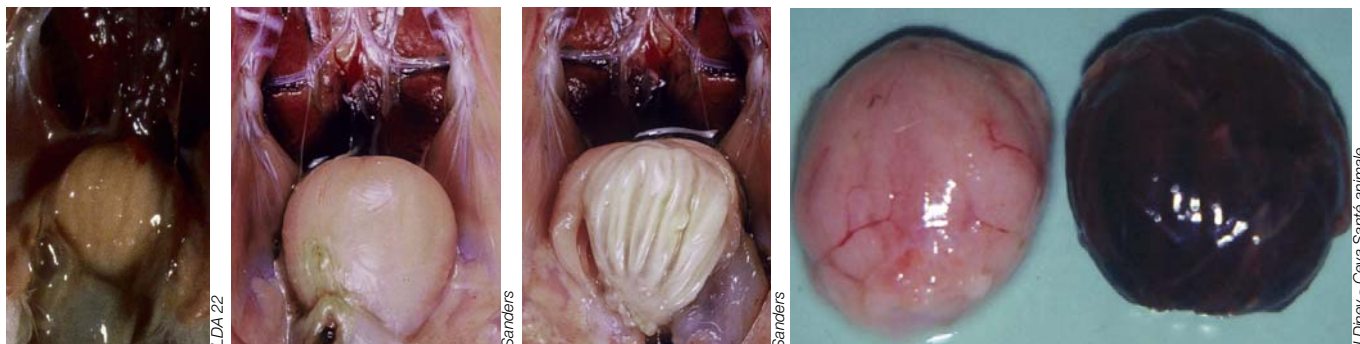


Fig.32.6, 32.7, 32.8 & 32.9: IBD. In the beginning of the infection, the bursa is enlarged, edematous and covered with a gelatinous transudate. Bursa lesions undergo various stages of serohemorrhagic to severe hemorrhagic inflammation.

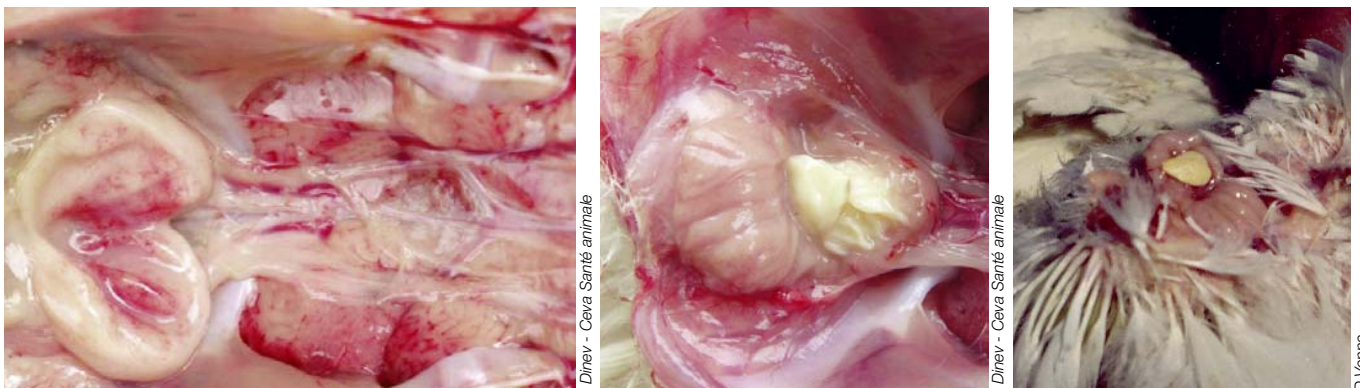


Fig.32.10, 32.11 & 32.12: IBD. Opening of the bursa confirms an edema with petechial hemorrhages (Fig.32.10). In some cases the bursa is filled with coagulated fibrinous exudate that usually forms casts with the shape of mucosal folds (Fig.32.11 & Fig.32.12).

Viral diseases

32. INFECTIOUS BURSAL DISEASE

INTRODUCTION

Infectious bursal disease virus (IBDV) causes an immunosuppressive disease in young chickens. The virus replicates in the bursa of Fabricius and destroys B lymphocytes. The virus also causes a significant reduction in the functions of T-cells. Many studies have demonstrated that IBDV induced immunosuppression exacerbates or is the underlying cause of other poultry diseases.

Infectious bursal disease (IBD), or Gumboro disease, has been observed in chickens since 1957. Birds that survive the disease are permanently immunosuppressed. Therefore, they are more susceptible to other disease causing agents and do not respond adequately to vaccinations which are essential to today's intensive poultry management programs.

The bursa of Fabricius (BF) is the primary target organ of IBDV. The virus replicates in the immature bursa-derived lymphocytes (B lymphocytes) of chickens. The humoral (antibody) immune response of susceptible chickens infected with IBDV at a young age is significantly compromised. The cellular immune response is also compromised during an IBDV infection.

Infectious bursal disease has only been documented in chickens albeit other avian species can become infected. The disease in chickens takes several forms and can range from a sub-clinical form with immune suppression but little or no disease signs to a very virulent form characterized by high morbidity and mortality.

ETIOLOGY

Infectious bursal disease is caused by a virus designated IBDV that belongs to the *Avibirnavirus* genus. Serotypes 1 and 2 of the virus are recognized however only serotype 1 viruses are known to cause disease in chickens. Within serotype 1, several antigenic subtypes of the virus have been identified. These antigenic subtypes of serotype 1 have been generally designated classic and variant. The classic virus types were isolated and characterized prior to the year 1980. Since that time, IBDV strains that were determined to be antigenically different from these classic viruses were characterized and designated antigenic variants. A third

group of viruses was identified based on their pathogenicity. This group was designated very virulent (vvIBDV) because they can cause very high mortality in susceptible chicken flocks.

Studies using monoclonal antibodies and molecular sequence analysis have demonstrated that within the classic group of IBDV, different antigenic types exist. Likewise, viruses placed in the variant group were not identical in their sequences or antigenic composition. Epidemiologic studies indicate that a considerable amount of molecular diversity exists among IBDV strains. This molecular diversity suggests that these viruses may also be antigenically diverse but this has not been conclusively demonstrated. It appears that if the amount of molecular and resulting antigenic diversity is minor, the chicken's immune system will mount a cross-reacting immune response to different IBDV strains. This has led to the general classification of classic and variant antigenic groups. The vvIBDV strains are thought to fit into the classic virus group, but recent studies demonstrated they too may be an antigenically diverse group.

CLINICAL SIGNS & LESIONS

Several pathogenic types of IBDV have been reported. Historically, the virus caused a clinical disease characterized by high morbidity and low mortality. The birds would appear depressed and could have ruffled feathers and mild diarrhea. Gross lesions include large edematous bursa (often yellowish in color) and small hemorrhages in skeletal muscles. Histological lesions in the bursa include severe lymphocyte depletion accompanied by inflammation. Some birds may present an atrophy of the bursa, lesion usually seen 8 days after the infection.

Sometimes, infections of IBDV result in a subclinical disease that can go undetected except for the resulting immunosuppression. Gross lesions in these subclinical cases are restricted to small atrophied bursa. Histologically, the bursa is devoid of lymphocytes.

Another pathogenic type of IBDV that has been observed is characterized by high morbidity and mortality. Viruses responsible for these outbreaks are designated vvIBDV. In some cases, mortality greater than 50% of the flock has been observed.

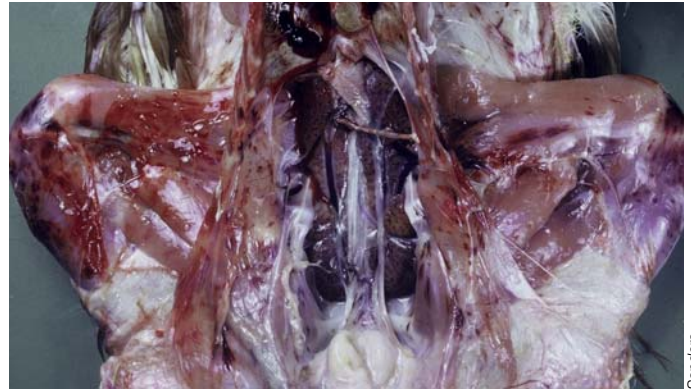
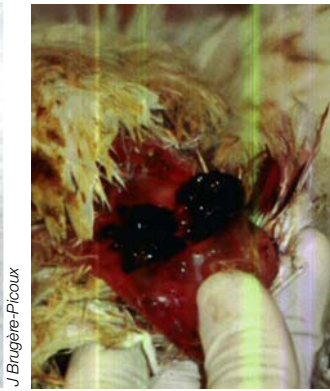
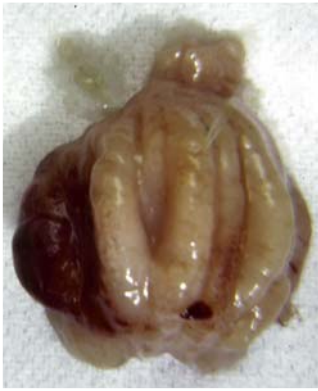
Fig.32.13 & 32.14: IBD. Hemorrhages of bursa (Fig.32.13). In some cases, the bursa is filled with blood clot (Fig.32.14). In this case, bird may excrete blood in their droppings.

Fig.32.15: IBD. The dead birds are dehydrated, often with hemorrhages in the pectoral, thigh and abdominal muscles.

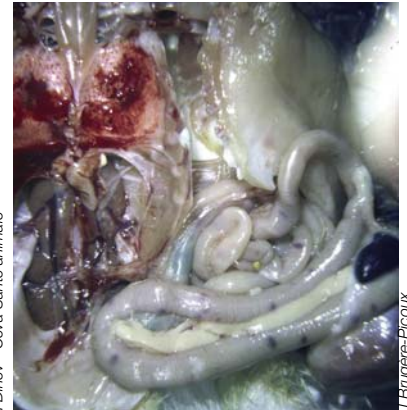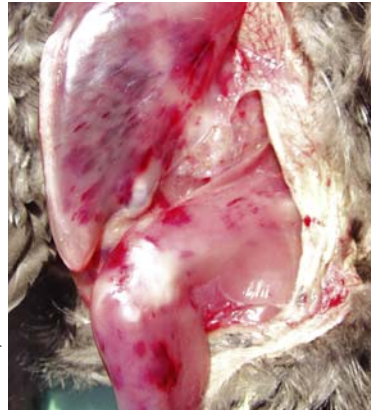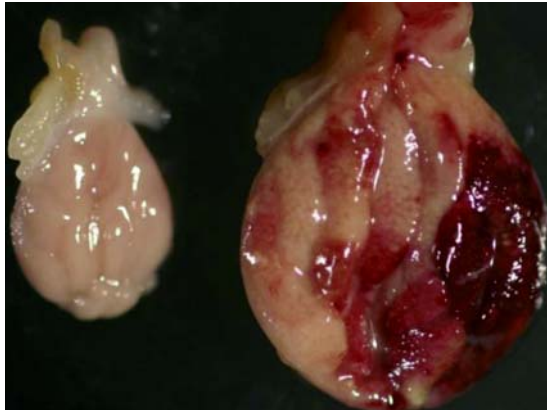


Fig.32.16, 32.17 & 32.18: Gumboro disease. Petechial and echymotic hemorrhages are seen in bursa (Fig.32.16), thigh and pectoral muscles (Fig.32.17), and sometimes at the junction of the proventriculus and gizzard or in the intestine, particularly in the duodenum of Fig.32.18 (Note also the nephritis). Hemorrhages are not a consistent lesion.

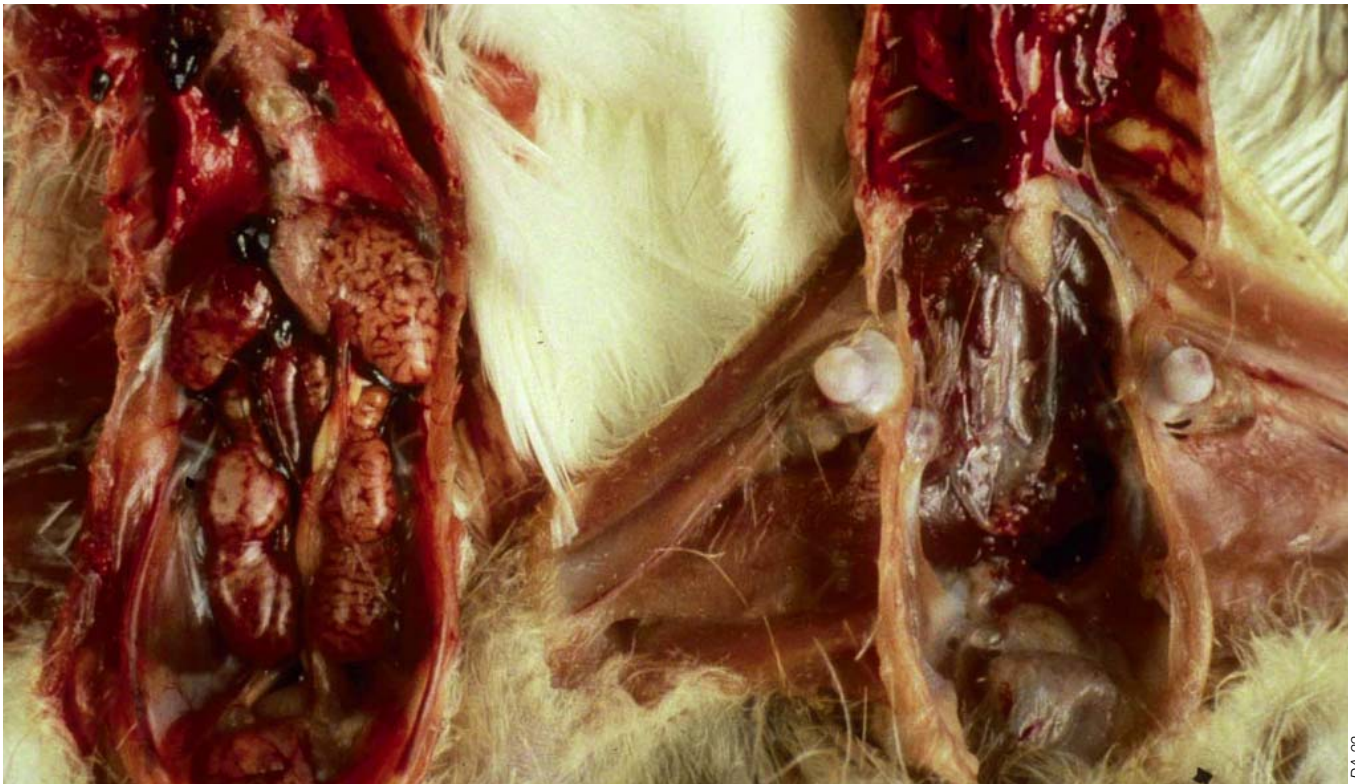


Fig.32.19: IBD. In some birds the kidneys appear swollen and may contain urate deposits and cell debris that can be due to dehydration and/or the result of the blockage of the ureters by a severely swollen bursa (normal kidneys on the right).

Gross lesions include enlarged bursa (often with hemorrhages) and hemorrhages in muscle and organ tissues.

DIAGNOSIS

Detection of IBDV in chickens or the environment is very important because antigenic diversity among wild-type strains can confound vaccination control efforts. The identification of new antigenic types of the virus has been examined using sentinel birds with immunity to known antigenic types of the virus. Viruses that replicate in these sentinel birds must then be identified. Traditional methods for the identification of IBDV include the agar-gel precipitin assay and virus isolation in embryonated eggs or cell culture. Although still widely used, the sensitivity of the agar-gel precipitin assay is poor and virus isolation is expensive and time consuming. Furthermore, some wild-type viruses have been very difficult to isolate and grow in cell culture. Isolation of viruses in embryonated eggs has a greater likelihood of success.

Monoclonal antibody based assays have been used to identify IBDV and provide information on their antigenic composition. The antigen-capture enzyme-linked immunosorbent assay (AC-ELISA) is inexpensive and very accurate. Monoclonal antibodies are used in this assay to determine the relatedness of wild-type strains to known antigenic types of the virus. Viruses that react with the same panel of monoclonal antibodies are considered to be antigenically related and should be cross-protective in a vaccination/challenge study.

Molecular diagnosis of IBDV has gained popularity because it is more sensitive than any other diagnostic test for this virus. The reverse transcriptase/polymerase chain reaction (RT/PCR) has been used to identify IBDV by detecting the presence of the viral genome. Various assays on these RT/PCR products are then used to differentiate viruses. One of these assays is the restriction fragment length polymorphism (RFLP) assay.

Molecular assays for IBDV have provided valuable diagnostic and epidemiologic information. These assays have been used to detect all antigenic and pathogenic types of IBDV. They can be used to differentiate viruses into molecular groups, detect multiple IBDV strains in a single sample, identify vaccine strains from wild-type viruses, and identify vvIBDV. Because of the versatility of these molecular assays, their results will vary depending on the region of the viral genome being examined. Thus, caution in choosing and comparing the

results of molecular diagnostic assays is recommended.

The ELISA can be used to detect IBDV-specific antibodies. Several commercially available assays exist and are used to determine the immune status of a flock. These assays can be used to follow the decline in maternal antibodies during the first several weeks of life or to identify that a disease outbreak has occurred. The efficacy of vaccination programs can also be monitored using the ELISA. Because of the antigenic diversity among IBDV strains, the performance of commercially available ELISA kits can vary from one region to the next. As a result, new antigenic compositions have been incorporated into some ELISA kits. The performance of these kits will also vary depending on the antigenic type of IBDV present in the environment, so when choosing an ELISA kit make sure it will adequately reflect the immune status of the flock.

TREATMENT & CONTROL

Infection with IBDV is very common in all chicken rearing regions of the world. The virus is highly resistant to environmental conditions and thus, its persistence in the environment can serve as a continual challenge to chicken flocks. Antibodies produced as a result of an IBDV vaccination or infection will protect birds from the disease. Thus, control of this immunosuppressive disease is achieved by vaccination with live-attenuated and/or inactivated viruses. Because the immunosuppressive effects of an IBDV infection are most pronounced in birds infected at a young age, maternal antibodies transferred *via* the yolk are used to protect chicks during the first several weeks of life.

Vaccination of broilers has varied from no vaccination to vaccination one or more times during the life of the bird. Maternal antibodies in broilers will decline appreciably by the end of the second week of life. At that point, broilers become susceptible to field strains of the virus unless some vaccination program is instituted. The rationale for not vaccinating broilers is that maternal antibodies are sufficient for protection of the very young chickens and while the quantity of maternal antibodies is declining, the birds are challenged with field viruses leading to development of active immunity. Vaccination may be warranted when this balance is offset by high quantities of pathogenic virus in the environment or wild-type viruses that are antigenically different from the vaccine viruses being used in the breeder flock.

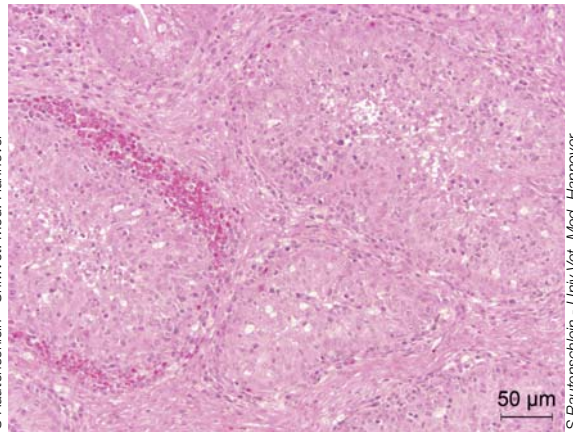
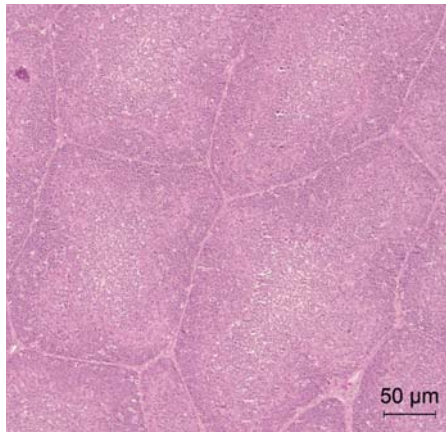
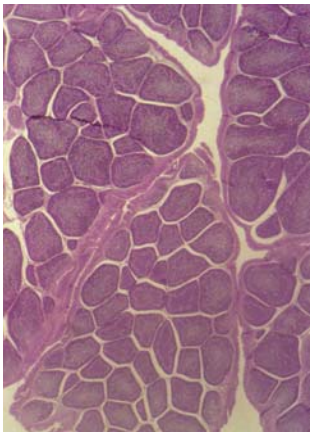


Fig.32.20 & 32.21: Histology of bursa of non-infected chickens at different magnifications. Histological lesions in the bursa will vary with the time of death: very few bursa lesions in birds that die acutely or severe lymphocyte depletion with significant inflammation in convalescent birds or those that experience a longer disease course.

Fig.32.22: IBD. Histology of bursa of infected chicken. Infected follicle with heterophil infiltration. Compare with normal follicles of Fig.32.21 with the same magnification.

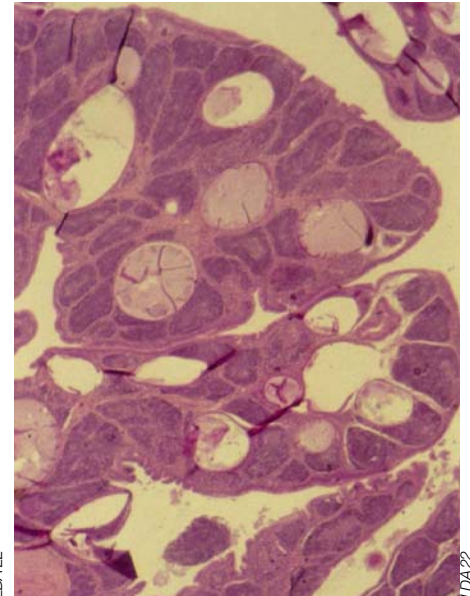
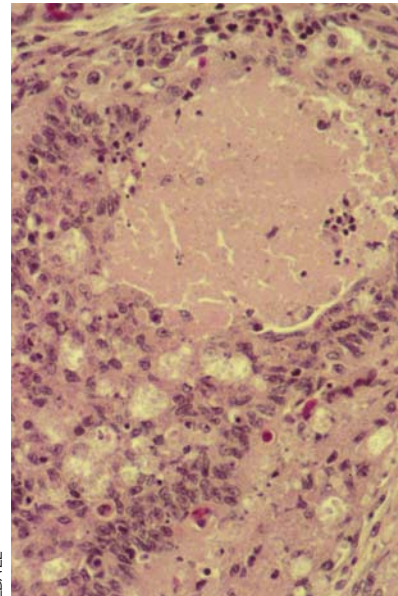
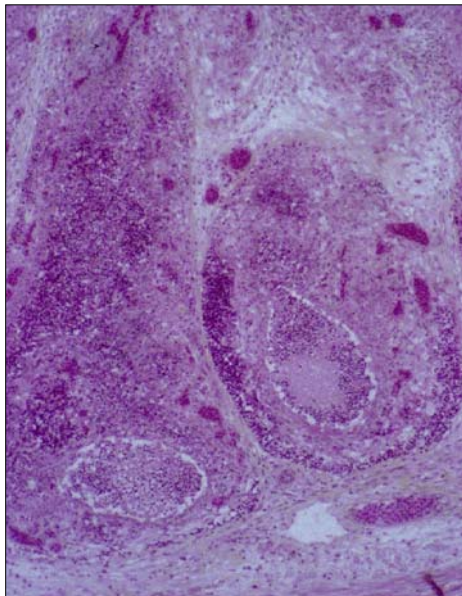


Fig.32.23: IBD. Extensive necrosis of bursal follicular lymphoid cells, inflammation of follicles, edema and heterophils in the connective tissue are typical lesions of the classical form of infectious bursal disease.

Fig.32.24 & 32.25: IBD. Massive destruction of lymphoid cells in the bursal follicles (Fig.32.24). This massive destruction of lymphoid cells in the bursal follicles lead to cysts formation within the follicles (Fig.32.25). The cysts are also characteristic of age-associated regression.

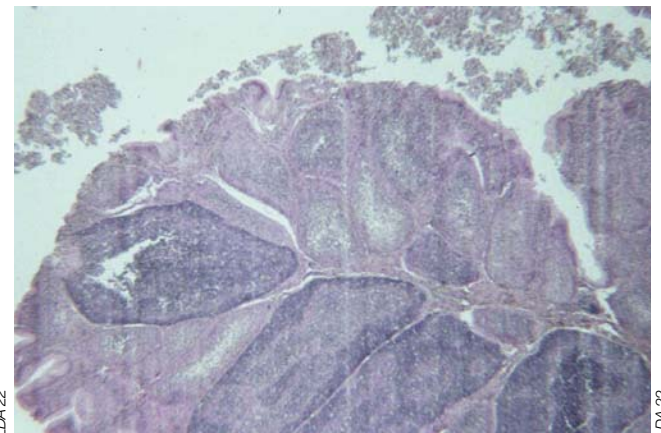
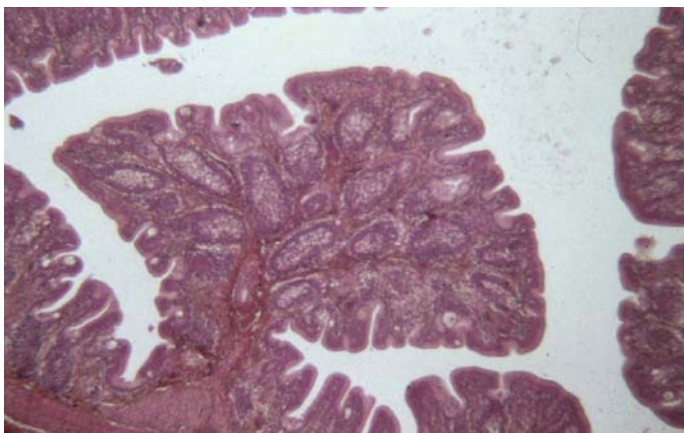


Fig.32.26: IBD. Variation in the size of bursal follicles and irregular folding of the epithelium surface of the plicae are features of atrophy. These changes also are characteristic of age-associated regression.

Fig.32.27: IBD. Bursal regeneration following injury with peripheral repopulation of follicles with lymphocytes.

The virulence of live-attenuated IBDV vaccines varies. Mild vaccines do not cause appreciable damage to the bursa but their immunogenicity is weak compared to intermediate and hot vaccines. Intermediate and hot refer to higher degrees of virulence and although these viruses are good immunogens, they can cause bursa damage and immunosuppression. The hot vaccines have been used primarily to control vvIBDV infections and intermediate vaccines seem to work better than mildly virulent vaccines when maternal antibodies are present.

Selection of the appropriate antigenic subtype for vaccination of a chicken flock or breeder flock (induction of maternal antibodies) must be based on the antigenic subtypes of IBDV present in the environment of the birds. This has been a difficult task because the antigenic diversity of this double-stranded RNA virus appears to be extensive.

Vaccination programs often fail when the antigenic composition of the wild-type IBDV strains circulating in the environment is different from the vaccine(s) being used in the breeder flocks. Thus, diagnosis of the wild-type viruses is extremely important to a successful control program for IBD.

REFERENCES

Boot HJ et al. Rescue of very virulent and mosaic infectious bursal disease virus from cloned cDNA: VP2 is not the sole determinant of the very virulent type. *J Virol*, 2000,74:6701-6711.

Cosgrove AS. An apparently new disease of chickens avian nephrosis. *Avian Dis*, 1962,6:385-389.

Jackwood DJ et al. Studies on naturally occurring infectious bursal disease viruses suggest that a single amino acid substitution at position 253 in VP2 increases pathogenicity. *Viol.*, 2008, 377:110-115

Jackwood DJ & Sommer SE. Genetic heterogeneity in the VP2 gene of infectious bursal disease viruses detected in commercially reared chickens. *Avian Dis*, 1998,42:321-339.

Le Nouen C et al. Very virulent infectious bursal disease virus: reduced pathogenicity in a rare natural segment-B-reassorted isolate. *J Gen Virol*, 2006,87:209-216.

Letzel T et al. Molecular and structural bases for the antigenicity of VP2 of infectious bursal disease virus. *J. Virol*, 2007,81:12823-12835.

van Loon A et al. Alteration of amino acids in VP2 of very virulent infectious bursal disease virus results in tissue culture adaptation and attenuation in chickens. *J Gen Virol*, 2002,83:121-129.

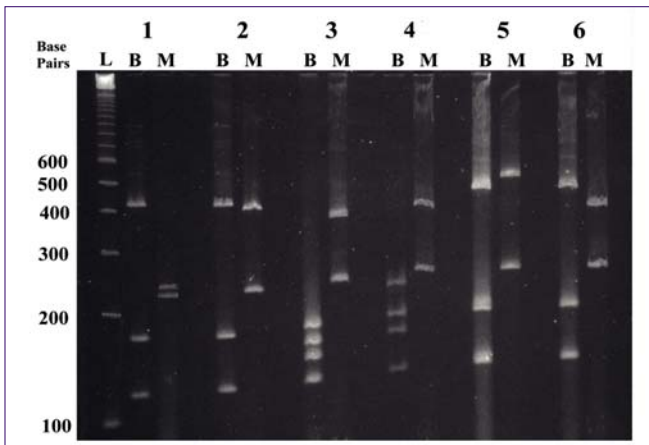


Fig.32.28: The RT/PCR-RFLP assay has been used to place vaccine strains of IBDV into six molecular groups. Each group is designated 1- 6, is distinguished by its molecular banding pattern following digestion with *BstNI* (B) and *MboI* (M) enzymes. Molecular size markers (L) are shown for comparison.

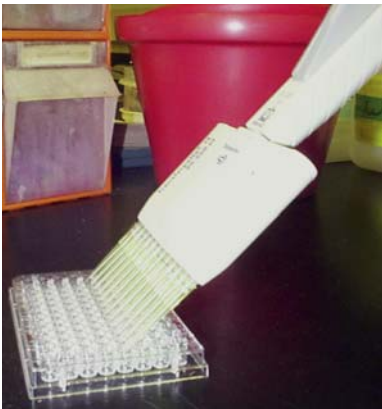

Fig.32.29: The AC-ELISA can be used with monoclonal antibodies to identify antigenic strains of IBDV. A limitation of this test is that antigenic drift has resulted in no binding of the monoclonal antibodies in a panel. New monoclonal antibodies for these strains are necessary.



Fig.32.30 & 32.31: Inoculation of embryonated chicken eggs is used for the isolation and propagation of IBDV field strains. Chicken embryos at 9 days of incubation were infected via the chorioallantoic membrane using a variant strain of IBDV. Seven days following inoculation, the embryos were observed for lesions.

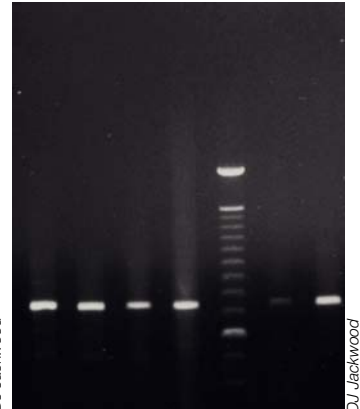
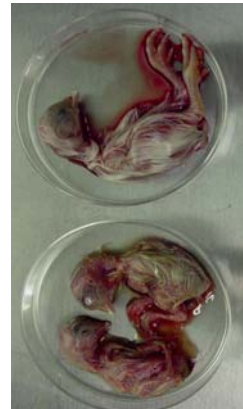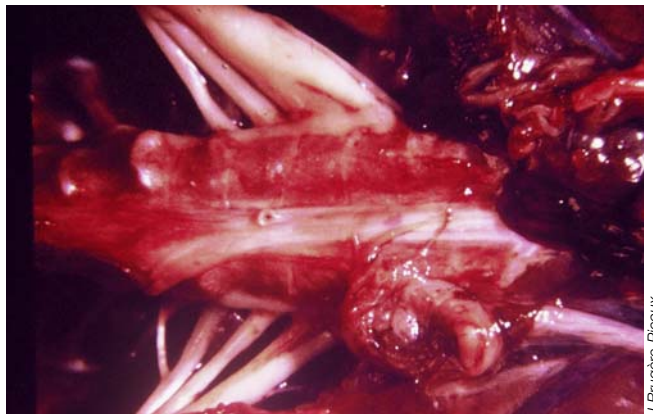


Fig.32.32: Molecular diagnosis of IBDV using RT-PCR yields products that can be visualized using agar gel electrophoresis.



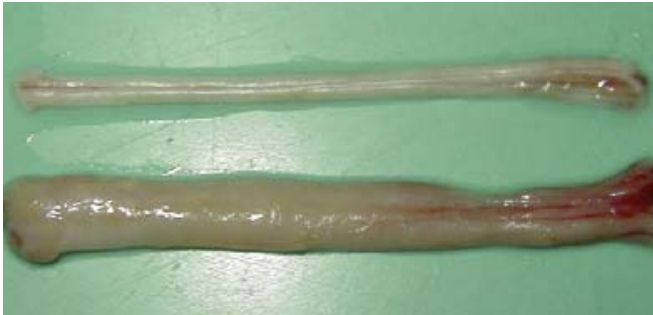I Dinev - Ceva Santé animale

Fig.33.1: Marek's disease (MD). Paralysis. Posture characteristic of fowl paralysis, one wing and one leg paralyzed.



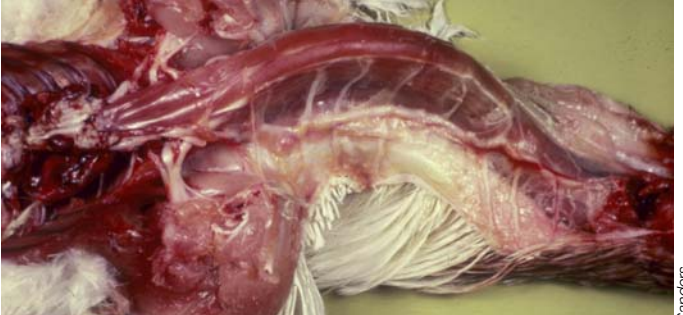J Brugère-Picoux

Fig.33.2: MD. Assymmetric sciatic nerve plexus enlargement, enlarged sciatic nerve plexus (at top) compared to normal (at bottom).



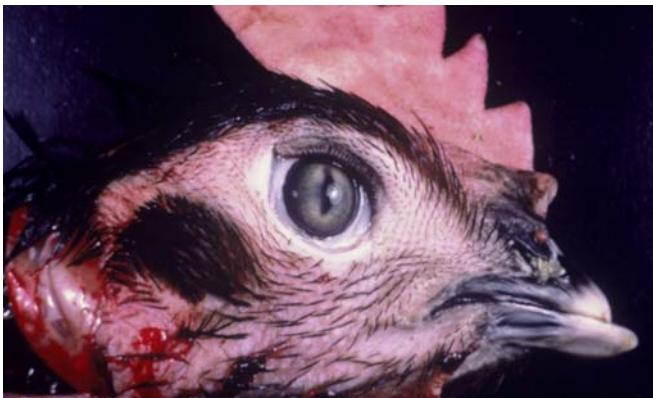I Dinev - Ceva Santé animale

Fig.33.3: MD. This enlargement is seen also in the sciatic nerve. Compare with the normal nerve (on top).



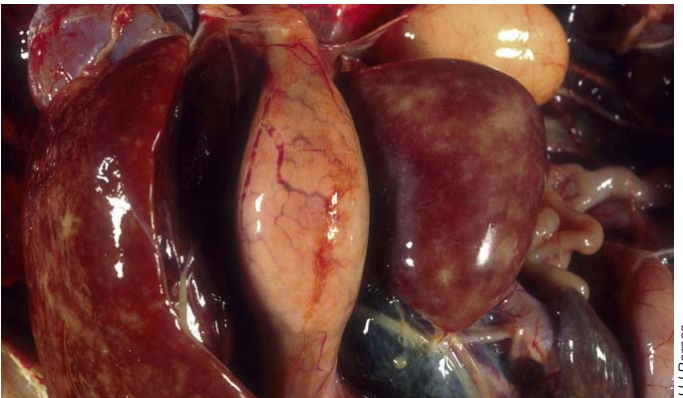
Sanders

Fig.33.4: MD. Enlargement of the pneumogastric nerve.



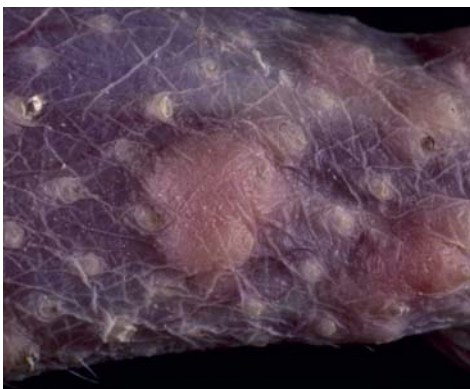
Sanders

Fig.33.5: MD. Lymphoid cell infiltration of iris, note irregular grey iris.

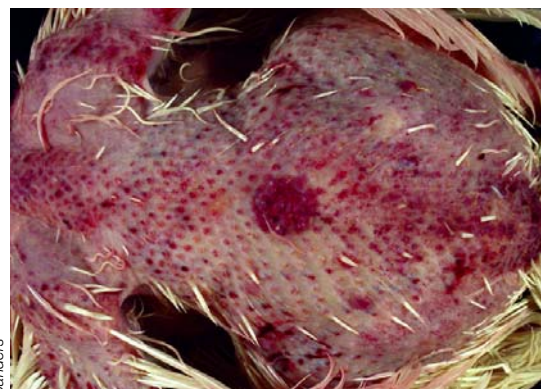


HJ Barnes

Fig.33.6: MD. Tumors in the spleen and liver (normal spleen is 1/3 size of proventriculus).

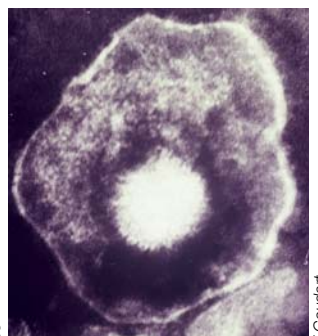


Sanders



HJ Barnes

Fig.33.7 & 33.8: MD. "Skin leukosis" involving skin follicles. Nodular lesions may involve a few scattered follicles or they may coalesce, often there is reddening of the skin.



F Couderc

Fig.33.9: The cell-free MDV (enveloped form) released from the feather follicle epithelium is relatively resistant to environmental factors and is fully infectious.

Viral diseases

33. MAREK'S DISEASE

INTRODUCTION

Marek's disease virus (MDV) is a herpesvirus (*Gallid herpesvirus 2* or GaHV-2, genus *Mardivirus*) that causes tumors and immunosuppression in chickens. Turkeys, pheasants and quail can also be affected. The disease is characterized by infiltration of various nerve trunks and/or organs with pleomorphic lymphoid cells. The introduction of vaccination against Marek's disease (MD) in the 1970s resulted in the first effective and widespread use of a vaccine to prevent a virus-induced cancer in any species.

Prior to the 1960s, MD infection usually resulted in unilateral wing or leg paralysis, referred to as fowl paralysis. However the intensification of poultry production, with reduction of genetic diversity in commercially produced poultry and changes in their environment, may have favored the development of new virus strains with increased virulence. The initial MDV vaccines, mainly serotype 3 herpesvirus of turkeys or HVT (*Meleagrid herpesvirus 1* or MeHV-1) decreased losses. In the late 1970s MDV isolates with increased virulence were isolated. These isolates were able to break the protection induced by the first generation of HVT vaccines, especially those that were used as cell-free vaccine. In Europe a serotype 1 vaccine, CVI988, was introduced and when used in combination with HVT, this vaccine is effective in field situations. In the USA a serotype 2 SB-1 vaccine was introduced in the 1970s and when used in combination with HVT, this vaccine was successful at controlling losses. However, new more virulent strains of the virus continued to be isolated in the USA. In the 1990s CVI988 vaccine was introduced in the USA and when used in combination with HVT, this vaccine has been effective.

Today poultry are vaccinated against MDV in almost all commercial operations throughout the world. Current MDV vaccines control field problems and reduce but do not prevent infection or shedding. Thus there is a continuous virus reservoir in vaccinated flocks, allowing for selection and adaptation of new MDV strains. The most virulent strains (very virulent plus) produce an acute early cytolytic infection with high early mortality and severe atrophy of the thymus and bursa of Fabricius in chickens. Recently there have also been documented field outbreaks of MD in commercial turkeys in France, Germany, Israel and the UK. The estimated worldwide economic impact of the disease is 1-2 billion US\$ per year.

ETIOLOGY

MDV are cell-associated viruses, belonging to the family *Herpesviridae*, the subfamily *Alphaherpesviridae* subgroup *Mardivirus*. These viruses are closely related antigenically, and are further classified into three serotypes. Serotype 1 (MDV1) viruses are oncogenic and the etiological agents of MD. Serotype 2 isolates are common in chickens and are nononcogenic. The serotype 3 isolates are thought to be ubiquitous in turkeys and are non-oncogenic. All three serotypes are antigenically cross-reactive.

Serotype 1 strains can be divided into four groups based on their apparent virulence and ability of different vaccines preparations to prevent tumors in susceptible chickens. Mildly virulent strains (mMDV) cause only minimal lesions in susceptible strains of chickens. Virulent strains (vMDV) cause more severe lesions, but are effectively protected against by monovalent vaccines such as HVT. Very virulent strains (vvMDV) cause even more significant pathology, and are protected against by bivalent vaccines, such as HVT/SB-1. Finally, very virulent plus strains (vv+MDV) cause the greatest pathological effects. Vaccination with HVT/CVI988 provides improved protection against vv+MDV strains.

MDV is usually propagated and assayed in tissue culture, embryonated eggs or young chicks. Cultured chicken kidney cells or duck embryo fibroblasts prepared from 1-2 week-old chicks are best for isolation and propagation of new strains. Infected cultures develop discrete focal lesions, consisting of clusters of rounded, refractile degenerating cells when mature. Virions are commonly seen within the nucleus, and occasionally the cytoplasm of infected cells. Hexagonal nucleocapsids (85-100 nm in diameter) and enveloped particles (150-160 nm in diameter) may be visualized in thin sections of infected cell cultures. The MDV virus replicates in living cells and in its cell-associated form, is very unstable. However, cell-free virus released from the feather follicle epithelium (FFE) is relatively resistant to environmental factors. Both cell-associated and cell-free viruses are susceptible to most common disinfectants.

EPIDEMIOLOGY

Many factors influence the incidence of MDV; these include age at exposure, genetic constitution, level of maternal antibodies, virulence of the virus strain, sex of the host and complicating factors such as infection with other immunosuppressive agents.

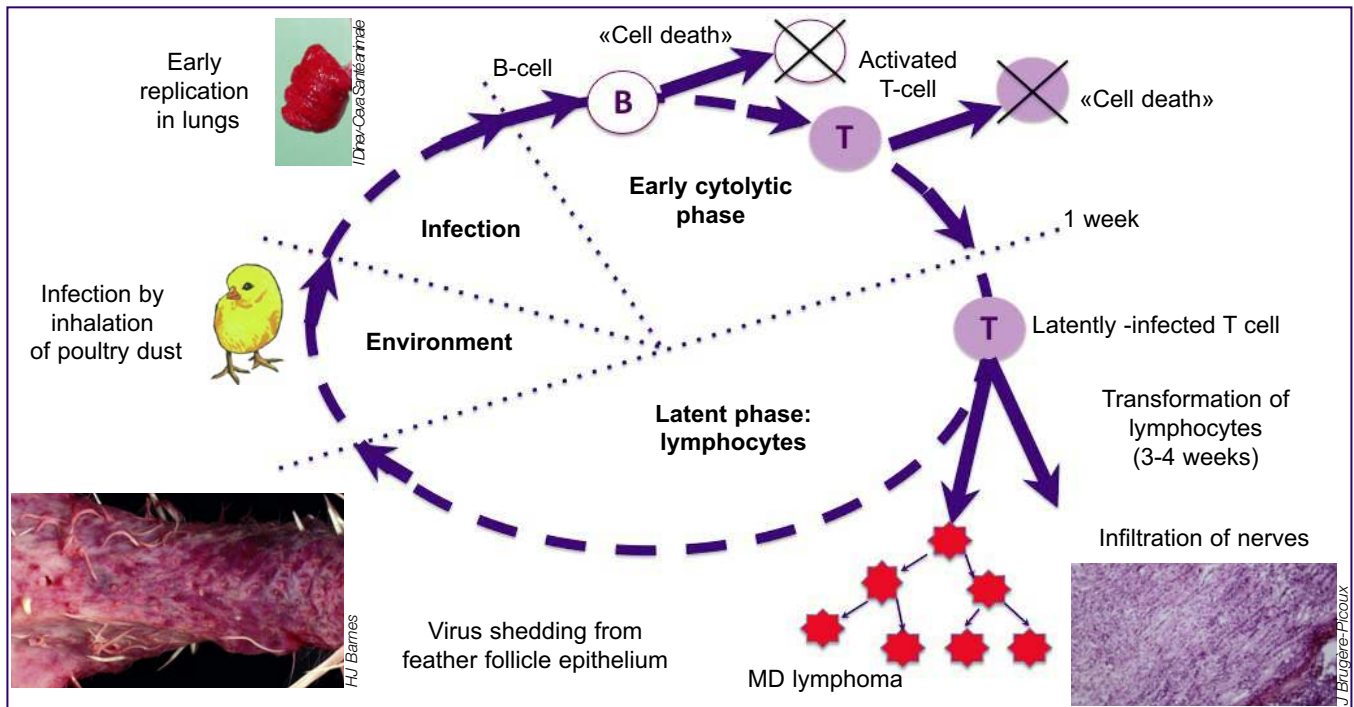


Fig.33.10: Schematic diagram showing the different stages of the pathogenesis of Marek's disease.

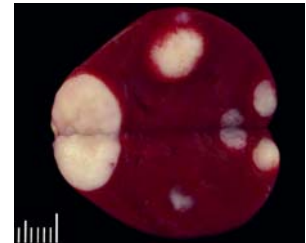
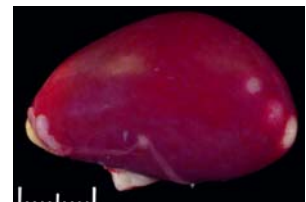
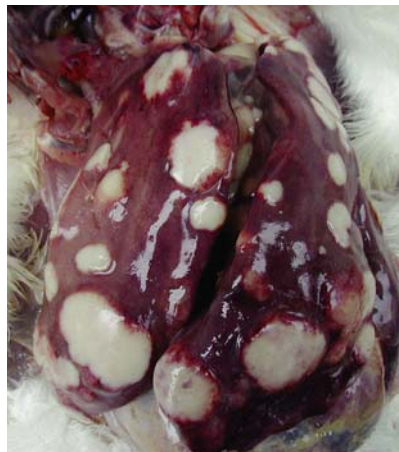
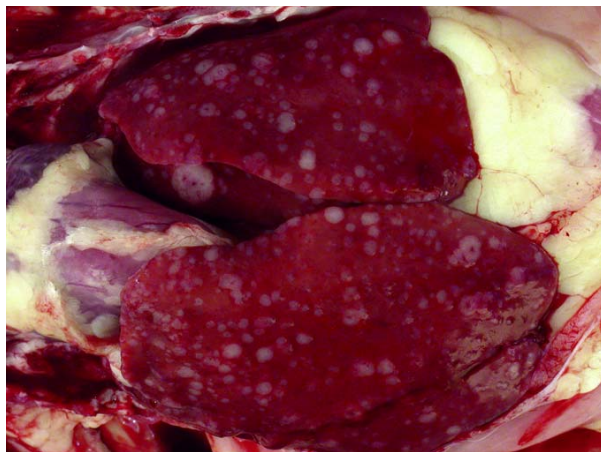
Fig.33.11 & 33.12: MD. Liver and heart tumors. The liver enlargement in adult bird can be very similar to that seen in lymphoid leukosis. Tumoral infiltration can be diffuse or nodular like in these two figures.

Fig.33.13 & 33.14: MD. Lymphomatous involvement of spleen (Chicken).

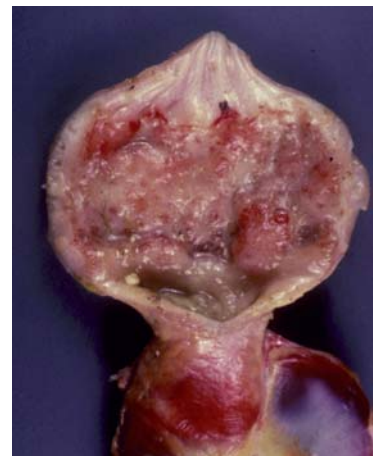
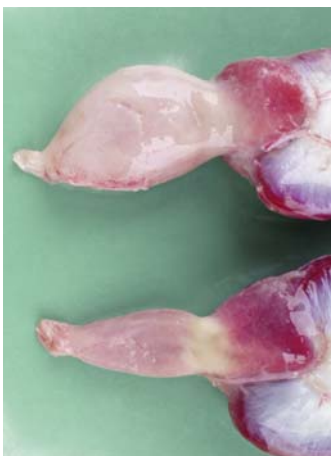
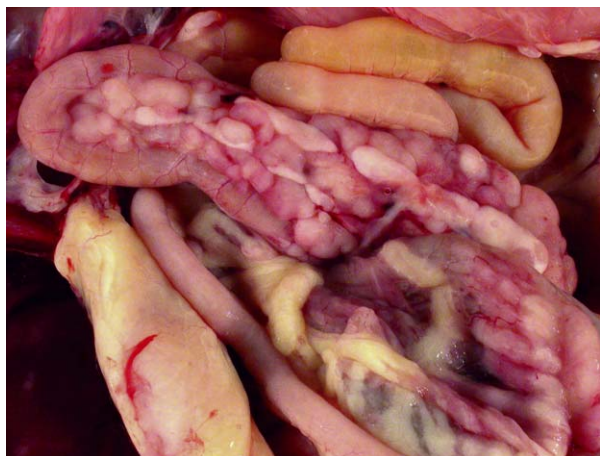
Fig.33.15: MD. Lymphomatous involvement of the pancreas (Chicken).

Fig.33.16 & 33.17: MD. Lymphomatous involvement of the proventriculus (Chicken). Normal proventriculus at the bottom of Fig.33.16.

Initial infection and spread within the host occur by direct cell-to-cell contact. The virus gains entry *via* the respiratory tract and then travels to the major lymphoid organs (spleen, thymus and bursa of Fabricius). The mechanism of transfer from the respiratory tract to the lymphoid organs is not well understood; however macrophages are thought to be involved. By three days post infection, a productive-restrictive infection can be detected in lymphoid organs. The term productive-restrictive is used because the infection is strictly cell-associated. The early cytolytic infection occurs mainly in B-cells *in vivo* and in most culture cells, where the virions produced are non-enveloped and thus non-infectious. Cytolytic infection stimulates an inflammatory host response, leading to activation of T-cells. In the primary lymphoid organs, productive-restrictive infection is characterized as an acute reticulitis with infiltration by macrophages and granulocytes. Hyperplasia of reticular cells may occur, resulting in splenic enlargement.

Following primary infection, herpesviruses typically switch to a latent form of infection and may be reactivated periodically throughout the life of the host. At about 5-7 days post infection with MDV, there is a switch to the type of infection seen in lymphocytes. While cytolytic infection involves mostly B-cells with a few T-cells, latent infection occurs predominantly in T-cells. These latently infected T-cells bear *Ia* antigen, indicating that they are activated T-cells. In the latent phase of MD, there is little evidence of virus-associated antigens or virus particles *in vivo*, yet the virus can be recovered *in vitro*. Expression of the viral genome is limited to a few transcripts transcribed from the repeat regions of the genome.

In susceptible chickens, a second wave of cytolytic infection may occur at two to three weeks post infection resulting in permanent immunosuppression. This productive-restrictive infection leads to intranuclear inclusion body formation, cell destruction and necrotic lesion formation in epithelial tissues including the kidney, proventriculus, and FFE. Lymphocytes may become cytolytically infected at these sites, as well as in the primary lymphoid organs. Fully productive infection, which occurs only in the FFE, results in the development of enveloped, fully infectious virions. The greatest concentration of virions in the FFE can be found in samples collected from chickens at three to five weeks post-inoculation.

Transforming infection occurs in CD4+T-lymphocytes of chickens and has been demonstrated only with virulent serotype 1 strains. Current research indicates that one or more MDV gene products may act in concert with cellular factors to induce

transformation. Analysis of MDV gene transcription in MDV-induced lymphoma tissues and MDV-transformed lymphoblastoid cells lines, demonstrates that viral gene transcription is limited to the repeats flanking the unique long and unique short sequences. Thus, much attention has been focused on identification and characterization of viral transcripts encoded within these regions. Viral candidates for involvement in transformation include *Meq*, *vIL-8*, *pp38* and two small open reading frames, *pp14* and *p7*.

Fully productive infection results in shedding of FFE containing virus; this is the source of infection for other poultry. Infected birds may or may not show signs of illness and may sporadically shed virus throughout their lifetime. Infectious dander can spread over long distances and is very contagious. Vertical transmission through the egg does not occur. Hatchery transmission through shell contamination is unlikely due to adverse environmental conditions.

CLINICAL SIGNS & LESIONS

Clinical signs of MD usually appear at about 3 weeks of age and peak between 2 and 7 months, however they are of little help in establishing a diagnosis. Multifocal lymphoid proliferation in a variety of tissues begins as early as 1 week post-infection, becoming progressively more pronounced and leading to fatal gross lymphomatosis. Birds with visceral tumors may appear depressed and are often cachectic prior to death.

Cellular infiltration of peripheral nerves, leading to gross enlargement, loss of striation and paralysis is a characteristic of classical MD. Birds with lymphoid infiltration of the peripheral nerves may demonstrate asymmetric partial paralysis and/or dilation of the crop due to vagal paralysis. MDV can also infect the brain leading to transient paralysis or persistent neurological disease. Blindness is associated with lymphoid infiltration the iris. Skin leukosis is usually associated with the feather follicles. Nodular lesions may involve a few scattered follicles or they may coalesce, often there is reddening of the skin. Visceral tumors are the most frequent lesions, however combinations of lesion patterns are common. Tumors are common in the liver, spleen, gonad, kidney, heart and proventriculus.

Microscopically, MD lymphomas are characterized by a mixture of pleomorphic lymphocytes. Some of these cells are probably true tumor cells that carry T-cell surface antigens and a Marek's tumor-associated antigen; others are probably host T- and B-cells reacting against viral or tumor antigens.

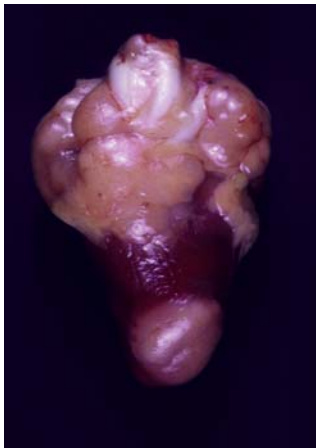


Fig.33.18: MD. Lymphomatous involvement of the heart (Chicken).

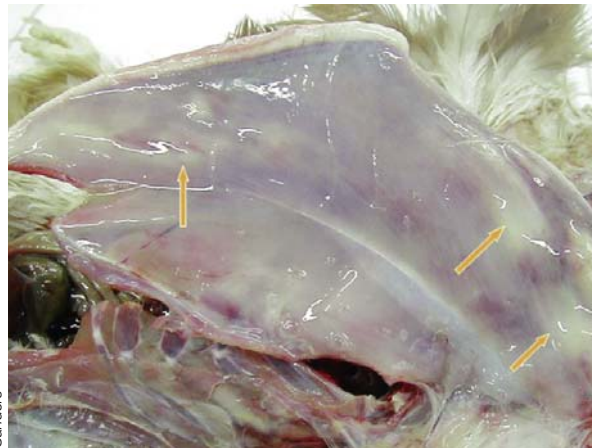

Fig.33.19: MD. Multicentric MD tumours (arrows) protruding or seen through the superficial and deep pectoral muscles (Chicken).

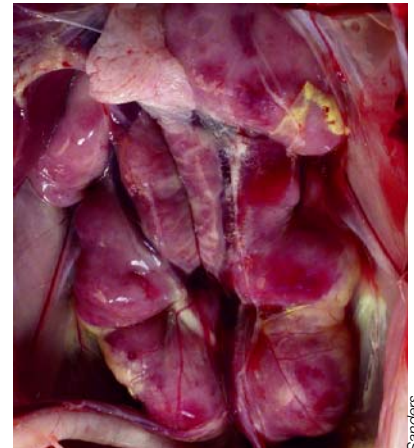


Fig.33.20: MD. Lymphomatous involvement of the kidneys (Chicken).

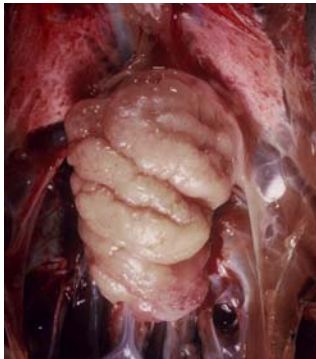


Fig.33.21: Typical cauliflower-like appearance of the ovary, distinctive for MD (Chicken).

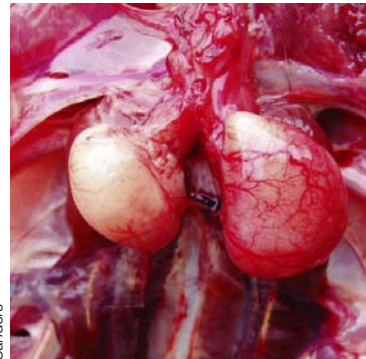


Fig.33.22: MD. Marked asymmetry of testes in a cock following unilateral lymphoid cell proliferation.

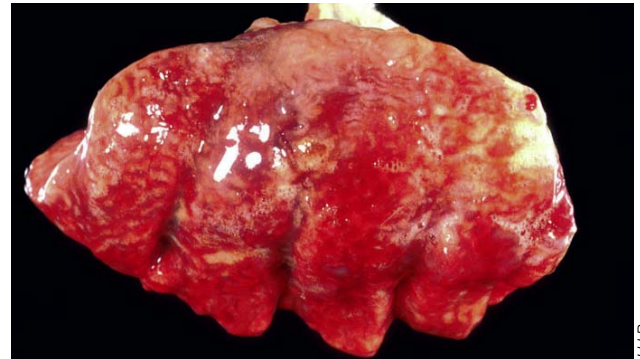


Fig.33.23: MD. Lymphomatous involvement of the lung (Turkey).

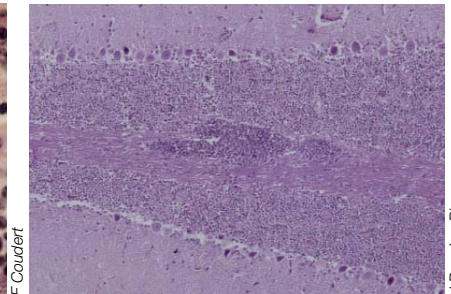
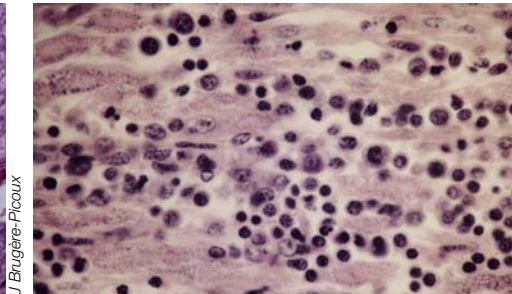
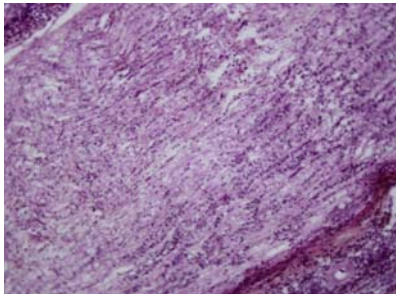


Fig.33.24 & 33.25: Microscopical lesions of MD in peripheral nerves. On the left, type A lesions of brachial nerve characterized by marked cellular infiltration numerous proliferating lymphoblastic cells and no edema. On the right, pleomorphic lymphocytes in an enlarged nerve.

Fig.33.26: MD. Extensive infiltration of lymphocytes around blood vessels in the neuropil of the cerebellum.

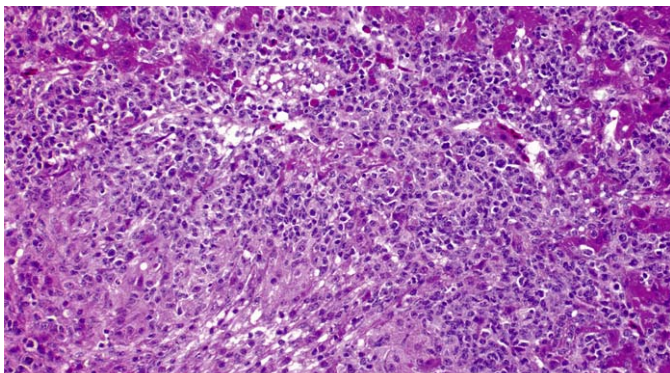


Fig.33.27: MD. Pleomorphic lymphocytes in a liver lymphoma (Turkey).

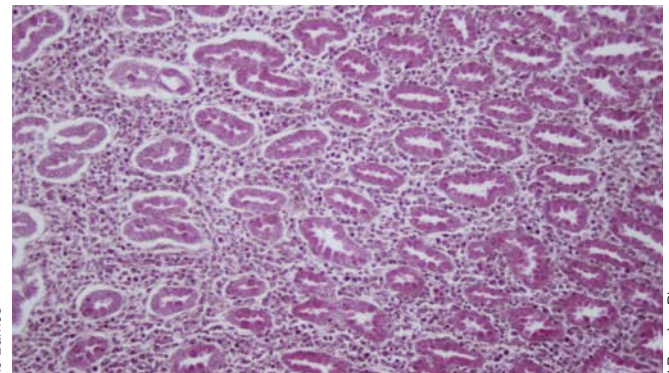


Fig.33.28: MD. Pleomorphic lymphocytes in a proventriculus lymphoma (Chicken).

DIAGNOSIS

Marek's disease is characterized by a mononuclear infiltration of peripheral nerves, gonads, various viscera, iris, muscle and/or skin. Although enlarged peripheral nerves and visceral lymphomas are common in MD, neither lesion occurs consistently. Criteria such as age (4-20 weeks, except in breeders where MDV tumors increase at the beginning of lay), lesion distribution, and absence of other tumor causing viruses such as avian leukosis virus (ALV) and reticuloendotheliosis virus (REV) should also be considered.

Histologic examination can enhance the accuracy of diagnosis between ALV and MDV. MD tumors have a mixed population of small to large lymphocytes. Lymphoblasts and plasma cells may be observed. Lymphoid tumors caused by ALV are typically made up of lymphoblasts of similar size containing prominent nucleoli, usually occur in chickens older than 20 weeks, and commonly occur in the bursa of Fabricius. The tumors caused by MDV and REV may appear similar on both gross and histologic analysis. Thus diagnosis of the etiology of chronic neoplasia in the chicken, in which bursal tumors are lacking and the latent period is too short for ALV, should be made on the basis of virologic or serologic tests. Clinical disease is much more common with MDV than with REV, and REV is not considered to be a major economic problem by the poultry industry.

Virus can initially be isolated one or two days following inoculation of chickens with MDV, five days after contact exposure and thereafter throughout the life of the bird. Virus may be obtained from infected samples of heparinized whole blood, suspensions of lymphocytes, isolated tumor cells, as well as some cell-free preparations of skin, dander, or feather tips from infected chickens.

Chicken kidney cells and duck embryo fibroblast cultures are typically used for isolation of serotype 1 MDV. Chicken embryo fibroblasts are usually used as substrates for serotypes 2 and 3. Cultures develop typical plaques within 4-14 days. Serotype identity can be determined by immunofluorescent staining with serotype-specific monoclonal antibodies. At this time, diagnosis of MDV pathotype requires *in vivo* challenge experiments.

TREATMENT & CONTROL

There is no effective treatment for MD, however proper application of an appropriate vaccine and good biosecurity can prevent clinical disease. Commercial poultry flocks are usually vaccinated either at day 18 of embryonation (*in ovo*) or at

hatch. Of the vaccines available, the best protection against highly virulent challenge strains is provided by CVI988 (Rispens) vaccine. None of the current vaccines provide sterilizing immunity and vaccinated flocks can still be infected with virulent MDV, which can replicate, be shed in FFE and infect other chickens. This has almost certainly contributed to increased virulence of field strains. In areas with high chicken density and challenge with the most virulent strains, high levels of biosecurity should be maintained to prevent early exposure of chicks to the MDV and multivalent vaccines (HVT + CVI988 or HVT + RB1B + CVI988) should be considered.

Improper handling of vaccine is one of the main reasons for increases in MDV mortality. The most effective and widely used MDV vaccines are cell-associated and must be maintained at -196°C during transport and until thawed for use. Ampules of vaccine must be thawed quickly in cold water and once thawed and diluted the vaccine must be kept cold and used within 2 hours. In addition, additives, such as antibiotics that may damage the vaccine, should be avoided.

Vaccines introduced since the 1970s have helped to control economic losses from MDV, however since none of these vaccines provide sterilizing immunity the virus has spread with the commercial poultry industry throughout the world. Current vaccines do provide protection against current strains, but new strategies will be needed in the future. Good vaccination and biosecurity practices should help to delay the development of more virulent strains of the virus.

REFERENCES

- Davidson I et al. Marek's disease in turkeys. I. A seven-year survey of commercial flocks and experimental infection using two field isolates. *Avian Dis*, 2002,46:314-21.
- Morrow C & Fehler F. *Marek's a Worldwide Problem*. In Davison E & Nair V Ed. *Marek's Disease: An Evolving Problem*, 2004. Elsevier. Amsterdam, 49-61.
- Nair V & Kung H-J. *Marek's Disease Oncogenicity: molecular mechanisms*. In Davison E & Nair V Ed. *Marek's Disease: An Evolving Problem*, 2004. Elsevier. Amsterdam, 32-48.
- Nair V et al, Herpesviridae. In Pattison M et al ed., *Poultry diseases*, 2008, Saunders Elsevier, Edinburgh, 258-275.
- Payne LN. Pathological Responses to Infection. In Davison E & Nair V Ed. *Marek's Disease: An Evolving Problem*, 2004. Elsevier. Amsterdam, 78-87.
- Witter RL & Schat KA. Marek's Disease. In Saif YM et al (eds.) *Diseases of Poultry*, 11th ed. 2003, Iowa State University Press: Ames, IA, 407-465.

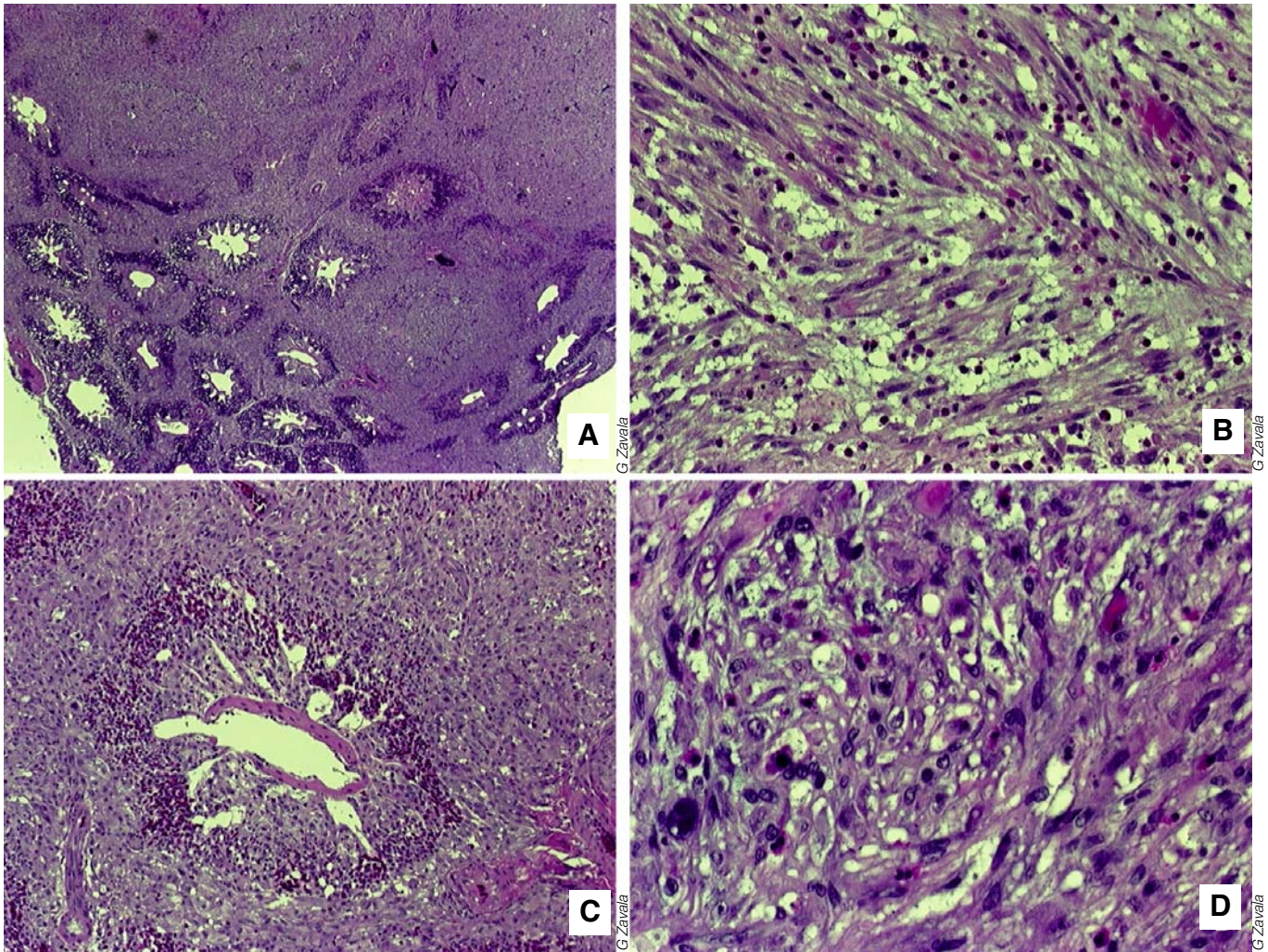


Fig.34.1, 34.2, 34.3 & 34.4: 24-day-old SPF chickens infected at 6 days of embryonation with ALV-A (RCASBP-A). **A.** Pulmonary sarcoma. The sarcomatous tissue has replaced most of the normal pulmonary parenchyma. **B.** Undifferentiated sarcoma in the lung. Note the spindle shaped cells with partial polarity. **C.** Undifferentiated sarcoma around a parabronchus in the in the lung. **D.** Detail of the sarcomatous tissue in panel C. Whorls of undifferentiated spindle cells with abundant cytoplasm and relatively large nuclei have replaced the pulmonary parenchyma.

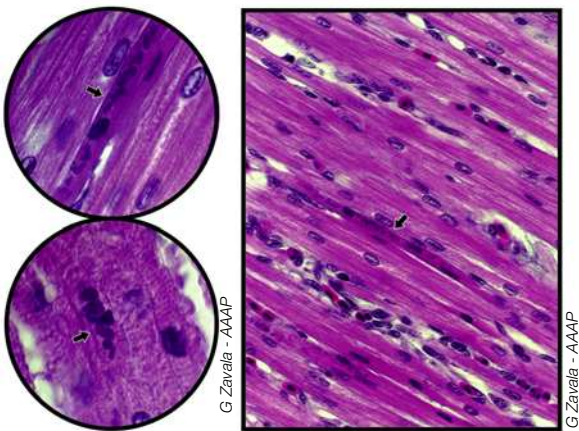


Fig.34.5, 34.6 & 34.7: Intracytoplasmic paranuclear retroviral matrix inclusion bodies. Retroviral inclusions are most typically basophilic or magenta colored and are seen adjacent to the nucleus in the cytoplasm of the myocardial fibers (arrows).

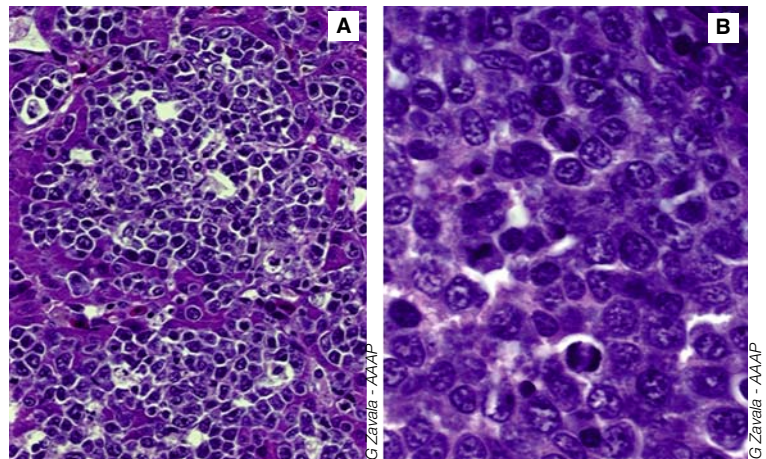


Fig.34.8 & 34.9: **A.** Lymphoma of the liver induced by ALV-A (RCASBP-A). The cells in the lymphoblastic infiltrates exhibit a characteristic immature appearance and display a relatively increased cytoplasmic-to-nuclear ratio compared to non-neoplastic mature small lymphocytes. The infiltrating cells are relatively uniform in size and their nuclei are relatively large and open with non-condensed chromatin. **B.** Occasional mitotic figures.

34. AVIAN LEUKOSIS

INTRODUCTION

Neoplastic conditions of infectious origin in commercial chickens are transmissible and predominantly of mesodermal origin. Virus-induced tumors in chickens are primarily associated with herpesvirus or retrovirus infection. Some of the most commonly diagnosed tumor conditions in chickens include Marek's disease (MD), a variety of leukosis including lymphoid (LL) and myeloid leukosis (ML), and reticuloendotheliosis (RE). All four conditions are of economic significance in commercial chicken production.

Avian leukosis is a group of neoplastic conditions of the chicken hemopoietic and lymphoid systems, and is induced by viruses belonging to the avian leukosis sarcoma group of retroviruses (ALSV).

The ALSV induce a variety of detrimental effects including tumors, increased mortality, delayed growth, feather abnormalities, and reduced egg and embryo size. The commercial table egg industry and the meat-type chicken industry have made significant and successful efforts towards eradication of members of the ALSV from commercial breeding stock.

ETIOLOGY & EPIDEMIOLOGY

The ALSVs are classified as simple retroviruses and contain a single-stranded, positive-sense, non-segmented, diploid RNA genome. Various internal proteins are closely associated with the genome and with the matrix and envelope proteins. The most relevant structural proteins include a group specific antigen protein (*p27*, *gs* or *gsa*) and the viral envelope proteins. The virus genome contains three essential genes known as *gag*, *pol* and *env*. The *gag* gene encodes primarily internal structural proteins, *pol* encodes a reverse transcriptase and a protease, and *env* encodes a poly-protein that matures into two envelope proteins, namely the transmembrane protein (TM or *gp37*), and the surface protein (SU or *gp85*). All three genes are flanked by long terminal repeats (LTR). Some ALSVs carry additional sequences or even oncogenes in addition to or in place of some of the regular genes (see Fig.33.11).

The ALSV include 10 subgroups of avian retroviruses (A-J), 6 of which (A-E and J) affect chickens naturally (see Tabl.34.1).

Subgroups F-I have been isolated from various species of pheasants, partridges and quail.

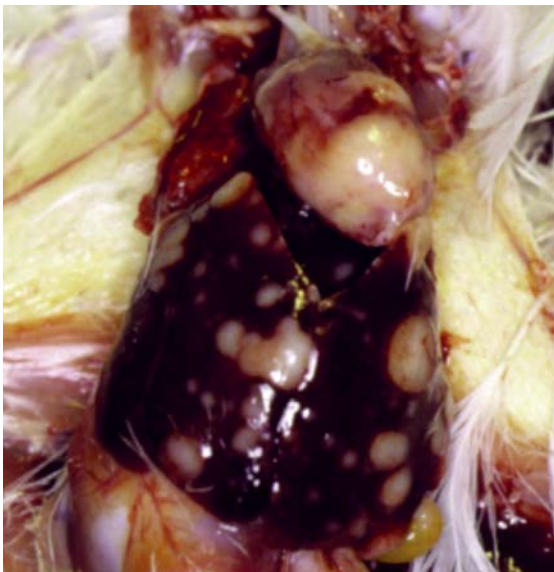


Fig.34.10: Lymphoma induced by subgroup A avian leukosis virus (RCASBP-A) in a 24-day-old SPF chicken. Multiple foci of neoplastic tissue can be seen affecting the liver and heart.

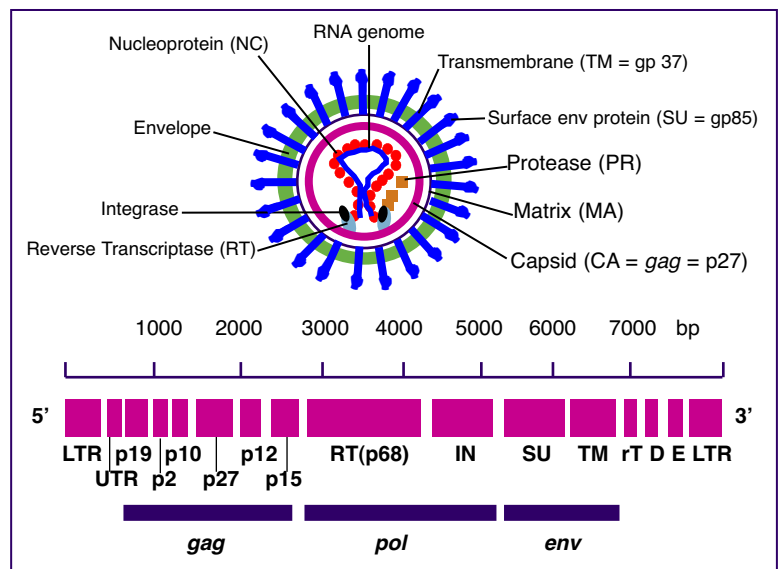


Fig.34.11: Diagram of ALV and its genome. The genome of replication competent ALV contains 3 genes known as *gag*, *pol*, and *env*. In the ALV provirus these 3 essential genes are flanked by 2 identical long terminal repeats (LTR). Some ALSVs may carry additional sequences in their genome. This diagram illustrates 3 additional sequences identified in ALV-J (rT = rTM, or non-functional redundant transmembrane region; D = DR1, or direct repeat; and E = E element).

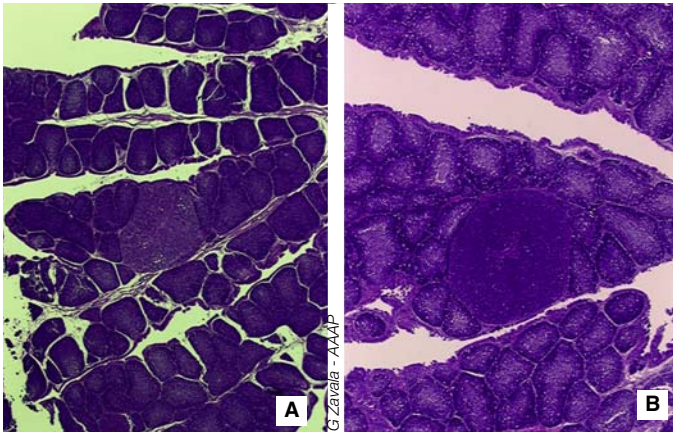


Fig.34.12 & 34.13: **A.** Bursal lymphoma in a 24-day-old SPF chicken infected with ALV-A (RCASBP-A). A single lymphomatous bursal follicle is seen in one bursal plica. **B.** Bursal lymphoma in an 8-week-old turkey infected with reticuloendotheliosis virus (REV APC-566) for comparison. A solitary lymphomatous bursal follicle is seen.

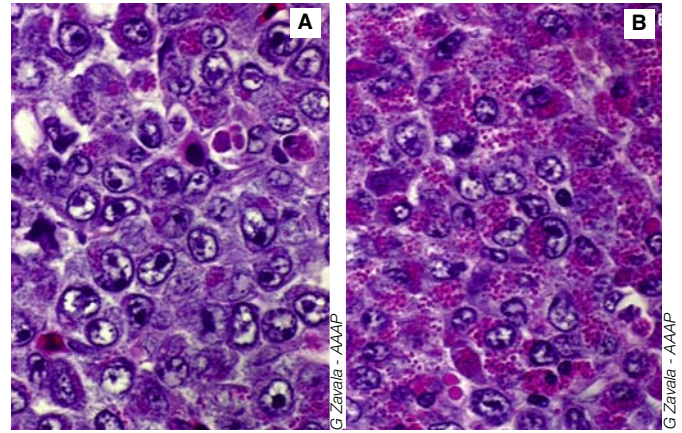


Fig.34.14 & 34.15: Myelocytoma induced by avian leukosis virus subgroup C (ALV-C) in a Bantam chicken. Exogenous ALV was isolated in cell culture and ALV-C subgrouping was accomplished by partial virus genome sequencing. Note the large size of the nuclei and the prominence of the nucleoli. Neoplastic tissues like the ones in panels A and B were present primarily in the liver and peritoneum.



Fig.34.16: Mandibular myelocytoma in a 35-day-old meat type chicken infected experimentally with ALV-J (isolate ADOL-7501).

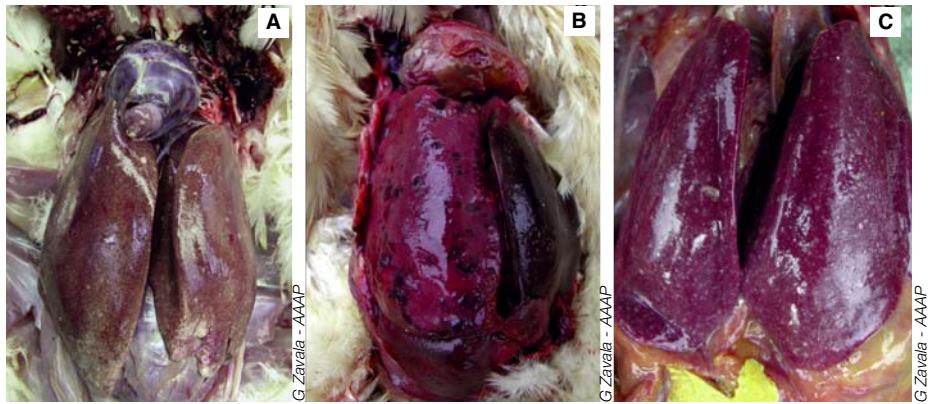


Fig 34.17, 34.18 & 34.19: **ALV-J infections.** ALV-J infection was detected using virus isolation, PCR and partial virus genome sequencing. **A.** Myeloid leukosis in an adult broiler breeder male infected with ALV-J. The discolored areas of the liver are myelocytomas, which were confirmed upon microscopic examination. **B.** Hemangiosarcoma in a grandparent meat type chicken infected with ALV-J. The smaller dark foci correspond to neoplastic tissue affected with hemangiosarcoma. The larger dark areas represent subcapsular hemorrhages, which are commonly found due to hepatic friability in cases of hepatic hemangioma or hemangiosarcoma. **C.** Myelocytoma in a grandparent meat type chicken infected with ALV-J.

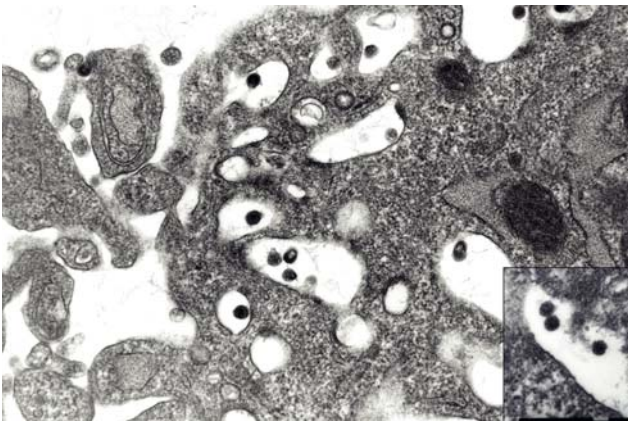


Fig.34.20: **Avian leukosis virus subgroup J.** This ALV-J (isolate AF97-L17, also known as ADOL-4817) was isolated in 1996 from a meat type male line pedigree chicken. Transmission electron microscopy of secondary C/E chicken embryo fibroblasts infected with ALV-J (AF97-L17) (64,000X). Insert = The same virus culture (AF97-L17) with a reference bar for virus dimensions.

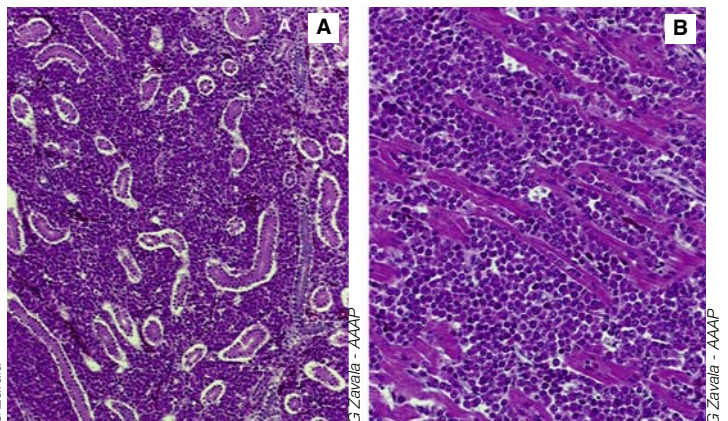


Fig.34.21 & 34.22: **Myelocytoma.** **A.** Renal myelocytoma characterized by solid sheets of relatively immature myelocytes. The renal tubules are partially autolytic and well disassociated due to the severe myelocytic infiltration. **B.** Myocardial myelocytoma. The cell morphology is similar to that in panel A.

Subgroup	Host	Compartment
A	Chicken	Exogenous
B	Chicken	Exogenous
C	Chicken	Exogenous
D	Chicken	Exogenous
E	Chicken	Endogenous
F	Ring-necked pheasant Green pheasant	Endogenous Endogenous
G	Ghinghi pheasant Silver pheasant Golden pheasant	Endogenous Endogenous Endogenous
H	Hungarian partridge	Endogenous
I	Gambel's quail	Endogenous
J	Chicken	Exogenous

Tabl.34.1: Subgroups of ALV recognized in chickens and other avian species.

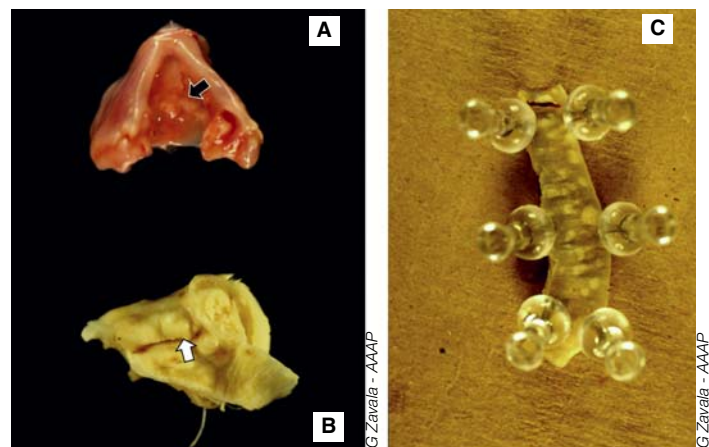


Fig.34.23 & 34.24: **Myelocytoma**. **A.** Ventral aspect of the laryngeal vestibulum exhibiting neoplastic nodules (black arrow). Such nodules are frequently myelocytomas induced by ALV-J. **B.** Myelocytomas in the laryngeal vestibulum (white arrow). These neoplastic changes usually involve the submucosa of the larynx and trachea in chickens infected with ALV-J. **C.** Myelocytoma. Multifocal neoplasia in the trachea of an adult meat type chicken infected with ALV-J.

Agent	Onset of tumors	Most common tumor	Common gross lesions	Common microscopic lesions
MDV	> 4 W	Lymphoma	Focal to diffuse buff colored mass Usually no bursal tumors	Irregular neoplastic lymphocytes
REV	> 16 W	Lymphoma	Diffuse to focal buff colored mass Bursal tumors Occasional nerve enlargement	Uniform lymphocytic infiltrates Bursal interfollicular infiltrates
ALV-A	> 16 W	Lymphoma	Diffuse to focal buff colored mass Bursal tumors	Uniform lymphocytic infiltrates Bursal interfollicular infiltrates
ALV-J	> 4 W	Myelocytoma	Focal to diffuse buff colored mass around bone and cartilage No bursal tumors No nerve involvement	Solid sheaths of myelocytes

Tabl.34.2: Differential diagnosis of infectious conditions in chickens.

Subgroups A-D and J infecting chickens are considered **exogenous viruses** since they usually infect susceptible cells from the outside and are transmitted congenitally and horizontally.

Subgroup E encompasses a family of **endogenous viruses** (*endogenous viral* or **ev loci**) transmitted vertically (genetically). Among the endogenous viruses, the *ev* loci are most closely related to the exogenous ALSV. The *ev*'s are regarded as simple retroviruses that are often transcriptionally silent, although some of them, including *ev2* and *ev21*, can replicate and produce infectious endogenous virus with a subgroup E phenotype.

Some differences between exogenous and endogenous viruses include:

- 1) endogenous viruses (*ev*'s) infect the target cells genetically, whereas exogenous viruses infect the host cells from the outside;
- 2) *ev*'s are often defective and lack a complete genome with all coding and non-coding

sequences necessary for viral replication; 3) *ev*'s tend to be transcriptionally silent, which is a reflection of a reduced number of transcription regulatory sequences in their LTRs.

Other families of endogenous retroviral sequences of chickens include EAV, *ev/J*, ART-CH and CR-1. The **EAV** family is considered evolutionarily more ancient than the *ev* loci, and it has been suggested that members of the EAV family of endogenous retroviral sequences may have participated in recombination events leading to the emergence of some of the most recently identified ALVs. The **ev/J** family is considered by some as the equivalent of the EAV-HP family.

The **ART-CH** (avian retrotransposon from chicken genome) family consists of non-transcribed fragments of endogenous retrovirus-related sequences flanked by two LTRs, and are considered important mutagens with a role in chicken evolution.

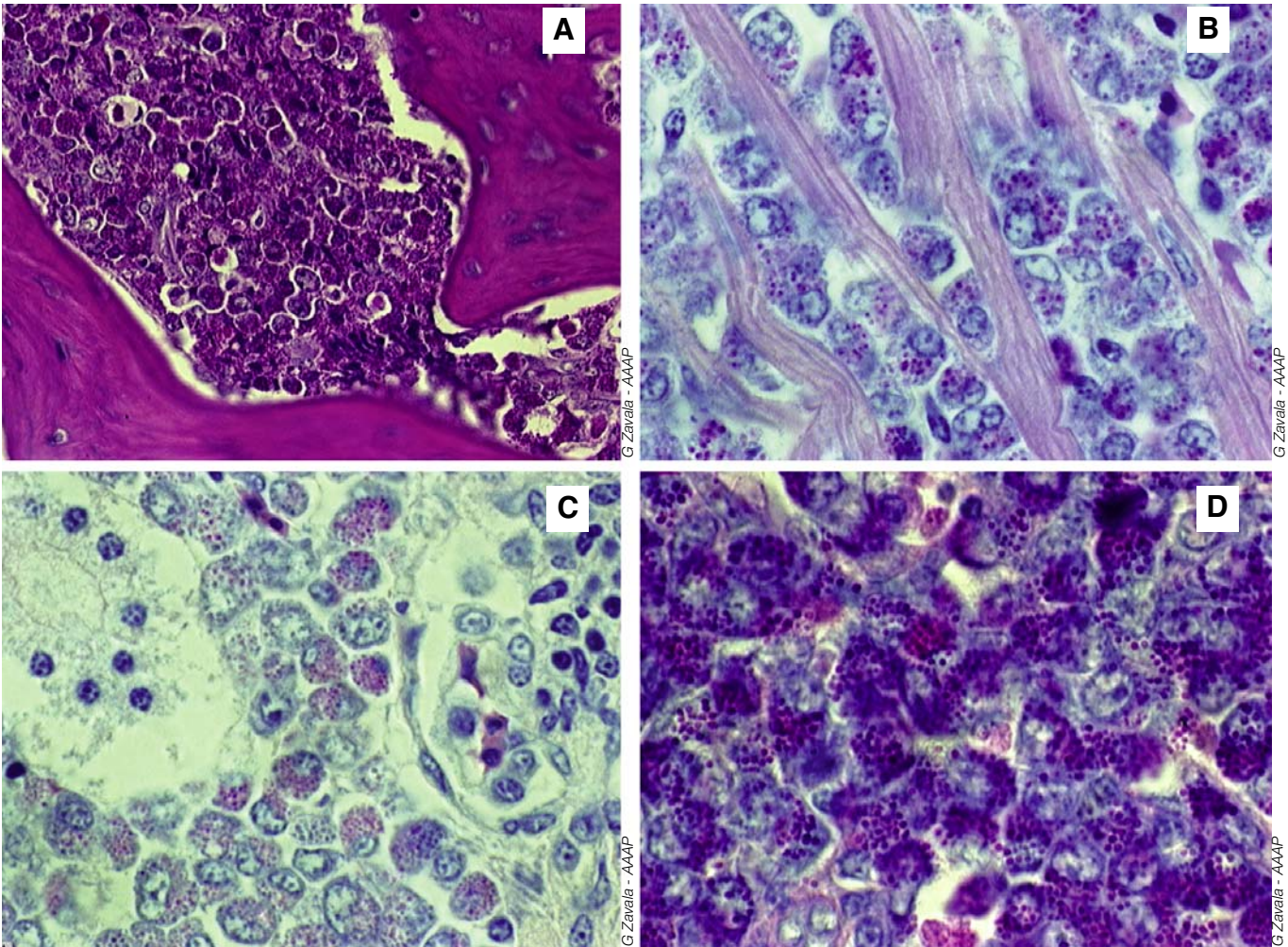


Fig.34.25, 34.26, 34.27 & 34.28: **A.** Bone marrow of a broiler breeder chicken infected with ALV-J. The entire marrow space is filled with solid sheets of immature neoplastic granulocytes. Most outbreaks of myelomonocytic myeloid leukemia are characterized by severe proliferation of myeloblasts and/or myelocytes stemming from the bone marrow. Cells of the erythroblastic lineage are undetectable in this field (H&E). **B.** Infiltrating immature myelocytes in the myocardium. Note the myofibers being displaced by infiltrating cells (Giemsa). **C.** Solid sheets of infiltrating immature myelocytes in the renal interstitium. Note the grossly enlarged pleomorphic and open nuclei of the neoplastic cells. The cytoplasm of the infiltrating cells is tightly packed with acidophilic spherical granules (Giemsa). **D.** Myelocytoma of the liver. The cell morphology is similar to that of the neoplastic cells in panel C. The liver, spleen and kidney are often targets for neoplastic change induced by ALV-J (Giemsa).

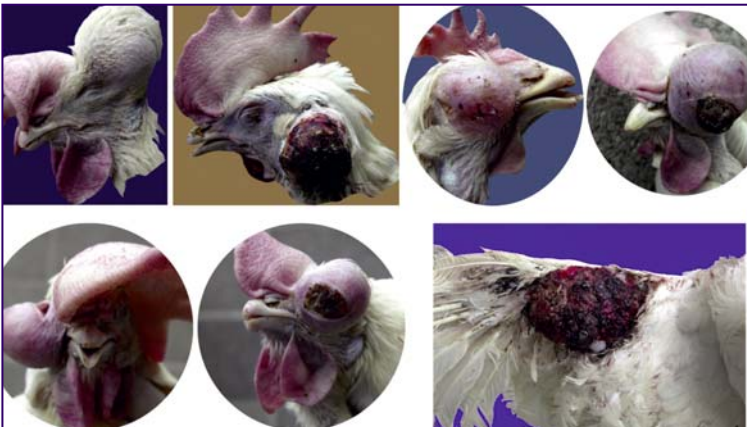

Fig.34.29 to 34.35: Subcutaneous sarcomas in adult commercial egg layer chickens infected with myeloblastosis associated virus type 1 (MAV-1). This yet unclassified avian retrovirus is partially related antigenically to ALV-A. Note the large predominantly subcutaneous masses around the eyes and dorsal aspect of the wing. Similar lesions were observed above the shanks.

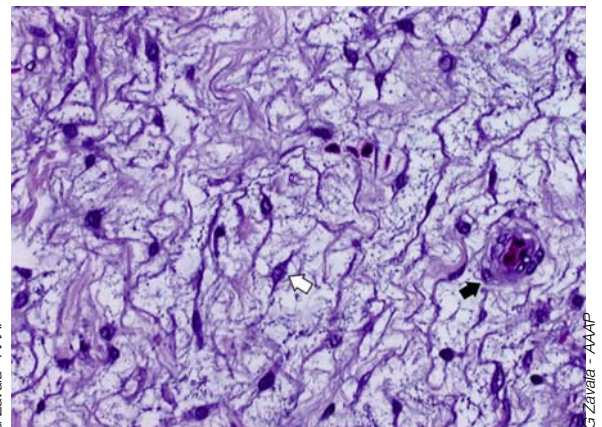


Fig.34.36: Subcutaneous sarcoma in a 34-week-old white Leghorn commercial layer (H&E, 400X). Note the relative lack of cell polarity, the presence of proliferating perivascular cells (black arrow) and the fusiform, independent cells (white arrow) surrounded by loose mucigenous material. Mitotic figures are absent in this field. Myeloblastosis associated type 1 (MAV-1) was isolated in this field case.

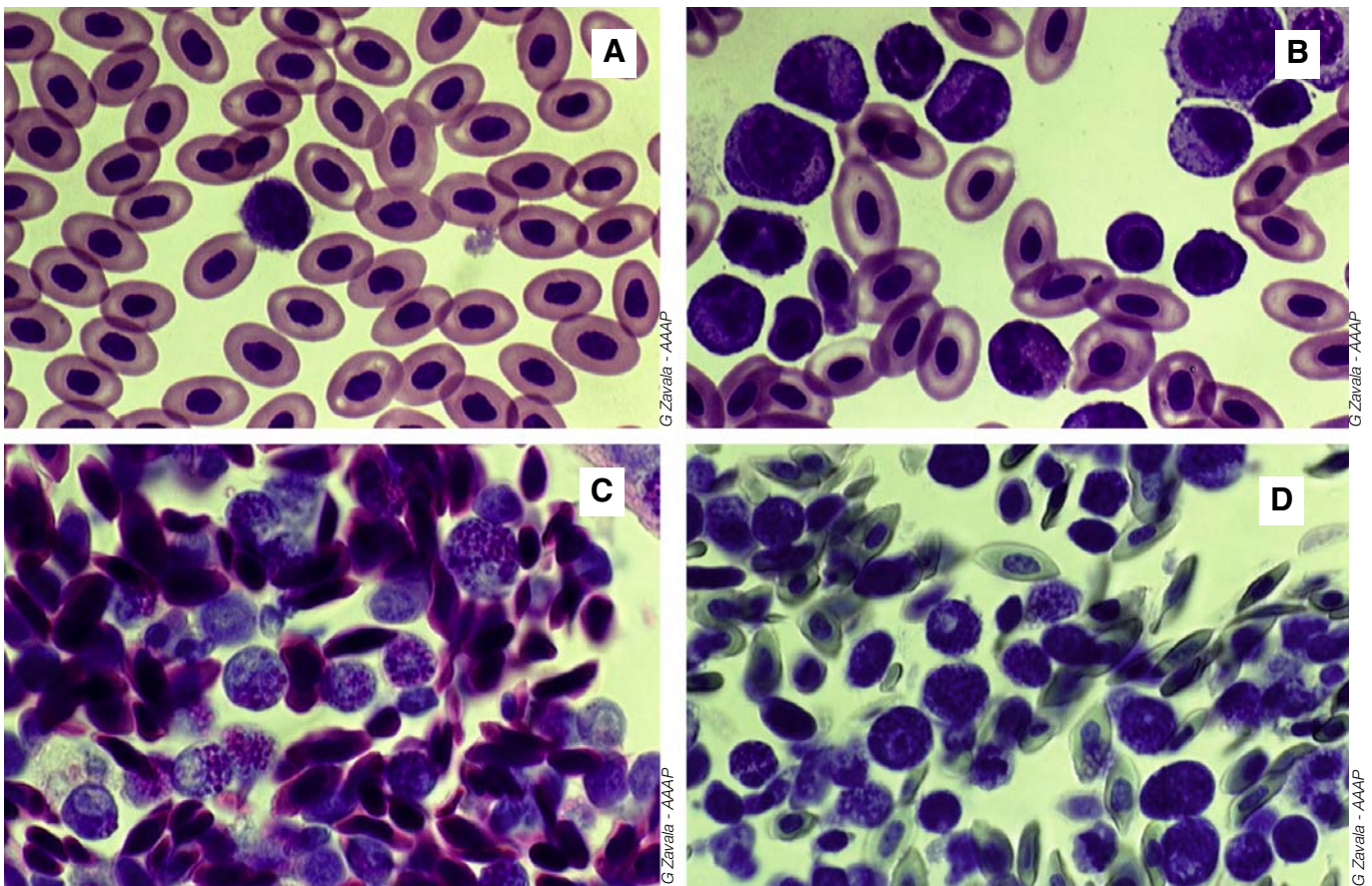


Fig.34.37, 34.38, 34.39 & 34.40: **A.** Blood smear from a clinically healthy adult meat-type pedigree chicken (Giemsa). **B.** Blood smear prepared from an 23-week-old meat-type pedigree chicken in a flock with an outbreak of myeloid leukosis caused by ALV-J. Abundant large immature white blood cells contain metachromatic granules in their cytoplasm (Giemsa). **C.** Lumen of a blood vessel in the liver of an adult broiler breeder chicken infected with ALV-J and expressing myelocytomas. Abundant immature myelocytic cells are present (Giemsa). **D.** Blood smear from an adult broiler breeder chicken infected with ALV-J and expressing myelocytomas (Diff Quick).

The **CR-1** family (chicken repeat 1) consists of a group of retrotransposons not containing LTRs, but displaying reverse transcriptase sequences. A significant proportion of the chicken genome contains CR-1-related sequences. These families of endogenous viruses and endogenous retroviral elements are generally considered of low or no economic significance for the poultry industry, but they should be considered important from the point of view that they can favor mutational variations in the genomes of the economically important exogenous retroviruses.

The exogenous ALVs are considered pluripotential since they can induce a variety of neoplastic conditions. One of the most commonly recognized of these conditions is lymphoid leukosis (LL), typically induced by subgroups A and B, but other subgroups may be associated with LL. Before effective eradication programs were adopted subgroup A (ALV-A) was considered the most frequent exogenous virus in commercial layers.

Avian leukosis subgroup J (ALV-J), also an exogenous ALV, has been recognized in recent years as the most frequent subgroup infecting meat-type chickens and causing severe losses associated with neoplasia, mortality and poor economic performance. ALV-J became widespread in the meat-type chicken industry in the 1990s. Although the frequency of infection has already been reduced very significantly in female lines, at least until early 2001 there was still a significant prevalence in broiler breeder males in some geographic areas.

CLINICAL SIGNS & LESIONS

The clinical signs and lesions vary significantly according to various aspects, including the virus subgroup, genetics of the host, endogenous viruses present in the chicken genome, immune competency, concomitant pathogens and other factors.

Tabl.34.2 includes some characteristics that may contribute in facilitating diagnosis of neoplastic conditions of infectious origin in chickens.

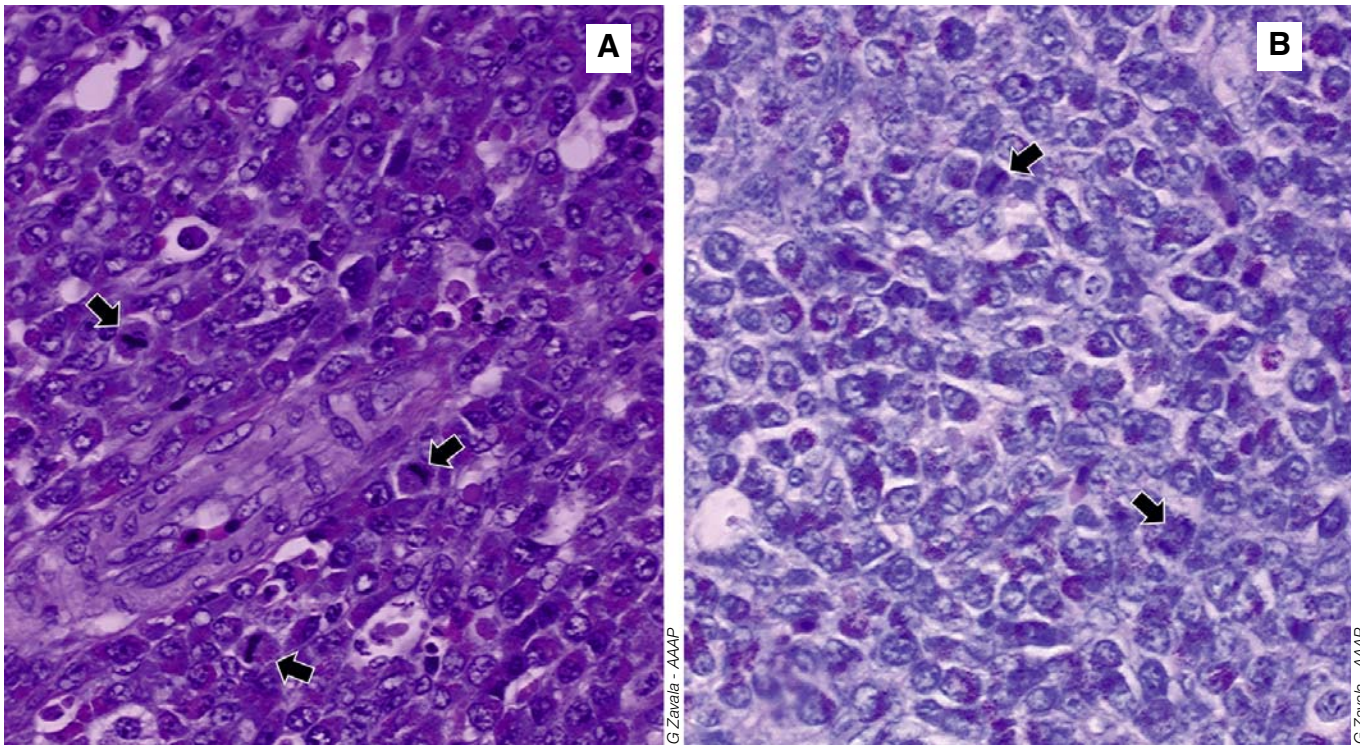


Fig.34.41 & 34.42: **A.** Myelocytoma detected in an 8-week-old chicken infected experimentally with MAV-1 (H&E). Various mitotic figures are seen in this field. **B.** The same tissue as in panel A (Giemsa). Myelocytomas induced by MAV-1 are often indistinguishable histologically from those induced by ALV-J and other ALVs.

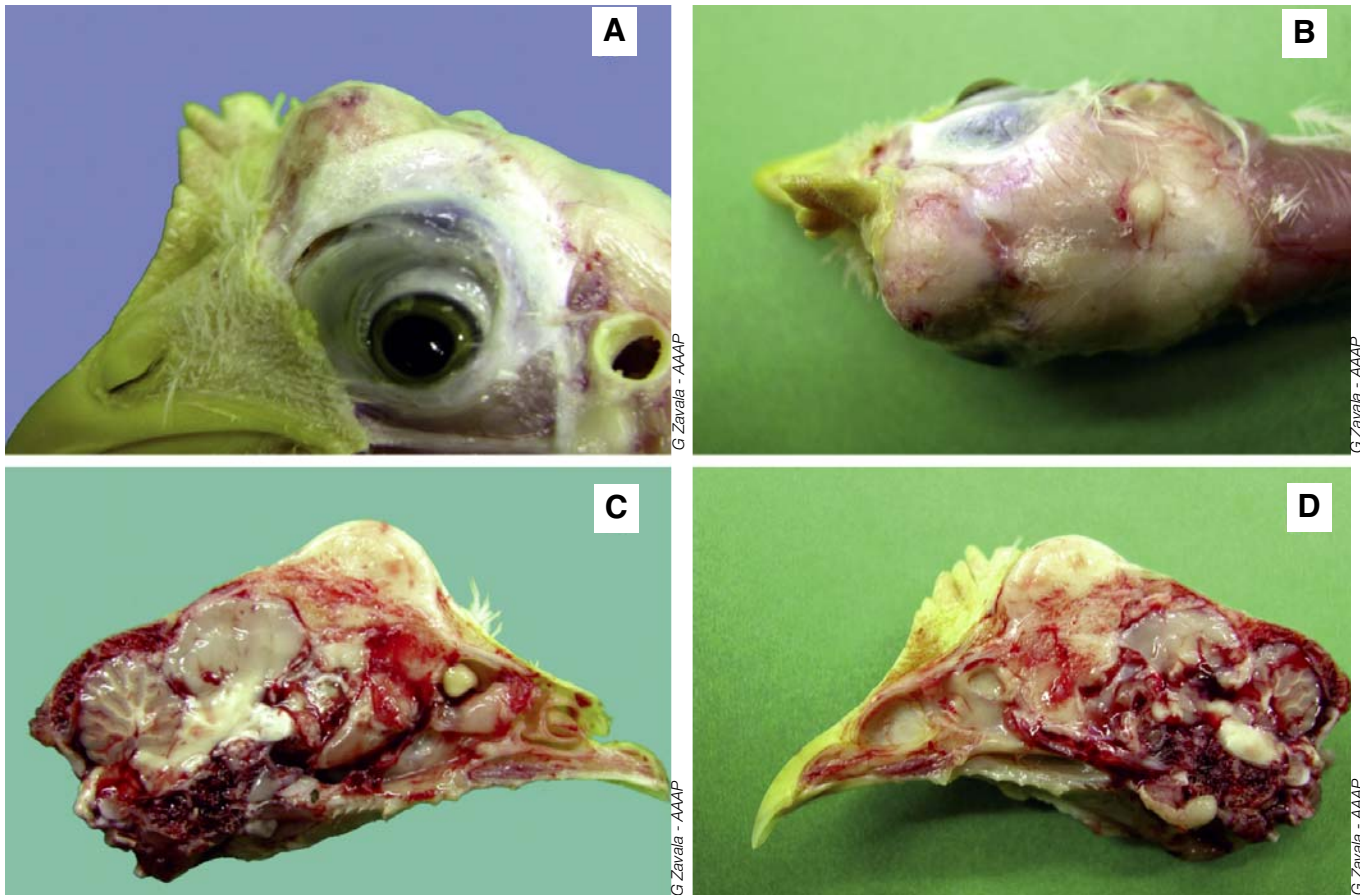


Fig.34.43, 34.44, 34.45 & 34.46: **A-B.** Myelocytomas topping the planar bones of the cranium in a young commercial egg layer. Myelocytomas are not induced exclusively by ALV-J. Like many other avian retroviruses, MAV-1 is a pluripotent virus in that it can induce a variety of tumors, including myelocytomas. This chicken was infected experimentally during embryonic development with a MAV-1 isolate obtained from commercial egg layers infected with MAV-1 and expressing primarily subcutaneous sarcomas. **C-D.** Sagittal sections of the head from the chicken in panels A and B.

Lymphoid leukosis

One of the most important factors determining the type of neoplastic expression is the viral subgroup. Subgroups A and B induce most commonly lymphoid leukosis, which in general is detected not before 16 weeks of age. This is typical of slowly transforming viruses, but it should not be taken as an invariable rule that subgroups A and B induce lymphoid leukosis by 16 weeks of age or later.

Common lesions associated with LL include depression, paleness, undersized chickens, a significantly enlarged liver and spleen, bursal tumors and lesions suggestive of neoplasia in a variety of organs. Most tumors associated with LL appear buff-colored and may be local or diffuse and are localized primarily in visceral organs, but some chickens may display lesions involving skeletal tissues. Within a flock affected with LL the majority of chickens will express one type of tumor, while some may express a different array of tumors. Therefore it is important to do postmortems in as many chickens as possible.

Myeloid leukosis

Myeloid leukosis (ML) is not exclusively associated with infection with ALV-J, but in recent years ALV-J has been diagnosed in most cases of ML in meat-type chickens. Experimental infection with ALV-J results in expression of myelocytomas primarily. A usual observation in young chickens is delayed growth and poor uniformity on a flock basis. Although the incidence of tumors is not high in chickens under 8 weeks of age it is not uncommon to observe occasional chickens with tumors at a very young age. Apart from some depression and paleness there are no obvious clinical signs in mature chickens. The highest incidence of tumors is seen in sexually mature chickens, which usually express high mortality and a variety of tumors in visceral organs as well as in the tissues adjacent to the sternum, ribs, vertebrae and the hip joints, as well as the larynx and trachea among other organs.

Most of the tumors induced by ALV-J are myelocytomas, but other tumors have been observed, including hemangiomas and sarcomas. Severely affected flocks also express various forms of leukemia, with the myelomonocytic type being most common.

The high mortality associated with ALV-J infection in mature chickens is usually coupled with egg production losses and reduced egg and embryo

size. Progeny flocks from breeder flocks infected with ALV-J frequently show poor economic performance.

DIAGNOSIS

Diagnosis of infection with ALV can be accomplished using a variety of methods intended to confirm the presence of exogenous viruses. The standard methods used currently include histopathology, virus isolation and molecular detection of specific genetic sequences of ALV.

Examination of microscopic lesions is helpful but not conclusive. A thorough description of the microscopic lesions observed in ALV infection is beyond the objectives of this chapter, particularly because of the wide variety of tumors induced by the various members of ALSV.

For virus isolation, the most commonly used samples include plasma, peripheral white blood cells and filtered tumor homogenates. Virus isolation should be done only in secondary chicken embryo fibroblasts that are permissive to exogenous ALV (C/E). Ordinary embryo fibroblasts (including fibroblasts from specified pathogen free embryos) are permissive to exogenous and endogenous ALV.

Demonstration of infection with endogenous viruses is usually irrelevant, since virtually all commercial chickens carry endogenous retroviral sequences in their germline. Therefore, it is important to demonstrate exogenous viruses only for a meaningful diagnosis. A standard protocol includes infection of secondary chicken embryo fibroblasts and incubation of the cultures for at least 7 days. At the end of the incubation period, the cells are sequentially disrupted by sequential freezing and thawing or sonication to expose the group specific antigen (gsa), which is then detected using an antigen-capture ELISA system. This approach is helpful to detect any of the ALV subgroups, excluding subgroup E (ALV-E). Other assays are needed to determine the subgroup involved, including virus neutralization and/or molecular-based methods. A number of PCR and RT-PCR systems have been designed for the rapid diagnosis of ALV-J in a variety of samples, including plasma, white blood cells, allantoic fluid, a variety of tissues and feather pulp. In addition to virus isolation, antigen capture ELISA and PCR/RT-PCR, antibodies to ALV can be detected using ELISA systems or virus neutralization. The presence of antibodies against ALV-A and ALV-B can be determined with commercially produced ELISA.

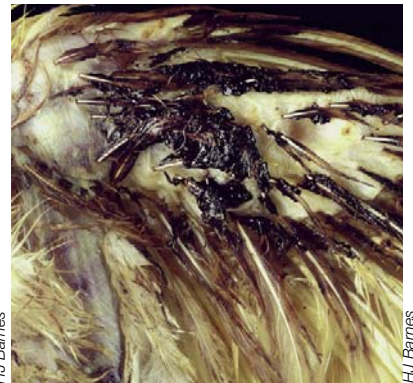
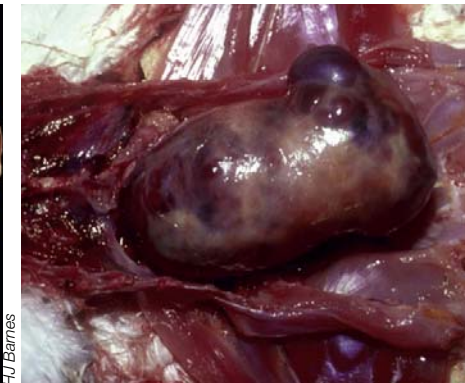
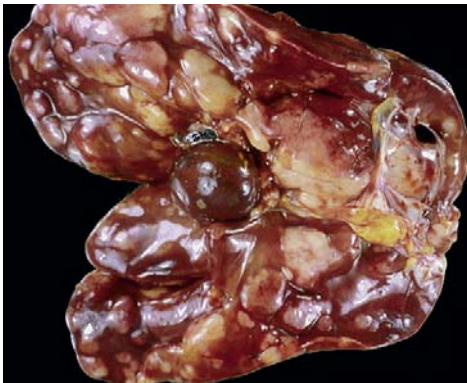


Fig.34.47: Fowl 18 months - liver, myelocytomatosis.

Fig.34.48: Fowl - kidney, nephroblastoma.

Fig.34.49: Broiler Breeder - multiple hemangiomas.

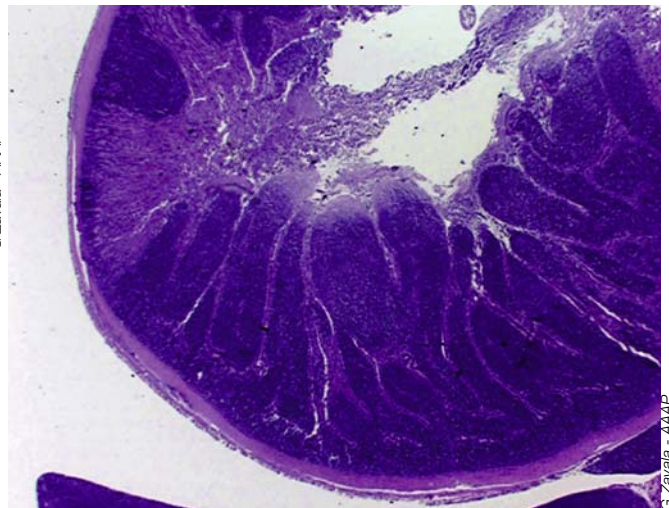
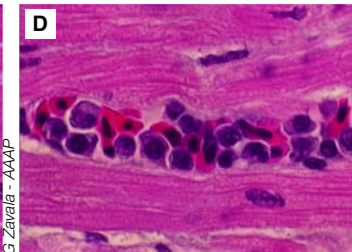
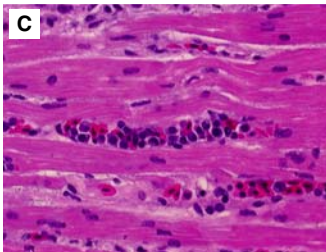


Fig.34.50, 34.51, 34.52 & 34.53: **A.** Reticuloendotheliosis. Neoplastic foci in the spleen of a 58-day-old SPF chicken infected at hatch with the REV APC-566 isolate of REV. **B.** Feather abnormalities in a 28-day-old SPF chicken infected at hatch with the REV APC-566 isolate of REV. **C.** Myocardium with abundant intravascular large immature neoplastic lymphoblasts in a SPF turkey infected at hatch with the REV APC-566 isolate of REV (H&E, 400X). **D.** Larger magnification of the same tissue in panel C (H&E, 1000X).

Fig.34.54: Reticuloendotheliosis. Chronic lymphosarcoma involving the *lamina propria* of the duodenum in an Attwater's prairie chicken. Solid sheets of immature lymphocytes populate the *lamina propria*. The lumen of the intestine is reduced due to the neoplasia.

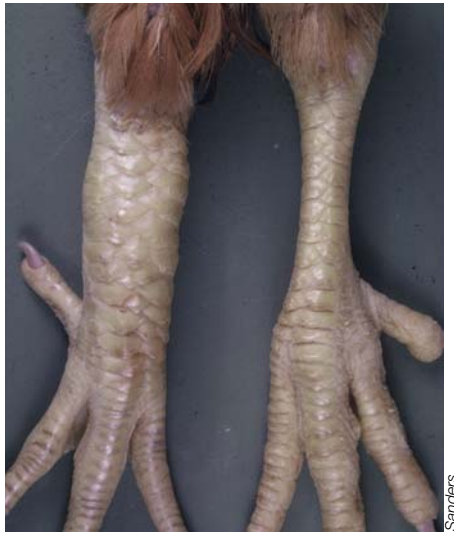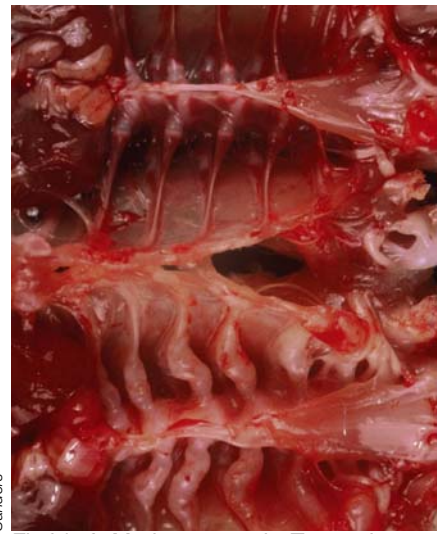
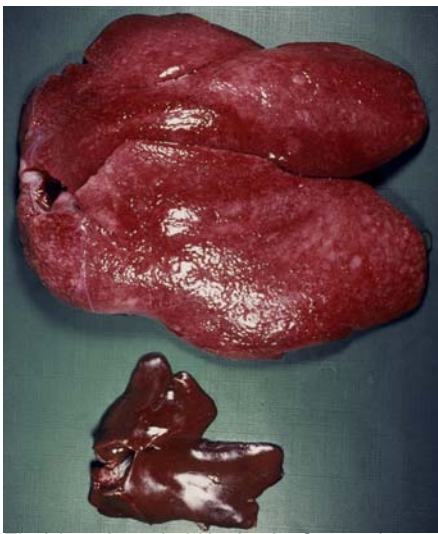


Fig.34.55: Lymphoid leukosis. Comparison of greatly enlarged tumorous liver (diffuse form) with liver of a chicken of the same age.

Fig.34.56: Myelocytomatosis. Tumors have a predilection for the visceral surface of flat bones as the ribs (normal chicken on the top).

Fig.34.57: Osteopetrosis (on the left) with excessive osteoblast proliferation. Comparison with normal leg on the right.

Antibodies against ALV-J can also be detected using commercially developed ELISA, but the specificity has been questioned. Interpretation of antibody ELISA results is not trivial, and certainly antibody ELISA should not be used as a conclusive diagnostic assay for ALV infection, whether it is caused by ALV-A, ALV-B or ALV-J. Direct detection of *gsa* using antigen-capture ELISA is useful for control and eradication purposes but it should not be considered a conclusive diagnostic assay. Virus isolation and identification is the only conclusive diagnostic approach, and it usually requires a variety of strategies to confirm the diagnosis.

TREATMENT & CONTROL

There is no treatment for chickens infected with ALV. Considering the forms of transmission of ALSV, their control involves a complex approach geared to eradicate exogenous viruses from pedigree and multiplier flocks by arresting congenital and horizontal transmission. Most poultry breeding companies use a variety of methods for detecting ALVs in their breeding stock. Eradication programs are extremely complex and require substantial and costly modifications or adaptations of the breeding programs, housing, incubation and biosecurity practices.

A typical approach involves virus isolation from blood components at various ages, antigen-capture ELISA for detection of group specific antigen in vaginal and/or cloacal swabs, egg albumen and chick meconium, and molecular-based methods for confirmation of suspect or dubious results.

Any chickens suspected of being infected at any of the sampling ages and using any of the referred methods are removed from the breeding flocks. Infected breeders and their progeny are not used for breeding purposes and introduction of any new genetic stock into the gene pool should be carefully scrutinized for several generations before it qualifies as ALV-free.

REFERENCES

- Crittenden LB. Retroviral elements in the genome of the chicken: implications for poultry genetics and breeding. *Critical reviews in poultry biology*, 1991, 3, 73-109.
- Fadly AM. Avian Retroviruses. *Vet. Clinics North Am: Food An Practice*, 1997,13:71-85.
- Payne LN & Howes K. Eradication of exogenous avian leukosis virus from commercial layer breeder lines. *Vet Record*, 1991,128:8-11.
- Payne LN. History of ALV-J. In: Kaleta EF et al (ed.), Int.Symp. on ALV-J and other avian retroviruses, pp. 3-12, *World Vet. Poultry Association & Institut für Geflügelkrankheiten*, Justus Liebig Univ., Rauschholzhausen, Germany 2000.
- Payne LN. Myeloid leukaemogenicity and transmission of a new strain of avian leukosis virus. In: McNulty MS & McFerran JB (ed.), *New and Evolving Virus Diseases of Poultry*, pp. 311-325, Community Research and Technological Development Programme in the Field of "Agriculture and Agro-Industry, Including Fisheries,1990-1994," (AIR), Brussels, Belgium 1992.
- Payne, LN & Fadly AM. Leukosis/Sarcoma Group. In: BW Calnek (ed.), *Diseases of Poultry*. Vol. 1, pp. 414-466, Iowa State University Press, Ames (1997).

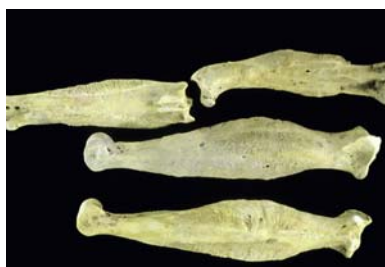

Fig.34.58: Bone lesions - osteopetrosis.

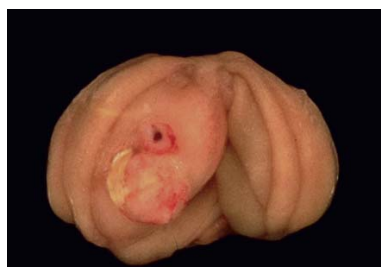


Fig.34.59: Lymphoid leukosis (layer) - bursal tumor.

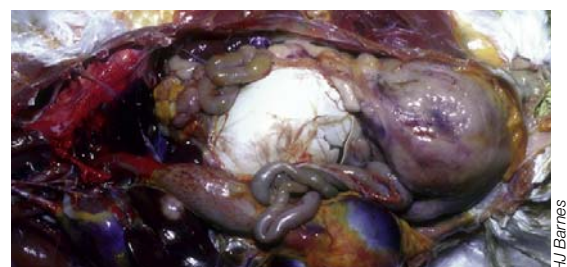

Fig.34.60: Lymphoid leukosis (layer) - bursal tumor. Abdominal laying - large bursal tumor obstructing cloaca.

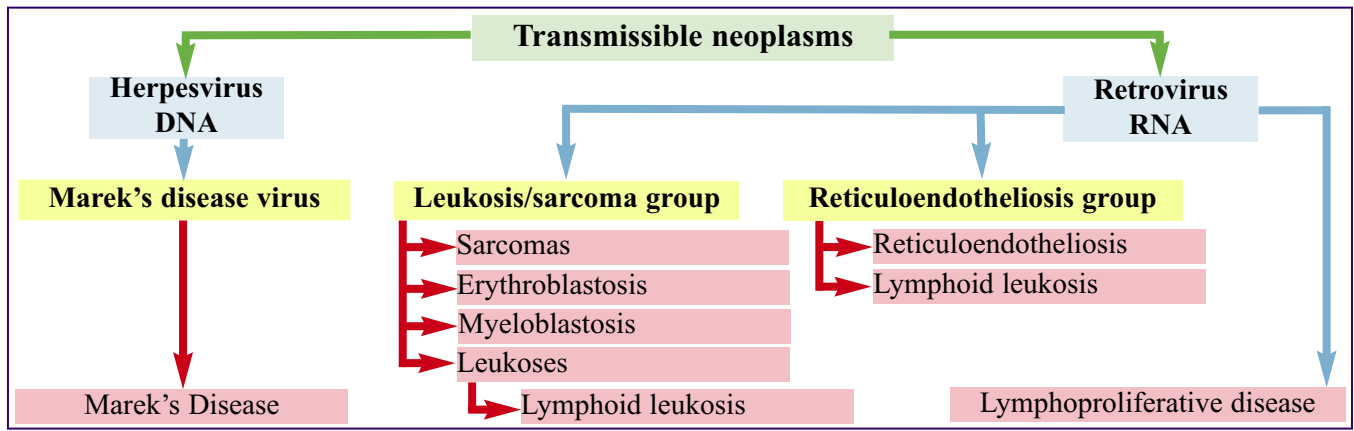


Fig.35.1: Principal transmissible neoplasms of poultry (adapted from Nair V, 2013).

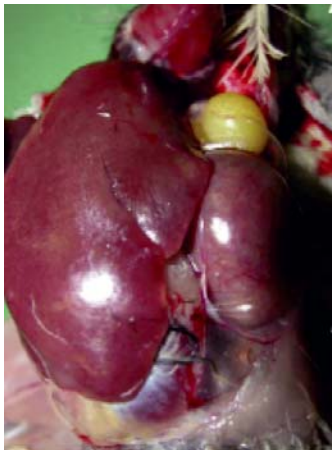

Fig 35.2: Reticuloendotheliosis (32-week-old quail). The liver and spleen are grossly enlarged.

Fig 35.3: Reticuloendotheliosis (20-week-old quail). Liver and spleen (at the top) grossly enlarged (diffuse infiltration with lymphoblasts). Compare with normal sizes at the bottom.

Fig 35.4: Reticuloendotheliosis. Feather abnormalities in a 28-day-old chicken infected at hatch with REV.

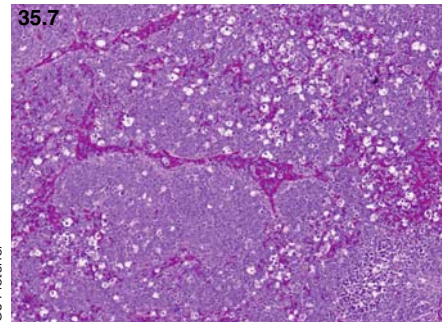
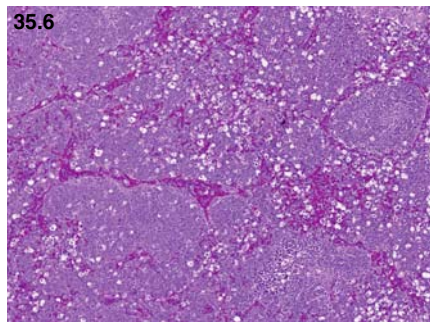
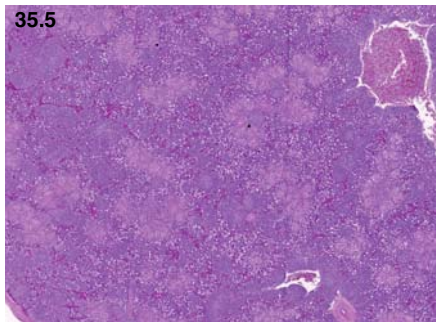


Fig.35.5, 35.6, 35.7, 35.8 & 35.9: Reticuloendotheliosis. Different power views of the spleen from a 41-week-old turkey affected by reticuloendotheliosis.

Fig.35.5: Low power view shows increased lymphoid cell population and multiple regions of pale reticular cells within which are foci of fibrinoid necrosis.

Fig.35.6: Higher magnification of Fig.35.5 shows the multinodular coalescing regions of basophilic neoplastic lymphoid cells.

Fig.35.7: Higher magnification of Fig.35.6 shows multinodular masses of lymphoid cells filling and expanding the red pulp region.

Fig.35.8: Higher magnification of Fig.35.7 shows edge of a large nodular mass, large number of apoptotic cells, and loss of capsule on the lower edge (bottom) of this collection.

Fig.35.9: Higher magnification of Fig.35.8 shows the edge of a nodular collection of lymphoid tumor cells. Note the closely packed cells with large nuclei and indistinct cell borders.

35. RETICULOENDOTHELIOSIS & LYMPHOPROLIFERATIVE DISEASE

INTRODUCTION

Transmissible neoplasms in poultry are essentially caused by a herpes virus and several retroviruses (see Fig.35.1 & tabl.35.1). Chickens are mainly affected by Marek's disease, avian (lymphoid) leucosis, and reticuloendotheliosis; while turkeys are mainly affected by reticuloendotheliosis and occasionally by Marek's disease (sporadically reported over the past 20 years) and lymphoproliferative disease, which only affects turkeys.

These viral conditions are oncogenic and immunosuppressive. Marek's disease is covered under its own chapter (see Chap.II.33). The recognition of Marek's disease in turkeys complicates the diagnosis of lymphoid tumors because the histological lesions are the same as for the lymphoproliferative disease. Virologic tests (often not done routinely) are needed to differentiate these two conditions.

Some of these viruses have demonstrated a propensity to evolve over time, creating ongoing issues for diagnosis and disease control. Thankfully, except for rare occasions when the reticuloendotheliosis virus (REV) is a contaminant of live vaccines produced in chicken embryo cells or tissues, the economic importance of REV is relatively minor. As for lymphoproliferative disease, it is also presently considered sporadic and of minimal importance.

ETIOLOGY

Reticuloendotheliosis

The reticuloendotheliosis virus is a single stranded RNA virus from the genus *Gammaretrovirus* of the *Retroviridae* family. The nomenclature for both the disease and the virus comes from the lesions caused by a defective strain labeled "T" (defective for replication in cell culture). The terminology is the same for non-defective strains, even if they almost never produce reticuloendothelial cell lesions. These non-defective REV strains are a single serotype subdivided into three antigenic subtypes. They cause the runting disease and the chronic neoplastic disease observed in the field. The defective strain T causes an acute reticulum cell neoplasia that has yet to be reported in nature.

The REV can integrate into the host genome and in DNA viruses like Marek's disease and fowlpox. Reticuloendotheliosis viruses are different from the leucosis/sarcoma group (see Fig.35.1). REV isolates are very homogeneous in antigenicity, and their replication *in vivo* is possible in many avian species.

Lymphoproliferative disease

The lymphoproliferative disease virus (LPDV) is another retrovirus that is distinct from those associated with lymphoid leucosis and reticuloendotheliosis.

EPIDEMIOLOGY

Reticuloendotheliosis

The runting disease syndrome rarely occurs and is mainly observed when chicks are vaccinated with a REV-contaminated vaccine, resulting in a high prevalence of stunted birds. Chronic neoplasia is also rare. Lymphomas in commercial turkeys have been reported in the USA, England and Israel. Mortality and condemnations can reach 20%. In addition to chicken flocks, where it is even less frequently observed than in turkeys, chronic neoplasia may occur in ducks, quails, pheasants, geese, peafowl, and prairie chickens.

Horizontal transmission occurs between commercial flocks, but the epidemiology is poorly understood. Experimental studies have demonstrated the possible role of insect transmission. In fact, transmission via mosquitoes may explain the increased infection incidence during summer months in the USA, although it is doubtful that enough viremic chickens would be present on a site at any given time to make this an important mode of transmission.

In an experimental study, horizontal transmission did not occur when chickens were separated by wire mesh. In the field, REV infection is noted in older flocks. Contaminated poultry houses (via contaminated feces) and biological reservoirs, such as insects, are suspected environmental sources. Vertical transmission has been shown in chickens, turkeys, and ducks. REV is not resistant in the environment.

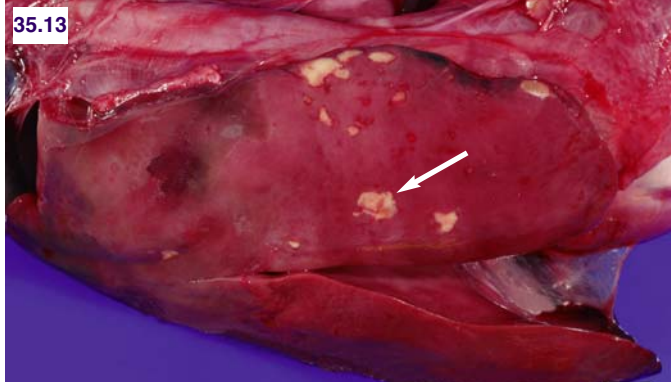
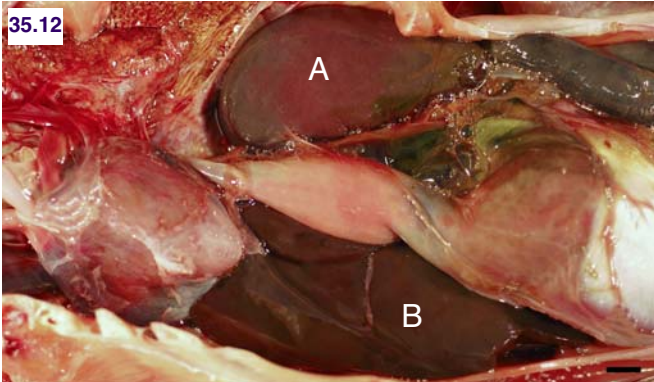
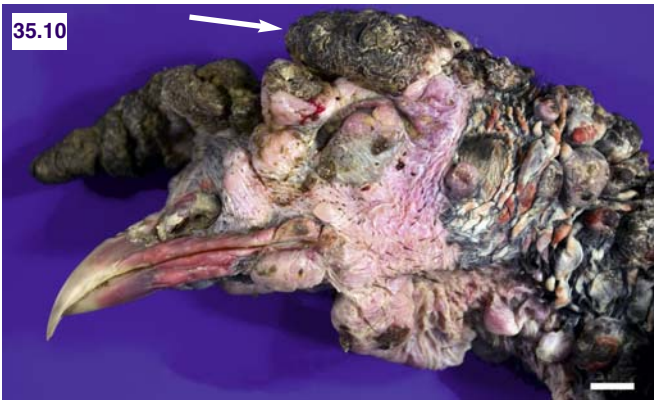


Fig.35.10, 35.11, 35.12 & 35.13: “Gross lesions in adult wild turkeys naturally-infected with LPDV. Fig.35.10: The unfeathered skin over much of the head and neck is covered by variably-sized, proliferative nodules, some of which contain superficial crusts (arrow); Fig.35.11: The skin over two digits and the plantar aspect of the foot is severely thickened with multiple folds and is covered by dark, dry crusts; Fig.35.12: The spleen (A) is markedly enlarged, a characteristic gross lesion also observed in domestic birds (B=liver); Fig.35.13 : The liver contains numerous, irregular, variably-sized pale foci, corresponding to aggregates of pleomorphic lymphoid cells (arrow). All scale bars=1.0 cm” (Courtesy of Virology, Allison et al, 2014, Copyright Elsevier).

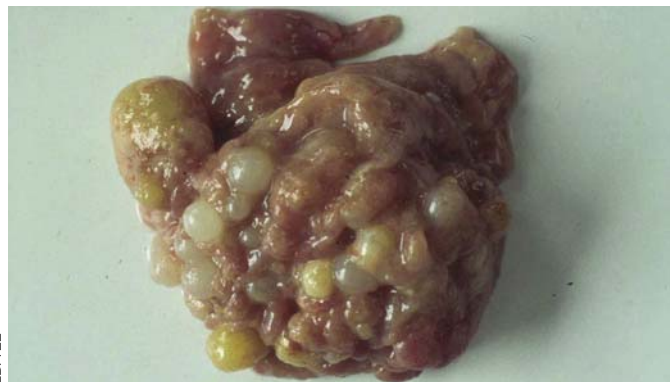
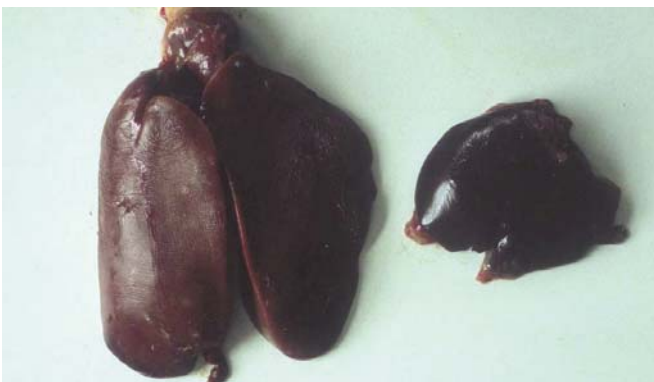
Fig.35.14 & 35.15: Lymphoproliferative disease (Turkey). Hepatomegaly and ovarian tumor. Compare affected liver with normal liver on the right of Fig.35.14.

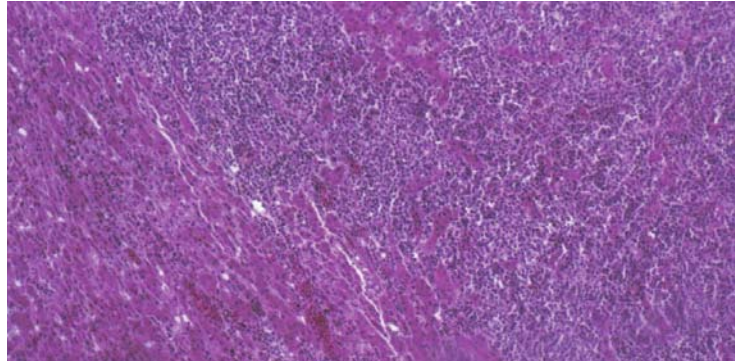
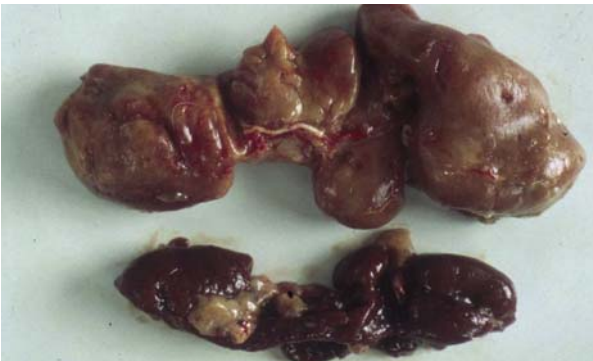

Fig.35.16: Lymphoproliferative disease (Turkey). Renal tumor. Compare the size of the affected kidney with normal kidney (bottom). Fig.35.17: Lymphoproliferative disease (Turkey). Histological examination of the liver allows to observe a tumoral lymphocytic infiltration.

Lymphoproliferative disease

LPDV has been shown to infect only wild and domestic turkeys. A report from the USA demonstrated a high level of genetic diversity between strains isolated from different states. But the disease has only been reported sporadically in the USA and in England, France, Austria, the Netherlands, and Israel. It is suspected that it is in other European countries as well. Horizontal transmission by direct contact has been proven. There is no evidence of vertical transmission to date. Field studies have demonstrated that the infection may be prevalent while disease remains sporadic. In fact, some flocks have been shown to be completely infected with no increase in the mortality rate. However, outbreaks with up to 25% mortality have been associated with the disease in 7-18-week-old flocks. Males may be more susceptible than females. As for REV, the LPDV virus is not resistant in the environment.

CLINICAL SIGNS

Reticuloendotheliosis

REV-induced syndromes in chickens can be similar to lymphoid leucosis and Marek's disease. Chickens with runting disease syndrome are much smaller than non affected birds and are pale. An abnormal wing feather development, with adhesion of the barbs to a section of the shaft, may be observed. Lameness or paralysis rarely occurs. Mortality is rare in commercial chicken broiler flocks but culling may be extensive, at times reaching half the flock by the end of production. Birds affected with chronic lymphomas are essentially depressed prior to death. This is also observed with LPDV, although sudden deaths are reported as well.

Lymphoproliferative disease

In domestic turkeys, disease due to LPDV infection is generally first noted around 8 to 10 weeks of age, with a flock mortality that can reach 25%.

LESIONS

Reticuloendotheliosis

In chickens, the runting disease syndrome results in stunted birds, atrophy of the thymus and bursa of Fabricius (although not always present in the field), occasionally enlarged

peripheral nerves, abnormal feathers, proventriculitis, enteritis, anemia, necrosis of the liver and spleen. Nerve enlargement may not be accompanied by other neoplastic lesions and may be marginal, with histopathology showing an infiltration of lymphocytes and plasma cells. Turkeys with chronic lymphomas have enlarged nerves and enteritis. Lymphoid infiltrations are also clearly visible in the liver (hepatomegaly), intestine, spleen (splenomegaly with focal lesions), and other visceral organs; lesions may be seen less frequently in the bursa of Fabricius. Humoral and cellular immunities are normally depressed. In the field, this is particularly noted with embryo- or vaccine-derived REV infections.

The chronic form of REV in ducks and geese is similar to what is described in chickens and turkeys.

Lymphoproliferative disease

Lesions appear two weeks post-infection first in the spleen and thymus. The most typical lesion is a splenomegaly with the spleen having a pale or marbled appearance. Gray-white tumor foci are noted in the liver, thymus, gonad, pancreas, kidney, intestine, lung, and heart. Peripheral nerves may be enlarged. Lymphoid cells, reticulum cells, and plasma cells are found in tumors. Bursa of Fabricius and thymus atrophy is noted by day 3 post-infection. A growth differential between infected and control chicks is seen by 6 days of age. Chronic neoplastic response takes longer in chickens (17-43 weeks post-infection), in turkeys (8-12 weeks with birds between 15 and 20 weeks of age), in goose (20 to 30 weeks of age), and in ducks (4-24 weeks).

DIAGNOSIS

Reticuloendotheliosis

The presence of REV antigen in infected cell culture can be demonstrated by using polyclonal or monoclonal antibodies, immunofluorescence, immunoperoxidase staining, complement fixation, or enzyme immunoassay. An indirect immunofluorescent assay and a polymerase chain reaction (PCR) are used on field samples. Indeed, PCR is recommended for rapid diagnosis of these viruses. A multiplex PCR is available for rapid differential diagnosis of avian oncogenic viruses and detection under field conditions.



Fig.35.18: Lymphoproliferative disease (Turkey). The most typical lesion is a splenomegaly. Compare affected spleen with normal spleens on right.

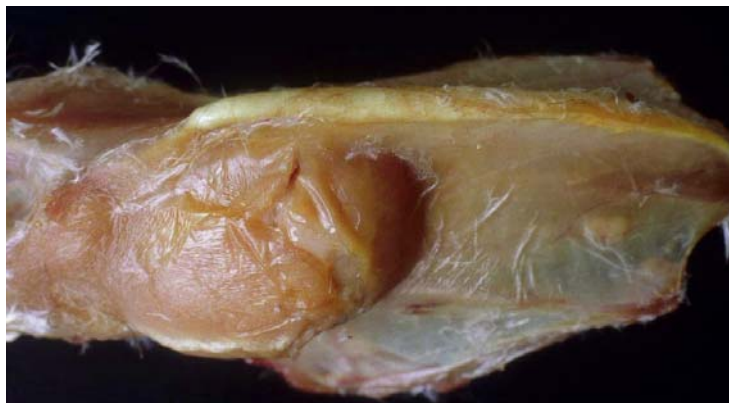

Fig.35.19: Sarcoma in the breast (Fowl).

Symptoms & lesions	Affected species	Main clinical signs & lesions	Etiology	Chap.	
RETROVIRUS	Leukoses	Chicken	Depression, pallor, nodular or diffuse tumors of liver, spleen, bursa and other organs; skeletal tissues; subclinical infection without neoplastic lesions: egg drop	Lymphoid leukosis (<i>Retrovirus ALV-A</i>)	II.34
		Chicken	Diffuse myeloid leukosis: pallor; liver and spleen enlarged and granular appearance of the liver; sometimes tumor of bursa; tumor infiltration of bone marrow; myeloblastic leukemia; other tumors (ovary, kidney, bursa)	Myeloid leukosis Myeloblastosis (<i>Retrovirus ALV-J</i>)	II.34
		Chicken	Tumoral form of myeloid leukosis: diffuse nodular tumors of creamy-white color; other tumors [ovary, kidney, thymus, surface of bones (sternum, ribs, skull)]	Myelocytomatosis (<i>Retrovirus ALV-J</i>)	II.34
		Chicken	Solid sheets of relatively immature myelocytes	Renal myelocytoma	II.34
		Chicken	Leukemia, malignant cells remaining within the blood vessels; erythrocytosis in liver, spleen, bone marrow; particular cherry-red coloration of liver and spleen; other tumors in kidney, sometimes hemorrhages in muscles	Erythroid leukosis (<i>Retrovirus ALV-J</i>)	II.34
	Related neoplasms	Chicken	Tumors (skin or visceral organs); blood-filled cystic masses or solid tumors	Renal hemangioma	II.34
		All species	Nephroblastoma, tubular adenoma, adenocarcinoma, etc.	Other renal tumors	
		Chicken, guinea-fowl, turkey	Abnormal growth of bone resulting in pericortical accumulation of immature bone	Osteopetrosis (<i>Retrovirus</i>)	II.34 IV.69
	Reticuloendotheliosis	Turkey, chicken, duck, geese	Runting; pallor; abnormal feather development; lameness; atrophy of thymus and bursa; enlarged peripheral nerves (marginal); proventriculitis, enteritis; hepatomegaly, splenomegaly; other tumors (gonad, pancreas, kidney, heart)	Reticuloendotheliosis (<i>Gammaretrovirus</i>)	II.35
	Lymphoproliferative disease	Turkey	8-10-week-old turkey; mortality (up to 25%); marble spleen enlarged; tumors (liver, thymus, gonad, pancreas, kidney, intestine, lung, heart)	Lymphoproliferative disease (<i>Retrovirus</i>)	II.35
HERPESVIRUS	Marek's disease	Chicken (turkey)	Depression, weight loss, diarrhea, diffuse or nodular lymphomas in visceral organs (liver, spleen, ovary, kidney, proventriculus, heart, bursa) and sometimes in skin (feathers follicles) and skeletal muscles	Marek's disease Acute form (<i>Very virulent Mardivirus</i>)	II.33

Tabl.35.1: Differential diagnosis of main tumoral infections in birds. Sarcomas and other sporadic connective tissue tumors can occur.

Serology

The best tests for detection of antibodies to REV are virus neutralization and immunoperoxidase plaque assay. Indirect immunofluorescence may also be used on serum and egg yolk. An indirect ELISA has also been developed. In susceptible chickens, antibodies may be detected two to three weeks post-infection. It may take several more weeks for chickens infected by direct contact with infected birds. Titers may decline with age, and tolerant birds rarely develop antibodies.

Lymphoproliferative disease

Diagnosis is based partly on gross and microscopic lesions. A persistent viremia can be detected in infected turkeys by a reverse transcriptase in the plasma or by enzyme immunoassays. The tumors are histologically different from those of reticuloendotheliosis. Antigen and antibody tests are available to differentiate this virus from the reticuloendotheliosis virus. A PCR has been developed to confirm the presence of the virus in the tumors. The plasma of infected turkeys is a good source of infective material.

Differential diagnosis

In chickens, REV lesions may be similar to Marek's disease and lymphoid leukosis. Note that mixed infections with other retroviruses are possible. Clinically, due to immunodepression, REV may also resemble infectious bursal disease or chicken infectious anemia. In turkeys, REV must be differentiated from LPDV and Marek's disease.

TREATMENT & CONTROL

There is no treatment for REV or LPDV. Because the infection with these viruses is relatively common in chickens and turkeys while disease is rare and self-limiting, nothing specific is recommended. Quality assurance programs for vaccine production, strict biosecurity measures, including a pest management program designed to limit insects suspected of spreading these viruses, are all useful. An eradication program developed for lymphoid leukosis would be effective in preventing egg transmission. A REV vaccine is in development, but has yet to be commercialized.

REFERENCES

- Allison AB et al. Avian oncogenesis induced by lymphoproliferative disease virus: A neglected or emerging retroviral pathogen? *Virology*, 2014,450-451:2-12.
- Brown J et al. Identification of lymphoproliferative disease virus in wild turkeys (*Meleagris gallopavo*) in the United States. *Proceedings of the 116th Annual Meeting of the United States Animal Health Association*. Greensboro, North Carolina October 18-24, 2012. Pp 97-98.
- Gopal S et al. Differential Detection of Avian Oncogenic Viruses in Poultry Layer Farms and Turkeys by Use of Multiplex PCR. *J Clin Microbiol*, 2012,50:2668-2673.
- Nair V. Neoplastic diseases. Chapter 15 in the 13th edition of *Diseases of Poultry*; Swayne DE et al editors; Wiley-Blackwell, Ames, Iowa, Pp 513-514.
- Nair V et al. Reticuloendotheliosis. Chapter 15 in the 13th edition of *Diseases of Poultry*; Swayne D.E. et al. editors; Wiley-Blackwell, Ames, Iowa: 593-604.
- Payne LN & Venugopal K. Neoplastic diseases: Marek's disease, avian leukosis and reticuloendotheliosis. *Rev sci tech Off Int Epiz*. 2000, 19: 544-564.

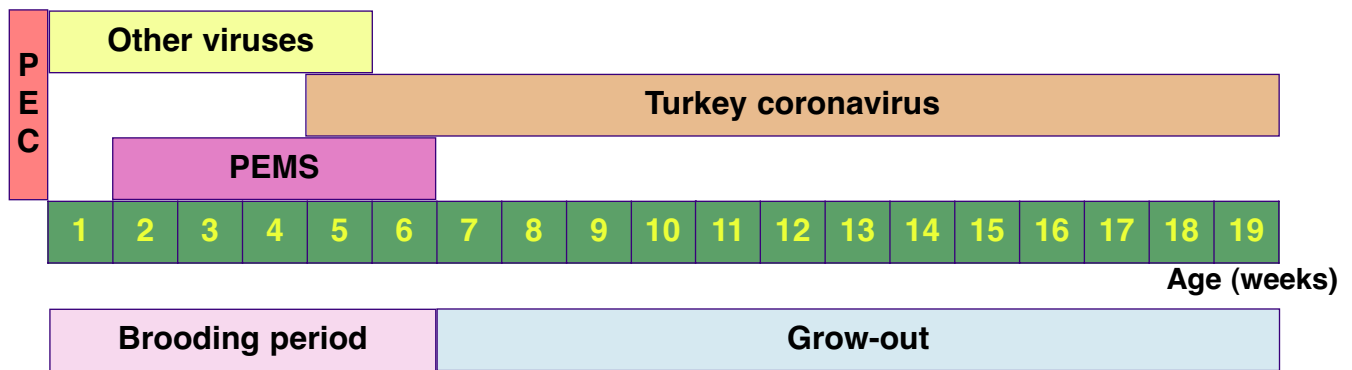


Fig.36.1: Age distribution of coronavirus infection. PEC = Poult enteritis complex; PEMS = Poult enteritis mortality syndrome.

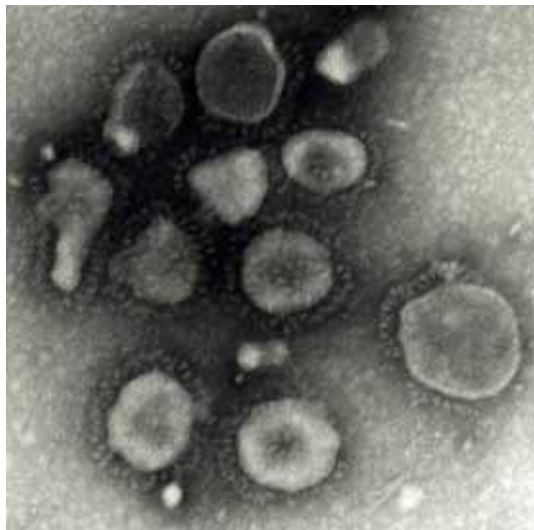


Fig.36.2: Turkey coronavirus (electron microscopy): coronavirus particles identified in intestinal contents of PEMS-affected turkey using negative-stain electron microscopy.



Fig.36.3: PEMS. Four week-old turkeys illustrating influence of PEMS on growth. Unaffected turkey is shown at left; PEMS-affected on right.

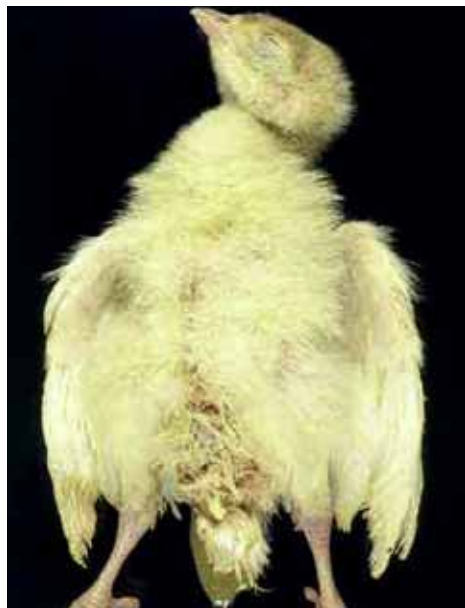

Fig.36.4: PEMS. Experimental infection in poulting (3 day post exposure). Note fecal staining of feathers and watery brown droppings leaking out the vent.

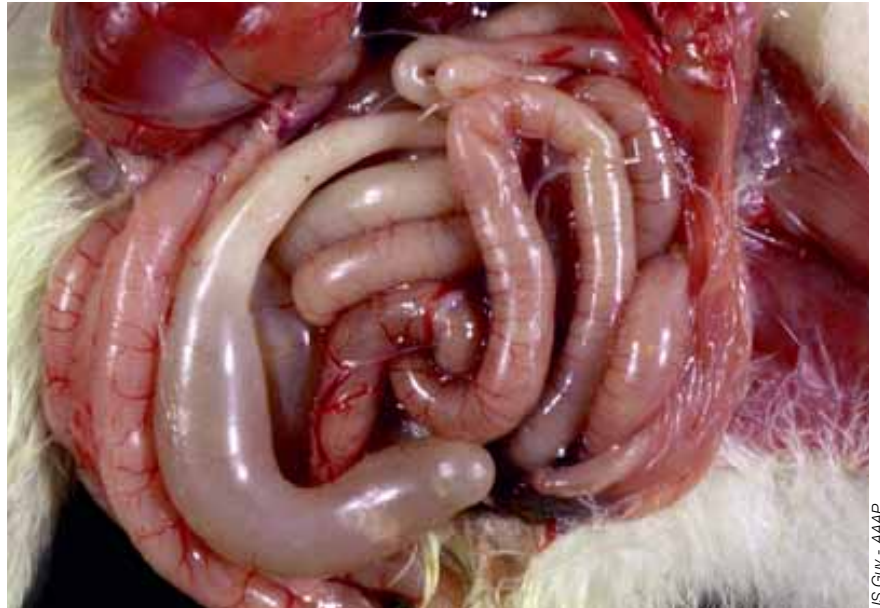

Fig.36.5: Intestines of PEMS-affected turkey. Note thinning and pallor of intestinal wall, and distention of intestines with fluid and gas.

Viral diseases

36. TURKEY CORONAVIRUS

INTRODUCTION

Turkey coronavirus (TCV) is the cause of an enteric disease in turkeys characterized by diarrhea, depression, anorexia and decreased weight gain. TCV is one of several viruses, including hemorrhagic enteritis virus, reovirus, and astrovirus that are responsible for enteric disease in turkeys. These viruses contribute to the poult enteritis complex (PEC), a term that encompasses the infectious intestinal diseases of young turkeys, which includes poult enteritis mortality syndrome or PEMS. TCV is considered a causal agent of PEMS when coupled with other pathogens such as certain strains of *Escherichia coli*.

Turkey coronavirus enteritis was first reported in 1951 in the state of Washington, USA. Severe economic losses were attributed to this disease in USA and Canada during the 1950s and 1960's; during this time the disease also was known as Bluecomb disease and mud fever. TCV enteritis continues to be a source of economic loss to turkey producers in the USA.

ETIOLOGY

Turkey coronavirus is a RNA virus within the *Coronaviridae* family affecting only turkeys. It was first recognized as the cause of the disease in 1973. Coronaviruses are enveloped pleomorphic particles that are nearly spherical. Their surface structure is characterized by widely spaced club-shaped peplomers that give the appearance of a crown (*corona* in latin, hence the name coronavirus). They are divided into three major antigenic groups. Turkey coronavirus is in group 3 with infectious bronchitis virus of chickens. Turkey coronaviruses are antigenically and genetically closely related. It is not known whether virulence differs between virus strains.

The virus replicates mainly in enterocytes in the jejunum, ileum, and in the epithelium of the bursa of Fabricius. In the intestines, the upper one-half to two thirds of intestinal villi are most affected; in the bursa of Fabricius, virus infection occurs primarily in follicular and interfollicular epithelium. Virus replication occurs in the cytoplasm.

Turkey coronavirus is relatively resistant in the environment. It is stable at pH 3 at 22°C for 30 minutes and can last at least one hour at 50°C. Chloroform treatment at 4°C for 10 minutes will

inactivate the virus; but it can survive over five years in intestinal tissues stored at -20°C or lower. This explains why it was shown to survive in the field during Minnesota winters long after infected turkeys were removed. But a recent study indicated that the virus should not survive more than 10 days at 22°C and no more than 40 days at around 4°C. Most disinfectants, given sufficient contact time with the virus (e.g., 10 to 20 minutes) can inactivate it; notably, saponified cresol, glutaraldehyde and formaldehyde.

EPIDEMIOLOGY

TCV is a highly infectious pathogen affecting turkeys of all ages. The incubation period is typically 2-3 days, but could be as long as 5 days. Although most cases occur during the grow-out period (i.e., after six weeks of age), clinical disease is most severe in younger birds. Turkeys are the only natural host. Although it has been shown that chickens are susceptible to TCV, resulting only in mild-to-inapparent infection, they are not known to be reservoirs of the virus. Turkey coronavirus has been reported in many commercial turkey producing regions in North America and Europe, as well as Brazil and Australia.

Turkey coronavirus is shed for several weeks in feces of infected birds, leading to horizontal transmission *via* used litter, equipment, live and dead birds, and people with contaminated clothing and footwear. Darkling beetle larvae and domestic house flies have been shown, under experimental conditions, to be mechanical vectors. Vermin and dogs can also serve as mechanical vectors. There is no evidence of vertical transmission.

Many risk factors have been associated with the incidence of the disease and severity of its expression; in particular, bird age (mainly between 2 and 6 weeks of age), high regional farm density (number of commercial turkey farms for a given area), multi-age turkey production sites, high bird density within a barn, and poor brooding conditions.

In the late 90's, at least 80% of the flocks diagnosed with PEMS in the western part of North Carolina were coronavirus positive. In eastern North Carolina, both coronaviruses and PEMS appeared to be less prevalent than in the west portion of the state (Tabl.36.1). This led many to suggest that coronavirus was the main causal agent

Flock status	Western North Carolina		Eastern North Carolina	
	Number of flocks	Percentage	Number of flocks	Percentage
PEMS positive ¹	39	78	17	59
PEMS negative	11	22	12	41
Total	50	100	29	100
Corona positive ²	35	70	5	17
Corona negative	15	30	24	83

Tabl.36.1: Distribution of Poulter Enteritis Mortality Syndrome (PEMS) and Coronavirus positive (Corona) flocks in Western and Eastern North Carolina in 1996. The data is shown considering the PEMS and Corona flock status separately.

¹ PEMS status based on the definition included in the text

² Corona status based on direct immunofluorescence test

	Western North Carolina		Eastern North Carolina	
	PEMS positive ¹	PEMS negative	PEMS positive ¹	PEMS negative
Corona positive ²	28 (80%)	7 (20%)	4 (80%)	1 (20%)
Corona negative	11 (73%)	4 (27%)	13 (54%)	11 (46%)
Fisher's exact test ³	p-value = 0.71		p-value = 0.37	

Tabl.36.2: Distribution of Poulter Enteritis Mortality Syndrome (PEMS) flock status according to their Coronavirus status by North Carolina region in 1996.

¹ PEMS status based on the definition included in the text

² Corona status based on direct immunofluorescence test

³ p-values from Fisher exact tests performed on the two 2x2 tables

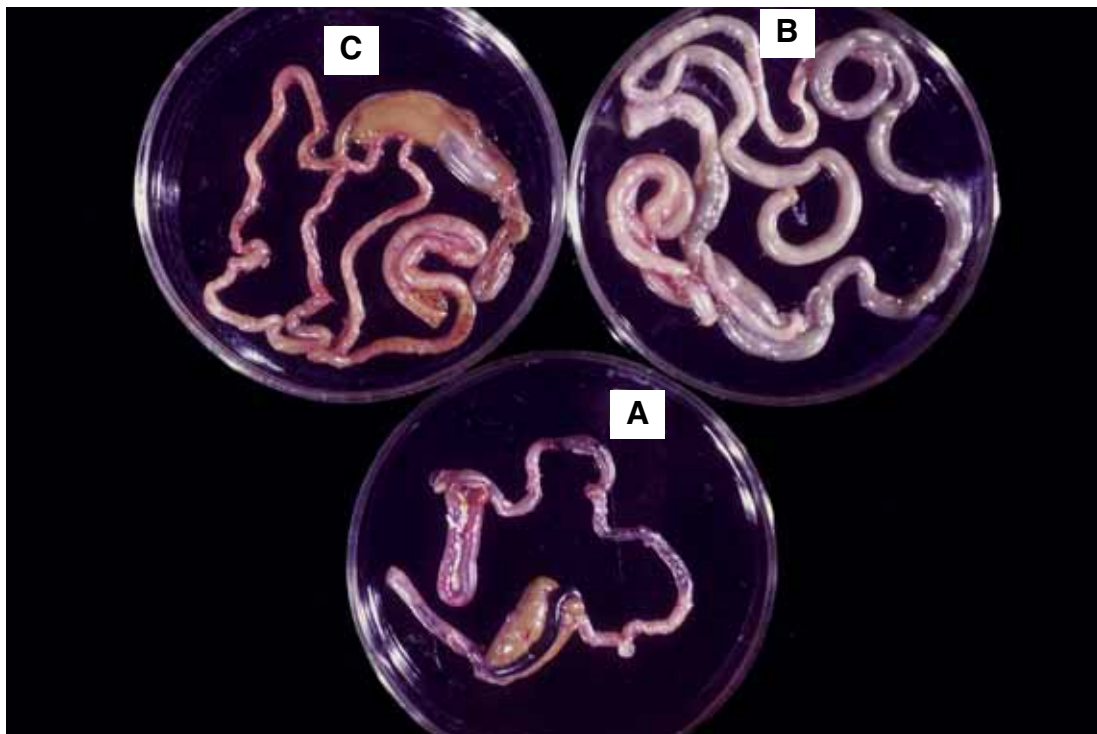

Fig.36.6: Turkey coronavirus. A: Severe enteritis; B: Normal intestine; C: Moderate enteritis.

HJ Barnes

responsible for PEMS. However, a comparison of PEMS positive and negative flocks showed that coronavirus could be almost as prevalent in PEMS-free flocks (Tabl.36.2).

CLINICAL SIGNS

Clinical signs generally occur suddenly with high morbidity in commercial flocks. Birds are noisy, depressed (a drop in feed and water consumption is obvious), and excessive mucus is noted in the droppings that are green to brown mixed with undigested feed. Reduced growth results in unevenness of the flock. Mortality will vary depending on age of the birds (< 6 weeks), concurrent infection, and management conditions (as low as less than 1%, but it may easily exceed 10% under inadequate rearing conditions and when other enteric pathogens are present). In breeders, a rapid drop in egg production and egg quality is noted. However, a flock may be infected without showing obvious clinical signs. The course of the disease in a flock generally is between 10 to 15 days. Flock unevenness (weight variation) may then be observed and will last until the end of production.

LESIONS

Gross lesions are found primarily in the intestinal tract and bursa of Fabricius. The duodenum, the jejunum and the ceca are filled with watery material and gas. The intestinal wall is thin and flaccid. Small petechial hemorrhages may be seen on the intestinal mucosa. Atrophy of the bursa of Fabricius may be noted. When chronically affected, birds will be emaciated and dehydrated (similar to PEMS cases).

Microscopically, a decrease in villous length, increase in crypt depth, and a decreased intestinal diameter are noted. There are less goblet cells and a moderate infiltration of the superficial and deep *lamina propria* with heterophils and lymphocytes. The normal columnar epithelium changes to a cuboidal epithelium with a loss of microvilli; these lesions may cause malabsorption and maldigestion resulting in the observed watery diarrhea. It is also believed that the virus may negatively affect the normal intestinal flora.

In the bursa of Fabricius changes in epithelial cells consist of necrosis and the normal pseudostratified columnar epithelium is replaced with a stratified columnar epithelium. A severe heterophilic inflammation is seen within and beneath the epithelium, with a moderate lymphoid atrophy of bursal follicles.

DIAGNOSIS

Several diagnostic tests are available. Laboratory diagnosis includes virus isolation, electron microscopy, serology, or detection of viral antigens or viral RNA in intestinal tissues, intestinal contents, or the bursa of Fabricius. RT-PCR is considered a very sensitive and specific diagnostic test. Samples should be kept cold (on ice at 4°C or frozen) at all times. Direct and indirect immunofluorescence tests for detection of viral antigen in tissues have been developed. Monoclonal antibodies specific for turkey coronavirus have also been produced to improve the detection of the virus in tissues and for development of an enzyme-linked immunosorbent assay (ELISA).

TCV enteritis must be distinguished from other enteric infections, including those associated with astrovirus, rotavirus, reovirus, *Salmonella* spp., and *Cryptosporidia* spp.

TREATMENT

Current intervention strategies have drug and management components. These are basically the same for PEMS and TCV.

Given the viral nature of PEMS and TCV, no “silver bullet” exists. Supportive care is needed at the early onset of clinical signs. This includes water soluble multiple vitamin preparations with vitamin E at twice the recommended level (because of its antioxidant properties, which help stabilize the intestinal villus epithelial cells); and water soluble antibiotherapy when elevated mortality is observed due to coinfection. Impression smears of the intestines should be performed to determine whether gram-positive or gram-negative bacteria are dominant. Once the disease is present, antibiotherapy may contain mortality but will not prevent morbidity. Palliative care is not complete without sustained efforts to optimize the environment. A slight increase of the ambient temperature (1-2°C) is often needed because the birds are chilled. Every effort should be made to keep the litter as dry as possible (using ventilation, tilling, top dressing with fresh litter if needed).

CONTROL

The best way to control TCV is to prevent its occurrence. Given its infectious nature, major efforts must go towards improving biosecurity (in particular, limiting movement of people from farm to farm). Since coronavirus is the principal pathogenic virus found with PEMS, and for

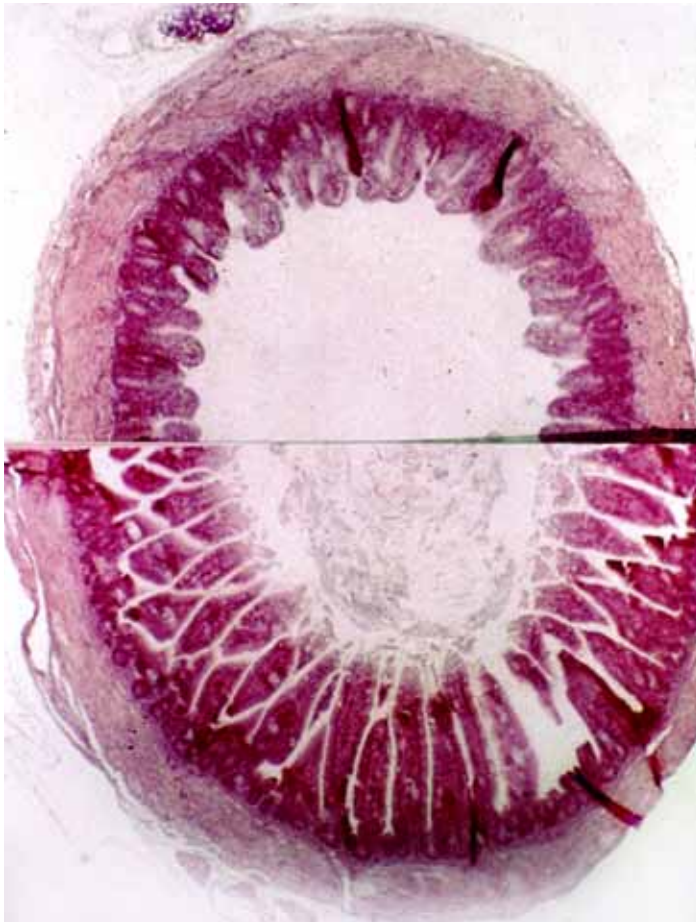

Fig.36.7: Turkey coronavirus. Microscopically, a decrease in villous length, increase in crypt depth, and a decreased intestinal diameter are noted. Compare the normal intestine (bottom) with the affected intestine (top).

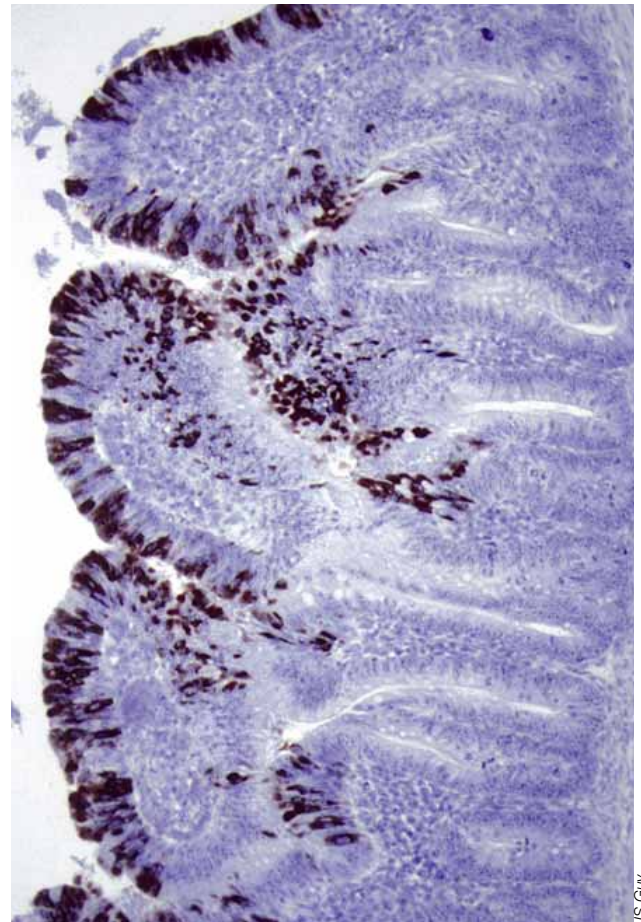


Fig.36.8: Turkey coronavirus. Immunohistochemical localization of TCV antigens in jejunum of TCV-infected turkey.

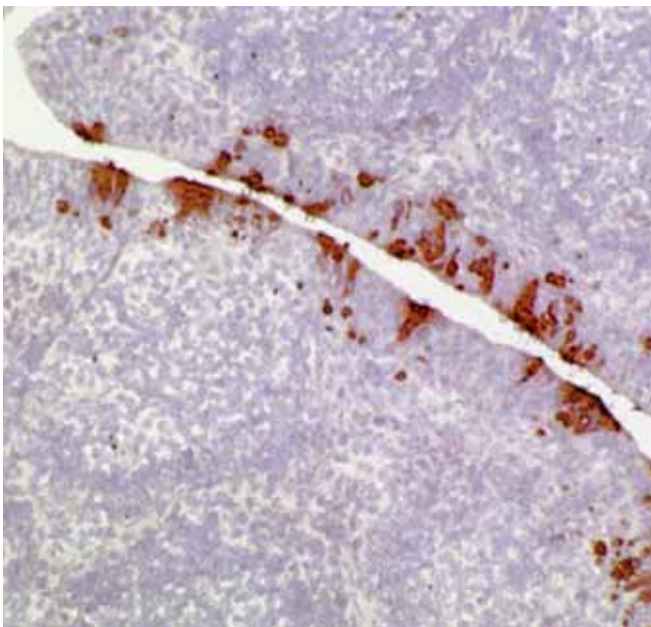


Fig.36.9: Indirect peroxidase test for coronavirus in bursal epithelium. Viral antigen is not present in the bursal lymphocytes.



Fig.36.10: Flock unevenness (weight variation) will last until the end of production.

which diagnostic tests exist, major efforts are being directed towards controlling and eradicating it (serological testing; depopulation of infected farms; all-in all-out production systems). Although research is being conducted on potential vaccines, there is little hope that TCV will be solved this way in the near future.

Depopulation following a TCV outbreak must be followed by a thorough house cleaning followed by vigorous washing [use a sprayer with a force of at least 30 kg-force/cm² (about 400 p.s.i.); > 700 p.s.i. or about 50 kg-force/cm² is best]. Disinfection of all surfaces in the barn is essential. Water sanitation is also important (see Chap.V.81 on water quality for details).

Finally, since darkling beetles and flies have been shown to be potential vectors of TCV, it is important to pay attention to the insecticide program during the downtime between the infected and the upcoming new flock. If a total downtime of two

weeks is normally recommended between two healthy flocks, it is best if the downtime following a TCV outbreak is extended for another two weeks. Essentially, it must be long enough to allow enough time for the extra efforts going into washing and disinfection and in order to make sure that the facilities get dry and stay dry for several days.

REFERENCES

- Guy JS. Turkey coronavirus enteritis. In: *Diseases of Poultry*, 12th ed., Y. M. Saif et al. Blackwell/Iowa State University Press, Ames, Iowa. 2008, pp. 330-338.
- Guy JS. Virus infections of the gastrointestinal tract of poultry: a review. *Poult Sci*, 1998,77:1166-1175.
- Jackwood M W & Guy JS. Turkey coronavirus. 2008. In: *Isolation and Identification of Avian Pathogens*, 5th ed., Am Assoc Avian Pathol, Athens, GA, 2008, pp. 150-152.

Virus	Taxonomy	Vector	Clinical signs in poultry
<i>Viruses that cause disease in birds</i>			
Highlands J	Family <i>Togaviridae</i> Genus <i>Alphavirus</i>	Mosquitoes (and <i>via</i> semen)	Weakness, decreased egg production, high mortality in young turkeys
Turkey meningo-encephalitis	Family <i>Flaviviridae</i> Genus <i>Flavivirus</i>	Mosquitoes	Nervous clinical signs in turkeys older than 10 weeks and decrease in egg laying rate
Tembusu virus	Family <i>Flaviviridae</i> Genus <i>Flavivirus</i>	Mosquitoes	Acute infection in ducks sharp drop in egg production
Turlock-like Bunyavirus	Family <i>Bunyaviridae</i> Genus <i>Bunyavirus</i>	Mosquitoes	Rare - cases observed in an ostrich chick
<i>Virus that cause disease in birds and humans</i>			
Eastern equine encephalitis	Family <i>Togaviridae</i> Genus <i>Alphavirus</i>	Mosquitoes : <i>Culiseta melanura</i>	Nervous symptoms and high mortality in pheasants, partridges and ducks
Western equine encephalitis	Family <i>Togaviridae</i> Genus <i>Alphavirus</i>	Mosquitoes	Rare - nervous symptoms in turkeys, pheasants and partridges
Venezuelan equine encephalitis	Family <i>Togaviridae</i> Genus <i>Alphavirus</i>	Mosquitoes	None in poultry?
West Nile virus	Famille <i>Flaviviridae</i> Genus <i>Flavivirus</i>	Mosquitoes	Infects many species of wild and domestic birds (geese and pigeons in particular)
Usutu virus	Family <i>Flaviviridae</i> Genus <i>Flavivirus</i>	Mosquitoes	Infects many species of wild birds. Human contamination exceptional
<i>Viruses that infect birds and cause disease in humans</i>			
Crimean-Congo hemorrhagic fever	Family <i>Bunyaviridae</i> Genus <i>Nairovirus</i>	Ticks (<i>Hyalomma</i> spp.)	Infections reported in ostriches, chickens and guinea fowl
Japanese encephalitis	Family <i>Flaviviridae</i> Genus <i>Flavivirus</i>	Mosquitoes	Wild birds (<i>Ardeidae</i>)
St. Louis encephalitis	Family <i>Flaviviridae</i> Genus <i>Flavivirus</i>	Mosquitoes	Sparrows and pigeons especially suspected

Tab.37.1: Arboviruses infecting domestic poultry and wild birds (*adapted from Capua, 2008*).

More than 500 arboviruses are known but only 130 are pathogens belonging to a dozen different families. Among these viruses, only six have been identified as causes of disease in domestic poultry and farm reared game birds: Eastern equine encephalitis (EEE) virus, Western equine encephalitis (WEE), Highlands J (HJ), West Nile (WN) virus, meningoencephalitis virus of turkey, Israel-turkey meningoencephalitis (IT) virus and a bunyavirus Turlock-like.

Many other viruses can infect wild birds and sometimes pose a risk to humans; for example, the virus of Venezuelan equine encephalitis (*Alphavirus*) encountered in the American tropics, the Japanese encephalitis virus (*Flavivirus*) endemic in Asia, the virus of Crimean-Congo (*Nairovirus*) or Usutu virus (*Flavivirus* of South African origin very close to the West Nile virus), which has emerged in Europe since the first description of an abnormal mortality among blackbirds in Vienna (Austria) in 1996. All these virus are RNA viruses.

Viral diseases

37. ARBOVIRUS INFECTIONS

INTRODUCTION

The term arbovirus, abbreviation for "arthropod-borne-virus", is used to describe all the viruses that share a common property, that of being transmitted through hematophagous arthropods (ticks, mosquitoes, sandflies, culicoides). In nature, arboviruses are able to multiply in the infected arthropod or live without compromising their fertility. They are transmitted by the bite of infected arthropod receptive to vertebrates, causing early and transient viremia. This results in a complex cycle between viruses, arthropod vector and vertebrate host. Vertebrates are then either amplifiers and disseminators of viruses or accidental hosts or epidemiological dead ends.

Arthropod activity is intense during the hot and humid months. Arbovirus infections are seasonal illnesses, especially in tropical and sub-tropical regions, caused by a very heterogeneous group of viruses.

ALPHAVIRUS

Eastern equine encephalitis (EEE) virus, Western equine encephalitis (WEE) virus and Highlands J (HJ) virus are found mainly on the American continent. EEE and WEE are zoonoses. They can cause in humans severe encephalitis which can progress to paralysis, convulsions, coma and death. The mortality rate of EEE virus in humans is 50-75%. Survivors often retain permanent neurological sequelae. Western equine encephalitis virus is less severe. Most infections are not associated with clinical disease in humans. The primary host affected by EEE or WEE, as the name suggests, is the horse, in which there is severe encephalitis.

Eastern equine encephalitis

The virus is transmitted from bird to bird by an ornithophilic mosquito (*Culiseta melanura*). Humans and horses are accidental hosts. In this case, the transmission is due to other mosquito species. In birds, the first outbreaks were diagnosed in pheasants. Outbreaks in pigeons, partridges, turkeys and ducks have also been described. Episodes of clinical disease in chickens and quail were not recorded, but the two species are extremely sensitive to experimental infection.

The occurrence of infection in flocks is always due to the contamination of a small number of birds by the bite of infected mosquitoes. Spread within the farm can be linked to cannibalism, pecking, or even during artificial insemination of females, since the sperm may be contagious. Poultry generally have neurological disorders by central nervous system involvement. There are sometimes visceral infections.

Western equine encephalitis & Highlands J virus

These two alphaviruses are very close genetically. Western equine encephalitis virus is responsible for sporadic disease in poultry. Cases have been reported in turkeys, pheasants and partridges. Turkeys experience high mortality due to encephalitis associated with the following clinical signs: drowsiness, tremors and leg paralysis. In turkey breeders, egg production suddenly drops and eggs become small, white even without shell.

The Highlands J virus was identified for the first time in a blue jay and then in partridges. It causes drowsiness, ruffled feathers and recumbency prior to death. The lesions are mainly encephalitis and myocardial necrosis. In turkey breeders, a very important drop in egg production is observed. In young turkeys, this virus is responsible for high mortality.

FLAVIVIRUS

Birds are the primary hosts of several flaviviruses. With some flaviviruses, birds are healthy carriers, which may facilitate human infections (Japanese encephalitis virus or St. Louis encephalitis). Other flaviviruses [West Nile (WN) virus and turkey meningoencephalitis virus] rarely affect domestic poultry, but can still cause significant economic losses.

West Nile virus

This virus was primarily known in Europe, Asia and Africa, where it is endemic. It became especially well known in 1999, when it appeared for the first time on the American continent. The epidemic

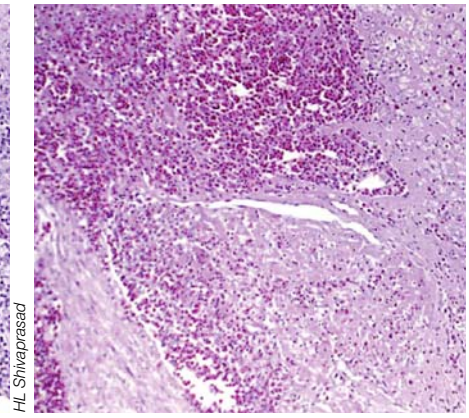
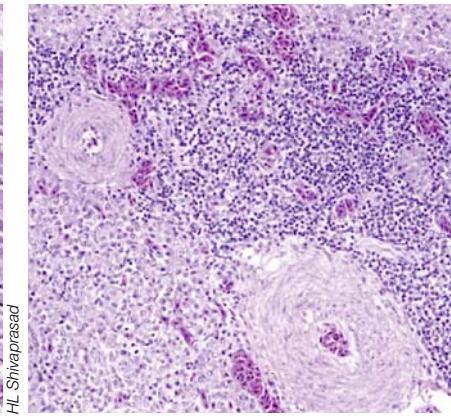
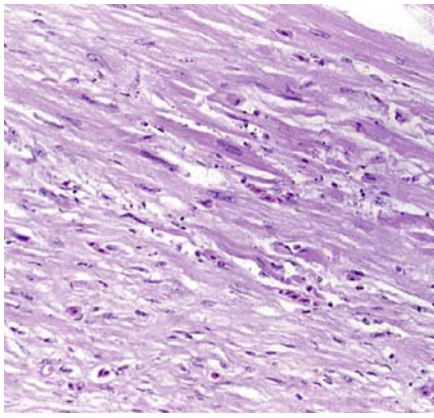


Fig.37.1, 37.2 & 37.3: Western equine encephalitis virus. Lesions of encephalitis (Emu).

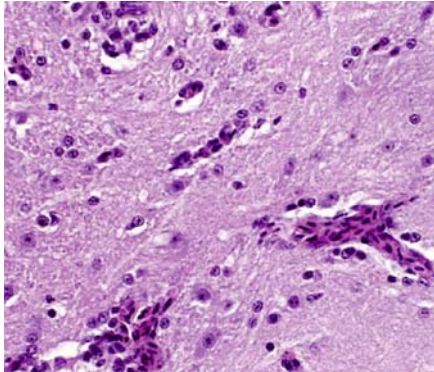


Fig.37.4: Western equine encephalitis virus (Pigeon).

Fig.37.5 & 37.6: West Nile virus disease (Geese). Clinical features of encephalitis accompanied by paresis or paralysis.

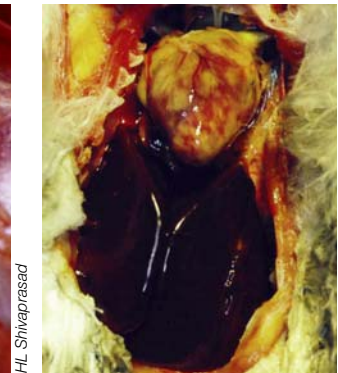
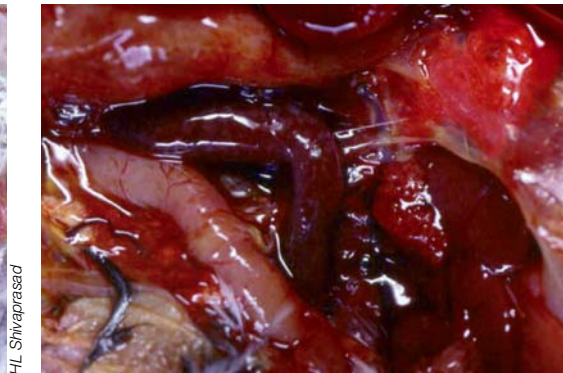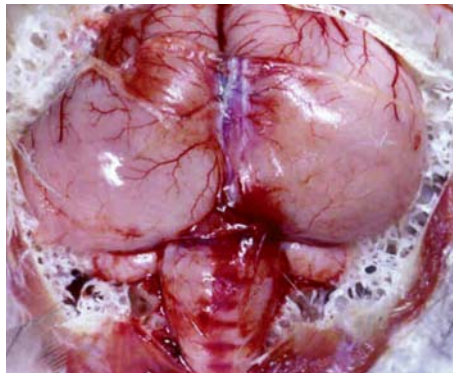


Fig.37.7 & 37.8: West Nile virus disease (Crow). Hemorrhagic lesions of the brain and the digestive tract.

Fig.37.9: West Nile virus disease (Goshawk). Hemorrhagic lesions of the heart and liver.

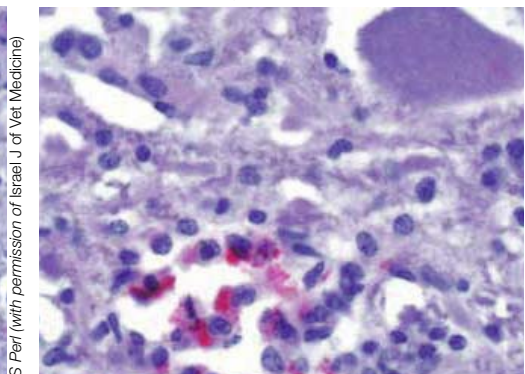
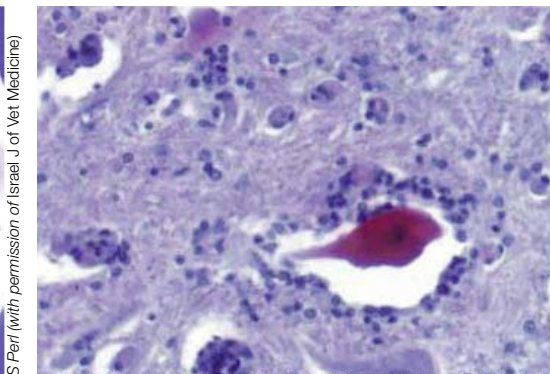
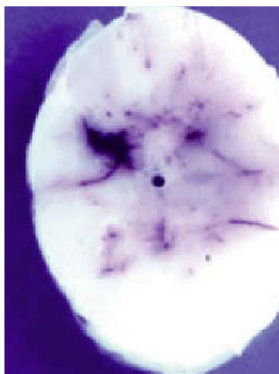


Fig.37.10, 37.11 & 37.12: West Nile virus disease (horse spinal cord). Nerve lesions in the spinal cord in horses are similar to those observed in birds and help to understand the clinical signs of paresis observed. Fig.37.10: Multifocal and diffuse hemorrhages in the gray matter. Fig.37.11: Gliosis and immunohistochemical staining of West Nile viral antigen in the cytoplasm of a neuron (x20). Fig.37.12: immunoperoxidase staining of West Nile viral antigen in the cytoplasm of glial cells (x40).

since then has been dramatic for humans, horses and birds. The disease is generally observed in summer and autumn. The virus is mainly transmitted by mosquitoes (*Culex*), but can also be transmitted by some ticks.

West Nile virus has a wide host range, replicating in birds, reptiles, amphibians, mammals, mosquitoes and ticks.

In geese

In Israel, for the first time in 1997, clinical signs of fatal encephalitis have been observed in several farms of young geese. Since then, similar observations have been reported in Canada, Hungary and the United States. Clinical signs include loss of equilibrium, apathy, torticollis, opisthotonos and pendulum movement of the head. Young geese fall on one side, often pedaling before dying. Morbidity and mortality are variable.

Geese are more susceptible between three and eight weeks of age, although clinical cases have been described until the age of 12 weeks. Older geese usually do not develop clinical signs but elevated antibody levels demonstrate that they have been infected.

The relatively prolonged period of viremia (several days before the onset of clinical signs) and the very high viral load promote the infection of mosquitoes and the spread of the virus to other hosts (horses, birds or humans).

In other domestic birds

Infection of chickens or turkeys is usually asymptomatic. The short duration of viremia associated with a low viral titer does not allow spread by mosquitoes.

In wild birds

A multitude of bird species (over 110 species) is susceptible to infection. In general, many species are resistant to infection but may act as a reservoir.

Turkey meningoencephalitis

This condition was described for the first time in a turkey farm in 1958 in the coastal plain of Israel. In 1978, the virus was isolated in South Africa, the only other country that has officially reported the disease. This *Flavivirus* is now classified in serogroup Ntaya. The turkey is the only species known

to be naturally infected to date. Very young chicks and Japanese quail are susceptible to the virus. Unlike geese, ducks, chickens and pigeons are resistant to infection. The virus is transmitted by some mosquitoes (*Aedes* and *Culex* spp.) and *Culiscoïdes*. Epidemics are observed between August and December.

The disease appears in turkeys older than 10 weeks and is characterized by progressive paralysis with a mortality rate of about 15-30%, but that may reach 80%. The main signs include paresis, incoordination, paralysis of the wings and greenish diarrhea. In layers, reduced egg production is significant.

Tembusu virus

Tembusu virus is a *Flavivirus* of the Ntaya virus group. Tembusu virus infection leads to an acute disease of ducks, characterized by a sudden onset and quick spreading through the flock. A severe drop in egg production is observed with a degeneration of the ovary with hemorrhagic lesions. The disease is of significant economic importance to egg-laying and breeder duck farms (see Chap. VI.92).

TURLOCK-LIKE BUNYAVIRUS OF THE OSTRICH

Ostriches may be asymptomatic carriers of the Crimean-Congo hemorrhagic fever bunyavirus transmitted by ticks or by contact with infected animals. Fatal human cases associated with ostrich farms have been reported in South Africa.

Only one case of a Turlock-like bunyavirus causing encephalomyelitis and myocarditis in an ostrich chick has been reported in North America.

DIAGNOSIS

In the absence of treatment for these viral infections, it is important to identify these different arboviruses, particularly when there is a risk of zoonosis.

Alphavirus

Alphaviruses can be isolated from blood or from different organs (brain, spleen, liver, heart) using different methods: intracerebral injection of newborn mice, subcutaneous or intramuscular inoculation of day-old chicks, intravitellus inoculation of chicken embryos older than 7 days and/or inoculation of cell

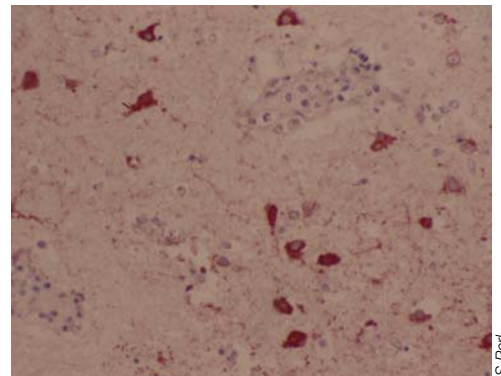
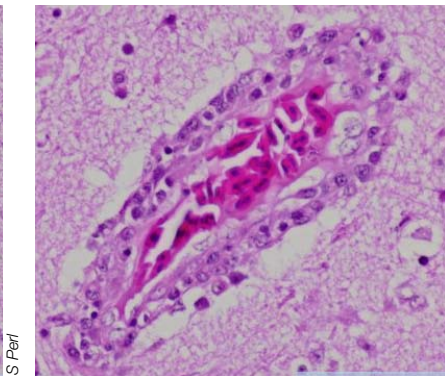
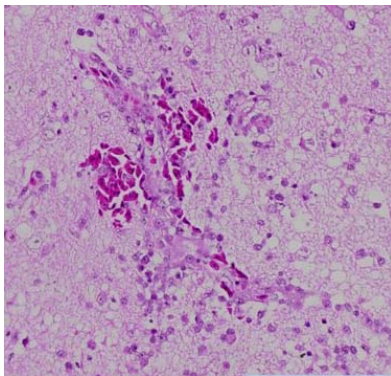


Fig.37.13 & 37.14: West Nile disease (Goose). Brain: swelling of the endothelium, multifocal hemorrhages and gliosis (x 20) (left). Perivascular lymphocytic cuff (x 40) (right).

Fig.37.15: West Nile virus disease (Goose); demonstration of viral antigen by immunohistochemistry in the brain (x 20).

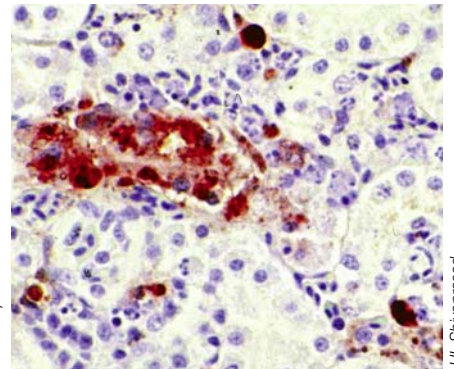
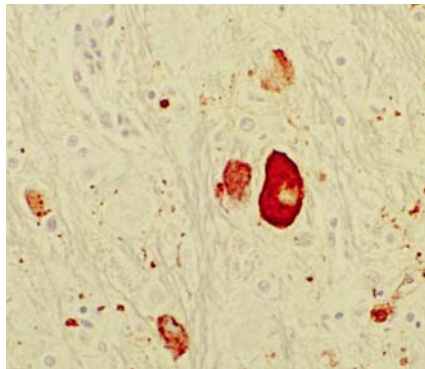
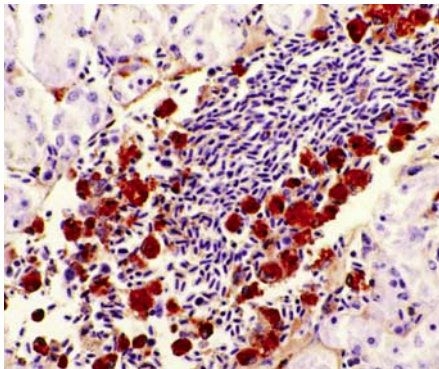


Fig.37.16, 37.17 & 37.18: West Nile virus disease. Encephalitis and immunoperoxidase staining of West Nile viral antigen in a sparrow (Fig.37.16) and in a psittacine (Fig.37.17 & 37.18).



Fig.37.19, 37.20 & 37.21: Turkey meningoencephalitis. Affected turkeys. Note flaccid paralysis of the wings.

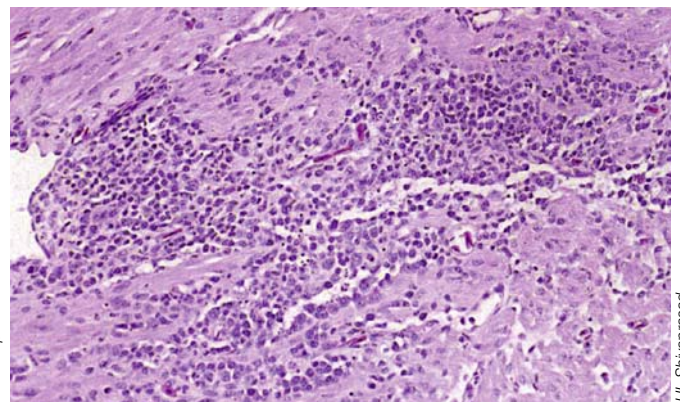
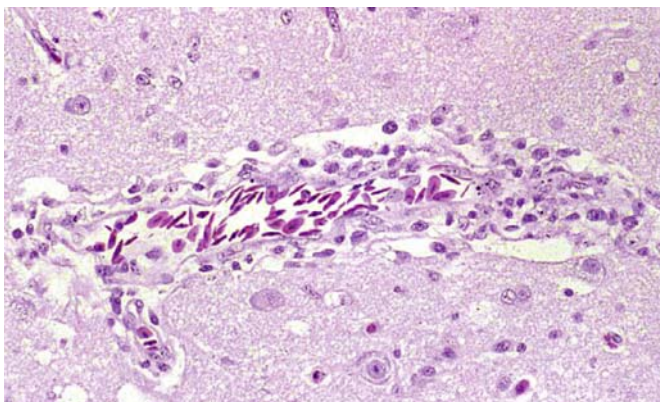


Fig.37.22 & 37.23: Infection by a Turlock-like bunyavirus in an ostrich chick. Encephalomyelitis (left) and myocarditis (right).

culture (Vero, BHK-21 cells and primary cultures of duck or chicken embryos, highly sensitive). Generally, mice and day-old chicks die in 2-5 days from encephalitis. Chicken embryos die in 18 to 72h and have a hemorrhagic appearance. Cytotoxic effects are observed in 24-48 hours in cell cultures.

Identification of the virus is usually performed by virus neutralization (VN), complement fixation or ELISA tests. The antigen or viral RNA can also be detected by immunohistochemical test or by RT-PCR (reverse transcriptase-polymerase chain reaction).

Serological tests available are VN, hemagglutination inhibition (HI), ELISA and complement fixation.

West Nile virus

Samples for isolation of West Nile virus may be obtained from the brain, spleen and kidneys. The virus is inoculated by the intracranial route to mice aged from one to two days or in the vitellus of seven-day-old chicken embryos. The mice develop ataxia in four to seven days; chick and chicken embryos die in two to six days. Tissue cultures are also used for virus isolation. They develop a cytotoxic effect in 48 to 72 hours and identification is then performed using antibodies revealed by immunofluorescence. The use of RT-PCR allows for an accurate and rapid diagnosis.

Two serological tests are available: hemagglutination inhibition assay and ELISA.

Turkey meningoencephalitis

The best diagnostic procedure is the isolation of virus from the brain, spleen or blood of infected turkeys, either by intravitellus inoculation of 7 day-old chicken embryos or by the intracranial inoculation to mice aged two to three days. Chicken embryos die in three to four days and are a very characteristic cherry-red color. Mice develop

flaccid paralysis in five to six days. A rapid diagnosis can be achieved by using RT-PCR.

Serological tests are the hemagglutination inhibition assay and VN.

CONTROL

Vector control

Due to the risk of zoonosis for some of these viruses, it is important to implement measures to control vectors to prevent the occurrence and spread of arboviruses. Such measures will include the reduction of vector habitats with changes in the environment and the use of pesticides.

Vaccination

A vaccine developed against Eastern equine encephalitis for horses has been tested in pheasants, but its efficacy has yet to be validated.

An inactivated vaccine produced from extracts of mouse brain provides an excellent protection against West Nile virus.

Turkey meningoencephalitis is controlled by vaccination, although there is a risk of post-vaccinal encephalitis.

REFERENCES

- Capua I. Arthropod-borne viruses. In "*Poultry diseases*" sixth edition, Ed Pattison M et al. Saunders Elsevier pp 415-425.
- Guy JS & Malkinson M. Arbovirus Infections, In *Diseases of poultry*, Ed. Saif YM, 12th ed., Blackwell Publ. 2008, pp 414-422.
- Perl S et al. West Nile virus encephalitis in horses in Israel. *Israel J Vet Med*, 2002, 57:65-69.
- Shivaprasad HL et al. Turlock-like bunyavirus associated with encephalomyelitis and myocarditis in an ostrich chick. *J Vet Diagn Invest*, 2002, 14:363-370.

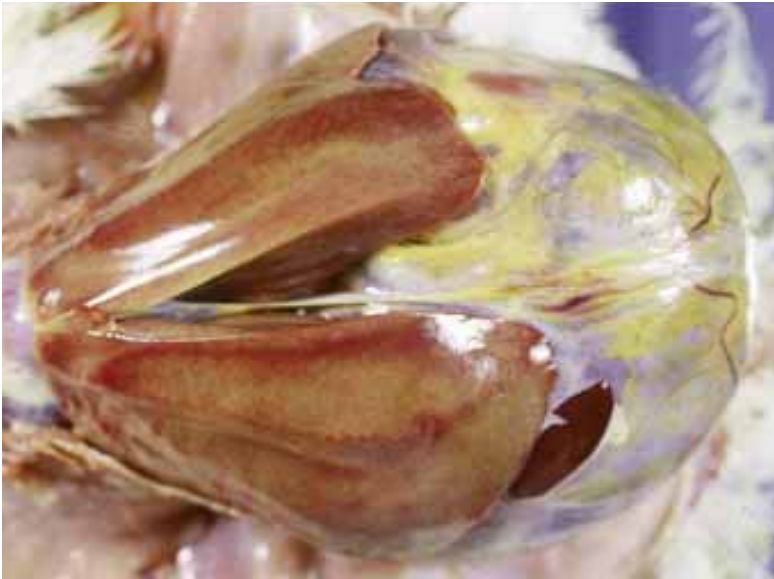

Fig.38.1: Liver hemorrhage in adult layer due to hepatitis E virus.

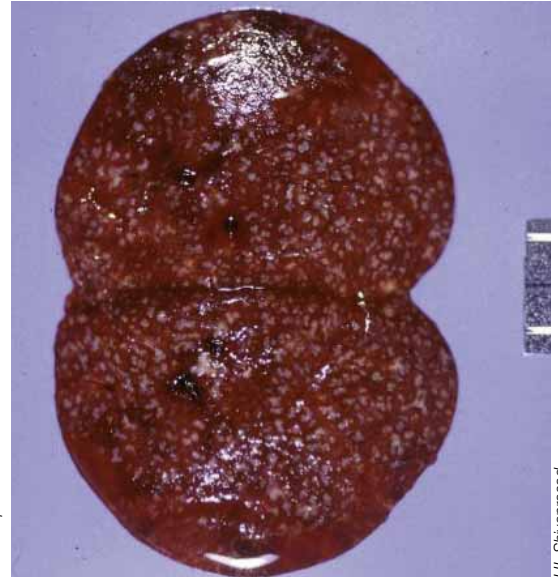


Fig.38.2: Affected spleen enlarged and showing mottled white on cut surface.

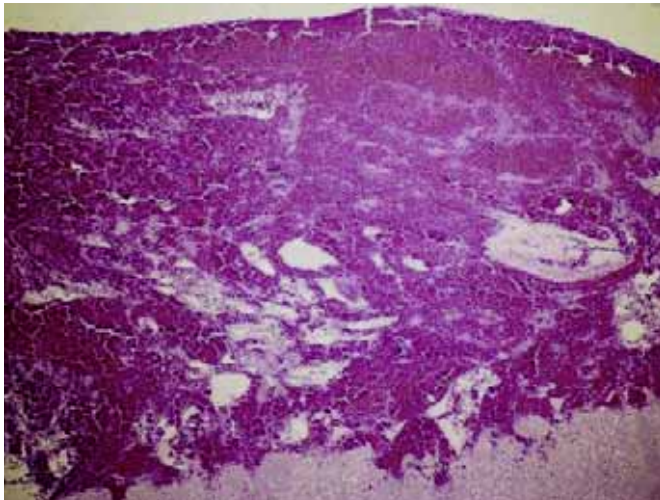


Fig.38.3: Photomicrograph of liver with severe subcapsular hemorrhage.

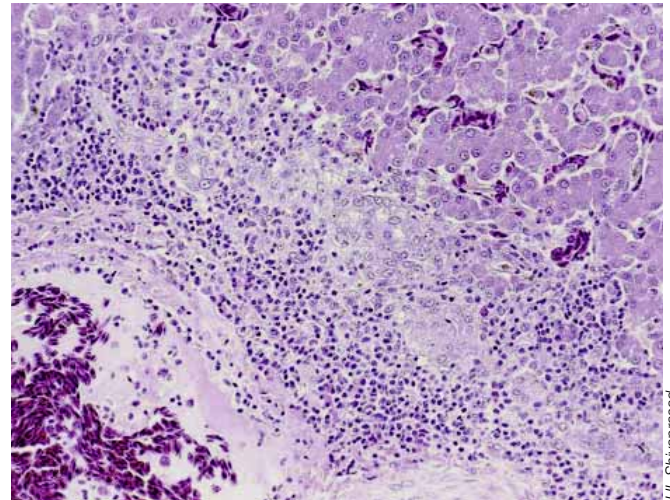


Fig.38.4: Liver with severe periportal hepatitis, vasculitis and mild biliary hyperplasia in an adult broiler chicken.

INTRODUCTION

Hepatitis-splenomegaly (HS) syndrome is a disease of both layer and broiler-type chickens characterized by increased mortality and decreased egg production caused by the Hepatitis E virus. Dead birds have hemorrhagic livers, with clotted blood around the liver or abdominal cavity and splenomegaly. The disease has been seen in the USA, Australia, Canada, Europe, and China and is also probably present in other parts of the world.

ETIOLOGY & EPIDEMIOLOGY

HS is primarily caused by Hepatitis E virus (HEV) distantly related (58 to 61% with the helicase gene) to human and swine Hepatitis E viruses. Hepatitis

E virus is a spherical, non-enveloped, symmetrical virus of about 32-34 nm in diameter. It is a single-stranded, positive sense RNA virus that has been placed in a new family *Hepeviridae* and genus *Hepevirus*. There are genetic differences among various isolates of Avian HEV isolated from different geographic regions such as Australia, the USA and Europe. Avian HEV has also been isolated apparently from clinically normal chickens.

HS syndrome was first reported in Western Canada in 1991, and since then has been recognized in the United States, Australia and Europe. The disease has been called by many names in the US and Canada: weeping liver disease, necrohemorrhagic hepatitis, necrotic hemorrhagic hepatosplenomegaly syndrome, chronic fulminating cholangiohepatitis and

38. HEPATITIS-SPLENOMEGALY SYNDROME

necrotic hemorrhagic hepatitis splenomegaly syndrome. In Australia, the disease is called Big Liver and Spleen (BLS) disease.

It has been determined that there is a 79% nucleotide sequence (in the helicase gene) similarity between avian Hepatitis E viruses that cause HS and BLS. The syndrome is most common in laying hens between 30 and 72 weeks of age, with the highest incidence occurring between 40 and 50 weeks of age. Leghorn hens in cages are typically affected and on some farms HS frequently reoccurs. The disease is endemic in chicken flocks in the US. Serological studies in the US revealed that 71% of the flocks and 30% of chickens are positive for avian HEV antibodies. About 17% of chickens less than 18 weeks of age and about 36% of adult chickens are positive for avian HEV antibodies. Antibodies to BLS have also been demonstrated in chickens in the US. Transmission of Avian HEV appears to be by fecal-oral, but experimentally the disease has been reproduced by oronasal route of inoculation. In the field transmission occurs readily within and between chicken flocks. Embryonic chicken eggs can be infected by the intravenous route.

CLINICAL SIGNS & LESIONS

Clinical signs due to HS are non specific and consist of anorexia, depression, pale combs and wattles and soiled vents. Some birds can die suddenly without exhibiting any clinical signs. Birds that die from HS are generally in good body condition but may have pale combs and wattles. The morbidity and mortality in the field can be low. Mortality can be 1% per week lasting for 3 to 4 weeks. Egg production drops are above normal, but can be significant in some affected flocks, as high as 20%. In broiler chickens small eggs with thin and poorly pigmented shells can be observed.

Reported gross lesions include clotted blood in the abdominal cavity and/or on the livers, as well as red fluid within the abdominal cavity. Livers can be enlarged, friable, and stippled with pale white, red or tan foci. Subcapsular hematomas can be seen occasionally in the liver. Spleens can be severely

enlarged and pale. Ovaries are often regressing. Microscopically, liver lesions range from multifocal to extensive hepatic necrosis and hemorrhage, with infiltration of mononuclear inflammatory cells around portal triads. Infiltration of lymphocytes in and around the blood vessels in the liver is a characteristic lesion of this syndrome. Microscopic lesions in the spleen include lymphoid depletion, hyperplasia of mononuclear phagocytic system cells and the accumulation of eosinophilic material in and around small arteries and in the interstitium of the vascular sinuses. Similar eosinophilic material can also be present in the interstitium of the liver. This material is usually positive for amyloid using Congo red stain.

DIAGNOSIS

A presumptive diagnosis can be made based on clinical signs, mortality patterns combined with gross and microscopic lesions. However, gross lesions of HS can appear similar to hemorrhagic fatty liver syndrome (HFLS) of chickens. With HS syndrome the livers tend not to be fatty both grossly and microscopically and amyloidosis is not seen with HFLS. Virus can be isolated in chicken egg embryos by inoculation through intravenous route but it is not practical as this method is difficult and many embryos may die by this technique. Negative stain electron microscopy to detect 30 to 35 nm virus particles in the bile or the feces in chickens suffering from HS syndrome can also be used. Immunohistochemistry (IHC) on tissues can also be used for diagnosis. Serology by ELISA and AGID are other methods that can be used for diagnosis of HS. Currently, the diagnosis of avian HEV is made primarily based on the detection of virus RNA by RT-PCR either in the feces or liver samples.

CONTROL & TREATMENT

Biosecurity implementation may help limit the spread of the virus. Currently there is no treatment available to control HS. One study suggested that immunization of chickens with avian HEV recombinant ORF2 capsid protein with aluminum as adjuvant can induce protective immunity against avian HEV infection.

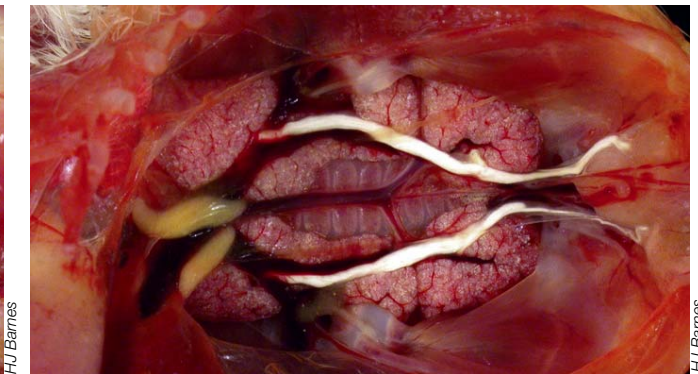
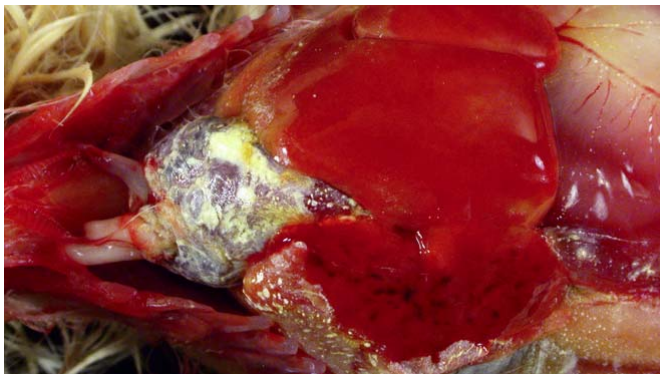


Fig.39.1 & 39.2: In avian nephritis due to astrovirus, affected chicks may show enlarged and pale kidneys and visceral urate deposition over the heart (left) and the kidneys and ureters (right) like in this 4-day-old chick.

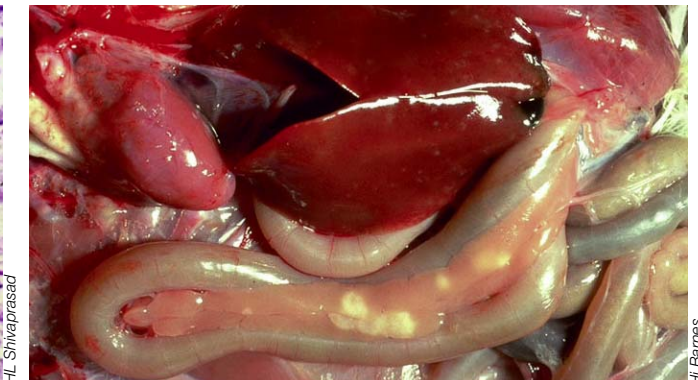
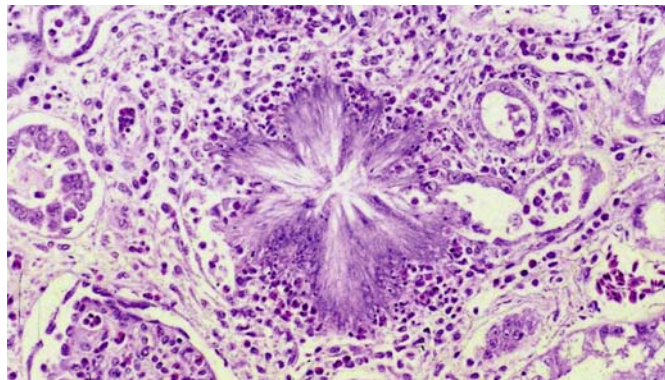


Fig.39.3: In visceral urate deposition, *tophi* formation can be observed in kidney but also in various other organs.

Fig.39.4: Poult with turkey viral hepatitis. Pancreas showing prominent foci.

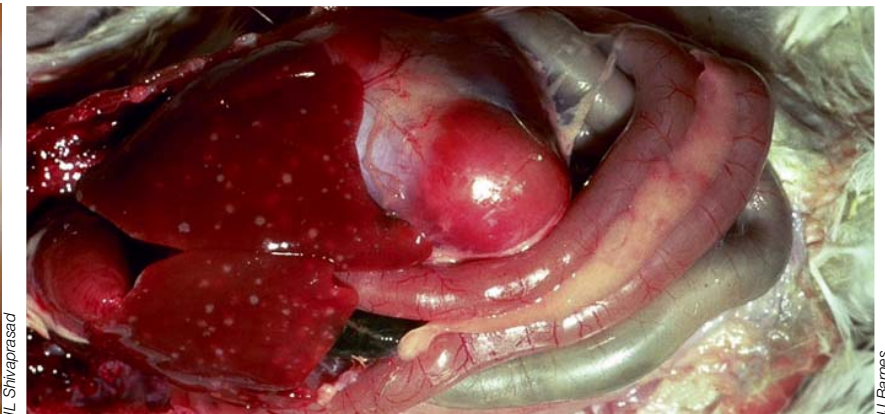
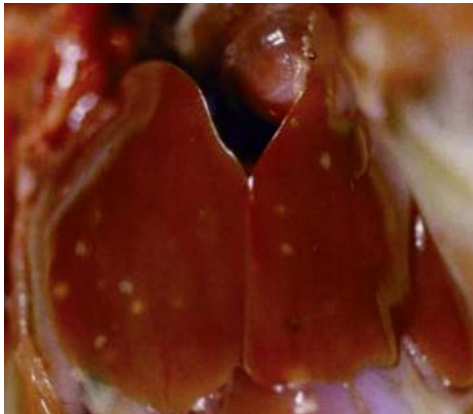

Fig.39.5 & 39.6: In turkey viral hepatitis, the main necropsy findings are a few to multiple necrotic pale white foci in the liver. Livers are generally enlarged.

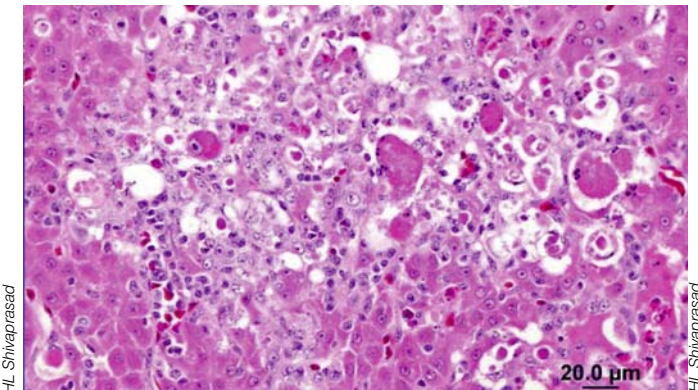
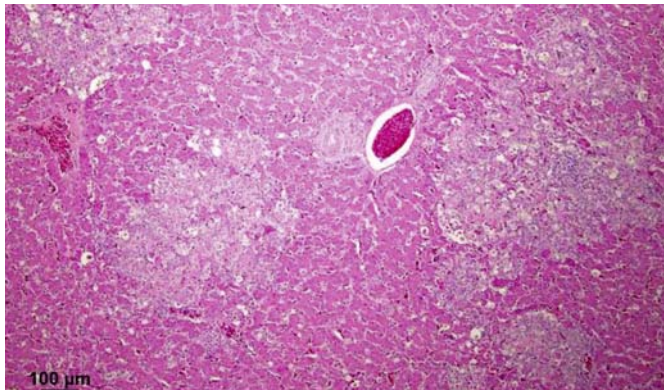


Fig 39.7 & 39.8: Histopathology of turkey viral hepatitis showing acute multifocal coagulative necrosis and hepatocytes and inflammation.

Viral diseases

39. OTHER VIRAL INFECTIONS

INTRODUCTION

There are numerous other viruses some of which are very important such as avian bornavirus and other viruses that affect various species of birds but are difficult to cover in detail. In this chapter, a brief description of the viruses and the disease they cause, clinical signs, transmission, pathology, diagnosis and treatment and control will be presented. Some of these viruses include avian nephritis virus which, as the name implies, cause nephritis in chickens, a novel picornavirus which cause turkey viral hepatitis, a novel birnavirus which cause transmissible proventriculitis in chickens, reoviruses of turkeys which causes myocarditis and other diseases, avian bornavirus which causes proventricular dilatation disease primarily in psittacines but also in other birds, psittacine herpesviruses which causes Pacheco's parrot disease and others, polyomavirus that causes Budgerigar fledgling disease in psittacines, circoviruses that cause Psittacine beak and feather disease in psittacines, immunosuppressive diseases in pigeons and diseases in other species of birds, West Nile virus, a *Flavivirus* that is lethal to corvids but also infects various other species of birds, adenoviruses that affect psittacines pigeons, raptors, *etc.*, *Avian Paramyxovirus-3* that affects psittacines and passerines and reovirus of psittacines.

AVIAN NEPHRITIS

Avian nephritis virus (ANV) is an astrovirus that causes infection of the kidneys in young chickens. The infection is acute, highly contagious but usually subclinical in nature characterized by nephritis and urate deposits in the kidneys and abdominal viscera.

Etiology & epidemiology

ANV has been classified as an astrovirus distinct from Duck Hepatitis type 2 and 3, turkey and chicken astroviruses. Astroviruses are non-enveloped single-stranded positive sense RNA icosahedral virus, 28-30 nm in diameter that may exhibit five or six pointed star-like surface when viewed by electron microscopy. ANV has been placed in a new genus *Aviastrovirus* in the family *Astroviridae*. There are genetic differences among various isolates of ANV.

ANV was first reported from Japan and the disease or the antibodies have been reported in Europe and USA. Transmission of ANV appears to be by direct contact with infected birds. Vertical transmission of the virus has also been suggested.

Clinical signs & lesions

The only clinical sign reported due to ANV in 1-day-old chicks is transient diarrhea but not all birds will show this. But some of the characteristic lesions develop in chicks up to 4 weeks of age. Runting stunting of chicks and decrease in body weights are observed. Mortality can range from negligible to 6%. Grossly the chicks suffering from ANV may show enlarged and pale kidneys with increased urates. Visceral urate deposits (gout) in the pericardium, capsule of the liver, abdominal cavity, subcutaneous tissues, *etc.*, can be observed. Histologically degeneration and necrosis of the epithelial cells of the proximal convoluted tubules and dilation accompanied by lymphocytic interstitial nephritis with tophi formation can be observed. *Tophi* and associated inflammation can also be observed in various other organs.

Diagnosis

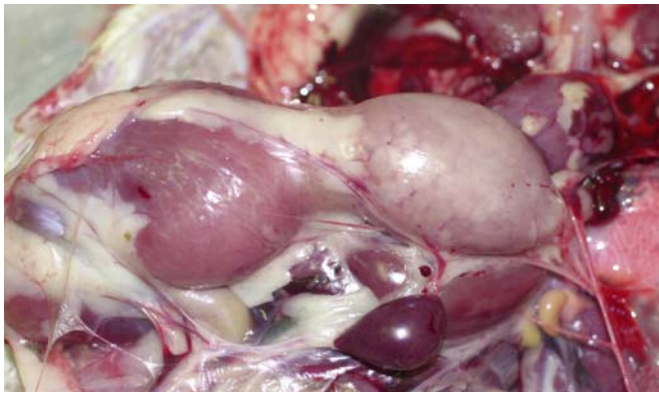
A presumptive diagnosis can be made based on clinical signs, mortality patterns combined with gross and microscopic lesions in young chicks. Virus can be difficult to isolate. It can be isolated in 6-day-old chicken egg embryos by inoculation through yolk sac route and in chicken embryo kidney cells. Other techniques such as RT-PCR, immunofluorescence, ELISA and electron microscopy have been used to diagnose ANV.

Control & treatment

Currently there are no control or treatment measures that are available and biosecurity implementation may help limit the spread of the virus.

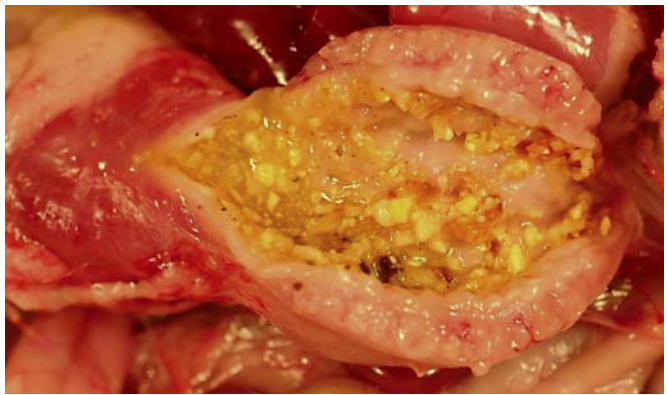
TURKEY VIRAL HEPATITIS

Turkey viral hepatitis (TVH) is an acute to subacute, highly contagious but usually subclinical disease restricted to turkeys. The disease occurs most commonly in young turkeys under the age of 6 weeks, characterized by hepatitis and pancreatitis. The



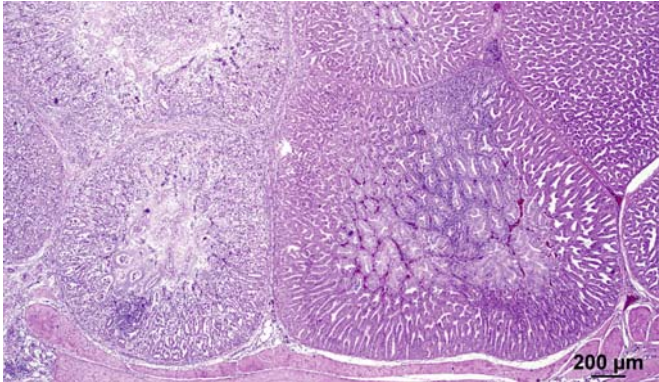
HL Shivaprasad

Fig.39.9: Transmissible viral proventriculitis (TVP). Proventriculus is severely enlarged and pale.



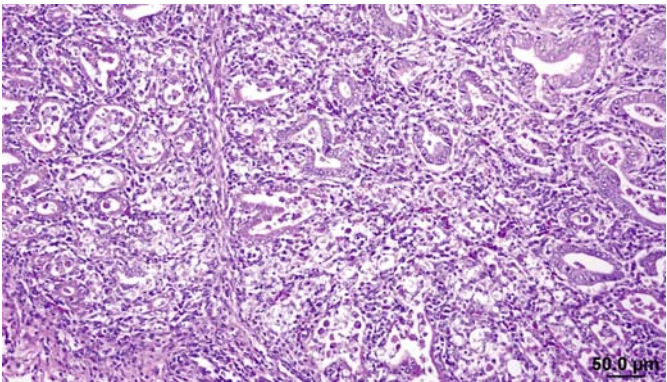
HL Shivaprasad

Fig.39.10: TVP. The wall of the proventriculus is thickened and pale.

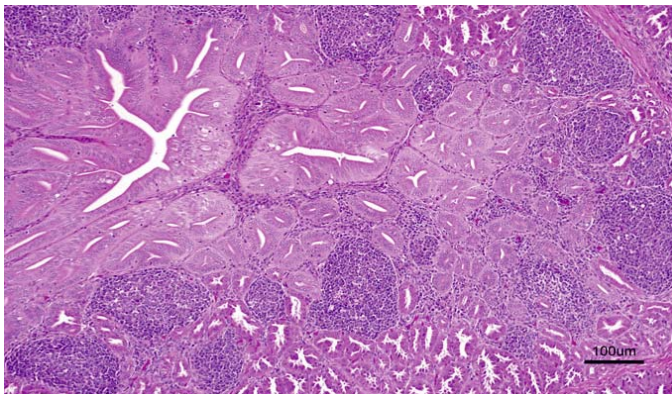


HL Shivaprasad

Fig.39.11 & 39.12: Histopathology of TVP. Acute necrosis of the glandular epithelium and mild infiltration of lymphocytes.

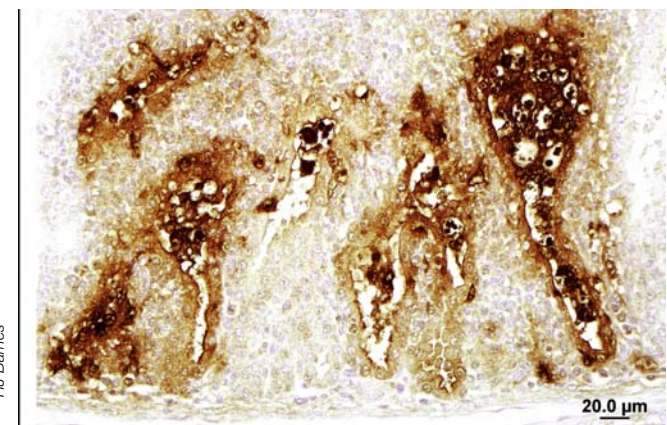


HL Shivaprasad



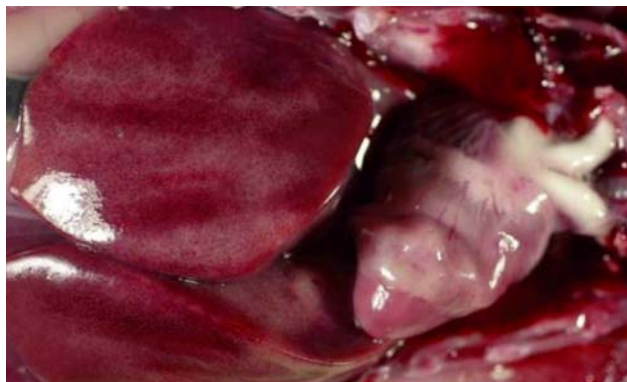HL Barnes

Fig.39.13: TVP. Numerous lymphoid follicles have developed while the diffuse interstitial lymphoid infiltrate has diminished. Note the relative loss of glandular tissue and increased duct epithelium (H & E).



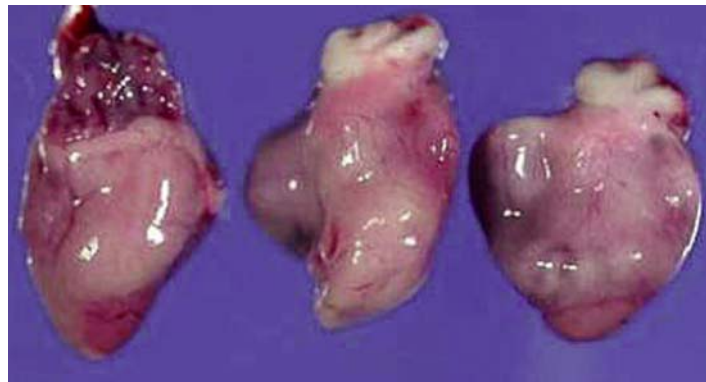HL Shivaprasad

Fig.39.14: TVP. Immunohistochemistry.



HL Shivaprasad

Fig.39.15: Myocarditis due to reovirus in a 13-day-old turkey poults. Note the pale epicardium and passive congestion in the liver.



HL Shivaprasad

Fig.39.16: Myocarditis due to reovirus in three 15-day-old turkey poults. Note the pale epicardium and dilation of right ventricle in two birds.

disease is common in some areas of USA like in California. It has also been reported in Canada, Italy, France and UK.

Etiology & epidemiology

The etiological agent of THV was recently identified by pyrosequencing to be a novel *Picornavirus* of 25-30 nm in diameter. Transmission is thought to be *via* the faeces and vertical transmission may also occur. But not much is known about the occurrence of TVH in turkey flocks.

Clinical signs & lesions

The disease is usually subclinical and may become apparent when the birds are stressed. Affected turkeys are stunted and unthrifty. Morbidity and mortality vary according to the severity of stress. In poults less than 5 weeks old, morbidity may reach 100%. Mortality, reported only in poults, is confined to a 4-to-8-day period, and may reach 25%. Breeder flocks may exhibit decreased production, fertility and hatchability but deaths are not seen in birds over 6 weeks of age. TVH often occurs with poult enteritis.

The main necropsy findings are a few to multiple necrotic pale white foci in the liver. Liver may be enlarged in acute stages. Less frequently pale or gray patches of necrosis may be present in the pancreas. Occasionally spleen may be enlarged and mottled pale or gray. Often the poults with TVH will have enteritis characterized by pale serosa of the small intestine and distension with watery contents.

Microscopically, pale foci represent multifocal acute coagulative necrosis of hepatocytes and infiltration of lymphocytes, plasma cells and macrophages. In acute stages the inflammation is accompanied by the presence of multinucleated cells or syncytia of unknown origin. In subacute to chronic stages infiltration of mononuclear inflammatory cells is the characteristic feature. Lesions in pancreas range from acute acinar cell necrosis with minimal inflammation to severe lymphoplasmacytic inflammation with formation of lymphoid nodules in chronic stages. Transmission electron microscopy of liver and pancreas has demonstrated 23 to 27 nm virus particles either arranged loosely or in a geometric fashion in the cytoplasm of hepatocytes and acinar cells of the pancreas. Often the poults with TVH will have enteritis characterized by increased cellularity of the *lamina propria* suggesting that the novel picornavirus probably can cause enteritis also.

Diagnosis

Diagnosis of suspicion of TVH is based on observation of gross and microscopic lesions of the liver and pancreas. Gross liver lesions may resemble those of bacterial infections, particularly from *Salmonella* spp, *Pasteurella multocida*, or *Escherichia coli*, and infections caused by Group 1 and Group 2 avian adenoviruses and reoviruses and acute histomoniasis. Transmission electron microscopy of the liver and/or pancreas can demonstrate characteristic virus particles.

Diagnosis of TVH can be made by RT-PCR on feces and cloacal swabs from live birds and liver, pancreas, bile and intestine from dead poults with typical lesions. Isolation of the virus from samples of internal organs or the faeces inoculated into embryonated chicken eggs can be used for confirmation.

Treatment & control

There is no known treatment. Improved sanitation may be of value in preventing dissemination of the agent.

TRANSMISSIBLE VIRAL PROVENTRICULITIS

Transmissible viral proventriculitis (TVP) is a viral disease of young broiler chickens characterized by inflammation and enlargement of the proventriculus. The disease is a recognized cause of production losses in broiler chickens of 1 to 8 weeks of age but is also reported in broiler breeders and commercial layer hens (9-20 weeks of age).

Etiology & epidemiology

A newly recognized birnavirus of chickens referred to as chicken proventricular necrosis virus (CPNV) has been associated as a cause of TVP. This recently recognized virus of chickens is a new member of the family *Birnaviridae*, deeply divergent from other birnaviruses, especially the *Avibirnavirus* of infectious bursal disease.

Experimental studies demonstrated accentuation of induced TVP in young broiler chickens when these chickens were treated with chemical immune suppressants (cyclophosphamide, cyclosporin) or infected with infectious bursal disease virus.

Clinical signs & lesions

TVP is characterized in broiler chickens by inflammation and enlargement of the proventriculus. The

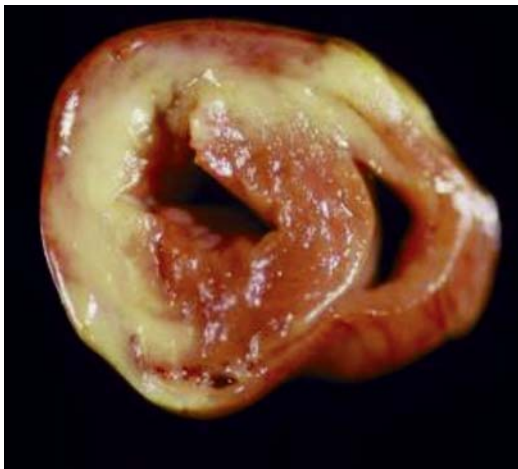


Fig.39.17: Myocarditis due to reovirus in a 5-week-old turkey poult.

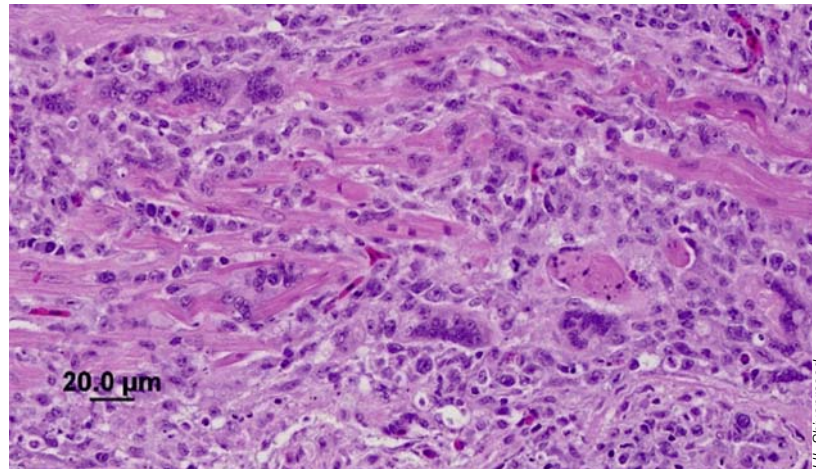


Fig.39.18: Histopathology of myocarditis due to reovirus. Degeneration, necrosis and inflammation including multinucleated cells.

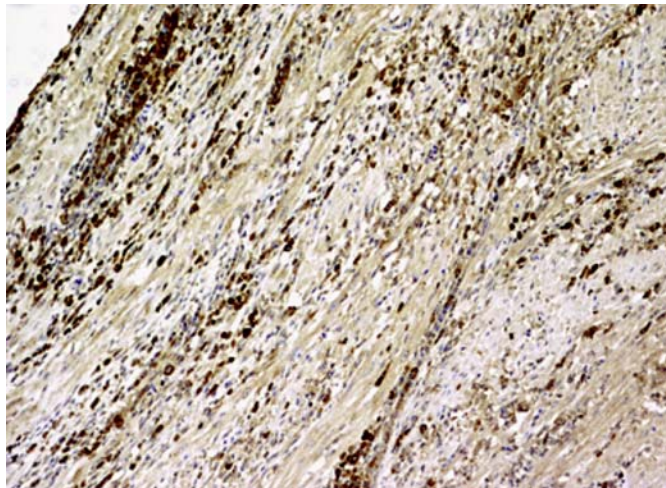


Fig.39.19: Myocarditis due to reovirus. Immunohistochemistry (heart): antigen in the cytoplasm of inflammatory cells and myocytes.

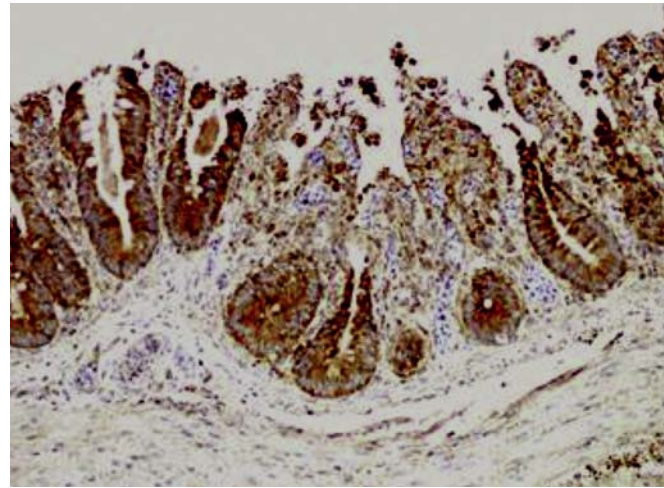


Fig.39.20: Myocarditis due to reovirus. Immunohistochemistry (intestine): antigen in the cytoplasm of inflammatory cells and enterocytes.

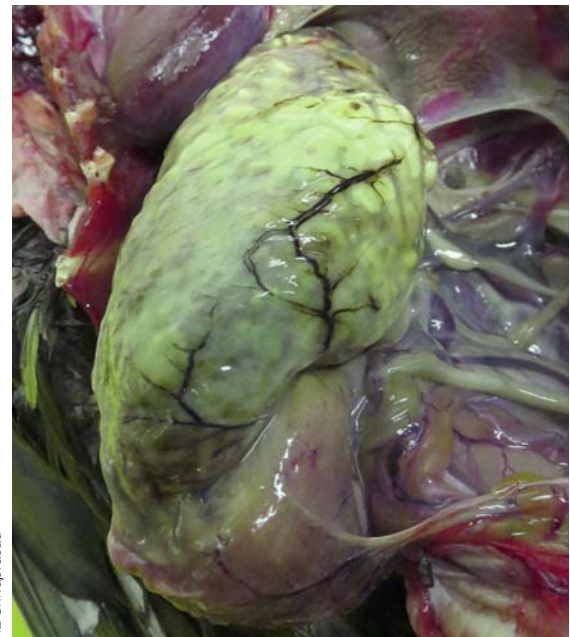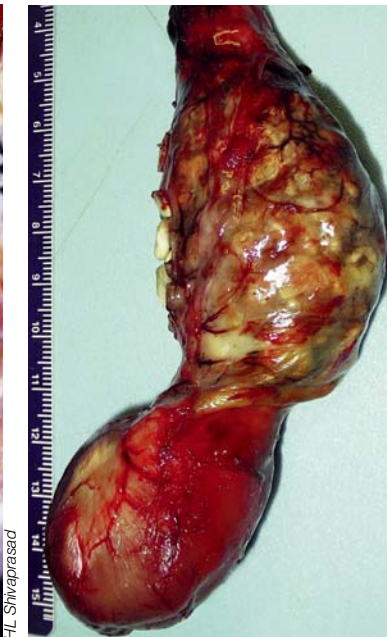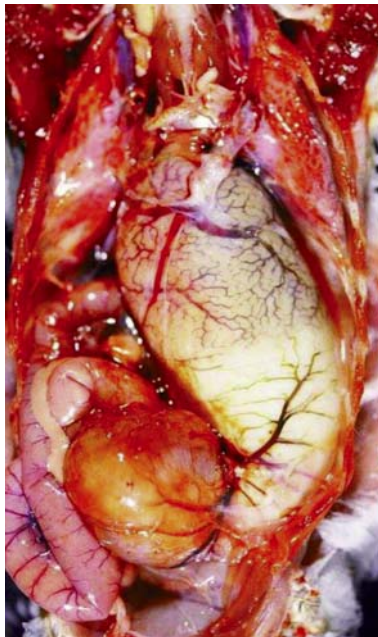


Fig.39.21, 39.22 & 39.23: Proventricular Dilatation Disease (PDD). Moderate to severe dilatation of the proventriculus due to Avian Bornavirus (ABV) in an african gray parrot (Fig.39.21), scarlet macaw (Fig.39.22) and a Blue and Gold Macaw (Fig.39.23). Notice the thin wall of the proventriculus showing seeds (Fig.39.22 & 39.23).

disease is associated with proventricular fragility, impaired growth, poor feed conversion, and impaired feed digestion. The disease results in increased fragility of the proventriculus and a tendency to rupture at processing. This is responsible for increased processing costs because of higher numbers of reprocessed carcasses and condemnations.

Gross lesions can range from mild pale mottling to diffuse paleness of the proventricular serosa associated with mild to severe dilation of the proventriculus. The wall and mucosa of the proventriculus can be thickened. Microscopic lesions range from acute necrosis of glandular epithelium with diffuse interstitial infiltration of lymphocytes in acute stages to ductal epithelial hyperplasia, replacement of glandular epithelium with ductal epithelium and lymphoid nodule formations in subacute to chronic stages. Immunohistochemistry demonstrated viral antigen in the cytoplasm of glandular and to an extent in the mucosal epithelium of the proventriculus.

Diagnosis

Characteristic gross and microscopic lesions should help diagnose TVP. Confirmation of the diagnosis can be obtained with the detection of the virus by PCR or immunohistochemistry. At necropsy it is difficult to differentiate TVP from proventricular dilatation due to finely ground diet and sometimes with Marek's disease.

Treatment & control

There is no treatment. Biosecurity measures and improved control of infectious bursal virus disease can reduce incidence of TVP.

REOVIRUS INFECTIONS

Reoviruses are recognized as a cause of tenosynovitis/viral arthritis in chickens (see Chap.II.27) but they have also been isolated from several other disease conditions in chickens (runting stunting syndrome or malabsorption syndrome), ducks (see Chap.VI.85) and turkeys.

Reovirus infection of turkeys

The number of studies on reovirus in turkeys include arthritis, synovitis, immune dysfunction, and poult enteritis caused by turkey reovirus are distinct from chicken reovirus. Poult enteritis mortality syndrome is a disease of complex etiologies, such as viruses, bacteria, and protozoa (see Chap.IV.72). More recently, myocarditis associated with turkey reovirus has been described in 17-day-old turkey poults

with a history of diarrhea and increased mortality ranging from 0.35% to 3% per week. Affected poults had pale myocardium often associated with dilation of the right heart, grossly and microscopically mild to severe lymphoplasmacytic and macrophage inflammation and a few multinucleated giant cells. Transmission electron microscopy of the heart revealed 85 to 88 nm diameter virus particles in the sarcoplasmic reticulum. Immunohistochemistry using polyclonal antibody for turkey reovirus revealed positive staining in the inflammatory cells of the myocardium, bursa of Fabricius, spleen, intestine, liver and lungs as well as in the myofibers, epithelium of the intestine and bursa of Fabricius.

Reovirus infection in psittacines

Unique psittacine reoviruses have been attributed as the cause of clinical disease and mortality in various species of psittacines; african gray parrots, budgerigars and various other species. Hepatosplenomegaly associated with necrosis and inflammation and enteritis were the most consistent lesions.

PROVENTRICULAR DILATATION DISEASE

Proventricular Dilatation Disease (PDD) is one of the most common and fatal diseases of psittacines. PDD has been reported in USA, Europe, Australia, South Africa, and Brazil and probably it occurs in other parts of the world. The disease is a progressive neurologic disease that primarily affects the gastrointestinal nervous system but can also affect other systems. The disease has been known since the late 1970's. PDD has been called by various names, including macaw wasting syndrome, proventricular dilation syndrome, neuropathic gastric dilation, myenteric ganglioneuritis, and infiltrative splanchnic neuropathy, to name a few. PDD has been observed in more than 80 species of psittacines but also in some non psittacine species such as ostriches, canaries, Canada geese, trumpeter swans, ducks, finches, toucan, peregrine falcon, red-tailed hawk, golden eagle, mouse bird, honey-creeper, long-wattled umbrella bird, bearded barbet and roseate spoon bill.

Etiology & epidemiology

The cause of proventricular dilation syndrome remained unknown in spite of extensive studies by numerous workers till 2008 when Kistler *et al.* and Honkavuori *et al.* independently reported on the recovery of a novel *Bornavirus* from birds with PDD. The virus was named avian bornavirus

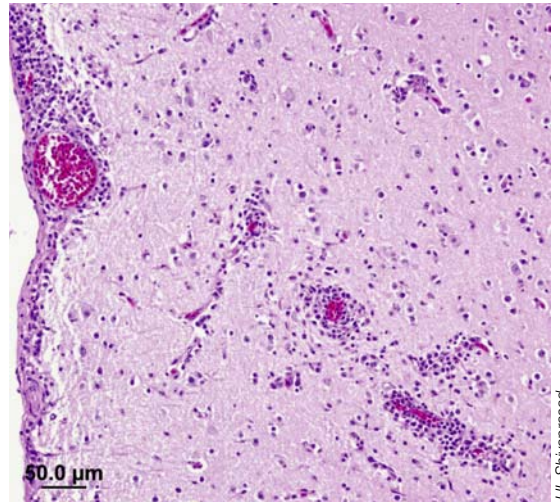
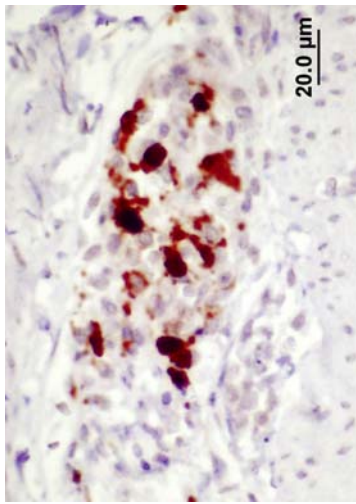
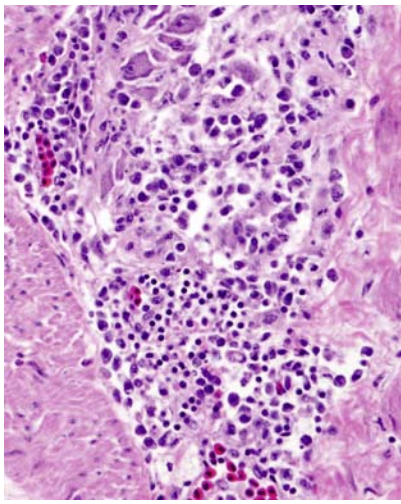


Fig.39.24 & 39.25: PDD (histopathology & immunohistochemistry). Severe ganglioneuritis of the proventriculus due to ABV in an Eclectus parrot. Immunohistochemistry of the same ganglia showing ABV antigen in the nuclei and cytoplasm of the cells (Fig.39.25).

Fig.39.26. PDD (histopathology). Severe meningoencephalitis in the brain due to ABV in an Eclectus parrot.

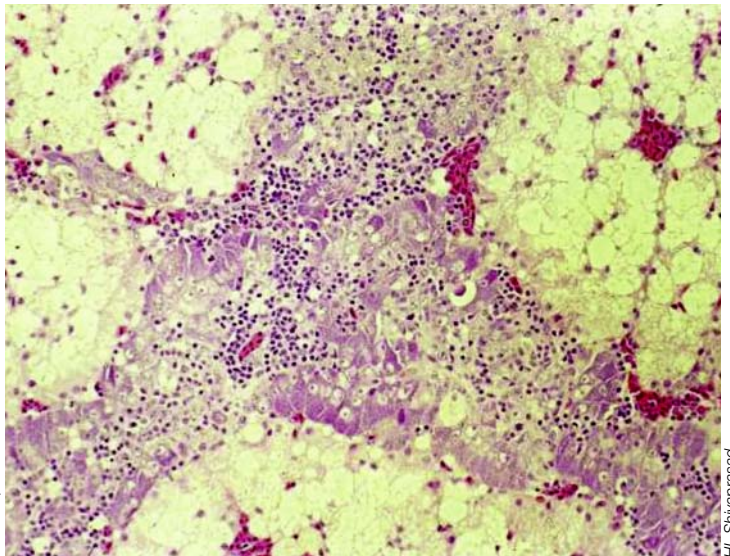
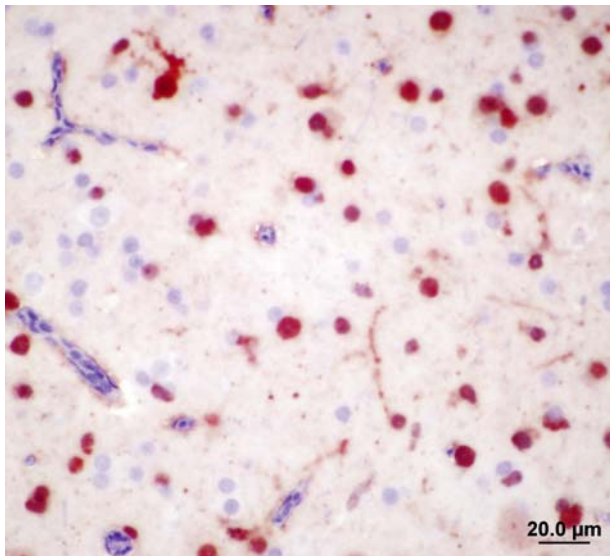


Fig.39.27: PDD. Immunohistochemistry of the brain showing ABV antigen in the nucleus, cytoplasm and dendrites of neurons and glial cells.

Fig.39.28: PDD (histopathology). Moderate adrenitis of the medullary cords due to ABV in a psittacine.

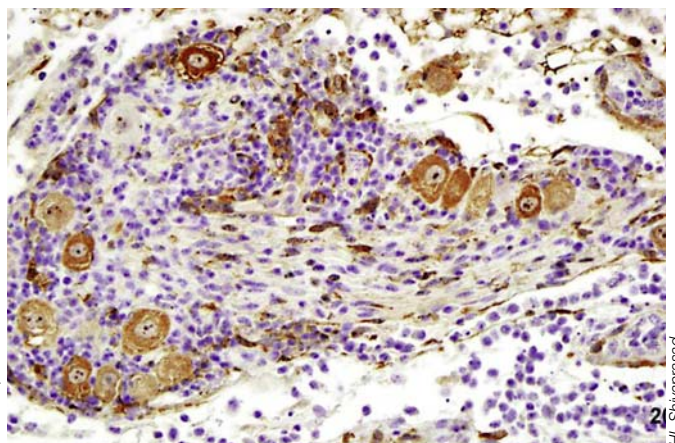
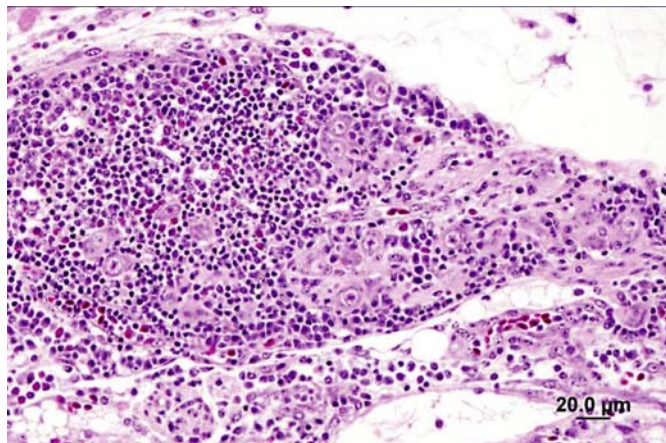


Fig.39.29 & 39.30: PDD (histopathology & immunohistochemistry). Severe ganglioneuritis of the epicardial ganglia due to ABV in a canary. Immunohistochemistry of the same ganglia showing ABV antigen in the nuclei and cytoplasm of the cells (Fig.39.30).

(ABV) because it was quite distinct and shared only 65% nucleotide sequence with the well known Borna disease virus (BDV) of mammals. Borna disease caused by BDV has been known since 1858 and is an encephalitic disease of horse, sheep and occasionally other domesticated mammals and it is endemic in Central Europe. Bornaviruses are negative sense, enveloped, single-stranded spherical medium-sized (70-130 nm in diameter) RNA viruses that are members of the family *Bornaviridae*, order *Mononegavirales*. BDV strains show a remarkable sequence homogeneity and are all derived from mammalian hosts. Based on nucleotide sequence analysis of numerous ABV isolates from psittacines, seven distinct genotypes designated ABV1 to 7 have been identified. Other distinct genotypes have been described from non-psittacine species such as canaries (*Serinus canaria*), finches, Canada geese, trumpeter swans and ducks with typical pathology of PDD. But ABV has not been demonstrated by conventional PCR in other species of birds which also had pathology of PDD.

The mode of transmission of ABV appears primarily through the fecal-oral route. Vertical route of transmission has also been demonstrated. The virus is shed intermittently in the droppings. The incubation period for ABV is believed to be months or even more than a year but recent work suggests that it could be as short as a few days depending on the age of the birds at exposure.

Clinical signs & lesions

The clinical signs of PDD vary and may be predominantly neurologic such as weakness, ataxia, proprioceptive deficits, seizures, blindness and/or gastrointestinal such as weight loss, regurgitation of food, delayed emptying of crop, passing of undigested seeds in the feces. Sudden death has also been reported. The dilatation of the proventriculus is due to accumulation of food secondary to defects in the motility of proventriculus and the intestine. The intestinal dysfunction is probably due to virus-induced immune damage to the autonomic nerves affecting the upper and middle gastrointestinal tract.

Gross pathology in most cases (80%) of PDD is characterized by dilation of the proventriculus and occasionally the gizzard and duodenum. Sometimes the proventriculus is so severely dilated and thin walled that it can rupture spilling *ingesta* into the peritoneum. Birds with protracted infection can be severely emaciated. Microscopic lesions can be variable from bird to bird and

include mild to severe, focal to multifocal lymphoplasmacytic ganglioneuritis involving the myenteric ganglia of the esophagus/crop, proventriculus, gizzard and intestine. Non-suppurative encephalomyelitis, myocarditis, adrenalitis, chorioretinitis in the eye can also be seen. Similarly peripheral nerves and individual nerves as well as ganglia in various organs, and the arrector pili muscles in the skin can have lymphoplasmacytic infiltration. In one study of cockatiels when challenged with ABV4, unusual pathology of PDD was observed not only in the neural tissues but also in the non-neural tissues such as liver, spleen, kidneys, lungs, etc.

Immunohistochemistry can demonstrate the ABV antigen not only in the cytoplasm but also in the nucleus of inflammatory cells. Glial cells and neurons in the brain, spinal cord, retina and ganglia throughout the body are similarly stained sometimes with no inflammation.

Diagnosis & treatment

PDD can be diagnosed in birds based on clinical signs and radiography of the bird, ELISA, indirect immunofluorescence (IIFA) and Western blot analysis on serum and plasma, polymerase chain reactions (PCR) on choanal secretion, feces, feathers and organs, histopathology of crop biopsy, *in situ* hybridization (ISH), immunohistochemistry (IHC) of brain and other organs and virus isolation on the brain, proventriculus, adrenal glands, etc. Vitreous of the eye is a consistent source of the virus.

ABV does not cause cytopathic effect in cell cultures such as in duck embryo fibroblasts and other cell lines.

It should be pointed out that most of the diagnostic tests have limited practical applications. Crop biopsy can miss as many as 26% of the positive PDD birds. PCR, IIFA and Western blot analysis have demonstrated that positive results for ABV can occur in normal and non-symptomatic PDD birds as well as false negatives in PDD birds. PCR and IHC have demonstrated the ABV not only in the neural tissues but also in non neural tissues.

Though the pathogenesis of PDD is not known it is probably an immune mediated disease. General treatment has been directed against the immune response. Non-steroidal anti-inflammatory drugs are widely used with variable and unknown results. These include celecoxib, cyclosporine, ribavirin, and meloxicam. There is no vaccine available at the present time to prevent or control PDD.

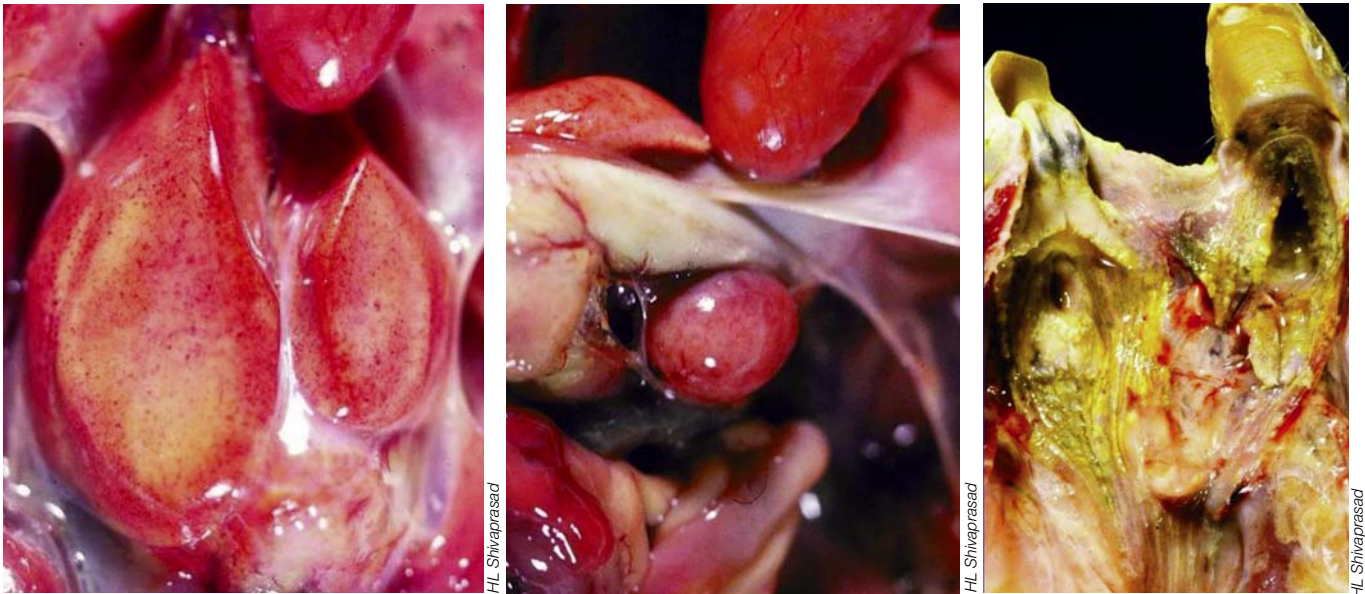


Fig.39.31, 39.32 & 39.33: Pacheco's parrot disease. Enlarged liver with petechiae (Fig.39.31), enlarged spleen (Fig.39.32) and fibrinonecrotic stomatitis and esophagitis (Fig.39.33) in Amazon parrots due to psittacine herpesvirus.

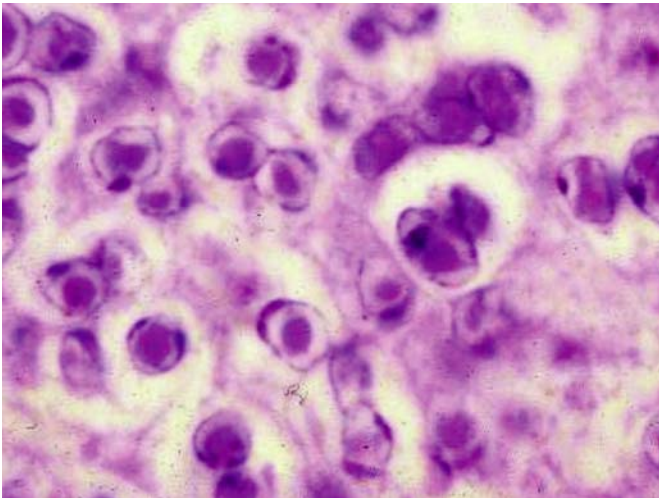


Fig.39.34: Eosinophilic intranuclear inclusions of herpesvirus in the intestinal epithelial cells of a parrot.

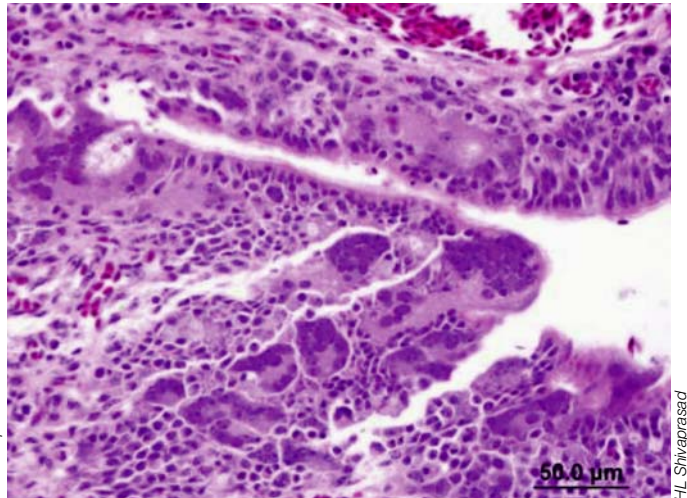


Fig.39.35: Histopathology of severe bronchitis and presence of syncytia due to psittacine herpesvirus 3 in a Rosy Bourke Parakeet.



Fig.39.36: Severe conjunctivitis in a Gouldian Finch due to Passerid herpesvirus.

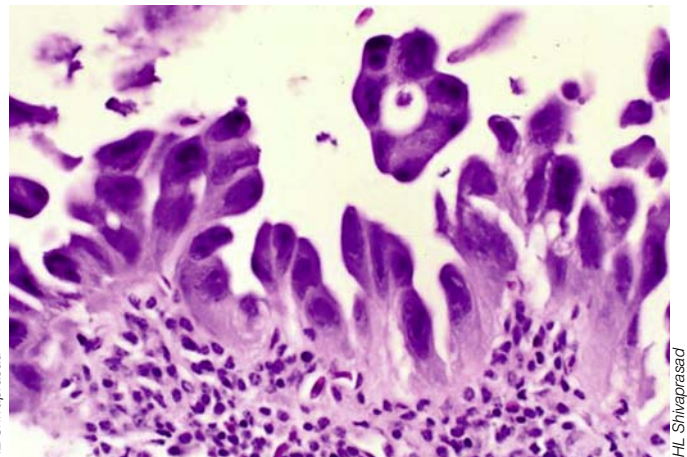


Fig.39.37: Histopathology of conjunctivitis in the Gouldian Finch with hypertrophied epithelial cells containing intranuclear inclusion bodies.

MISCELLANEOUS HERPES INFECTIONS

In the order of *Herpesvirales* and the family of *Herpesviridae*, herpesviruses of birds, grouped in the subfamily of *Alphaherpesvirinae*, have a broad host range and infect many avian species, including chickens, turkeys, ducks, peafowl, pheasants, pigeons, psittacines, passerines, eagles, storks, falcons, cranes, bobwhites, cormorants, penguins, owls, *etc.* Some of the important diseases are Marek's disease (*Gallid herpesvirus 2*, genus *Mardivirus*) (see Chap.II.33), infectious laryngotracheitis (*Gallid herpesvirus 1*, genus *Iltovirus*) (see Chap.II.22), duck virus enteritis or duck plague (*Anatid Herpesvirus 1*, not classified but closed to genus *Mardivirus*, *Varicellovirus* and *Simplexvirus* in the same subfamily) (see Chap.VI.89). These *Alphaherpesvirinae* may cause substantial economic and ecological losses.

Other herpesviruses can infect psittacines (*Psittacid herpesvirus 1* - Pacheco's disease and others), passerines (*Passerid herpesvirus*), pigeons as well as owls, falcons, hawks (*Columbid herpesvirus 1*) (see Chap.VI.99), and various other species of birds.

Pacheco's disease was first recognized in Brazil by Pacheco in 1930. Herpesvirus responsible (PsHV) mainly affects genus *Amazona* spp. and other parrots. The disease often occurs after stress (travel, environmental changes, *etc.*) and is highly contagious. Often the most frequent symptom observed is sudden death of the bird but other symptoms can be observed; nasal and ocular discharge, diarrhea and nervous disorders, greenish droppings discolored with urates, *etc.* Other birds can be latent carriers without showing any clinical signs. Gross and histopathology includes hepatitis sometimes with syncytia, enteritis, esophagitis, stomatitis, conjunctivitis, *etc.*, with intranuclear inclusion bodies in the hepatocytes and epithelial cells. Tentative diagnosis can be made based on histopathology demonstration of intranuclear inclusion bodies. The diagnosis can be confirmed by virus isolation from tissue samples of the liver, spleen or kidney in chicken egg embryo or liver cell culture.

Clinical signs of respiratory signs and lesions similar to infectious laryngotracheitis: airsacculitis, conjunctivitis, laryngitis, bronchitis and bronchopneumonia associated with syncytia and intranuclear inclusion bodies, due to a novel psittacine herpesvirus has been described primarily in Rosy Bourke parakeets and a few other psittacines.

Passerid herpesvirus has been described in various

species of finches most commonly in Gouldian finches associated with respiratory disease and increased mortality. Pathology of airsacculitis, conjunctivitis, sinusitis, laryngitis, tracheitis, bronchitis and esophagitis associated with hypertrophied karyomegalic cells with large basophilic intranuclear inclusion bodies has been observed.

OTHER CIRCOVIRUS INFECTIONS

As described in previous chapters [CIAV of chickens (see Chap.II.30) and circovirus infection of ducks and geese (see Chap.VI.91)] there are other distinct circoviruses of birds that cause severe disease in various species of birds. These include psittacine beak and feather disease in psittacines, circovirus infection of pigeons and doves, circovirus of finches and canaries and circovirus of gulls, ravens, and starlings. Circovirus infection has been reported in pheasants also but has not been characterized. Circoviruses are non-enveloped small viruses with icosahedral morphology, about 15 to 20 nm in diameter, contain unique circular DNA and belongs to the genus *Circovirus* and family *Circoviridae*. It has been reported that there is a high degree of genetic diversity among some of these circoviruses (BFDV and PiCV) due to the continuous occurrences of recombinations between circoviruses circulating within an aviary and due to continuous parrot trade.

Psittacine beak and feather disease (PBFD)

PBFD is a highly contagious disease of many species of psittacines caused by psittacine circovirus also called Beak and Feather Disease Virus (BFDV). The disease is probably widespread throughout the world. The clinical signs, lesions and the outcome of the disease probably depend on the genetics of the virus and the host susceptibility as there are multiple viral genotypes or lineages of BFDV. BFDV can cause acute death in some species of birds such as african gray parrots due to acute bursal necrosis that results in immunosuppression and secondary bacterial and fungal infections. In some species the disease can be chronic characterized by lethargy, loss of weight with or without feather and beak dystrophy and death secondary to immunosuppression or other causes. The disease is transmitted horizontally but vertical transmission has also been demonstrated. Clinical signs of PBFD range from sudden death to dystrophic feathers first noticed in the powdery down feathers that progresses to contour feathers followed by primary, secondary and tail feathers and almost symmetrical in distribution. Gross and microscopic lesions consist of sloughing of claws

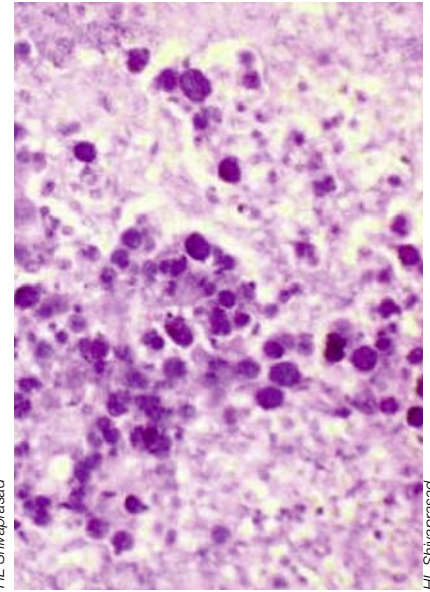
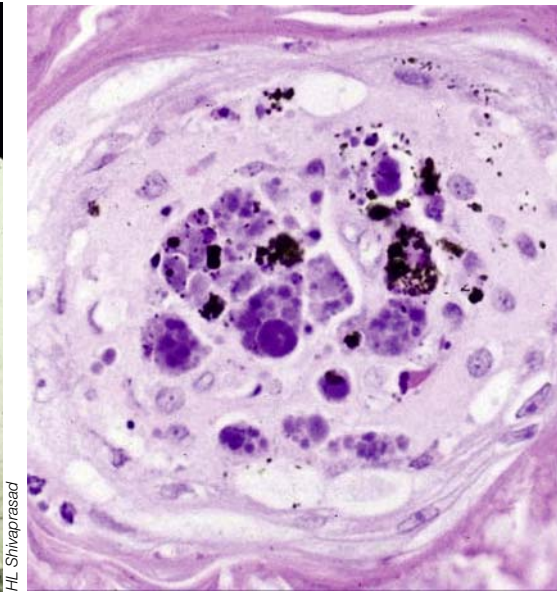


Fig.39.38: Severe beak and feather dystrophy in a Moluccan Cockatoo (left) due to PBF virus. Note normal cockatoo on the right.

Fig.39.39: PBFV. Histopathology showing typical botryoid inclusions of PBFV in the mononuclear cells of the pulp cavity.

Fig.39.40: PBFV. Histopathology of bursa of Fabricius in an african gray parrot showing typical botryoid inclusions of PBFV in the mononuclear cells.

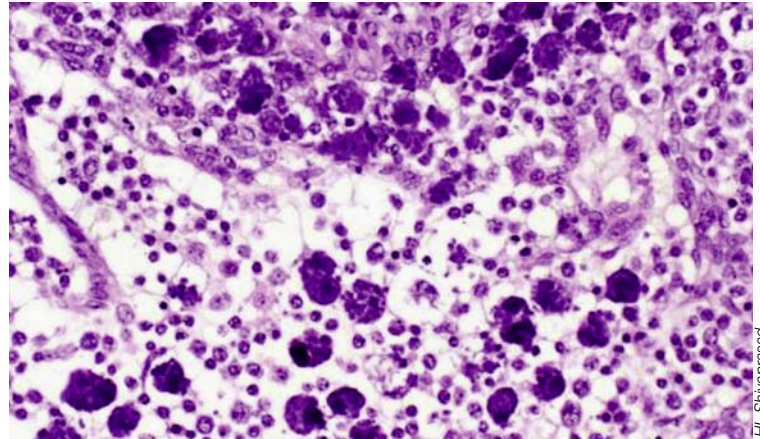
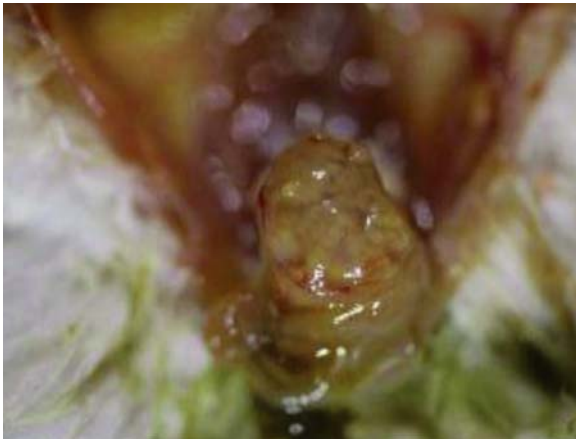

Fig.39.41: Fibrinous exudate in the bursa of Fabricius of a pigeon due to bacteria but primary infection with circovirus.

Fig.39.42: Histopathology showing typical botryoid inclusions in the mononuclear cells of the bursa of Fabricius in a pigeon.

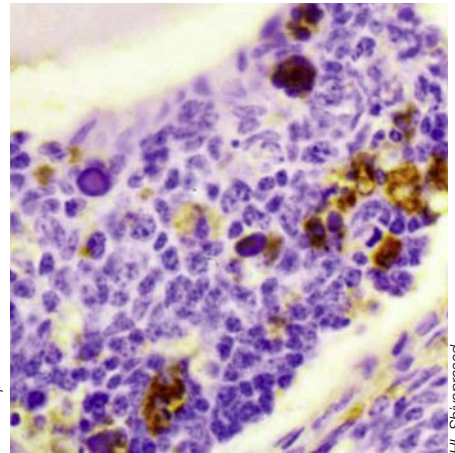
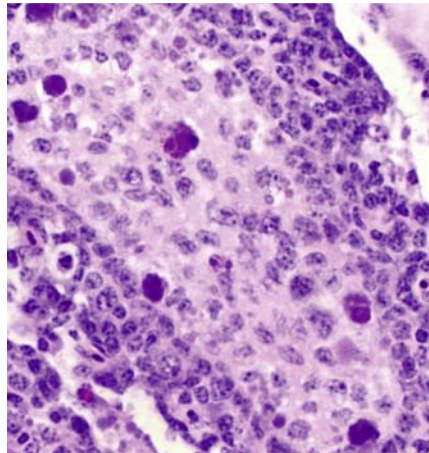
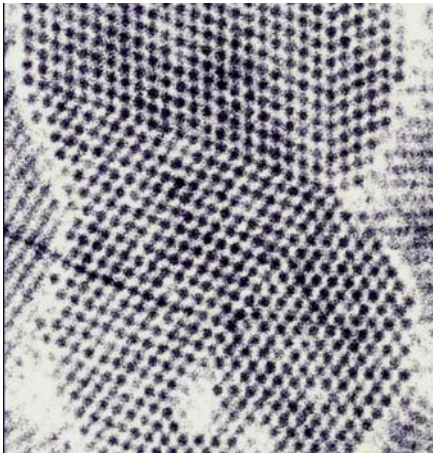

Fig.39.43: Transmission electron microscopy of circovirus particle arranged in a geometric pattern from the bursa of Fabricius (Pigeon).

Fig.39.44: Histopathology of circovirus inclusions in the mononuclear cells of the bursa of Fabricius in a Gouldian Finch.

Fig.39.45: *In situ* hybridization of the bursa of Fabricius staining the nucleic acid of circovirus in the Gouldian Finch.

and beak necrosis, necrosis of the oral mucosa, liver, bursa of Fabricius. Pteryilitis (inflammation of the feathers) and pulpitis associated with characteristic botryoid (grape-like) inclusions in the cytoplasm of macrophages and also in the bursa of Fabricius, bone marrow, thymus, beak, claws and other organs are characteristic microscopic lesions of PBFD. Intranuclear inclusion bodies in the epithelium of the feathers, esophagus, intestine, hepatocytes, *etc.*, can also be observed. Diagnosis of PBFD can be made based on clinical signs, gross lesions and demonstration of characteristic botryoid inclusion bodies in the feathers by histopathology. PCR *in situ* hybridization tests are also available in some laboratories for diagnosis of PBFD.

Pigeons and doves circovirus

Circovirus infection of pigeons is caused by a distinct different circovirus called Columbid or Pigeon circovirus [PiCV (see Chap.VI.99)]. Circovirus infection is one of the most common diseases of young feral and racing pigeons as well as other types of pigeons including squabs raised for meat. Transmission is primarily through horizontal means but vertical transmission is also possible. The disease has been called “Young pigeon disease syndrome” (YPDS) and clinically it is characterized by anorexia, lethargy, regurgitation from the crop, diarrhea and loss of weight in birds up to eight months of age. Subclinical infections are common and sometimes poor race performance is the only sign observed in racing pigeons. In young pigeons, bursa of Fabricius is one of the main targets of the virus and it causes severe necrosis and inflammation. This results in immunosuppression and secondary viral, bacterial, fungal and parasitic infections. Microscopically characteristic botryoid inclusions in the cytoplasm of macrophages can be seen in the bursa of Fabricius, bone marrow, thymus and cecal tonsils. Though not common, feather dystrophy has also been reported in pigeons infected with circovirus. Diagnosis is similar to PBFD.

Finches and canaries circovirus

These circovirus have not been well studied or described. An outbreak of circovirus infection in an aviary of Gouldian finches associated with increased mortality has been described. The disease was characterized by the presence of characteristic inclusion bodies in the mononuclear cells of the bursa of Fabricius, severe lymphoid depletion and secondary bacterial infection in the respiratory tract. Circovirus was confirmed by *in situ* hybridi-

zation test and transmission electron microscopy on the bursa of Fabricius.

In canaries the disease has been called Black Spot disease which probably represents enlarged gall bladder in fledgling canaries. The disease was associated with increased mortality and intracytoplasmic inclusion bodies in the smooth muscle cells of the intestine.

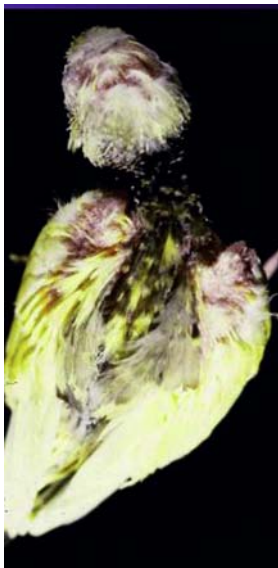
POLYOMAVIRUS INFECTIONS

Avian Polyomavirus (APV) infection is a common generalized inclusion body disease of various species of psittacines that can result in high mortality especially in immature birds. The disease is also called Budgerigar Fledgling Disease (BFD) as budgie fledglings are highly susceptible to APV characterized by feather dystrophy and high mortality. The disease has also been reported in various non-psittacine species such as domestic geese (see Chap.VI.88), finches, canaries, seed crackers, blue-bills, falcons, buzzards, Aracaris, *etc.* Clinical signs in psittacines can vary among species and are non specific. They can range from sudden death and increased mortality in young birds to digestive, respiratory, neurological disorders and hemorrhages in the skin. Pathology in psittacines can range from severe subcutaneous and epicardial hemorrhages to hepatosplenomegaly with petechiae and hemorrhage in the intestine. Hepatomegaly and splenomegaly are the primary lesions in finches and canaries. Microscopic lesions in psittacines can be widespread with hemorrhages and necrosis and mononuclear cell inflammation in various organs. Sometimes mid-zonal necrosis in the liver and membranous glomerulonephritis can be observed. One of the characteristics of microscopic lesions is the presence of karyomegalic faintly staining bluish glassy appearing intranuclear inclusion bodies in various cell types. Diagnosis of polyomavirus can be made based on clinical signs, gross pathology and microscopic lesions with characteristic intranuclear inclusion bodies. PCR and *in situ* hybridization tests are available for diagnosis in some laboratories.

AVIAN PARAMYXOVIRUSES (APMV) 2 & 3

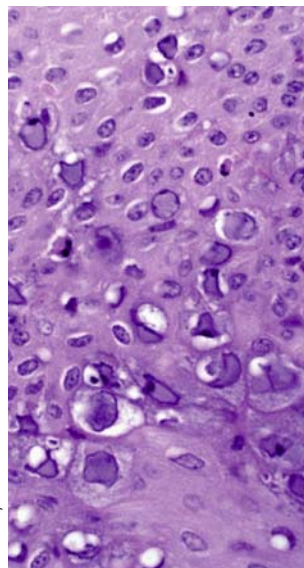
APMV-2 has been associated with respiratory disease in young turkeys and chickens and drop in egg production in layers. It has also been isolated from various other species of birds.

There are two strains of APMV-3, the turkey strain and the psittacine/passerine strain. The turkey



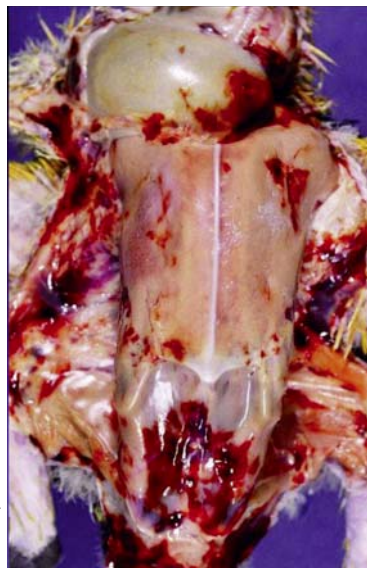HL Shivaprasad

Fig.39.46: Budgerigar Fledgling Disease (BFD): symmetrical feather loss in a budgerigar infected with *Polyomavirus*.



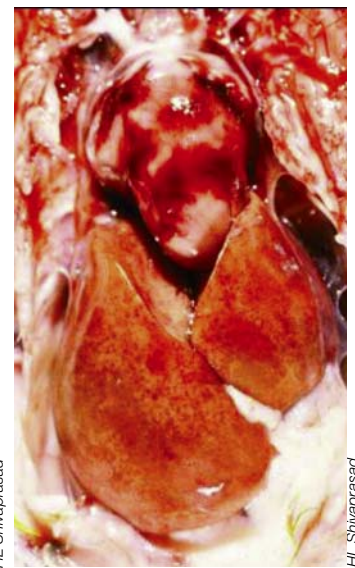HL Shivaprasad

Fig.39.47: BFD. Typical intranuclear inclusion bodies in the epithelial cells of the feather follicles.



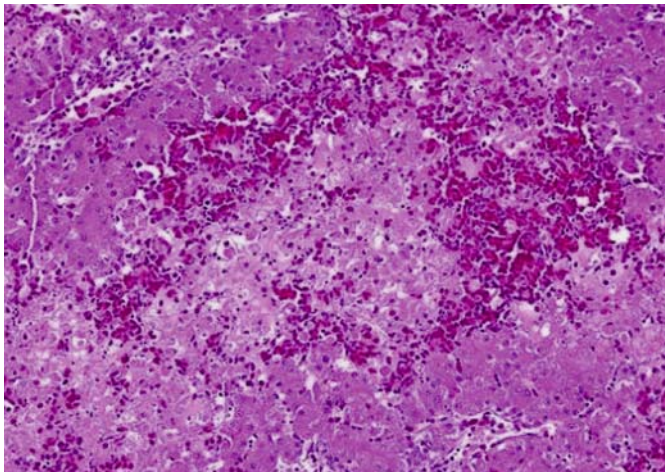
HL Shivaprasad

Fig.39.48: *Polyomavirus* infection. Severe disseminated subcutaneous hemorrhages in a parrot.



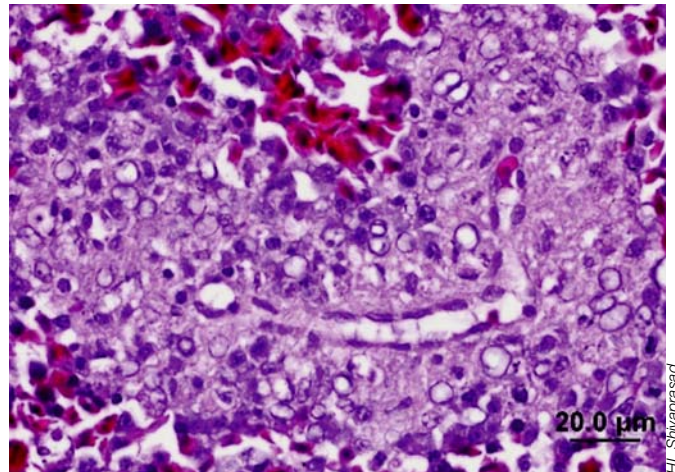
HL Shivaprasad

Fig.39.49: *Polyomavirus* infection. Severe epicardial hemorrhages and enlarged liver with petechiae in a conure.



HL Shivaprasad

Fig.39.50: *Polyomavirus* infection. Histopathology of the liver with severe hepatocellular necrosis, hemorrhage and minimal or no inflammation.



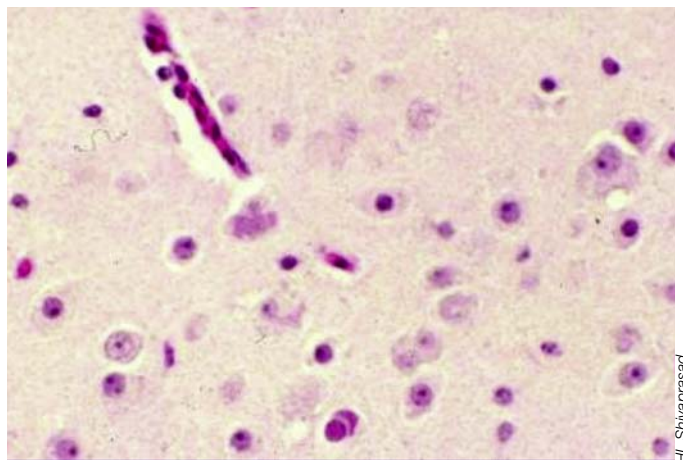
HL Shivaprasad

Fig.39.51: *Polyomavirus* infection. Histopathology of the spleen showing glassy appearing intranuclear inclusion bodies in the mononuclear cells around the periarteriolar sheath.



HL Shivaprasad

Fig.39.52: Avian Paramyxovirus-3 (APMV-3) affects psittacines and passerines sometimes associated with encephalitis like in this budgerigar. APMV-3 also affects chickens, turkeys and ostriches.



HL Shivaprasad

Fig.39.53: APMV-3 infection. Encephalitis with intranuclear and intracytoplasmic inclusions in glial cells in a passerine.

strain causes mild respiratory disease and drop in egg production in turkeys and chickens. Serologically there is cross reaction between APMV-3 and APMV-1.

In psittacines and passerines APMV-3 causes digestive problems with diarrhea and neurological signs due to encephalitis associated with both intranuclear and intracytoplasmic inclusion bodies in glial cells. Other lesions include myocarditis and pancreatitis with intranuclear inclusion bodies.

REFERENCES

- Andral B et al. Picorna-like viruses of young turkeys: Pathogenesis of a disease of poult caused by a picorna-like virus, *Avian Pathol*, 1990,19:245-254. AvianBiotech.com. Pacheco's Disease (PDV). <http://www.avianbiotech.com/diseases/pachecos.htm>
- Bode L & Ludwig H. Borna-disease virus infection, a human mental-health risk. *Clin Microbiol Rev*, 2003,16:534-545.
- Brugère-Picoux J et al. Identification du virus de la maladie de Borna en France. *Bull Acad Vét de France*, 2000,153:411-420.
- Brugère-Picoux J et al. Les herpèsvirus des oiseaux. *Bull Acad Vét de France*, 2011,164,341-351.
- Franca M et al. A retrospective study of myocarditis associated with Reovirus in Turkey Poults. *Avian Dis*. 2010,54:1026-1031.
- Gough RE & McNulty MS. *Picornaviridae*. In *Poultry diseases*. Ed. Pattison M et al, 6th ed. 2008, Elsevier, pp 350-358.
- Guy JS. Turkey viral hepatitis. In “*Diseases of poultry*”. Ed. Saif YM, 12th Ed, Blackwell Publishing, Iowa, IA, 2008, pp 426-430.
- Guy JS et al. Physical and genomic characteristics identify chicken proventricular necrosis virus (R11/3 virus) as a novel birnavirus. *Avian Dis*, 2011,55:2-7.
- Honkavuori SK et al. Novel Borna virus in psittacine birds with proventricular dilatation disease. *EID*, 2008,14:1883-1886.
- Honkavuori SK et al. Novel Picornavirus in Turkey Poults with Hepatitis, California, USA. *EID*, 2011,17:480-487.
- (<http://www.ncbi.nlm.nih.gov/pmc/articles/PMC3166023/>).
- Hoppes SM et al. Avian Bornavirus and proventricular dilatation disease. Diagnostics, pathology, prevalence, and control. *Vet Clin Exot Anim*, 2013,16:339–355.
- Jones RC. Other reovirus infections. In “*Diseases of poultry*”. Ed. Saif YM, 12th Ed, Blackwell Publishing, Iowa, IA, 2008, pp 322-328.
- Ludwig H et al. Bornavirus infection (Borna disease) in naturally and experimentally infected animal: its significance for research and practice. *Tierarztl Prax*, 1985,13:421–53.
- Luppi, MM et al. Identification and isolation of psittacid herpesvirus from psittacids in Brazil. *Vet Microbiol*, 2011; 154(1-2):69-77.
- Marusak RA et al. Transmissible viral proventriculitis identified in broiler breeder and layer hens. *Avian Dis*, 2012,56:757-759.
- Payne S et al. Unusual and severe lesions of Proventricular Dilatation Disease in cockatiels (*Nymphicus hollandicus*) acting as healthy carriers of Avian Bornavirus and subsequently infected with a virulent strain of ABV. *Avian Pathol*. 2011,41:15-22.
- Phalen, D.N. et al. Fatal columbid herpesvirus-1 infections in three species of Australian birds of prey. *Australian Vet J*, 2011,89: 193-196.
- Reed WM. Turkey viral hepatitis. In *The Merck Veterinary manual*. http://www.merckmanuals.com/vet/poultry/turkey_viral_hepatitis/overview_of_turkey_viral_hepatitis.htm l (revision june 2013)
- Shivaprasad HL & Phalen D. A Novel Herpesvirus Associated with Respiratory Disease in Bourke Parrots (*Neopsephotus bourkii*). *Avian Pathol*. 2012,41:531-539.
- Shivaprasad HL et al. Circovirus infection in a Gouldian Finch (*Chloebia gouldidae*). *Avian Pathol*. 2004,33:525-529.
- Shivaprasad HL et al. Myocarditis associated with reovirus in turkey poults. *Avian Dis*,2009,53:523-532.
- Stacheli P et al. Avian Bornavirus associated with fatal disease in psittacine birds. *J Virol*, 2010,84:6269-6275.

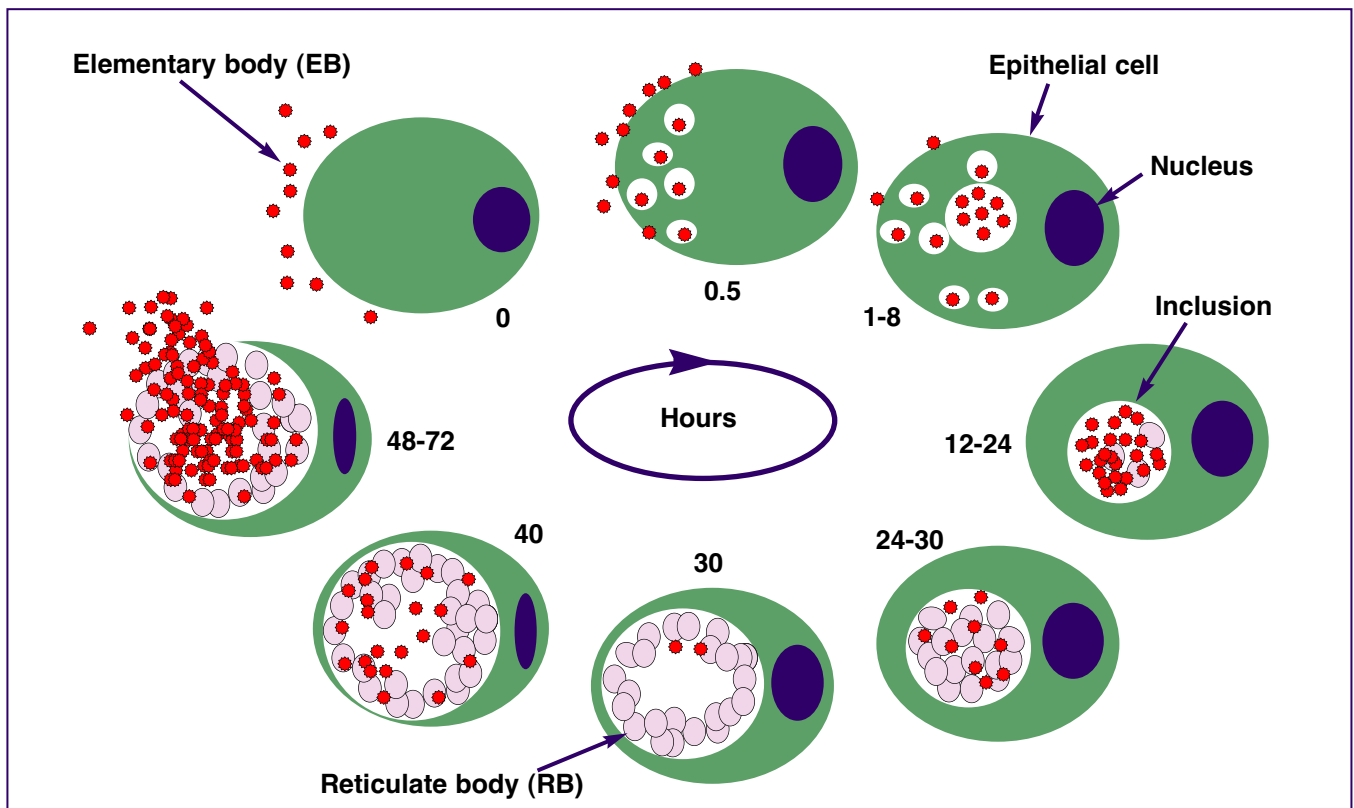
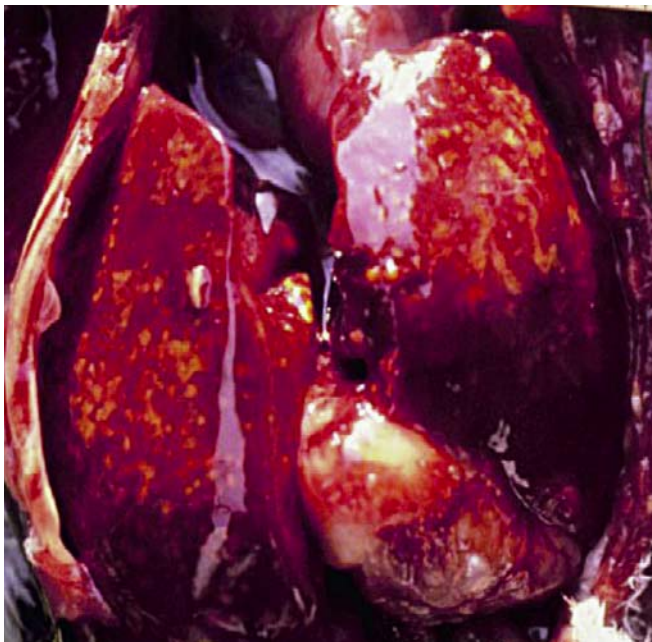
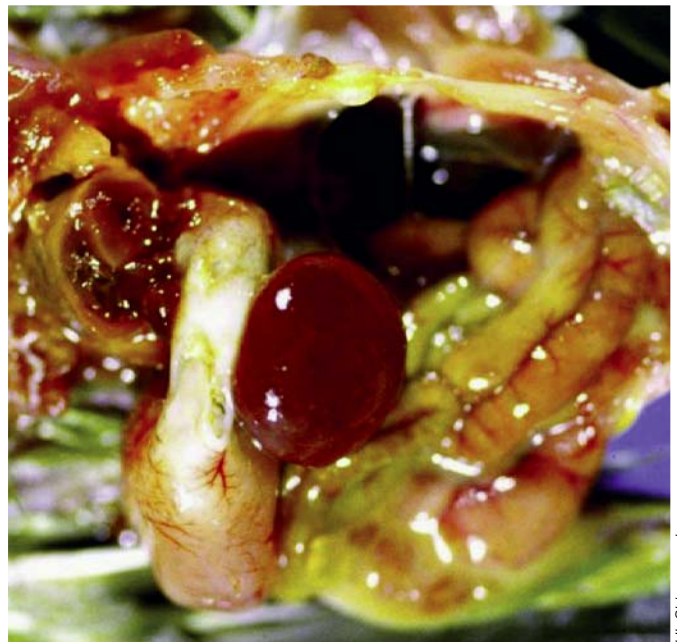
Fig.40.1: Developmental cycle of *Chlamydia trachomatis* (According to Y Pannekoek, http://chlamydiae.com/twiki/bin/view/Cell_Biology/GrowthRegulation).



HL Shivaprasad

Fig.40.2: Avian chlamydiosis (Amazon parrot). Enlarged liver with foci of necrosis.



HL Shivaprasad

Fig.40.3: Avian chlamydiosis (Love bird). Splenomegaly.

Bacterial diseases

40. AVIAN CHLAMYDIOSIS

INTRODUCTION

Avian chlamydiosis is an infectious and zoonotic disease of various species of birds caused by the bacterium *Chlamydia psittaci*. It has been reported in more than 460 species of birds and in 30 orders. Among poultry, it is most commonly reported in turkeys and ducks and more recently in chickens. Other species of birds that are susceptible include psittacines, pigeons, doves, rheas, raptors, geese, passerines (perching birds) and other free-living wild birds. Outbreaks have also been reported in shorebirds and migratory birds. The disease is generally associated with respiratory signs and results in morbidity and mortality. Lesions seen include airsacculitis, pericarditis, perihepatitis and nasal gland adenitis in turkeys and primarily conjunctivitis in ducks. Clinical signs and lesions in chickens have not been well documented.

The disease can be transmitted to humans and it is called psittacosis. In 1929, exposure to imported Amazon parrots from Argentina caused a pandemic in the United States and Europe and, since then, improved control of avian infections has decreased the incidence of psittacosis in human.

ETIOLOGY & EPIDEMIOLOGY

The etiology of Chlamydiosis is *Chlamydia psittaci*. This name is well accepted now and the old name *Chlamydophila psittaci* has been discontinued. *C. psittaci* has been placed in the order *Chlamydiales*, family *Chlamydiaceae*, genus *Chlamydia* and species *C. psittaci*. There are 8 serovars (A to F, M56 and WC) of *C. psittaci* but genotyping based on *ompA* (outer membrane protein A) gene analysis is more common now. The serovars and genotypes correlate well. Based on the analysis of *ompA* gene certain genotypes have been known to occur in a particular order of birds. For example, genotype D strain is often associated with chlamydia in turkeys but it can also infect pigeons, egrets and gulls. Similarly, genotype B is endemic in pigeons but can also infect turkeys, chickens and ducks. Genotype C is often associated with chlamydia in waterfowl (ducks, geese) but it has been detected in pigeons and chickens. Genotype A is most common in psittacines but it can infect turkeys, pigeons, chickens and passerines. Genotype E has been isolated from various species of birds including turkeys, pigeons, ducks,

ostrich and rhea. Other genotypes identified include F in psittacines but also in turkeys and E/B in ducks but also in parrots, turkeys and pigeons. M56 was isolated from muskrats and hares and WC from cattle, dogs, cats and horses. All avian genotypes should be considered to have the potential to cause disease in humans. Other species of chlamydia that have been isolated from birds include *C. abortus*, *C. muridarum*, *C. suis*, *C. pecorum*, and *C. trachomatis*. Recently other strains of chlamydia have been isolated from birds: *C. gallinacea* from chickens, *C. avium* from pigeons and *C. ibidis* from ibis.

Chlamydia is an obligate intracellular Gram-negative bacterium with a unique nonsynchronous life cycle in the cytoplasm of the host cell within a non-acidified vacuole, called inclusion. Unlike bacteria that replicate in the host cell cytoplasm having free access to cytosolic nutrients, *C. psittaci* imports host nutrients across the inclusion membrane. Three morphologically distinct forms of chlamydia have been recognized: elementary body (EB), reticulate body (RB) and intermediate body (IB). EB is the infectious form of the organism, a small electron-dense spherical body which measures about 0.2 to 0.3 μm in diameter. It is characterized by a highly electron-dense nucleoid, located at the periphery and clearly separated from an electron-dense cytoplasm. After entering the cell the EB converts to RB, which is the intracellular metabolically active form. RBs measure about 0.5 to 2.0 μm in diameter and they multiply by binary fission maturing into new EBs. During this process IBs measuring about 0.3 to 1.00 μm in diameter can be observed in cells by light or electron microscopy.

Chlamydiosis is a worldwide problem in turkeys, ducks, psittacines, pigeons, recently in chickens and other species of birds. It can cause significant economic losses to the poultry industry especially to the turkey industry. However, its greatest impact may be zoonosis; personnel in various segments of the poultry and pet bird industry are at risk. There are many reports of chlamydiosis in workers in the turkey abattoirs. Others include workers on the poultry farms, hatcheries, pet stores, owners of pet and other birds, aviculturists, veterinarians, diagnosticians, technicians, etc. Transmission to humans is primarily through inhalation of the bacteria. Incubation period can range from 1 to 2

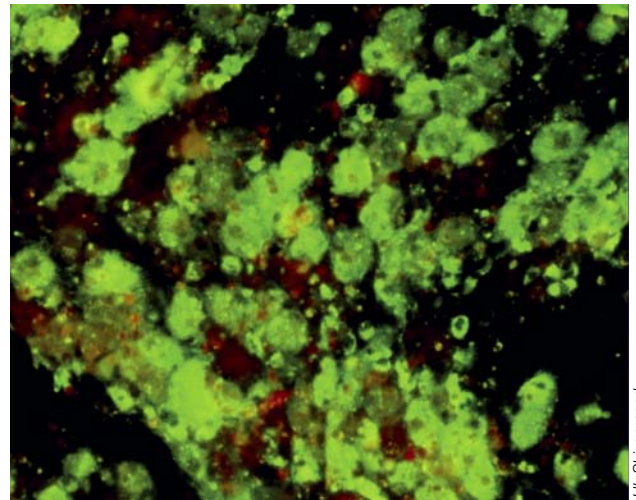
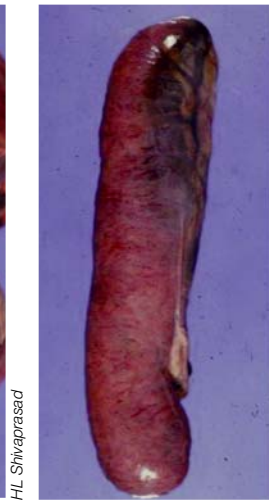
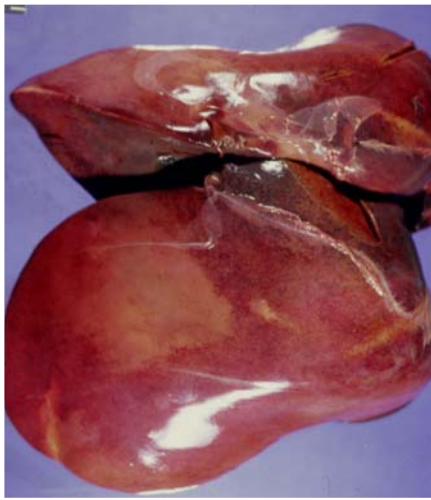
Fig.40.4 & 40.5: Avian chlamydiosis (Rhea). Enlarged liver with pale areas of necrosis (on left) and splenomegaly (on right).

Fig.40.6: Avian chlamydiosis. Immunofluorescence test of spleen smear from a psittacine strongly positive in the cytoplasm of macrophages.

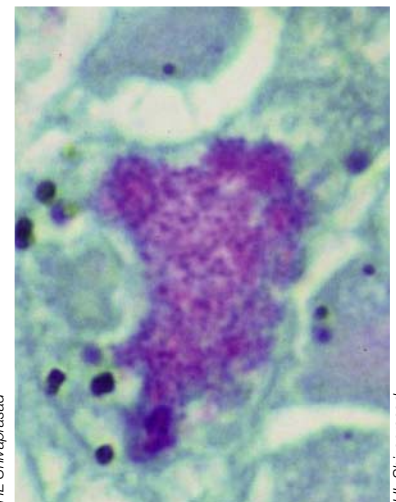
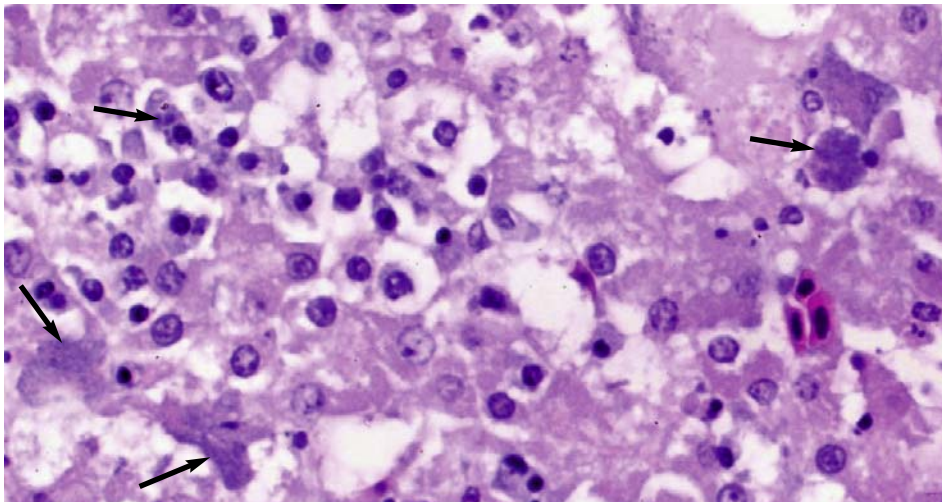


Fig.40.7: Avian chlamydiosis. Hepatitis associated with elementary bodies (arrows) in the cytoplasm of hepatocytes and macrophages (hematoxylin & eosin).

Fig.40.8: Avian chlamydiosis. Elementary bodies (purple color) in the macrophage of the liver of a psittacine (PVK stain).

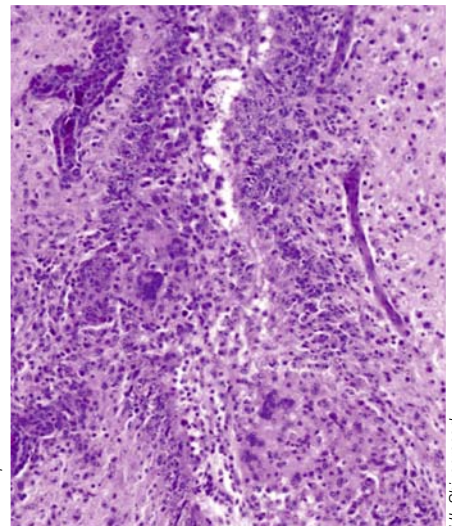
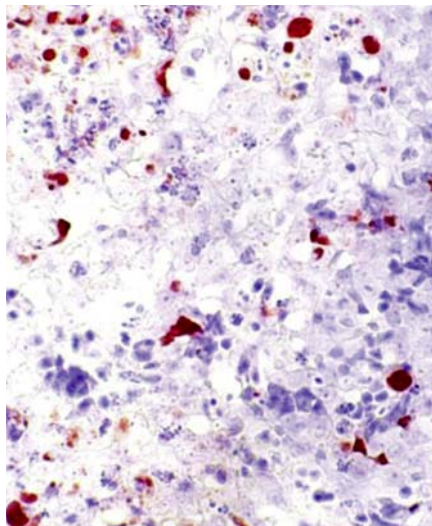
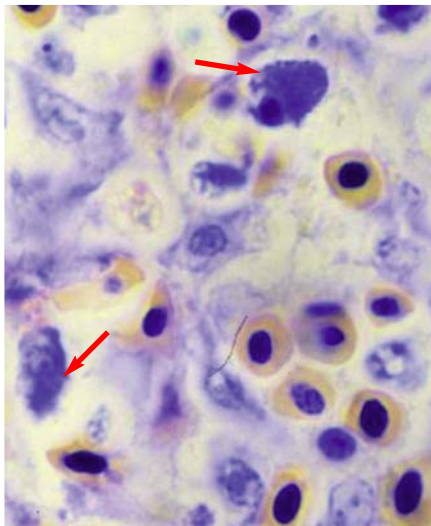


Fig.40.9: Avian chlamydiosis. Elementary bodies in inclusions (arrows) of cells in the liver of a psittacine (Giemsa).

Fig.40.10: Avian chlamydiosis. Positive chlamydia antigen (brown) in the mononuclear inflammatory cells of the spleen in a psittacine (immunohistochemistry).

Fig.40.11: Avian chlamydiosis (Pigeon). Brain with severe meningoencephalitis (hematoxylin & eosin).

weeks or more and clinical signs include flu-like symptoms and occasionally pneumonia, endocarditis, encephalitis and death if not treated promptly.

CLINICAL SIGNS & LESIONS

Clinical signs and lesions due to *C. psittaci* in birds depend on the virulence of the chlamydia strains, age, immune status, concurrent diseases and species of the birds affected. Strains that cause severe disease in one avian species can be mildly virulent or asymptomatic in others. Generally younger birds are more susceptible than adults. Adults may or may not show any clinical signs and can be carriers. Stress due to nutritional deficiency, overcrowding, adverse environmental temperature, transportation, handling, egg laying and breeding can influence clinical signs and shedding of bacteria. Fecal shedding of chlamydia occurs intermittently but it is more consistent through the respiratory tract. Wild birds, sick birds, contaminated feed, water and equipment can be sources of infection. Transmission of *C. psittaci* primarily occurs through inhalation of contaminated air or through ingestion of contaminated feed and water. Contact as well as vertical transmission has been reported. Ectoparasites can also transmit the disease. Transmission from parents to young through feeding of contaminated regurgitated feed like in pigeons, cormorants, herons, egrets as well as consumption of contaminated carcasses by raptors are other modes of transmission.

In birds the incubation period of *C. psittaci* can vary from 5 to 10 days or more depending on many factors listed before. Similarly, clinical signs also vary but include anorexia, lethargy, ruffled feathers, coughing, nasal and ocular discharge, loose green droppings, and loss of weight and decreased egg production. Occasionally neurological signs can be observed in ducks, geese, psittacines and pigeons. In turkeys, one of the unique and unusual clinical sign is the unilateral or bilateral swelling above the eyes resulting in swollen eyelids. Morbidity and mortality are variable depending on the species and age of birds affected, virulence of the organism, concurrent infections, but in general it ranges from 1 to 20%. Morbidity as high as 80% and mortality of 30% and 50% have been reported in ducks and psittacines, respectively.

Lesions due to *C. psittaci* can be variable depending on the species of birds affected as well as various other factors listed above for clinical signs. In turkeys the most common lesion described is the accumulation of a fibrinous exudate in the air sacs, pleura, pericardium and capsule of the liver. Liver

and spleen may be dark and enlarged. Other lesions include conjunctivitis, keratitis, sinusitis, enteritis and congestion of ovary and testes. Lesions in turkeys can be complicated due to concurrent infections with *Escherichia coli*, *Ornithobacterium rhinotracheale*, *Mycoplasma* spp., or avian metapneumovirus. Microscopically the lesions can range from mild to severe fibrinoheterophilic inflammation in acute stages to lymphoplasmacytic and macrophage infiltration in subacute to chronic stages. One of the unusual and only lesions of chlamydiosis that can be observed in turkeys sometimes is swelling above one or both eyes. This is due to the result of fibrinoheterophilic inflammation of the lateral nasal (salt) glands which are present in the dorsolateral aspect of the extra-orbital region of the nasal cavity.

The most common lesions seen in psittacines are hepatosplenomegaly, although fibrinous airsacculitis, pleuritis, pericarditis, perihepatitis, meningitis and pneumonia can also be observed. Similar lesions can be seen in other species of birds. Microscopically small basophilic coccoid bacteria either elementary or reticulate bodies of chlamydia can be observed in the cytoplasm of macrophages and epithelial cells on H&E stain. Pierre Van der Kamp (PVK), and modified Gimenez stains reveal purple coccoid bacteria while Giemsa stain reveals blue bacteria in the cytoplasm of infected cells. Formations of chlamydia inclusions are rare in birds.

DIAGNOSIS

1. **A tentative diagnosis of chlamydiosis** can be made based on clinical signs and pathology in birds. Swelling above the eyes due to nasal gland adenitis is quite unique and characteristic of chlamydiosis in turkeys. However, confirmation of chlamydiosis by test is necessary in order to take preventive and therapeutic measures.

2. **Several serological tests** such as Complement Fixation Test (CFT), Enzyme-Linked Immunosorbent Assay (ELISA) and Elementary Body Agglutination test (EBA) can be used to tentatively diagnose chlamydiosis. However, none of these tests are particularly useful in diagnosing active or current chlamydia infections because of the high incidence of infections and long lasting antichlamydial antibodies (up to several months) in birds unless paired sera are used. Other factors such as treatment of birds for chlamydia, or timing of blood taken prior to seroconversion, lack of commercial antigens for tests such as CFT, low sensitivity of EBA, labor and cost of reagents are limiting factors for performing these tests.

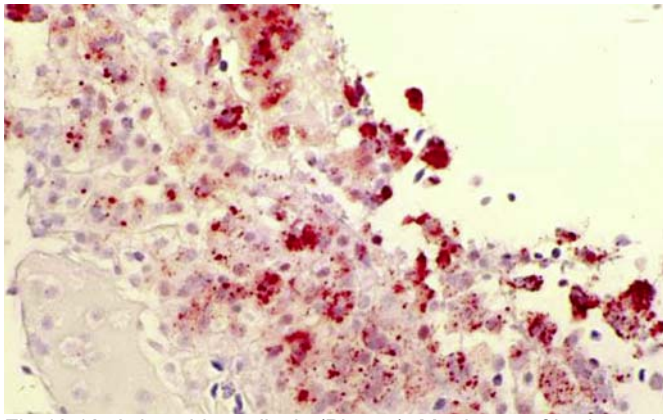


Fig.40.12: Avian chlamydiosis (Pigeon). Meninges of brain positive for chlamydia in inflammatory cells (immunohistochemistry).

HL Shivaprasad

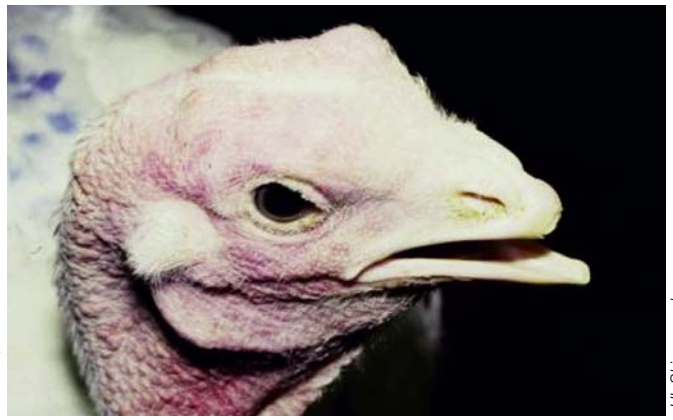

Fig.40.13: Avian chlamydiosis. Turkey with unilateral swelling above the left eye due to nasal gland adenitis.

HL Shivaprasad

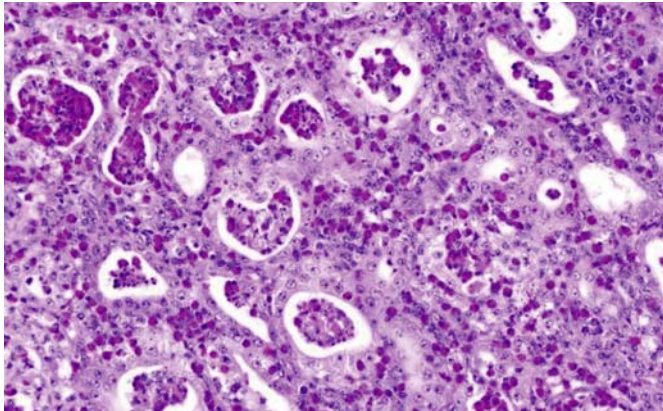


Fig.40.14: Avian chlamydiosis. Severe inflammation of the nasal glands in a turkey (hematoxylin & eosin).

HL Shivaprasad

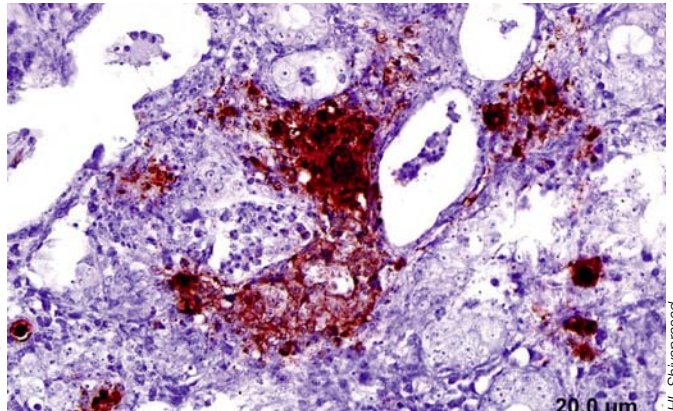


Fig.40.15: Avian chlamydiosis. Positive antigen of chlamydia in the nasal glands, inflammatory cells and debris (immunohistochemistry).

HL Shivaprasad

3. **Indirect immunofluorescence (IIF)** can be used for diagnosis of chlamydia as the reagent is readily available. It is rapid, less expensive and easier to perform. But IFF can give false positive results as the reagent tends to cross-react with other bacteria, making it difficult to interpret the results.

4. **Cytology** with the aid of special stains on the exudate from oropharyngeal and conjunctival swabs from live birds or smears from the air sac, liver, spleen and conjunctiva from dead birds can also be used for the diagnosis of chlamydiosis. Similarly histopathology of various organs with the aid of special histochemical stains is helpful in the diagnosis of chlamydiosis.

5. **Immunohistochemistry** - detection of chlamydial antigen in the cytoplasm of cells of various organs - is becoming a common diagnostic test as it is rapid, easy to perform, accurate and inexpensive.

6. **Polymerase Chain Reaction (PCR) tests** such as nested PCR, real time PCR and others are also becoming readily available for diagnosing chlamydiosis. These tests have the advantage of being accurate, rapid and inexpensive, provided the samples are not degraded.

7. **Isolation of chlamydia** from birds can also be performed from suitable specimens by the use of cell cultures and inoculation into the yolk sac of 6-day-old SPF embryonating chicken eggs. Various cell lines such as BGM (Buffalo Green Monkey kidney cells), McCoy (mouse fibroblasts), Vero (monkey kidney epithelial cells), HeLa (human cervical epithelial cells), L-929 (mouse fibroblasts) and others including chicken embryo fibroblasts have been used to isolate chlamydia. Identification of chlamydia in these systems is made by immunofluorescence assay (IFA) on the smears or other techniques such as PCR. Even though these tests provide accurate diagnoses they are labor intensive, expensive and time consuming.

Most importantly, the risk of contracting chlamydia or psittacosis should be considered, so that *C. psittaci* can be cultured only in laboratories with biosafety level 3 facilities.

8. **Chlamydia species** can be further determined by various molecular methods. These include analysis of full-length 16S and 23S rDNAs, multi-locus sequence typing (MLST) and DNA microarrays. Other sensitive tests that can distinguish chlamydia within the same species are multi locus variable-number tandem-repeats analysis (MLVA), and ompA gene sequencing. But most of these techniques are available only in research laboratories.

TREATMENT & CONTROL

No vaccine is available for avian chlamydiosis.

For poultry flocks and outdoor aviaries, biosecurity is the best method for prevention of chlamydiosis. Birds should be reared in confinement with good sanitation and no contact from feral and wild birds, rodents, insects, visitors, *etc.* Ovotransferrin, a natural anti-microbial protein has been successfully used in reducing clinical signs, lesions, excretion and replication of chlamydia in experimentally infected SPF turkeys. For treatment, the drugs of choice are chlortetracycline and doxycycline but enrofloxacin can also be used.

Turkeys infected with chlamydia should be treated with chlortetracycline (CTC) at a concentration of 400 g/ton of pelleted feed for two weeks and then replaced with non-medicated feed for two weeks before slaughter. Doxycycline and enrofloxacin can also be used in drinking water for 3 to 10 days depending upon the chronicity of the disease.

In pet birds like psittacines treatment with doxycycline in drinking water for 45 days is recommended.

In many countries (Australia, US, most European countries) chlamydiosis in birds is a reportable disease to state veterinarian and public health officials. However, regulations may vary from country to country and, as such, the local authorities should be consulted for appropriate actions to be taken.

REFERENCES

- Anderson DC et al. Psittacosis outbreak in employees of a turkey-processing plant. *Am J Epidemiol*, 1978,107:140-148.
- Durfee PT et al. Human psittacosis associated with commercial processing of turkeys. *JAVMA*, 1975, 167:804-808.
- Filstein MR et al. Epidemic of Psittacosis in a College of Veterinary Medicine. *JAVMA*, 1981,179:569-572.
- Kuo C & Stephens R, 2011. Family I. Chlamydiaceae. In: Whitman, William B. (Ed.), *Bergey's Manual of Systematic Bacteriology*. Second Ed. Springer Science/Business Media, New York, USA, pp. 845.
- Laroucau K et al. Isolation of a new chlamydial agent from infected domestic poultry coincided with cases of atypical pneumonia among slaughterhouse workers in France. *Infect Genet Evol*, 2009,9:1240-1247.
- Page LA & Bankowski R. Investigation of a recent ornithosis epornitic in California turkeys. *Am J Vet Res*, 1959,20:941-945.
- Page LA et al. An epornitic of fatal chlamydiosis (ornithosis) in South Carolina turkeys. *JAVMA*, 1975,166:175-178.
- Riddell C & Roepke D. Inflammation of the nasal gland in domestic turkeys. *Avian Dis*, 1991,35:982-985.
- Sachse K et al. Evidence for the existence of two new members of the family Chlamydiaceae and proposal of *Chlamydia avium* sp. nov. and *Chlamydia gallinacea* sp. nov. *Syst Appl Microbiol*, 2014 Jan 22. [Epub ahead of print]
- Shivaprasad HL et al. Two unusual cases of chlamydiosis (ornithosis) in turkeys. *JAVMA Proceedings*, 1996,209:373-374.
- Tappe JP et al. Respiratory and pericardial lesions in turkeys infected with avian or mammalian strains of *Chlamydia psittaci*. *Vet Pathol*, 1989,26:386-395.
- Vanrompay D. Avian Chlamydiosis. In: *Diseases of Poultry*, 13th ed., Swayne, D, et al. (Ed.), Wiley-Blackwell Publishing, Ames, Iowa, 2013, pp 1055–1073.
- Yin L et al. Emerging *Chlamydia psittaci* infections in the chicken industry and pathology of *Chlamydia psittaci* genotype B and D strains in specific pathogen free chickens. *Vet. Microbiol*, 2013,162:740-749.

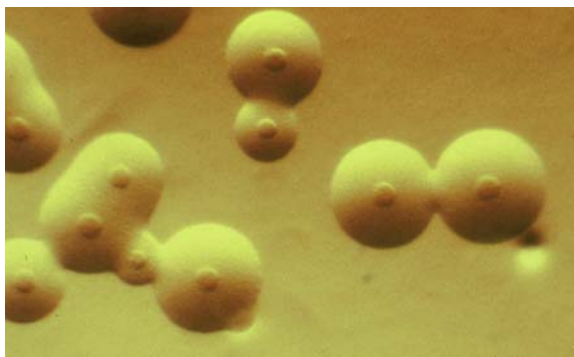


Fig.41.1: Typical mycoplasma colonies (fried-egg appearance) at low magnification.



Fig.41.2 & 41.3: Tubes of mycoplasma liquid medium. The non-inoculated tubes are red. The inoculated tubes with mycoplasma growth show a yellow color change of the phenol red indicator. This phenol red indicator in microtiter format allows determination of minimum inhibitory concentrations (MIC).




Fig.41.4: A tracheal swab can be done in order to obtain a culture of *Mycoplasma* spp. from a live bird.



Fig.41.5 & 41.6: Tracheitis linked to MG (scanning electron micrograph). Compare the normal trachea (left) with the affected trachea with numerous deciliated and edematous epithelial cells (right).

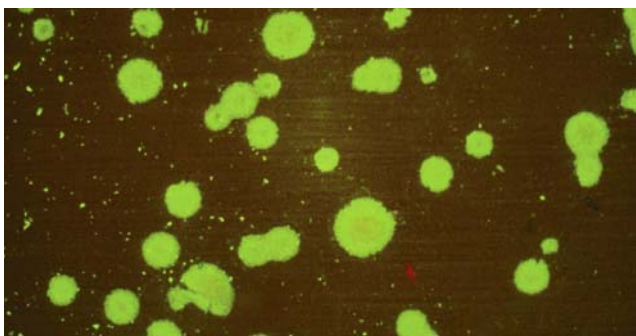


Fig.41.7: Immunofluorescence of mycoplasma colonies. MG colonies, stained by species-specific fluorescein labeled antiserum, are bright green. Other colonies are less distinct (x 100).



Fig.41.8. & 41.9: MG. Sinusitis in two poults.



Fig.41.10: MG (breeder male). Note cyanosis of the comb and the wattles.



Fig.41.11: MG (breeder male). Note the conjunctivitis.



Fig.41.12: MG (breeder male). Note the conjunctivitis, the cyanosed comb and the nasal discharge with dust and pieces of litter sticking to the nostrils.

Bacterial diseases

41. AVIAN MYCOPLASMOSIS

INTRODUCTION

Many mycoplasma species can infect birds, but only *Mycoplasma gallisepticum* (*MG*), *M. synoviae* (*MS*), *M. meleagridis* (*MM*) and *M. iowae* (*MI*) are considered pathogenic in chickens and turkeys, and can cause economic losses due to stunted growth, condemnations associated with lesions, or synovitis, airsacculitis, decreased egg production, and decreased hatchability. Worldwide, the incidence of mycoplasma infection is favored by the intensification of poultry production.

ETIOLOGY

Mycoplasma spp.

Mycoplasma bacteria are small (about 200 nm) without a cell wall, bounded by a single cell membrane and possessing a small genome (about 600 to 1300 kbp). Consequently, their biosynthetic capabilities are limited and these organisms require complex culture media containing serum, a source of cholesterol and fatty acids. On agar, viewed with some magnification, typical colonies show a «fried egg» morphology after several days of incubation. The absence of a cell wall explains the fragility of these microorganisms and their insensitivity to antibiotics degrading or inhibiting bacterial cell wall synthesis, such as β -lactamines or cephalosporins.

Other factors

Chronic respiratory disease (CRD) in chicken results from infection with *MG* often associated with other infectious agents, such as wild-type or vaccine viruses (Newcastle disease, coronavirus, metapneumovirus, *etc.*) or bacteria (*Escherichia coli*, *Haemophilus* spp., *Pasteurella* spp., *Ornithobacterium rhinotracheale*, other *Mycoplasma*, *etc.*) or fungi (*Aspergillus*, *etc.*). Similarly, the pathogenicity of *MS* is exacerbated in association with bacteria or viruses with similar respiratory or articular tropism (reovirus, *etc.*). Poor environmental conditions (excessive levels of ammonia, dust, humidity, misadjusted ventilation, *etc.*) stress on birds (social stress, handling, vaccinations, selection, beak conditioning, *etc.*), nutritional deficiencies and parasitism could also be predisposal or aggravating factors.

PATHOGENICITY

The pathogenicity of avian mycoplasmas depends on several factors (host, species and strain of *Mycoplasma*, *etc.*). Thus, for example, *MI* is pathogenic for turkeys and not for chickens, and there are low pathogenic strains of *MG* naturally or artificially used as vaccines. Avian mycoplasmas have tropism for the respiratory tract, the joints and the genital tract especially in turkeys. Studies reveal the sophistication of the pathogenic mechanisms implemented by these bacteria. They have genetic systems allowing them to quickly change the nature and structure of their surface membrane proteins: membrane antigens may differ in their expression (+/-), their characteristics (size variation) and accessibility of their epitopes. These phenomena can be observed *in vitro* as well as *in vivo*. This variability seems to be a crucial evaluative mechanism allowing this microorganism to escape from the immune reactions of the host and explains its persistence. Attachment of *Mycoplasma* to cells of the host through adhesins, genes encoded in multiple copies of *MG* and *MS*, ciliostasis phenomena, release of toxins, nucleases or peroxides and consumption of essential metabolites for the host cells are other virulence factors.

EPIDEMIOLOGY

In the modern poultry world, the selection or breeding flocks are most often free of *MG* and *MS*. But *Mycoplasma* spp. contamination is still common in production flocks, especially if located in areas with high poultry density.

Generally considered as fragile bacteria, the avian mycoplasmas can nevertheless survive for several days in the external environment, in particular on feathers or diverse materials: for example, *MG* is viable for 61 days under dry conditions at 4°C, or 5 days in the water of wells; *MI* survives 6 days on human hair. On farms, the most frequent mode of infection for *MG* or *MS* is the respiratory route. Transmission occurs primarily by direct contact between sick or latent carriers and susceptible birds. Indirect transmission through human activity, wild birds or insects or livestock equipment is also possible.



Fig.41.13: MG (Turkey). Sinusitis and severe respiratory signs.



Fig.41.14: MG (Turkey). Severe bilateral sinusitis. Note the soiled feathers at the base of the neck.



Fig.41.15: MG (breeder female). Sinusitis and clear nasal discharge.



Fig.41.16: MG (experimentally infected turkey). Advanced case of bilateral infectious sinusitis showing marked swelling of infra-orbital sinuses and nasal exudate.

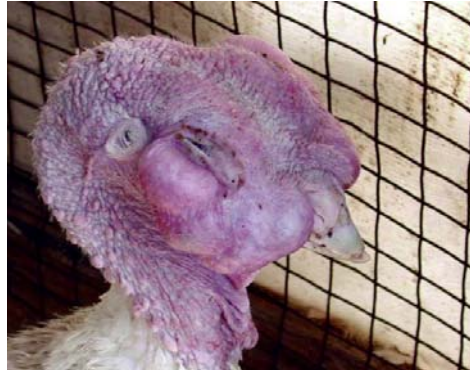

Fig.41.17: MG (Turkey). Co-infection MG and lentogenic Newcastle disease virus.

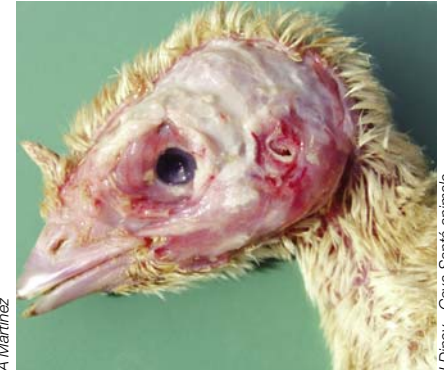

Fig.41.18: MG (Turkey). Note the diffuse accumulation of the fibrinous exudate after removal of the overlying skin.



Fig.41.19: MG. Sinusitis is rarely observed in hens infected with MG.

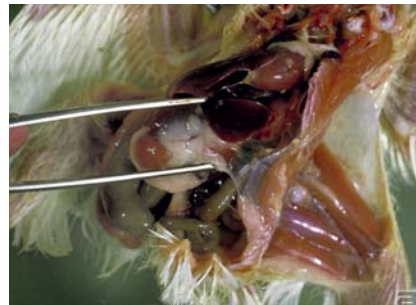


Fig.41.20: Normal air sacs of a chicken. They should appear as a thin, transparent membrane.

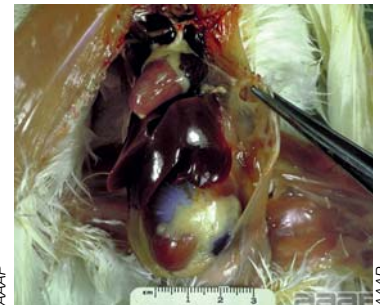

Fig.41.21: MG (Broiler chicken). Aisracculitis of the posterior thoracic air sac.

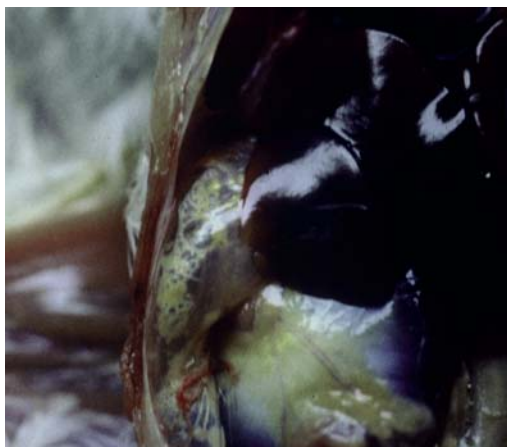


Fig.41.22: MG (Broiler chicken). Aisracculitis of the abdominal air sac.

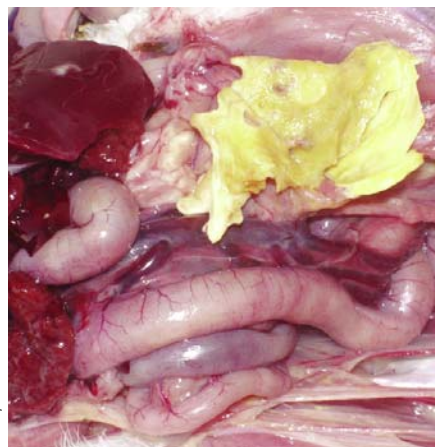
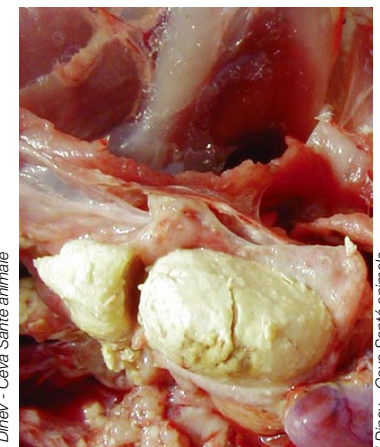


Fig.41.23 & 41.24: MG. The fibrino-caseous exudate observed in the air sacculitis (left) can become dense and compact (right).



In addition, *MG* and *MS* can be transmitted vertically through the egg, either by contamination of the embryo by blood route, or because of contiguity between the oviduct and the infected air sacs. The percentage of infected eggs remains limited but probably allows the spread of infection in the hatchery and then the farms. The rate of vertical transmission would be greater in the first weeks of infection.

The location of *MM* and *MI* in turkeys' genital tract of provides an important venereal transmission through the infected semen with artificial insemination, as well as vertical transmission due to the contamination of the oviduct. The number of infected eggs appears to be lower at the beginning and the end of the laying period. Horizontal transmission is also possible either by direct contact between birds or through intervention teams (sexing, insemination). The transmission rate of infection in poultry depends on the density of the flock and the extent of the reservoir. Environmental factors that exacerbate the disease, such as high levels of ammonia or concurrent infections may increase the excretion of *Mycoplasma* and hence the speed of transmission.

In some cases, the development of infection may be more or less severe as a result of various stresses (transfers, at the onset of laying, etc.). Dissemination of *MS* seems generally faster than that of *MG*. However some strains of *MG* or *MS* show a low transmissibility and development of infection in a flock with these strains is slower.

CLINICAL SIGNS & LESIONS

Mycoplasma gallisepticum

Alone or in combination with other pathogens, *MG* is the agent of the CRD. Under experimental conditions, the incubation period is around five to ten days, but under natural conditions, this duration is sometimes much higher. Birds from infected breeders (especially if they or their eggs were treated with antibiotics) can present clinical signs and/or seroconvert only after several months.

Clinical signs include coryza, sneezing, nasal discharge, coughing, tracheal rales and dyspnea. The most severely affected birds remain prostrate, with open mouth breathing. Growth rate is slowed, the rate of lay decreases (about 10-15 eggs less per hen), and the percentage of poor quality eggs may increase. In turkeys, an infra-orbital

unilateral or bilateral sinusitis may be observed, and prevents birds from opening the eyes and thus impairs feed intake. Morbidity is often high, and the mortality varies according to the age of birds and the occurrence of surinfections.

In the early stages of infection, the lesions are limited to a catarrhal inflammation of the airways and a beaded appearance or edema of the air sacs. Then, a fibrinous inflammation of air sacs and sometimes internal organs (peritoneum, hepatic capsule) may be observed. In turkeys, the sinuses are filled with an abundant serous mucus and then caseous material. Lesions of the respiratory tract can be severe in birds showing few clinical signs. Lesions of pneumonia, keratoconjunctivitis, tenosynovitis, arthritis or salpingitis have been occasionally reported.

Mycoplasma synoviae

The first signs of infection by *MS* consist of paleness of the comb, stunting, and swollen joints (hence the name of «infectious synovitis»). The acute joint damage includes edema of synovial membranes, periarticular tissue and tendon sheaths. In turkeys, a viscous exudate, then creamy even cheesy or fibrino-purulent, is found in the joints of the legs, which are amyotrophied, and in more severe forms, in the skull and cervical vertebrae. Breast blisters are frequently observed. In chronic forms, the joints remain swollen and the birds are reluctant to move. Morbidity is around 10% but varies widely depending on the virulence of strains, sometimes leading to very important condemnations in the slaughterhouse. The infection of the respiratory system by *MS* is mostly subclinical, but many birds are carriers. When clinically expressed, the clinical signs and lesions of the respiratory tract are similar to those observed with *MG* but are usually less severe.

Mycoplasma meleagridis

Mycoplasma meleagridis infects only turkeys and causes, in congenital infections, airsacculitis characterized by swelling and sometimes a yellowish exudate on the thoracic air sacs. These lesions then spread to the cervical and abdominal air sacs. In young birds, the infection may remain subclinical or cause stunting, abnormal feathering and deformity of the vertebrae or tarsometatarsal bones. In adult birds, the infection is often subclinical but hatchability may be reduced because of late embryonic mortality. Synergies between *MM* and

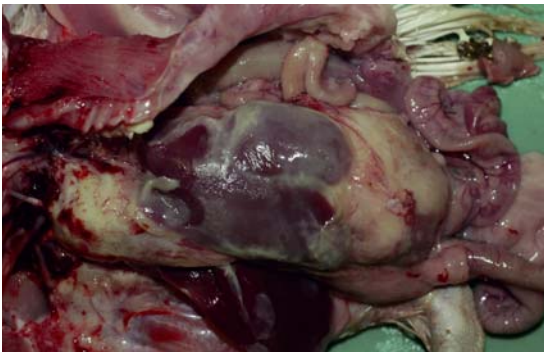


Fig.41.25: The classic triad of lesions (pericarditis, perihepatitis, airsacculitis) is a common sequelae when *Escherichia coli* infection occurs in MG-infected chickens with extensive condemnation of infected birds at slaughter and mortality.

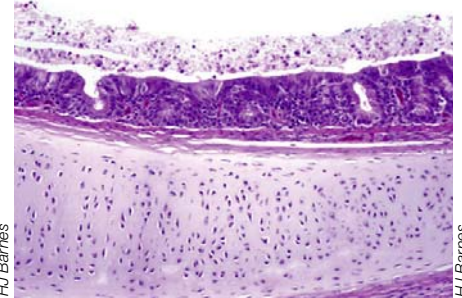
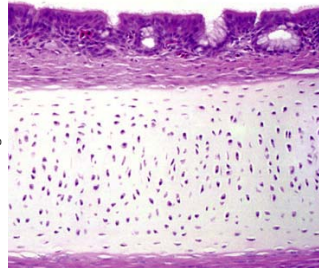


Fig.41.26 & 41.27: MG. Tracheitis (Turkey). By comparison with normal trachea (left), tracheal mucosa is increased in thickness due to a diffuse lymphocytic cell infiltration and cilia are absent. Layer of mucus with heterophils on the surface.

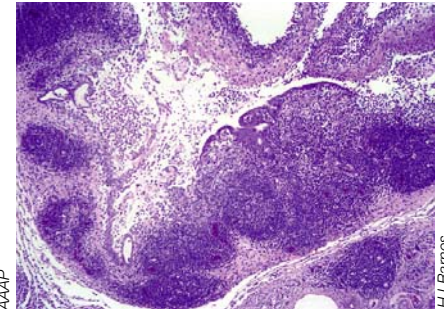
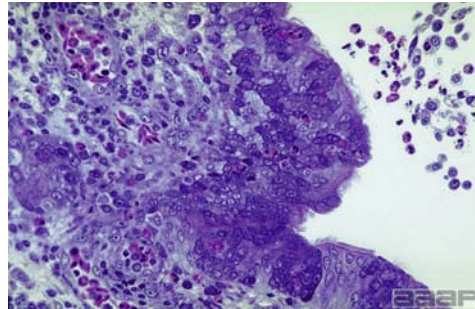
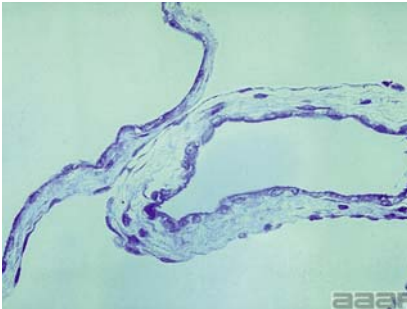

Fig.41.28, 41.29 & 41.30 : MG airsacculitis. By comparison with a normal air sac showing the simple squamous lining epithelium (left), the infected air sacs are greatly thickened due to epithelial cell hyperplasia, increased number of blood vessels, and infiltration by heterophils and lymphocytes (right). In Fig.41.30, lymphoid nodules are prominent.

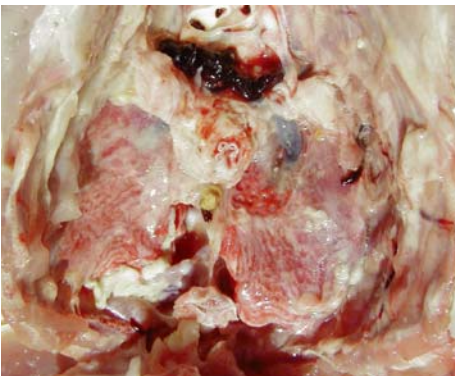


Fig.41.31: MG. Bilateral serofibrinous pneumonia.

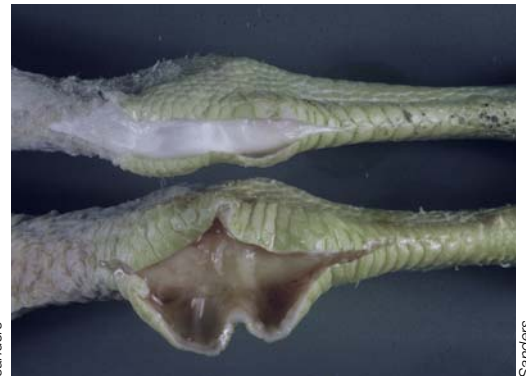
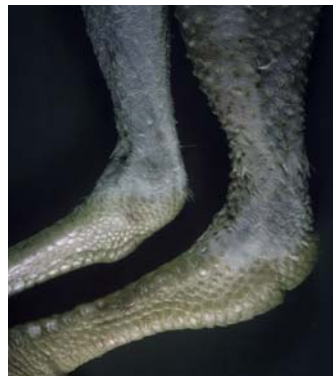
Fig.41.32 & 41.33: MS. Hock tendon areas swollen due to infectious synovitis produced by MS. This swelling is produced by inflammation of the affected joint (edema and thickening of the periarticular tissues, especially the synovial membranes) and/or the tendon sheaths. Comparison with normal bird (on the right on each figure).

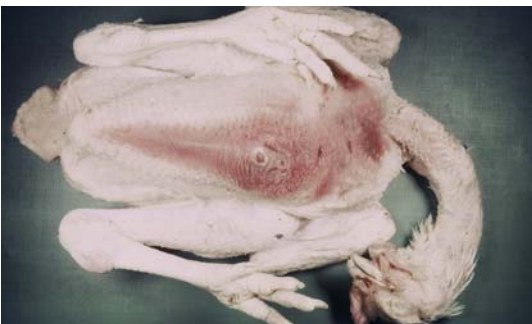

Fig.41.34: MS. In sternal bursitis there is enlargement of the bursa and accumulation of exudate. Enlarged foot pads.

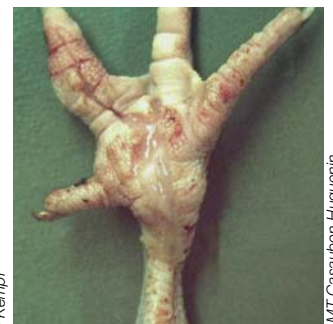
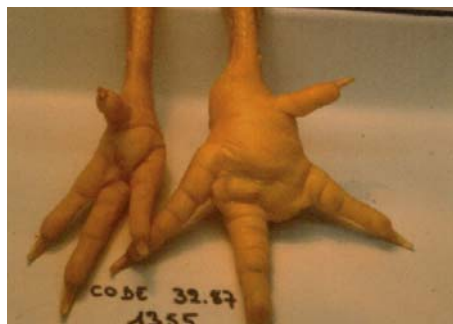
Fig.41.35 & 41.36: MS. Enlarged food pads are typical of infectious synovitis produced by MS. Upon incision, a viscous watery fluid almost flows out, but becomes more yellowish and caseated as the lesion becomes older and more chronic.

MI or *MS* have been described and are respectively the source of airsacculitis or sinusitis.

Mycoplasma iowae

In natural conditions, the infection of turkeys by *MI* is associated with a reduction of 5% to 20% of hatchability due to late embryonic mortality (18 to 24 days of incubation). The dead embryos are small, congested, and present a swelling of the head and the neck, urate deposits on the surface of the body and in the ureters, and hepatitis. Experimental infection of one day-old turkeys leads to airsacculitis, growth retardation, feather abnormalities and leg deformities (chondrodystrophy, curvature of bones, ruptures of the flexor tendons of the feet).

DIAGNOSIS

Because mycoplasma infections may remain sub-clinical or cause non-specific clinical signs and lesions, screening or diagnosis of infection should be performed in the laboratory. Detection of the bacteria can be performed by cultures from live birds (tracheal, cleft palate, sinuses, oviducts or cloaca swabs, semen); or sacrificed or dead birds (sinuses, trachea, air sacs, lungs, *etc.*). If typical mycoplasma colonies appear on culture, they may either be identified using immunofluorescence or immuno-enzymatic techniques, or be cloned and identified by determination of antigenic (growth inhibition assay for example), biochemical or genetic (PCR) characteristics. Cultures must be kept for at least three weeks before being considered negative. The methods of polymerase chain reaction (PCR) are sensitive and specific to detect the presence of mycoplasma DNA. Their interest lies in the rapidity of obtaining results and the ability to identify mycoplasmas in samples contaminated with bacteria or carrying several species of mycoplasma, or coming from birds treated with antibiotics, which makes it difficult to diagnose by culture.

The detection of mycoplasma infections can also be based on serological methods. During infection, systematic or local antibodies are produced, their protective role remaining limited. Immunoglobulin (Ig), class G mainly, are transmitted to the chick *via* the yolk. Antibodies can be detected during the first two weeks of life of the chick. The humoral immune response towards *MI* seems insignificant and there is no currently reliable serological test for this mycoplasma.

The rapid plate agglutination (RPA) test is widely used because of its simplicity and its low relative cost. The main advantage of this method is its earliness as it detects *IgM*, but its lack of specificity is sometimes a problem. Thus, for example, the presence of genes and antigens common to several species of mycoplasma, particularly between *MG* and *MS* may cause cross-reactions interfering with the interpretation of serological results.

Various precautions in taking samples, the method of analysis and the interpretation of results are recommended. When in doubt, repeat sampling can be used and analyzed after fifteen days, or other serological tests such as hemagglutination inhibition (HAI) or enzyme-linked immunosorbent assay (ELISA) can be performed. The HAI is indeed more specific than the RPA but detects mainly *IgG* that appears later. The difficulty of using HAI is related to the preparation and preservation of antigens. ELISA tests available now are more specific than the first kits marketed, but their relatively high cost still limits their use.

TREATMENT & CONTROL

The methods of mycoplasma infection control must take into account the particularities of these microorganisms: relatively low resistance in the environment, persistence in the infected animal, and mode of transmission (horizontal and especially vertical). Depending on the type of flock (genetic stock, breeders, meat-birds), the objective may be to eradicate or to simply reduce the level of infection in order to limit the economic consequences of mycoplasmosis.

Eradication programs must include the strict observance of the classic rules of biosecurity (disinfection, downtime, isolation and protection of the flock, «all-in, all-out» production, *etc.*) as well as appropriate programs of vaccination or prevention of the other bacterial and viral infections. Regular testing on a sufficient number of birds is made to ensure the absence of mycoplasma infections, and infected flocks have to be quickly eliminated. In some countries, official procedures describe these dispositions to control mycoplasma infections in the context of improving the health status of herds or trade between countries.

When breeder flocks are infected and the elimination of the flock is not economically feasible, it might be possible to reduce vertical transmission with antibiotics such as macrolides (erythromycin,

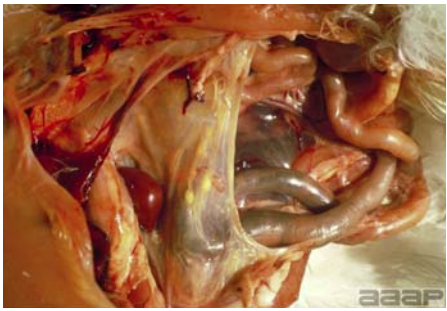

Fig.41.37: MS. Airsacculitis (severe thickening of the air sac membrane with large masses of caseous exudate containing cellular debris and increased vascular activity as the lesion is starting to regress).



Fig.41.38: MS. Some chickens may exhibit enlarged spleens and livers.



Fig.41.39: MS. Eggshell apex abnormalities (altered shell surface, increased translucence and cracks in the apex) are associated with MS infection.

Section III



Fig.41.40, 41.41 & 41.42: MM. Bowing of the tarsometatarsal bones of poults infected naturally with MM by the egg-borne route.

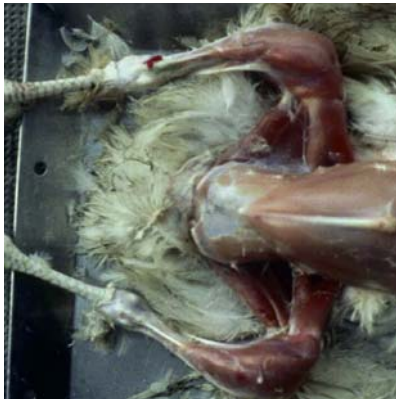
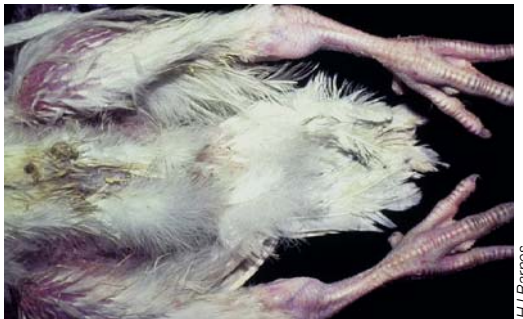
Fig.41.43: MM. Bowing of the tibiotarsal bones.

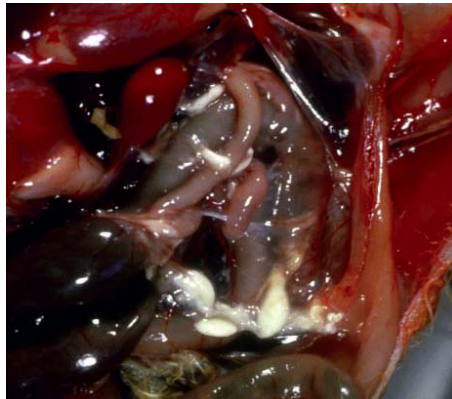


Fig.41.44: MM causing airsacculitis in poult. The thoracic air sacs are most commonly involved in egg-borne infections. Then the lesion progresses to the abdominal air sacs and regresses within 16 weeks in the absence of concurrent infection.



Fig.41.45: This flock of mature hens naturally infected (respiratory and reproductive tracts) with MM and did not show clinical signs. Infection status can be determined only by cultural, serological and PCR procedures.

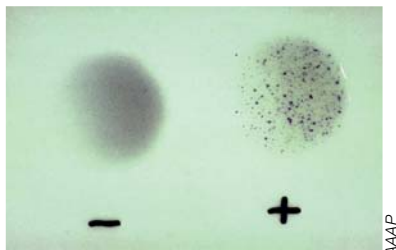


Fig.41.46: Serum-plate-agglutination test with MG antigen. The serum sample on the right is positive, and the sample on the left is negative.

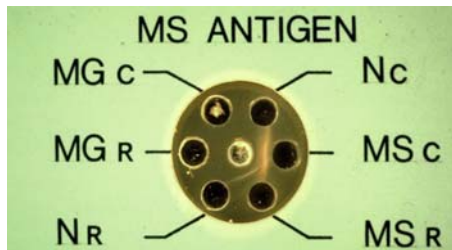


Fig.41.47: Agar gel precipitin test. Typical precipitin reaction between MS antigen (in the center well) and MSc (serum from known MS-positive chicken). MSr = serum from MS-inoculated rabbit, Nr = normal rabbit serum, MGr = serum from MG-inoculated rabbit, MGc = serum from known MG-positive chicken, Nc = normal chicken serum.




Fig.41.48: Micro-hemagglutination-inhibition (micro-HI) tests. Sera are diluted from top to bottom, beginning at 1/10. Sera in rows 2, 3, 4 are negative. Sera in rows 5, 6, 7 are positive (titers 1/640, 1/320 and 1/80). Rows 8 and 9 are antigen controls and row 10 and 11 are cell controls.

spiramycin, josamycin, lincomycin, tylosin), tetracyclines (tetracycline, chlortetracycline, oxytetracycline, doxycycline), spectinomycin, tiamulin or quinolones (where allowed). Treatments can be administered to adults or chicks, by injection or orally, in food or drinking water. The treatment of incubating eggs by dipping or injection of antibiotics has also been described, but the effects of these methods must be thoroughly evaluated, especially in terms of selection of antibiotic-resistant bacteria. Another technique consists of heating hatching eggs at a temperature of 46-47°C for approximately 12 hours, which limits infection but also reduces hatchability. All these procedures can reduce but not totally eliminate the level of contamination. These options must therefore be evaluated.

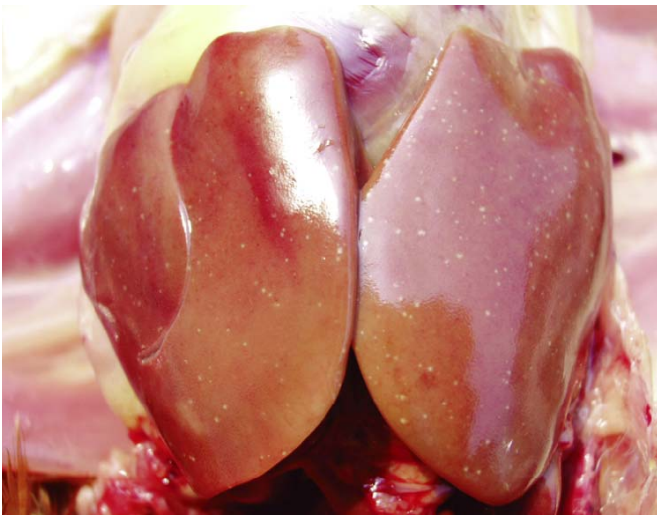In production flocks, treatments are administered either at a suspected infection of the flock during critical periods of breeding, or at the onset of the clinical signs. The antibiotics must reach sufficient concentrations in organs and tissues of the respiratory or genital tract and joints, and must also be effective against secondary bacterial infections.

The economic consequences of mycoplasma infection and the difficulty of controlling it, especially in multi-age farms, have generated interest in vaccine development. Thus, many types of vaccines have been developed for *MG*. Inactivated vaccines are marketed in some countries. They induce a humoral immune response but do not prevent the infection of birds. A local inflammatory reaction is observed at the injection site. Live vaccines have also been developed. The *MG* vaccine strain F, of

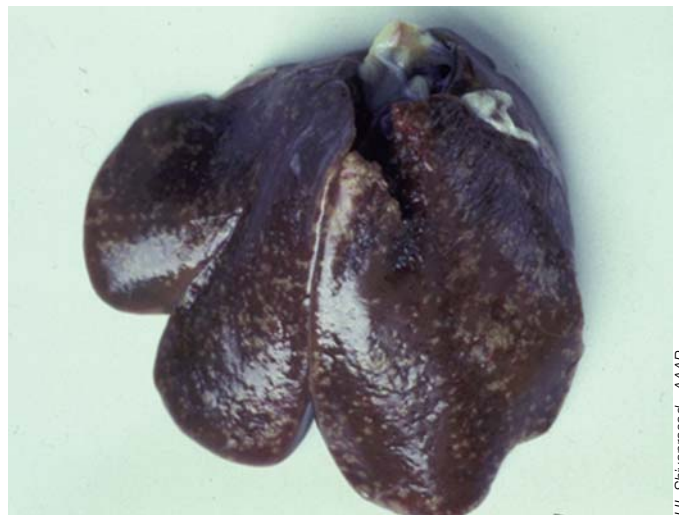moderate virulence, administered by different routes can spread in the farm; its residual pathogenicity is worth mentioning and it limits its use. The *MG* vaccine strains TS11 and *MG* 6/85, are less virulent and may also be employed. They spread less and induce a low humoral response. Under experimental conditions, it can be shown that some of these vaccine strains prevent infection by a wild strain and successive rounds of immunization may eventually eliminate the wild strain from a flock. Inactivated or live vaccines should be used only as a last resort when traditional measures of biosecurity do not control the infection. The last category of vaccines are vectored vaccines. They offer protection while not spreading to other flocks since they only contain fractions of the genome and not the whole mycoplasma. This makes it possible to use antibiotics at the same time if necessary.

REFERENCES

- Bradbury JM & Kleven SH. In "*Diseases of poultry*", Ed. Saif YM et al. Blackwell Publ., Ames 2008, pp 856-862.
- Kleven SH. In "*Diseases of poultry*", Ed. Saif YM et al. Blackwell Publ., Ames 2008, pp 805-807.
- Kleven SH & Ferguson-Noel N. In "*Diseases of poultry*", Ed. Saif YM et al. Blackwell Publ., Ames 2008, pp 845-856 & 862-864.
- Ley DH. In "*Diseases of poultry*", Ed. Saif YM et al. Blackwell Publ., Ames 2008, pp 807-845.
- Stipkovits L & Kempf I. Mycoplasmoses in poultry: an overview. *Rev sci tech OIE*, 1996,15:1495-1525.
- Whithear KG. Control of avian mycoplasmoses by vaccination, *Rev sci tech OIE*, 1996,15:1527-1553.

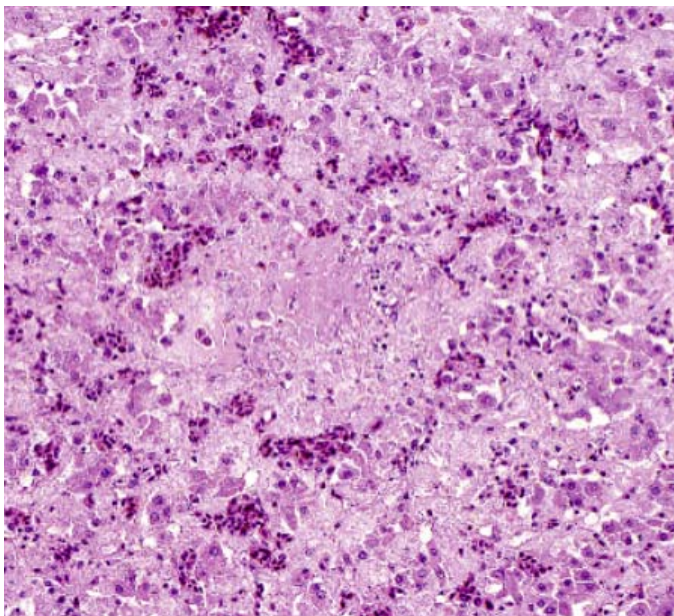


/Dinev - Ceva Santé animale



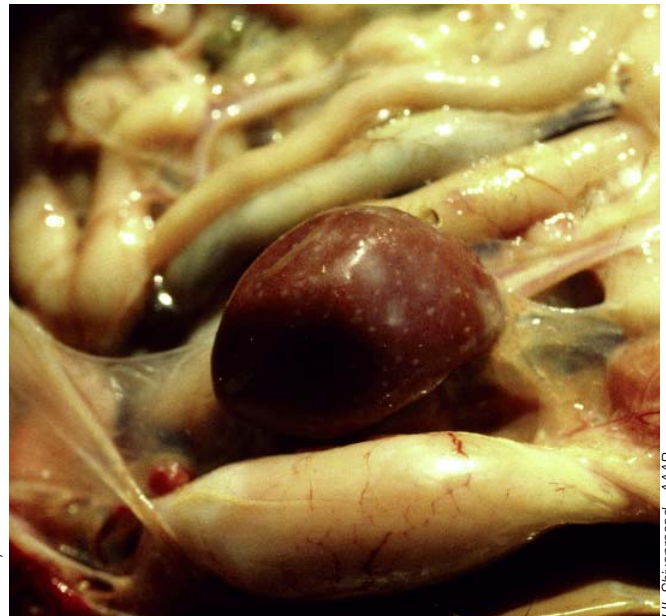HL Shivaprasad - AAAP

Fig.42.1 & 42.2: Pullorum disease. Enlarged and congested livers with white foci of necrosis.



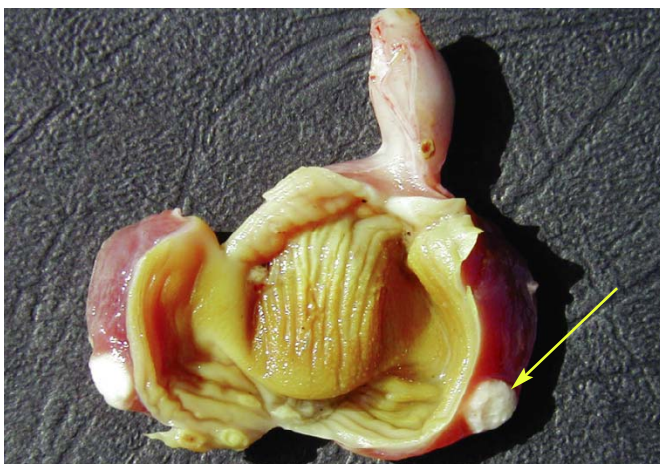
HL Shivaprasad - AAAP

Fig.42.3: Pullorum disease. Photomicrograph of the liver showing a focus of necrosis with fibrin exudation.



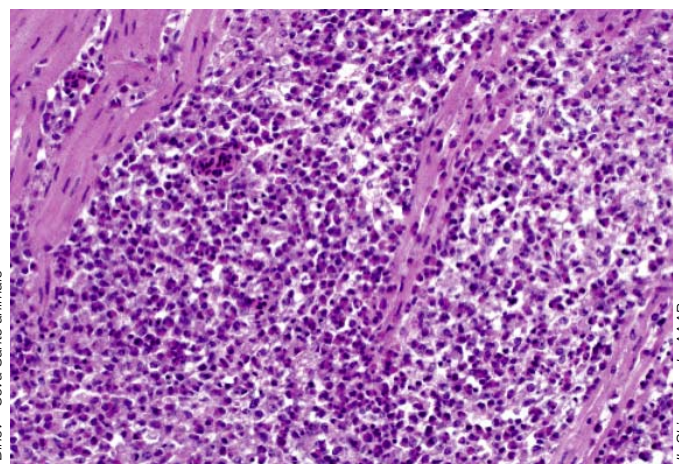
HL Shivaprasad - AAAP

Fig.42.4: Pullorum disease. White mottling and enlarged spleen.



/Dinev - Ceva Santé animale

Fig.42.5: Pullorum disease. Sometimes, grey-whitish nodules of various sizes (arrow) are found outside the liver, like in the wall of the gizzard.



HL Shivaprasad - AAAP

Fig.42.6: Pullorum disease (gizzard). Photomicrograph showing severe necrosis of muscle fibers and infiltration of heterophils and a few lymphocytes and macrophages.

Bacterial diseases

42. PULLORUM DISEASE & FOWL TYPHOID

INTRODUCTION

Pullorum disease (PD) and fowl typhoid (FT) are septicemic bacterial diseases primarily of chickens and turkeys, but other birds such as quails, pheasants, ducks, peacocks, and guinea fowls are susceptible. PD and FT have been recognized since 1899 and 1888, respectively. PD and FT are common diseases in many parts of the world, where they cause major economic losses. But the diseases have been eliminated from the commercial poultry in the United States, Canada, Australia, and Western Europe. These two diseases can result in significant mortality, ranging up to 100% in chicks, primarily attributed to egg-borne infection.

ETIOLOGY & EPIDEMIOLOGY

PD is caused by *Salmonella Pullorum* and FT by *S. Gallinarum*. These two bacteria, highly adapted to poultry, have been placed in a single species, *S. enterica* serovar *Gallinarum-pullorum*. The bacteria are Gram-negative non-motile slender rods. One distinguishing biochemical difference between the two bacteria is that *S. Pullorum* produces rapid decarboxylation of ornithine whereas *S. Gallinarum* does not.

Chickens are the natural host for both *S. Pullorum* and *S. Gallinarum*. However, outbreaks of PD and FT have been described in turkeys, guinea fowls, quails, pheasants, sparrows, parrots, and other birds. Mortality from PD and FT is usually confined to the first 2 to 3 weeks of age. There are higher losses in mature fowl due to FT. Both diseases can be transmitted in many ways such as horizontal transmission with contaminated feed, water, feces, and others. But egg transmission from the contamination of the ovum following ovulation is the most important mode of transmission.

CLINICAL SIGNS & LESIONS

The clinical signs in chicks and poults include anorexia, huddling together, droopy wings, dehydration, diarrhea, and increased mortality. The highest mortality is usually seen in birds 2 to 3 weeks of age that can range up to 100%. Other signs such as dyspnea, blindness, swelling of the hock joints may also be observed. In growing and mature

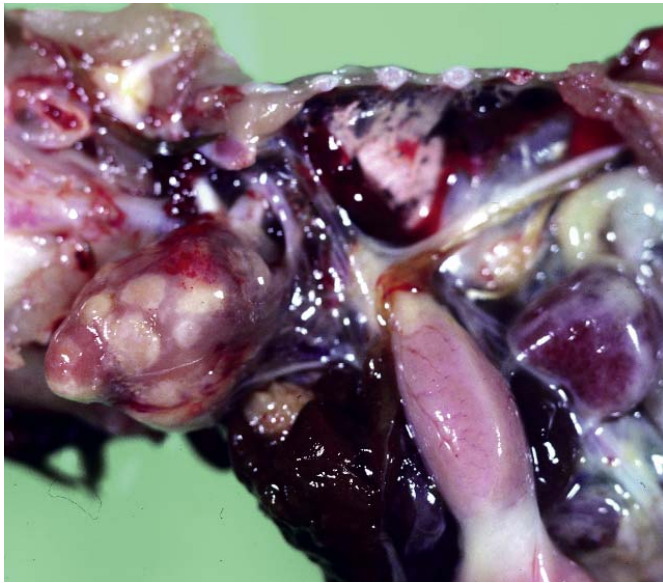
fowl, clinical signs may not be apparent in some cases. Signs such as declining feed consumption, droopy appearance, ruffled feathers, pale and shrunken combs may be observed. Other signs such as decreased egg production, fertility and hatchability may also be observed. Incidence and mortality due to FT in mature fowl is generally higher.

In peracute cases, there may be minimal gross lesions. In acute cases, enlarged and congested liver, spleen and kidneys can be seen. Livers may have white foci of necrosis and spleens may be enlarged and mottled white.

Contents of the yolk sac may be coagulated with fibrinous exudate in the pericardium, on the capsule of the liver, and peritoneum. White or pale yellow nodules may be present in the epicardium and myocardium, sometimes resembling tumors similar to those seen in Marek's disease. Similar small nodules may also be present in the gizzard, pancreas, lung, muscle, and occasionally in the wall of the cecum. The cecum may contain caseous cores in the lumen.

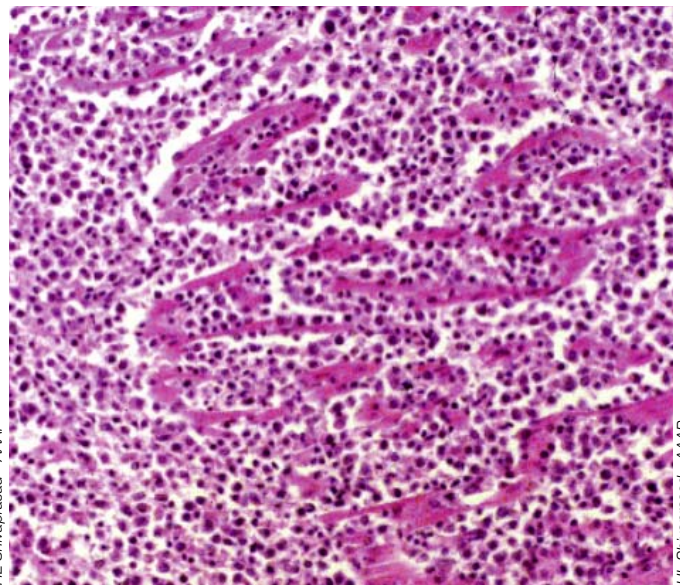
Other lesions may include swelling of the joints with viscous fluid in the synovium, exudate in the anterior chamber of the eye. In adult chickens, lesions may be minimal, such as small nodular regressing ovarian follicles. But the most prominent lesions are a few to many misshapen and discolored nodular ovarian follicles which may be attached to the ovary with a long stalk. Oviduct often contains caseous exudate in the lumen. Fibrinous exudate in the peritoneum and on the capsule of the liver may also be observed. In the male, testes may have white foci or nodules.

Histologically in acute cases in young chicks and poults, there is coagulative necrosis of hepatocytes with infiltration of heterophils mixed with fibrin, fibrinosuppurative inflammation of the yolk sac, pericardium, peritoneum, lungs, and caseous cores in the ceca. Nodules in the heart are usually composed of histiocytic macrophages. The nodules in the ovary of adults are usually composed of pyogranulomatous inflammation associated with many or numerous bacteria.



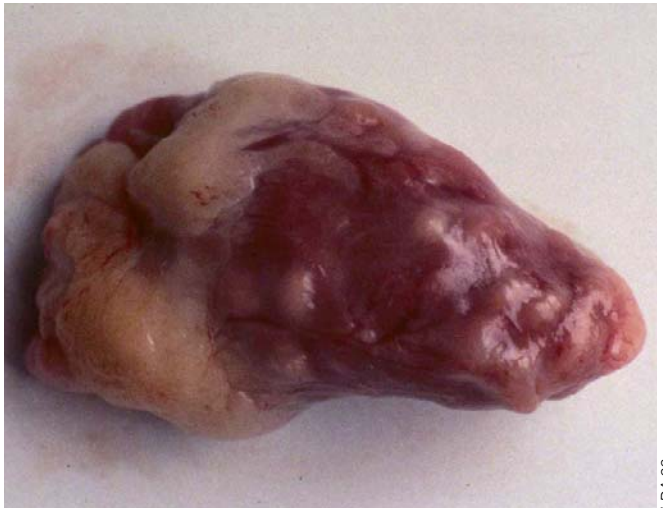HL Shivaprasad - AAAP

Fig.42.7: Pullorum disease. Heart with small pale nodules of myocarditis in a 20 day-old chick.



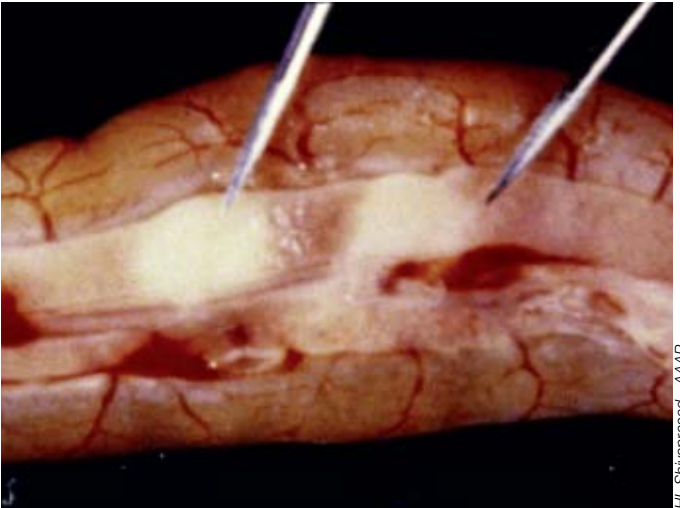
HL Shivaprasad - AAAP

Fig.42.8: Pullorum disease (heart of Fig.42.7). Photomicrograph showing severe infiltration of lymphocytes and macrophages in the myocardium.



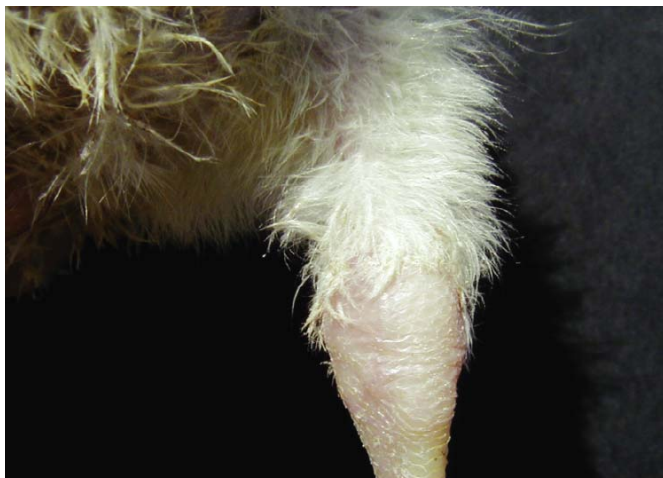LDA 22

Fig.42.9: Pullorum disease. Misshapen heart due to multiple yellow nodules in the myocardium.



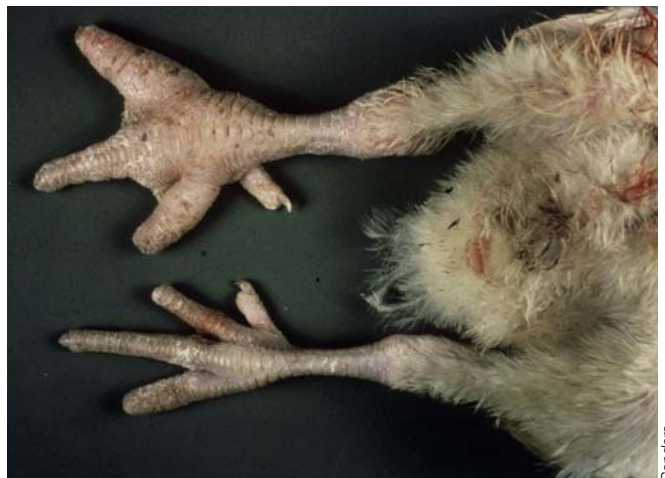HL Shivaprasad - AAAP

Fig.42.10: Pullorum disease (Chick). Multiple pale yellow nodules in the pancreas.



I Dinev - Ceva Santé animale

Fig.42.11: Pullorum disease (Chick). Edema of tibiotarsal joint is a frequent associated sign.



Sanders

Fig.42.12: Pullorum disease (Chick). Unilateral severely swollen in a foot joint.

Reactant or property	<i>Salmonella Gallinarum</i>	<i>Salmonella Pullorum</i>
Dextrose	Fermented with no gas	Fermented with gas
Lactose	Not fermented	Not fermented
Sucrose	Not fermented	Not fermented
Mannitol	Fermented with no gas	Fermented with gas
Maltose	Fermented with no gas	Usually not fermented
Dulcitol	Fermented with no gas	Not fermented
Ornithine	Not fermented	Fermented
Indole	Not produced	Not produced
Urea	Not hydrolysed	Not hydrolysed
Motility	Nonmotile	Nonmotile
Agglutination	Positive with group D	Positive with group D

Tabl.42.1: Biochemical reactions used to differentiate between *Salmonella Gallinarum* and *Salmonella Pullorum*.

DIAGNOSIS

A tentative diagnosis of PD and FT can be made based on the flock history, clinical signs, mortality, and lesions. Various serological tests such as microscopic tube agglutination test, rapid serum test, stained antigen whole blood test, and microagglutination test using tetrazolium stained antigens can be performed. Enzyme Linked Immunosorbent Assay (ELISA) is also available and can be used for screening large numbers of blood samples. However, the antigens used in these tests will cross-react with the sera from birds infected with other salmonella, especially *Salmonella* Enteritidis.

A definitive diagnosis of PD and FT requires isolation and identification of *S. Pullorum* and *S. Gallinarum*, respectively. Organs such as liver, spleen, yolk sac, and ceca are the preferred organs for culture. In mature birds, the lesions are present in reproductive organs and oviduct, ovarian follicles and testes can be cultured. These organs and other organs from chicks can be cultured directly on veal infusion and brilliant green agar plates and incubated for 48 hours at 37°C.

The digestive tract can be cultured by use of a swab of the various parts of the intestinal tract, including ceca, rectum/cloacal area in 10 ml tetrathionite brilliant green broth incubated and plated as previously described. In addition, portions of the intestinal tract can be pooled, ground, or blended in 10 times the volume of TBG broth. A quantity of the suspension from the digestive tract (10 ml) is transferred to 100 ml of TBG broth and incubated at 42°C or 37°C for 24 hours. Suspect organisms are transferred to triple sugar iron (TSI) agar and lysine iron agar and incubated at 37°C for 24 hours. Cultures revealing typical reactions of salmonella on these slants should be identified by appropriate biochemical or other techniques.

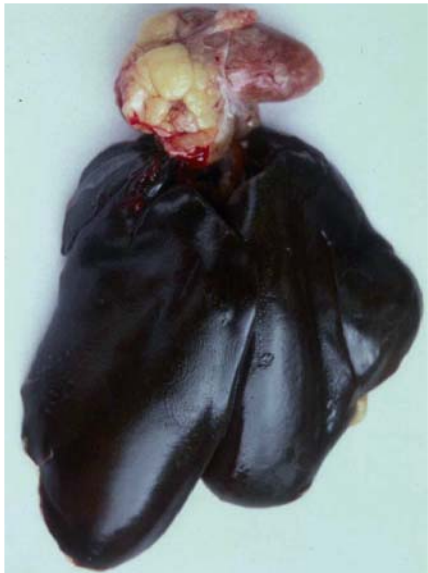Salmonella Pullorum and *S. Gallinarum* produce a red slant with a yellow butt that shows delayed blackening from H₂S production. Reactions listed in Tabl.42.1 which can be determined within 24 hours provide identification of a number of other common pathogens and allow differentiation between the two organisms.

TREATMENT & CONTROL

Every effort should be made to eradicate PD and FT and treatment should be the last option. Various sulfonamides followed by nitrofurans and other antibiotics have been found to be effective in reducing mortality from PD and FT. Various other antibiotics such as furaltodone, furazolidone, chloramphenicol, biomyacin, apramycin, gentamicin, and chlorotetracycline have been used for controlling and treating PD and FT. However, it is illegal to use chloramphenicol for treating poultry in many countries.

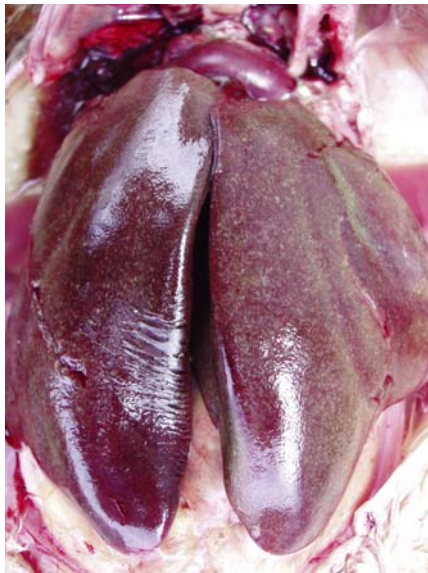Resistance to some of these antibiotics has also been reported. Care must be taken to follow directions given by the manufacturer in regard to the route of administration, dosage, duration of treatment, and withdrawal period for each antibiotic before use.

Establishing breeding flocks free of PD and FT and hatching and rearing progeny under conditions that will preclude direct or indirect contact with infected chickens or turkeys is a fundamental requirement of prevention of PD and FT. Since egg transmission plays an important role in the spread of these two diseases, only eggs from flocks known to be free of PD and FT should be introduced into the hatcheries. Management practices such as obtaining chicks and poults from sources free from FT and PD, regular serological testing, and elimination of carriers, placing chicks and poults in an environment that can be cleaned and sanitized and



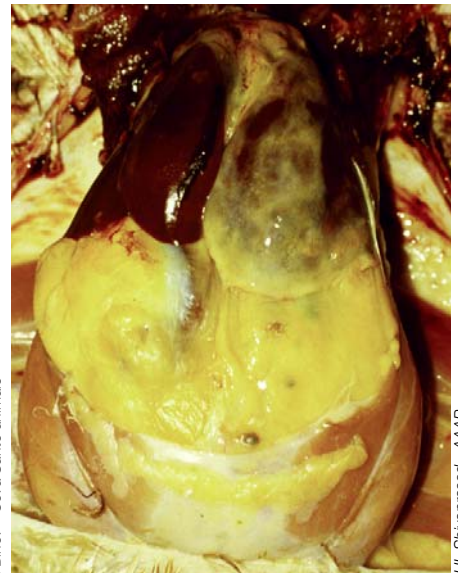LDA 22

Fig.42.13: In acute pullorosis and fowl typhoid, a characteristic lesion is the enlarged and bronze greenish tint of liver.



J Dinev - Ceva Santé animale

Fig.42.14: Acute fowl typhoid. Enlarged liver mottled with multiple miliary necroses.



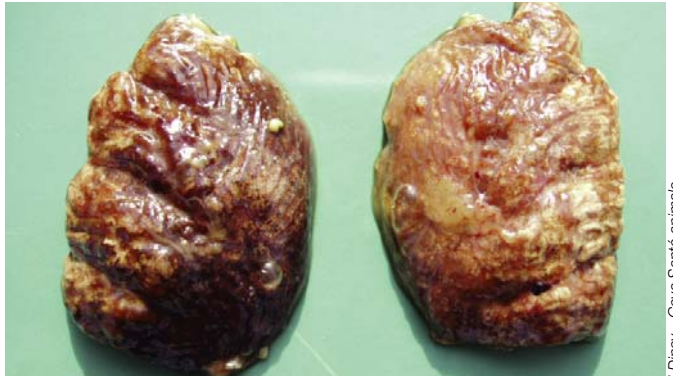
HL Shrivaprasad - AAAP

Fig.42.15: Fowl typhoid. Severe diffuse yellow fibrinous exudate in the peritoneum and on the capsule of the left liver.



J Dinev - Ceva Santé animale

Fig.42.16: Acute fowl typhoid. The spleen is 2-3 times bigger, sometimes with greyish-whitish nodules.

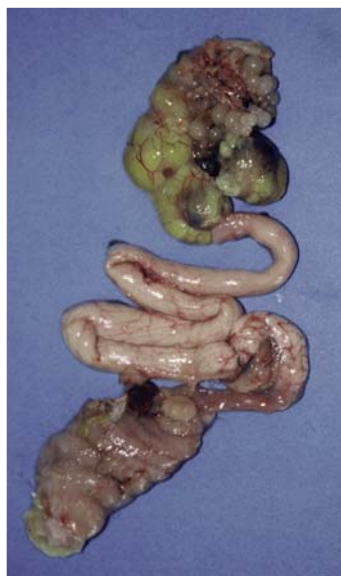

J Dinev - Ceva Santé animale


Fig.42.17: Acute fowl typhoid. Lungs showing characteristic brown colour and necroses foci forming «sarcoma-like nodules».



J Brugère-Picoux



J Brugère-Picoux



J Brugère-Picoux

Fig.42.18, 42.19 & 42.20: Chronic fowl typhoid in a breeder flock. In this breeder flock affected by the chronic form of fowl typhoid, an intense anemia produces pale combs and wattles (Fig.42.18). Ovary presents multiple degenerative follicles (Fig.42.19). Egg drop observed is associated with abnormalities of eggs (too small, without yolk, etc.) (Fig.42.20).

feeding ingredients free of salmonella and a sound biosecurity program will go a long way in preventing PD and FT.

Various vaccines such as 9R strain, outer membrane proteins, use of mutant strains of *S. Gallinarum*, and virulence plasmid cured derivatives of *S. Gallinarum* have been used to protect birds from fowl typhoid in countries where there is not eradication program.

REFERENCES

Pomeroy BS & KV Nagaraja. Fowl Typhoid. In Diseases of Poultry, 9th Ed. BW Calnek et al., Iowa State University Press, Ames, Iowa. 1997, 87-99.
 Shivaprasad HL. Fowl typhoid and pullorum disease, *Rev. Sci. Tech. Op. Int. Epiz.*, 2000, 19: 405-424.
 Snoyenbos GH. Pullorum Disease. In *Diseases of Poultry*, 9th Ed. B. W. Calnek et al., Iowa State University Press, Ames, Iowa. 1997, 73-86.

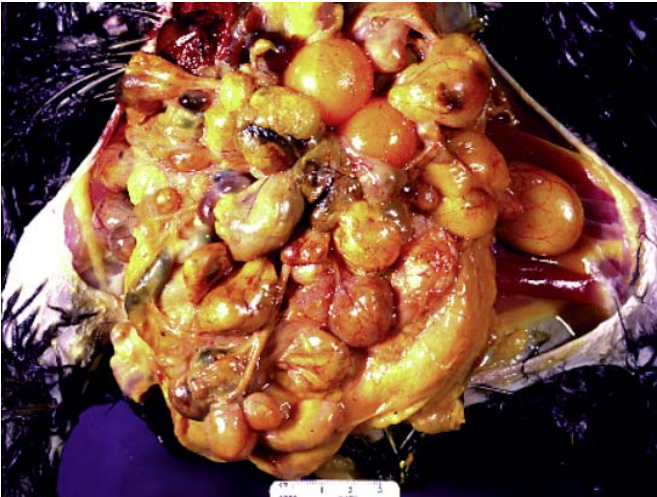

Fig.42.21: Fowl typhoid. Ovary with numerous misshapen, nodular and atretic follicles in an adult chicken.

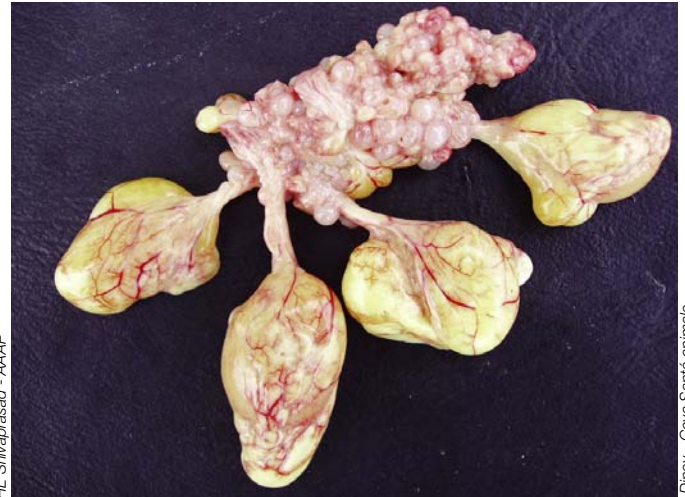

Fig.42.22: Chronic fowl typhoid. Follicles are deformed and appear like thick pendulous masses.

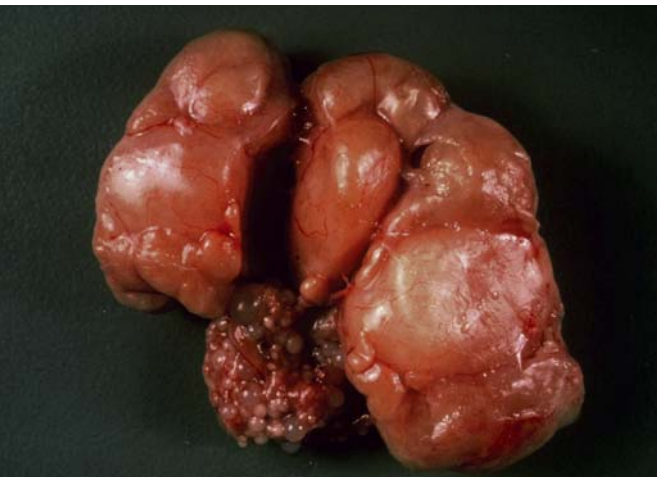

Fig.42.23: Chronic fowl typhoid. Degenerative ovarian follicles attached with a peduncle to the ovary and with a "cooked" aspect.



Fig.42.24: Rapid serum agglutination test showing positive (left) and negative (right) tests.

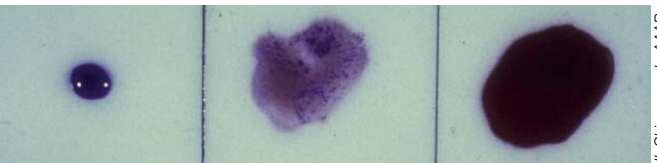


Fig.42.25: Rapid whole blood agglutination test. Antigen only (blue) in one well, positive agglutination in the center well, and negative agglutination (dark red) in another well.

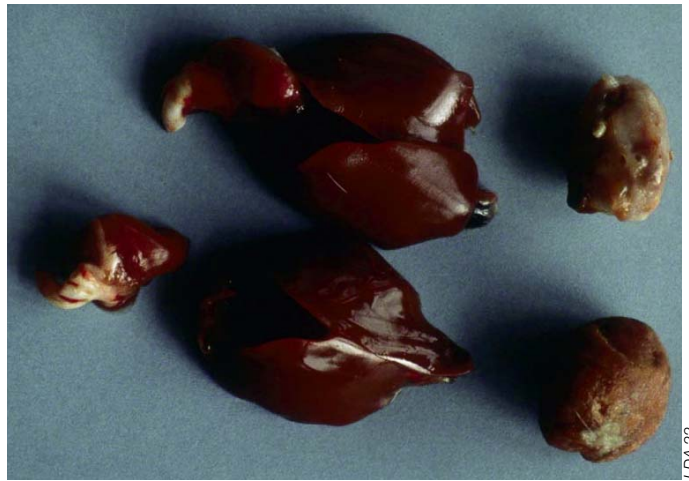


Fig.42.26: Microagglutination test for pullorum disease. This is a 96 well microagglutination test plate. Note positive and negative controls on 10th and 11th columns, respectively. Compare these to the 9 samples at various titers. Samples 2,5 and 8 are negative. Samples 1, 3, 4, 6, and 7 are positive at 1:320, 1:40, 1:20, 1:80 and 1:20, respectively. Sample 9 is suspicious, and needs to be re-tested.



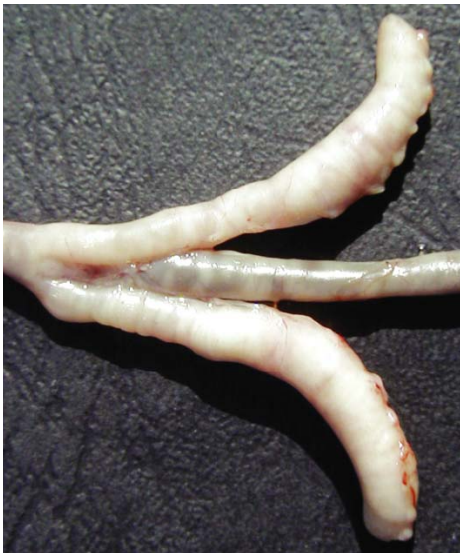I Dinev - Ceva Santé animale

Fig.43.1: In fowl paratyphoid the highest morbidity and death are usually observed during the first two weeks after hatching. The chicks are drowsy, with eyes closed, ruffled feathers and congregate near heat sources.

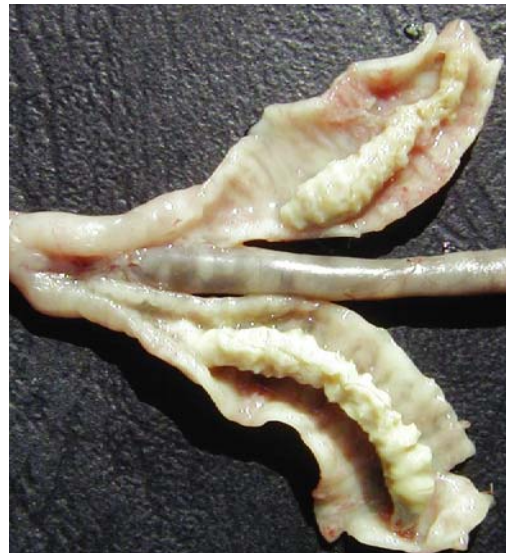

LDA 22

Fig.43.2: Omphalitis in chickens infected by *S. Enteritidis* (caseous yolk sac).

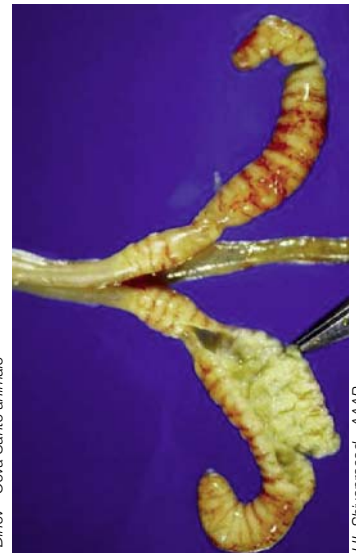

I Dinev - Ceva Santé animale



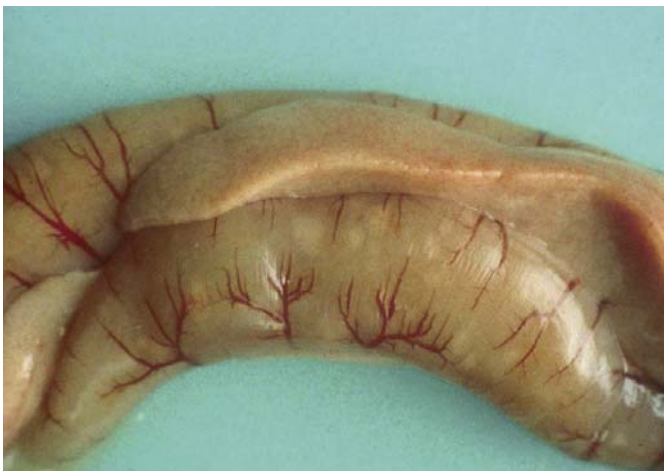I Dinev - Ceva Santé animale

Fig.43.3 & 43.4: Diarrhea, dehydration and pasted down appearance around the vent are observed. Often the ceca are filled with gelatinous, fibrinous, cheese-like exudate. This inflammatory fibrinous exudate in ceca often forms casts with the shape of mucosal folds. This is a finding, characteristic for salmonellosis, but not specific for any of serotypes. The most common isolates are *S. Enteritidis* and *S. Typhimurium*.



HL Shivaprasad - AAAP

Fig.43.5: Diffuse fibrinonecrotic typhlitis due to *S. Typhimurium* (Pheasant).



LDA 22

Fig.43.6: Paratyphosis due to *S. Typhimurium* (Pigeon). White foci of necrosis seen by transparency on the intestine.



LDA 22

Fig.43.7: Paratyphosis due to *S. Typhimurium* (Pigeon). Intestinal necrosis.

Bacterial diseases

43. PARATYPHOID SALMONELLA

INTRODUCTION

Considerable effort has been focused in recent years on the diagnosis and control of the paratyphoid (PT) salmonella in commercial poultry not because of their ability to cause disease in domestic birds, but rather their ability to establish chronic infections. Organisms shed from chronically infected birds can impact the safety of food products coming from poultry if the products are not handled properly and cooked thoroughly. Much remains to be learned about the control/eradication of PT salmonella in poultry populations. In the meantime, the threat to human food safety can be effectively controlled by consumer diligence.

ETIOLOGY & EPIDEMIOLOGY

Salmonella are Gram-negative rod shaped bacteria and have been placed in the family *Enterobacteriaceae*. There have been over 2300 different serotypes of *Salmonella* spp. identified. Of these, about 10% have been isolated in poultry and of this 10% only a small number have been established host specific pathogens for birds and/or people. The PT salmonella are motile, non-spore forming and ubiquitous. Natural hosts for the PT salmonella include a wide range of warm-blooded and cold-blooded animals. Many vertebrate and invertebrate species can serve as vectors for PT salmonella and represent an important risk factor in any control/eradication program.

Important in the epidemiology of the organism is its ability to persist in the environment. While the organism is sensitive to many different classes of disinfectants by *in vitro* testing, when tested using *in vivo* situations, such as poultry house disinfection, it can be very difficult to eliminate from the environment. The organism is sensitive to heat and will be eliminated by proper cooking temperatures (internal temperature of 60-79°C).

CLINICAL SIGNS & LESIONS

Clinical disease following PT salmonella infection appears to be an age dependent and dose dependent phenomenon. Usually, only very young birds show clinical signs although there have been reports of disease in older layers following field challenge with particularly virulent strains of *S. Enteritidis*. Oral exposure from infected feces or shell membranes appears to be the most important route of

infection. Following exposure, the organism first colonizes areas of the intestine, primarily the cecae, then may invade beyond the intestinal epithelium and establish a secondary infection in the reticuloendothelial system of the liver and spleen. Finally, the organism may be hematogenously spread to virtually any other organ system. In the vast majority of cases, this pathogenic sequence arrests at the intestinal colonization stage and an inapparent chronic infection is established.

Clinical signs of septicemic PT salmonella infection in very young chicks and poults are non-specific and include diarrhea, depression, anorexia, and emaciation. Occasionally, blindness and lameness have been reported. In the hatchery, PT infection can result in an increased number of late dead embryos. Many young chicks show no clinical signs and just appear to die acutely. In affected flocks the mortality usually peaks by 5 to 7 days post hatch.

Gross lesions observed are those consistent with diffuse septicemia caused by a variety of organisms and are not pathognomonic for PT salmonella infection. These include coagulated yolk sac contents, necrotic foci in the liver and spleen, and, in more advanced cases, fibrinopurulent perihepatitis and pericarditis. Less frequently, hypopyon, panophthalmitis, purulent arthritis, air sacculitis, typhilitis, and omphalitis can be observed. In laying hens with *S. Enteritidis* infection, peritonitis and oophoritis may be observed.

There are no distinctive histopathologic lesions indicative of PT salmonella infection. The lesions seen are typical for a non-specific inflammatory disease and include heterophilic infiltration and diffuse cellular necrosis.

DIAGNOSIS

Diagnosis of PT salmonella infection must be considered on two levels. First, when presented with a history of high mortality in young birds, the diagnosis is usually based on culture results from swab or tissue specimens collected during post mortem examination of individual birds. Swabs collected from visual lesions are the best samples to collect. In the context of food safety, an even bigger challenge is presented when one attempts to diagnose the salmonella status of an entire flock.

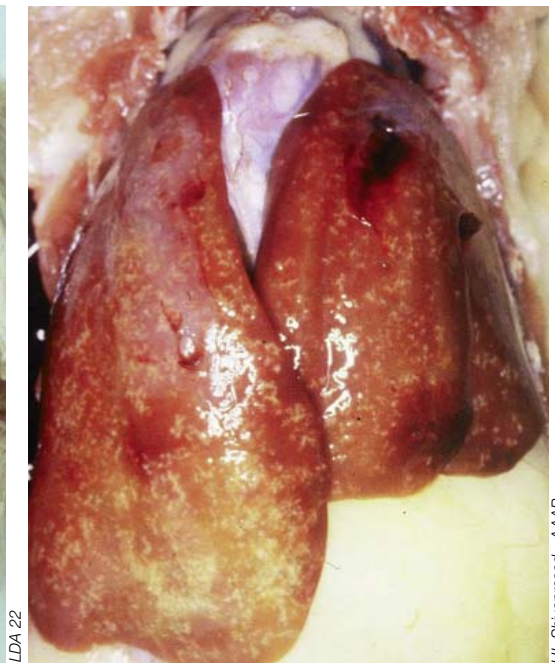
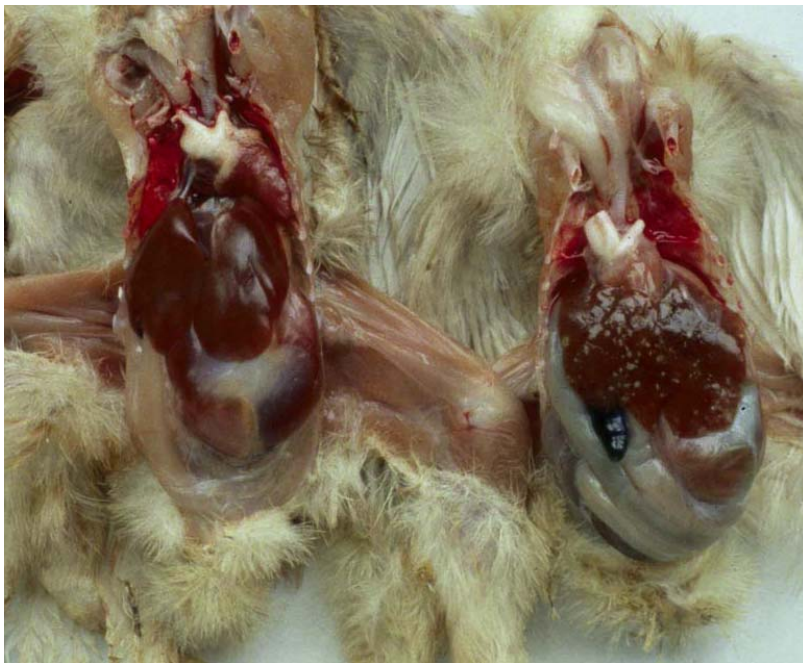
Fig.43.8 & 43.9: Paratyphosis due to *S. Enteritidis* (Fowl). Sometimes, liver is enlarged with white foci of necrosis.

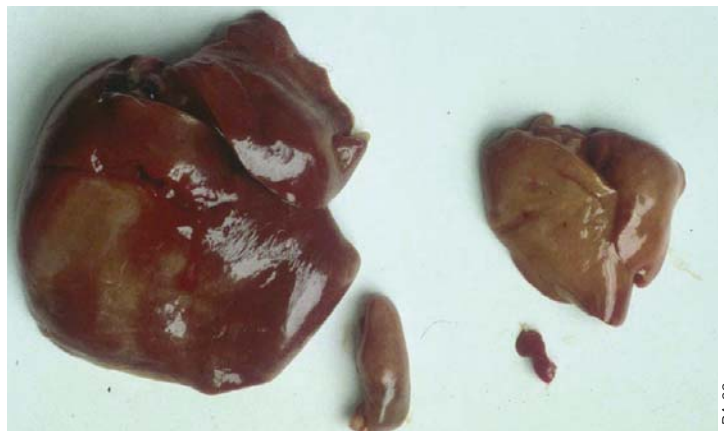
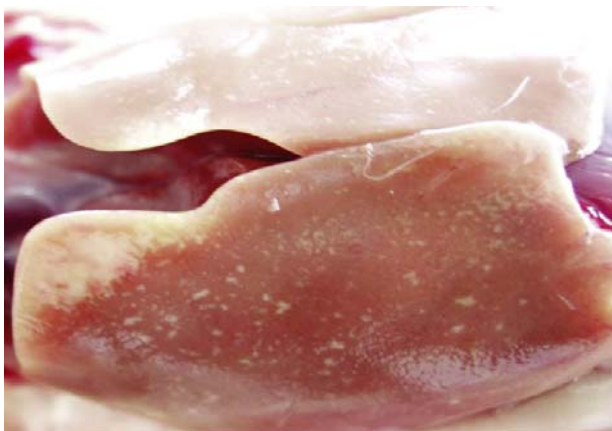
Fig.43.10: Paratyphosis (Fowl). Necrotic foci in the liver. The infection of chicks can occur by penetration into eggs after fecal contamination.

Fig.43.11: Paratyphosis due to *S. Typhimurium* (Pigeon): Hepatitis with hepatomegaly (compare with the normal liver on the right).

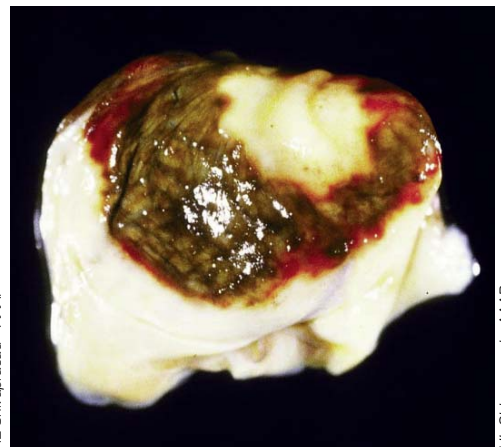
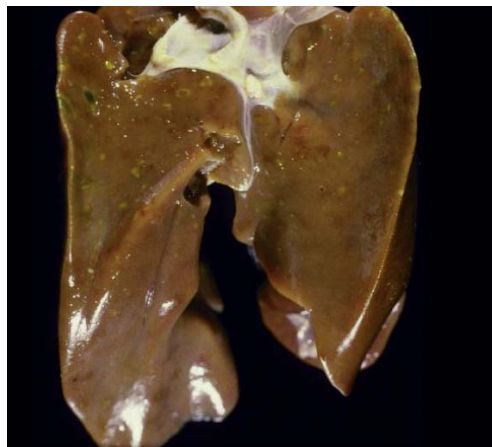
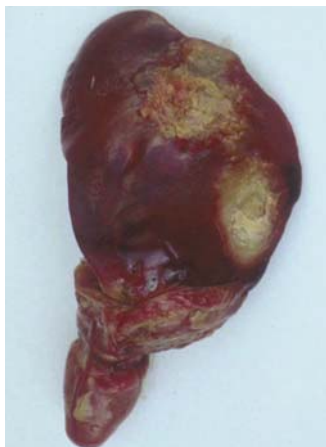

Fig.43.12: Paratyphosis due to *S. Typhimurium* (Pigeon). Liver with important foci of necrosis.

Fig.43.13: Paratyphosis due to *S. Typhimurium* (Fowl). Liver with green (cholangiohepatitis) and pale foci of necrosis.

Fig.43.14: Paratyphosis due to *S. Typhimurium* (Fowl). Gall bladder from the chicken of the Fig.43.13 with ulcerative cholecystitis.

For this a variety of samples can be used including litter samples, cloacal swabs from a random sample of the population, drag swabs collected throughout the house, and swabs from cecal droppings found in the house. To monitor in the hatchery, fluff samples and chick box papers have been shown to be useful. Dust samples from exhaust fan hoods and swab samples from nest pads or egg belts are particularly good samples because these areas tend to concentrate the organisms and give a good representation of what is going on throughout the house.

Definitive diagnosis is based on isolation and identification of a PT salmonella. Isolation and identification of salmonella in environmental samples is usually done as a three step process beginning with resuscitation (preenrichment) in either buffered peptone water or trypticase soy broth. Following incubation overnight at 37°C, an aliquot of the sample is inoculated into selective enrichment broth and incubated overnight again at 37°C or 42°C. For samples from clinical cases, the swab can be inoculated directly into selective enrichment broth. Generally, the selective enrichment broths used are selenite-cystine, tetrathionate, or Rappaport Vassiliadis. Final isolation is accomplished by streaking on agar media. The two most commonly used agars are brilliant green with added novobiocin, on which colonies of *Salmonella* appear pinkish-red, and XLT4, on which colonies of *Salmonella* appear black. Bismuth sulfite, XLD, and Hektoen enteric agars may also be used. In the United States, guidelines for sampling and laboratory procedures are provided by the National Poultry Improvement Plan.

Colony appearance on selective agar is a good preliminary indication that salmonella is present. Definitive diagnosis depends on identification of the organism as a producer of H₂S using a combination of triple sugar iron agar and lysine iron agar. The isolate can then be serogrouped by testing in a slide agglutination test using commercially available polyvalent antisera to groups of somatic O antigens. Finally, the specific serotype of salmonella can be identified using agglutination tests with monovalent O and H antigens.

The biggest drawback to the use of culture and identification for diagnosis is the turn around time. Generally, for environmental samples, a minimum of four days is required from the time of sample collection until results are available. For this reason, a variety of commercial tests

have been developed using molecular technology to identify the presence or absence of salmonella. While these tests do improve the turn around time, generally less than 48 hours, they have yet to gain wide acceptance because of cost, concerns about sensitivity and specificity, and the lack of serotype information. In order to ascertain the serotype, standard culture methods must be resorted to.

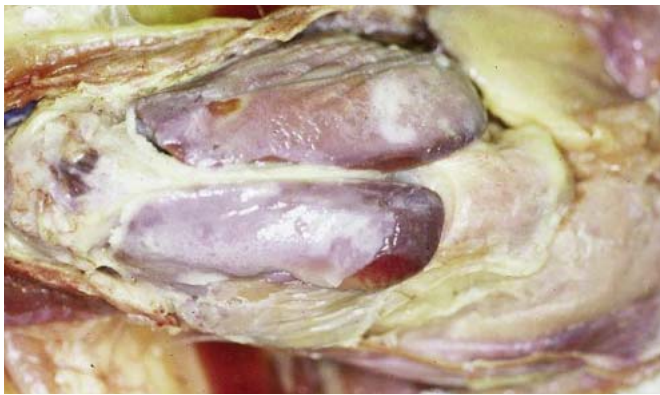Serologic testing can be successfully used for diagnosis of infected flocks. Commercial Elisa kits are available for testing for antibodies to *S. Typhimurium* and *S. Enteritidis*. While it can be a useful tool, serologic testing has generally not been included in routine diagnostic regimens. As our knowledge of the immune response to PT salmonella increases and as the testing methods are refined, serologic testing may become increasingly important as a diagnostic screening method to identify flocks that should be monitored more intensively.

TREATMENT & CONTROL

As with diagnostic methods, the discussion of treatment and control is vastly different for mortality due to clinical disease in young birds and control/eradication for food safety. In acute outbreaks of salmonellosis antibiotic therapy using tetracycline, neomycin, bacitracin, sulfonamides, or fluoroquinolones (if approved for use) may be effective in reducing the acute mortality. The decision of the choice of antibiotic to use must be based on sensitivity testing and cost. While antibiotic therapy may be effective at reducing the acute mortality pattern, it is highly unlikely that antibiotics by themselves will completely clear a flock of infection.

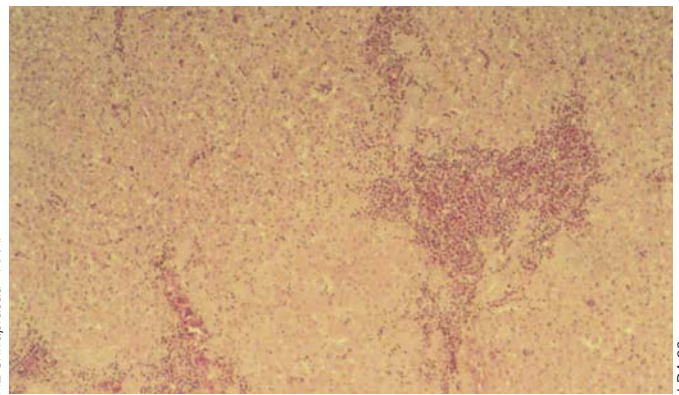
Control/eradication of PT salmonella for food safety is best handled as a risk management exercise. The biggest risks to a flock becoming infected with salmonella are the breeder flock(s) from which the chicks were derived, the environment in which the birds are being reared, the feed coming into the environment, and breakdowns in biosecurity.

Salmonella can be transmitted vertically either by direct transovarian or transuterine transmission or indirectly by shell contamination with migration of the organism into the egg via the pores. There are tools available to control shedding of salmonella and vertical transmission. None of these tools are completely effective and must be viewed as only a part of an overall risk reduction program.



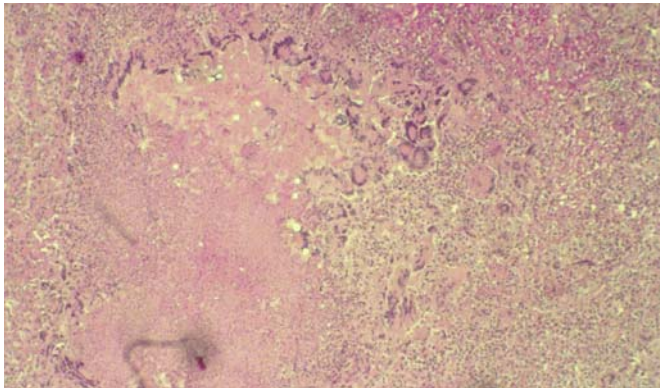
HL Shivaprasad - AAAP

Fig.43.15: Paratyphosis due to *S. Enteritidis* (Fowl). Severe fibrinous pericarditis, perihepatitis and airsacculitis/peritonitis.



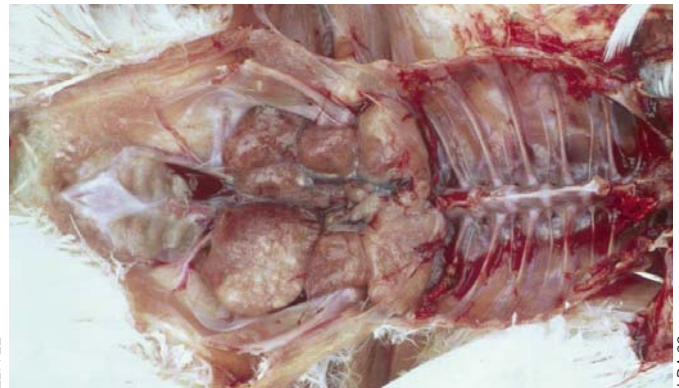LDA 22

Fig.43.16: Paratyphosis (Pigeon). Liver infiltration by heterophilic polymorphonuclear leukocytes (hematoxylin & eosin, x 100).



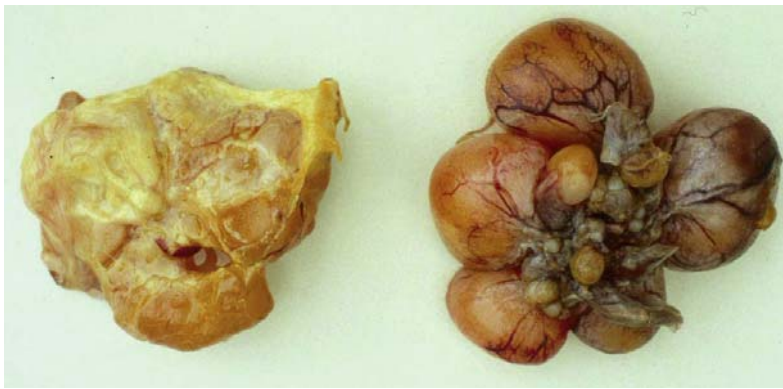LDA 22

Fig.43.17: Paratyphosis due to *S. Typhimurium* (Pigeon): granuloma in the spleen (PAS, x 100).



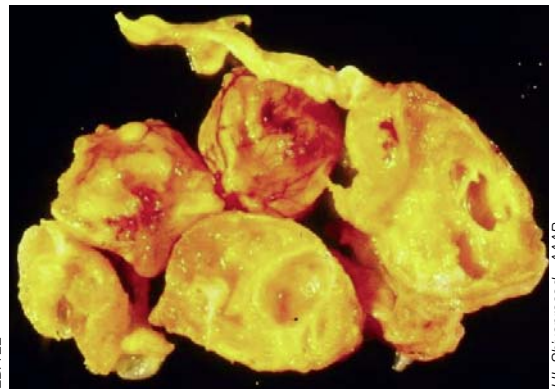
LDA 22

Fig.43.18: Paratyphosis due to *S. Typhimurium* (Pigeon). Renal abscess.

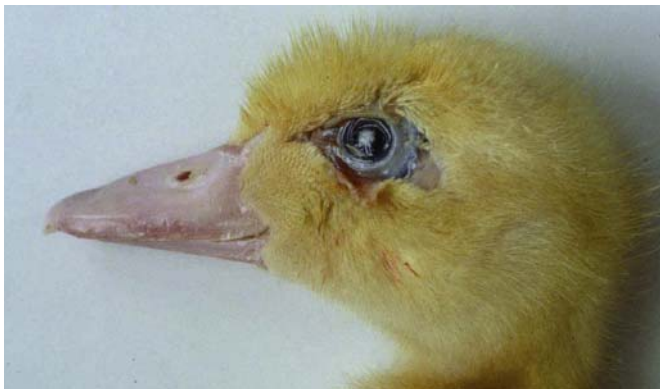

LDA 22

Fig.43.19 & 43.20: Paratyphosis due to *S. Enteritidis* (Fowl). Severe fibrinous oophoritis (compare the infected ovary on left with the normal ovary on right in the Fig.43.19).

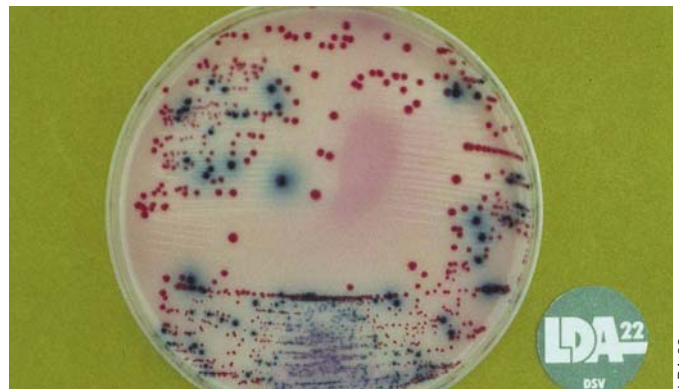


HL Shivaprasad - AAAP



LDA 22

Fig.43.21: Paratyphosis due to *S. Typhimurium* (Duckling). Iridocyclitis.



LDA 22

Fig.43.22: *S. Enteritidis*. Pink bacterial colonies isolated on Rambach agar.

The use of antibiotics in positive flocks is controversial because of the possibility of the creation of resistant bacteria. In addition, the efficacy of therapy in completely clearing shedder flocks of the organism is questionable. Certainly if the decision is made to use antibiotics, it must not be done until all of the other environmental and feed risk factors have been evaluated and the risk of immediate reinfection is eliminated.

Competitive exclusion is a process whereby a collection of non-pathogenic enteric bacteria is administered to birds per os. Competitive exclusion products are believed to help reduce or eliminate colonization of the intestine by salmonella by competing with the organism for available receptor sites and/or altering the acid-base balance of the tract making it less hospitable for salmonella. These products are either defined, in which the composition and concentration of organisms is known, or undefined, in which the exact composition is not known but the product has been tested for various avian pathogens. While it is widely believed that the undefined products are more efficacious, there is the reluctance on the part of some federal agencies to approve the use of these products because the complete milieu is not totally identified.

One control method that is still in its infancy is vaccination. Vaccines available commercially in the United States are killed vaccines using *S. Enteritidis* and live vaccines using genetically altered *S. Typhimurium*. As stated above, much needs to be learned regarding the serologic response to the PT salmonella and this includes the use of vaccine in the control/eradication of these organisms.

Even the best methods to control shedding and vertical transmission of PT salmonella are useless unless the environment and feed are free of salmonella and a stringent biosecurity program including rodent and insect control is in place. The single biggest risk to an uninfected flock is contamination from any one of innumerable sources. Poultry houses must be completely cleaned and disinfected and dried between flocks. The efficacy of these procedures must be checked by extensive and stringent bacteriological testing. Feed ingredients must be from reputable sources. Temperature and retention times for heat processing of feed must be adequate and monitored.

Steps must be taken to prevent recontamination of clean feed. Beetles and rodents in and around the poultry house must be eliminated. And lastly, all personnel in contact with the birds must realize the importance of and implement the best biosecurity practices.

On farm control of the PT salmonella relative to food safety is a formidable and expensive task. In addition, on farm control of PT salmonella is of little use if the integrity of the product is not going to be maintained as it moves from the farm to the consumer's table. Achievement of food safety must be a shared responsibility between the producer, the processing plant and the consumer. With existing technology, the likelihood of eradication of all food borne pathogens is highly unlikely. Even as new technologies are developed and PT salmonella levels are reduced, the need for proper food storage and handling and cooking techniques will remain of paramount importance.

REFERENCES

- Anonymous, "National Poultry Improvement Plan and Auxiliary Provisions", Animal and Plant Health Inspection Service, United States Department of Agriculture, Washington, D.C., 1997, p. 53-92.
- Bentley AH & Pettit J. "Salmonella in the Canadian Poultry Meat Industry". Agriculture Canada, Food Production and Inspection Branch, Ottawa, Ontario, 1980.
- Cox NA et al. Salmonella penetration of eggshells and proliferation in broiler hatching eggs – a review. *Poult Sci*, 2000,79:1571-1574.
- Davies RH & Wray C. Observations on disinfection regimens used on Salmonella enteritidis infected poultry units. *Poult Sci*, 1995,74:638-647.
- Gast RK. Paratyphoid infections. In "Diseases of Poultry" tenth edition, Iowa State Press, Ames, Iowa, 1997, p.97-121.
- Horrox N. Salmonella – all you wanted to know but were afraid to ask. *International Hatchery and International Poultry Practice* suppl., 1995, 10: I-XVI.
- Miles RD & Butcher GD. Salmonella: controlling it in the broiler, egg industries. *Feedstuffs*, 1993, 65, 24.
- Stavric S & D'Aoust JV. Undefined and defined bacterial preparations for the competitive exclusion of Salmonella in poultry - a review. *J Food Prot*, 1993, 56:173-180.



Fig.44.1: Twisted neck in a two week-old poullet due to *S. arizonae* infection of inner ear.

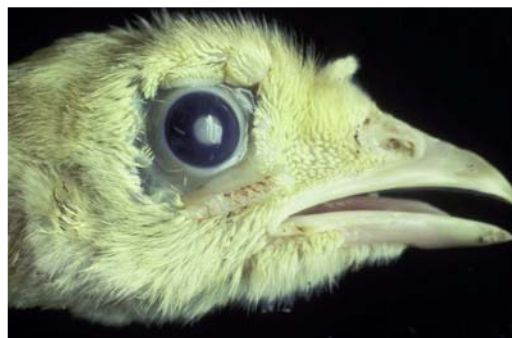

Fig.44.2: Exudate in the anterior chamber of eye (ophthalmitis) in a poullet due to *S. arizonae*.

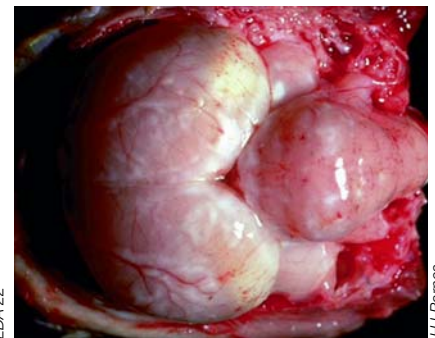


Fig.44.3: Encephalitis in two week-old poullet due to *S. arizonae* infection.

Section III

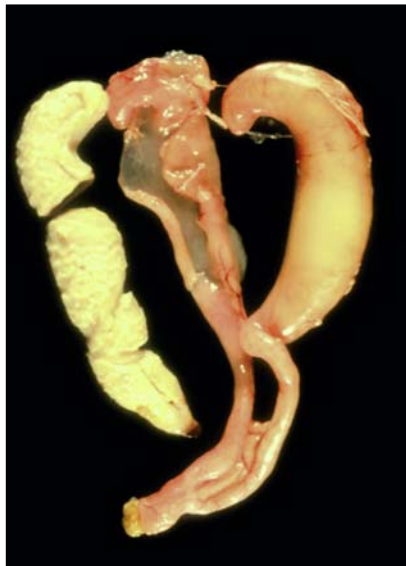

Fig.44.4: Cecae with fibrinonecrotic core in the lumen (*Salmonella typhlitis* of a fowl). These lesions are also seen in *S. arizonae* infection in poullet.

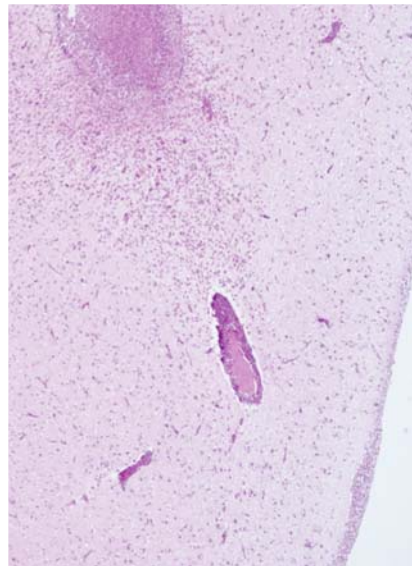


Fig.44.5: Brain. Photomicrograph of encephalitis in a poullet due to *S. arizonae*.

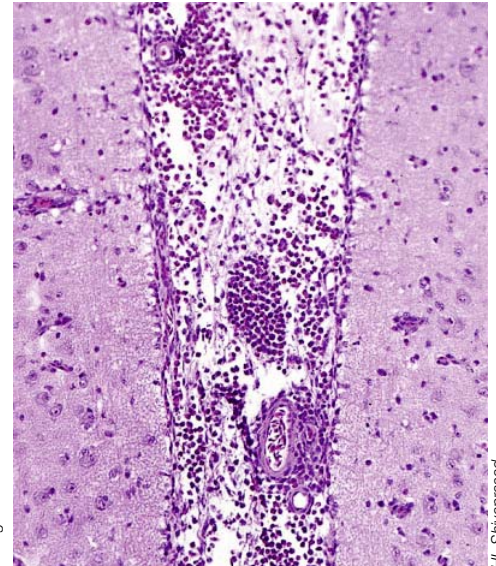


Fig.44.6: Brain showing severe meningoencephalitis characterized by infiltration of primarily heterophils in the meninges due to *S. arizonae* in a poullet.

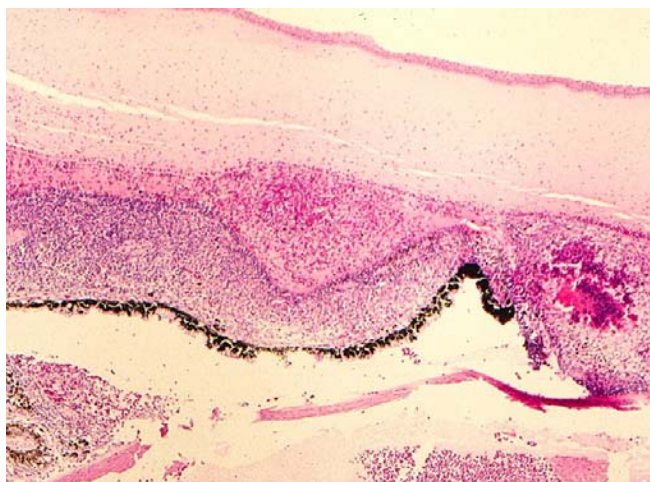


Fig.44.7: Photomicrograph of iris and cornea with severe fibrinosuppurative and focal giant cell inflammation (anterior uveitis, iriditis and keratitis) from a poullet due to *S. arizonae*.

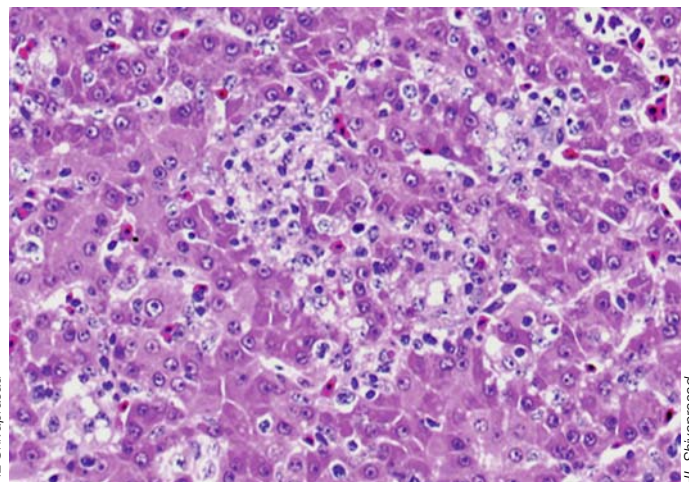


Fig.44.8: Liver with hepatitis characterized by infiltration of lymphocytes scattered throughout due to *S. arizonae* in a poullet.

Bacterial diseases

44. ARIZONOSIS

INTRODUCTION

Arizonosis is an acute or chronic septicemic egg-transmitted disease primarily of young turkeys caused by the bacterium *Salmonella enterica* subsp. *arizonae* characterized by septicemia, neurological signs, blindness and increased mortality. Other species of birds are also susceptible including chickens, ducks, canaries, psittacines and wild birds.

ETIOLOGY & EPIDEMIOLOGY

The etiology of arizonosis is *Salmonella enterica* subsp. *arizonae* a Gram-negative, non-sporogenic, motile bacterium that ferments lactose slowly and is classified in the family *Enterobacteriaceae*. There are numerous serotypes of *S. arizonae* among which 18:Z4,Z23 and 18:Z4,Z32 are the most common.

The disease is worldwide in distribution but has been eradicated from commercial turkeys in some countries such as the UK. Epidemiology of arizonosis can be similar to other salmonella infections most notably paratyphoid infections. Arizonosis is a disease of great economic significance due to the morbidity and mortality it causes in young turkey poults, but also the bacteria that can localize in the ovary and oviduct of breeder turkeys producing poults which are infected. Also, adult birds which are infected with *S. arizonae* will frequently become intestinal carriers and intermittent shedders of the organisms contaminating egg shell surfaces. This can lead to penetration of the shells by organisms and infection of the progeny. The progeny can experience clinical signs and high mortality in the first few weeks after hatching, as well as act as a source of organisms transmitting the disease horizontally to other poults. Infection of hatching eggs will also result in embryo mortality and poor hatchability. Reptiles and rodents, as well as contaminated feces, feed and environment can be sources of *S. arizonae* to the turkeys.

CLINICAL SIGNS & LESIONS

Clinical signs due to arizonosis in poults are not specific and include listlessness, depression, weakness and development of anorexia, diarrhea, paralysis, opisthotonus and torticollis. Poults can develop blindness due to corneal opacity and exudate in the anterior chamber or vitreous. Mortality can range from 10% to as high as 50% in the first week and mortality continuing up to 3 to 5 weeks. Hatchability ranged from 0% to 21-70% in experimentally inoculated or dipped embryonated chicken eggs in *Salmonella enterica* subsp. *arizonae*.

Gross lesions due to arizonosis are also not specific and include retained yolk sacs, yolk sacs which may have watery yellow or caseous exudate, prominent yolk stalks (navel buttons), and cores in the ceca, livers enlarged and mottled pale, enlarged and congested spleens, cloudy meninges in the brain and cloudy corneas and/or exudate in the vitreous of the eye. Other lesions may consist of fibrinous exudate in the air sacs, pericardium, synovium and inner ears. Histologically the lesions consist of mild to severe fibrinosuppurative or fibrinoheterophilic inflammations generally associated with numerous colonies of bacteria in yolk sacs, meninges, eyes and ears.

DIAGNOSIS

Preliminary diagnosis can be made based on clinical signs, mortality pattern combined with gross and microscopic lesions. However, gross lesions of arizonosis will be similar to other bacterial infections including paratyphoid infections. *Salmonella enterica* subsp. *arizonae* can be isolated readily from most lesions such as from the yolk sac, liver, ceca, brain, eyes and other organs. At the hatchery dead embryos or unhatched embryos, egg shells and environmental samples can be cultured for *S. arizonae*. Culturing of organs like ceca, ovary, oviduct from infected breeders are effective in isolating the organisms. Various serological methods are available for diagnosing *S. arizonae* but some of the antigens used in the tests can have a tendency to cross react with other serotypes of salmonella.

TREATMENT & CONTROL

Various kinds of bacterins have been used in breeder turkeys with varying success to reduce shedding, development of septicemic infection and prevent egg transmission. Administration of *S. Enteritidis*-immune lymphokines in turkey poults has also been helpful. Antibiotics such as gentamicin, tetracyclines and sulfonamides can be effective in preventing excess mortality. But treatment does not prevent breeders from becoming carriers of *S. arizonae*.

Testing of primary breeders for *S. arizonae* and elimination of positive birds is the best method of prevention. Dipping of contaminated eggs in gentamicin solution prior to hatching can also be successful in control of *S. arizonae*. Biosecurity implementation, total confinement of birds, bird and rodent proofing the houses, cleaning, disinfecting and monitoring of birds, eggs and egg trays and environment, both at the breeder and the hatchery levels is essential for prevention and successful elimination of *S. arizonae*.

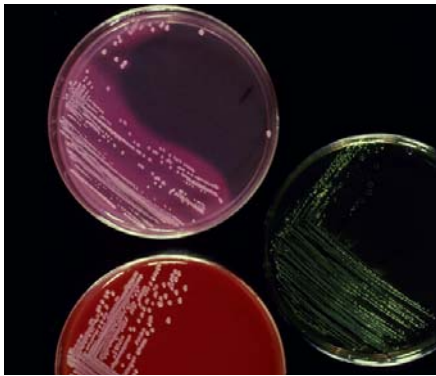

Fig.45.1: Characteristic appearance of *E. coli* after 24h incubation at 37°C on 5% blood agar (lower left), MacConkey agar (upper left), and eosin-methylene blue agar (right).

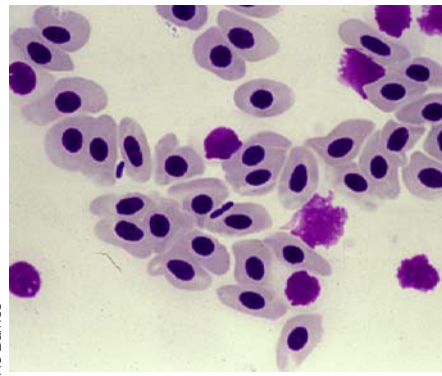


Fig.45.2: *E. coli* in the blood of a bird with colisepticemia (Giemsa stain).

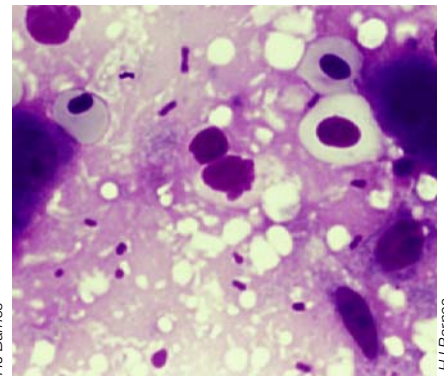


Fig.45.3: *E. coli* in the liver of a bird with colisepticemia (Giemsa stain).




Fig.45.4: Avian pathogenic *Escherichia coli* (APEC). Virulences factors. The majority of APEC infections are extraintestinal. Some APEC have characteristics associated with intestinal *E. coli* pathotypes, including enteropathogenic *E. coli* (EPEC), enterotoxigenic *E. coli* (ETEC), enteroinvasive *E. coli* (EIEC), and enterohemorrhagic *E. coli* (EHEC). APEC strains with diverse gene compositions can be associated with the same clinical expression. Consequently, there are no set of virulence factors allowing to easily separate all APEC from all commensal *E. coli* strains.

Virulence factors include:

- *Adhesins* (fimbrial or nonfimbrial). They allow bacteria to adhere to cell surfaces. (AEEC).
- *Toxins*. *E. coli* causing colibacillosis in birds are not particularly toxigenic. However, some birds, especially pigeons, are reservoirs for shigatoxin (*stx*) producing *E. coli* (STEC), a potential zoonosis. Infected pigeons are healthy carriers.
- *Iron acquisition mechanisms*. This attribute is a key component of the pathogenesis of avian colibacillosis.
- *Protectins*. The ability to resist complement and other components of the immune defenses is an attribute of APEC.
- *Invasins*. Some APEC strains harbor the *ibeA* gene permitting the invasion of microvascular endothelial cells in the brain.
- *Other*. APEC can better resist sanitation when residing in a biofilm; this environment also facilitates acquisition of virulence and resistance genes by horizontal gene transfer.



Fig.45.5: Often, at the flock level, the first indication of a problem is a marginal increase in overnight mortality. Severity of the outbreak is normally greater when deaths are recorded during the day.

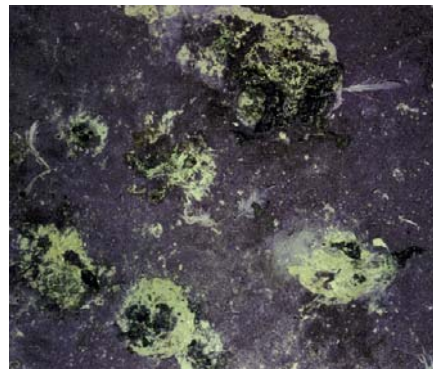


Fig.45.6: Droppings from birds with colibacillosis submitted for necropsy. Feces are green with white to yellow urates because of anorexia and dehydration. Chronic lameness leads to coating of the vent and abdominal feathers with droppings.



Fig.45.7: Birds with colisepticemia are often terminally moribund.

Bacterial diseases

45. COLIBACILLOSIS

INTRODUCTION

Avian colibacillosis encompasses a number of different localized and systemic infections caused by an avian pathogenic *Escherichia coli* (APEC). The disease has a worldwide distribution and all poultry species are susceptible to infection. APEC often takes advantage of impaired host defenses due to co-infections and/or over exposure due to poor environmental conditions. Collectively, the many forms of colibacillosis are the most frequently reported bacterial diseases of commercial poultry flocks and are responsible for significant economic losses.

Most APEC affect only birds and are unlikely to be zoonotic. However, *E. coli* O157:H7, an important zoonotic pathogen, has been isolated from both chickens and turkeys; and pigeons can carry shiga-toxin producing *E. coli* (STEC), which may affect people. APEC may also share multiple virulence factors with human extraintestinal pathogenic *E. coli*, raising the possibility that APEC may be involved in some cases of human disease.

ETIOLOGY

The etiological agent of colibacillosis is *Escherichia coli*, in the family *Enterobacteriaceae*. Infrequently, *E. fergusonii* and *E. albertii*, which can be differentiated from *E. coli* by biochemical and genomic tests, also can cause disease in birds and people. The former affects day-old chicks and can cause fatal disease in adult ostriches; the latter may cause severe intestinal problems.

Escherichia coli is a Gram-negative, non-spore-forming bacillus that readily grows under aerobic and anaerobic conditions at a temperature range of 18–44°C and at a pH between 4.5 and 9. Characteristic colonies develop within 24 hrs at 37°C on MacConkey and eosin-methylene blue agars because of its ability to ferment lactose. The organism typically does not survive 60°C for 30 minutes or 70°C for 2 minutes. It resists freezing and can persist for long periods at cold temperatures (e.g., several weeks at 4°C). The sun, *via* ultraviolet light and high temperature, greatly reduces coliform contamination in water and on hard surfaces. Dryness is also effective. Different organic acids (citric, tartaric, salicylic) reduce the numbers of *E. coli* in litter.

Although washing followed by drying can destroy *E. coli*, this microorganism can develop resistance to a wide range of heavy metals and disinfectants, including formaldehyde, hydrogen peroxide, and quaternary ammonium compounds.

Antigenic structure & characterization

Escherichia coli serogroups are identified by three antigens: O (somatic antigen, endotoxin), K (capsular antigen), and H (flagellar antigen). Currently, there are around 180 O, 60 H, and 80 K antigens. There are other antigens, such as the F (pilus, fimbrial) antigen involved in cell attachment. In terms of O antigen, APEC are diverse with many being untypeable using standard antisera.

The immune response is mainly directed against O antigens. The O1 carbohydrate capsule inhibits phagocytosis and some specific serogroups are consistently associated with disease (e.g., O111 causing mortality, septicemia, and polyserositis in egg-laying chickens).

Characterization of *E. coli* strains may include phenotyping, serotyping, antibiotic resistance profiling, toxigenicity, virulence testing in embryos or chicks, cell attachment, hemagglutination, lysogeny (phage typing), plasmid profiling, phylogenetic typing, and virulence genotyping. Embryo and chick lethality tests can differentiate APEC from commensal *E. coli* strains. There is not a particular virulence factor that differentiates APEC from commensal strains; however, testing for multiple virulence factors is often useful.

Although colibacillosis is usually a secondary disease (i.e., following some primary insult such as infection with *Mycoplasma gallisepticum*, infectious bronchitis virus, or infectious bursal disease virus), there is growing evidence that APEC may occasionally be a primary agent.

Pathogenesis

Escherichia coli are common inhabitants of the intestinal tracts of poultry and most other animals. Their presence in the lower intestinal tract is normally beneficial; even pathogenic strains aid in the bird's growth and development. Evidence exists that it also can inhibit colonization of the intestine by other bacteria including *Salmonella*.

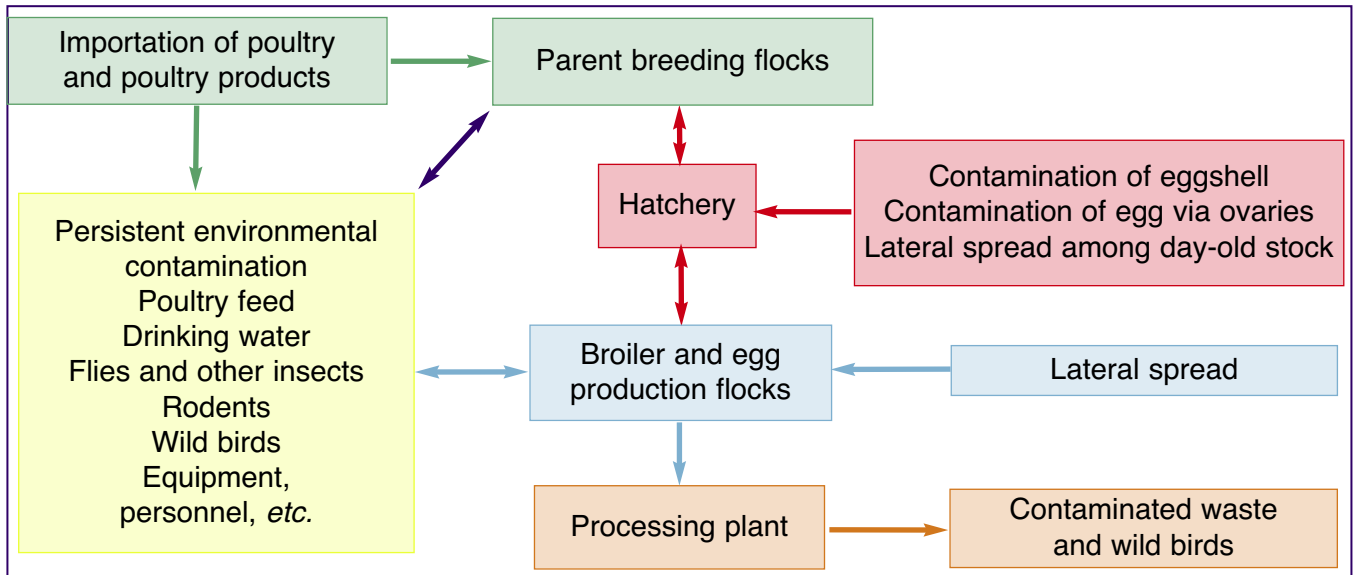


Fig.45.8: Routes of transmission of *Escherichia coli* in poultry broiler flocks (Modified from Lister & Barrow, 2008). *E. coli* only represents a small proportion of total bacteria in litter. Environmental isolates are different from APEC occurring in the flock.



Fig.45.9: Chronically affected birds are usually stunted with poor feathering and lameness. The arched back is typical of spondylitis. This bird also had polyarthritis.



Fig.45.10: Dehydration. Skin of the shanks and feet appears dark and dry. In this 3 day-old dehydrated chick, toenails appear black.

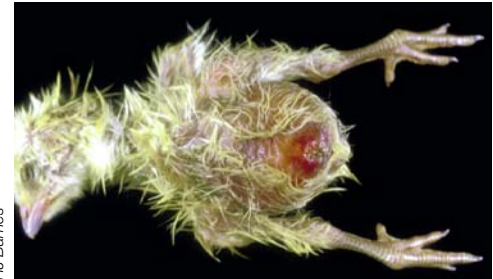

Fig.45.11: Coliform omphalitis/yolk sacculitis. Swelling, edema, redness, and possibly foci of necrosis characterize acute inflammation of the navel.

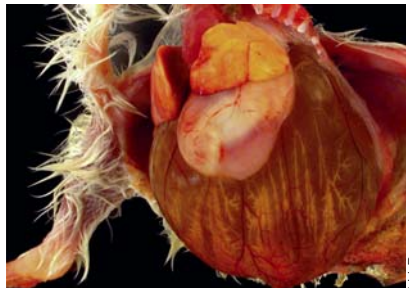


Fig.45.12: Coliform omphalitis/yolk sacculitis. The abdomen is distended and yolk sac blood vessels are hyperemic.

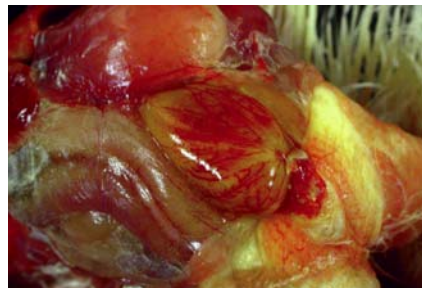


Fig.45.13: Coliform omphalitis/yolk sacculitis. Visceral gout.

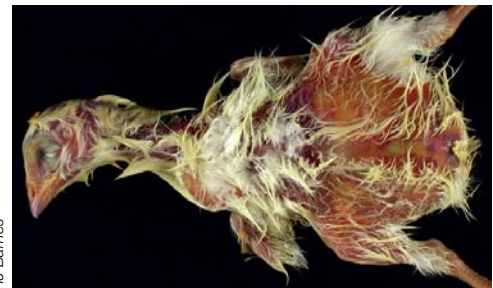


Fig.45.14: Coliform omphalitis/yolk sacculitis. «Mushy chick disease».

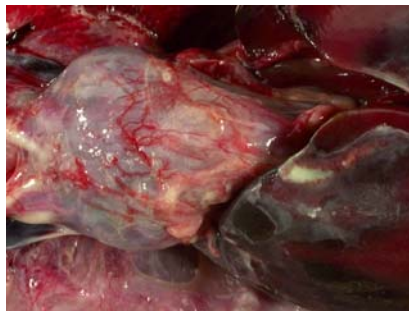


Fig.45.15 & 45.16: Coliform omphalitis/yolk sacculitis. Chicks or poults with infected yolk sacs and living over 4 days often develop pericarditis or perihepatitis, indicating systemic spread of *E. coli*.

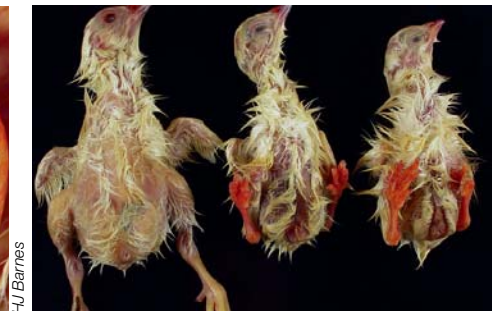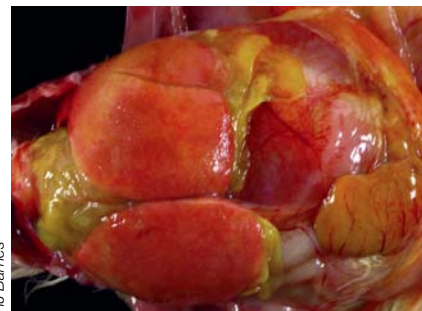


Fig.45.17: Survivors are usually stunted and do poorly. Compare the affected 2 day-old chicks with the normal chick on left.

Escherichia coli have an array of fimbrial and non-fimbrial adhesion factors that allow the organism to attach to enterocyte receptors and colonize the intestinal mucosa. Adhesion factors are often lost when the organism is in the blood stream as they enhance phagocytosis.

When virulent strains pass through the mucosa or enter the body through breaks in the skin, an acute inflammatory response develops within a few hours. Endotoxemia leads to a rapid decrease in feed consumption and efficiency, which limits body and breast weight gain. Bones are also affected with reduced breaking strength. Mortality and increased liver weight, plasma ionized calcium, and antibody responses follow infection. Vascular permeability increases and fluid and serum proteins leak into the tissues, making serous membranes edematous. *E. coli* cause cellulitis after invasion directly through skin.

Fibrinogen in the plasma is converted to fibrin by thrombin when it contacts tissues outside of the vascular compartment. Endotoxin is strongly chemotactic for heterophils, which, when combined with the fibrin, leads to deposition of fibrinoheterophilic exudate that becomes progressively caseated and grossly recognizable. Terminally, in birds that survive, the inflammatory process becomes granulomatous and damaged tissue is ultimately replaced by fibrous scar tissue.

Highly virulent APEC do not produce severe lesions because death occurs before they can develop. Often the only changes seen are edema of serous membranes and a markedly enlarged congested spleen. By contrast, less virulent strains typically produce extensive caseous (“cheese-like”) lesions.

EPIDEMIOLOGY

Escherichia coli are distributed worldwide and all poultry species are susceptible to colibacillosis. Egg transmission occurs frequently, which can result in embryo infection and high early chick mortality. The bacterium enters the egg through pores in the shell following fecal contamination of the egg surface. Spread of *E. coli* is rapid after hatching. Turkey hens artificially inseminated with contaminated semen is another route of infection. Horizontal transmission occurs *via* direct and indirect contact between birds in a flock. Common sources of pathogenic coliforms include feed,

rodent droppings, wild birds, and well water. Larval and adult darkling beetles (*Alphitobius diaperinus*) and adult houseflies (*Musca domestica*) are excellent mechanical vectors of *E. coli*. The incubation period is variable, depending on the disease caused by *E. coli*. Under field conditions, colisepticemia normally occurs 5 to 7 days after infection by primary agents (e.g., infectious bronchitis virus, Newcastle virus, *Mycoplasma gallisepticum*, hemorrhagic enteritis virus, *etc.*).

Host susceptibility factors

Host susceptibility is an important determinant for the expression of the disease. Healthy birds with a normal immune system usually resist *E. coli* infection, including most virulent strains. Lesions develop and clinical disease occurs when the mucosal and skin barriers are disrupted, the immune system is compromised, or the exposure is overwhelming. Among the important factors that increase susceptibility are environmental stress and damage to the respiratory mucosa by other infectious agents or high levels of ammonia or dust in the house.

CLINICAL SIGNS & LESIONS

Clinical signs (including morbidity and mortality rates) vary greatly depending on the disease or lesion produced by *E. coli*. There is no age predisposition, although younger birds are more often affected with more severe clinical disease. Clinical signs may be absent when the lesion is mild or localized and when birds die peracutely. With bacterial septicemia in broiler chickens, the first indication of a problem is often a marginal increase in overnight mortality. In caged layers and broiler breeder hens, coliform salpingitis/peritonitis is a common cause of sporadic mortality.

Birds with colisepticemia may become lethargic and stop eating and drinking. Severely affected birds become moribund and unresponsive. Dehydration is readily visible with the skin of the shanks and feet appearing dark and dry. Young dehydrated birds have prominent raised folds of skin mainly along the sides of the shanks and dark, occasionally, black toenails. The degree of reduced water consumption indicates the severity of the disease. Chronically affected birds are often stunted and unthrifty. When joints, tendons, and/or bones are affected, birds will show lameness and can become non-ambulatory if either both legs or the spine are affected.

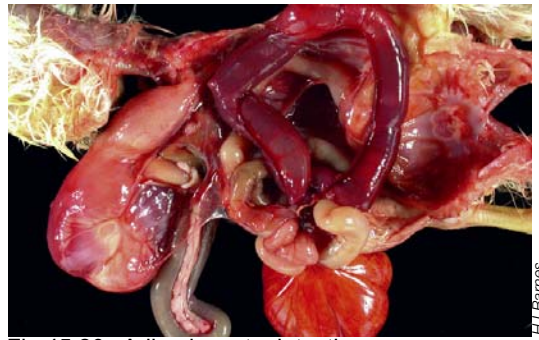
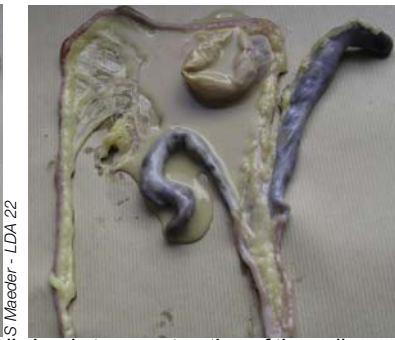

Fig.45.18 & 45.19: Inflammation eventually leads to a contraction of the yolk sac, with *E. coli* persisting in the inflamed sac for several weeks.

Fig.45.20: Adhesions to intestines are common. Occasionally the elongated stalk of the yolk sac will strangulate the intestine.

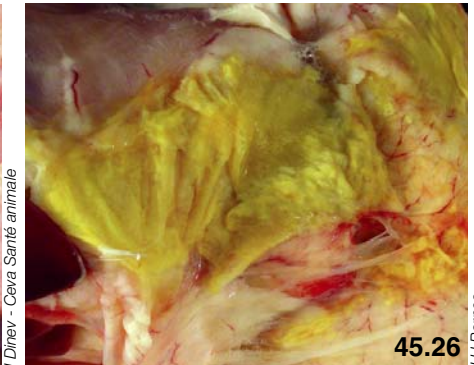
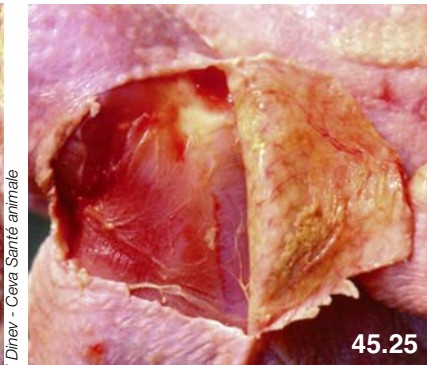
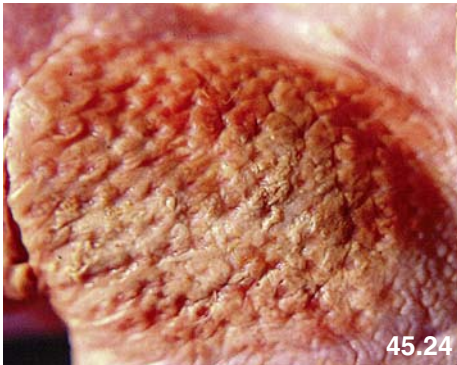
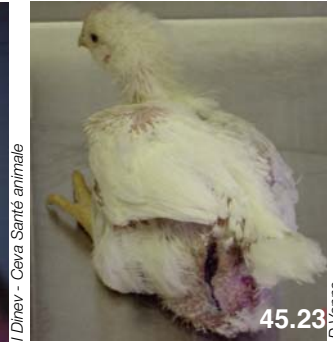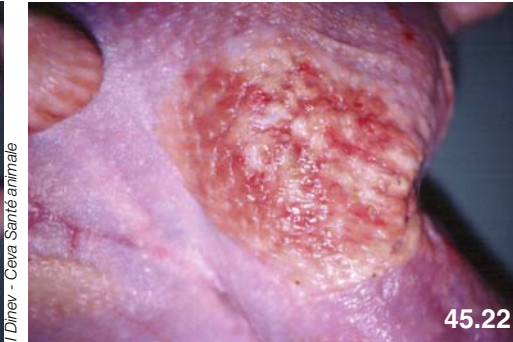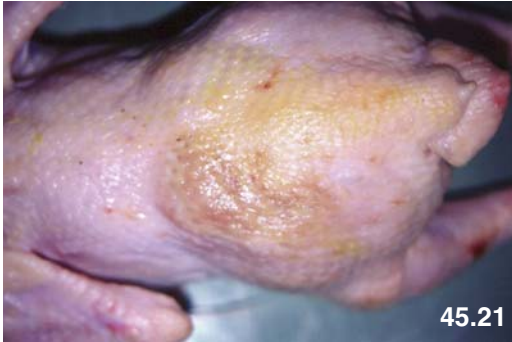


Fig.45.21, 45.22, 45.23, 45.24, 45.25 & 45.26: Coliform cellulitis. Lesions are often unilateral and located on the abdomen or thigh. Although the skin covering the lesion may appear normal, in most cases it is yellow to red-brown and swollen. The size of the lesion varies greatly (Fig.45.21 & 45.22). Skin scratches and scabs are often found overlying the lesions (Fig.45.23). Subcutaneous edema, exudate, and hemorrhage are found under the skin (Fig.45.24 & 45.25). Serosanguinous to caseated exudate forming plaques in subcutaneous tissues is characteristic of coliform cellulitis. Lesions are identified at processing (Fig.45.26).

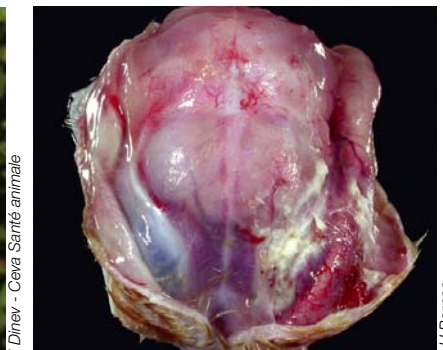



Fig.45.27: Valgus-varus leg deformity is often more prevalent in carcasses condemned for cellulitis.

Fig.45.28 & 45.29: Swollen head syndrome: an acute to subacute form of cellulitis affecting the subcutaneous tissues around the periorbital area, giving a swollen appearance to the head in chickens, turkeys and guinea fowl. It follows upper respiratory viral infections and may be worst in flocks with high ammonia concentration in the environment.

Localized forms of colibacillosis

Coliform omphalitis/Yolk sac infection

Inflammation of the navel (omphalitis) of newly hatched chicks often leads to concurrent infection of the adjacent yolk sac (yolksacculitis). Poor hatchery hygiene and eggshell contamination are important sources of infection. Low numbers of *E. coli* can often be isolated from normal yolk sacs. Occasionally, greater contamination occurs *in ovo* when hens have oophoritis or salpingitis. Translocation of bacteria from the bird's intestine or from the bloodstream may also lead to yolk sac infection. If the *E. coli* strain is not very virulent, embryos and young birds may live, some having a retained, infected yolk sac. However, yolk sac infection can lead to embryo mortality and, with some highly virulent strains, such as serogroup O1a:K1:H7, none of the exposed embryos and newly hatched birds survived. When infected newly hatched birds do survive, they can be a source of *E. coli* for their hatchmates. If the hatching environment is too dry, this can lead to a high incidence of omphalitis and yolksacculitis occurs, mainly during the first week of life.

An infected yolk sac is not absorbed; hence, it is distended, usually smelly, and abnormal in color and consistency (liquid, flocculent, coagulated). Affected birds are often dehydrated, stunted, and may have vent pasting and an enlarged gall bladder. Tissue around the navel is often wet and red (inflamed); which is why the disease is often called "mushy" chick or poult disease. Although *E. coli* is the most frequent pathogen associated with omphalitis, other bacteria also can cause this condition including *Bacillus cereus*, *Staphylococcus* spp., *Pseudomonas aeruginosa*, *Proteus* spp., and *Enterococcus* spp.). At necropsy, abnormal yolk consistency is indicative of yolk sac infection.

Coliform cellulitis

Coliform cellulitis, principally a disease of chickens, produces sheets, also called plaques, of serosanguinous to caseous exudate in subcutaneous tissues commonly located over the abdomen or between the thigh and midline. Cellulitis in turkeys is a different condition caused by *Clostridium* (see Chap.III.51).

Although growth performance may be affected, clinical signs are usually absent and lesions are

seen at processing following defeathering revealing a thickened yellow abdominal skin. This disease emerged during the mid-80s causing increased condemnations and downgrading at processing. Although other bacteria may be present, in over 90% of cases, *E. coli* is isolated in pure culture. *E. coli* strains causing coliform cellulitis are the same serogroups as those found in other forms of colibacillosis.

Environmental and husbandry factors play important roles in the occurrence of the disease. Fast-growing, heavy broiler lines are more likely to have skin scratches, which predispose to coliform cellulitis. Aggressiveness or nervousness of some genetic lines of chickens may also be determinant contributor. Other risk factors include poor feathering, crowded conditions, litter quality (straw is associated with coliform cellulitis compared to shavings or sawdust), high ambient temperature and relative humidity, feed (higher incidence with vegetarian feed compared to feeds containing animal products), age (older chickens), sex (male), and musculoskeletal problems (e.g., valgus-varus leg deformity, which leads to greater contact exposure between the skin and the *E. coli* present in the litter). Supplementation with vitamin E or vitamin A act as protective factors, however, high doses of vitamin E are not effective. Longer downtimes (time between removal and placement of flocks) lower the prevalence of cellulitis. Although the hatchery of origin was initially considered a possible source of infection, this hypothesis has largely been disproved over the years.

Occasionally, systemic colibacillosis (colisepticemia) occurs concurrently with cellulitis. It is not clear whether systemic infection has resulted in localized skin lesions or it has originated from the skin lesions.

Treatment and eradication of coliform cellulitis are not possible. However, acting on known risk factors can greatly reduce the prevalence of the disease. As lesions may be present within 12 hours after a bird is scratched, even loadout and transportation conditions to processing should be investigated when acute lesions are present. On farm, stocking density, feeder and waterer space, type and quality of litter, feed restriction, and lighting programs represent key factors to investigate. Essentially, it is worth considering all risk factors that could lead to skin scratches and increased contamination where chickens are housed.

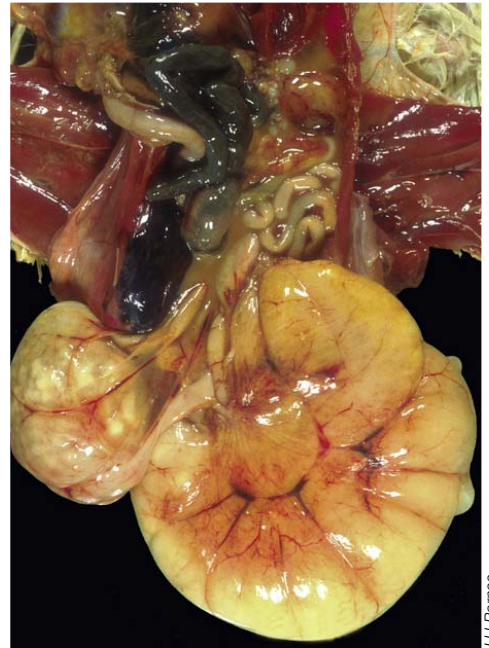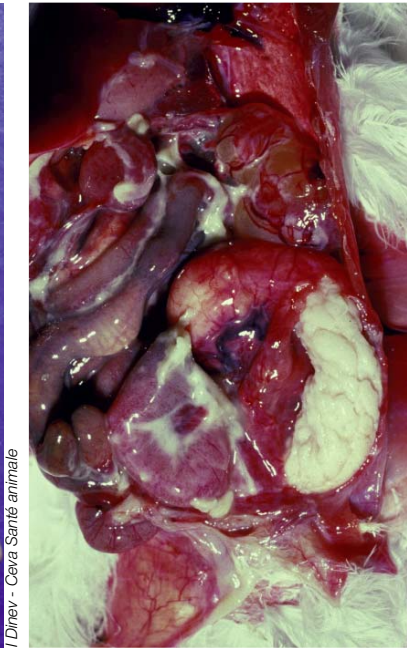

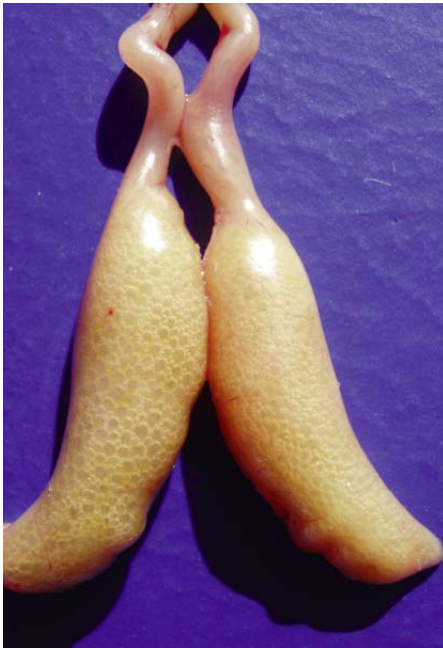
Fig.45.30: Enterotyphlitis. Ceca filled with pale brown fluid and gas.

Fig.45.31 & 45.32: Coliform salpingitis. Large caseated masses distending the oviduct. In chronic cases, the oviduct is thin-walled.

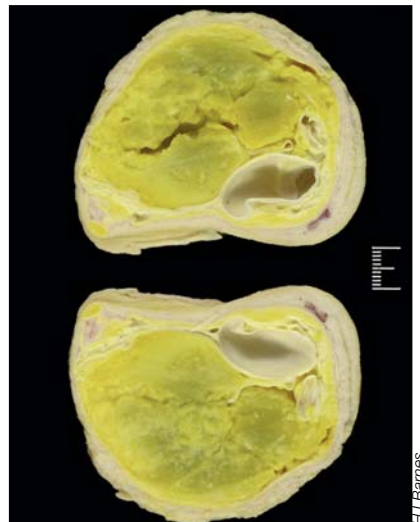
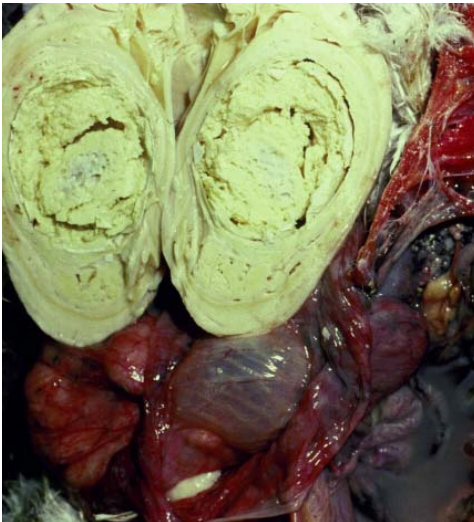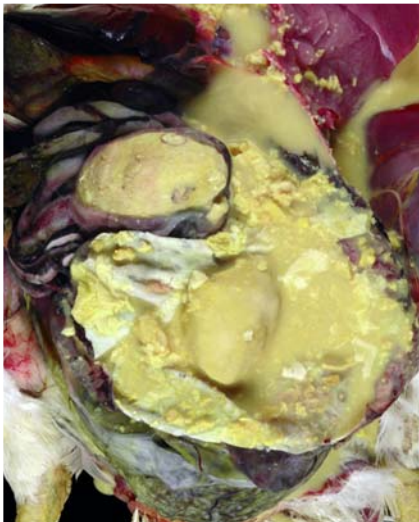


Fig.45.33: Coliform salpingitis. The mass of exudate may almost fill the body cavity.

Fig.45.34 & 45.35: Coliform salpingitis. Exudate is laminated, often contains a central egg, shells, and/or membranes, and is malodorous.

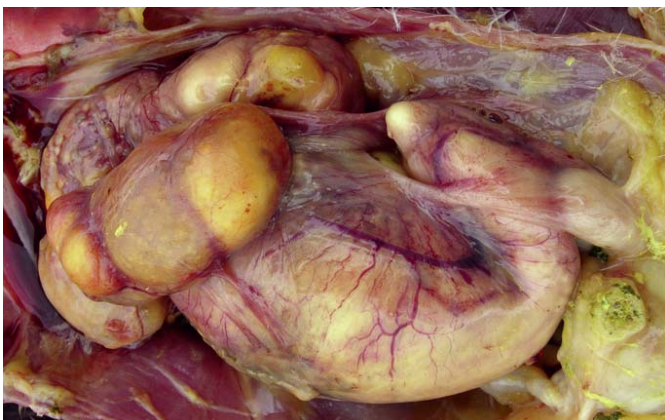

Fig.45.36 & 45.37: Coliform salpingitis. Less exudate and caseation is seen in acute cases. But affected hens are normally no longer producing eggs.

Swollen head syndrome

This is a relatively uncommon acute to subacute form of cellulitis affecting the subcutaneous tissues of the periorbital area, giving a swollen appearance to the face of chickens, turkeys, and guinea fowl. It usually follows viral upper respiratory infections (e.g. infectious bronchitis virus) and is worst in flocks exposed to high ammonia levels in the air.

Diarrheal disease

In contrast to mammals, primary *E. coli* enteritis is rare in poultry. A few strains are capable of attaching and effacing the intestinal epithelium causing enteric disease. They are called attaching and effacing *E. coli* (AEEC). Depending on which virulence factors AEEC isolates possess, they are further classified as enterotoxigenic (ETEC), enterohemorrhagic (EHEC), enteropathogenic (EPEC), or enteroinvasive (EIEC).

Natural infections with AEEC have been seen in chickens, turkeys, pigeons, ducks, and other avian species. Predisposing factors to AEEC infection include immunosuppressive pathogens such as infectious bursal disease virus in chickens and adenovirus infection in pigeons. When clinical signs are present, birds have diarrhea and are dehydrated. In turkey poults, experimental coinfection of EPEC with turkey coronavirus (TCV) caused high mortality and a marked reduction in daily gain; but when poults were infected with EPEC alone, mortality and weight gain were similar to control birds. Specific strains of *E. coli* have been associated with poult enteritis mortality syndrome in turkeys (see Chap.IV.72).

Intestines and ceca of affected birds are pale and distended with fluid and flecks of mucus. Characteristic “pits and pedestals” attaching effacing lesions covered with adhering *E. coli* are seen in the intestines. Ceca are most commonly affected but lesions in the small intestine are in seen when the disease is severe.

Venereal colibacillosis (acute vaginitis)

Venereal colibacillosis affects turkey breeder hens following their first insemination. Vaginitis is acute and often causes death. Cloacal and intestinal prolapse, peritonitis, egg binding, and internal laying often accompany vaginitis. The mucosa of affected hens is thickened, ulcerated, and covered with a caseo-necrotic membrane. The upper oviduct is normal. Excess mortality and culling occurs. Egg production is also affected, being reduced with a greater number of small eggs.

Coliform salpingitis/peritonitis/salpingoperitonitis

Infections of the oviduct with extension to the peritoneum are common causes of sporadic mortality and decreased egg production in commercial layers, chicken and turkey breeders, and female ducks and geese. A firm mass or masses of caseous exudate are found in the oviduct, which obstructs and greatly distends the oviduct. Extensive inflammation and exudation of peritoneal surfaces is seen in coliform peritonitis. In contrast, yolk peritonitis is normally a mild diffuse inflammation associated with free yolk in the body cavity.

Salpingitis originates from *E. coli* in the cloaca (ascending infection). Some primary agents (e.g., infectious bronchitis virus, mycoplasmas) may predispose hens to this infection. Egg-binding or other oviductal obstruction is another predisposing factor. Cutting through the mass in the oviduct often reveals an old developing egg in the center surrounded by multiple layers of exudate. Over conditioned heavy hens are prone to develop the disease. Salpingoperitonitis occurs when *E. coli* spreads from the oviduct into the abdomen.

In immature birds, the oviduct becomes infected by extension from airsacculitis involving the left abdominal air sac.

Coliform orchitis/epididymitis/epididymo-orchitis

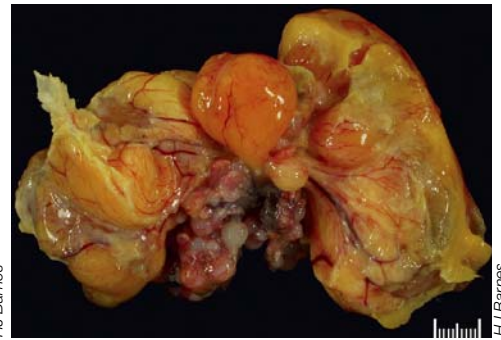
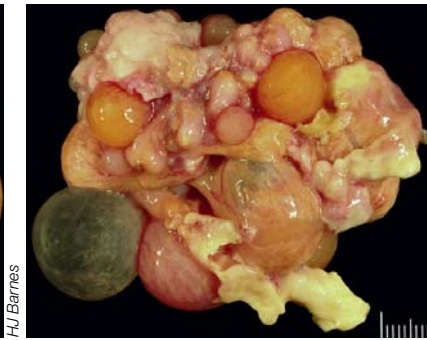
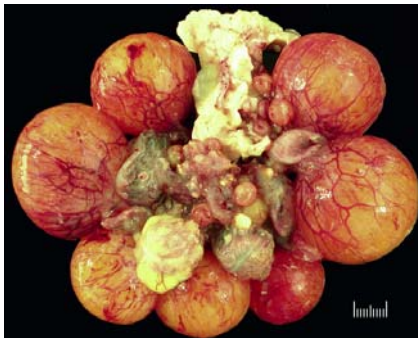This rare disease of roosters also is an ascending *E. coli* infection that is the male counterpart of salpingitis in the female.

Affected testes and epididymides are swollen, firm, irregularly shaped, and may have adhesions to adjacent tissues; necrosis is extensive. Lesions are typically unilateral. *E. coli* is easily isolated from affected tissues.

Systemic forms of colibacillosis

Colisepticemia

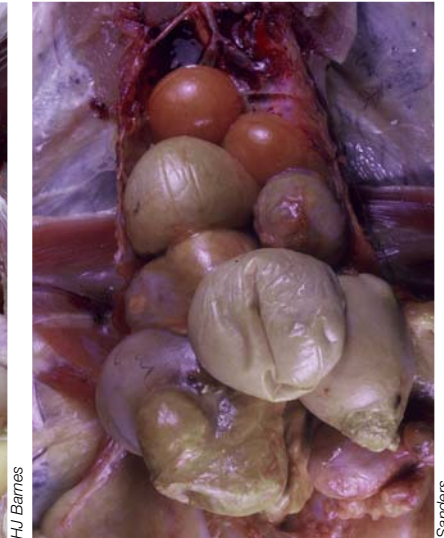
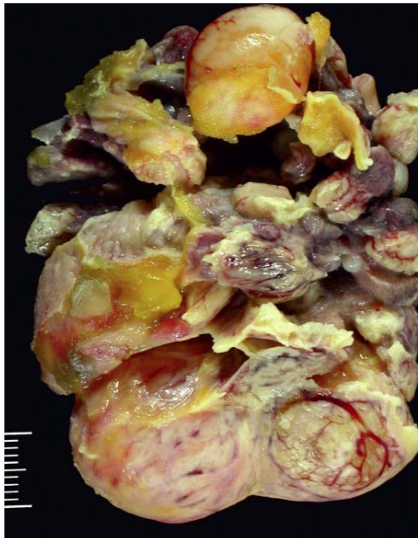
Infection pressure (quantity of bacteria in direct contact with the bird), virulence factors, and the bird's defense mechanisms interplay to determine the duration and severity of the disease. Colisepticemia may be acute, subacute with polyserositis, or chronic with granulomatous inflammation. Even though gross lesions are characteristic of colisepticemia, other bacteria also can occasionally produce septicemic lesions. It is necessary to isolate from appropriate tissues and identify *E. coli* to confirm a diagnosis of colisepticemia.



H.J Barnes

H.J Barnes

H.J Barnes

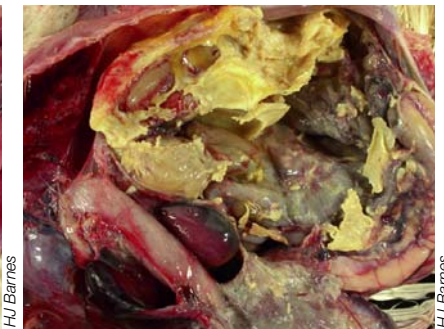
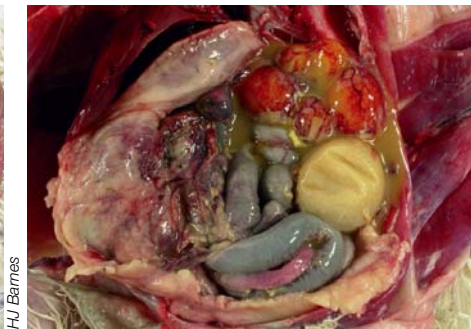
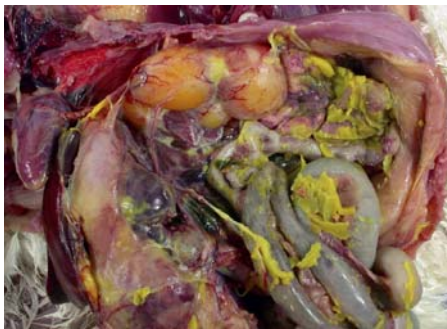


H.J Barnes

H.J Barnes

Sanders

Fig.45.38, 45.39, 45.40, 45.41, 45.42 & 45.43: Oophoritis.



H.J Barnes

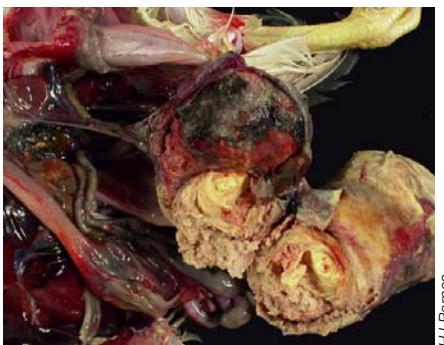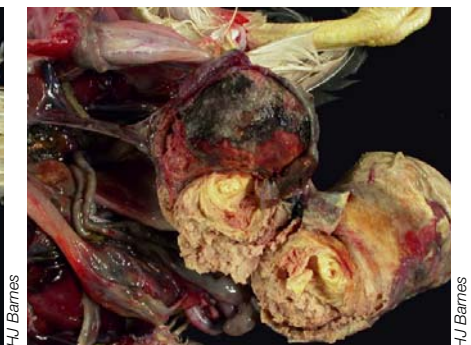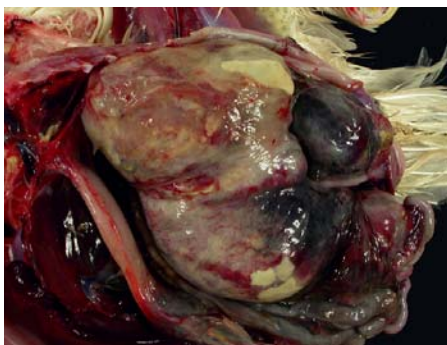H.J Barnes

H.J Barnes

Fig.45.44: Infectious peritonitis: *E. coli* infection of serous membranes in the body cavity.

Fig.45.45: Abdominal laying may accompany salpingitis and contribute to peritonitis.

Fig.45.46: Salpingo-peritonitis and oophoritis.



H.J Barnes

H.J Barnes

H.J Barnes

Fig.45.47, 45.48 & 45.49: Salpingo-peritonitis and oophoritis. It is common for the oviduct and peritoneum to be involved concurrently in *E. coli* infections.

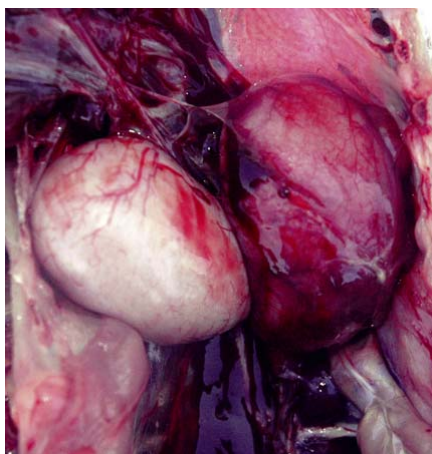

Fig.45.50: Coliform orchitis. It is an ascending (from the cloaca) *E. coli* infection reaching the testicles that are swollen, firm, irregularly shaped with partly necrotic tissues. Peritonitis is also observed.



Fig.45.51: Colisepticemia. Green discoloration of the liver.

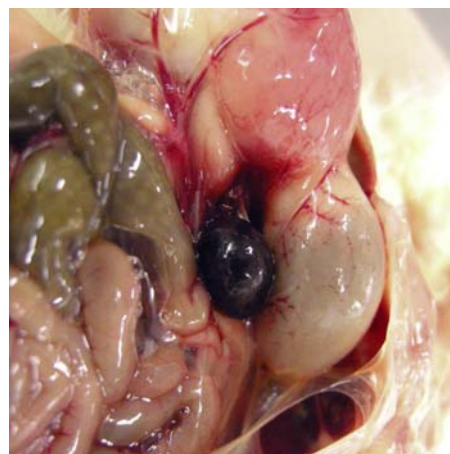

Fig.45.52: Hemorrhagic spleen picture: 4 day-old broiler breeder pullet with colisepticemia. The spleen is enlarged and looks hemorrhagic. This is a frequently seen lesion in few-day-old chickens with colisepticemia. Culture of such a spleen almost always yields a heavy, pure growth of *E. coli*.

Depending on the chronicity of the disease, the bursa of Fabricius may be atrophied or inflamed because of colisepticemia. Bursal atrophy can be solely caused by *E. coli* without involvement of a primary agent such as infectious bursal disease virus.

Pericarditis is frequently observed and may be associated with myocarditis. The pericardium becomes cloudy and edematous due to inflammation and exudation. Initially, exudate in the pericardial sac is fluid, but it rapidly becomes caseous and yellow to white. The pericardial sac then adheres to the epicardium. With time, the inflamed adherent pericardial sac undergoes organization (fibrosis), which results in constrictive pericarditis and heart failure. Other common lesions are fibrinous perihepatitis (hepatic serositis) and an enlarged, markedly congested spleen. Tissues often develop a green to gray-green discoloration as they sit after necropsy.

Clinical signs associated with colisepticemia vary depending on the type of bird, its age, and how *E. coli* gets into the bloodstream.

Respiratory-origin colisepticemia

This is the most frequent type of colisepticemia in broiler chickens, ducks, and turkeys. Primary agents (e.g., field and vaccine strains of infectious bronchitis virus and Newcastle disease virus, mycoplasmas, avian metapneumovirus in turkeys, dust, ammonia, etc.) injure the respiratory mucosa, allowing *E. coli* to enter the blood stream. There is airsacculitis of varying severity, and the lesion is

usually of long duration. This expression of the disease used to be called chronic respiratory disease or CRD when *Mycoplasma gallisepticum* was the initial insulting agent. Infected air sacs are thickened, opaque, and may contain caseous exudate. Other respiratory lesions include pneumonia (more frequent in turkeys), pleuritis (more frequent in chickens), and pleuropneumonia. In addition to airsacculitis and lung lesions, affected birds usually have peritonitis and other lesions consistent with bacterial septicemia.

Enteric-origin colisepticemia

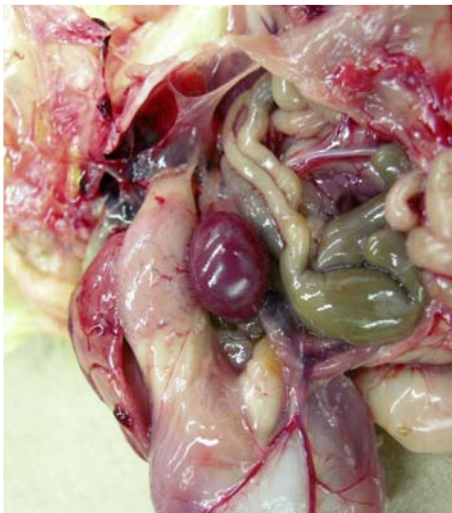Enteric-origin colisepticemia is mainly seen in turkeys following hemorrhagic enteritis virus (HEV) infection. HEV damages the intestinal mucosa and is immunosuppressive. *E. coli* crosses the intestinal mucosal barrier and enters the bloodstream, rapidly causing acute lesions of pericarditis, perihepatitis, etc. Because it is quite sudden, affected birds are normal in appearance and are often found dead with a full crop.

Hemorrhagic septicemia

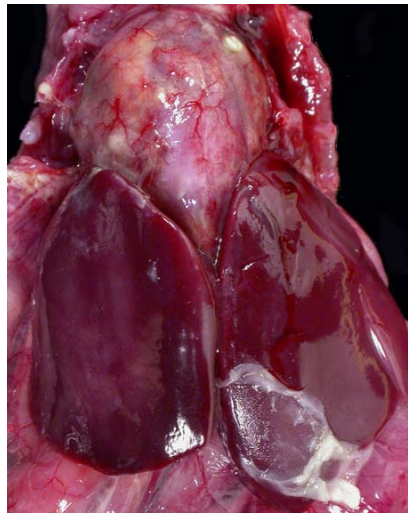
This condition affects turkeys, causing widespread circulatory disturbances. Pulmonary edema and hemorrhage are observed with hepatomegaly, splenomegaly, and swelling of the kidneys. Necrotic tissues are found in the liver and spleen.

Neonatal colisepticemia

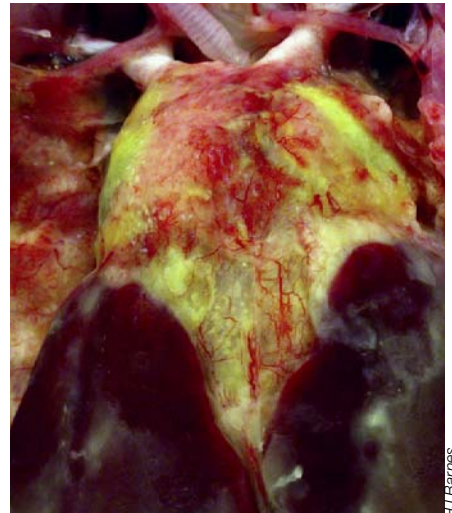
Chicks and poults are affected within two days post-hatch. Mortality may be higher than expected



TA Abdul-Aziz



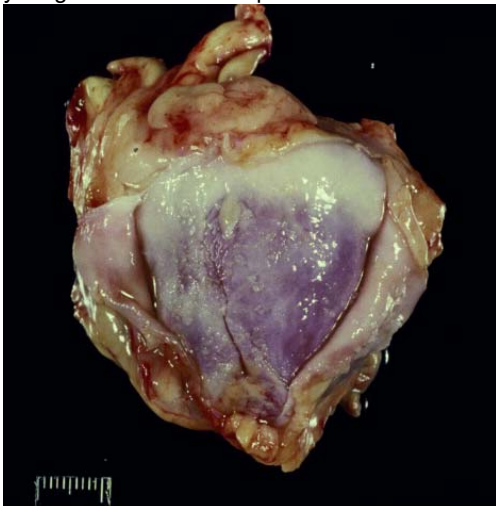
HJ Barnes



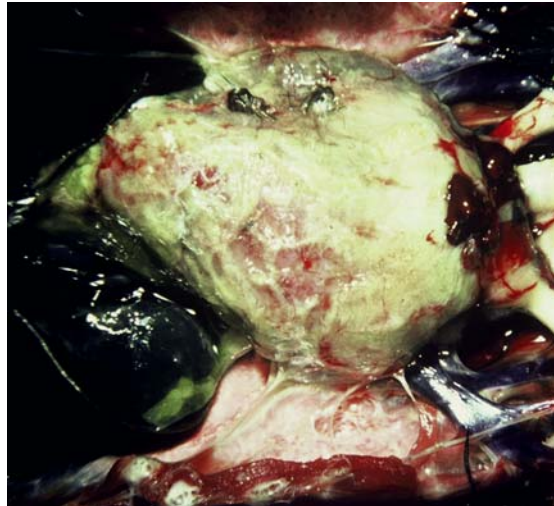
HJ Barnes

Fig.45.53: Enlarged spleen picture: 4 day-old broiler with colisepticemia. The spleen looks enlarged. This is a common lesion in young chicks with colisepticemia.

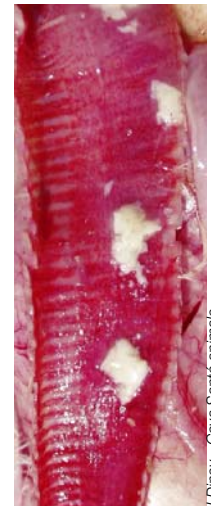Fig.45.54 & 45.55: Colisepticemia. Pericarditis and perihepatitis. Perihepatitis results from inflammation of the peritoneum covering the liver. Exudate is often thick because of gravity.



HJ Barnes



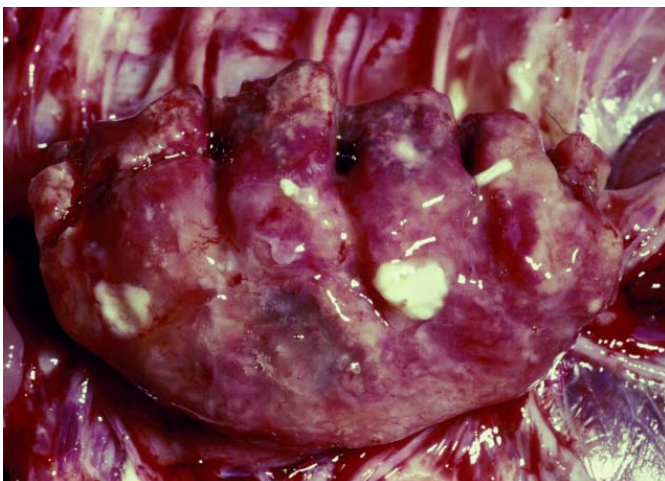
J Brugère-Picoux



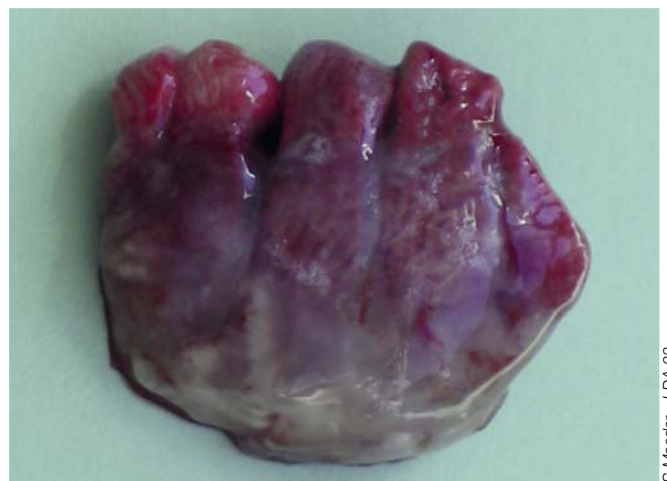I Dinev - Ceva Santé animale

Fig.45.56 & 45.57: Colisepticemia. Pericarditis. Chronic lesions are occasionally seen at the slaughter plant. Scarring as the exudate organizes leads to constrictive pericarditis and right heart failure.

Fig.45.58: Respiratory-origin colisepticemia. Tracheitis.



HJ Barnes



S Maeder - LDA 22

Fig.45.59 & 45.60: Respiratory-origin colisepticemia. Pneumonia (more frequent in turkeys), airsacculitis and pleuropneumonia are common. Infection can spread to neighboring tissues, causing pericarditis, peritonitis, and salpingitis in juvenile birds.

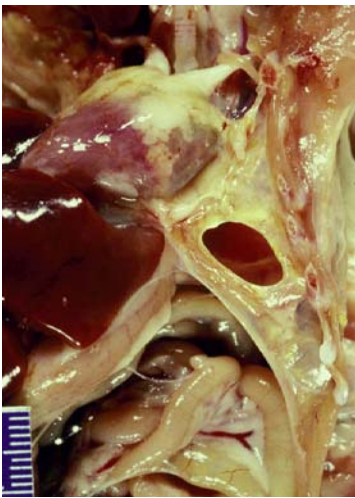

Fig.45.61: Respiratory-origin colisepticemia. Airsacculitis. Infected air sacs are thickened and caseous exudate may be present.

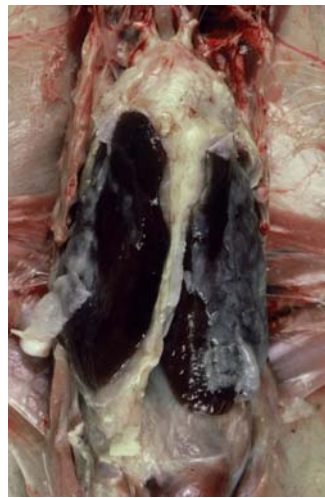
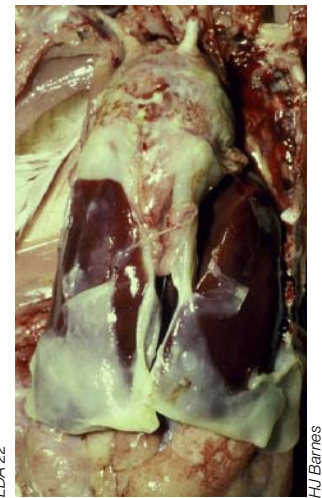
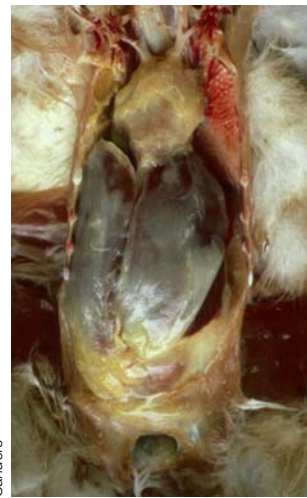Fig.45.62, 45.63 & 45.64: Respiratory-origin colisepticemia. Serofibrinous polyserositis (perihepatitis, pericarditis, etc.).



for the first few days after hatching. Early lesions consist of congestion of the lungs, edema of serous membranes, and enlargement of the spleen. An enlarged and/or hemorrhagic spleen may be the only lesion seen in some birds. Following death, the proventriculus and lungs progressively darken because of the action of *E. coli* on iron released from hemoglobin. A few days later this may lead to lesions of pericarditis, pleuritis, airsacculitis, and peritonitis. As survivors remain stunted, culling may be required and can reach 2 to 5% of the flock. This form of colisepticemia is not contagious.

Colisepticemia in laying chickens and turkey breeders

Acute colibacillosis is an emerging condition in laying hens and turkey breeders. Although colisepticemia is not as frequent as it is in younger birds, adult chickens and turkeys can be affected. Most outbreaks occur at the onset of egg production. The disease may spread between flocks on the same farm. Once contaminated, the barn that housed an affected flock is a site of repeat outbreaks. Mortality is usually sudden; however, signs of depression may be observed in some birds prior to death. Mortality can reach 10% over several weeks.

Coliform septicemia of ducks

Coliform septicemia of ducks causes pericarditis, perihepatitis, and airsacculitis. The liver and spleen

are swollen and dark. A distinctive odor at necropsy has been reported. Serogroup O78 is most frequently recovered from affected birds.

Other lesions

Birds that survive colisepticemia often develop chronic lesions including osteomyelitis, arthritis, tenosynovitis, and spondylitis. Lameness should always be examined for osteomyelitis, especially at the proximal end of tibiotarsi. Meningitis and encephalitis caused by *E. coli* occur in young chickens when *E. coli* localizes in central nervous system. Affected birds have neurologic signs of paddling and/or twisting of the neck. Panophthalmitis is occasionally seen and is characterized by severe inflammation and damage to the internal eye tissue. It is typically unilateral.

Turkey osteomyelitis complex is a condition affecting bones, joints, and periarticular soft tissues. When present, the liver is enlarged and green. This discoloration is used by slaughter plant inspectors to investigate further the possible presence of osteomyelitis.

Coligranuloma (Hjarre's disease) is a sporadic form of colibacillosis that affects chickens, turkeys, and quail. Multiple granulomas occur in the liver, proventriculus, ventriculus, small intestines, ceca, and mesentery. The spleen is not affected. On rare occasions, a majority of birds can be affected in a flock.

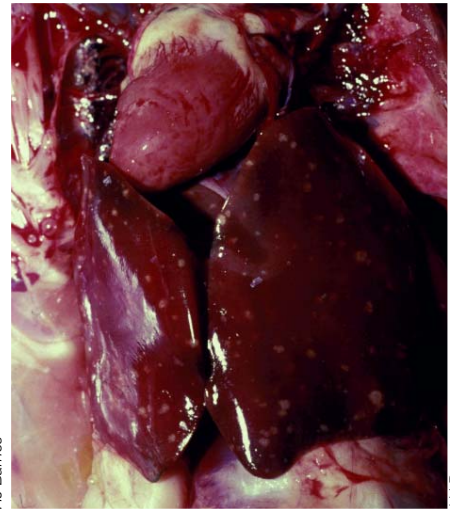
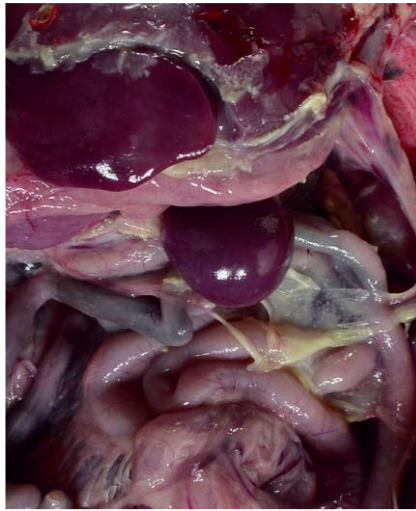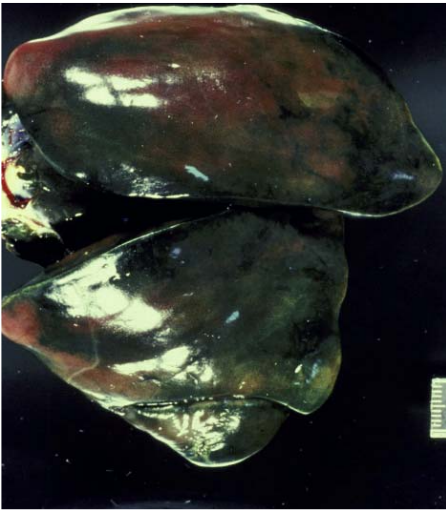


Fig.45.65, 45.66 & 45.67: Enteric-origin colisepticemia. Characteristic lesions are congestion and green discoloration of the liver (Fig.45.65), splenomegaly (Fig.45.66), and congested muscles. Occasionally, multiple, pale foci in the liver are observed (Fig.45.67).

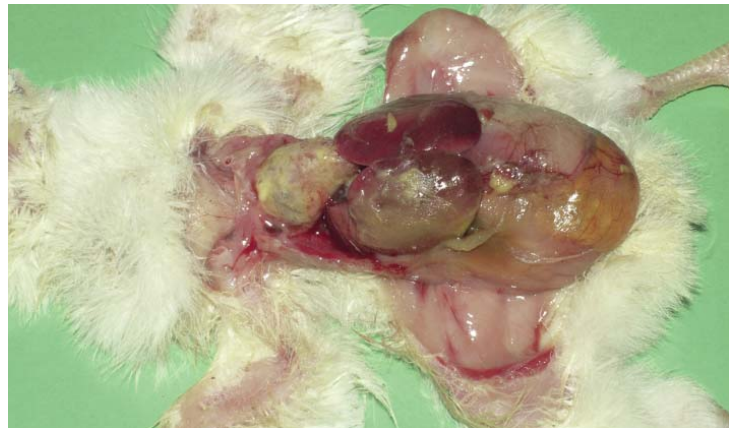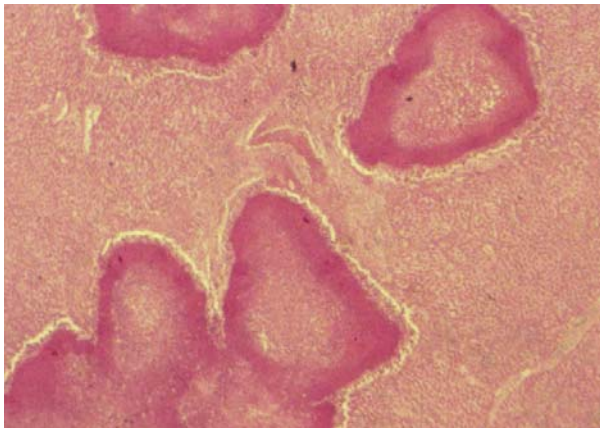


Fig.45.68: Enteric-origin colisepticemia. Liver. Microscopically, areas of acute necrosis turn into granulomatous hepatitis in surviving birds.

Fig.45.69: Neonatal colisepticemia. At first, congested lungs are noticed with edema of serous membranes, and an enlarged spleen. The lungs develop a dark color. A few days later this may lead to lesions of pericarditis, pleuritis, airsacculitis, and peritonitis. Enlarged, pale or hemorrhagic spleen is a common lesion. Because survivors remain stunted, culling may be required and can reach 2 to 5% of the flock.

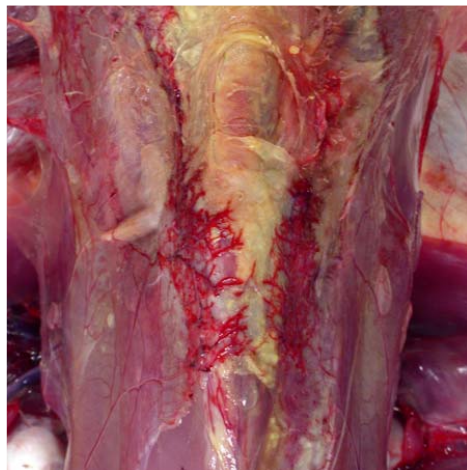

Fig.45.70, 45.71 & 45.72: Osteoarthritis, synovitis & spondylitis. Bones most often affected are the tibiotarsus, femur, thoracolumbar vertebra, and humerus (Fig.45.70). Tenosynovitis is often observed with arthritis. Occasionally, the infection spreads from a joint into the periarticular tissues. Infectious sternal bursitis is also frequent but must be differentiated from traumatic sternal bursitis (Fig.45.71). Lesions in the articulating free thoracic vertebra cause spondylitis, leading to paresis and paralysis (Fig.45.72).

DIAGNOSIS**Isolation & identification**

Diagnosis is based on isolation and identification of *E. coli* from lesions. Several media may be used to grow *E. coli* (Eosin-Methylene Blue, MacConkey, tergitol-7 and non-inhibitory agars). As *E. coli* is a normal inhabitant of the intestine, it is important to avoid fecal contamination when sampling affected tissues. In cases of septicemia, bone marrow and brain are good sites to sample as they are not affected by postmortem spread from the intestines. Pericardial sac swab, liver, and spleen are excellent specimens for bacterial isolation from culled or freshly dead birds with subacute lesions (pericarditis, perihepatitis, airsacculitis, *etc.*).

Determination of virulence factors and fingerprinting of isolates are useful for epidemiologic investigations. Six virulence genes associated with pathogenic strains have been identified in the majority of APEC isolates: iron-related genes (*sitA*, *ironN*, and *iutA*), toxin/bacteriocin-related genes (*hlyF*), protectins (*Iss*), and *etsA*. Resistance to complement is an important indicator of virulence.

As these 6 virulence genes are rarely found in commensal strains, a multiplex PCR has been developed to distinguish between commensal and pathogenic isolates.

Differential diagnosis

Several bacteria cause lesions similar to those seen in colisepticemia. It is important to keep in mind that *E. coli* may also be present concurrently with the pathogens listed below:

Acute septicemia: *Pasteurella*, *Ornithobacterium*, *Riemerella*, *Salmonella*, *Streptococcus*, *Staphylococcus*, *Pseudomonas*, *etc.*

Pericarditis and peritonitis: *Chlamydia* (uncommon), *Pasteurella multocida*, *Streptococcus* spp., and *Enterococcus* spp. In ducks, *Riemerella anatipestifer* may also cause airsacculitis.

Airsacculitis: *Pasteurella*, *Mycoplasma* spp., and *Chlamydia*.

Yolk sac infection: Species of the genera *Aerobacter*, *Klebsiella*, *Proteus*, *Salmonella*, *Bacillus*, *Staphylococcus*, *Enterococcus*, *Clostridium*, *etc.*

Liver granulomas: Anaerobic bacteria from the genera *Eubacterium* and *Bacteroides*.

TREATMENT

Concerns over the development of antibiotic resistance have changed how colibacillosis is treated in the commercial poultry industry. It is best to perform a sensitivity test in order to select the proper antibiotic. However, when treating colibacillosis, time is of the essence. Hence, veterinarians in the field will usually take samples for sensitivity testing but will simultaneously initiate treatment based on past experiences (e.g., apramycin, neomycin). Multiresistance is common with APEC (e.g., tetracyclines, sulfonamides, ampicillin, and streptomycin). Anticoccidials such as monensin, have antimicrobial properties that help in the control of coliforms.

In order to minimize using antibiotics, efforts have gone into developing alternative strategies including prebiotics, probiotics (e.g., *Bacillus* spp.), enzymes, digestive acidifiers, vitamins, immune enhancers, anti-inflammatory drugs, *etc.*

CONTROL**Management**

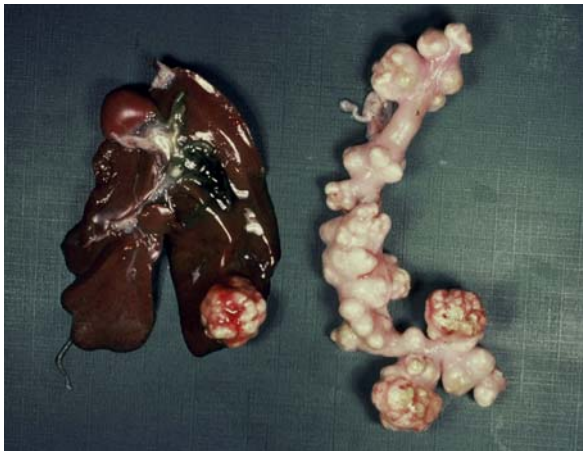Determining and correcting risk factors are essential to controlling colibacillosis. It starts with obtaining newly hatched birds from disease-free breeder flocks (e.g., *Mycoplasma*-free) and hatcheries (not setting eggs with contaminated shells - floor eggs). Next, attention must be paid to flock management (e.g., good air and litter quality with adequate ambient temperature); access to quality feed (pelleted is associated with lower incidence), and water. Water is often overlooked as a source of APEC. Sanitation of drinking water is particularly important and closed (nipple) watering systems have contributed greatly to reducing the incidence of colibacillosis (see Chap.V.81 on water quality for recommendations regarding sanitation). Adequate ventilation minimizes respiratory tract damage caused by ammonia and dust, and reduces exposure to APEC. Wet litter is an excellent environment in which *E. coli* can grow. The prevalence and severity of footpad dermatitis at slaughter are good indicators of litter and air quality during the growout period. Vermin infestation can also be a significant source of pathogenic *E. coli*.

In addition to proper environmental and managerial conditions, commercial competitive exclusion

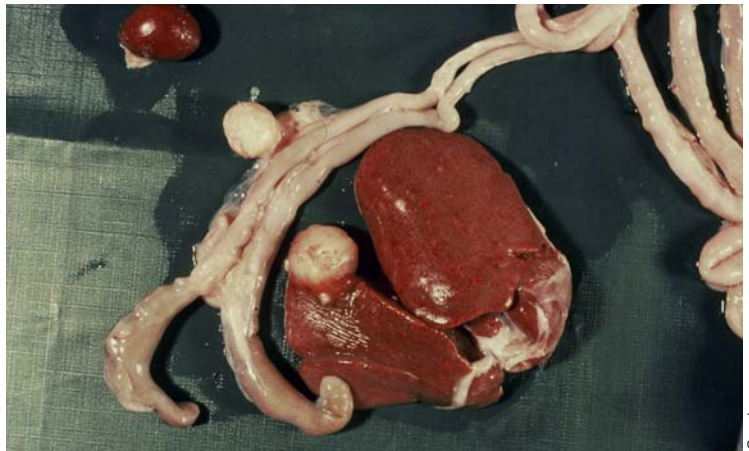

I Dinev - Ceva Santé animale

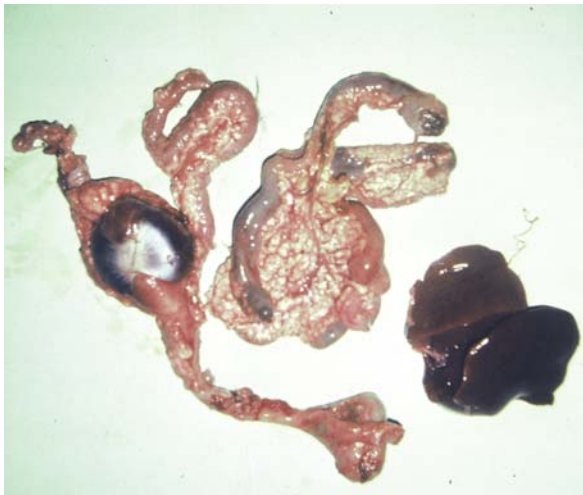Fig.45.73: Panophthalmitis. Infection is normally unilateral. Initially hyperemic, the eye is swollen and appears cloudy to opaque. Eventually, the eye becomes atrophic.



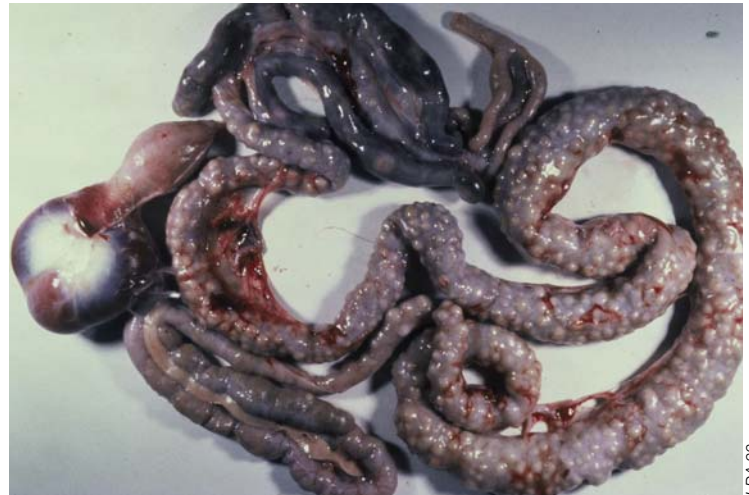Sanders



Sanders



J Brugère-Picoux



LDA 22

Fig.45.74, 45.75, 45.76 & 45.77: Coligranuloma (Hjarre's disease). Serosal lesions resemble leukosis tumors or tuberculous nodules. Multiple granulomas are seen in the liver, ceca, duodenum, and mesentery. The spleen is not affected.

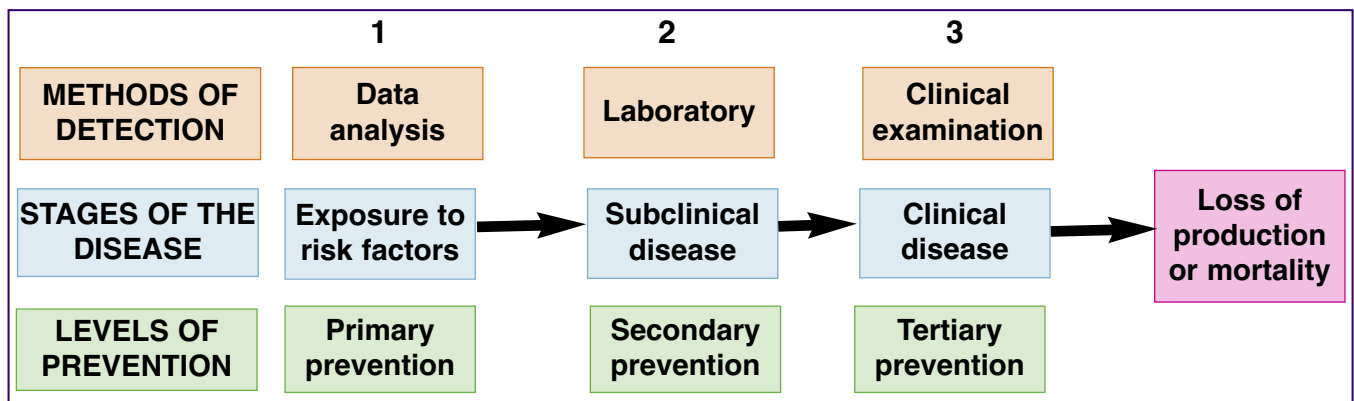


Fig.45.78: Levels of prevention of avian colibacillosis. The best way to control colibacillosis is by observing high biosecurity and flock management standards.

products may be used to exclude APEC from the intestine of young poultry. Inoculation of *Lactobacillus reuteri in ovo* has been successful in preventing APEC by seeding the gut of newly hatched birds. Strict biosecurity measures are also critical to prevent exposure to primary agents. Effective vaccination against some of these agents may be essential depending on the region where the flock is raised.

Vaccination

Different vaccines are available commercially, but few have proven very efficacious in the field. Inactivated vaccines specific to some serogroups, such as O2:K1 and O78:K80, are effective and their use in breeders has provided progeny with passive protection against homologous strains. Live or recombinant vaccines are also effective against specific strains. In Europe, maternal immunity may be achieved by vaccinating broiler breeders with a commercial vaccine containing F11 (*PapA*) fimbrial antigen and flagellar antigen (*FT*)

molecular vaccines, e.g., immunizing chickens with *Iss* (a surface protein common to APEC), could provide cross-protection among different serogroups.

REFERENCES

- Barnes HJ & Lozano F. Colibacillosis in Poultry. *Pfizer Veterinary Practicum*, Pfizer Animal Health, Lee's Summit, 1994.MO, 45.
- Gross WB. Diseases due to *Escherichia coli* in poultry. In Gyles CL ed.. *Escherichia coli in Domestic Animals and Humans*. CABI, Wallingford, 1994, pp 237–260.
- Harry, EG & Hemsley LA. The association between the presence of septicaemia strains of *Escherichia coli* in the respiratory and intestinal tracts of chickens and the occurrence of coli septicaemia. *Vet Rec*, 1965,77:35-40.
- Nolan LK et al. Colibacillosis. In “*Diseases of Poultry*”, Swayne D. ed., Wiley-Blackwell 13th ed, 2013, pp 751-805.

	<i>P. multocida</i>	<i>Av. gallinarum</i>	<i>Av. avium</i>	<i>Av. volantium</i>	<i>Av. paragallinarum</i>	[<i>P.</i>] <i>langaa</i>	ORT	<i>R. anatipestifer</i>
Nitrate, red	+	+	+	+	+	+	-	-
Urease	-	-	-	-	-	-	+	d
Arginine dihydr.	-	-	-	-	-	-	+	(+)
Ornithine decar.	+	-	-	d	-	-	-	-
Indole	+	-	-	-	-	-	-	-
D(+)xylose	+	d	d	d	d	-	-	-
D(-)mannitol	+	-	-	+	+	+	-	-
D(-)sorbitol	d*	-	-	d	+	-	-	-
D(+)galactose	+	+	+	+	-	+	(+)	-
Maltose	-	+	-	+	d	-	(+)	-
Trehalose	d*	+	+	+	-	-	-	-
Dextrin	-	+	-	+	-	-	(+)	-
α-galactosidase	-	-	-	-	-	-	+	+
α-glucosidase (PNPG)	d*	+	+	+	d	-	+	+

Tabl.46.1: Important characters used to separate *Pasteurella multocida* from other relevant taxa (*Avibacterium*, *Omithobacterium rhi-notracheale*, *Riemerella*)

+ : 90% or more of the strains positive within 1-2 days

(+) : 90% or more of the strains positive within 3-14 days

* : character used for separation of subspecies of *P. multocida*

- : 90% or more of the strains negative

d : different



Fig.46.1: Gram-negative rods of *P. multocida*.

AAAP (courtesy Dr. R. B. Rimler, NADC)

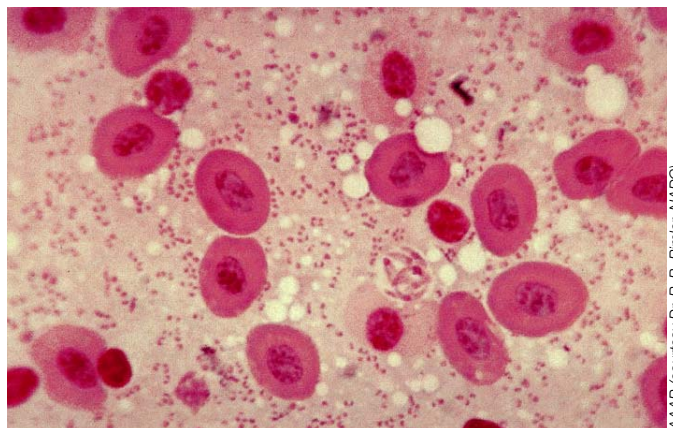


Fig.46.2: Bipolar morphology of *P. multocida*, liver impression, Wright's stain.

AAAP (courtesy Dr. R. B. Rimler, NADC)




Fig.46.3: Typical colonies of *P. multocida* on a blood agar plate.

AAAP

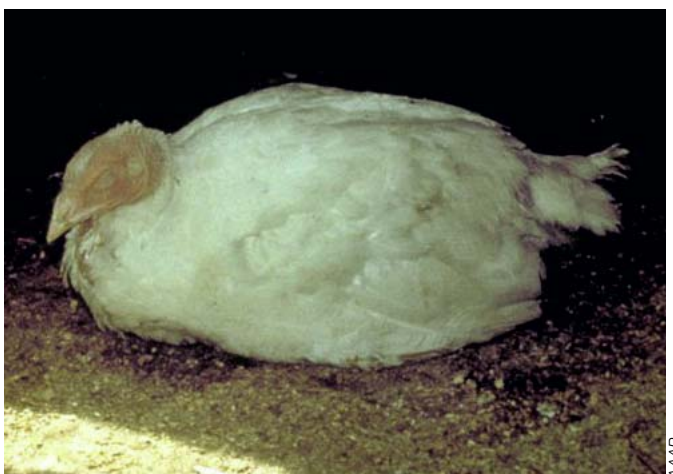

Fig.46.4: Turkey with clinical signs of acute fowl cholera showing severe depression.

AAAP

Bacterial diseases

46. FOWL CHOLERA

INTRODUCTION

The family *Pasteurellaceae* was conceived to accommodate a large group of Gram-negative chemo-organotrophic, facultatively anaerobic, and fermentative bacteria including the genera *Pasteurella*, *Actinobacillus*, *Haemophilus*, and many other groups of organisms that exhibited phenotypic and genotypic relationships with these genera. Several new genera and species have been reported since the taxonomy of the family was defined. Presently, the family includes 10 genera, 60 named species in addition to numerous, not yet named taxa. In addition, the number of genomospecies representing genotypical distinct species without sufficient phenotypic diversity to allow separation and naming, has increased.

By tradition the composite term “avian pasteurellosis” has been used to cover a variety of infectious diseases caused by certain *Pasteurellaceae* and organisms like *Yersinia pseudotuberculosis*, *Riemerella anatipestifer* and *Ornithobacterium rhinotracheale* showing neither phenotypic nor genotypic relationships. Since these organisms only share difficulties as to isolation and characterization the term pasteurellosis should not be used.

The genus *Pasteurella* previously included nine named species and two unnamed. Reclassification of the avian cluster 18 as *Gallibacterium*, *Volucribacter* and *Avibacterium*, however, limited the genus to include *P. multocida*, *P. canis*, *P. stomatis*, *P. dagmatis* and the unnamed species B. Based upon genotypic similarity *P. multocida* was recently reclassified to include biovar 2 variants of *Av. avium* and *P. canis*. Recent studies also documented the existence of two new species-like taxa of *Pasteurella* related to *P. multocida*, and special care should be taken in the identification of *Pasteurella*-like organisms. Only *P. multocida* is regarded as a major pathogen for birds.

With the exception of *Avibacterium gallinarum* which might result in infections similar to *P. multocida* only fowl cholera will be dealt with in this chapter for the above mentioned reasons.

ETIOLOGY

P. multocida is the causative agent of fowl cholera. A single species status for *P. multocida* has been maintained although extended to include the subspecies *multocida*, *septica* and *gallicida*. Recent genetic investigations have clearly indicated the existence of two distinct phylogenetic lineages of which one included the type strains of subspecies *multocida* and *gallicida* while the other included the type strain of *P. multocida* ssp. *septica*. Phenotypic criteria for separation of these two lineages, however, remain to be identified.

Pasteurella multocida subspecies *multocida* is the most common cause of disease, but subspecies *septica* and *gallicida* may also cause fowl cholera-like disease. *Pasteurella multocida* subspecies *gallicida* is mainly associated with web-footed birds and chickens, but has also been reported in pigs. The relationship between subspecies and serovars of *P. multocida* obtained by published serotyping systems has not been elucidated.

For many years a passive hemagglutination test was used for detection of capsule antigens, whereas tube agglutination and gel diffusion precipitin tests have been used to detect somatic antigens. A highly specific multiplex capsular PCR assay has subsequently been developed and five capsular (A, B, D, E and F) and sixteen somatic (1-16) serovars of *P. multocida* are currently recognized. All but serotypes 8 and 13 have been isolated from avian hosts as have capsular types A, B, D and F. However, subspecies *multocida* and serovar A appear to be the most frequently isolated subspecies and serogroup from cases of the most severe form of fowl cholera. Several of the sixteen somatic serovars have been demonstrated among serovar A isolates, just as somatic serotype variation has been shown to occur within serovars B, D and F. Isolates that have multiple somatic antigens are often encountered and are considered distinct serotypes. Although the somatic serovars 1,3 and 3,4 within serovar A apparently dominate among strains isolated from fowl cholera in England and the United States of America, no particular serovar

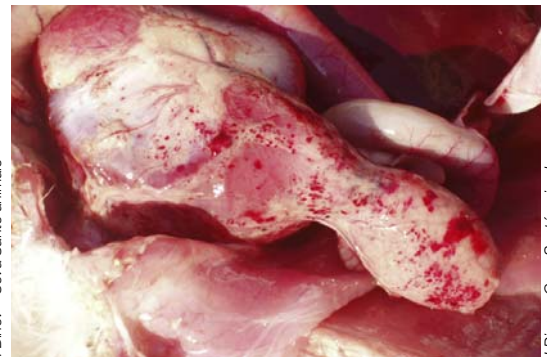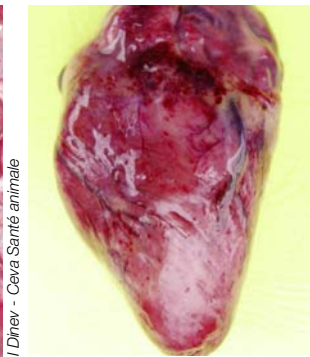
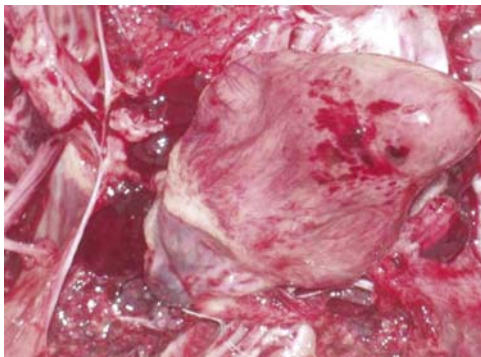


Fig.46.5 & 46.6: Acute fowl cholera. Multiple subepicardial petechial hemorrhages affecting are a characteristic finding.

Fig.46.7: Acute fowl cholera. Subserous petechial or ecchymosed hemorrhages in the anterior part of the digestive tract.

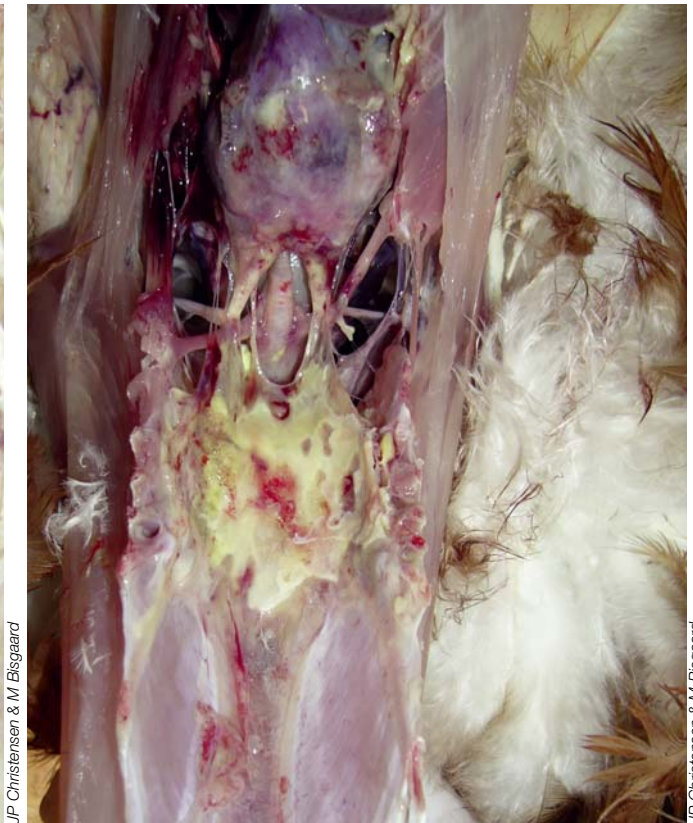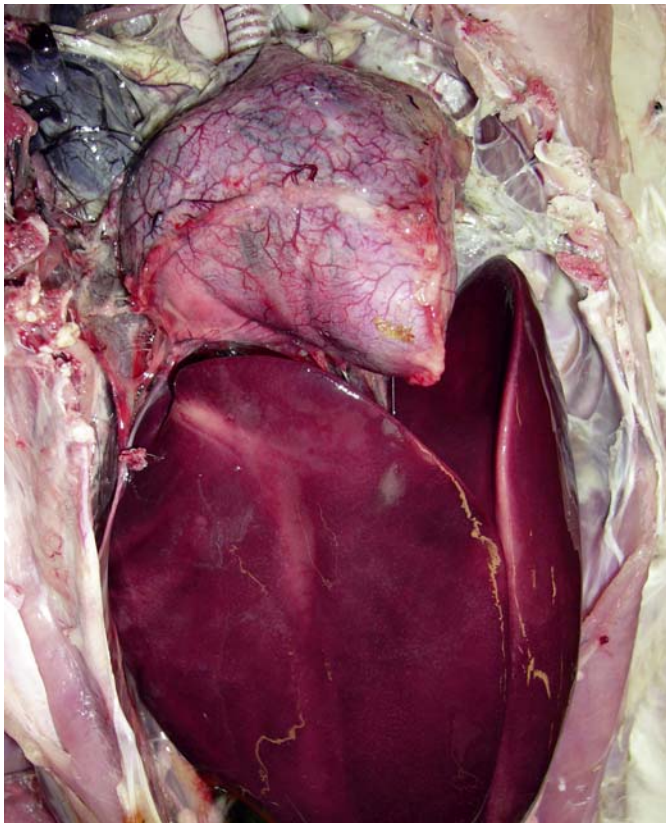


Fig.46.8: Fowl cholera (Turkey). Acute sepsis with vascular disturbances of the pericardium.

Fig.46.9: Fowl cholera (Turkey). Fibrinous pericarditis.

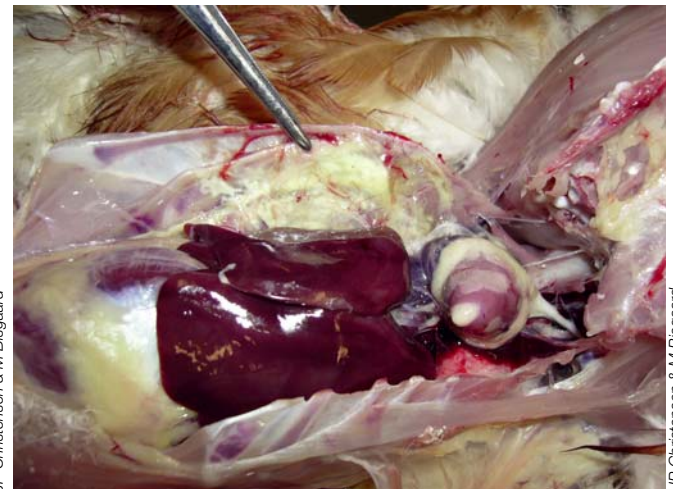
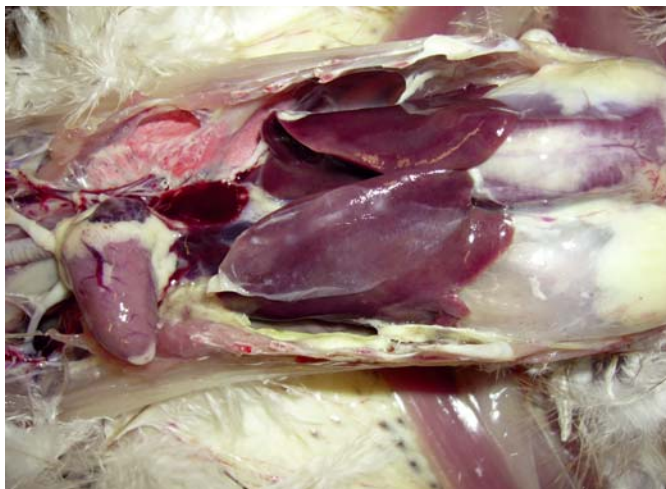

Fig.46.10: Fowl cholera (Turkey). Subacute infection with perihepatitis.

Fig.46.11: Fowl cholera (Turkey). Purulent airsacculitis.

appears to be more or less virulent than others. It has been demonstrated that different isolates of the common serovar A:3,4 vary greatly in virulence. Virulence properties of the different subspecies for different avian hosts are also unclear.

P. multocida, like other *Pasteurellaceae*, does not survive for long outside colonized animals under normal conditions. In addition, *P. multocida* is destroyed easily by ordinary disinfectants.

Within the order *Galliformes*, *Av. gallinarum* formerly designated [*P.*] *gallinarum*, has been reported associated with fowl cholera-like lesions in *Gallus domesticus*, *Meleagris gallopavo* and *Numida meleagris*. However, only isolates from chickens in addition to a single turkey isolate have been confirmed by genetic analysis such as ribotyping and/or 16S rRNA gene sequence comparison. Identification of the same clone of *Av. gallinarum* from 14 outbreaks of acute respiratory disease in turkeys within a time period of two months suggests a common source of infection and a primary rather than secondary role of *Av. gallinarum* in the outbreaks. Isolates from rats identified as *Av. gallinarum* by conventional phenotypic tests belonged to a different ribotype cluster and showed only 93% 16S rRNA similarity with *Av. gallinarum* and belong to a new genomospecies tentatively designated taxon 47.

EPIDEMIOLOGY

Probably all types of poultry are susceptible to infection with *P. multocida*. However, major differences in susceptibility to the infection have been documented. Among domestic fowl, turkeys are one of the most susceptible species in addition to waterfowl. Chickens are considered relatively resistant to infection although mortality may be high during outbreaks caused by some isolates under certain exaggerated conditions (accumulated mortalities up to 60% in organic layers have been observed in Denmark). Partridges and pheasants are also highly susceptible.

Age markedly influences the outcome of the infection in chickens in particular birds less than 16 weeks of age appear fairly resistant. In turkeys this effect is not as pronounced since 100% mortality may be observed following experimental infection of three week-old poults.

Several other factors have been reported to influence the severity and incidence of the disease including environmental factors such as crowding and climate in addition to concurrent infections and general stress.

Molecular typing methods have enabled a better understanding of the often complex epidemiology of fowl cholera. Due to genotypic variation within serotypes of *P. multocida*, serotyping in many cases does not provide sufficiently detailed information to determine the epidemiology of infections. Within the last 15 years, DNA fingerprinting in the form of restriction endonuclease analysis (REA), in particular, but ribotyping and Pulsed Field Gel Electrophoresis (PFGE) have also been used to characterise avian isolates of *P. multocida* from different sources. More recently, PCR typing (AP, REP & ERIC) and Amplified Fragment Length Polymorphism (AFLP) analysis have been applied successfully as tools for typing avian isolates of *P. multocida*.

The results obtained by the use of such methods have significantly added to our understanding of the epidemiology of fowl cholera. However, obtaining basic information concerning, for example, the introduction of *P. multocida* to a flock or farm still represents a problem. It has been documented that wild birds carrying isolates of *P. multocida* which are virulent for different species of domestic poultry may represent a source of infection for domestic poultry. In addition, it is the current opinion that carriers occur in flocks of domestic poultry previously affected by fowl cholera.

Recently, data have been generated that indicate that cloacal carriers also may be present in flocks of chickens and ducks with no previous recognised problems with *P. multocida* infection. The epidemiological significance of this finding is unclear, as excretions from the mouth, nose and conjunctiva of diseased birds are generally believed to be the primary source of contamination of the environment.

Different mammals (including rodents) may also carry *P. multocida* but their role as a reservoir has not been thoroughly investigated by molecular methods and challenge studies. However, it has been shown that dogs, cats and pigs may act as reservoirs for strains of *P. multocida* which are virulent for poultry. Recent investigations seem to indicate that respiratory tract infections in different animal species are caused by different clonal lineages of *P. multocida*. Other potential sources of infection include cannibalism of sick or dead birds and *P. multocida* is resistant enough to be readily spread by contaminated crates, feed bags, shoes, equipment and mechanically by insects. The infection does not seem to be egg-transmitted.

Although the reservoir of *P. multocida* appears complex and several sources theoretically may be

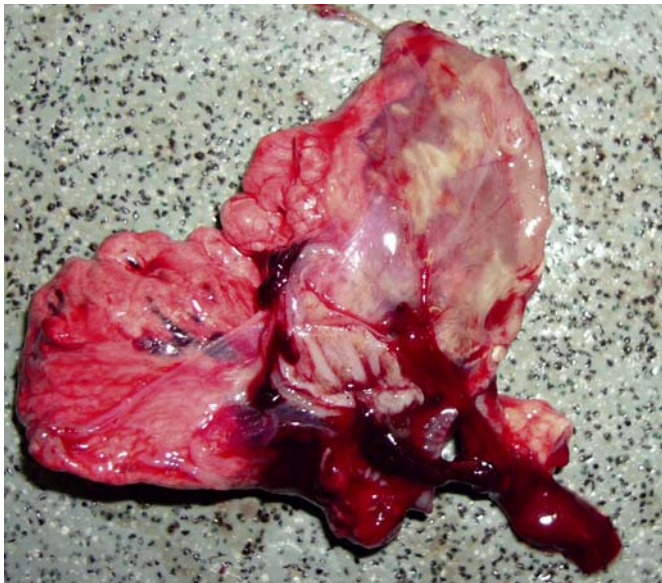


Fig.46.12: Fowl cholera (Turkey). Typical lung lesions caused by *P. multocida*.

JP Christensen & M Bisgaard

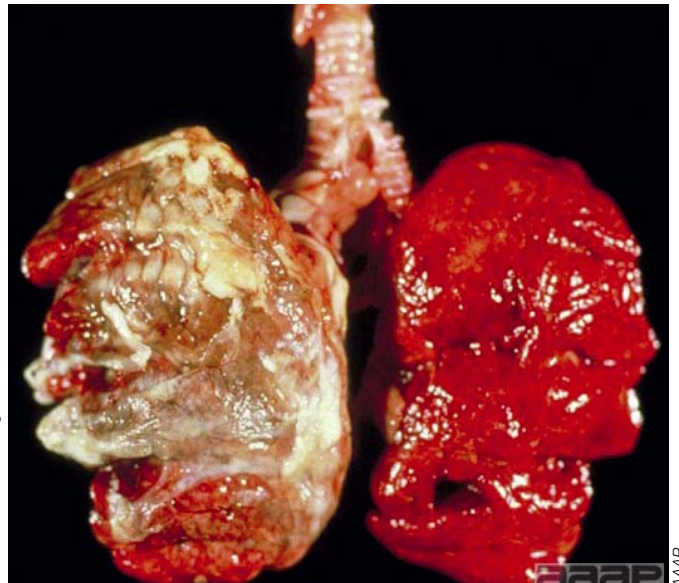


Fig.46.13: Fowl cholera (Turkey). Acute fibrinous pleuritis and pneumonia. Notice the unilateral involvement of the lung.

AAAP

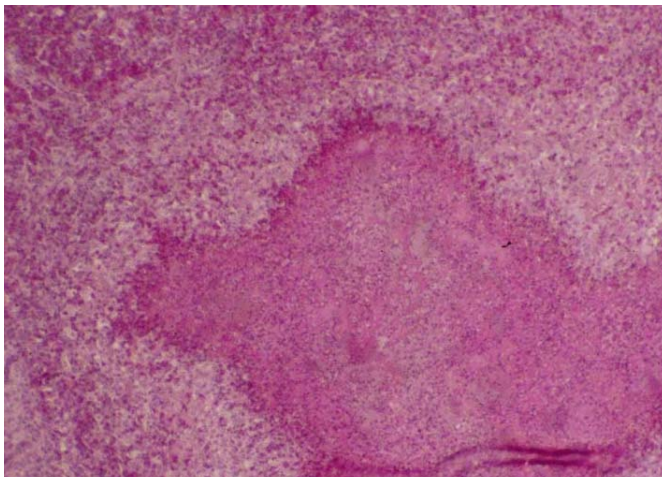


Fig.46.14: Fowl cholera. Lung (histology) with numerous abscesses (hematoxylin, eosin & safran).

LDA 22



Fig.46.15: Fowl cholera. Multiple miliary or submiliary foci of necrosis in the liver.

I Dinev - Ceva Santé animale

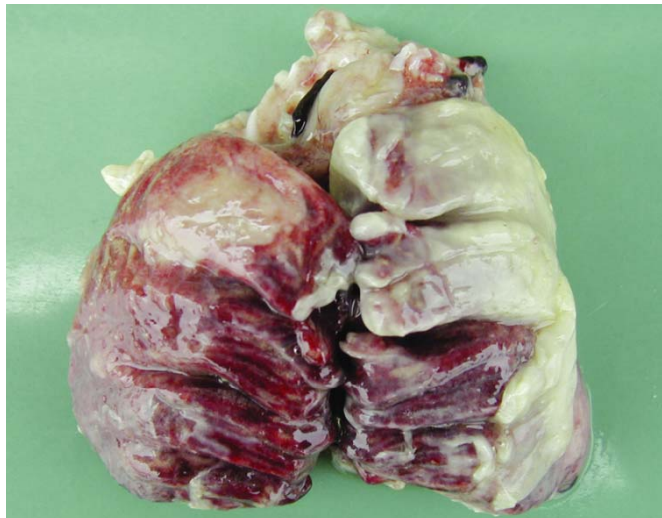

Fig.46.16: Fowl cholera (Turkey). Bilateral croupous pleuropneumonia.

I Dinev - Ceva Santé animale



Fig.46.17: Fowl cholera. The inflammation could possibly be spread from sinus to adjacent air-filled skull bones with subsequent necrosis and onset of neurological signs (opisthotonos and torticollis).

I Dinev - Ceva Santé animale

responsible for introducing the infection to a flock of poultry, the most recent studies indicate that in layer chickens, at least, most fowl cholera outbreaks are clonal. This suggests that only few introductions actually take place during the production period or that once a certain clone has colonised the flock it is difficult for other clones to manifest themselves in the same flock. However, earlier investigations concerning turkeys have shown that multi-clonal outbreaks can occur. This could perhaps be explained by the differences in the production system. Outbreaks of *P. multocida* infections associated with a single clone have also been reported in wild birds involving different geographical regions.

CLINICAL SIGNS & LESIONS

It is generally accepted that the main site of infection for *P. multocida* is the respiratory tract. But inoculation through oculo-nasal-oral routes also may result in typical lung lesions and a progressive bacteremia, indicating that other mucosal membranes may serve as ports of entry. Furthermore, cutaneous wounds may serve as port of entry. The ability of *P. multocida* to survive passage of the gastro-intestinal tract remains to be investigated in more detail, but as *P. multocida* has been isolated from the cloaca of carrier birds it shows that some strains may survive passage.

In addition, the observation that some strains of *P. multocida* can be virulent and immunogenic following oral administration suggests that intestinal invasion or some sort of interaction with the intestinal mucosa may occur.

Following colonisation of the upper respiratory tract by pathogenic *P. multocida* strains, subsequent spread to the lungs followed by invasion, bacteremia and septicemia usually can be observed. It has been suggested that some of the differences in host susceptibility to *P. multocida* infection may be due to differences in the host response expressed in the lung during the early phase of infection. In chickens, heterophil influx and activation probably play a dual role in the outcome of an infection; where it initially seems to promote invasion and systemic spread, later it limits the infection by giant cell formation and bacterial clearance resulting in localised pneumonic lesions. In turkeys a more severe fibrino-necrotizing hemorrhagic pneumonia can be observed following intra-tracheal inoculation with *P. multocida* which could be speculated to be due to a different innate immune response where the role of the heterophils differs from that of the chickens.

With acute fowl cholera sudden, unexpected deaths of a large number of birds in a flock are observed without any signs. Mortality often increases rapidly. In more protracted cases anorexia, ruffled feathers, mucous discharge from the mouth and nose, diarrhea, cyanosis and general depression may be observed.

In chronic infections, signs are mainly due to localised infections of joints, abscesses of the head (cranial bones, infraorbital sinuses, subcutaneous tissue, comb and wattles), oviduct and the respiratory tract (dyspnea and rales). Torticollis might be associated with infections of the cranial bones, middle ear, and meninges. Dermal necrosis in turkeys may also be observed. A chronic infection may follow an acute infection or be due to infections with organisms of low virulence.

Lesions observed in peracute and acute forms of the disease are dominated by general septicemic lesions including vascular disturbances in the form of general passive hyperemia and congestion throughout the carcass accompanied by enlargement of the liver and spleen. Often there are petechial and ecchymotic hemorrhages at sites such as the heart under serous membranes, in mucous membranes, on the gizzard, subepicardially and in abdominal fat. In addition, acute oophoritis with hyperemic follicles may be seen. Acute lesions develop as a result of disseminated intravascular coagulation. In subacute cases, pin-point necrotic areas may be disseminated throughout the liver and spleen.

In chronic forms of fowl cholera suppurative lesions may be widely distributed, often involving the respiratory tract, the conjunctiva and adjacent tissues of the head. Caseous arthritis and productive inflammation of the peritoneal cavity and the oviduct are common in chronic infections. A fibrino-necrotic dermatitis including caudal parts of the dorsum, the abdomen and breast, involving cutis, subcutis and the underlying muscle, has been observed in turkeys and broilers. Sequestered necrotic lung lesions in poultry should always arouse suspicion of cholera.

DIAGNOSIS

Although the history, signs and lesions may be helpful in establishing the diagnosis, *P. multocida* should be isolated, characterized and identified for confirmation. Primary isolation can be accomplished using media such as blood agar, dextrose starch agar or trypticase soy agar. Isolation may be improved by the addition of 5%

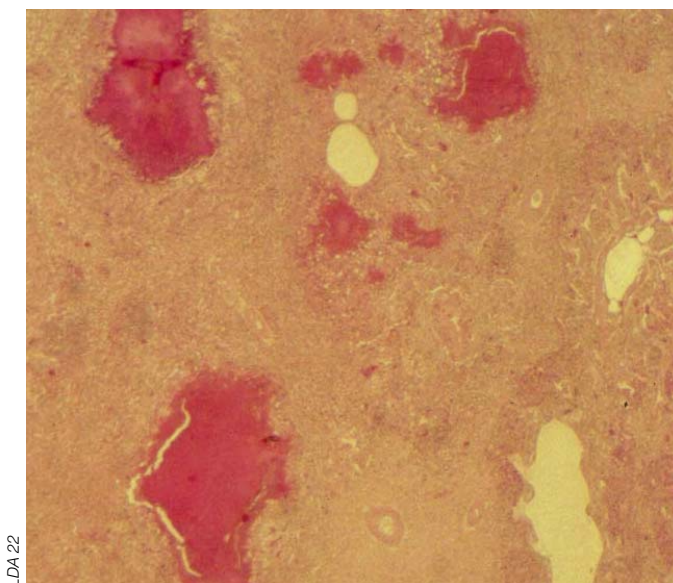


Fig.46.18 & 46.19: Acute fowl cholera (Turkey). Enlarged spleen with foci of necrosis. Histology of granulomas in the spleen.

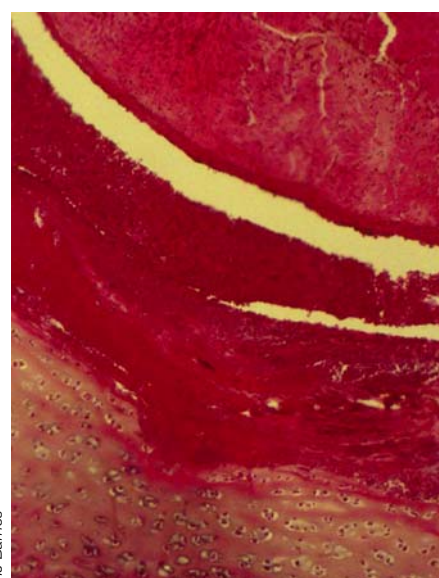
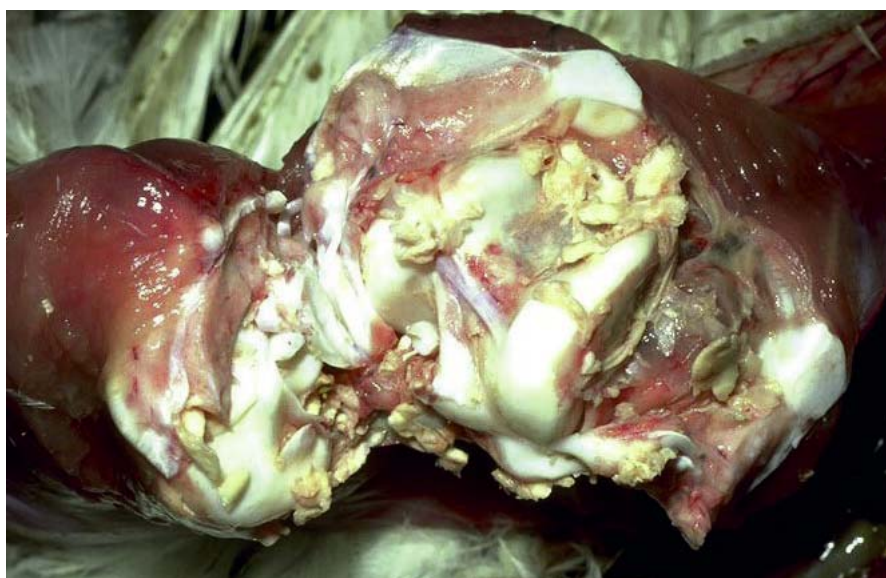

Fig.46.20 & 46.21: Fowl cholera. Purulent arthritis. Lameness may be a clinical sign in some outbreaks. Macroscopic and microscopic aspects.

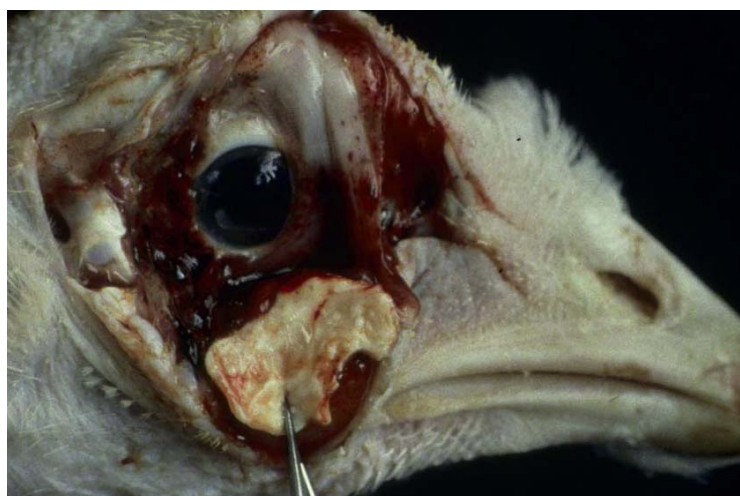

Fig.46.22 & 46.23: Chronic fowl cholera is characterized by local inflammations. Serofibrinous inflammation of periorbital sinuses in a fowl on the left and in a turkey on the right.

heat inactivated serum. *P. multocida* can be readily isolated from viscera of birds dying from peracute/acute fowl cholera whereas isolation from suppurative lesions of chronic cholera may be more difficult. At necropsy, bipolar microorganisms may be demonstrated by the use of Wright's or Giemsa staining of impression smears obtained from the liver in the case of acute cholera. In addition, immunofluorescent microscopy and *in situ* hybridization have been used to identify *P. multocida* in infected tissues and exudates.

Recently a polymerase chain reaction (PCR) has been developed and used for the detection of *P. multocida* in pure and mixed cultures and clinical samples. Such methods may be helpful for establishing knowledge concerning carrier animals within flocks just as the complexities associated with the diagnosis of fowl cholera by conventional methods of isolations, identification, capsular serotyping may be overcome. However, the specificity and sensitivity of these tests are not yet satisfying for several reasons.

Carrier status of a population of animals may also be investigated by the use of mouse inoculations. Swabs should be taken from the cloaca and pharynx. Following suspension of the swabs in broth medium and thorough shaking, 0.2 - 0.5 ml of the contents is injected into mice by the intraperitoneal route. If the samples are *P. multocida* positive, the mice will usually die within 24 to 48 hours and *P. multocida* can be isolated in pure culture from heart, blood, liver and spleen. Selective media (including an enrichment step) have also been used as an alternative for mouse inoculations but the method appears less sensitive than mouse inoculations.

Following isolation, classical identification is based on the results of biochemical tests. The most important characteristics for the differentiation of *P. multocida* from other related organisms are shown in Tabl.46.1. However, simple diagnostic keys do not allow a firm diagnosis within the family *Pasteurellaceae*. For this reason, extended characterisation, including the use of reference strains, is recommended. Further delineation of *P. multocida* into subspecies presently seems uncertain. Serotyping may also be included for characterisation and be of some use epidemiologically or in order to evaluate the relevance of the vaccine strains used in a certain area, but serotyping is mainly reserved to specialized laboratories.

Serological testing can be done by rapid whole blood agglutination, serum plate agglutination, agar diffusion tests and ELISA. Serology may be used to evaluate vaccine responses but has very limited value for diagnostic purposes.

It should be emphasized that several bacterial infections may be confused with fowl cholera based solely on the gross lesions. *Escherichia coli*, *Salmonella enterica*, *O. rhinotracheale*, Gram positive cocci and *Erysipelotrix rhusiopathiae* (erysipelas) may all produce lesions indistinguishable from those caused by *P. multocida*.

TREATMENT & CONTROL

A number of drugs will lower the mortality from fowl cholera but mortality may resume when treatment is discontinued showing that treatment will not eliminate *P. multocida* from a flock. The drugs used to control cholera *via* feed or water application include sulfadimethoxine, sulfaquinoxaline, sulfamethazine, trimethoprim/sulfadiazine, semi-synthetic penicillins, tetracyclines and erythromycin. In ducks it has been reported that good results may be obtained by the combined use of streptomycin and dihydrostreptomycin administered as injections. More recently, the fluoroquinolone, norfloxacin, has been shown to be effective against fowl cholera in chickens and turkeys when administered *via* drinking water. It lowered mortality significantly during experimental infections without recognised side effects. However, it is illegal to use fluoroquinolones for treating poultry in many countries. Furthermore, whenever medical treatment is considered, sensitivity testing of the causative agent should be performed and it must be remembered that resistance to treatment may develop and cause serious future problems.

Moving an infected flock to clean premises and/or improving sanitation during an outbreak may slow the course of the outbreak. The use of vaccination during an outbreak may also improve the situation. However, in order to eradicate infection from premises the only rational strategy includes depopulation, cleaning and disinfection of buildings and equipment. Subsequently, the premise should be kept free of poultry for a few weeks.

To avoid infection of a flock, the focus should be on the application of appropriate biosecurity measures. Contact with wild birds, rodents and pet animals should be avoided as they all have been shown to represent a potential risk of introducing

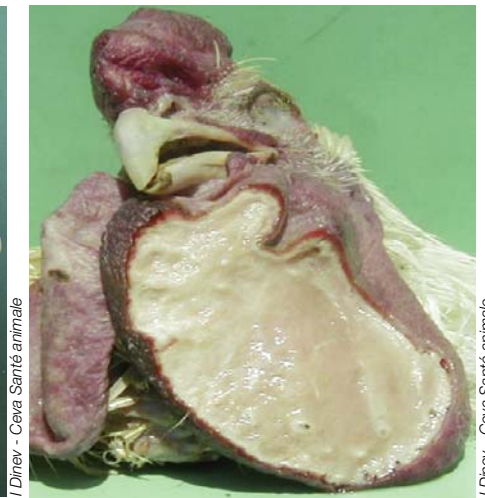
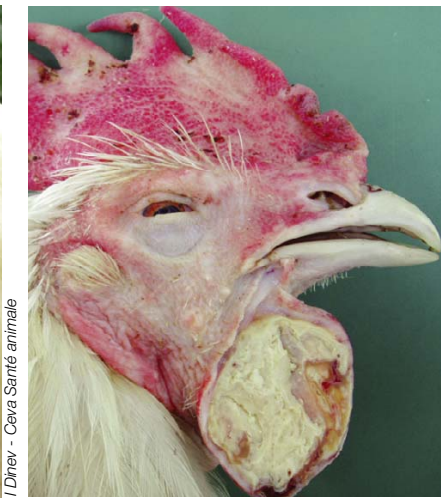
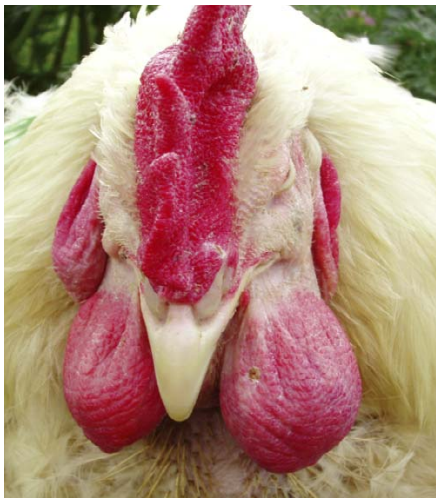Fig.46.24, 46.25 & 46.26: Local form of the disease with lesions to wattles filled with fibrinous caseous material. This may occasionally lead to gangrene of the covering skin.

Section III

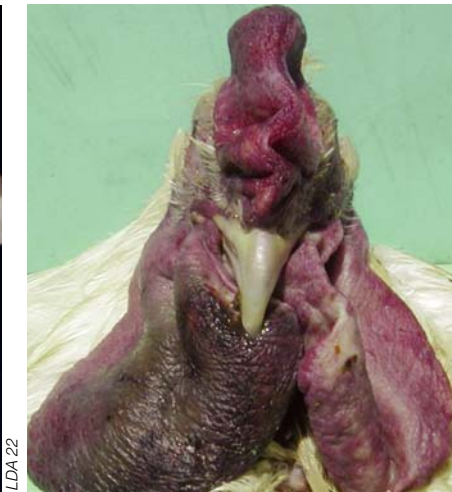
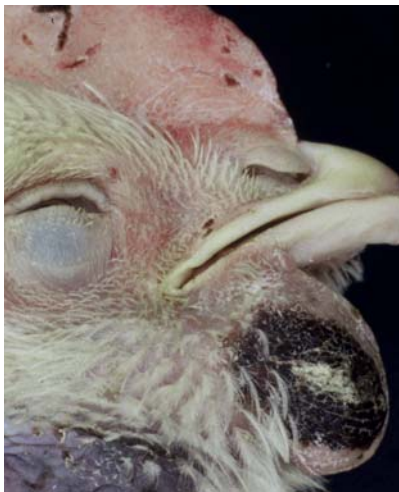
Fig.46.27 & 46.28: Important gangrene of the covering skin of affected wattles.

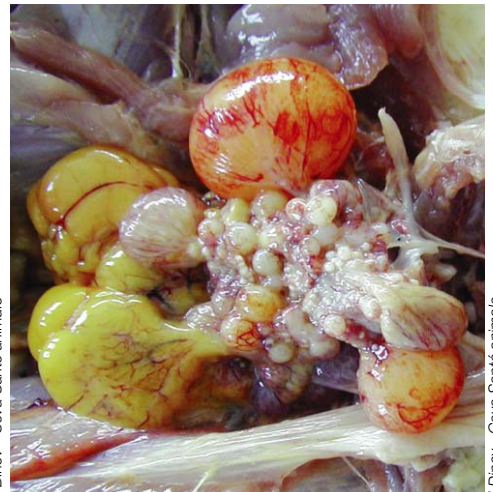

Fig.46.29: In layers, acute oophoritis with regressing follicles and consequently, diffuse peritonitis are commonly observed.

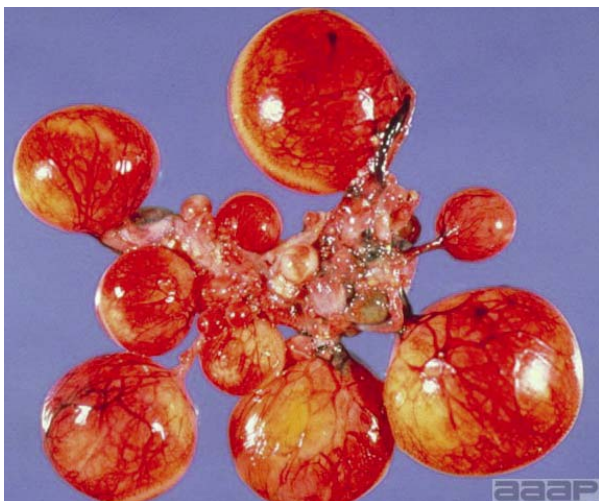

Fig.46.30: Ovary of a hen with acute fowl cholera. Severe congestion of the follicular membranes.

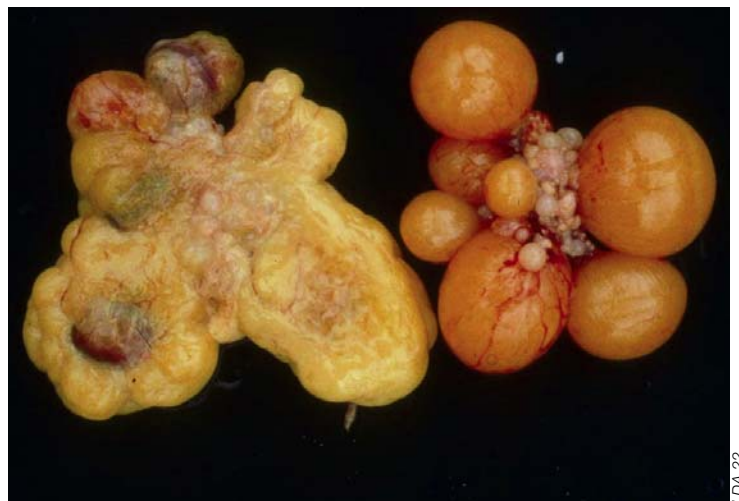


Fig.46.31: Comparison of an affected ovary in chronic fowl cholera (note the cooked appearance of the follicles) on the left with a normal ovary on the right.

P. multocida to the flock. In addition, proper handling of carcasses should be performed as asymptomatic carriers may be present in flocks. Only young birds should be introduced as new stock and the birds should originate from farms with a high level of biosecurity and which preferably follow all in/all out principles in a confined environment.

Extensive production systems in many parts of the world may have problems in achieving an appropriate level of hygiene and biosecurity in which case vaccination against fowl cholera should be employed. This includes non-confined poultry production in the industrialized world which has become increasingly popular due to animal welfare concerns.

Vaccines used against fowl cholera include inactivated bacterins and live attenuated vaccines. Bacterins are widely used, but must be injected and only induce immunity to homologous serotypes. Autogenous vaccines of inactivated organisms may be helpful under certain circumstances. In contrast, live vaccines have been reported to confer immunity against heterologous serotypes but may revert to its virulent form as the live vaccines currently in use all are undefined attenuated strains. The principal live strains currently used, primarily in North America, are the Clemson University strain, which is a naturally occurring low-virulent organism, and its derivative the M-9 strain, both of which are of serotype A: 3, 4. Both strains have been implicated in outbreaks of fowl cholera and as a consequence, attempts have been made to further modify these strains. Temperature sensitive mutants of both strains have been constructed.

Other attempts to modify *P. multocida* strains for vaccination purposes include the creation of auxotrophic mutants and the selection of clones with a reduced growth rate. Recently, promising results have been obtained with an acapsular *P. multocida* A: 1 mutant strain suggesting it could be a potential

vaccine candidate. Live vaccines are normally given as wing web inoculations to chickens and *via* drinking water to turkeys.

REFERENCES

- Bisgaard M et al. Investigations on the clonality of strains of *Pasteurella gallinarum* isolated from turkeys in Germany. *Avian Pathol*, 2005, 34: 106-110.
- Bisgaard M et al. Avian infections caused by species of Pasteurellaceae. An update. In: *Proceedings of the 14th World Veterinary Poultry Congress*, Istanbul 22-26 August 2005.
- Blackall PJ & Mifflin JK. Identification and typing of *Pasteurella multocida*: a review. *Avian Pathol.*, 2000, 29: 271-287.
- Bojesen AM et al. *Pasteurella multocida* infection in heterophil-depleted chickens. *Avian Dis*, 2004, 48: 463-470.
- Christensen H et al. Revised description and classification of atypical isolates of *Pasteurella multocida* from bovine lungs based on genotypic characterization to include variants previously classified as biovar 2 of *Pasteurella canis* and *Pasteurella avium*. *Microbiology* 2004, 150, 1757-1767.
- Christensen H & Bisgaard M. The genus *Pasteurella* in: Dworkin, M. & C. Lyons (Eds.), *The Prokaryotes: an evolving electronic resource for the microbiological community*, Springer-Verlag, New York, 2003.
(<http://www.springer-ny.com> ; <http://141.150.157.117:8080/prokWIP/chaphtm/455> (complete.htm).
- Davies RL et al. Characterization of bovine strains of *Pasteurella multocida* and comparison with isolates of avian, ovine and porcine origin. *Vet Microbiol*, 2004, 99: 145-158.
- Glisson JR et al. Fowl Cholera. In “*Diseases of Poultry*”, Iowa State Press, Ames 2003, 658-676.
- Hunt ML et al. The Molecular biology of *Pasteurella multocida*. *Vet Microbiol*, 2000,72:3-25.


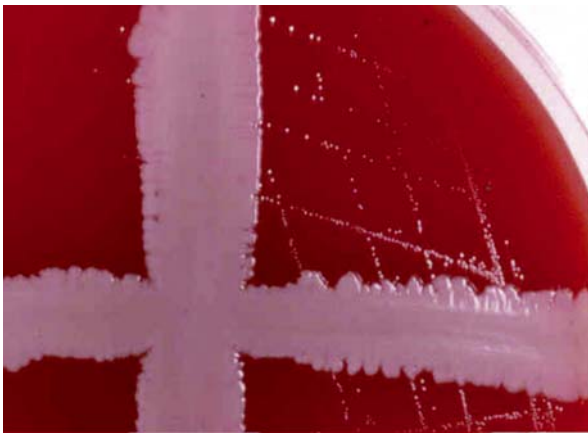


Fig.47.1: Typical satellitic growth of *Avibacterium paragallinarum* around a nurse colony of *Staphylococcus hyicus* or *Staphylococcus epidermidis*.

Fig.47.2: Typical vigorous growth of V-factor independent *Av. paragallinarum*.



Fig.47.3: The lower chicken shows the typical signs of mild infectious coryza – swelling of the infra-orbital sinus and slight nasal discharge.

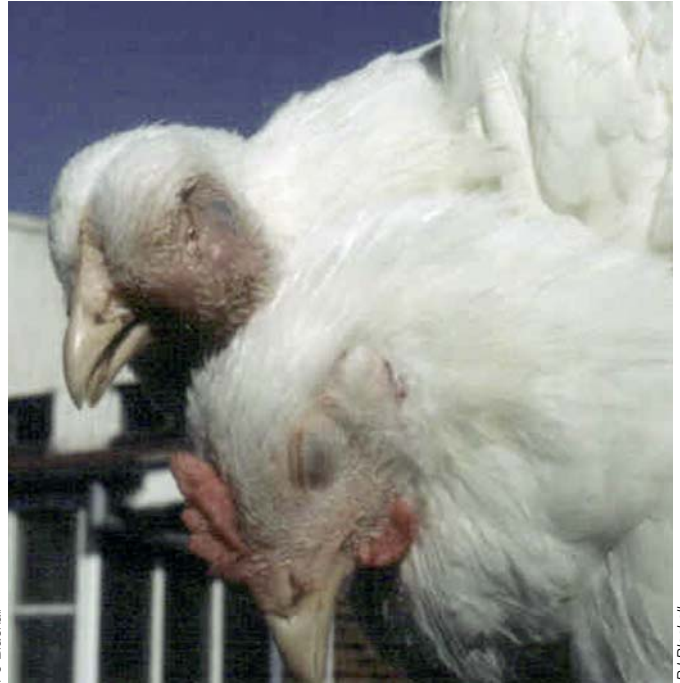

Fig.47.4: The upper chicken shows the typical signs of advanced infectious coryza – severe swelling of the infra-orbital sinus and closure of the affected eye.



Fig.47.5: Female broiler-type chicken showing mouth breathing.



Fig.47.6: Typical signs of infectious coryza with depression, facial edema (severe swelling of the infra-orbital sinus) and closure of the affected eye.

Bacterial diseases

47. INFECTIOUS CORYZA & RELATED DISEASES

INTRODUCTION

Infectious coryza is an acute respiratory disease of chickens caused by the bacterium *Avibacterium paragallinarum* (once known as *Haemophilus paragallinarum*). The genus *Avibacterium* also contains a number of other species: *Av. avium* (once known as *Pasteurella avium*), *Av. endocarditidis*, *Av. gallinarum* (once known as *P. gallinarum*) and *Av. volantium* (once known as *P. volantium*). Of these additional members of the genus, there are reports of both acute and chronic disease conditions (fowl cholera-like in nature) in chickens and turkeys that have been associated with *Av. gallinarum* while *Av. endocarditidis* has been isolated from valvular endocarditis conditions in adult broiler parents. Little is known about *Av. Endocarditidis* as there has been only one publication to date, and the organism will not be discussed any further.

The rest of this text will provide information on *Av. paragallinarum* and, where available, *Av. gallinarum*.

ETIOLOGY & EPIDEMIOLOGY

The causative bacterium of infectious coryza, *Avibacterium paragallinarum* (once known as *Haemophilus paragallinarum*) is a Gram-negative, pleomorphic, nonmotile, catalase-negative, microaerophilic rod that requires nicotinamide adenine dinucleotide (V-factor) for *in vitro* growth. When grown on blood agar with a staphylococcal nurse colony that excretes the V-factor, the satellite colonies appear as dewdrops, growing adjacent to the nurse colony. Recently, V-factor-independent *Av. paragallinarum* has been recovered in Mexico and South Africa. These V-factor-independent *Av. paragallinarum* are grown like *Pasteurella* spp. on blood agar – with no need for a nurse colony.

The most commonly used serotyping scheme is the Page scheme which groups *Av. paragallinarum* isolates into three serovars (A, B and C) that are correlated with immunotype specificity, i.e., a killed vaccine containing serovar A protects against serovar A and not serovars B or C.

Chronically ill or healthy carrier birds are the reservoir of infection. While chickens of all ages are susceptible, the susceptibility increases with

age. Typically, the incubation period is one to three days and the duration of the disease is usually two to three weeks for a simple infection. The disease may run up for longer periods in the presence of other diseases such as mycoplasmosis.

Once a flock has been infected, it is a constant threat to any nearby uninfected flocks. Transmission is typically by direct contact, airborne droplets and contamination of drinking water. “All-in/all-out” production can be a very effective management tool. Commercial farms that have multiple-age flocks tend to perpetuate the disease. Egg transmission does not occur.

Molecular techniques such as restriction endonuclease analysis and ribotyping have been used to trace outbreaks of infectious coryza. These molecular methods have provided the confirmatory evidence that the main means of entry of coryza to a property is replacement stock. At the same time, these molecular methods have shown that some farms can be chronically infected – the disease may seem to disappear for a flock or two but will reappear in subsequent flocks.

Traditionally, *Av. gallinarum* (once known as *Pasteurella gallinarum*) was regarded as an opportunistic pathogen of chickens. The organism is widely regarded as one that is a secondary agent that is associated with other primary pathogens such as viruses or mycoplasmas. A critical reading of the literature does suggest that the bacterium can play a significant role in infection. While there are reports of infections in chickens, turkeys and guinea fowl, only the chicken and turkey isolates have been definitely identified by both phenotypic and genotypic methods. There are no accepted serotyping schemes, although genotyping methods such as restriction endonuclease analysis and ribotyping have proven useful in a study of respiratory disease in turkeys.

CLINICAL SIGNS & LESIONS

Infectious coryza is characterized by nasal discharge, sneezing, and swelling of the face under the eyes. The disease occurs wherever chickens are raised. The disease occurs only in chickens. Early reports of the disease in quail and pheasants most probably describe a similar disease that is caused by a different etiological agent.

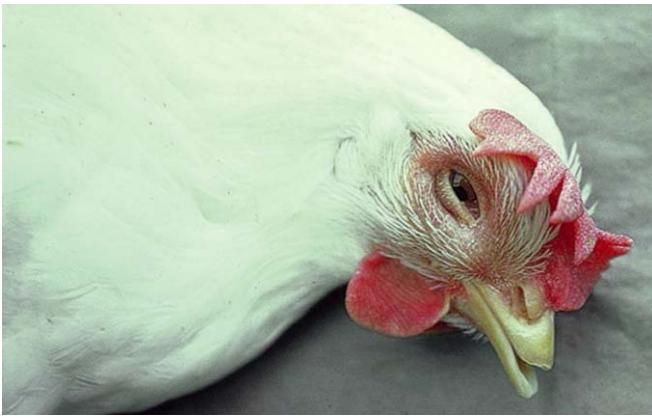

Fig.47.7: Sixteen-week-old White Leghorn pullet with facial edema.



Fig.47.8: White Leghorn rooster showing depression caused by *Av. paragallinarum*.

Section III

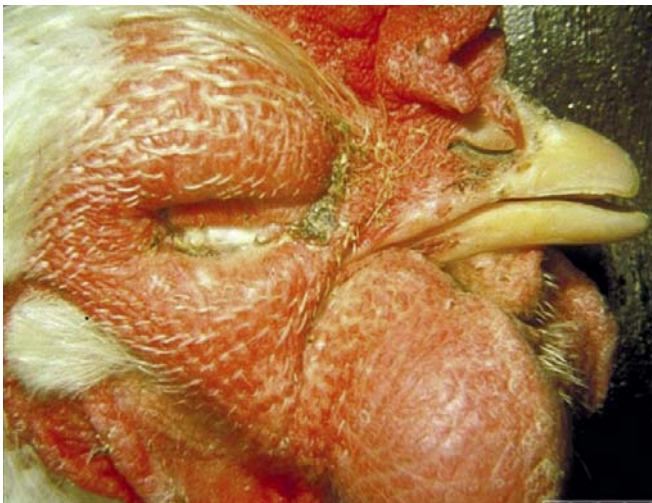

LDA 22



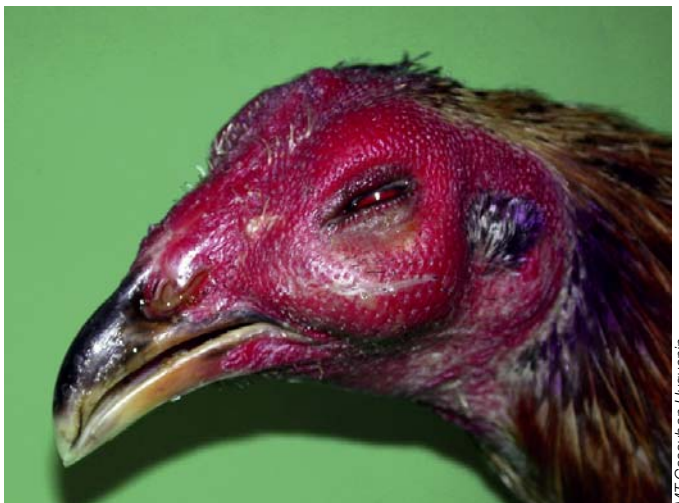LDA 22

Fig.47.9 & 47.10: Infectious coryza with swelling of the infra-orbital sinus and of wattle.



AAAP

Fig.47.11: Infectious coryza is associated with severe edema of both face and wattle (adult male broiler-type chicken).



MT Cassaubon Huguenin

Fig.47.12: Infectious coryza with important swelling of the infra-orbital sinus.

In the developed countries such as Australia and the USA, infectious coryza occurs primarily in pullets and layers and only occasionally in broilers. In the developed poultry industries, the impact of the disease is primarily due to a drop in egg production – 10 to 40%. The impact is greatest in multi-age flocks.

In other countries, infectious coryza often occurs in very young chicks, even as young as three weeks of age. Poor biosecurity, poor environment and the stress of other diseases are probably the main reasons why infectious coryza is more of a problem in such countries. The disease is often associated with significant mortalities under these conditions.

While the disease is typically thought of as a disease of intensively raised chickens, it can also occur in village chickens. Reports from Indonesia and Thailand are suggesting that the disease can be significant in these types of chickens.

In the mildest form of coryza, the only signs may be depression, a serous nasal discharge and slight facial swelling. In the more severe form of the disease, there is severe swelling of one or both infra-orbital sinuses with edema of the surrounding tissue, which may close one or both eyes. The swelling usually abates in 10-14 days; however, if secondary infection occurs, the swelling can persist for months.

Egg production may be delayed in young pullets and severely reduced in laying hens. Egg drops of 10-40% are typical in simple outbreaks in otherwise healthy layers. In layers that are also suffering concurrent diseases, egg drops of up to 87% and lasting for four weeks have been reported in some countries. Birds may have diarrhea and feed and water consumption usually is decreased during the acute stage of the disease.

In Argentina, a septicemic form of the disease has been reported, probably due to concurrent infections.

In acute cases, lesions may be limited to the infra-orbital sinuses. There is a copious semifluid exudate from the nostril. As the disease becomes chronic or other pathogens become involved, the sinus exudate may become consolidated and turn yellowish. Other lesions may include conjunctivitis, tracheitis, bronchitis, and airsacculitis, particularly if other pathogens are involved. The histopathological response of respiratory organs consists of disintegration and hyperplasia of mucosal and glandular

epithelia and edema with infiltration of heterophils, macrophages, and mast cells.

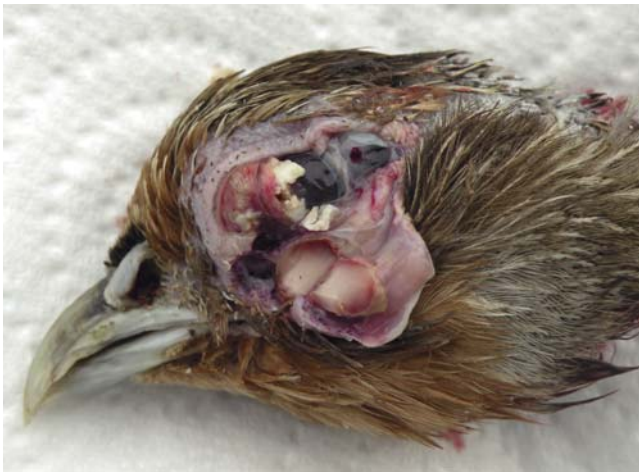The pathology associated with infections due to *Av. gallinarum* is quite diverse, including reports of conjunctivitis, abscesses in the head and wattles, sinusitis, tracheitis, airsacculitis, hepatitis, endocarditis, salpingitis, oophoritis, peritonitis and synovitis. Further careful evaluations of the role of *Av. gallinarum* are required and the organism should not be simply dismissed as non-pathogenic.

DIAGNOSIS

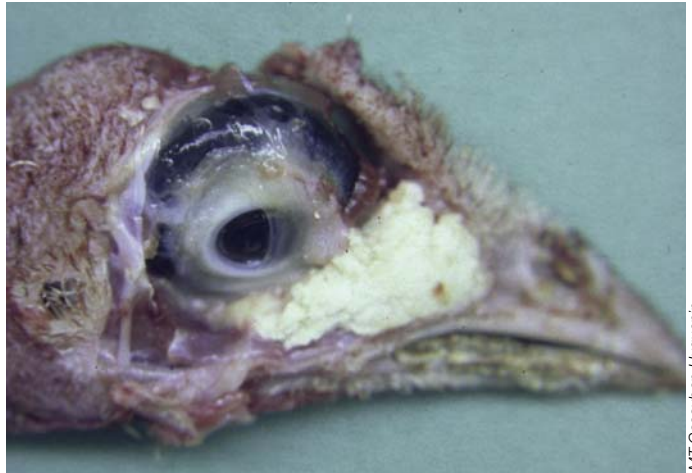Isolation of a Gram-negative, catalase-negative, satellitic organism from chickens in a flock with a history of a rapidly spreading coryza is diagnostic for infectious coryza. The catalase test must be performed as satellitic non-pathogenic species such as *Av. avium* and *Av. volantium*, that are catalase positive, are present in both healthy and diseased chickens. For those laboratories with more extensive facilities, biochemical tests can be performed to confirm the identity of any isolate. *Av. paragallinarum* is characterised by an ability to ferment glucose, sucrose and mannitol and an inability to ferment galactose and trehalose. Care must be taken with the galactose test as some poor quality galactose preparations contain enough contaminating glucose to give a false positive reaction.

Care must be taken in those regions where V-factor-independent *Av. paragallinarum* occur. These V-factor-independent *Av. paragallinarum* can only be confidently identified by biochemical testing or PCR (see below).

Undoubtedly, the definitive diagnostic test for infectious coryza is a PCR test that specifically detects *Av. paragallinarum*. The *Av. paragallinarum* PCR can be used directly on the live chicken by squeezing mucus from the sinus. The mucus is collected by swab and submitted for examination – there is no need for aseptic techniques. The PCR can also be on agar cultures (pure or mixed). When sinus swabs contain blood, they can be treated by low speed spin to get rid of RBC before extracting crude DNA by boiling method or extract DNA with commercial blood/tissue genomic DNA extraction kits (such as DNeasy blood & Tissue kit, Quiagen cat.69504). For the PCR test, swabs are processed as follows. The swab is soaked in 1 ml of phosphate-buffered saline in a 1.5-ml microfuge tube. The tube is centrifuged at 2000 rpm for 3-5 min to settle the blood. The *Av. paragallinarum*



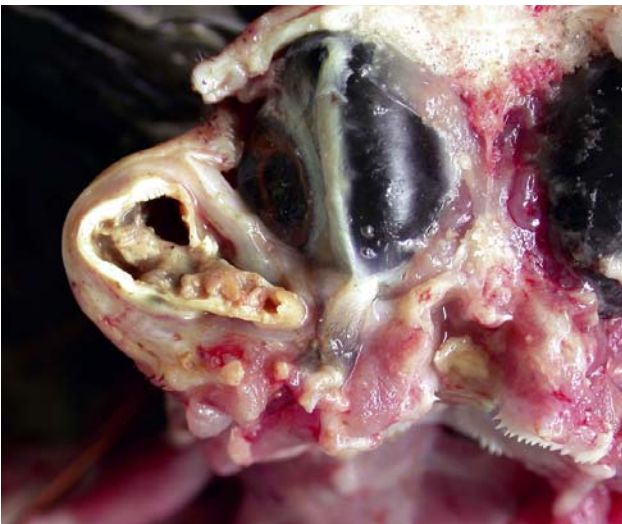B Robineau



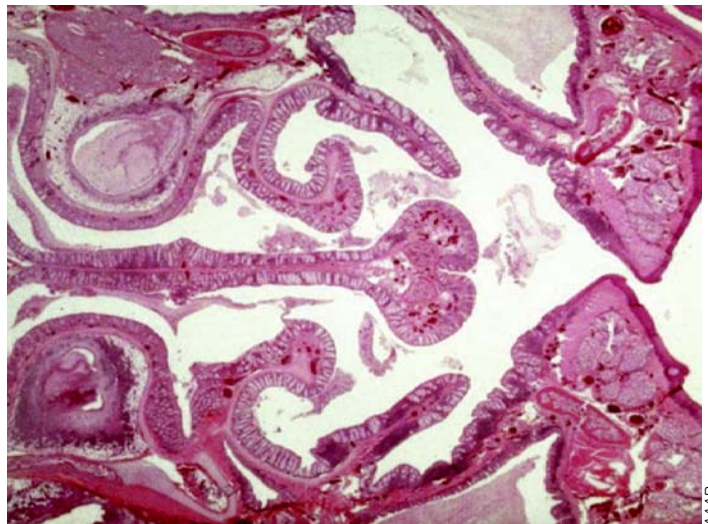
MT Casaubon Huguenin

Fig.47.13 & 47.14: Caseous plug in the sinus after removing facial skin.

Section III



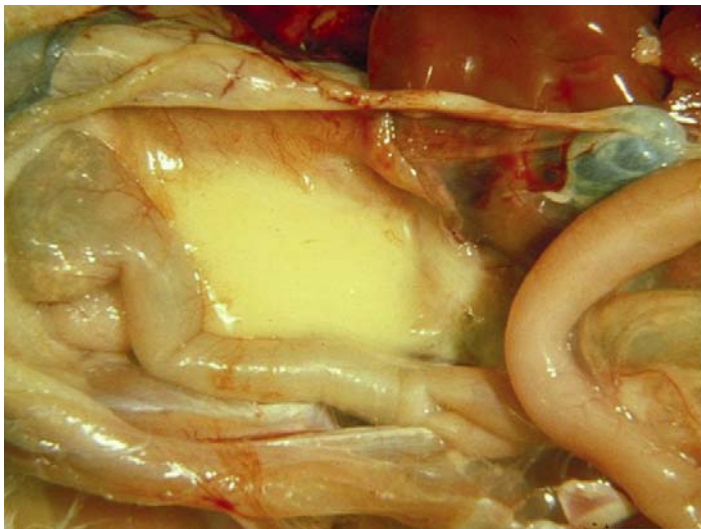
MT Casaubon Huguenin



AAAP

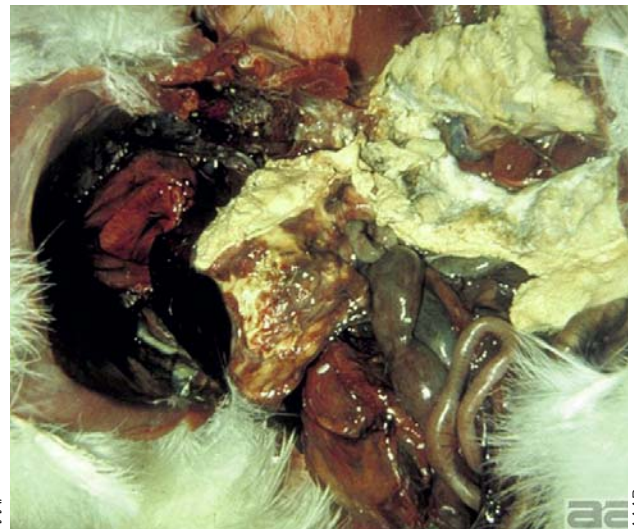
Fig.47.15: Transverse section of the nasal cavity showing caseous plug in the sinus.

Fig.47.16: Transverse section of the posterior nasal cavity of an experimentally infected rooster. Exudate is evident in the nasal cavity around the turbinates and nasal septum and in the lumina of the posterior turbinates and infraorbital sinuses. Hematoxylin & eosin; x2.



AAAP

Fig.47.17: Exudative airsacculitis in 9-week-old White Leghorn pullet caused by *Av. paragallinarum*.



AAAP

Fig.47.18: Caseous exudative airsacculitis produced by *Av. paragallinarum* and *M. synoviae* in a 9.5 week-old chicken.

PCR has proven superior to culture, even in developing countries.

No suitable serological test exists, although a hemagglutination-inhibition test is the best of the available tests. Hence, serology is not a widely used diagnostic tool. Other diseases that must be considered in a differential diagnosis are fowl cholera, mycoplasmosis, ornithobacterosis, laryngotracheitis, Newcastle disease, infectious bronchitis, avian influenza, swollen head syndrome and vitamin A deficiency.

Bacterial culture and identification is the only means of investigating infections associated with *Av. gallinarum*. Culture for *Av. gallinarum* is best done using sheep blood agar plates at 37°C with a 5-10% carbon dioxide atmosphere. Standard texts contain suitable identification tables. To date, no DNA based identification method, other than DNA sequencing, has been established for *Av. gallinarum*.

TREATMENT & CONTROL

Prevention of infectious coryza is the best method of control. “All-in/all-out” farm programs with sound management and good biosecurity are the best way to avoid the disease. Replacements should be raised on the same farm or obtained from flocks known to be free of coryza. If replacement pullets are to be placed on a farm that has a history of infectious coryza, vaccines should be used.

Infectious coryza vaccines are widely available. As Page serovars A, B and C are not cross-protective, it is essential that vaccines contain the serovars present in the target population. The immunization should be completed three to four weeks before infectious coryza usually breaks out on the individual farm. Antibodies detected by the hemagglutination-inhibition test after vaccination correlate with protective

immunity (titers of >1/5 indicate protection).

Controlled exposure to live *Av. paragallinarum* has also been used to immunize layers in endemic areas. This is a dangerous procedure and should only be used as a method of last resort.

Early treatment of infectious coryza is important. Water medication is recommended immediately until medicated feed is available. Erythromycin and oxytetracycline are usually beneficial. Antibiotics should only be used with due care and attention to the local regulatory environment. In more severe outbreaks, although treatment may result in improvement, the disease may recur when medication is discontinued. Preventive medication may be combined with a vaccination program in which started pullets are to be reared or housed on infected premises.

There appears to be no widespread use of *Av. gallinarum* vaccines.

REFERENCES

- Blackall PJ. Vaccines against infectious coryza. *World's Poult Sci J*, 1995,51:17-26.
- Blackall PJ et al. Reclassification of *Pasteurella gallinarum*, [*Haemophilus*] *paragallinarum*, *Pasteurella avium* and *Pasteurella volantium* as *Avibacterium gallinarum* gen. nov., comb. nov., *Avibacterium paragallinarum* comb. nov., *Avibacterium avium* comb. nov. and *Avibacterium volantium* comb. nov. *Int J Syst Evol Microbiol*, 2005,55:353-362.
- Bisgaard M et al. *Avibacterium endocarditidis* sp. nov., isolated from valvular endocarditis in chickens. *Int J Syst Evol Microbiol*, 2007, 57:1729-1734.
- Bisgaard M et al. Investigations on the clonality of strains of *Pasteurella gallinarum* isolated from turkeys in Germany. *Avian Pathol*, 2005, 34:106-110.
- Chen X et al. Development and application of DNA probes and PCR tests for *Haemophilus paragallinarum*. *Avian Dis*, 1996, 40:398-407.

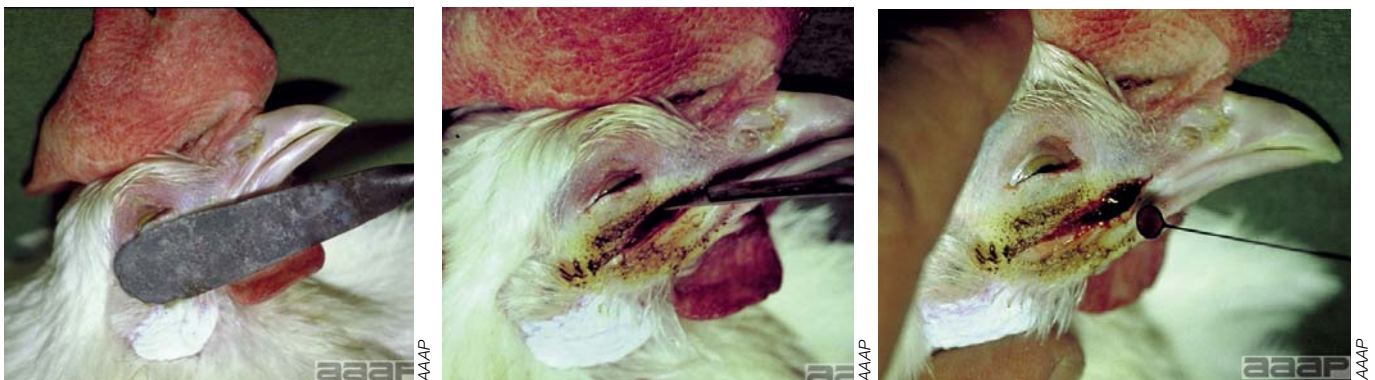

Fig.47.19, 47.20 & 47.21: To isolate the organism, the area beneath the eye and the corner of the beak is seared with a hot spatula to remove surface contamination. A cut is made into the infraorbital sinus with a flamed or sterile scalpel in the direction shown here. Exudate is collected by inserting a bacteriological loop into the sinus. The loop should be directed toward the back of the head to avoid isolation of bacteria that occupy the frontal areas of the respiratory tract.



Fig.48.1: ORT. Sinusitis in turkey poults.

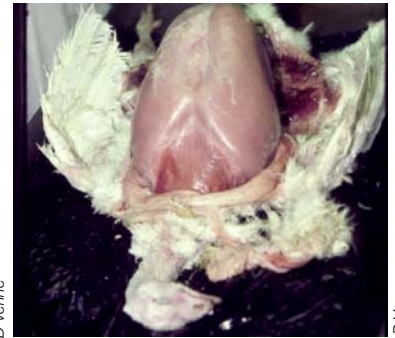
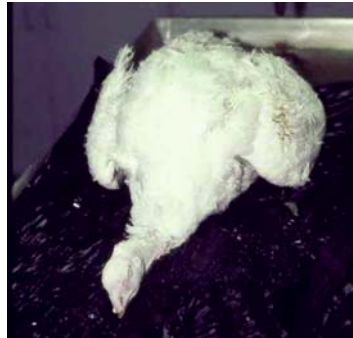
Fig.48.2 & 48.3: In older birds (e.g., > 12 weeks of age), ORT can cause acute pneumonia with mortality rates of up to 50%.

Section III

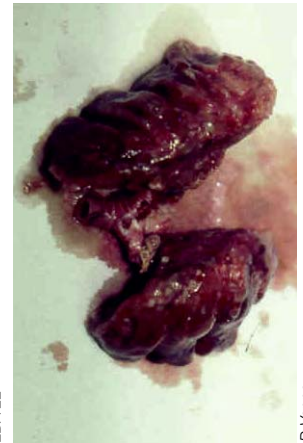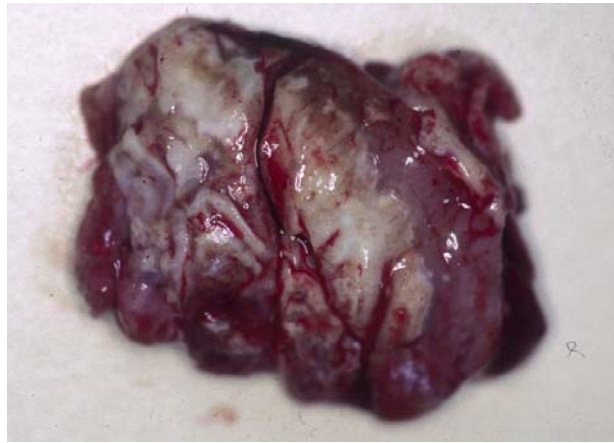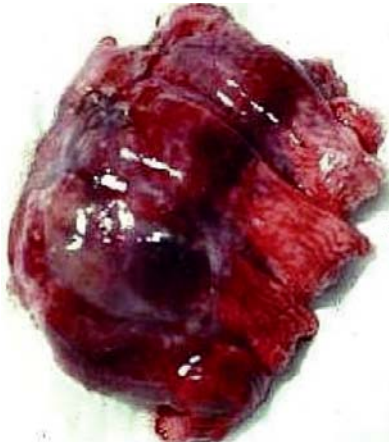


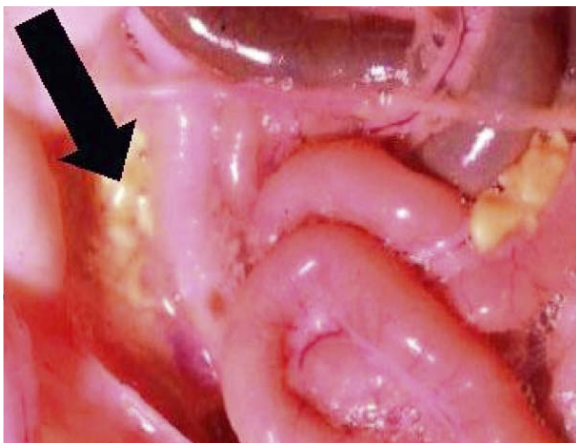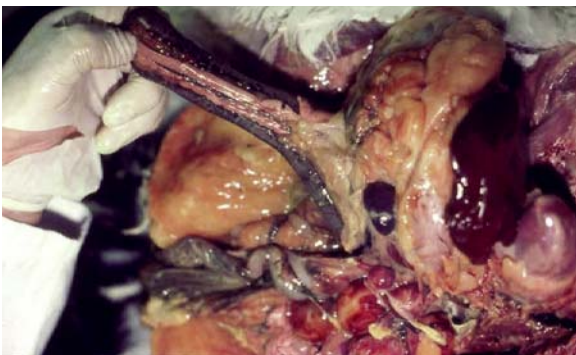Fig.48.4, 48.5 & 48.6: ORT. Pneumonia and pleuritis. Pneumonia is often unilateral, showing only parts of the lungs to be affected.

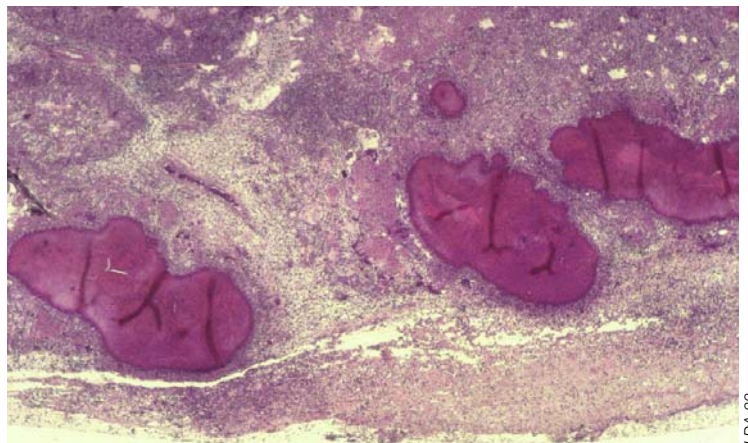


HM Hafeez



D Venne

Fig.48.7 & 48.8: ORT. Airsacculitis (abdominal air sacs). Thickened, opaque air sacs with profuse foamy «yogourt-like» exudate (white to yellow) with clots of fibrin (arrow).



LDA 22

Fig.48.9: ORT. Severe purulent pneumonia with granulomas (hematoxylin, eosin & safran).

Non infectious	Infectious
Management	Viral agents
Litter quality	TRT, ND, Influenza, IB, ILT
Stocking density	Bacterial agents
Ventilation rate	<i>Pasteurella multocida</i>
Temperature	<i>C. psittaci</i> , <i>E. coli</i> , <i>B. avium</i> ,
High ammonia level	<i>Mycoplasma</i> spp., <i>Streptococcus</i>
High dust concentration	spp., <i>Staphylococcus</i> spp.
Feed	Mycotic agents
High dust concentration	<i>Aspergillus fumigatus</i>
Vitamin A deficiency	Parasites

Tabl.48.1: Some possible causes of respiratory disease in poultry. ILT: infectious laryngotracheitis. Parasites: *Syngamus*, *Cryptosporidium*.

Bacterial diseases

48. ORNITHOBACTERIUM RHINOTRACHEALE

INTRODUCTION

Ornithobacterium rhinotracheale (ORT) is an acute highly contagious disease of chickens and turkeys. The infection has been recognized in many countries worldwide and incriminated as additional causative agent in the respiratory disease complex. The disease is mostly accompanied with heavy economic losses by increased mortality rates, increased medication costs, increased condemnation rates and drop in egg production.

ETIOLOGY & EPIDEMIOLOGY

Ornithobacterium rhinotracheale is a slow growing, pleomorphic, gram-negative, rod-shaped non-motile, non-sporulating bacterium. ORT belongs to the rRNA superfamily V within the *Cytophaga-Flavobacterium-Bacteroides* phylum. The bacteria grow on 5-10% sheep blood agar; develop very small non-hemolytic colonies under aerobic, micro-aerobic and anaerobic conditions. The optimal growth temperature is 37°C. It can also grow on tryptose soy agar and chocolate agar. All isolates are β-galactosidase (ONPG) positive, catalase negative and most of them react positively in urease test.

ORT has been isolated from chicken, turkey, duck, goose, guinea fowl pheasant, pigeon, quail, chukar, gull, ostrich, partridge, and rook. Currently 18 serotypes designated A to R are known. However, there is no indication of any host specificity of the serotypes. Within this bacterial species, isolates with different virulence seem to exist. Neither the origin nor the serotype of the ORT strains has an effect on the pathogenicity. Most of the chicken isolates belong to serotype A and turkey isolates are more heterogeneous and belong to serotypes A, B, E and D. Serotype C could only be isolated from chickens and turkeys in South Africa and USA.

The disease is spread horizontally by direct and indirect contact through aerosols or drinking water. Vertical transmission is suspected, since some research has shown that ORT can be isolated at very low incidence from reproductive organs and hatching eggs, infertile eggs and dead embryos. It is however not yet known if this vertical transmission is caused by ovarian or cloacal contamination.

CLINICAL SIGNS & LESIONS

The severity of clinical signs, duration of the disease and mortality are extremely variable and are

influenced by many environmental factors such as poor management, inadequate ventilation, high stocking density, poor litter conditions, poor hygiene, high ammonia level, concurrent diseases and the type of secondary infection. There are many reports showing synergism between ORT and Newcastle disease (ND), infectious bronchitis (IB), turkey rhinotracheitis (TRT), *Bordetella avium*, *Escherichia coli* as well as *Chlamydia psittaci*.

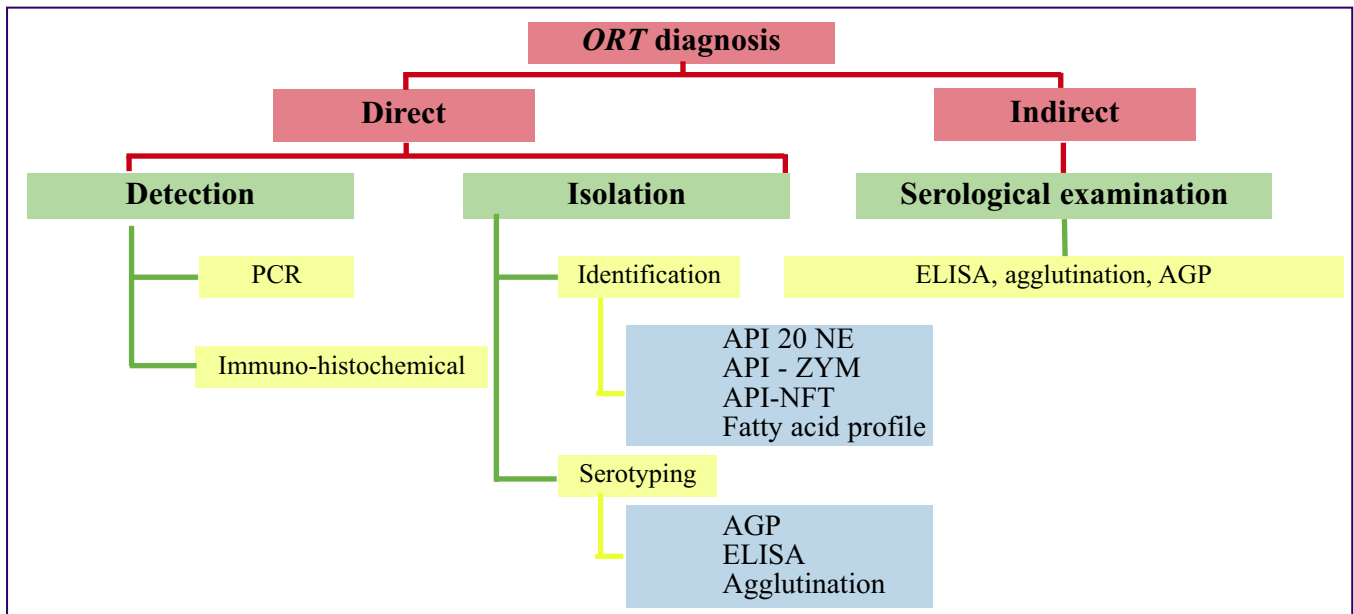
In turkeys, outbreaks mostly have been observed in male birds over 14 weeks of age. However, young poults between the 2nd and 8th week of age can also be affected. Mortality ranges between 1-15% during the acute phase (8 days). Initial clinical signs are coughing, sneezing and nasal discharge followed in some cases by severe respiratory distress, dyspnea, prostration and sinusitis. These signs are accompanied with a reduction in feed consumption and water intake. In turkey breeder flocks, clinical signs are accompanied mostly with drops in egg production and increases in the number of unsettingtable hatching eggs.

Problems in broilers generally appear between the 3rd and 4th week of age with a mortality rate of 2-10%. The clinical signs are depression, decrease in feed intake, reduced weight gains, transit nasal discharge, sneezing, followed by facial edema. In broiler breeders and layers the disease primarily affects them at the peak of production mostly between the 24th and 52nd week of age. Mild respiratory signs are the first indication of the disease. The mortality is variable and relatively low in uncomplicated cases. The clinical signs are generally accompanied with a drop in egg production, decrease in egg size and poor eggshell quality. Fertility and hatchability are unaffected in many cases.

The common gross lesions are localized in the lungs and include edema and uni- or bilateral consolidation of the lungs with fibropurulent exudate, pleuritis and airsacculitis. Peritonitis, pericarditis and enteritis could be detected.

DIAGNOSIS

Clinical signs and lesions are of little value for the diagnosis, since many other conditions produce similar signs and lesions. Accurate diagnosis must be substantiated by direct detection or isolation of the causative bacteria and/or indirectly through



Tabl.48.2: Laboratory diagnosis of ORT (AGP: agar-gel precipitin test).

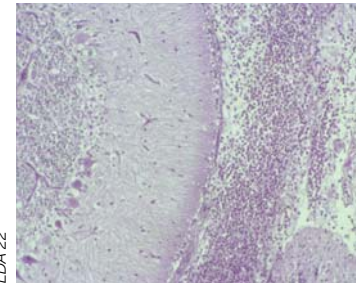
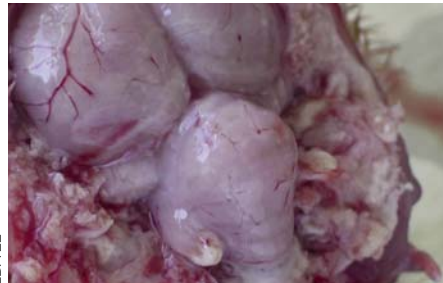
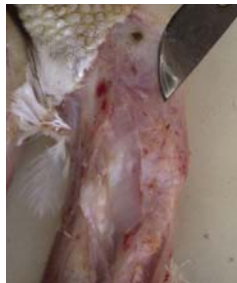
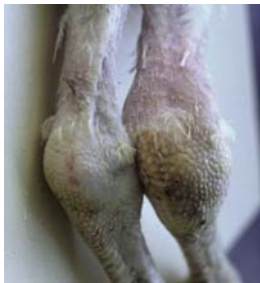Fig.48.10 & 48.11: Arthritis (53 day-old turkey). ORT with concurrent infection with viral arthritis.

Fig.48.12 & 48.13: ORT. Meningitis. Macroscopic and microscopic lesions (hemaloxilin, eosin & safran).

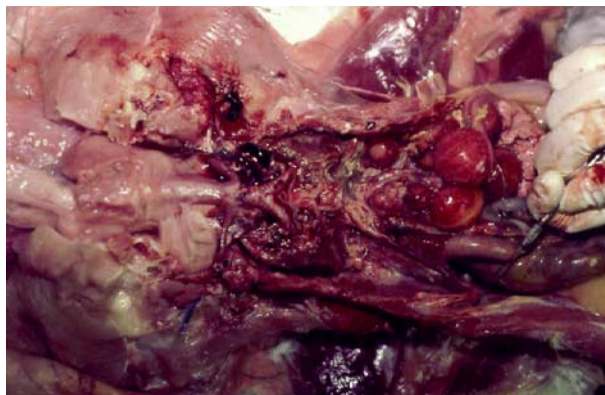


Fig.48.14 & 48.15: ORT in layers leads to a drop in egg production and a decrease in egg quality.

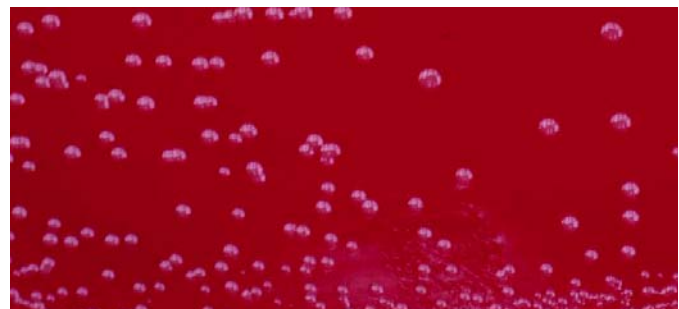

Fig.48.16 & 48.17: On the left, 24h culture of ORT on blood agar (note small colonies). On the right, 72h culture of ORT on blood agar.

detection of antibodies using serological examination. For detection of the bacteria, a sensitive immuno-histochemical staining or a specific Polymerase chain reaction (PCR) can be performed. The PCR assays can also be optimized for the demonstration of *ORT* in tracheal swabs, eggs and environmental samples. Samples for bacterial isolation should be collected at an early stage of the disease. *ORT* can usually be isolated from trachea, lungs and air sacs. Blood agar with 5-10% sheep blood is commonly used for primary isolation. The incubation of the plate at 37°C for 48 h under anaerobic or micro-aerobic condition is recommended. On blood agar the colonies are small, grey-white, opaque, non hemolytic and differ in diameter (1-3 mm). Identification trials can be carried out using commercial biochemical test-kit (API 20 NE, Bio-Mérieux, France). Colonies with a reaction code of 02 2 000 4 (61% of known isolates) or 00 2 000 4 (38.5% of known isolates) in this API 20 NE system are highly suspected. Another commercial identification system, the RapID NF Plus system (Innovative Diagnostics, USA), gives high identification scores (Biocodes 4-7-2-2-6-4, 4-7-6-2-6-4, 6-7-6-2-6-4 or 6-7-2-2-6-4). Disease confirmation could also be carried out using serological examination with known positive antisera in agar gel precipitation (AGP), enzyme linked immunosorbent assay (ELISA) or rapid slide agglutination. A further possibility for the typing is using the random-amplified-polymorphic-DNA (RAPD) or Pulse Field Gel Electrophoresis (PFGE).

Indirect diagnosis for detection of antibodies can be carried out using serological examination as slide agglutination test prepared from different serotypes or ELISA-tests. The serotype specificity of the ELISA depends on the method of antigen extraction used for coating the ELISA plates. Commercial available ELISA-kits are able to detect antibodies against all tested *ORT* serotypes.

TREATMENT & CONTROL

The treatment of infections with antibiotics is very difficult because of the inconstant sensitivity of the strains and regional variations in antibiotic sensitivity patterns. It is advisable, in all cases, to estimate the sensitivity of the strain involved. Under field conditions, however, water medication, using amoxicillin at a dose level of 250 ppm for 3-7 days often gives satisfactory results. Also application of

chlortetracycline at dose level of 500 ppm in drinking water for 4-5 days appears to be very effective. *ORT* has been shown to be highly sensitive to different chemical disinfectants. However, in some regions *ORT* infection appears to have become endemic and can affect new flocks even in previously cleaned and disinfected houses, especially in areas with intensive poultry production as well as in multiple age farms. Failure to clean and disinfect properly after an infected flock has been removed, can cause the infection of neighboring flocks and may allow *ORT* to continuously cycle between poultry houses. Thorough cleaning and disinfection of the houses between placements are important to minimize the infection pressure.

Vaccination trials using inactivated vaccine in broilers, in broiler breeders as well as in turkey flocks have been carried out. The primarily results showed that application of an inactivated vaccine on mineral-oil adjuvant base at one day of age in broilers gives a good protection and moderate serological response. Vaccination of broiler breeders with an inactivated vaccine at 12 and 18 weeks of age did also induce enough antibodies to supply the progeny with high levels of maternal antibodies and good protection against an *ORT* challenge for 14-30 days. The protection, however, decreased with increasing age of progeny. *Ornithobacterium rhinotracheale* vaccination trials using an inactivated vaccine in meat turkey flocks were carried out. The primarily results showed that application of an inactivated vaccine on mineral-oil adjuvant base can reduce the mortality and condemnation rates. A live vaccine based on a temperature sensitive mutant of *ORT* was found to have some protective properties but more tests are needed to evaluate the efficacy and safety of this strain.

REFERENCES

- Chin R & Droual R. Interaction of *Ornithobacterium rhinotracheale* infection. In "Diseases of Poultry", Iowa State Press, Ames 1997, pp.1012-1015.
- Hafez HM & Sting R. Investigations on Different *Ornithobacterium rhinotracheale* "ORT" Isolates. *Avian Dis*, 1999,34:1-7.
- Van Empel P & Hafez HM. *Ornithobacterium rhinotracheale*: a review. *Avian Pathol*, 1999,28:217-227.

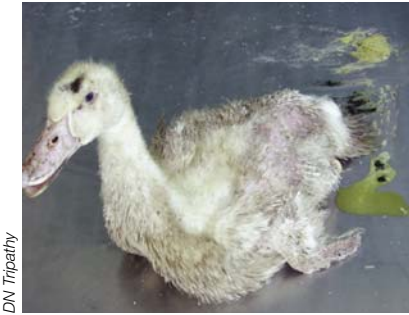


Fig.49.1: Differences in weight of three ducks of same age. An uninfected control duck (top) and two ducks (bottom) which were infected with a pathogenic strain of *Riemerella anatipestifer*.

Fig.49.2: Clinically, sneezing, coughing, trembling of the head and neck, ataxia and greenish diarrhea could be present.

Fig.49.3 & 49.4: Colonies of *Riemerella anatipestifer* on a blood agar plate.

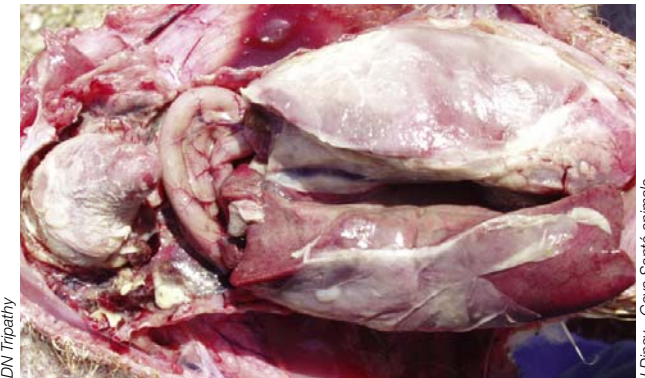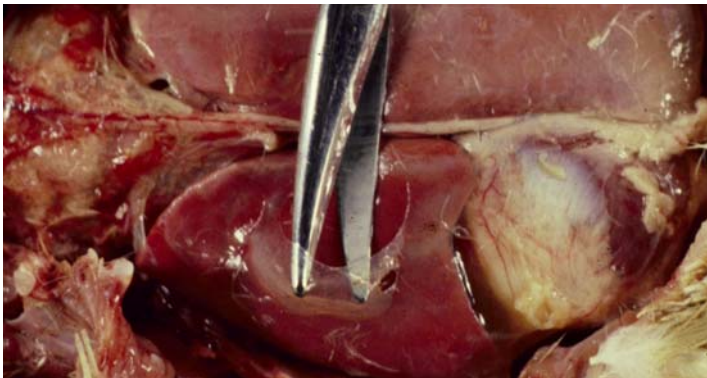


Fig.49.5 & 49.6: Gross lesions in ducks caused by *Riemerella anatipestifer* are characterized by fibrinous epicarditis and pericarditis.

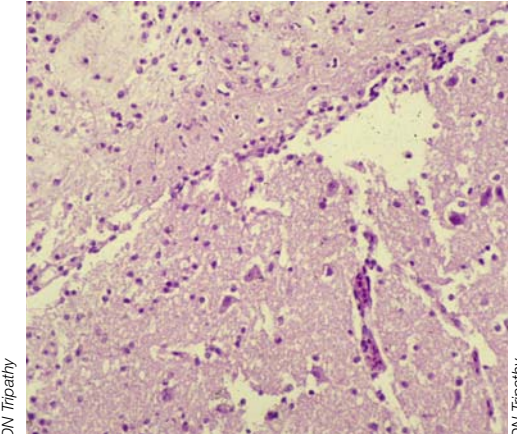
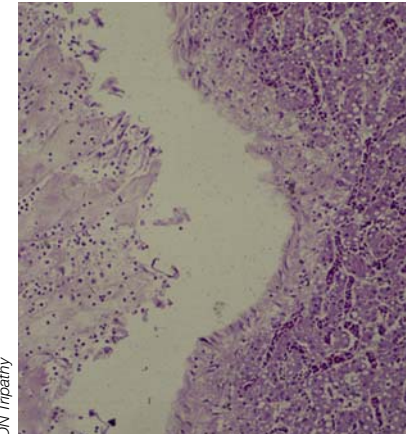
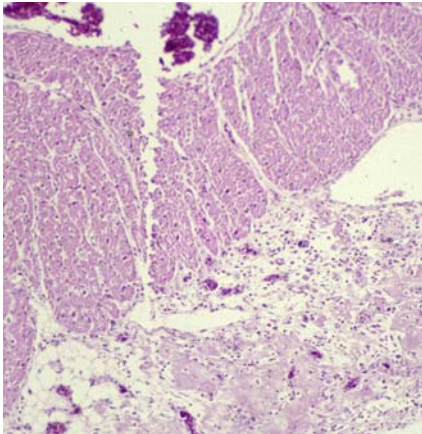


Fig.49.7: Microscopic lesions in the liver of a duck experimentally infected with *Riemerella anatipestifer* showing marked hepatitis.

Fig.49.8: Microscopic changes in the heart of a duck experimentally infected with *Riemerella anatipestifer*. The lesion is characterized by marked pericarditis.

Fig.49.9: Microscopic changes in the brain of an experimentally infected duck by *Riemerella anatipestifer*. Marked meningitis is evident.

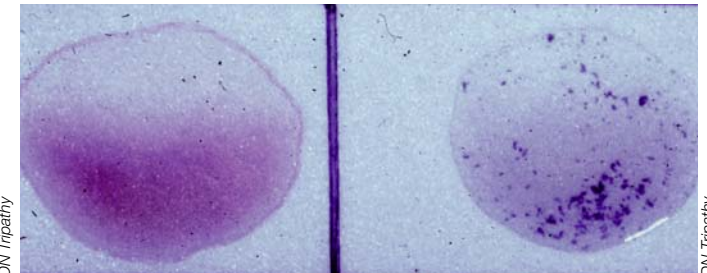
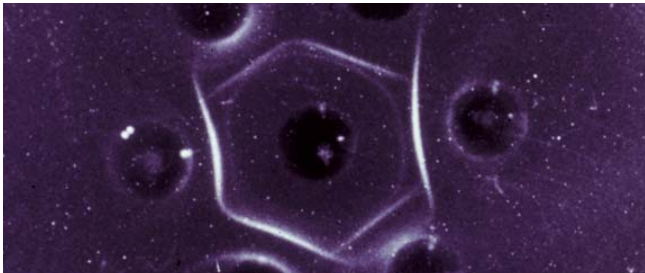


Fig.49.10: Agar gel diffusion test showing antigenic similarities as well as differences among serotypes of *Riemerella anatipestifer*.

Fig.49.11: Plate agglutination test: Antiserum against «ML» strain and antigen of «LI» strain» (left) – showing a negative reaction. Antiserum against «ML» strain and antigen of «ML» strain (right) - showing a positive agglutination reaction.

Bacterial diseases

49. RIEMERELLA ANATIPESTIFER INFECTION

INTRODUCTION

Riemerella anatipestifer infection is a septicemic disease of ducks, turkeys, and other birds. The disease is reported worldwide. It has been referred as “new duck disease”, “anatipestifer syndrome”, “anatipestifer septicemia”, “duck septicemia” and “infectious serositis”. It is an economically important disease for the commercial duck operations. Losses are due to high mortality, reduced weight gain, condemnation, downgrading and salvage. Infection with virulent strains may cause mortality as high as 75%.

ETIOLOGY & EPIDEMIOLOGY

Riemerella anatipestifer is a gram negative, non-motile, non-spore forming rod, which may occur singly, in pairs or in chains. A capsule can be demonstrated by special staining. Twenty-one serotypes of *Riemerella anatipestifer* have been recognized. Pathogenic strains cause depression, inability to stand, incoordination and torticollis. The ducks which survive the infection have stunted growth.

CLINICAL SIGNS & LESIONS

The disease is characterized by listlessness, nasal and ocular discharge, coughing, sneezing, greenish diarrhea, head and neck tremors and torticollis. Depending on the serotype and virulence of the strain(s), mortality may vary from 10 to 75%. Postmortem examination reveals fibrinous perihepatitis, pericarditis, hemorrhages in the brain, and airsacculitis. Microscopic changes such as pericarditis, perihepatitis and meningitis are observed on histopathological examination of the affected tissues.

DIAGNOSIS

The organism can be isolated from blood, liver, heart and brain of clinical cases. *Riemerella anatipestifer* grows in blood agar. Pure cultures are obtained from the brain. It does not grow in McConkey's agar and does not ferment sugars. However, it produces oxidase, catalase and phosphatase, but is indole negative.

Diagnosis can be made with serotype specific polyclonal antibodies by immunodiffusion test or

by a slide/plate agglutination test. Rapid diagnosis can also be made by reacting the impression smears from tissues e.g., brain, liver with type specific fluorescent antibody to detect the presence of the organisms.

For differential diagnosis, *Pasteurella multocida*, *Salmonella* and *Escherichia coli* must be considered because these diseases produce similar gross lesions. Therefore, diagnosis must be based on isolation and identification of the causative agent.

Naturally infected birds that survive the infection and vaccinated birds develop antibody responses. Although antibody responses of such birds can be determined by plate agglutination and agar gel precipitation tests, ELISA is more sensitive than other tests.


TREATMENT & CONTROL

Riemerella anatipestifer is susceptible to many antibiotics e.g., penicillin, novobiocin, chloramphenicol, lincomycin, enrofloxacin, ceftiofur, streptomycin, erythromycin, ampicillin, bacitracin, neomycin and tetracyclines. However, it is resistant to kanamycin and polymyxin B. Antibiotics and sulfa drugs have been used for treatment of *Riemerella* infection with varying degree of success.

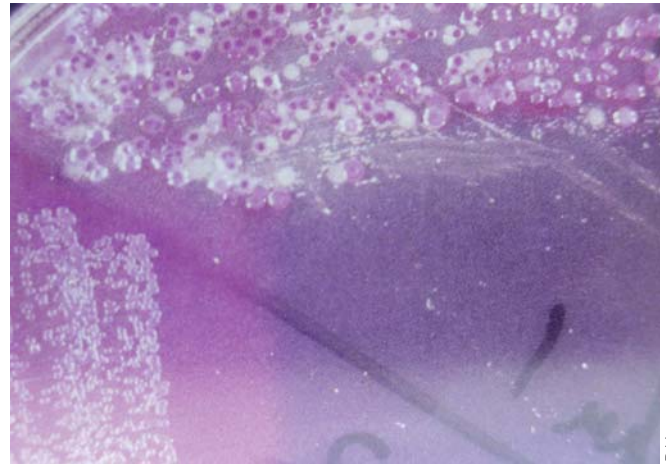
Both attenuated and inactivated vaccines have been used towards prevention of the disease. Immunity induced by the vaccines is serotype-specific. Inactivated vaccines against the prevalent serotype(s) provide a significant reduction in mortality. In this regard, autogenous vaccines prepared from recent isolates are quite effective in reducing losses associated with the disease.

REFERENCES

- Glisson JR et al. Pasteurellosis, Avibacteriosis, Gallibacteriosis, Riemerellosis and Pseudotuberculosis. In: *A Laboratory Manual for the Isolation, and Characterization of Avian Pathogens*. 5th ed. Eds. L. Dufour-Zavala et al, AAAP, Jacksonville, FL 2008; pp. 12-18.
- Sandhu TS. Riemerella anatipestifer infection. Chapter 19: In: *Diseases of Poultry*, 12th ed. Eds. YM Saif et al, Blackwell Publishing, 2008, pp. 758-764.



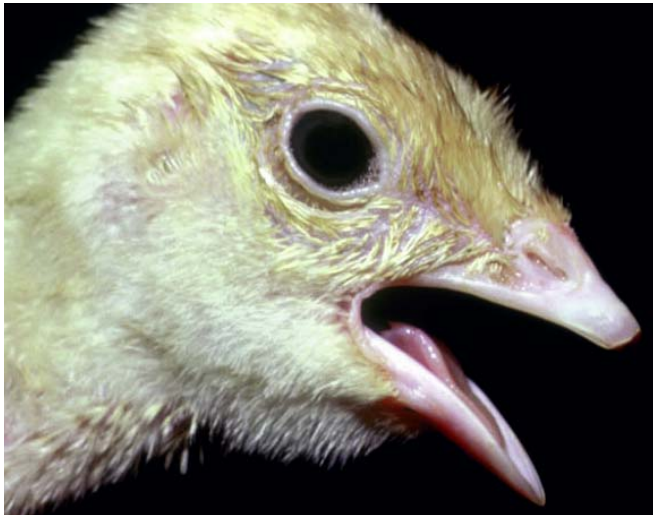D Venne



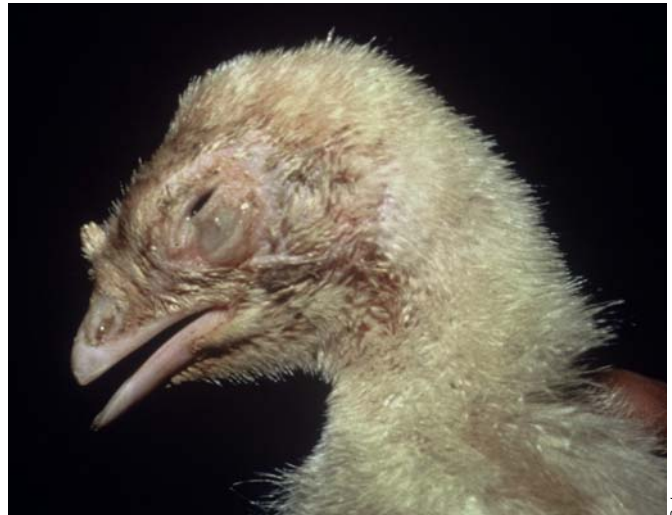D Venne

Fig.50.1 & 50.2: Colonies of *B. avium* type I on blood agar medium (left) and MacConkey agar medium (right). Culture on agar medium usually shows small colonies of 0.2 to 1 mm in diameter after 24 h at 35 °C (1 to 2 mm after 48 hours of incubation), pearl-like (round, convex translucent with raised center and regular edge). These colonies are differentiated from flatter and larger type II colonies or rough type III colonies with a dry appearance and an irregular serrated edge, the latter corresponding to nonpathogenic *B. avium*.

Bacteriological diagnosis must be done early to avoid isolation of opportunistic bacteria having secondarily invaded the respiratory tract. These bacteria can overgrow *B. avium* colonies. Samples (infraorbital sinuses and trachea) should be taken soon after death. When using MacConkey agar, it is important to differentiate *B. avium* from *Ornithobacterium rhinotracheale* and *B. hinzii*.



HJ Barnes - AAAP

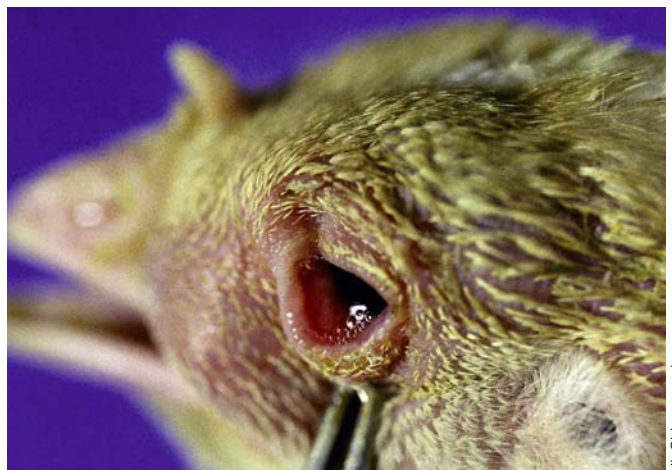

Solvey

Fig.50.3 & 50.4: Bordetellosis (Poult). The first clinical signs are sneezing, conjunctivitis and coughing, with wet tracheal rales. One can observe a clear exudate by pressing the dorsal part of the nostrils. Intermandibular edema is often observed.



Solvey



HL Shivaprasad

Fig.50.5 & 50.6: Bordetellosis (Poult). Conjunctivitis. Sometimes a foamy discharge is observed with conjunctivitis.

Bacterial diseases

50. BORDETELLOSIS

INTRODUCTION

Bordetellosis (or turkey coryza), previously named *Alcaligenes faecalis* rhinotracheitis, is a highly contagious upper respiratory tract disease caused by *Bordetella avium*. The disease primarily affects young turkeys. First described in Quebec in 1967, this disease is now known in many countries (USA, Israel, South Africa, Australia, France, Italy, UK, etc.).

Colonization of the ciliated epithelium of the upper respiratory tract by *B. avium* results in respiratory disorders predisposing young birds to secondary infections (particularly colisepticemia) resulting in growth retardation and increased mortality.

Bordetella avium has been shown to have properties similar to those of other pathogenic *Bordetella*, in particular *B. Pertussis*. The isolation of *B. avium* and *B. avium*-like in cases of human respiratory disease does not exclude the possibility that these bacteria may be opportunistic pathogens of humans.

ETIOLOGY & EPIDEMIOLOGY

Bordetella avium is a strict aerobic, capsulated and motile, Gram-negative, rod-shaped bacterium.

Hemagglutination of guinea pig erythrocytes is associated with pathogenicity and can differentiate *B. avium* from *B. hinzii* (called *Bordetella avium*-like) which was regarded as nonpathogenic. But in 2009, the pathogenicity of *B. hinzii* was demonstrated in turkeys, but not in chickens.

There appears to be considerable variation in virulence between the strains. The following virulence factors have been identified: pertactin (outer membrane protein that promotes adhesion to tracheal epithelial cells), hemagglutinin, endotoxin, heat-labile dermonecrotic toxin (DNT), tracheal toxin (TCT), osteotoxin and a histamine-sensitizing factor. In the first stage of infection, the bacteria adhere to ciliated cells of the nasal mucosa then the tracheal mucosa to reach the primary bronchi in 7 to 10 days. Bacterial toxins and inflammatory response to infection will induce the onset of clinical signs, immunodepression and promote secondary infections by other pathogens, especially *Escherichia coli*.

Bordetella avium is resistant in the environment at low temperature, low humidity and neutral pH. It can survive for 25-30 days in droppings and dust at 10°C and relative humidity of 32-58%. Clinically affected birds or healthy carriers are the most important sources of infection either by direct contact or by contamination of litter and drinking water. Contaminated water can remain in water lines and be a source of infection for new flocks. There is no evidence of horizontal transmission by aerosol or vertical egg transmission. Some wild birds (wild turkeys, ducks and geese) can act as reservoir for *Bordetella*.

Bordetella avium is not only a primary pathogen for turkeys but also for Muscovy ducklings, quail chicks or cockatiel chicks. It appears to be an opportunist pathogen for chickens and perhaps for other bird species. Genetic susceptibility may exist among birds like heavy line turkeys being more susceptible than lighter line turkeys.

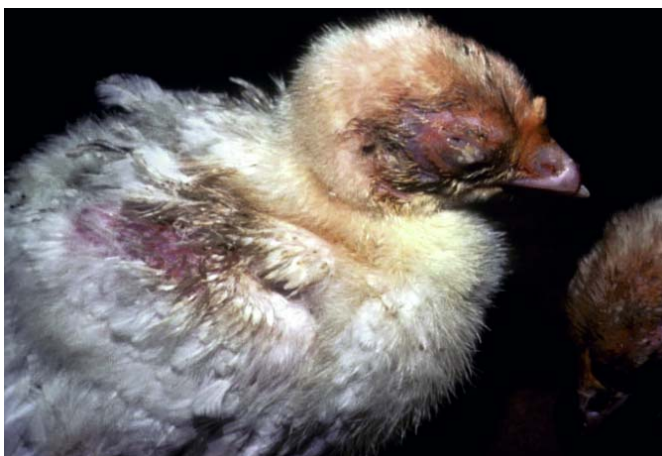Bordetella avium is susceptible to most disinfectants and very dry environmental conditions.

CLINICAL SIGNS & LESIONS

Bordetellosis occurs in two to six week-old poults. Disease can be attenuated by the presence of passive maternal immunity. The incubation period is 4 to 10 days. The disease is characterized by sudden onset and rapid spread with high morbidity (80 to 100% in 24-48h) and low mortality.

Clinical signs

The first clinical signs include foamy conjunctivitis, sneezing and coughing, with moist tracheal rales. One can observe a clear exudate by pressing the dorsal part of the nostrils. In older turkeys, the only clinical sign is a dry cough. New signs are observed during the second week after the onset of the disease. The exudate becomes progressively thicker, crusted, brown, soiling the nostrils and the feathers of the head and shoulders. Some poults may show dyspnea, open-mouth breathing and the voice of affected poults may become high-pitched. Submandibular edema is commonly noted. Tracheal rales may persist for several weeks after recovery.



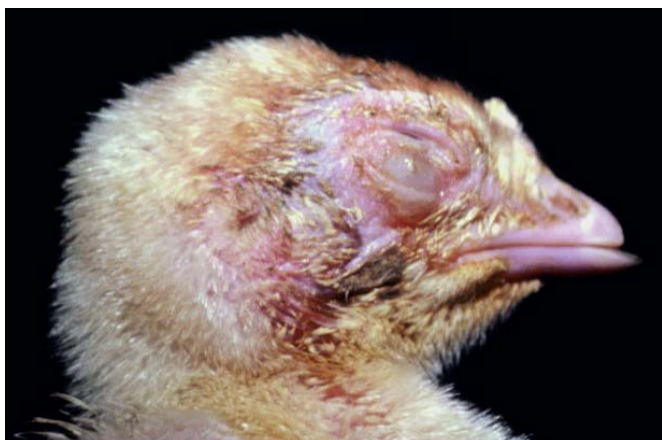HJ Barnes



D Venne

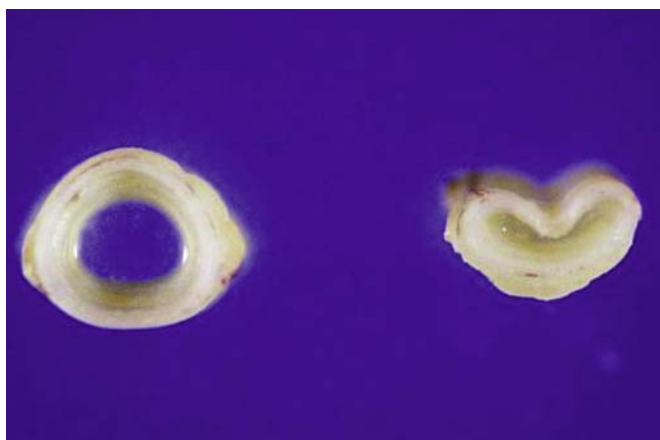
Fig.50.7 & 50.8: Bordetellosis. Turkey poults with stained head and shoulder feathers.

Section III



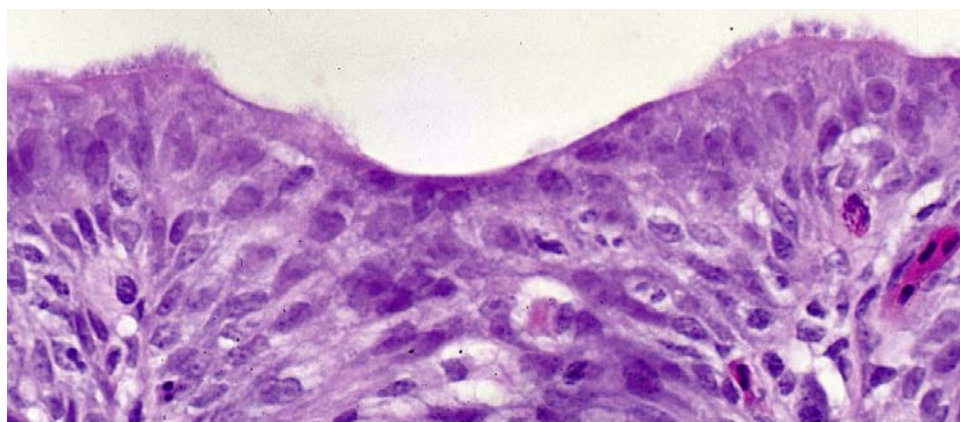
HJ Barnes

Fig.50.9: Bordetellosis (Poult). Late signs 14 days after the onset of the disease.



HL Shivaprasad - AAP

Fig.50.10: Bordetellosis (Poult). Cross section of the collapsed trachea from a poult with a characteristic flattening or dorsal infolding. Compare with the normal trachea on the left.



HL Shivaprasad

Fig.50.11: Bordetellosis. *B. avium* attaches readily to ciliated epithelial cells of the upper respiratory tract. This leads to deciliation, impairment of mucociliary clearance and mucus accumulation.

General signs may be observed: apathy, huddling, decreased consumption of feed and water resulting in growth retardation.

Mortality rates may vary and may be high (10-60%), depending on intercurrent infections, poor management, especially inadequate ventilation, and poor environmental conditions. *Escherichia coli* septicemia is the most common cause of death. Other agents like avian pneumovirus and *Ornithobacterium rhinotracheale* may also be involved.

Lesions

In the early stages of the disease, lesions are limited to excess mucus in the upper respiratory tract, which can be mucopurulent.

When cutting the trachea, the more distal rings are softer and may present distortions or dorsal folds. This tracheal lesion, often persistent and associated with the presence of a mucopurulent plug, is the cause of death by suffocation.

Microscopic observation of the trachea shows the presence of *B. avium* colonies adhering to cilia, loss of ciliated epithelium, dilated mucous glands depleted of mucus, and interstitial infiltration of plasma cells and lymphocytes.

Lower respiratory tract lesions are due to intercurrent infections.

DIAGNOSIS

Diagnosis of bordetellosis is partly based on its sudden appearance and rapid spread in young turkeys. The differential diagnosis mainly includes turkey rhinotracheitis due to pneumovirus and *Ornithobacterium rhinotracheale* infection. Other diseases to consider are Newcastle disease, chlamydiosis, mycoplasmosis, cryptosporidiosis and avian influenza.

It is important to confirm any suspicion by a bacteriological examination. *Bordetella avium* can also be demonstrated by indirect immunofluorescence using specific monoclonal antibodies or by polymerase chain reaction.

It is also possible to use various serological tests (rapid slide agglutination, microagglutination, enzyme linked immunosorbent assay). Serological

diagnosis is more accurate when the interpretation of the test is done at the flock level.

TREATMENT & CONTROL

Treatment

Numerous antimicrobial treatments have been used in drinking water, by injection or aerosol, but with only limited success. Some treatments like sulphonamides/trimethoprim in drinking water for 5 days can be effective but relapse occurs after the treatment is discontinued. The reason for this is not the inefficiency of the drug but rather the difficulty in reaching effective therapeutic levels in the trachea and the persistence of the agent in the environment. Nevertheless, treatment can help reducing losses linked to intercurrent infections.

Biosecurity

Implementation of biosecurity measures is effective in preventing or eliminating the disease. The success of these measures will depend on compliance: depopulation, cleaning and disinfection of premises and equipment (especially ventilation systems, feeders and waterers), preventing contact with carriers (e.g., older infected birds, wild birds).

Vaccination

Inactivated commercial vaccines, autovaccines, and a live temperature-sensitive mutant of *B. avium* vaccine are available. Live vaccines are used in poults (first dose by spray in the hatchery with a booster in drinking water two to three weeks later). Inactivated vaccines are used in breeder hens to provide passive immunity to progeny for the first two to three weeks of age, resulting in a less severe disease in poults.

REFERENCES

- Harrington AT et al, Isolation of *Bordetella avium* and Novel *Bordetella* Strain from patients with Respiratory Disease. *EID*, 2009,15:73-74.
- Hinz KH. Avian bordetellosis. In *Poultry diseases*. Ed Pattison M et al, 6th edition. 2008, Elsevier, pp 176-180.
- Jackwood MW JM & Saif YM. Bordetellosis (Turkey coryza). In "*Diseases of poultry*". Ed. Saif YM, 12th Ed, Blackwell Publishing, Iowa, IA, 2008, pp 774-788.

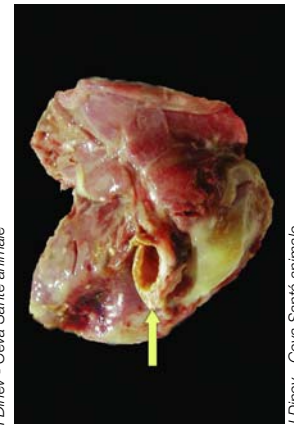
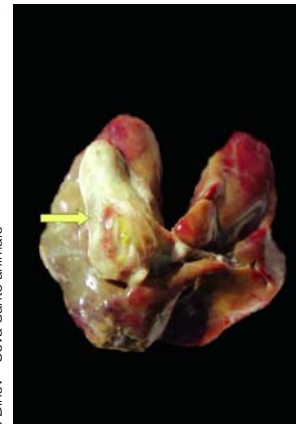
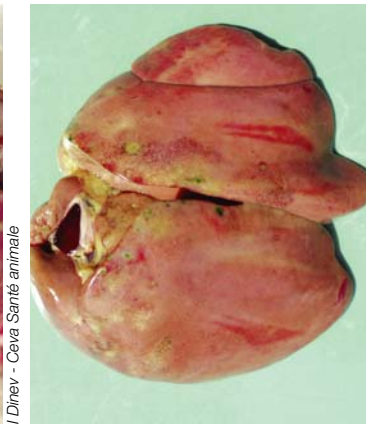
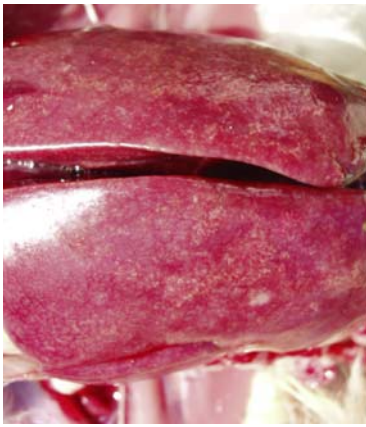

Fig.51.1 & 51.2: *C. perfringens*-associated hepatitis. The liver is enlarged and pale in color. In some cases, its surface has a characteristic acinous appearance and in others is mottled with multiple small grayish-white or greenish foci.

Fig.51.3 & 51.4: *C. perfringens*-associated hepatitis. The walls of the gallbladder (arrows) are thickened (up to 5-6 cm) and opaque (transverse cross section on the right).

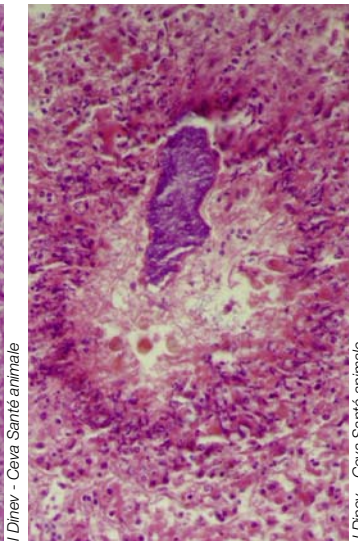
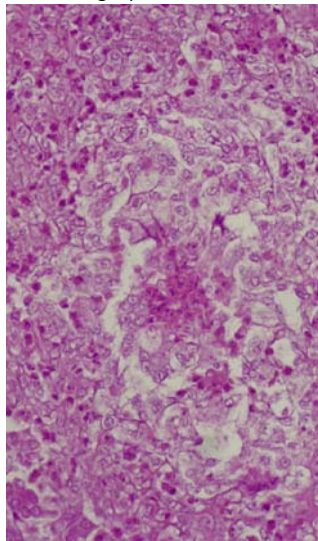
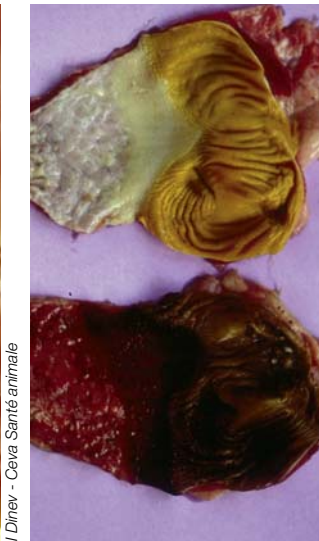
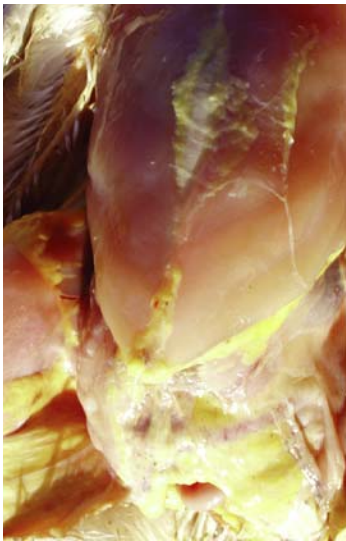


Fig.51.5: *C. perfringens*-associated hepatitis. In some chickens, the sub-cutaneous fat and the body fat have an icteric tint.

Fig.51.6: *C. perfringens*-associated hepatitis. Proventriculitis with hemorrhages can be also seen in chickens (age: 34 days).

Fig.51.7 & 51.8: *C. perfringens*-associated hepatitis. Liver microscopic lesions. On the left, the overgrown bile ducts form granulomatous structures, surrounded by fine reticular fibres. On the right, in many bile ducts, biliary stasis is present and within some, a huge amount of microorganisms are detected. Pericanalicularly, coagulation necroses are frequently noticed.

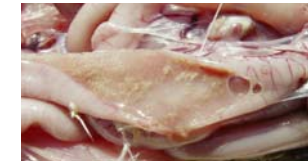
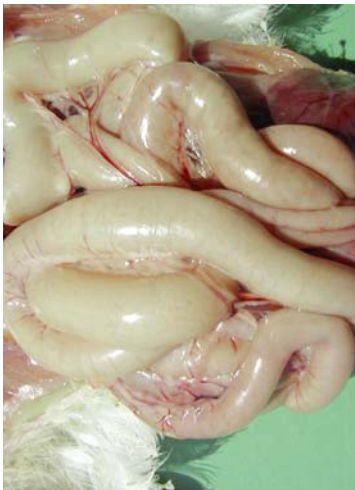
Fig.51.10: Necrotic enteritis (Chicken). The intestinal lumen is filled with brownish watery content, mixed with gas bubbles.

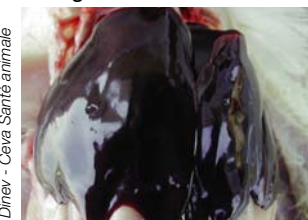

Fig.51.11: Necrotic enteritis. In acute cases, note the marked congestion of liver, responsible for its dark red to black appearance.

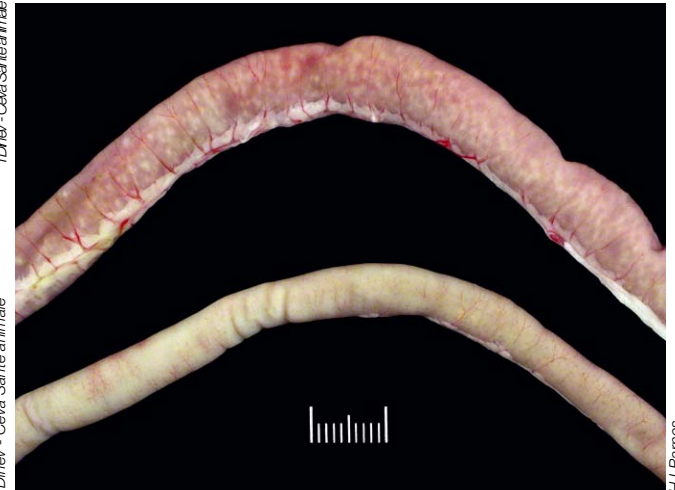

Fig.51.12: Necrotic enteritis (Chicken). Compare with normal intestine below.

Fig.51.9: Necrotic enteritis (Chicken). The small intestine is distended with gases and the necrotic mucosa is visible through the wall.

Bacterial diseases

51. CLOSTRIDIAL DISEASES

INTRODUCTION

There are four clostridial diseases of importance in poultry: necrotic enteritis (NE), ulcerative enteritis (UE), gangrenous dermatitis (GD), and botulism. Other clostridial species have been isolated from sporadic diseases in birds: *Clostridium chauvoei* (lesions of the comb, liver and/or intestine), *C. difficile* (enterotoxemia, enteritis in ostriches), *C. piliforme*, *C. novyi*, *C. sordellii*, and *C. sporogenes*. Increasing restrictions on the use of feed antimicrobials in some countries has changed the status of *C. perfringens*-associated necrotic enteritis in poultry. *C. perfringens* increasingly is being recognized as a cause of cholangiohepatitis in chickens. This liver disease is named «*C. perfringens*-associated hepatitis» (CPH). *Clostridium perfringens* is also associated with clostridial dermatitis of turkeys (CDT; equivalent to GD), gizzard erosions and navel infections. *Clostridium septicum* is considered the main agent associated with CDT.

NECROTIC ENTERITIS

Necrotic enteritis (NE) is a sporadic, acute, non-contagious disease of the small intestine of poultry, characterized by severe fibrinonecrotic enteritis with the formation of a diphtheritic pseudomembrane, and high mortality rates.

Etiology & epidemiology

The cause of NE is *Clostridium perfringens* Type A or C, a toxin-producing, anaerobic, gram-positive, spore-forming rod. *C. perfringens* is commonly found in soil and fresh water, and in the intestines and feces of normal birds, so NE is not considered a contagious disease *per se*. Highly contaminated feed or litter may cause some outbreaks. But in most cases, it appears that other predisposing factors favor the proliferation of resident *C. perfringens* as well as toxin production. These predisposing factors include a variety of dietary constituents such as high levels of fishmeal, and the so-called viscous cereals such as rye, barley, oats, triticale, and wheat. Damage to the intestinal mucosa, as with coccidiosis or from ingestion of rough, fibrous litter, may precipitate cases. Necrotic enteritis is principally a disease of young broiler chickens between 2 and 5 weeks of age, raised on litter. It has also been reported in layers both on litter and in cages, and in turkeys. Morbidity and mortality can be quite high.

Clinical signs & lesions

Many cases are peracute, and birds are simply found dead. Clinically affected flocks usually contain large numbers of severely depressed birds, with retracted head and neck, closed eyes, ruffled feathers, reluctance to move, watery diarrhea, and a humped-up appearance. The intestines are distended and friable, and contain copious gas and foul, dark reddish-brown, flocculent fluid. The characteristic lesion is a diffuse, adherent, rough, friable, fibrinonecrotic pseudomembrane that varies in color from tan to gray, yellow, or green. The livers of affected birds are often swollen and extremely dark. Enlarged, firm, pale livers with thickened gall bladders can be associated with NE. A subclinical form of NE produces few clinical signs and little or no mortality, but results in performance shortfalls. The lesions in this form consist of 1 to 2 mm circular depressions in the mucosa surrounded by a hyperemic periphery, and covered with adherent irregular, yellow necrotic material.

Diagnosis

Gross lesions are highly characteristic and diagnosis can usually be made on that basis in the field. Differential diagnoses should include coccidiosis (especially *Eimeria brunetti*), ulcerative enteritis, and histomoniasis.

Treatment & control

Necrotic enteritis generally responds favorably and rapidly to a variety of therapeutic antibiotics, including lincomycin, bacitracin, the tetracyclines, penicillin, and tylosin. Necrotic enteritis is effectively prevented by sub-therapeutic levels of a variety of antibiotics in the feed, including bacitracin, lincomycin, virginiamycin, penicillin, avoparcin, and nitrovin. Removal of fishmeal, replacement of viscous cereals with corn (maize), and increases in the grist size or use of whole grains may help decrease the incidence. Exogenous enzymes which break down the viscous polysaccharides in grains may have some benefit. A number of probiotics have shown beneficial effects in controlled challenge trials. Frequent cleaning and disinfection of facilities, the use of clean, deep litter, of organic acids in the feed or water, and acidifying the litter are other possible aids. Good control of coccidiosis is paramount.

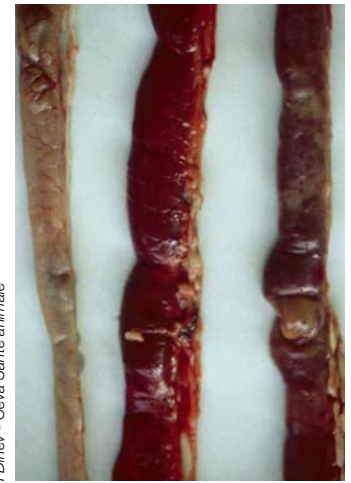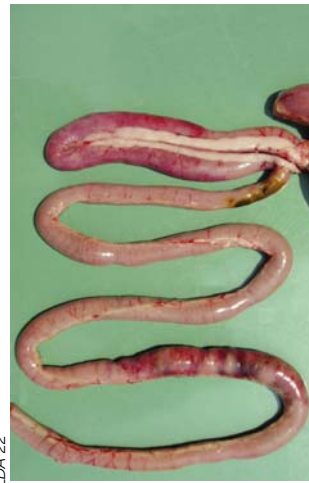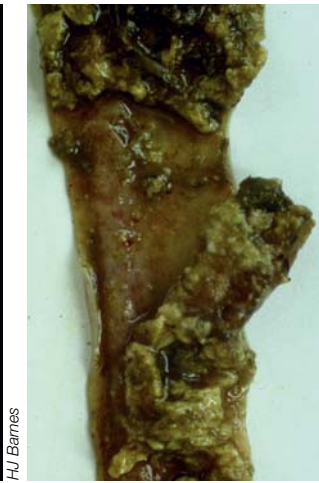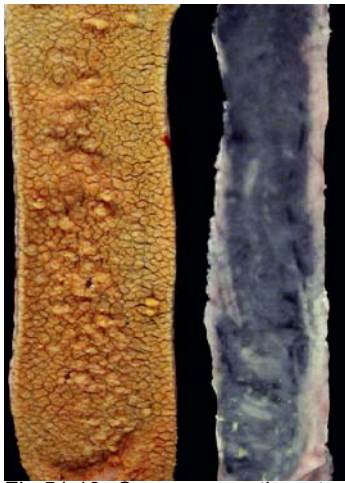


Fig.51.13: Severe necrotic enteritis (Chicken). Note the “Turkish towel” appearance to the necrotic pseudomembrane covering the intestinal mucosa. Compare with normal intestine on the right.

Fig.51.14: Severe necrotic enteritis (Chicken). Detachment of necrosed fragments having the aspect of bread-crums.

Fig.51.15 & 51.16: Necrotic enteritis. In cases when NE is associated with small intestinal coccidiosis, multiple petechial (on the left) or more important hemorrhages (on the right) could be perceived through the wall.

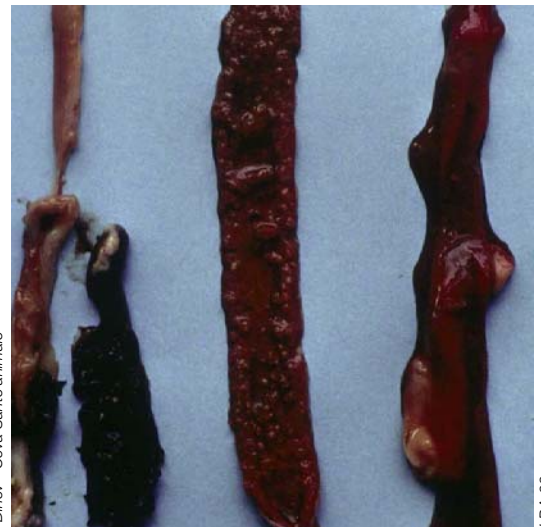
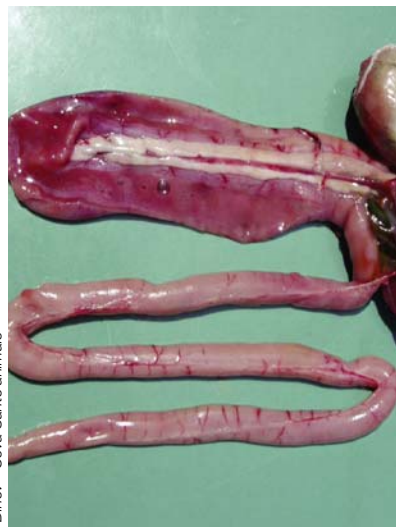
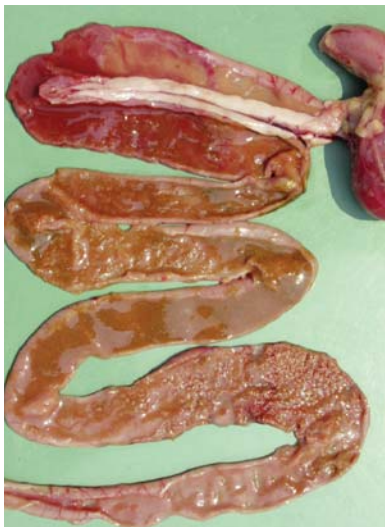Fig.51.17, 51.18 & 51.19 : Necrotic enteritis (Chicken). Simultaneous occurrence of NE and coccidiosis, the content of the lumen is bloody, mixed with necrotic tissue and gas bubbles.

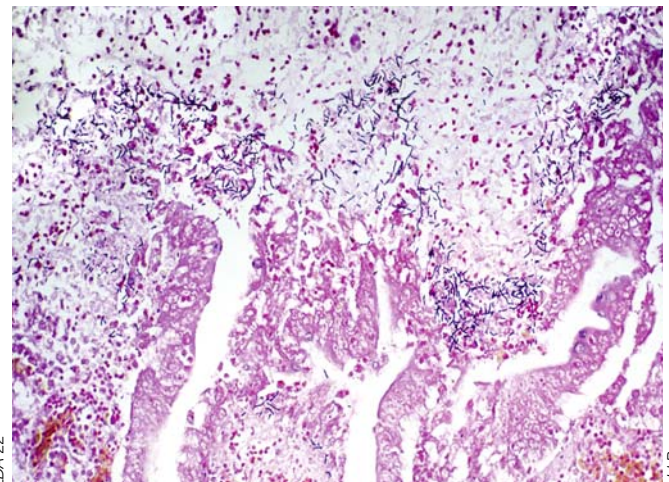
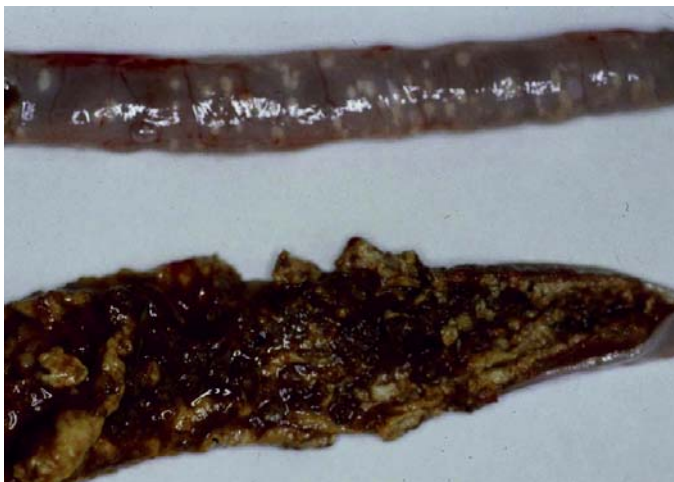

Fig.51.20 Necrotic enteritis (Turkey) associated with coccidiosis (*Eimeria meleagrimitis*). The content of the lumen is bloody, mixed with necrotic tissue.

Fig.51.21: Necrotic enteritis (Turkey). Gram-stained *C. perfringens* on the tip of villi.

ULCERATIVE ENTERITIS

Ulcerative enteritis (UE) was first seen in quail and named quail disease (see Chap.VI.96). Many avian species other than quail are susceptible, especially in some poultry-raising areas and in game birds.

Etiology & epidemiology

The causal organism of UE is *Clostridium colinum*, an anaerobic spore-forming bacterium with fastidious *in vitro* growth requirements. Waterfowl do not seem to be affected. *C. colinum* is ubiquitous in nature and excreted in large numbers in the faeces of affected birds. The spores result in permanent contamination of premises after an outbreak has occurred. Chronic carriers have been considered to be one of the most important factors in perpetuation of UE. Influencing factors like coccidiosis, immunosuppressive diseases, overcrowding, inadequate hygiene or other stress conditions can play an important part in the production of disease.

Clinical signs & lesions

In acute disease, there is an increasing mortality without premonitory signs. Mortality in young quail may be as high as 100%. Chicken losses typically range from 2-10%. Birds are in good condition, with feed in the crop. As UE progresses, signs include depression, huddling with ruffled feathers, anorexia (leading to emaciation after one week) and watery droppings.

The most important lesions are found in the intestine, liver and spleen. There are deep ulcers affecting small intestine, ceca and upper large intestine.

The ulcers may become perforated and result in peritonitis. Liver lesions vary from light yellow mottling to large, irregular yellow areas along the edges. Spleen is often enlarged and hemorrhagic.

Diagnosis

Diagnosis of UE can be made on the basis of gross postmortem lesions (typical intestinal ulcerations and liver lesions). As an aid to the diagnosis, slide smears of necrotic liver tissue may be Gram-stained for observation of large, Gram-positive rods with subterminal spores.

Differential diagnosis includes necrotic enteritis, coccidiosis and histomoniasis.

Treatment & control

Because the infectious organism is in the droppings and remains viable indefinitely in litter, it is recommended to remove it and use clean litter for each brood. Keeping chickens on wire floors has been reported to be preventive. Outbreaks can be treated with different antibiotics (penicillins, streptomycin, chlortetracycline, tylosin, *etc.*) added to the drinking water or feed.

GANGRENOUS DERMATITIS, CLOSTRIDIAL DERMATITIS OF TURKEYS

Gangrenous dermatitis (GD) is a peracute, fatal bacterial disease primarily affecting young rapidly growing chickens, and characterized by sudden onset, high mortality, and swollen, red, weeping skin lesions. Clostridial dermatitis of turkeys (CDT) is a much more recent clinical problem similar to GD and sharing largely the same etiology. It

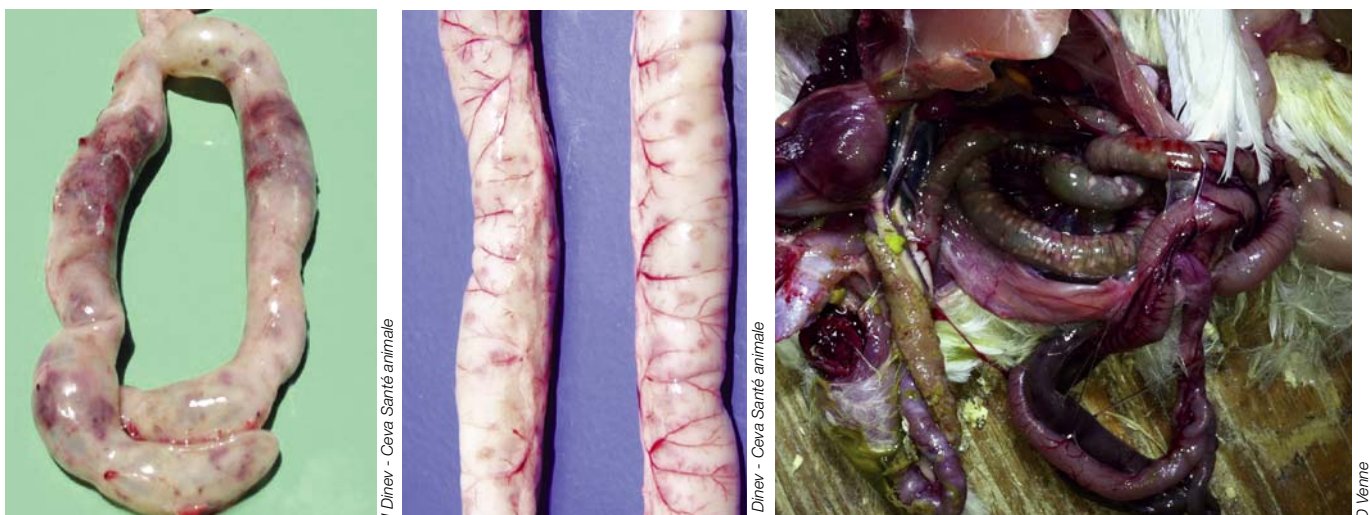
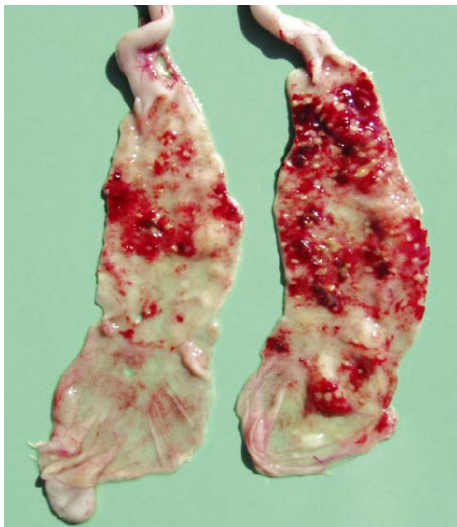
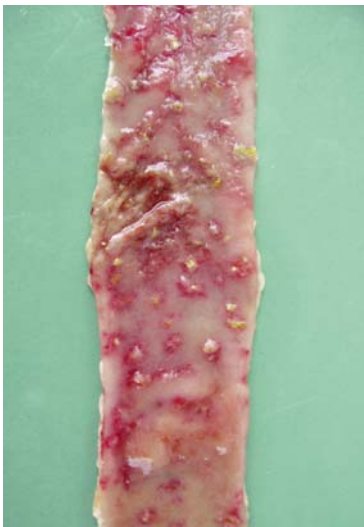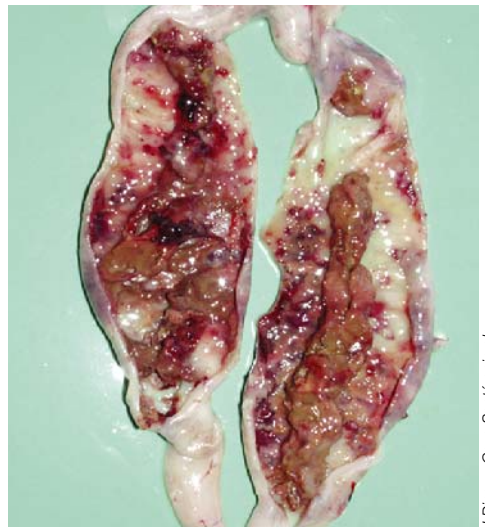
Fig.51.22, 51.23 & 51.24: Ulcerative enteritis. Deep button-like ulcers are observed, mainly in ceca and less frequently in some parts of small intestine, usually visible through the wall.



I Dinev - Ceva Santé animale

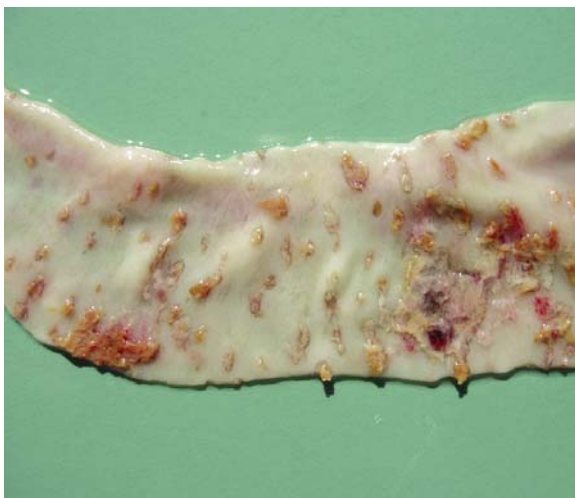

I Dinev - Ceva Santé animale

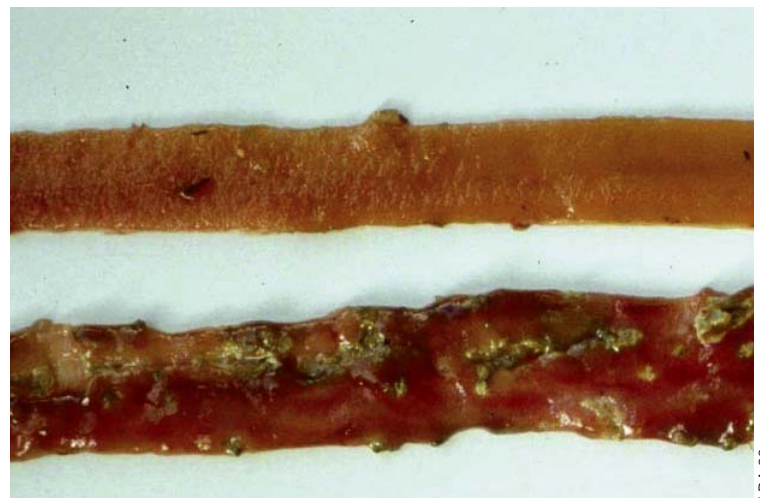

I Dinev - Ceva Santé animale

Fig.51.25, 51.26 & 51.27: Ulcerative enteritis. The early lesions appear like yellow foci with hemorrhagic boundaries that could be seen from both the serous and the mucosal surfaces. The intestinal content is often mixed with blood.

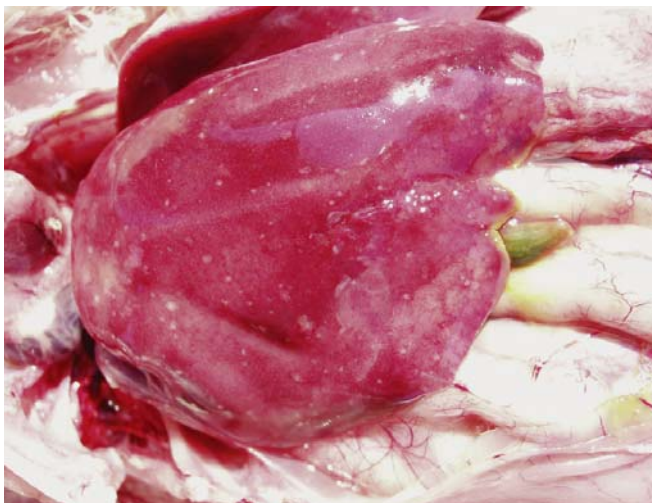

I Dinev - Ceva Santé animale

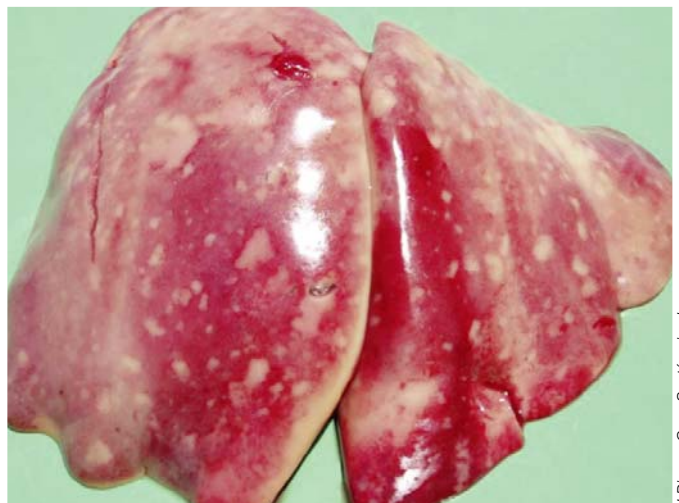

LDA 22

Fig.51.28 & 51.29: Ulcerative enteritis. In older and large ulcers, the hemorrhagic zones tend to disappear. The ulcers could have an irregular round or an elongated shape and are covered by large necrotic diphteric membranes. Compare with the normal intestine at the top in the Fig.51.29.

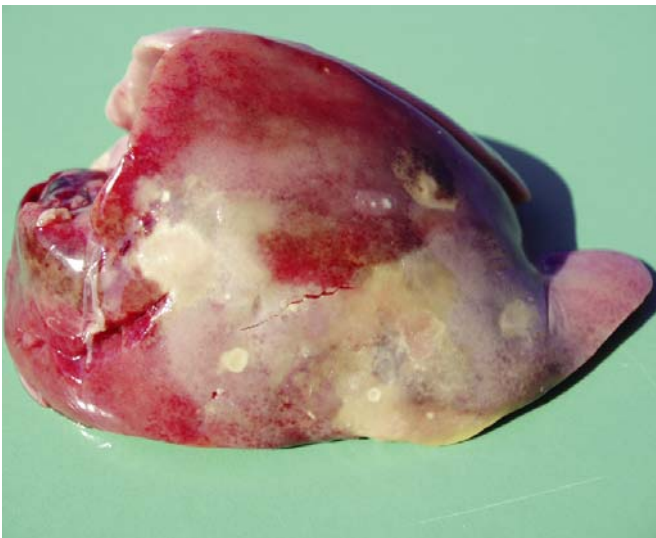


I Dinev - Ceva Santé animale

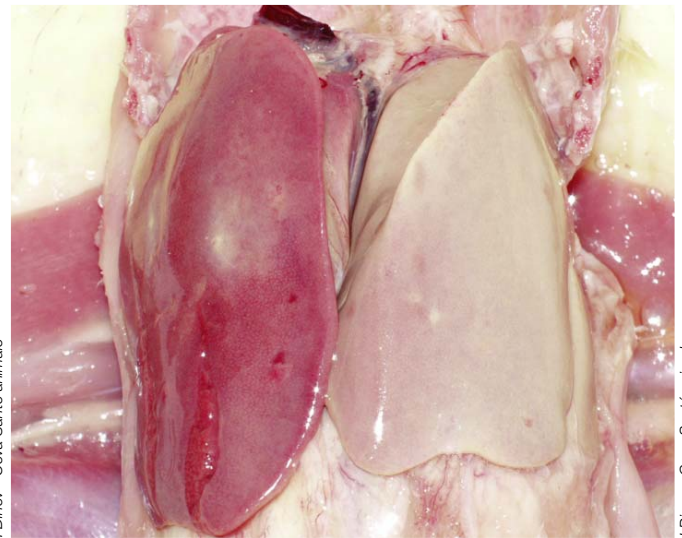


I Dinev - Ceva Santé animale

Fig.51.30 & 51.31: Ulcerative enteritis. Liver presents a variety of dystrophic changes and necroses (miliary necrotic foci, liver necroses reaching 1-2 cm surrounded by a hemorrhagic zone or involving a large part of the liver).



I Dinev - Ceva Santé animale



I Dinev - Ceva Santé animale

Fig.51.32 & 51.33: Ulcerative enteritis. Liver presents a variety of dystrophic changes and necroses. Most commonly, necroses are distinguished on the background of a marked parenchymatous dystrophy, affecting partially or totally (uni- or bilaterally) the liver.

affects turkeys as young as 7 weeks of age, but most are at the end of production age (16 to 18 weeks).

Etiology & epidemiology

The agents of GD include *Clostridium septicum*, *C. perfringens* Type A, *C. sordellii* (for CDT) *Staphylococcus aureus*, and possibly *Escherichia coli*. These agents are commonly found on the skin, in the intestines, and in the environment of normal birds, so the disease is not contagious *per se*, and other predisposing or contributing factors are usually involved. In most cases, outbreaks of GD involve 3 interacting factors: immune suppression, scratches or wounds, and the presence of sufficient numbers of the causative bacteria. While most common in broiler chickens from 28 days to market age, the condition occurs in layers, breeders, range turkeys, and turkey breeders. Morbidity and mortality can be quite high. In turkeys, affected birds used to be at least 12 weeks old; but age predisposition has been changing quickly over the past few years, at the same time that the severity of the condition has been increasing. Cases have been reported in 7 week-old birds. In turkeys, skin scratches may play a minor role. Research suggests that CDT could come from a systemic infection *via* the gastro-intestinal tract. An association has been reported between higher stocking density and CDT.

Clinical signs & lesions

The first sign is often a sudden, sharp increase in mortality. Because affected birds die so rapidly, it sometimes can be difficult to find live, affected

birds. Such birds are febrile and severely depressed, often to the point of appearing sleepy or unresponsive. Those that can be stimulated to rise may appear lame, weak, or uncoordinated. The typical lesion is an area of swollen, thickened, soft, dark reddish-purple, moist, weeping skin that frequently crackles with gas bubbles when gently pressed. The superficial layers of skin will rub off easily, leaving a moist, shiny, slick surface. The feathers may be missing from the affected area, or else they can be plucked easily. When the affected skin is reflected, there is often extensive clear golden to reddish gelatinous fluid, sometimes containing gas bubbles. The underlying muscles may have a gray or tan cooked appearance, and may contain numerous petechial hemorrhages, fluid between muscle bundles, and gas.

Birds that die from GD or CDT seem to decompose rapidly, and care is needed to avoid confusion of normal signs of postmortem decomposition with those of these conditions. In turkeys, the gelatinous accumulation often can be seen along the thighs and breast; and the skin does not always appear to be affected. Dead birds may also be found with “bubbly tails”, fluid filled blisters associated with broken tail feather follicles.

Diagnosis

The lesions are fairly diagnostic. It is important to identify and address the associated issues of immune suppression, scratches, and sanitation. Differential diagnoses include fungal dermatitis, contact dermatitis from wet litter, and photosensitization.

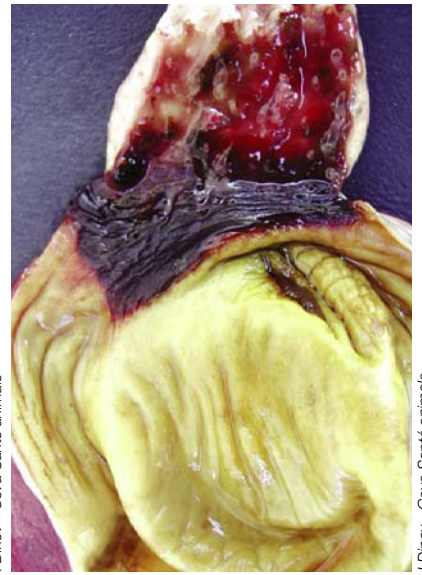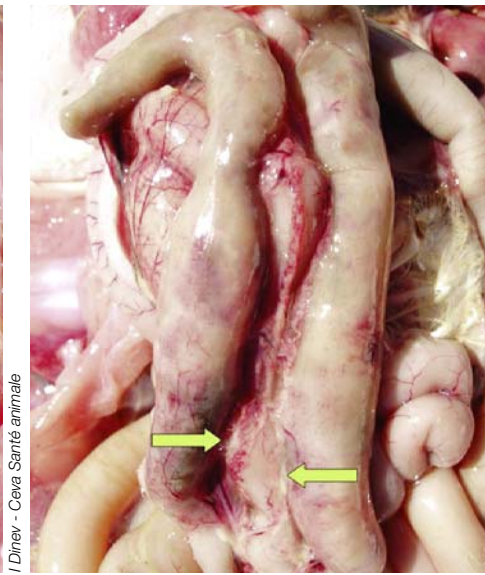
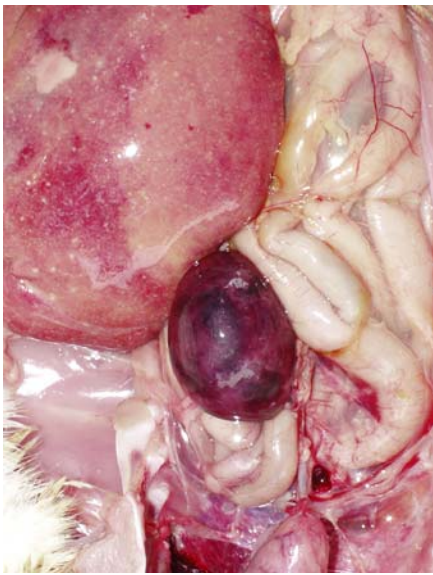


Fig.51.34: Ulcerative enteritis. The spleen could be enlarged, hemorrhagic and, sometimes, with necrose.

Fig.51.35: Ulcerative enteritis. Frequently, adhesive peritonitis due to inflammatory involvement of adjacent serous coats is observed.

Fig.51.36: Ulcerative enteritis. In some cases, hemorrhages with various intensities are detected in the mucous coat of the gizzard.

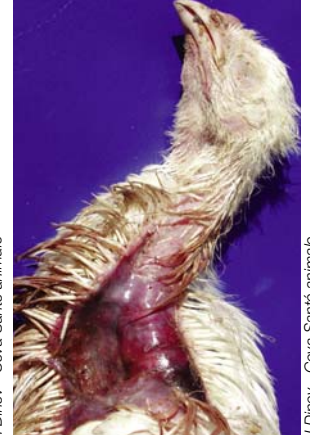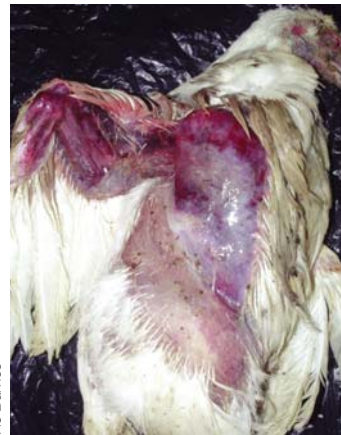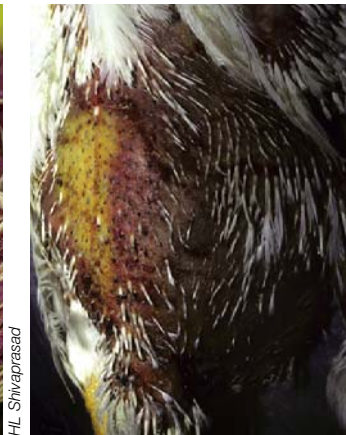
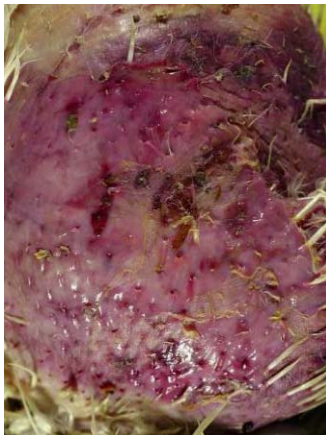


Fig.51.37 & 51.38: Gangrenous dermatitis (Chicken). Necrosis of different skin areas and severe cellulitis of the subcutaneous tissue, with feather loss in affected areas.

Fig.51.39 & 51.40: Gangrenous dermatitis (Chicken). The skin lesions involve the skin of the head, neck and breast, but also of the back and wings. These skin lesions are often crepitating.

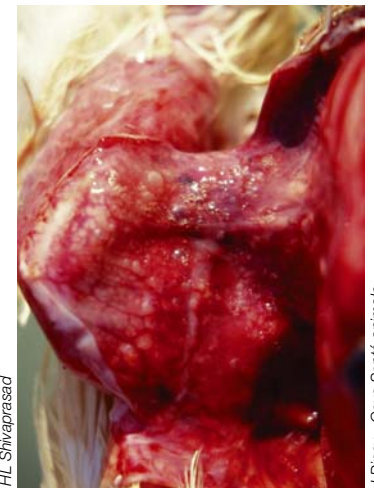
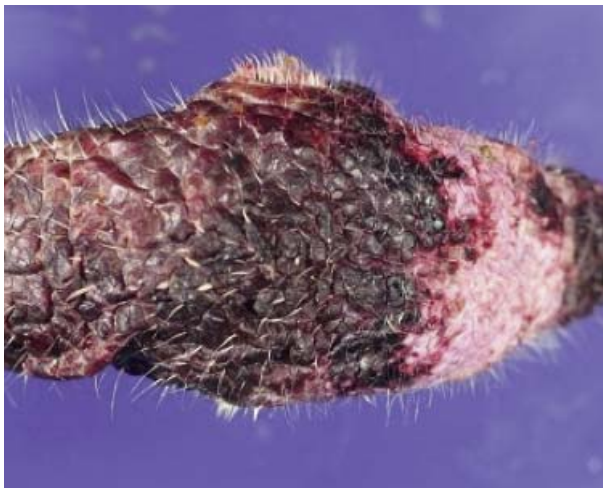

Fig.51.41 & 51.42: Gangrenous dermatitis (Turkey). Necrosis and hemorrhage of the skin of the head. The skin of the wing presents a blue green color.

Fig.51.43: Gangrenous dermatitis (Chicken). Under the affected skin, extensive hemorrhagic edemas with or without gas (emphysema) are discovered.

Treatment & control

Gangrenous dermatitis usually responds dramatically to treatment in feed or water with tetracyclines, erythromycin, penicillin, or lincomycin. Control measures involve controlling the ancillary factors and agents. Careful evaluation should be made of contributing factors such as immunosuppressive diseases (assess flock status and vaccination programs for Infectious Bursal Disease in chickens and hemorrhagic enteritis in turkeys; other agents may also be considered depending on the region), poor feathering, nutritional deficiencies, increased skin fragility, nervousness, cannibalism, scratches and wounds, excessive density, increased microbial challenge (filth), and the management faults that contribute to these conditions. Other strategies include using high levels of growth-promoting antibiotics with recognized efficacy against clostridia, such as bacitracin, lincomycin, tylosin, or virginiamycin. Increased levels of zinc, vitamin E, and selenium, either *via* the feed or water, may improve skin integrity and immune responses. Dead bird collection and disposal are critical. When a problem arises, dead birds must be collected at least twice daily. Pest control is paramount because insects and their larval stages are known carriers of clostridia.

It makes sense to focus on litter conditions that are detrimental to these pathogens (i.e., normal pH since alkaline pH favors spore production; low moisture because spores live longer in damp conditions). The addition of salt or acids such as sodium bisulfite to the litter has been advocated. Recommended application rates are 25 kg per 100m² for salt, 33 kg/m² for sodium sulfate (Glauber's salt), and 25 kg per 100 m² for sodium bisulfite. Increasing the time between flocks on a farm will reduce the challenge from many of the ancillary pathogens. Cleaning out the litter will physically remove large numbers of clostridial spores. Before starting the next flock, it will be beneficial to wash the barn well with a detergent and disinfect. Some disinfectants are known to be sporicidal (glutaraldehyde, peracetic acid, oxyhalogen). It may be useful to also inoculate a clean litter with commercial "litter cultures", such as *Lactobacillus* cultures that may displace *Clostridia*.

Recent field experiences in the U.S. suggest that broiler flocks in which coccidiosis vaccines are used for coccidiosis control (as opposed to coccidiostat drug programs), while possibly more susceptible to NE, appear to be highly refractory to

GD. While less consistent, flocks on chemical coccidiostats or on ionophore starter-chemical grower shuttle programs also appear to be less susceptible to GD than those on straight ionophore or chemical starter-ionophore grower programs.

BOTULISM (see also Chap.III.52)

Botulism is caused by an exotoxin of *Clostridium botulinum*, producing a progressive paralysis. Synonyms include limberneck and Western duck sickness.

Etiology & epidemiology

Clostridium botulinum is a gram-positive, anaerobic, spore-forming rod. Most outbreaks in birds are due to type C, although other types have been reported (A, C, D and E). *C. botulinum* type C produces the neurotoxin C1 and the enterotoxin C2. The emergence of bacteria from spores is favored by heat and humidity. The organism is commonly found in the gastrointestinal tract of wild and domestic birds. Botulism can be caused by ingestion of preformed toxin. Since the organism is found in the gut of birds, it may proliferate in dead birds. Other birds that cannibalize these carcasses or that eat the maggots feeding on such carcasses may become intoxicated. Small crustaceans and insect larvae in lakes may contain the organism. If these creatures are killed en masse by events such as algae blooms or oxygen deprivation, botulinum toxin may be produced and poison birds eating the dead crustaceans and larvae. Toxin may be produced in rotting vegetation along shorelines. In many cases, especially in commercial broilers, no source of preformed toxin is evident. It is theorized that these cases result from "toxico-infection", in which the resident *C. botulinum* in the gut proliferates and elaborates toxin *in situ*, secondary to gut damage from some other source. Excessive iron in the feed or water was suspected as the inciting factor in one case.

Litter and feces from infected flocks represent a potential source of infection for other domestic and wild birds and mammals. This is illustrated by the cases of botulism in cattle linked to contaminated poultry litter on pastures or in cattle feed. The sensitivity of birds to these toxi-infections is variable. For example, vultures are resistant.

Clinical signs & lesions

A flaccid paralysis begins in the legs and progresses cranially to the wings, neck, and eyelids.

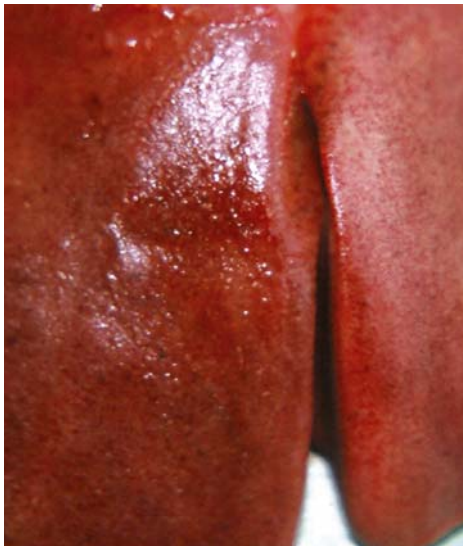

Fig.51.44: Gangrenous dermatitis (Chicken). In most cases, no changes in viscera are observed. Rarely gas bubbles (this figure) or necroses are seen in the liver.

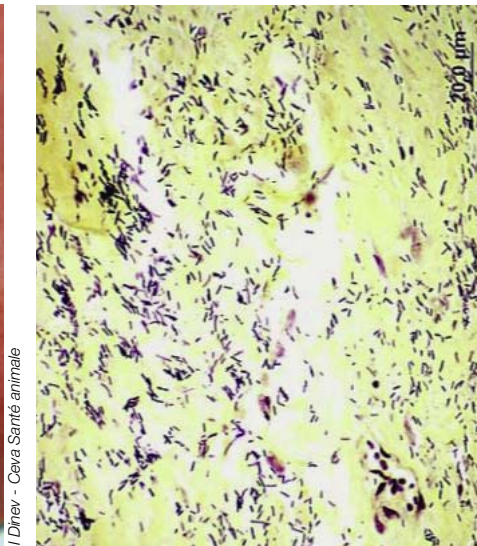


Fig.51.45: Gangrenous dermatitis (Chicken). Large number of Clostridium perfringens are shown in this Gram stain.

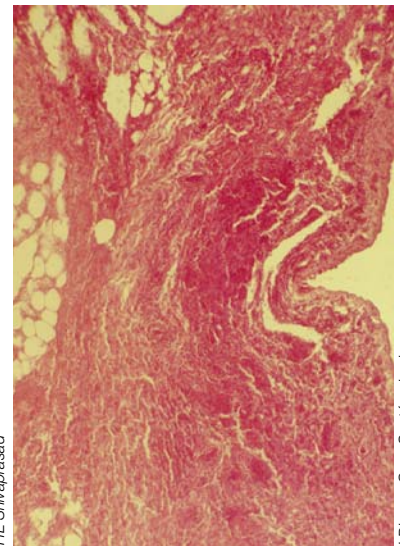


Fig.51.46: Gangrenous dermatitis (Chicken). Microscopic lesions are characterized by edema, emphysema, hyperemia, hemorrhages and necroses.



B Robineau



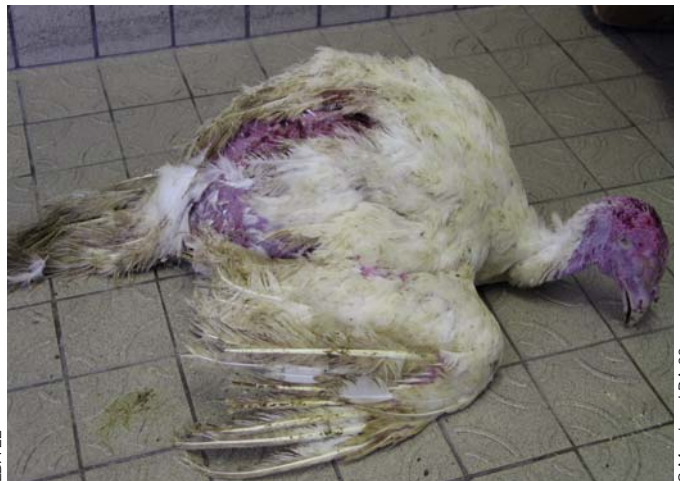LDA 22

Fig.51.47 & 51.48: Botulism. Flaccid paralysis of legs, wings, necks and eyelids is observed. The paresis is rapidly progressing to paralysis. The birds may drop their head on the floor using the beak as support, or they may lie down with the extended and paralysed neck on the floor.



LDA 22

Fig.51.49: Botulism. Flaccid paralysis of legs, wings, necks and eyelids.



S Maeder - LDA 22

Fig.51.50: Botulism (Turkey). Bruised and reddish skin caused by feather picking may be seen, as well as trauma caused by other birds trampling on recumbent individuals.

Initially, the birds appear reluctant to walk, and when forced to rise appear lame or ataxic. Next the wings droop, and finally the “limber neck” becomes evident and the eyelids droop. Fine tremors may be noted, the hackles may be raised, and the feathers are easily plucked in chickens. Death is due to respiratory and cardiac failure. There are no gross or histological lesions, other than dehydration.

Diagnosis

The signs and lack of lesions suggest the diagnosis. Eyelid paralysis is a key sign differentiating botulism from other conditions. The early stages of the disease (or the mild form of disease) should be differentiated from Marek’s disease, ionophore toxicosis, and lead poisoning.

Treatment & control

Valuable individuals can be treated with antiserum, laxatives (to remove residual toxin), antibiotics, and supportive therapy (fluids and alimentation). Commercial birds may be treated with sodium selenite, fat-soluble vitamins (A, D, and E), and antibiotics effective against clostridia (bacitracin, streptomycin, tetracyclines, penicillin, lincomycin, tylosin).

Flocks also can be given Epsom salts in a wet mash (0.5 kg per 75-100 birds) or in the water, as a laxative. Acidifying the water is also recommended. Citric acid (1.5 kg per 1500 l of drinking water) will both acidify the water and chelate iron.

Control involves preventing access to the toxin. Good sanitation, frequent removal of mortalities, insect control, and denial of access to shallow or

stagnant water are important. In affected confinement facilities, removal of all litter (and sometimes several inches of dirt), disinfection, addition of clean, deep litter, acidification of the litter, insecticide treatment, and prophylactic antibiotic treatment of subsequent flocks are recommended.

REFERENCES

- Cervantes H. Managing Gangrenous Dermatitis. *Poultry Digest*, 1999, 57: 20-24.
- Clark, S, Porter, R, et al. Clostridial Dermatitis and Cellulitis: An Emerging Disease of Turkeys. *Avian Dis*, 2010, 54:788-794
- Dinev I. *Diseases of Poultry. A colour Atlas*. Ed. CEVA Santé Animale 2007.
- Hutchinson TWS & Riddell C. A study of hepatic lesions in broiler chickens at processing plants in Saskatchewan. *Can Vet J*, 1990, 31: 20-25.
- Kaldhusdal M et al. Inclusion and avoparcin supplementation in broiler diets. 2. Clinical, pathological, and bacteriological findings in a mild form of necrotic enteritis. *Poult Sci*, 1992, 71: 1145-1153.
- Kaldhusdal M. & Jordan FTW. Clostridia. In *Poultry diseases*, Pattison M et al Ed., Elsevier, Edinburgh 2008, p 200-214.
- Pecelunas KS et al. Botulism in chickens associated with elevated iron levels. *Avian Dis*, 1999, 43: 783-787.
- Saif YM (ed.). *Diseases of Poultry*, 12th Edition, Blackwell Publishing, Iowa, IA, 2008, p. 865-889: Barnes HJ. Clostridial diseases (p. 865-866), Wages DP. Ulcerative Enteritis (Quail Disease) (p. 867-871), Opengart K. Necrotic Enteritis (p. 872-879), Dohms JE. Botulism (p.879-885), Opengart K. Gangrenous Dermatitis (p. 885-889).

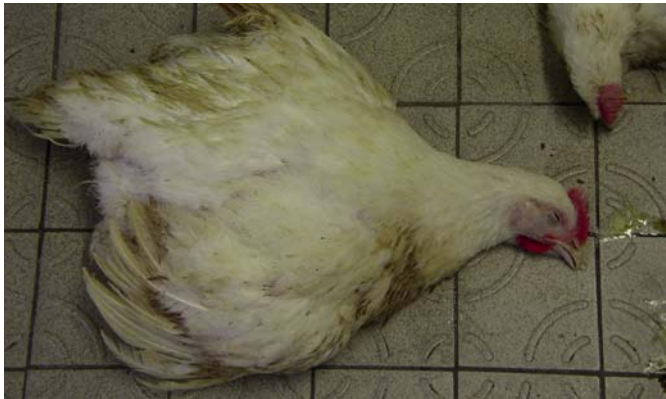

LBAA



LBAA

Fig.52.1 & 52.2: Botulism. The mortality rate can reach 100% in turkey flocks.



S Maeder - LDA 22



La Chesnaie des Fontaines



JY Ferré



JY Ferré

Fig.52.3, 52.4, 52.5 & 52.6: Botulism. Many species may be affected: chickens, pheasants, guinea fowl, ducks, etc. Ascending flaccid paralysis of legs, wings, necks and eyelids is observed: birds are lying, squatting, wings drooping, spread on the ground, unable to move, lack of coordination, ataxia and sternal recumbency.



JY Ferré



D Venne

Fig.52.7 & 52.8: Botulism. Birds may exhibit signs of nervousness with ruffled feathers and sometimes diarrhea.

Bacterial diseases

52. LABORATORY DIAGNOSIS OF BOTULISM

INTRODUCTION

Botulism is a neurological disorder caused by the neurotoxin that is produced by *Clostridium botulinum*, and that results in an ascending paralysis of the limbs and neck. The sensitivity of birds to the neurotoxin varies amongst species. The pheasant is more sensitive to toxin type C than the turkey and the chicken, while the vulture is very resistant. Chickens are highly resistant to the toxin type D and may be asymptomatic carriers. Botulism has affected poultry and waterfowl worldwide with greater severity during wet and warmer months. The disease is relatively rare in domestic poultry that are kept under good conditions.

DIAGNOSIS

Clinical diagnosis

Botulism is suspected based on clinical signs such as flaccid paralysis of the legs, wings, neck and eyelids, and in cases of an important increase in mortality without macroscopic lesions (up to 100% mortality can be observed in turkeys). Risk factors include a previous episode of botulism within the flock, inadequate flock sanitation (infrequent collection of cadavers, presence of insects, inadequate downtime and disinfection, inadequate storage of dead birds), periods of hot and stormy weather, or a nearby body of water in the case of free-range poultry.

It is important to include in the differential diagnosis other diseases characterized by an abnormal increase of the mortality rate of wild birds, such as cases of highly pathogenic avian influenza (fowl plague), or other diseases causing paralysis (Marek's disease, ionophore toxicosis, lead or alphachloralose poisoning). In milder forms related to the ingestion of a small amount of toxin, the differential diagnosis includes locomotor disorders.

In some countries, the health authorities must be notified of a case of botulism. This is the case in France since 2006.

Laboratory techniques for the diagnosis of botulism

A definitive diagnosis is reached by detection and typing of the toxin in the serum, the liver or the intestinal content from diseased birds. The body temperature of birds is ideal for the growth of *C. botulinum* type C and D, as well as maintaining the stability of their toxins C and D in the ceca.

Bacteriological diagnosis

Bacteriological diagnosis has no diagnostic value because the presence of the bacteria alone does not offer evidence of the presence of a toxin. *Clostridium botulinum* is a common bacteria of the host intestinal flora of the digestive tract of birds.

Detection of botulinum toxin

The detection of the toxin within tissues of dead birds does not confirm a diagnosis of botulism. *Clostridium botulinum* is found in the gut of normal chickens and the toxin can be produced in decaying body tissues. When worms consume a decaying carcass, they accumulate the toxin and can then be the source of intoxication of their predators (pheasants for example). One gram of maggots can contain 180 000 DL50. Pheasants will die after ingesting 8 or more maggots. The neurotoxins of *C. botulinum* is one of the most dangerous substances. The minimal lethal dose for a guinea pig is 0.00012 mg/kg via subcutaneous administration.

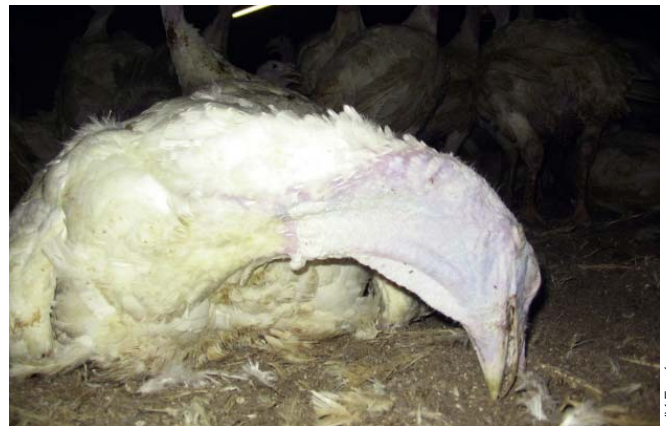To detect and recognize the toxin, it is important that the samples (serum, liver or cecal contents) are taken from recently diseased bird (<48 h).

Mouse lethality assay

The mouse lethality assay is a sensitive and reliable method that is still often used to confirm a heat-labile toxin, however it does not allow for the identification of the type of toxin involved. Intraperitoneal injection of serum or intestinal contents in mice causes paralysis and death of the animal within 1-2 days if the toxin is present.



JY Ferré



JY Ferré

Fig.52.9 & 52.10: Botulism. Evolution towards a weak flaccid neck; the beak is in the litter. This clinical sign is not consistent: some birds die without paralysis of the neck.



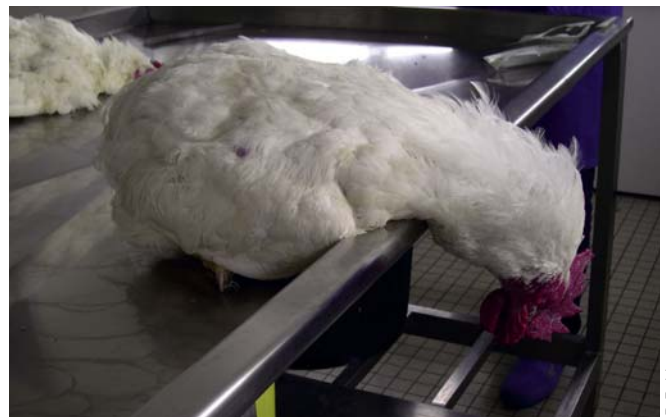JY Ferré



JY Ferré

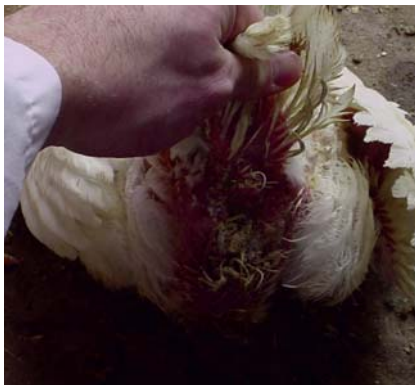

D Venne



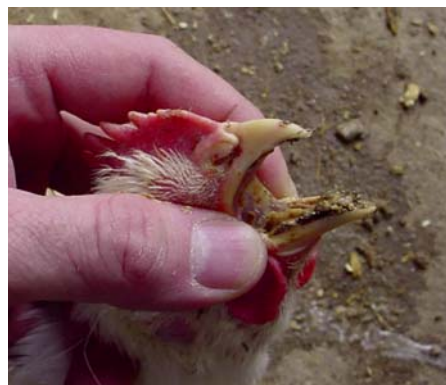B Robineau

Fig.52.11, 52.12, 52.13 & 52.14: Botulism. Drooping or closed eyelids give the birds a comatose or drowsy look, or they even appear dead while they are still alive. Paralysis of the eyelid is a key element in the differential diagnosis with other diseases.




D Venne

Fig.52.15: Botulism. Urate crystals can be seen on pasty vent



D Venne

Fig.52.16: Botulism. Litter consumption by affected bird.



D Venne

Fig.52.17: Botulism. Presence of maggots on dead chickens.

Toxinotyping of C. botulinum by seroneutralization

This technique, also called «mouse protection test» takes place in the same way as the mouse lethality assay, with the advantage of determining via the serum or intestinal contents the type of toxin involved. The typing is determined with the help of type-specific antiserum (sero-protection). Only the mice that receive samples inoculated with anti-toxin specific for the botulinum toxin involved will survive. This test is expensive and can only be performed in a reference laboratory that possesses the specific antisera.

PCR «Polymerase Chain Reaction»

The identification of the gene of the neurotoxin of *C. botulinum* found in the samples taken from the intestinal content is generally done by PCR in parallel with the mouse lethality assay.

Interpretation (in association with clinical signs)

The major problem with the laboratory diagnosis is that it results in a large number of false negatives. In fact, the quantity of botulinum toxin present is often lower than the detection threshold and the disease often results from the cumulative effect of very small doses of toxin over several days.

The interpretation of the tests is as follows:

- If the mice die and the PCR is positive, this means that there is presence of the toxin (specific type can be identified with the PCR).
- If the mice do not die and the PCR is negative, it strongly implies the absence of the botulinum toxin. However, if symptoms persist within the flock, it is recommended to conduct further analyses.
- If the mice remain alive, but the PCR is positive, it suggests the presence of the gene enabling the production of the botulinum toxin.
- If some of the mice die and the PCR is negative, the samples should be sent to a reference laboratory for carrying out the seroneutralization test or sampling of the affected flock should be done again.

However, in practice, the cost of analysis or the type of samples to be taken may limit the completion of the full range of recommended tests.

REFERENCES

- Dohms J.E. Botulism. In “*Diseases of Poultry*”, Ed. Saif YM, 12th Ed, Blackwell Publishing, Iowa, IA, 2008, p. 879-885.
- Kaldhusdal M. & Jordan FTW. Clostridia. In *Poultry diseases*, Pattison M et al Ed., Elsevier, Edinburgh 2008, p 200-214.

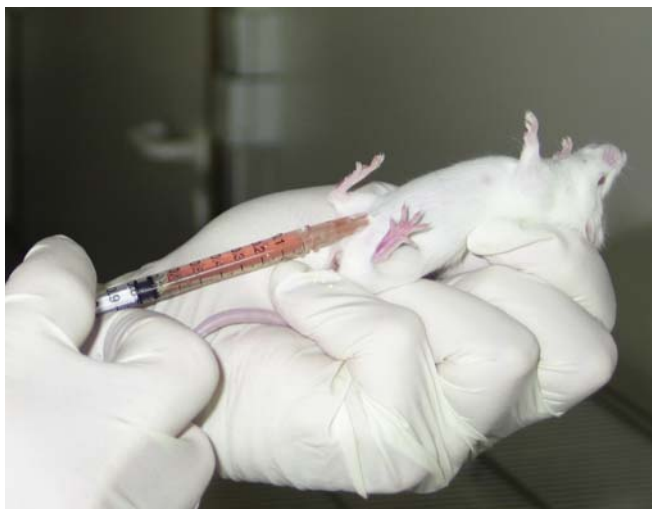

Fig.52.18: Botulism. The mouse lethality assay is the technique most often used. The sample (liver or cecal content) is ground, homogenized, centrifuged, diluted and filtered. After filtration, it is inoculated intraperitoneally into mice. For blood, serum obtained following centrifugation of the tubes is injected into mice.



Fig.52.19: Botulism. It is important to apply biosecurity measures, particularly by removing and eliminating the litter to aid in the control of the disease.

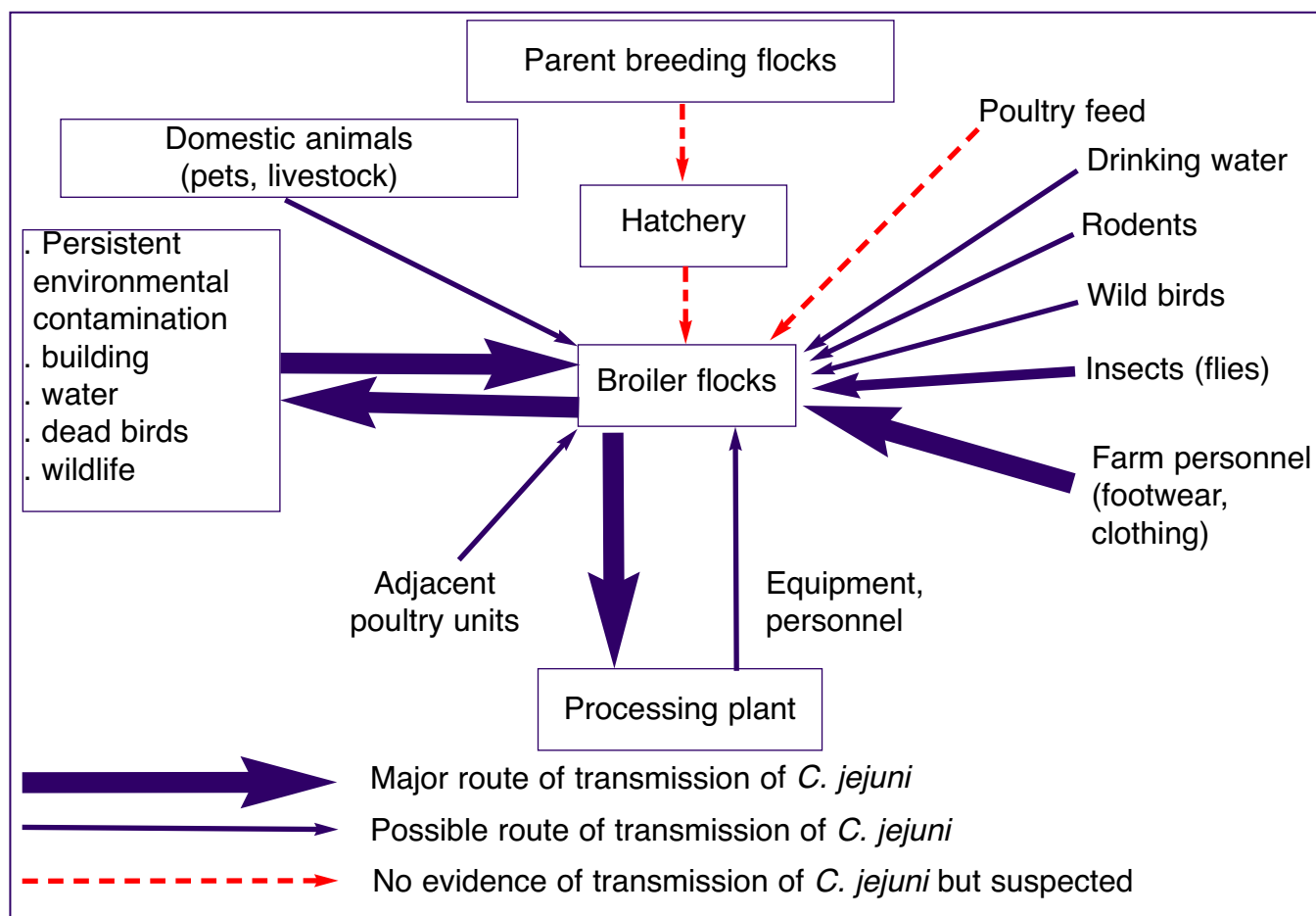


Fig.53.1: Routes of transmission of *Campylobacter jejuni* in broiler flocks (Modified from Evans & Powell, 2008)

Treatment	Average Body Weight (grams)		
	0 days PI	10 days PI	21 days PI
Control BHI 2 days of age	64.5	127.6	255.9
<i>C. jejuni</i> 5×10^7 CFU/ poult (2 days of age)	61.0	109.2	211.8
Control BHI 4 days of age	90.6	131.2	306.3
<i>C. jejuni</i> 5×10^6 CFU/ poult (4 days of age)	89.7	126.7	251.3

Table.53.1: Body weights of poult inoculated with *Campylobacter jejuni* by the oral route (Lam KM et al, 1992). This study compares turkeys and chickens inoculated at 2 days of age or 4 days of age with *C. jejuni*. The chickens exhibited no signs of intestinal disturbance and no differences in weight gain. The turkey poult exhibited foamy excretions for 3-5 days and gained significantly less weight than the sham inoculated birds (*Campylobacter* depressed weight gain by 20% when inoculated to newly hatched poult or 4-day-old poult). The poult inoculated at 2 days of age gained less weight than those inoculated at 4 days of age suggesting that age of infection affects the severity of clinical signs in turkey poult.

BHI : Brain-heart infusion medium; CFU : colony-forming units; PI : post inoculation.

Bacterial diseases

53. CAMPYLOBACTER SPP.

INTRODUCTION

The interest in *Campylobacter* spp. in poultry has historically been focused on its zoonotic potential. Public health agencies have been monitoring *Campylobacter* spp. in the human population and have had an active surveillance system in place since 1982. *Campylobacter* spp. are the most common cause of acute bacterial gastroenteritis in industrialized countries. Although rarely fatal, *Campylobacter* infections cause considerable illness and loss of productivity and may be associated with severe disabling consequences, including arthritis and demyelinating disease (Guillain-Barré syndrome). While contaminated poultry is only one of many sources of human infection with *Campylobacter* spp., the Centers for Disease Control and Prevention estimates that 50-70% of human cases in the United States are associated with mishandling of poultry products. In addition the potential for *Campylobacter* spp. to develop resistance to antibiotics has become a concern to the public health community.

Campylobacter spp. are known to infect most poultry flocks in the United States and other countries as evidenced by sampling on farm and on carcasses at processing. Prevalence of *Campylobacter* spp. is comparable in both organically grown and commercially grown poultry. Even so there is little evidence that *Campylobacter* spp. cause disease in poultry. The pathology of *Campylobacter* is not well defined as the perceived cost to the industry is minimal. Recent evidence of potential pathologic disease in turkey poults (unpublished data) associated with *Campylobacter* spp. is reason to investigate the contribution of *Campylobacter* to clinical disease in poults.

ETIOLOGY & EPIDEMIOLOGY

Campylobacter infections in poultry flocks are generally caused by *C. jejuni* or *C. coli*. These organisms are Gram-negative, motile, slender spiral rods that are microaerophilic, thermophilic, and do not survive well outside of the host. Like other motile organisms *Campylobacter* spp. spread efficiently through a population of birds. Because birds have a higher body temperature than mammals they serve as a preferred host for

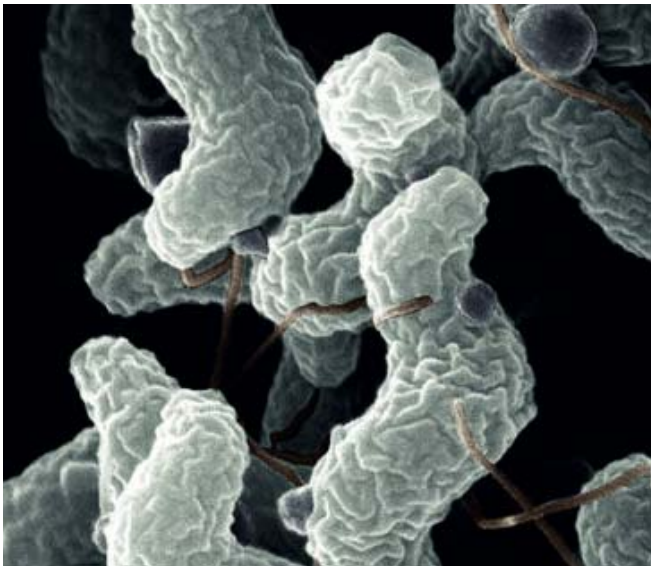
thermophilic *Campylobacter* spp. *Campylobacter* spp. are shed in the feces of infected birds and the organisms spread by the fecal oral route. Floor-raised birds are quite efficient at moving *Campylobacter* throughout a flock. Poultry do not typically shed *Campylobacter* during the first 2-3 weeks of life however, once shedding is confirmed it takes only 2-4 days to detect *Campylobacter* shed in 90-100% of sampled birds. This phenomenon occurs worldwide where poultry are produced.

Because of the fastidious nature of *Campylobacter* spp. the organisms cycling through a flock likely die out if left in the house when the birds go to market. Drying of the litter, the oxygen levels in the air, and the lack of a host render a hostile environment non conducive to survival of *Campylobacter* spp. How the organisms re-establish themselves is not clear. There is evidence that birds arrive on the farm with a few birds incubating the organisms obtained either via vertical transmission, from the hatchery or via a mechanical vector. Birds do not typically shed *Campylobacter* at detectable levels during the first few weeks of life. There is evidence that maternal antibodies are present which protect the young birds from infection. As maternal antibodies wane the birds become susceptible to colonization and begin to shed the organisms. *Campylobacter* has also been isolated from pigeons, game birds, and marine birds which though less likely to be a source of farm contamination should be prevented access to commercial birds.

CLINICAL SIGNS & LESIONS

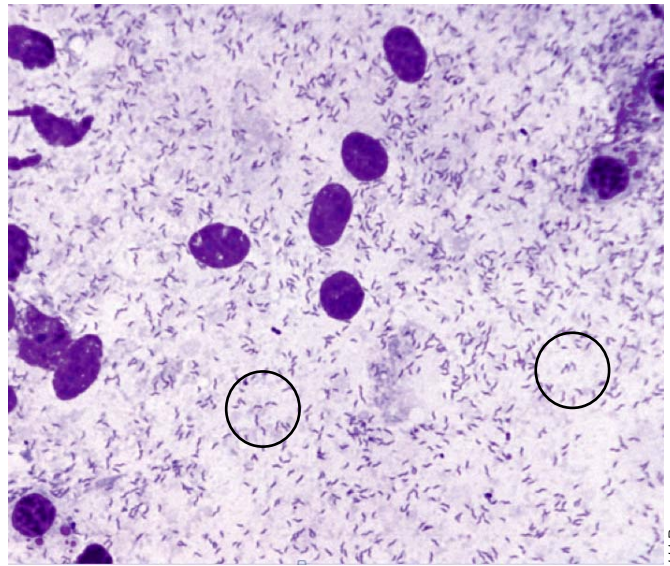
Clinical signs of infection with *Campylobacter* species range from no clinical signs to severe diarrhea and death. This range in clinical signs is related to the strain of the organism, the infective dose and the age of the bird at the time of infection. Additionally, the species of the host may play a role in the pathogenesis of *Campylobacter* infection, with evidence that turkey poults exhibit more severe clinical signs than do chicks (see Tabl.53.1).

The gross lesions seen with *Campylobacter* range from no lesions to distension of the intestinal tract, watery fluid in the intestine, and even hemorrhages in cases of infection with cytotoxic




De Wood - digital colorization by Chris Pooley - USDA

Fig.53.2: This scanning electron microscope image shows the characteristic spiral, or corkscrew, shape of *C. jejuni* cells and related structures.



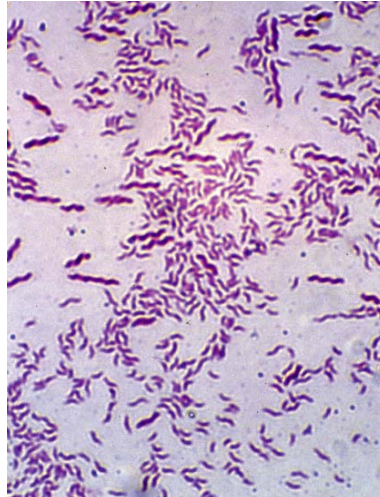
HJ Barnes

Fig.53.3: Small "gull-wing" *Campylobacter* organisms in intestinal contents.



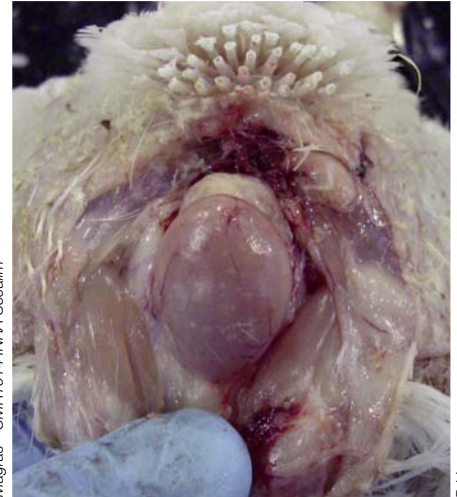
Magras - UMR1014 INRA Secalim

Fig.53.4: Typical colony morphology of *Campylobacter* thermotolerant (*C. jejuni*, *C. coli* indiscriminately). Karmali agar - 36h incubation at 42°C in microaerophilic atmosphere.



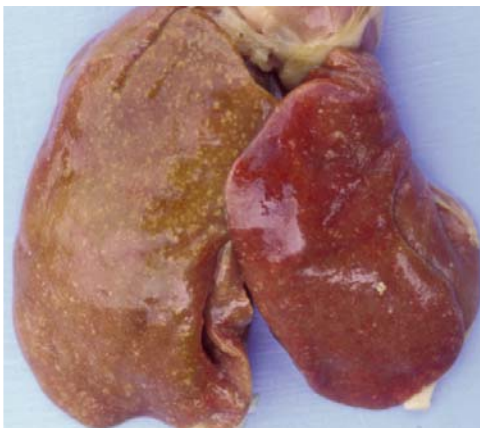
Magras - UMR1014 INRA Secalim

Fig.53.5: Typical morphological appearance (more or less spiral-shaped comma) of vegetative cells of *Campylobacter coli* (the appearance is identical to *C. jejuni*) after Gram staining (x100).

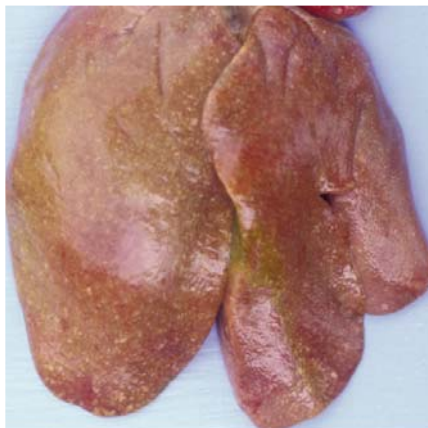

D Venne

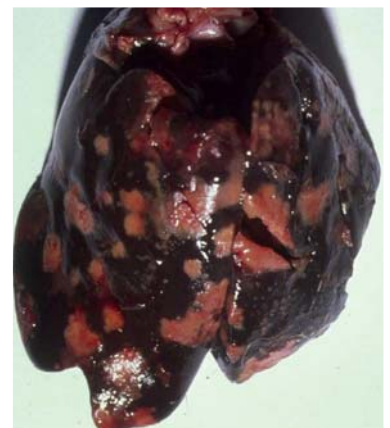Fig.53.6: Campylobacteriosis. Bursa of Fabricius with necrotic granulomas.



Y Robinson



Y Robinson



LDA 22

Fig.53.7, 53.8 & 53.9: Vibronic hepatitis (Fowl). This syndrome was attributed to a vibrio-like organism. The hepatic lesions were often distinct in appearance as stellate, asterisk-shaped, cauliflower-like or focal hepatitis necrosis with fairly large diffuse affected areas. *C. jejuni* is associated with, but not sufficient to cause, vibronic hepatitis in chickens. A predisposing factor, possibly within the host is required.

Campylobacter. Lesions outside of the intestine can occur with a mottled liver and/or liver necrosis most common. They are generally seen in immune-compromised birds.

Microscopic lesions seen with *Campylobacter* infection are congestion in the *lamina propria* and destruction of mucosal cells with accumulation of mucus, erythrocytes, mononuclear cells and a few polymorphonuclear cells. Hyperplasia and villous atrophy also occur in the distal intestinal tract.

Oral infections with *Campylobacter* can result in colonization throughout the intestine, cecum and cloaca. In turkeys certain *Campylobacter* spp. colonize the upper intestinal tract while others prefer the distal tract (unpublished data). In either case the organisms settle and multiply in the mucosal film. The degree of clinical signs produced by *Campylobacter* is dependent on a number of factors but organisms that produce a cytotoxin cause the diarrhea seen with some of these infections.

DIAGNOSIS

Diagnosing *Campylobacter* spp. can be as simple as a microscopic examination of intestinal scrapings where the small bacteria exhibit a “winged-gull” appearance. More sophisticated diagnostic methods require the ability to grow the organisms under thermophilic and microaerophilic conditions. Certain laboratories are equipped to isolate these organisms.

Organisms can be isolated from feces, cloacal swabs, intestines, carcass washes and litter. Once isolated, *Campylobacter* spp. can be differentiated using serotyping, electrophoresis, DNA restriction endonuclease analysis, plasmid analysis, and ribotyping. There are polymerase chain reaction (PCR) tests developed for identification of *Campylobacter*. The advantage of these tests is that viable organisms are not required for a positive test but the ubiquitous nature of *Campylobacter* on some farms can make interpretation of *Campylobacter*'s contribution to disease quite difficult.

When *Campylobacter* is suspected as a cause of intestinal disturbance in turkey poults, other potential causes of diarrhea must be ruled out. Intestinal viruses such as astrovirus and rotavirus are often present in poults and delineating what role each organism plays in the disease is challenging.

TREATMENT & CONTROL

Treatment of birds for *Campylobacter* infection is rare. *Campylobacter* is believed to be a commensal organism of the bird's intestinal tract. Because *Campylobacter* spp. are bacteria, they can be treated with antibiotics. Treatment of *Campylobacter* spp. with antibiotics should be done only with the results of a culture and sensitivity screening. *Campylobacter* spp. have become resistant to some antimicrobials and this resistance is not consistent among the different species. While prevalence of *Campylobacter* species does not differ between birds grown commercially vs. organically, the prevalence of antimicrobial resistant organisms is different, with isolates from organic birds susceptible to more classes of antibiotics. Antimicrobial resistance is wide spread in commercial turkeys (average 87% in turkeys). Knowing the species of *Campylobacter* and its susceptibility to antimicrobials is important in making a treatment decision.

REFERENCES

- Evans S & Powell L. *Campylobacter*. In *Poultry diseases*. Ed. Pattison M et al, 6th ed. 2008, Elsevier, pp 181-190.
- Friedman CR et al. Epidemiology of *Campylobacter jejuni* infections in the United States and other industrialized nations. In “*Campylobacter*”, Nachamkin I & Blaser MJ, ed. Washington: *American Society Microbiology*; 2000. pp121-138.
- Jennings JL et al. *Campylobacter jejuni* is associated with, but not sufficient to cause vibriotic hepatitis in chickens. *Vet Microbiol*, 2011,149:193-199.
- Lam KM et al. Pathogenicity of *Campylobacter jejuni* for Turkeys and Chickens. *Av Dis*, 1992, 36:359-363.
- Sahin O et al. Prevalence, antigenic specificity, and bactericidal activity of poultry anti-*Campylobacter* maternal antibodies. *Appl. Environ. Microbiol.* 2001, 67:3951–3957.
- Shane SM. & Stern NJ. *Campylobacter* infection. In “*Diseases of Poultry*”, Ed. YM Saif, Iowa State Press, Ames, 2003, pp 615-630.
- Shenhui C et al. Prevalence and antimicrobial resistance of *Campylobacter* spp. and salmonella serovars in organic chickens from Maryland retail stores. *Appl. Environ. Microbiol*, 2005, 71: 4108-4111.
- Wright SL et al Longitudinal study of prevalence of *Campylobacter jejuni* and *C. coli* from turkeys and swine grown in intertwined production systems. *J Food Protection*, 2008,71:1791-1796.

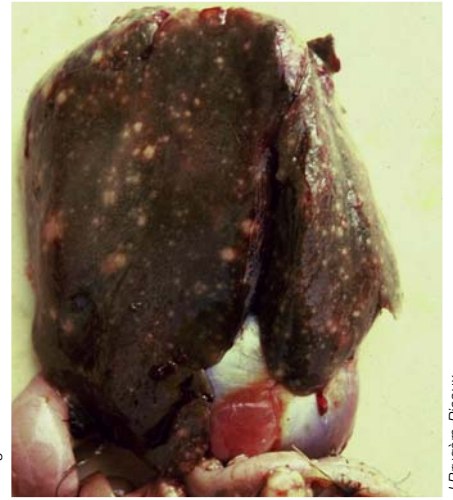
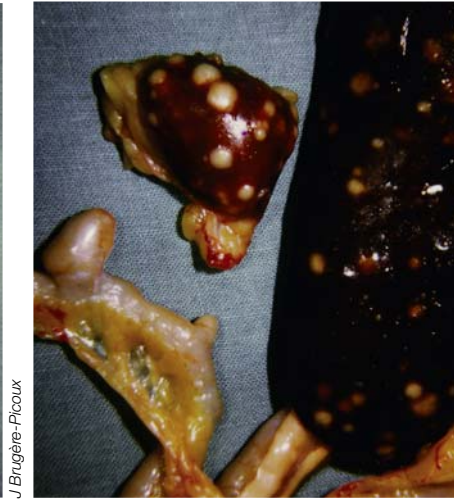
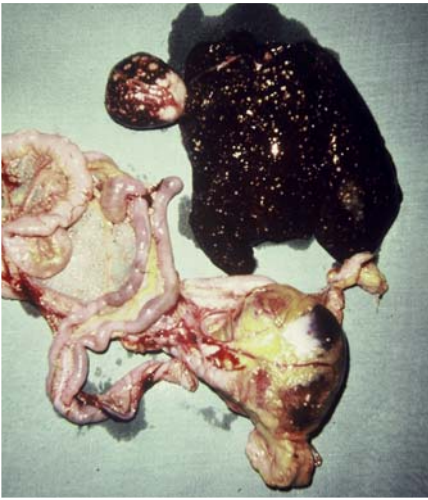Fig.54.1, 54.2 & 54.3 Avian tuberculosis lesions (Hen). Granulomas are most frequently encountered in the liver, spleen and intestines. These granulomas may be very variable in size and appear very prominent, especially in the gut.

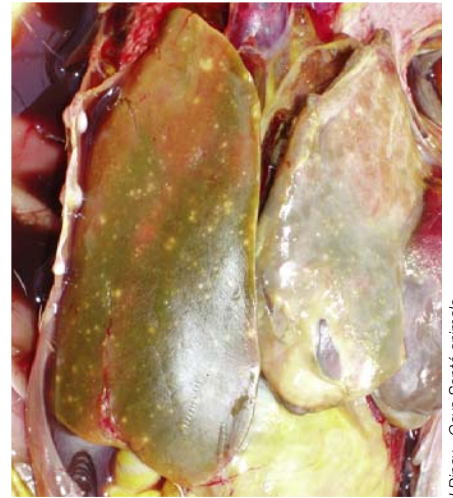
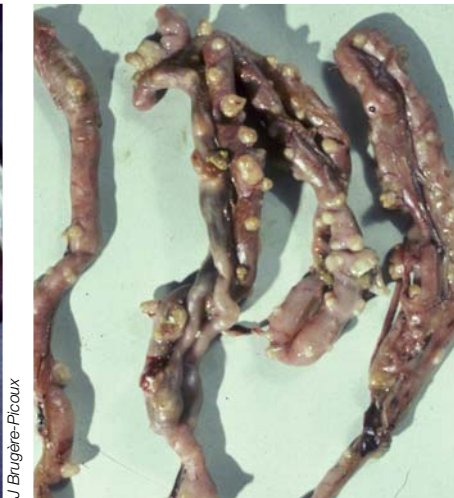
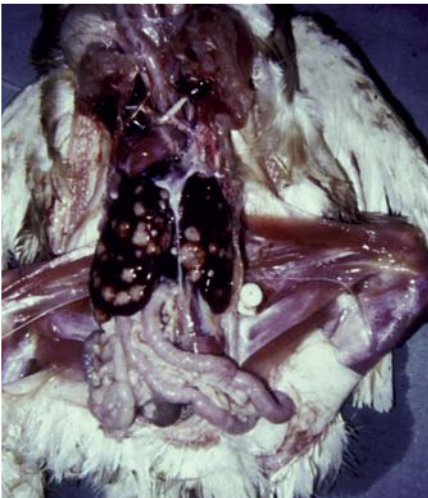Fig.54.4, 54.5 & 54.6: Avian tuberculosis (Hen). Because of the variability in size and appearance of the granulomas of these three cases of avian tuberculosis, they may be mistaken for tumors (Fig.54.4, especially because of the shiny appearance of granulomas), a coligranuloma (Fig.54.5, but in Hjarre's disease there are no nodules in the spleen) or a salmonellosis (Fig.54.6).

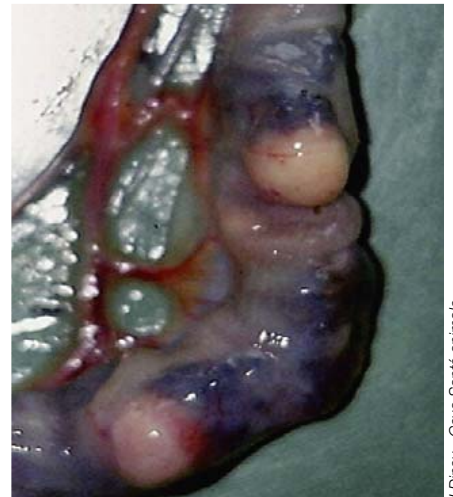
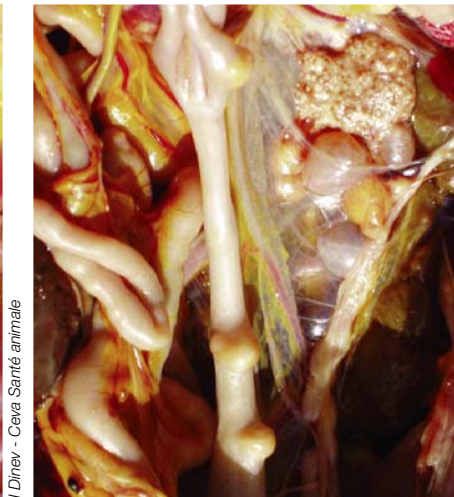
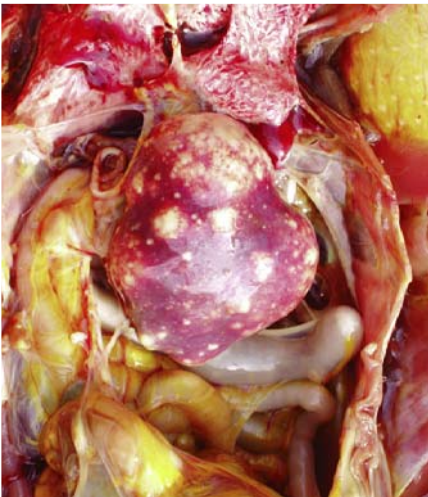Fig.54.7: Tuberculous granulomas (Hen). The presence of granulomas in the spleen differentiates the disease from coligranuloma.

Fig.54.8 & 54.9: Tuberculous granulomas in the intestine. In late stages, the hen stops laying and there is an involution of the ovaries (Fig.54.8). Following the necrosis of some granulomas, ulcers are formed allowing tubercle bacilli to be excreted in the droppings.

Bacterial diseases

54. AVIAN TUBERCULOSIS

INTRODUCTION

Avian tuberculosis is a chronic and contagious disease, caused by *Mycobacterium avium* and characterized by progressive weight loss, decreased egg production, and finally death. This disease occurs throughout the world in many avian and some mammalian species (e.g., pigs, rabbits and mink). In domestic poultry, it is generally seen in adult birds, particularly in backyard poultry, game and wild birds. It remains an important problem in captive exotic birds. In humans, *M. avium* infections have been common in patients with acquired immune deficiency syndrome (AIDS) but it seems that these human infections are more likely due to human-to-human or human-to-environment contacts rather than bird-to-human interaction.

ETIOLOGY

Mycobacteria responsible for avian tuberculosis are those of the *Mycobacterium avium* complex or MAC: *Mycobacterium avium* with four subspecies (subsp.) *Mycobacterium avium* subsp. *avium* (three serotypes, 1, 2 and 3, fully virulent for birds), *Mycobacterium avium* subsp. *hominissuis* (serotypes 6-11, 8-11 and 21, found in the environment and some are virulent for birds), *Mycobacterium avium* subsp. *paratuberculosis* (causative agent of paratuberculosis in ruminants and other species) and *Mycobacterium avium* subsp. *silvaticum* (virulent for birds). These mycobacteria are acid and alcohol fast and are easily recognized using the Ziehl-Neelsen stain. However, this technique does not allow identifying the species or strain of the bacterium. In this chapter, the avian tuberculosis bacillus will be referred to as *M. avium*.

EPIDEMIOLOGY

All species of birds can be infected with *M. avium*. Chickens, ducks and geese seem more susceptible than turkeys in which the infection is relatively uncommon. Avian tuberculosis is more common in zoological gardens. Other mammals can be infected, in particular pigs. However, contrary to previous reports, infected poultry are not the main source of infection for pigs.

The most important source of infection is the infected bird contaminating the environment with its droppings, especially the ground and litter but also the

water, the feed, *etc.*). Due to the long survival of *M. avium* in the environment (more than four years when not under direct sunlight), many other vectors have been identified: insects, vermin, staff (boots) or livestock and poultry equipment. Although *M. avium* can rarely be isolated from eggs, they are not considered a source of transmission of avian tuberculosis. *Mycobacterium avium* can be disseminated by the carcasses of dead birds (cannibalism might play a role in the transmission of *M. avium*).

Contamination occurs through ingestion (and rarely inhalation) of bacilli present in the environment.

CLINICAL SIGNS & LESIONS

Clinical signs are not pathognomonic. Signs may be present for weeks or months before death. The disease is chronic with a slow deterioration with progressive emaciation and lethargy. The striking loss of weight is evident with the atrophy of the breast muscles and with the keel becoming prominent. After bacteremia, the clinical signs vary depending on the affected organs. Classically, sick hens lose weight, are lame and have diarrhea. The recurring diarrhea results from the ulceration of intestinal nodules. The lameness, often unilateral, is associated with tubercular lesions in the marrow of bones in the legs or joints. Affected birds show a peculiar jerky type of locomotion. Feathers have a dull and ruffled appearance. The comb and wattle often appear pale and thinner than normal.

Affected birds may die within a few months. Some birds in good body condition may die suddenly as a consequence of an internal hemorrhage from the rupture of the liver or spleen.

Gross lesions are often characteristic with lesions mainly found in the liver, spleen and intestine. The bone marrow is frequently a site of infection following bacteremia. Ovaries, testes, heart, skin, lungs may be also affected.

Lesions of avian tuberculosis are irregular greyish-yellow or greyish-white nodules in the liver, spleen and intestines. They vary in size from pinpoint to several centimeters in diameter. Lesions near the surface of the liver or spleen are easily enucleated from adjacent tissues. Nodules are firm and more difficult to incise than a lymphoid tumor.

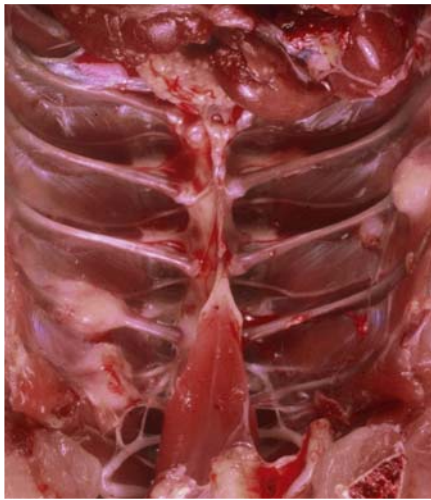


Fig.54.10: Avian Tuberculosis in the bones (Fowl). Tuberculous granulomas on the ribs.

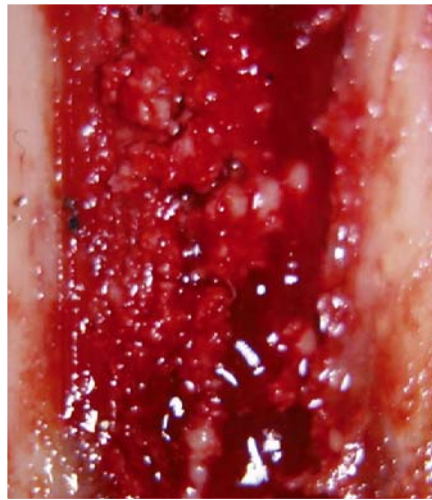

Fig.54.11: After sepsis, tuberculous granulomas are found in the bone marrow of the femur or tibia.

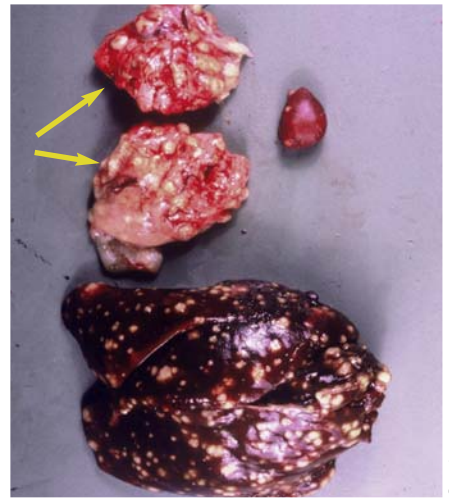


Fig.54.12: The lung (arrows) is less frequently affected than the liver, spleen or intestine.

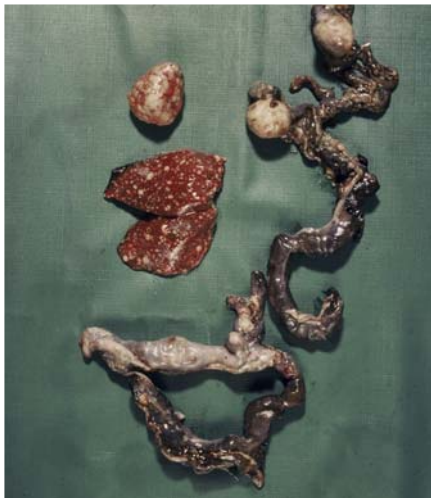

Fig.54.13 & 54.14: Gross lesions in the liver, spleen and intestine are strongly indicative of avian tuberculosis.

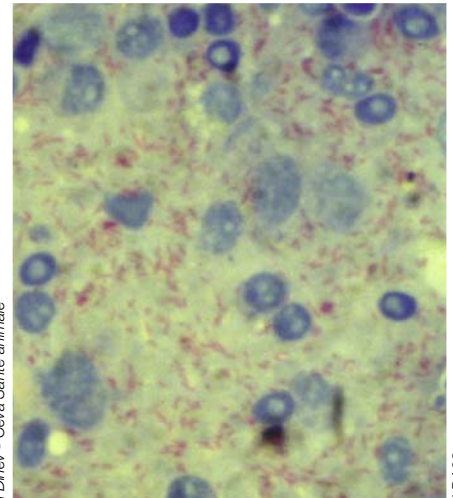
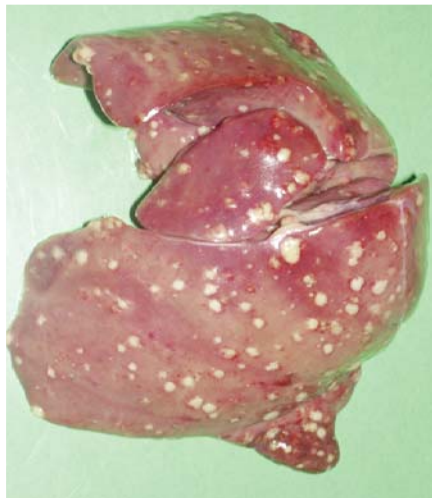

Fig.54.15: Smear of tuberculous granuloma. Laboratory confirmation of acid/alcohol-fast bacilli supports the diagnosis of avian tuberculosis (Ziehl-Neelsen stain).

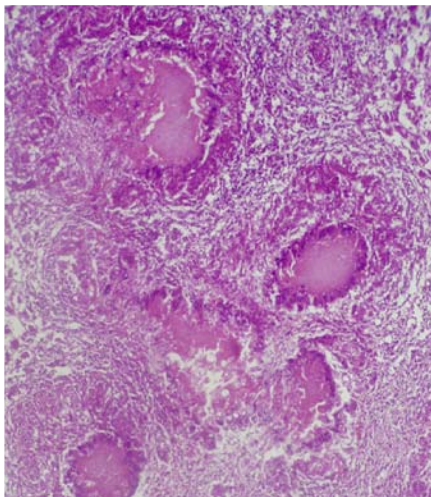


Fig.54.16 & 54.17: Avian tuberculosis (granuloma). The granuloma is composed of epithelioid cells with multinucleate Langhans giant cells in periphery. Caseous necrosis is found in the center of older granulomas.

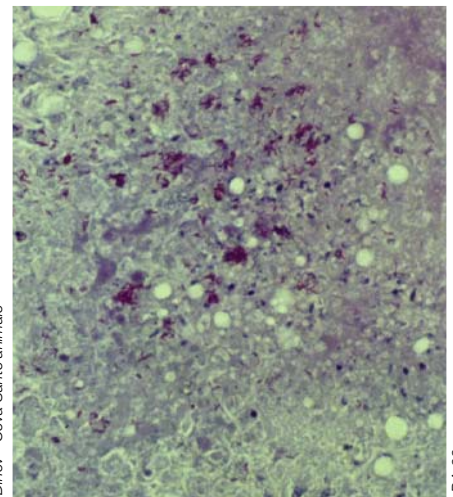
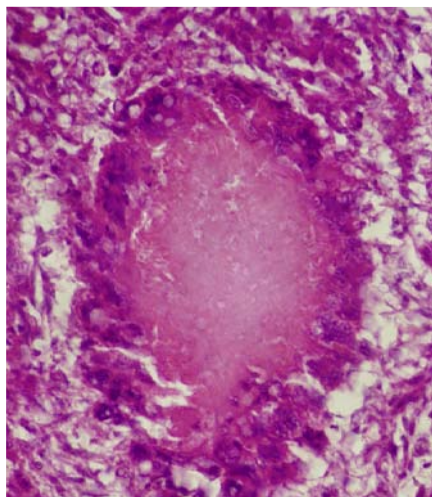


Fig.54.18: Spleen (Hen). Histological examination showing acid-and alcohol fast bacilli (Ziehl-Neelsen stain).

At histological examination, the basic lesion consists of multiple granulomas with central caseous necrosis surrounded by numerous lymphocytes, multinucleate Langhans giant cells, and macrophages rich in bacilli.

DIAGNOSIS

In live birds, the diagnosis is based on epidemiological and clinical findings (backyard poultry, older than 3-4 weeks of age, chronicity, lethargy, marked emaciation, recurring diarrhea, lameness, persistent mortality rate and/or a halt in egg production).

The presence of caseous nodules of variable size in the intestines, liver and spleen are highly suggestive of avian tuberculosis.

The demonstration of acid/alcohol-fast tubercle bacilli often present in very large numbers in lesions or secretions is normally sufficient for diagnostic purposes. Other diagnostic approaches include the culture and identification of the tubercle bacillus, utilization of DNA techniques and immunological tests (tuberculin, agglutination and ELISA tests).

For sanitary and epidemiological reasons, it is essential to differentiate avian tuberculosis from other nodular diseases. The conditions that should be included in this differential diagnosis are avian leukosis, Marek disease, coligranuloma (in Hjarre's disease there is no granuloma in the spleen), pullorum disease and other *Salmonella* infections, *Staphylococcus* infection, fowl cholera and aspergillosis.

TREATMENT & CONTROL

In some countries, avian tuberculosis is a reportable disease and authorities should be notified. The treatment is never recommended even in the case of valuable exotic birds or birds in danger of extinction, because it is uncertain, expensive, long and represents a potential risk of zoonosis.

The destruction of all sources of infection is essential to prevent the spread of avian tuberculosis, which is always difficult, if not impossible, in backyard or free-range flocks. As long as one infected bird remains in a flock, dissemination of the disease to healthy birds is possible.

The best approach to eradicate avian tuberculosis from a production site is by culling the entire flock and repopulating after the site has been decontaminated.

The eradication and disease-free status requirements include:

- removing all contaminated material;
- re-stocking with birds certified free of the infection;
- having preventative measures in place to prevent reoccurrence of the infection;
- having a monitoring program in place.

Since, as stated above, the eradication of avian tuberculosis is near impossible in backyard and free-range flocks, disease control under these circumstances is designed to essentially reduce the infection pressure:

- properly eliminate the culled flock (destroy and eliminate the flock according to local regulations);
- replacing all equipment and establishing the next flock (certified disease-free) on a different location (it is impractical to try to decontaminate soil);
- seal off the contaminated site to prevent access to birds.

No vaccines are available for avian tuberculosis.

REFERENCES

- Fulton RM & Sanchez S. Tuberculosis. In DS Swayne et al. in *"Diseases of Poultry"*. 13th Ed., Wiley Blackwell 2013, pp1008-1017.
- Jordan FTW & Hampson DJ. Some other bacteria. In *"Poultry diseases"*. Ed Pattison M et al, 6th edition. 2008, Elsevier, pp 243-256.
- Manning EJB & Collins MT. Infections mycobactériennes chez les animaux domestiques et sauvages. *Rev sci tech Off int Epiz*, 2001, 20.
- Norwegian School of Veterinary Science. "Sources of infection: Mycobacterium avium infections in pigs, humans and birds in Norway." ScienceDaily. ScienceDaily, 4 February 2010. <www.sciencedaily.com/releases/2010/02/100203091600.htm>.
- Pavlik I et al. Relationship between IS901 in the Mycobacterium avium complex strains isolated from birds, animals, human, and the environment and virulence for poultry. *Clinical Diagnostic Lab Immunol*, 2000, 7:212-217.
- Rastogi N et al. Introduction à la nomenclature et à la pathogénie des mycobactéries. *Rev sci tech Off int Epiz*, 2001, 20:21-54.

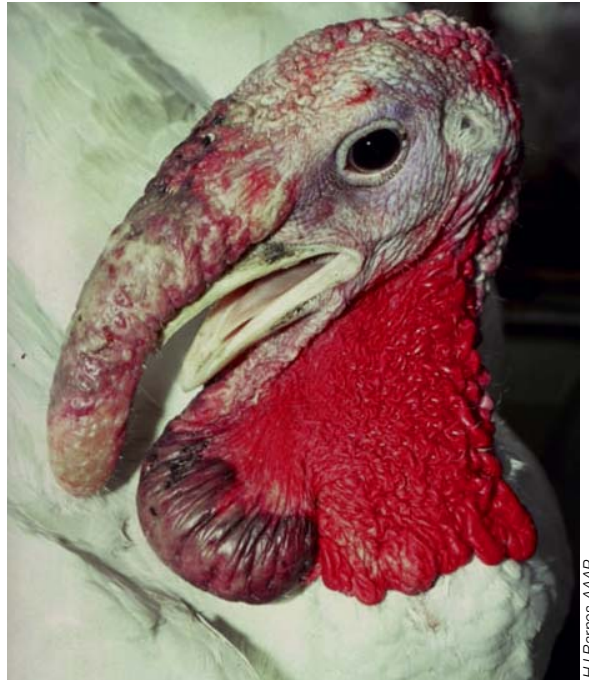
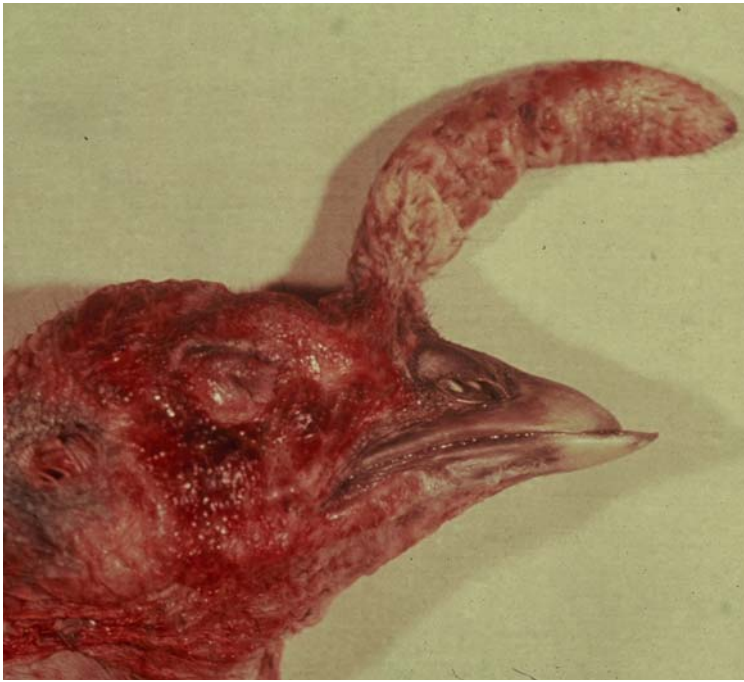
Fig.55.1 & 55.2: Erysipelas (Turkey). In the male turkey cyanosis and turgidity of snood and dewlap are characteristic (Fig.55.2: Chronic form).

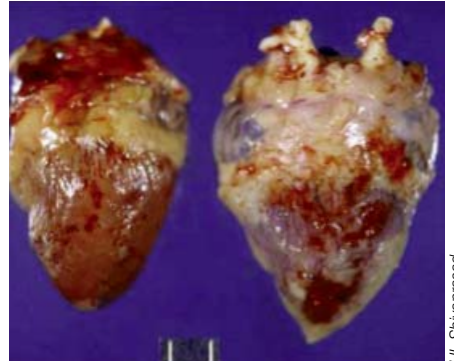
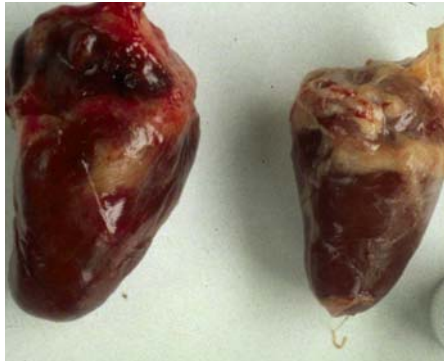
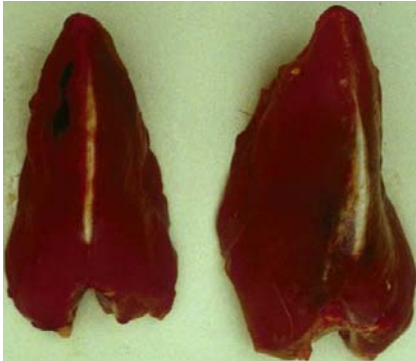
Fig.55.3: Erysipelas (Guinea fowl). Hemorrhagic suffusions in the breast muscle. Fig.55.4 & 55.5: Erysipelas. Congestion and hemorrhagic suffusions in the myocardium. Compared with a normal heart on the right in Fig 55.4 (Guinea fowl). (Fig.55.5: Turkey).

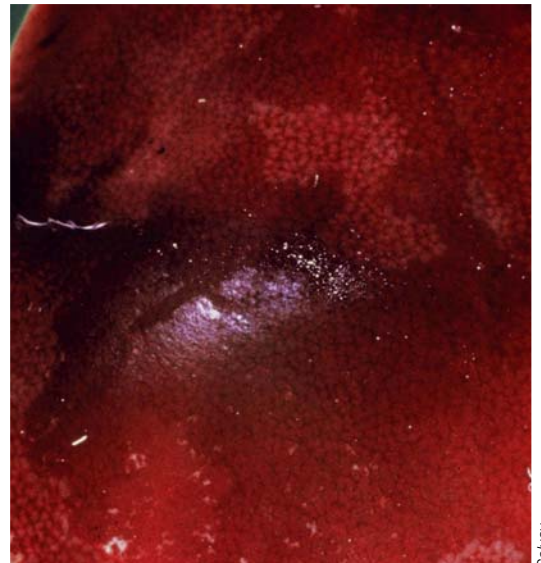
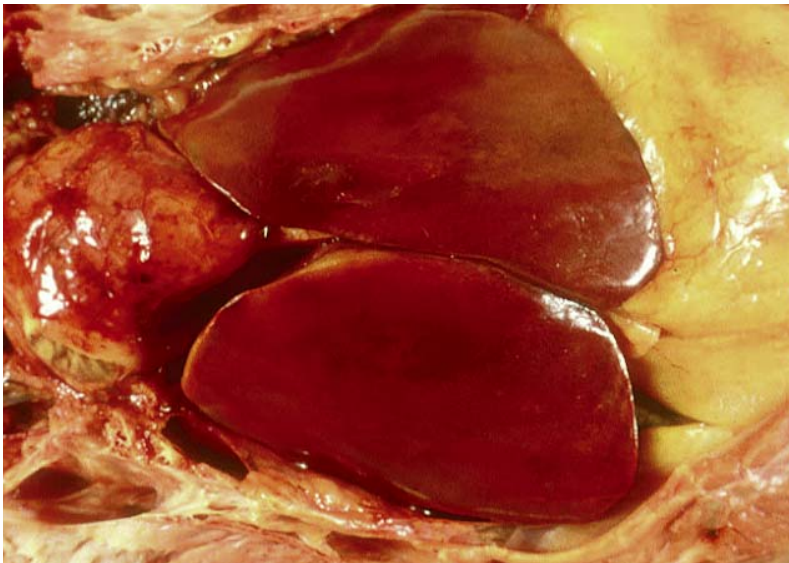

Fig.55.6: Acute erysipelas (Turkey). Severe congestion of liver and heart. Fig.55.7: Erysipelas (Turkey). Congestion of the liver with areas of necrosis.

Bacterial diseases

55. ERYSIPELAS

INTRODUCTION

Erysipelas is generally an acute septicemic, fulminating disease that occurs most commonly in older male turkeys. However, as a result of the pressure from animal welfare groups in many European countries, who promote free-range and organic farms, an increase in the number of cases in other species of birds is being observed. The disease is characterized by splenomegaly and serosal, cutaneous, and muscular hemorrhages. Chronic erysipelas, characterized by polyarthritis and endocarditis, occasionally occurs after an acute outbreak. Some birds can also be asymptomatic carriers. This disease has a worldwide distribution.

The disease is also a zoonosis. Erysipeloid in humans may occur as a localized skin infection or as septicemia (accompanied by often fatal endocarditis). The human disease is an occupational disease; a person is most often infected when working with diseased or carrier animals (pigs, fish, poultry, *etc.*), their excreta or animal by-products.

ETIOLOGY & EPIDEMIOLOGY

The causal agent, *Erysipelothrix rhusiopathiae*, is a Gram-positive non-spore-forming, non-encapsulated, rod-shaped bacterium that decolorizes easily (especially in older cultures), and tends to form long filaments. It is a facultative anaerobic bacterium that grows well on culture media containing thioglycollate and serum or serum components. There are two known species, *Erysipelothrix tonsillarum* (non-pathogenic) and *E. rhusiopathiae* (a frequent swine pathogen that can infect many other species, of which serovars 1, 2 and 5 are most frequently encountered in birds).

Domestic pigs are considered to be the main reservoir of *E. rhusiopathiae*, of which a relatively large percentage of animals (30 to 50%) are asymptomatic carriers. Fish, rodents and birds are also frequently colonized. Sporadic cases have been observed in sheep. *E. rhusiopathiae* is widely distributed in the soil and surface waters near farms or in untreated sewage effluent of slaughterhouses. Its presence in the environment generally indicates an environmental contamination of the soil or mud from infected animals, and not the indigenous origin of the organism. *Erysipelothrix rhusiopathiae*'s ability to survive in the soil in the environment for

several years exposes all poultry with access to the outdoors to a risk of contamination. Contamination of feed is also possible (fish meal, meat meal, *etc.*).

The source of the infection and the entry point of the organism are not always known, but there may be a history of indirect contact with pigs or sheep. The red mite *Dermanyssus gallinae* is a potential vector of *E. rhusiopathiae*. Breaks in the mucous membranes or skin can be an entry point: feather picking, fighting, vaccination (contaminated needles), biting arthropods (also vectors?), artificial insemination (particularly in female turkeys), parasitism or cannibalism (oral exposure). The birds that recover, as well as asymptomatic infected birds, can remain carriers for several weeks, shedding the organism in their droppings. Spread from one flock to another can be very slow, as there may be no contamination even between adjacent buildings.

Some factors may promote the emergence of the disease: stress, plucking of feathers (goose), intercurrent diseases (especially parasitic diseases such as coccidiosis), inadequate flock management, adverse weather conditions, *etc.*

While we can observe significant differences in mortality rates between different serovars, any given serovar may exhibit a wide variation in virulence. The virulence factors of *E. rhusiopathiae* are not fully understood but appear to be related to the production of a neuranimidase and the presence of a «capsule-like» structure resistant to phagocytosis.

All avian species are susceptible to infection. Turkeys appear to be the most susceptible. The infection in web-footed birds is often sporadic, and will persist in a flock for several months with only a few birds becoming affected at any one time.

CLINICAL SIGNS & LESIONS

The onset of the disease can be sudden and birds are found dead or dying after a short, acute illness. Clinical signs associated with this acute onset are depression, yellow-green diarrhea and sometimes an unsteady gait. In some cases, dark and thickened skin can be observed. In turkeys there is a cyanosis of the head with the snood in males showing a purple coloring and marked rigidity. In some hens, there may be congestion and hemorrhage of the cloacal region.



Fig.55.8: Erysipelas (Turkey). Splenitis. Observe the splenomegaly compared with a normal spleen on the right.

H. Shivaprasad

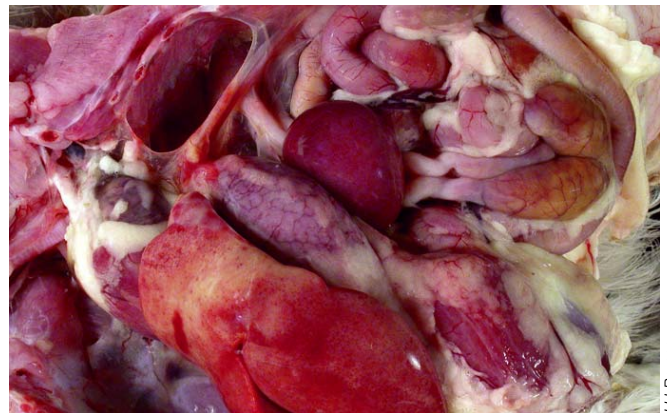

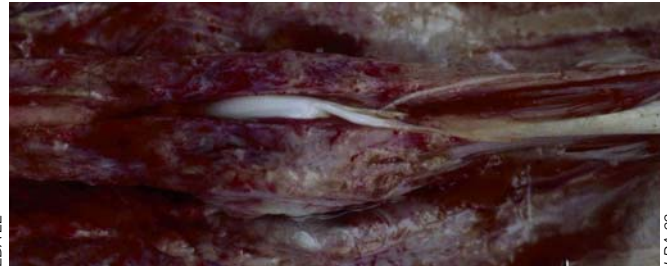
Fig.55.9: Erysipelas must be differentiated from sudden death syndrome in chickens where splenomegaly and some petechiae on the liver are also seen.

H.J. Barnes

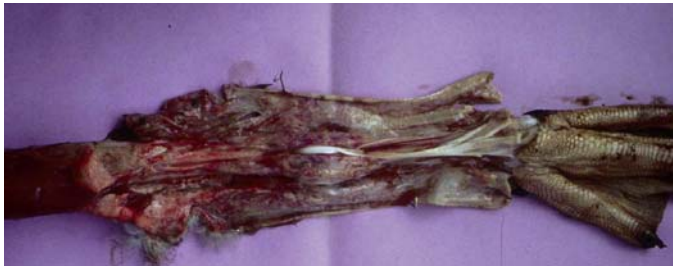

Fig.55.10 & 55.11: Erysipelas (Goose). Joint damage in an acute form (synovitis and tendinitis).

LDA 22



LDA 22

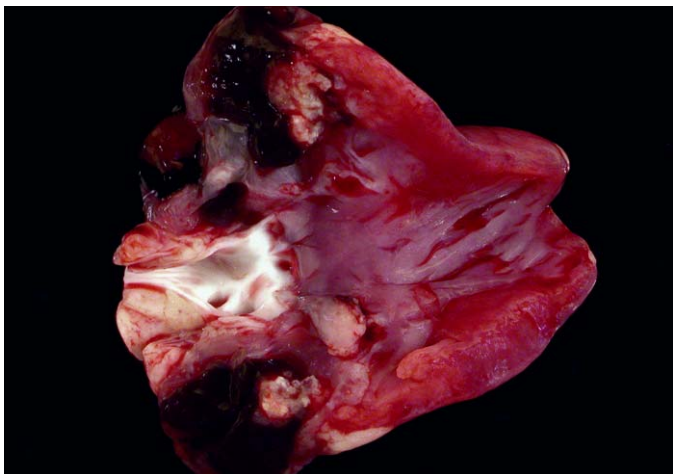


Fig.55.12: In chronic cases it is important to differentiate erysipelas from other causes of vegetative valvular endocarditis.

H.J. Barnes

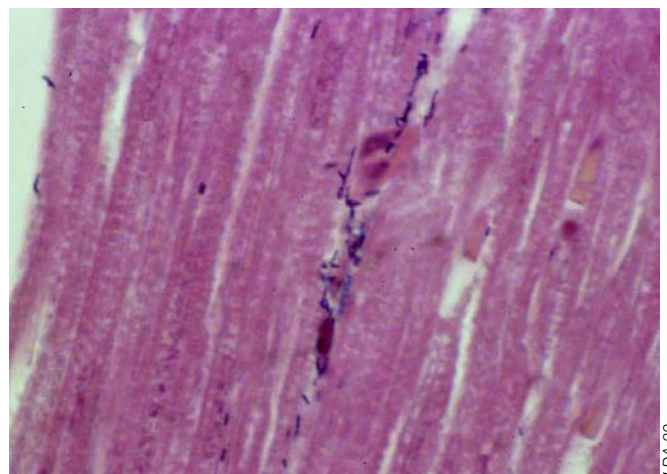


Fig.55.13: Erysipelas (Duck). Long and thin bacilli can be observed at histological examination of the myocardium (HES).

LDA 22

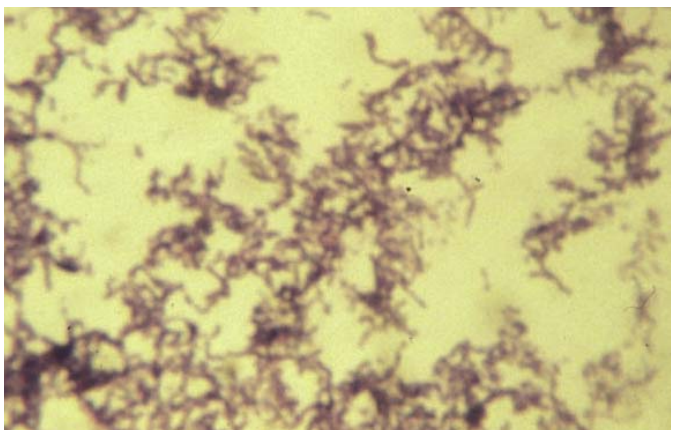


Fig.55.14: Erysipelas. Gram-positive *E. rhusiopathiae* forming long filaments.

LDA 22

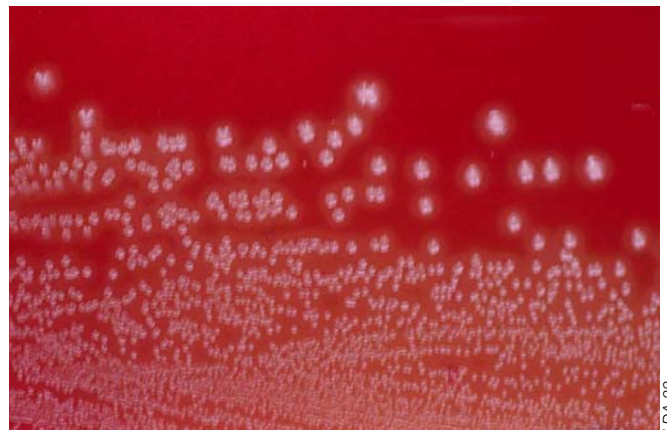

Fig.55.15: Erysipelas. Culture on blood agar of *Erysipelothrix rhusiopathiae*.

LDA 22

Mortality rates vary among avian species from less than 1% to over 50%. Mortality rate also depends on multiple factors such as vaccination and early treatment.

Some surviving or chronically infected birds may show a gradual loss of condition, declining laying performance and lameness associated with arthritis.

Lesions that are suggestive of septicemia are a widespread generalized congestion. The carcass is congested with petechial or suffusion hemorrhages in the abdominal and pericardial fat, in the heart muscle and under the serosal and mucous membranes. Pronounced catarrhal enteritis, dilation and thickening of the walls of the proventriculus and gizzard, and small ulcerations of the walls of the ceca can be seen. A notable splenomegaly is also often present.

Chronic cases may show yellow cauliflower-like, vegetative valvular endocarditis and a fibrinopurulent exudate in the joints of lame birds.

DIAGNOSIS

History, signs and lesions may suggest erysipelas. Differential diagnosis for the classic cases of acute disease includes fowl cholera, colisepticemia, salmonellosis, Newcastle disease and fowl plague. Confirmation is frequently obtained in a bacteriological laboratory with the isolation and identification of *E. rhusiopathiae* from samples taken from the spleen, liver, bone marrow and especially blood from the heart of dead birds. Gram-stained impression smears made from the samples taken during the necropsy will reveal Gram-positive, slightly curved bacteria. If specific antibodies are available, these smears may also be used to conduct immunofluorescence tests.

Polymerase chain reaction (PCR) assays are also used as a method of detection.

TREATMENT & CONTROL

Treatment

Penicillins are the treatment of choice for erysipelas. Antibiotic treatment that is administered through the water or feed is generally not an effective way to eliminate the infection, as the disease will often recur after treatment is stopped. Subcutaneous injections are preferred to quickly manage a severe outbreak. When deciding on the antibiotic treatment as well as the

route of administration, it is important to consider the required antibiotic withdrawal period before the birds can be sent for slaughter. In addition, catching and handling each bird may be impractical, expensive or even harmful. Intramuscular injections should not be given to poultry to avoid scaring or damaging the carcass.

Biosecurity

During an outbreak, implementation of strict biosecurity measures is essential. Carcasses should be removed from the flock as soon as possible to avoid further losses due to cannibalism.

As a precautionary measure, contact between poultry and potentially infected carriers (poultry, swine, sheep, rodents) should be avoided. Feed quality should also be monitored.

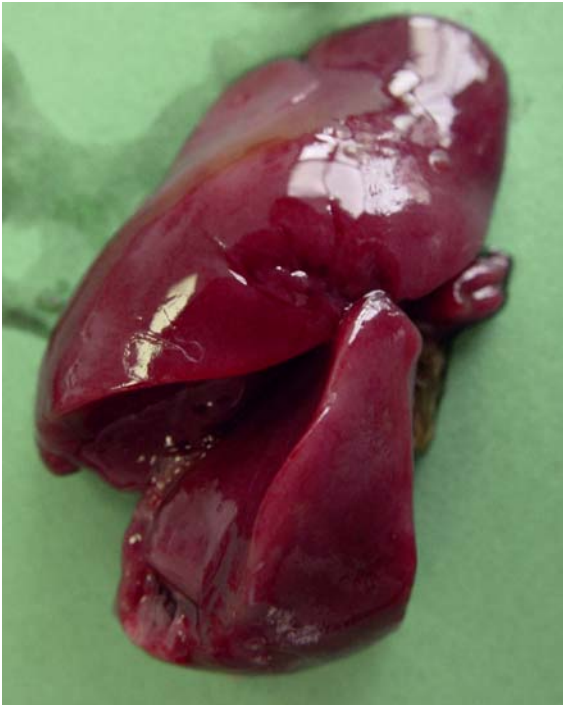Vaccination

Vaccination using either killed or live vaccines can be recommended for turkeys, free-range chickens or pheasants in high-risk areas.

These vaccines may stimulate nonspecific reactions to *Mycoplasma gallisepticum* and *Mycoplasma meleagridis* serum plate agglutination tests within a few weeks of vaccination.

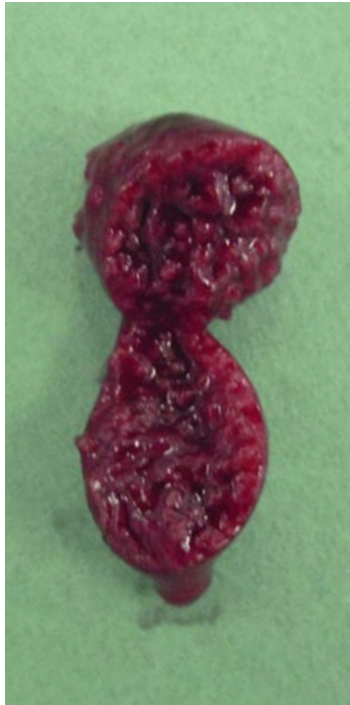
REFERENCES

- Bisgaard M et al. Erysipelas in poultry. Prevalence of serotypes and epidemiological investigations. *Avian Pathol*, 1980,9:355-352.
- Bricker JM & Saif YM. Erysipelas. In “*Diseases of poultry*”. Ed. Saif YM, 12th Ed, Blackwell Publishing, Iowa, IA, 2008,, pp 909-922.
- Chirico J et al. The poultry red mite, *Dermanyssus gallinae*, a potential vector of *Erysipelothrix rhusiopathiae* causing erysipelas in hens. *Med Vet Entomol*, 2003,17:232-234.
- Jordan FTW & Bisgaard M. *Erysipelothrix rhusiopathiae-erysipelas*. In *Poultry diseases*. Ed Pattison M et al, 6th edition. 2008, Elsevier, pp 215-219.
- Milne EM et al. Current infection with enteritic protozoa and *Erysipelothrix rhusiopathiae* in chicken and pheasant flocks. *Vet Rec*, 1997,141:340-341.
- Takeshi K et al. Direct and rapid detection by PCR of *Erysipelothrix* sp. DNAs prepared from bacterial strains and animal tissues. *J Clin Microbiol*, 1999, 37:4093-4098.
- Wood RL & Harrington R. Serotypes of *Erysipelothrix rhusiopathiae* isolated from swine and from soil and manure of swine pens in the United States. *Am J Vet Res*, 1978,39:1833-1840.



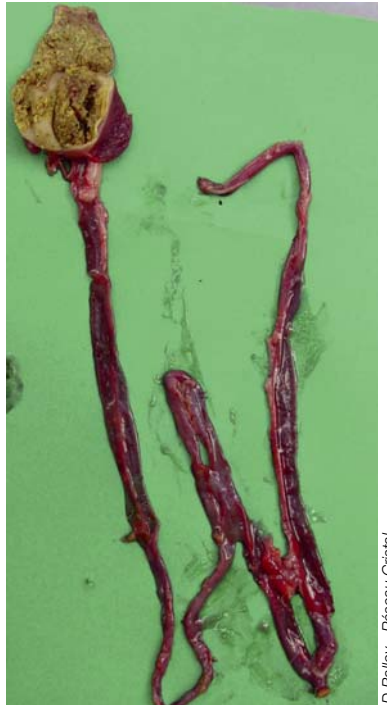
D Bailly - Réseau Cristal

Fig.56.1: *S. gallolyticus* subsp. *gallolyticus* (Duck, DSDS). Liver, enlarged and congested, has a mottled appearance.



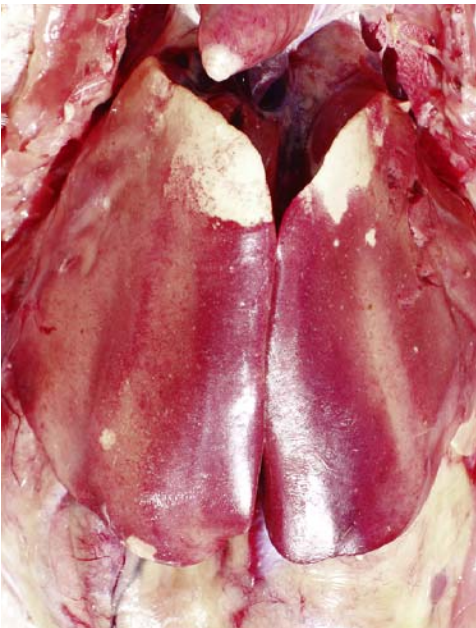D Bailly - Réseau Cristal

Fig.56.2: *S. gallolyticus* subsp. *gallolyticus* (Duck, DSDS). The spleen, also enlarged, presents a granular appearance with areas of necrosis.



D Bailly - Réseau Cristal

Fig.56.3: *S. gallolyticus* subsp. *gallolyticus* (Duck, DSDS). The intestinal mucosa is congested with hemorrhagic content, particularly in the ceca.

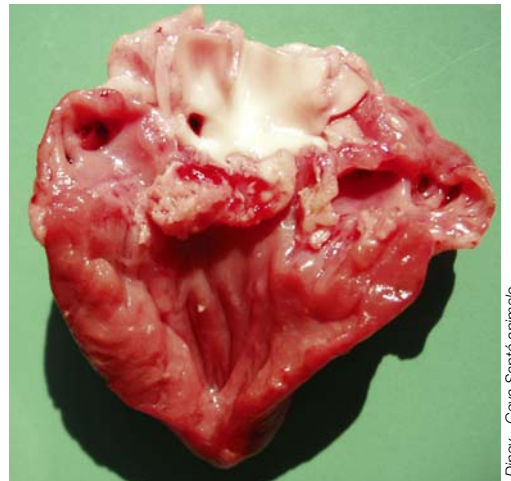


/Dinev - Ceva Santé animale

Fig.56.4. & 56.5: Streptococcosis. Liver and spleen infarctions are seen in acute septicemia.



/Dinev - Ceva Santé animale



/Dinev - Ceva Santé animale

Fig.56.6: Streptococcosis. The lesions in chronic streptococcal infections include arthritis, tenosynovitis, myocarditis and valvular endocarditis. Endocarditis affects predominantly mitral valves and less frequently, aortal and tricuspid valves.

Bacterial diseases

56. STREPTOCOCCI & ENTEROCOCCI

INTRODUCTION

Streptococci and enterococci are Gram-positive cocci. The enterococci were formerly classified as Lancefield's Group D streptococci. Enterococci are now assigned to a separate genus within the family *Streptococcaceae*. Several species of streptococci and enterococci have been identified.

Streptococci

Streptococci previously classified as *Streptococcus bovis* are now divided into five species including strains of *S. gallolyticus* that can degrade gallate. Other species of streptococci have been associated with disease in birds: *S. gallinaceus*, *S. zooepidemicus*, and *S. dysgalactiae*. *Streptococcus gallolyticus* subsp. *gallolyticus* is mainly responsible for septicemia, endocarditis, multifocal necrosis of the liver and spleen in many avian species (mainly pigeons and ducks as well as chickens, turkeys, etc.) but also in mammalian species. Humans are not spared and some streptococci isolated from poultry are considered zoonotic. *Streptococcus gallolyticus* subsp. *pasteurianus* is most often involved in meningitis and human neonatal infections. The isolation of *S. gallolyticus* subsp. *gallolyticus* in endocarditis is frequently associated with human colon carcinoma. Perhaps this normal inhabitant of the gastrointestinal tract can readily enter the bloodstream *via* intestinal lesions.

Enterococci

Enterococci are ubiquitous bacteria found in the intestine of humans and animals as well as in the environment. If some enterococci can be opportunistic pathogens that cause disease, some strains, however, are beneficial and are used as probiotic (e.g., *Enterococcus faecium*). The main enterococci isolated in avian pathology are *E. hirae*, *E. durans*, *E. faecalis* and *E. cecorum*.

The emergence of antibiotic-resistant enterococci in human nosocomial infections was behind the decision of the European Commission to ban additive growth promoters such as avoparcin in 1997 and, because of resistance to vancomycin, to permanently ban all additive growth promoters since 2006. Enterococci are opportunistic pathogens in humans, responsible for endocarditis, urinary tract infections, secondary postoperative infections,

neonatal infections and nosocomial infections. It was suggested that some enterococci, particularly *E. faecalis*, could be zoonotic agents.

Although worldwide in distribution, enterococci and streptococci infections are relatively uncommon. It is also possible that they are underdiagnosed and/or that the incidence of cases could be on the rise due to the banning of antibiotic growth promoters. These pathogens may be isolated in cases of «poor quality chicks» or when multiple infections are observed in chickens or turkeys (omphalitis, cellulitis, arthritis, osteomyelitis, endocarditis, salpingitis/salpingo-peritonitis, embryonic mortality, etc.).

ETIOLOGY & PATHOGENY

Streptococcus gallolyticus subsp. *gallolyticus*

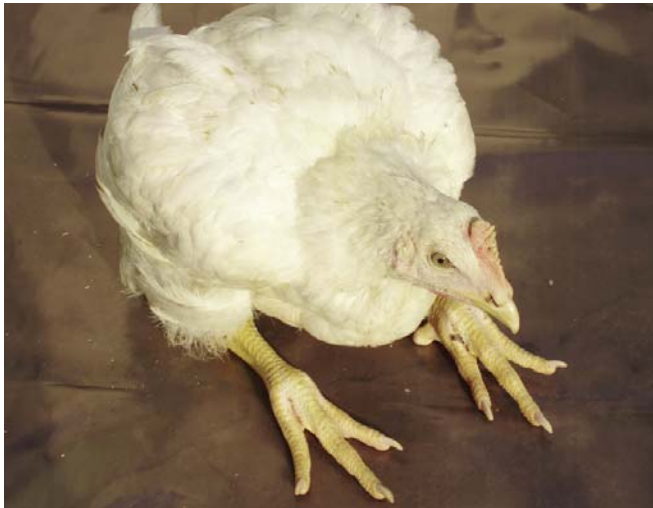Infections due to *S. gallolyticus* subsp. *gallolyticus* were first described in the pigeon. Currently, this is also a pathogen frequently found in commercial waterfowl flocks and it is responsible for an acute death syndrome in ducklings (ADSD) observed at the age of 1-3 weeks in Muscovy and mallard ducks. In the genus *Gallus*, the infection is also observed, but less frequently than in waterfowl.

The disease may originate from:

- a pseudo-vertical transmission by soiling of the eggshell. This organism has been isolated by swabbing the inside of eggshells of unhatched and unpipped eggs. It is believed that cleaning shells of dirty floor eggs with water may facilitate the penetration of the bacteria through the shell pores (dry scraping of the shells, rather than washing with water, has been associated with a reduction in the number of cases of ADSD on farms).
- a horizontal contamination by contaminated drinking water.

Enterococcus cecorum

Enterococcus cecorum has recently emerged in poultry farms in many countries. This pathogen is involved in cases of septicemia, pericarditis, local myositis, spondylitis, arthritis, and osteomyelitis. Economic losses associated with the disease are due to increased mortality and culling rates, decreased average processing weights, and lower

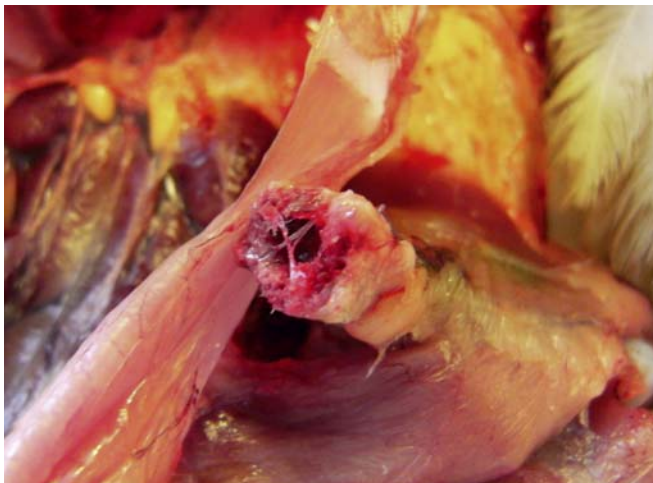

/Dhrev - Ceva Santé animale



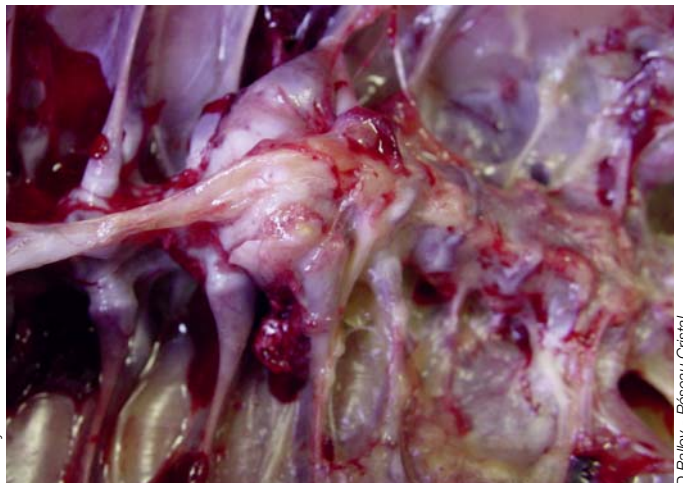
D Bailly - Réseau Cristal

Fig.56.7 & 56.8: Enterococcosis (*E. cecorum*). Affected birds rested on their hocks and on their side with legs extended forward and were unable to stand or walk. Differential diagnosis should be done with spondylitis, considering other infectious origins such as colibacillosis (case shown in Fig.56.7).



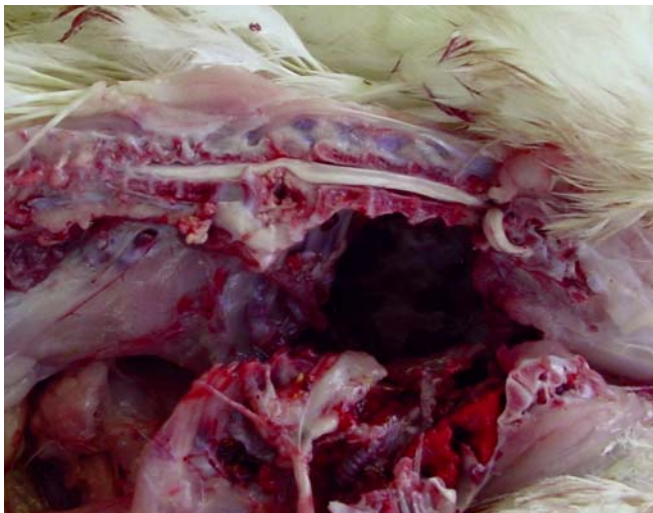D Bailly - Réseau Cristal

Fig.56.9: Enterococcosis (*E. cecorum*). The infection can cause femoral head necrosis.



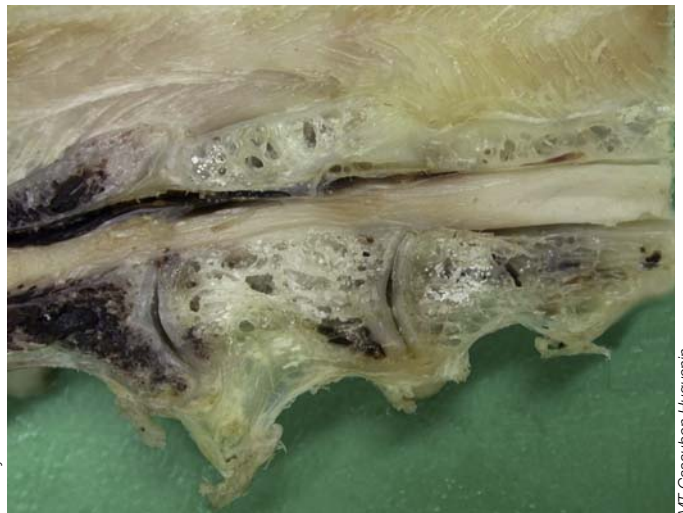
D Bailly - Réseau Cristal

Fig.56.10: Enterococcosis (*E. cecorum*). Osteomyelitis involving the thoracic vertebrae.



D Bailly - Réseau Cristal

Fig.56.11: Enterococcosis (*E. cecorum*). Infection affecting caudal thoracic vertebrae can cause compression on the spinal cord leading to paralysis in affected birds.



MT Casaubon Huguenin

Fig.56.12: Enterococcosis (*E. cecorum*). The vertebral osteomyelitis must be differentiated from all other causes of compression of the spinal cord, such as spondylolisthesis.

feed conversion. Males are more affected than females, especially in lines of chickens with rapid growth.

Enterococcus faecalis

Enterococcus faecalis affects many species at any age. It can be a contamination of embryos and young birds after fecal contamination of eggs but most transmissions occur by aerosol or orally. Any skin lesion may also promote infection. For example, such a contamination has been reported during vaccination against Marek's disease in pullets.

CLINICAL SIGNS & LESIONS

Streptococcus gallolyticus subsp. *gallolyticus*

In ducks, the disease appears suddenly, affecting the best performing ducklings and mortality rates may exceed 10%, even reaching 30%. Septicemic lesions are found in the liver, spleen and intestine.

The infection of broiler chickens or turkeys is less frequent than in waterfowl. It results either in septicemia, splenomegaly and hepatomegaly, osteomyelitis and/or arthritis with increased mortality, or it may produce a vegetative valvular endocarditis without clinical signs and no increase in flock mortality, but with an increase in slaughter plant condemnations.

Enterococcus cecorum

Chickens are susceptible from the age of 7 to 14 days. The morbidity rate increases over the following few weeks after infection. The first clinical signs are lameness progressing to paralysis. Affected birds cannot stand up or walk and rest on their hocks or on their side. The general condition of the flock gradually deteriorates with increasing heterogeneity, mortality in weaker individuals and an increase in culling. The economic impact is important.

Necropsy examination of affected birds shows femoral head necrosis, tendinitis, arthritis and osteomyelitis (especially at the level of the free thoracic vertebra that bulges dorsally and compresses the spinal cord). When opened, lesions contain pale, tan to yellow caseonecrotic material. Histopathologically, the spondyloarthritis shows necrosis with the presence of fibrin and a large number of heterophils and Gram-positive bacteria.

Muscovy ducklings can also be affected with deaths occurring during the second or third week

of age. *Enterococcus cecorum* has been isolated in such cases with liver and spleen lesions identical to ADSD, but with a less severe intestinal congestion.

Enterococcus faecalis

Enterococcus faecalis has been associated with several poultry conditions: endocarditis, hepatic granulomas in turkeys, arthritis in ducks and, most frequently, amyloidosis in layers and broiler breeders. In chickens with endocarditis, central nervous system lesions related to bacterial emboli can also be observed. Furthermore, *E. faecalis* has been associated with ascites in hens and pulmonary arterial hypertension in broilers.

Amyloid arthritis appears by 6 weeks of age and is characterized by lameness and growth retardation. Up to 20% of the birds can be affected in a flock. Amyloidosis lesions are observed on the liver and joints (yellow deposits in the tibio-tarsal joints).

Other streptococci and staphylococci infections

Since streptococci bacteria are ubiquitous and opportunistic pathogens present in the normal flora of the gut of poultry, other species of streptococci or enterococci may be isolated in association with various poultry conditions, although their prevalence is relatively low.

Thus, in cases of valvular **endocarditis**, in addition to *S. gallolyticus* subsp. *gallolyticus* and *E. faecalis*, it is also possible to isolate *E. faecium*, *E. hirae*, *E. durans*, *S. gallineous*, *S. pluranimalium* and *S. zooepidemicus*.

Enterococcus faecium in Peking ducks and *S. pluranimalium* in chickens can also be isolated in cases of **septicemia**.

Similarly, *E. hirae* or *E. durans* can be found in cases of mortality associated with nervous signs or tremor, torticollis and septicemic lesions and **encephalomalacia** in young chicks in the first or second week of age.

Finally, cases of **cellulitis** have been attributed to *S. dysgalactiae*, in combination with *Escherichia coli*.

DIAGNOSIS

Clinical signs and lesions are not specific to enterococcal or streptococcal infections. In cases of septicemia, the differential diagnosis includes other bacterial infections (*Staphylococcus*,

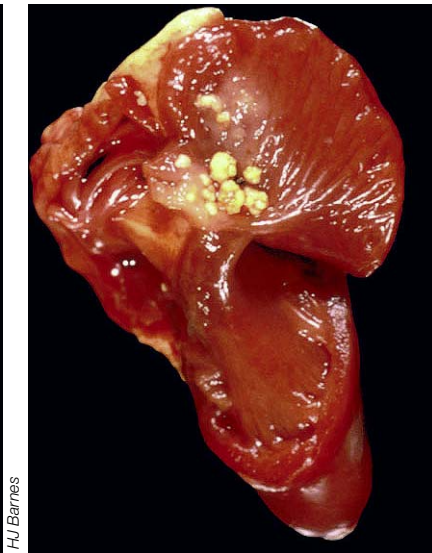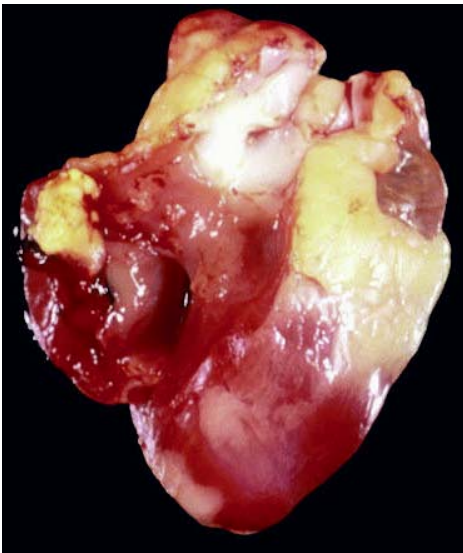


Fig. 56.13 & 56.14: Enterococcosis (4-week-old chicken). Vegetative valvular endocarditis is seen in the subacute and chronic forms of enterococcosis.

Fig. 56.15: Enterococcosis (8 day-old chick). Bilateral encephalomalacia of infectious origin.

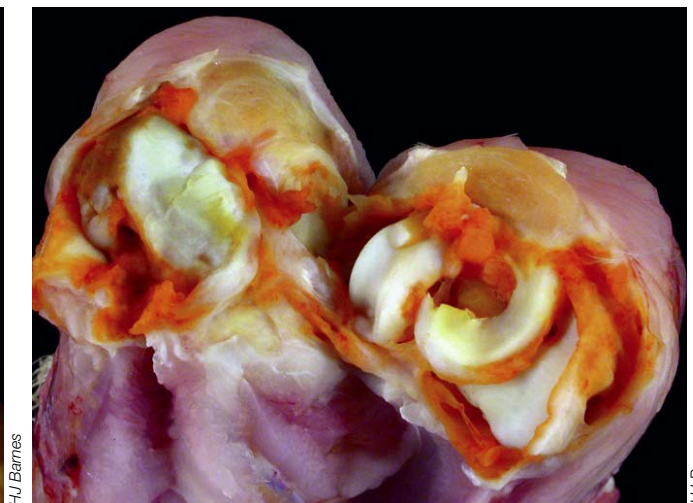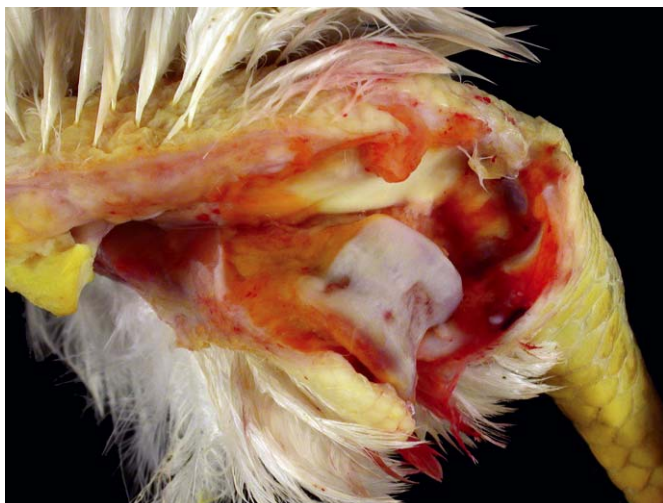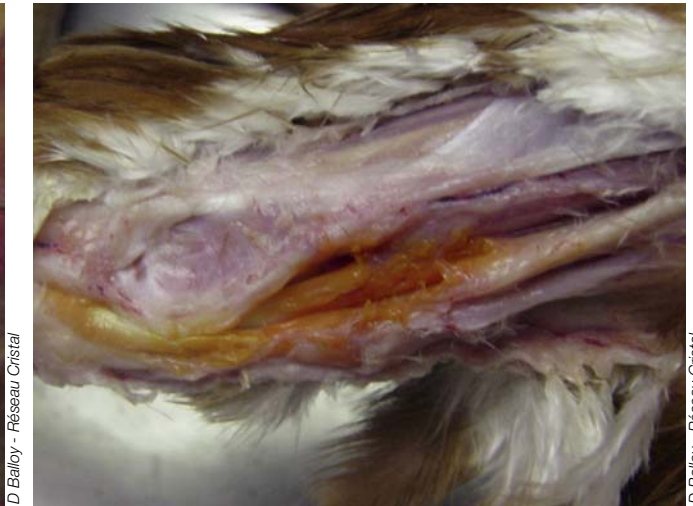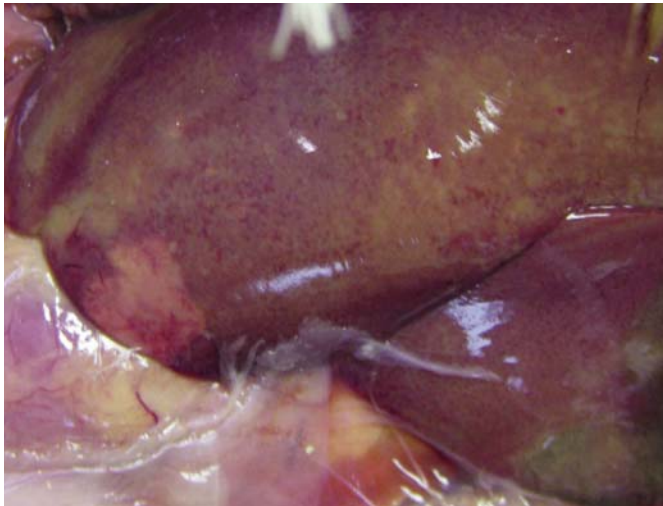


Fig. 56.16, 56.17, 56.18 & 56.19: *E. faecalis* (amyloid arthritis). Arthritis in pullets caused by *E. faecalis* is economically detrimental to poultry production. Pullets exhibit growth retardation and lameness from the age of 6 weeks. Up to 20% of infected birds in the flock may need to be culled, which represents a significant economic loss. Amyloidosis with hepatic infiltration (Fig. 56.16). Note the characteristic yellow deposits in the hock joints (Fig 56.17 & 56.18) or stifle joint (Fig. 56.19); figures 56.18 and 56.19 are of a 35-week-old hen.

Pasteurella, *Erysipelothrix*, *E. coli*). The encephalomalacia due to *Enterococcus* is associated with lesions of necrosis in the brainstem, optic lobe and cerebral peduncles and much less in the cerebellum (contrary to nutritional encephalomalacia associated with vitamin E deficiency). Vertebral osteomyelitis must be differentiated from all other causes of compression of the spinal cord, such as spondylolisthesis.

Diagnosis is confirmed by bacteriological examination following observation of Gram-positive cocci in the liver, spleen, or blood smear.

TREATMENT & CONTROL

Treatment

Antibiotherapy is of value in treating the acute form of the disease (β -Lactam antibiotics, particularly amoxicillin in drinking water, tetracyclines, etc.). It can stop the progression of the morbidity and mortality, but production performances will be negatively impacted. There is no treatment for the chronic form with endocarditis.

Control

Prevention involves biosecurity measures and the reduction of immunosuppressive factors which can induce the onset of disease: traditional cleaning and disinfection of buildings and poultry equipment, in particular watering equipment; using nipple drinkers instead of traditional open-water drinkers, dry cleaning eggs with an abrasive and not washing them, improving sanitary conditions associated with vaccination against Marek's disease, etc.

REFERENCES

Cardona CJ et al. *Enterococcus durans* infection in young chickens associated with bacteremia and encephalomalacia. *Avian Dis*, 1993,37:234-239.
Chadfield MS et al. Geno- and phenotypic diversity of avian isolates of *Streptococcus gallolyticus* subsp. *Gallolyticus* (*Streptococcus bovis*) and

associated diagnostic problems. *Clin Microbiol*, 2007,45:822-827.

Chamanza R et al. *Enterococcus*-associated encephalomalacia in one-week-old chicks. *Vet Rec*, 1998;143:450-451.

Harada T et al. Isolation of VanA-type vancomycin-resistant *Enterococcus* strains from domestic poultry products with enrichment by incubation in buffered peptone water at 42 degrees C. *Appl Environ Microbiol*, 2010,76:5317-5320.

Hedegaard L et al. Association of *Streptococcus pluranimalium* with valvular endocarditis and septicemia in adult broiler parents. *Avian Pathol*, 2009,38:155-160.

Kense MJ & Landman WJM. *Enterococcus cecorum* infections in broiler breeders and their offspring: molecular epidemiology. *Avian Pathol*, 2011,40:603-612.

Kim SY et al. A case of *Streptococcus gallolyticus* subsp. *gallolyticus* infective endocarditis with colon cancer: identification by 16S ribosomal DNA sequencing. *Korean J Lab Med*, 2010,30:160-165.

Landman WJM et al. Aerosol transmission of arthropathic and amyloidogenic *Enterococcus faecalis*. *Avian Dis*, 2001,45:1014-1023.

Poulsen JJ et al. *Enterococcus faecalis* clones in poultry and in humans with urinary tract infections, Vietnam. *EID*, 2012,18:1096-1100.

Robbins KM et al. An outbreak and source investigation of enterococcal spondylitis in broilers caused by *Enterococcus cecorum*. *Avian Dis*, 2012,56:768-773.

Sekizaki T et al. Endocarditis in chickens caused by subclinical infection of *Streptococcus gallolyticus* subsp. *Gallolyticus*. *Avian Dis*, 2008,52:183-186.

Smith JA & McNamee PT. Staphylococci, streptococci and enterococci. In *Poultry diseases*. Ed Pattison M et al, 6th edition. 2008, Elsevier, pp 191-199.

Tayer SG et al. Streptococcus and enterococcus. In "Diseases of poultry". Ed. Saif YM, 12th Ed, Blackwell Publishing, Iowa, IA, 2008, pp 900-908.

Van der Toorn et al. *Streptococcus gallolyticus* infections in racing pigeons, a literature review. *Tijdschr Diergeneeskd*, 2001,126:66-71.



Fig.57.1: Staphylococcosis. 6-day-old chicks with synovitis.



Fig.57.2: Swollen foot pads and a hock joint in turkey poulters due to *S. aureus*.

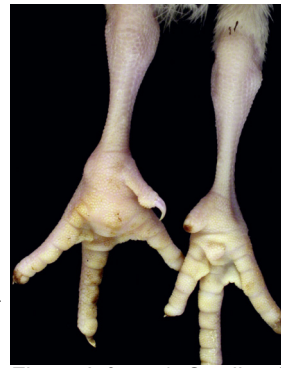

Fig.57.3: Swollen foot pads in turkey poulters due to *S. aureus*.

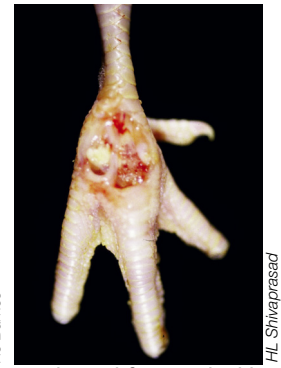

Fig.57.4: Swollen foot pad with exudate in turkey poulters due to *S. aureus*.



Fig.57.5: Bumble foot in an adult chicken due to *S. aureus*.

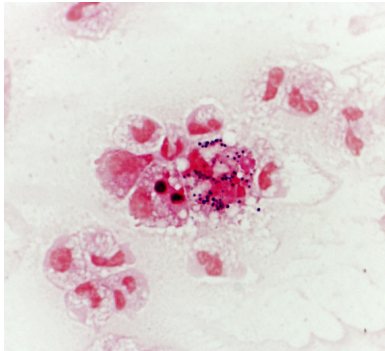


Fig.57.6: Staphylococcosis (9-day-old poult). Gram stain of the smear from bumblefoot (x700).

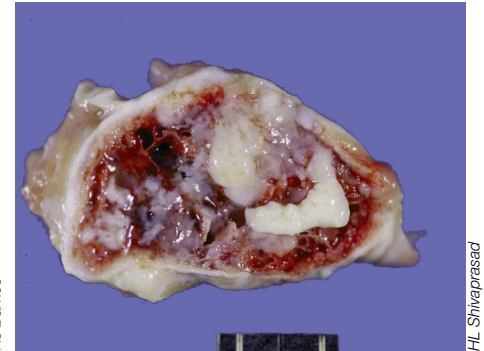


Fig.57.7: Severe osteomyelitis of tibiotarsus in broiler chicken.

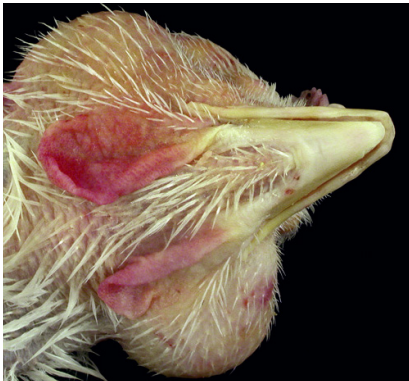

Fig.57.8 & 57.9: Staphylococcosis (35-week-old broiler breeder). Bilateral sinusitis and abscess.

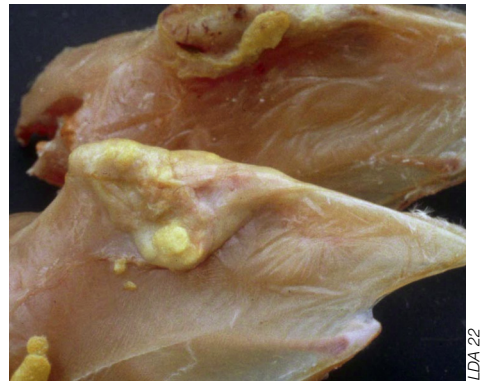
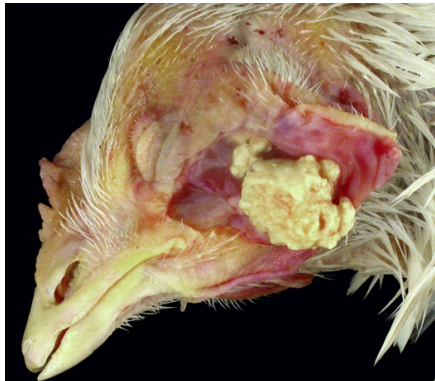
Fig.57.10: Staphylococcosis (Fowl). Sternal bursitis with abscess.

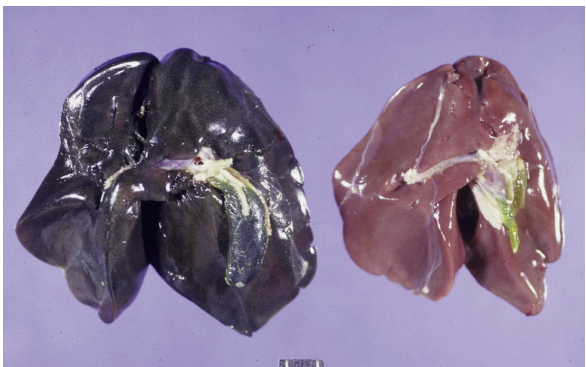


Fig.57.11: Green liver in a turkey due to *S. aureus*. Compare with normal liver on the right.

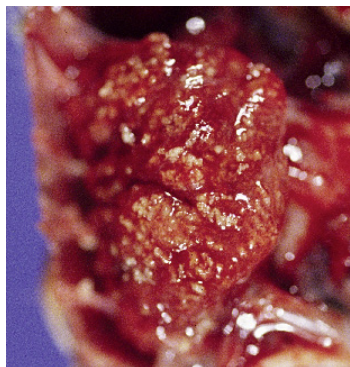


Fig.57.12: Lungs from 7-day-old poulters with numerous pale yellow foci due to *S. aureus*.

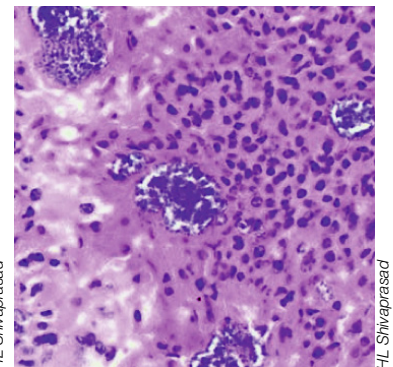


Fig.57.13: Photomicrograph of lung (poult) with severe granulomatous inflammation and bacterial colonies of *S. aureus*.

Bacterial diseases

57. STAPHYLOCOCCOSIS

INTRODUCTION

Staphylococcosis is a common septicemic disease of poultry, mostly turkeys and broiler chickens, caused by the bacterium *Staphylococcus aureus*. The disease is most commonly associated with arthritis, synovitis, osteomyelitis, gangrenous dermatitis, omphalitis and septicemia. Other species of birds are also susceptible to staphylococcosis including ducks, geese, psittacines, passerines and wild birds.

ETIOLOGY & EPIDEMIOLOGY

The etiology of staphylococcosis is mainly *Staphylococcus aureus*, a Gram-positive, coccoid bacterium that can be found in clusters in tissues. Other *Staphylococcus* sp. such as *S. epidermidis*, *S. intermedius*, *S. hyicus*, *S. xylosus*, and others have also been associated with disease in poultry and other birds. The bacteria are ubiquitous in the environment and as a result contamination of the skin in chickens and turkeys is common. Breaks in the skin, beak (beak trimming) or toes (toe trimming) enable bacteria to gain entrance. Primary immunosuppressive diseases in chickens such as infectious bursal disease (IBDV), chick infectious anemia (CIAV) and Marek disease, can predispose chickens for staphylococcosis.

Staphylococcosis is a worldwide problem in chickens and turkeys and can cause significant economic losses to the poultry industry. In turkeys it has been associated with green-liver and osteomyelitis complex resulting in condemnation and downgrading of carcasses at the processing plants. Occasionally, enterotoxin producing *S. aureus* strains in poultry meat have been associated with food poisoning in humans. Methicillin-resistant *Staphylococcus aureus* (MRSA) have also been identified, occasionally, in poultry.

CLINICAL SIGNS & LESIONS

Clinical signs due to staphylococcosis in poultry can depend on the organ system affected. These can range from non specific signs such as ruffled feathers, discolored skin, depression, weakness, respiratory signs and sudden death to lameness in one or both legs, droopy wings and increased mortality in the flock.

Similarly, gross lesions due to staphylococcosis are also not specific and can include yolk sacs which

may have watery yellow or caseous exudate, prominent navel buttons, swollen hocks; gangrenous dermatitis; swollen feet with yellow exudate in the joints sometimes extending into the tendon sheaths; necrosis and yellow exudate in the epiphysis of tibio-tarsus and tarsometatarsus; and vertebrae (usually T4); green liver; *etc.* Occasionally, lungs in turkey poultts can have yellow foci of granulomas, due to staphylococcosis, resembling brooder pneumonia (aspergillosis). Synovitis with orange exudate (amyloid arthropathy) in the hock and other joints can also be observed due to *S. aureus* in Brown Leghorn chickens. Other lesions due to staphylococcosis include vegetative endocarditis, swollen foot pads (bumble foot), necrotic foci in the liver and spleen.

Histologically the lesions usually consist of mild to severe fibrinosuppurative or fibrinoheterophilic inflammation and infiltration of multinucleated giant cells associated with numerous colonies of bacteria of coccoid morphology which will stain positive by Gram stain.

DIAGNOSIS

A presumptive diagnosis can be made based on clinical signs, gross and microscopic lesions. Gram stain of smears from lesions can provide a tentative and quick diagnosis. *S. aureus* and other *Staphylococcus* sp. can be readily isolated from most lesions such as in the yolk sac, liver, bone, joints, lungs, skin and other organs.

TREATMENT & CONTROL

Since *S. aureus* and other *Staphylococcus* sp. are ubiquitous in the environment any steps taken to reduce their numbers would be helpful. Interventions to reduce the portal of entry of bacteria such as wounds, scratches, bruises of the skin should be implemented, as well as exposure to immunosuppressive diseases such as IBVD, CIAV, *etc.* Cleaning and disinfection of the incubators and hatchers will help reduce or prevent exposure to *Staphylococcus* sp. Biosecurity implementation, total confinement of birds, bird and rodent proofing of the houses are essential for minimizing staphylococcosis.

Antibiotics such as penicillin, streptomycin, tetracyclines, sulfonamides, erythromycin, novobiocin, lincomycin, and spectinomycin can be effective in treatment. However, sensitivity tests should be performed frequently as the bacteria may develop resistance to certain antibiotics.



B Ribineau

Fig.58.1: Avian intestinal spirochetosis (*Brachyspira intermedia*). Sick breeding hen.



B Ribineau

Fig.58.2: Avian intestinal spirochetosis (*Brachyspira intermedia*). Characteristic foamy yellow-brownish cecal droppings.



DJ Hampson



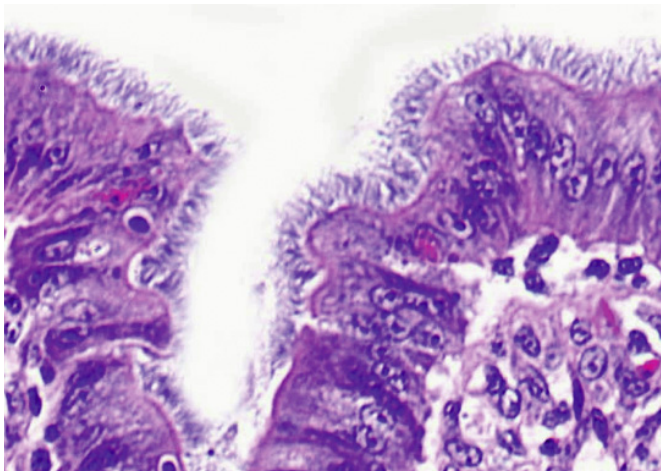
DJ Hampson

Fig.58.3. & 58.4: Avian intestinal spirochetosis. Comparison of frothy and caramel-colored fecal sample consistent with AIS (top) with normal fecal sample (bottom).



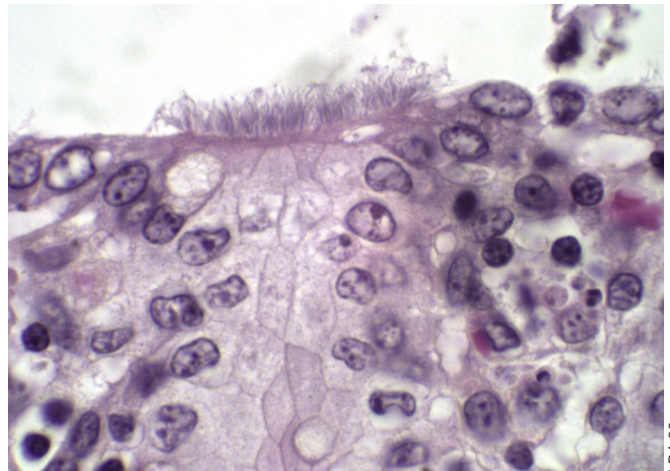
DJ Hampson

Fig.58.5: Avian intestinal spirochetosis. Normal egg (left) compared to fecal-stained, AIS affected egg (right).



HL Shivaprasad

Fig.58.6: Avian intestinal spirochetosis (Turkey poult). *Brachyspira pilosicoli* attached to the tips of enterocytes of a turkey poult forming a false brush border.



LDA 22

Fig.58.7: Porcine intestinal spirochetosis (*Brachyspira pilosicoli*). Note also the adhesion of *Brachyspira pilosicoli* to the top of enterocytes, forming a false brush border.

Bacterial diseases

58. BRACHYSPIRA SPP (AVIAN INTESTINAL SPIROCHETOSIS)

INTRODUCTION

Avian intestinal spirochetosis (AIS) is a term referring to the colonization of the avian ceca and/or rectum by spirochetes. These spirochetes are pathogenic *Brachyspira* species (*B. intermedia*, *B. pilosicoli*, *B. alvinipulli*) affecting chickens and other birds. Clinical signs include a reduction in egg production and diarrhea. *Brachyspira hyodysenteriae* is associated with a severe typhlitis in rheas. The pathogenic role of *B. innocens*, *B. murdochii* and *B. aalborgi* is still debated.

Significant economic losses are recorded in poultry flocks infected by *Brachyspira*. Similar losses are seen in the swine industry with infections by *B. pilosicoli* (porcine intestinal spirochetosis) and *B. hyodysenteriae* (swine dysentery).

Some avian strains are very close to human strains (and other animal strains) and an inter-species transmission of *B. pilosicoli* is possible. This makes *B. pilosicoli* a potential zoonotic agent. Human cases are observed mainly in immunocompromised patients in countries where poor drinking water sanitation is prevalent. However, the occupational hazard for poultry farmers is considered low.

ETIOLOGY & PATHOGENESIS

Brachyspira belongs to the order *Spirochaetales* of the *Brachyspiraceae* family. This species is Gram-negative, anaerobic, and helical (hence its former name *Serpolina*). The bacterium cell contains multiple periplasmic flagella producing a characteristic corkscrew-like movement.

In birds, the genus *Gallus* is the most affected by *Brachyspira*. Between 30 and 70% of layer and broiler breeder farms have been found to be infected with these spirochetes without showing any clinical signs. Other avian species such as turkeys, ducks, geese, pheasants, partridges and aviary birds are sensitive to *B. pilosicoli*, *B. intermedia* and *B. alvinipulli*. Although *Brachyspira* has long been observed in chickens, its pathogenic role has more recently been recognized due to improved diagnostic methods and, perhaps, also because of the withdrawal of routine antimicrobial growth promoters in poultry feed. In 2005, the presence of *B. pilosicoli* was demonstrated for the first time in

7.5-to-18-week-old turkey flocks with cecal spirochetosis, typhlitis and increased mortality.

Other species are susceptible to *Brachyspira*. Colonic spirochaetosis is observed in many hosts including humans, pigs and dogs. *B. hyodysenteriae*, responsible for swine dysentery, can also cause severe typhlitis in rheas.

The transmission of *Brachyspira* in poultry is not completely understood. *Brachyspira* species can survive up to 210 days in pig feces left in the environment. However, these organisms are very sensitive to disinfectants. This is why contamination of a flock placed in a clean and disinfected barn may be the result of horizontal transmission *via* an animal carrier (dogs, wild birds, rodents, flies), especially through contaminated drinking water. Indeed, stagnant water accessible to infected wild birds such as ducks can remain contaminated with *Brachyspira* for 2 months. Intestinal colonization by *Brachyspira* is rarely detected before the age of 15 weeks in layers. On a multi-age farm, contamination from older flocks to younger ones likely occurs *via* fomites (i.e., movement of personnel or equipment). Within flock transmission occurs *via* the fecal-oral route and possibly by aerosol. There is no evidence of vertical transmission.

Once a flock is infected, the infection spreads throughout the flock to reach 100% of the birds, especially on farms with outdoor runs. Dietary factors (e.g., excess wheat) and stresses such as molting or onset of lay are known predisposing factors associated with the expression of the disease.

CLINICAL SIGNS & LESIONS

Attachment of *B. pilosicoli* to enterocytes of the large intestine leads to the formation of a «false brush border» of spirochetes. *Brachyspira intermedia* do not attach specifically on enterocytes but the bacteria are present in the intestinal mucus.

The most common clinical sign is an intermittent chronic diarrhea observed in 5-20% of the flock. Droppings are brownish-yellow, foul smelling, frothy and/or mucoid with a 15% increase in water and lipid content, staining the vent, litter and eggs. Dirty eggs should be removed from the food chain.

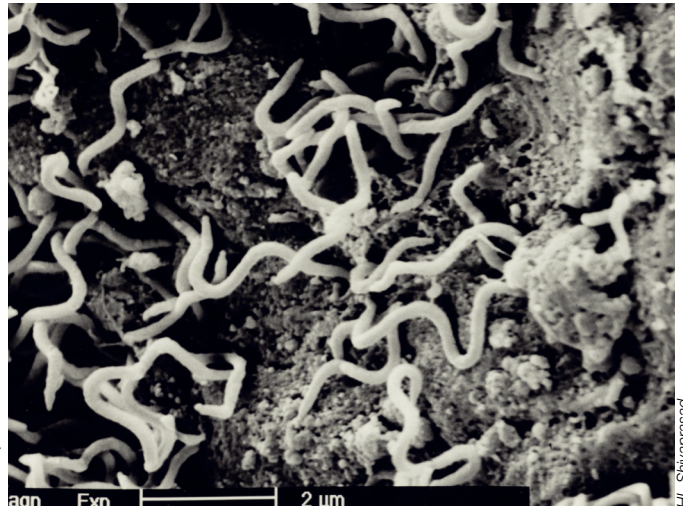
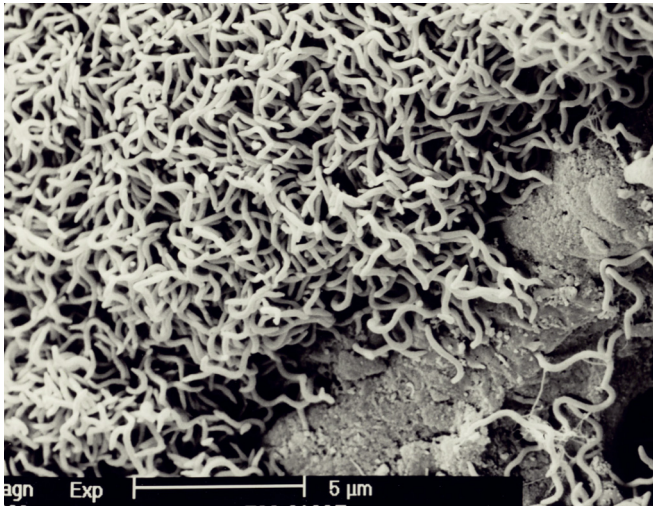


Fig.58.8 & 58.9: Avian intestinal spirochetosis (Turkey poul). Scanning electron microscopy showing the morphology of *B. pilosicoli* attached to the apical membrane of the enterocytes in the ceca of a turkey poul.

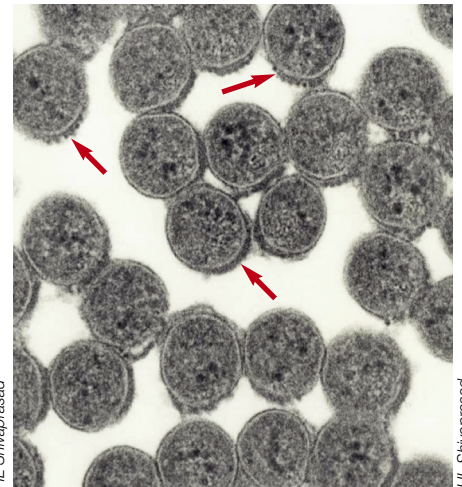
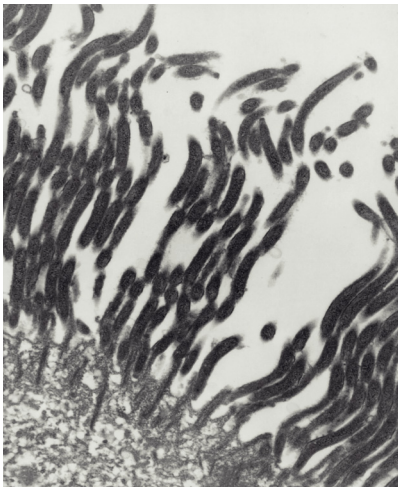
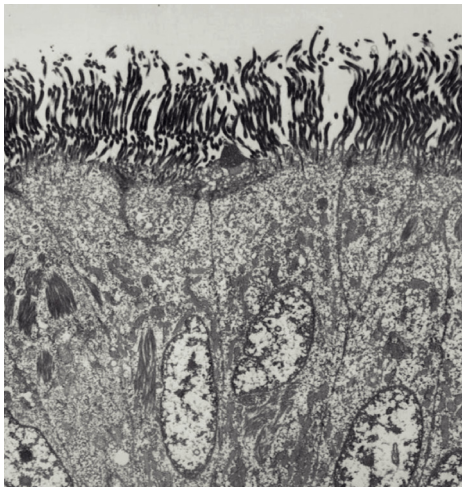


Fig.58.10 & 58.11: Avian intestinal spirochetosis (Turkey poul). Transmission electron microscopy showing the morphology of *B. pilosicoli* attached to the brush border of the enterocytes in the ceca of a turkey poul.

Fig.58.12: Avian intestinal spirochetosis. Transmission electron microscopy of the cross sections of *B. pilosicoli* showing periplasmic flagella (arrows).

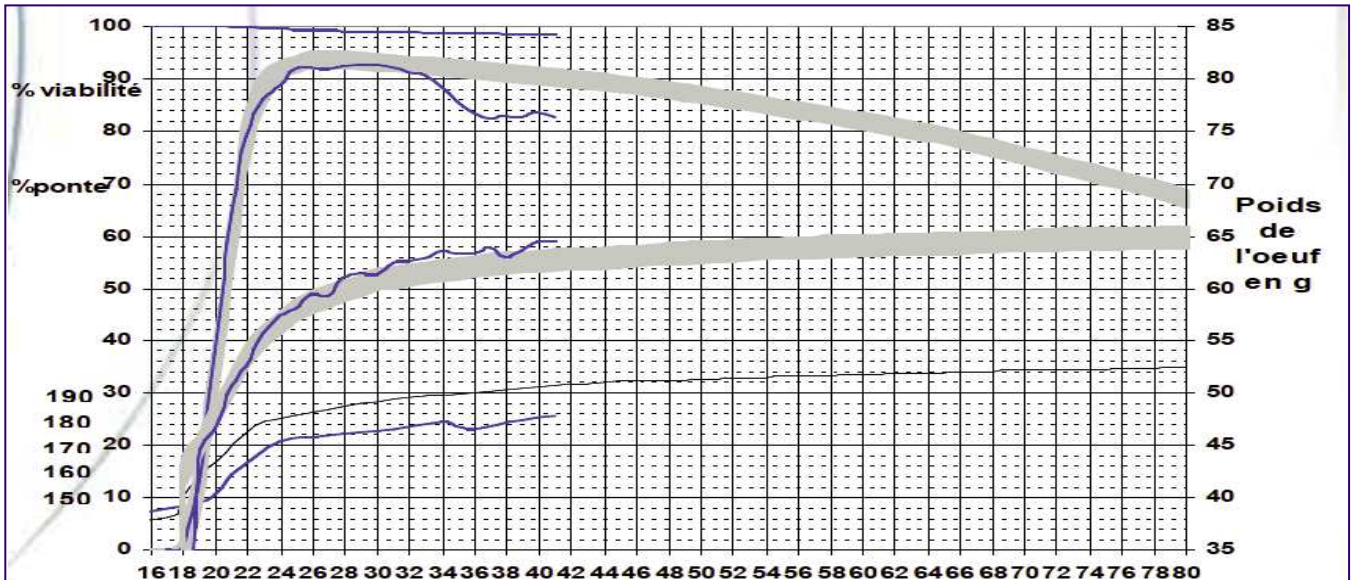


Fig.58.13: Avian intestinal spirochetosis. (*Brachyspira intermedia*). Drop in egg production and reduced egg weight.

Egg production may also be delayed and/or reduced (by 5-10%) with eggs of lower quality (smaller, lighter, poorer shell quality). Chicks hatched from affected breeders are weak and grow at a lower rate than expected. After a while, affected birds are prostrated with a shrunken comb.

There are no specific macroscopic lesions. The ceca may be dilated with foamy and watery content. Histological examination may reveal a moderate typhlitis, occasionally with the presence of spirochaetes.

DIAGNOSIS

Diagnosis is usually confirmed using microbiological techniques.

Direct microscopic examination of cecal droppings collected early (within 48 hours of the onset of clinical signs) allows for the observation of the characteristic helical bacteria.

The culture of *Brachyspira* from cecal droppings is long and difficult. It is carried out on blood agar under anaerobic conditions. Differentiation of *Brachyspira* species is not possible using routine morphological or biochemical criteria. Specific polymerase chain reaction (PCR) assays may be used to identify specific pathogenic strains.

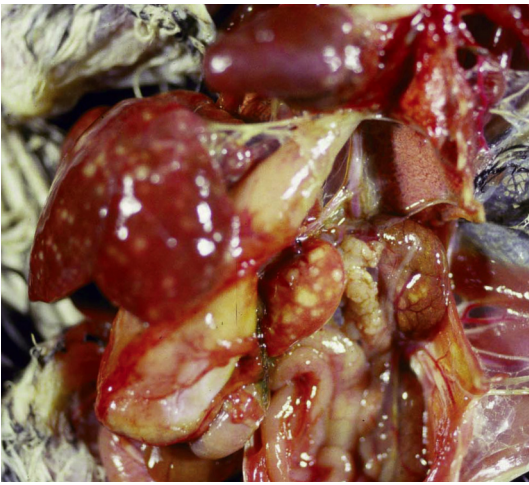
TREATMENT & CONTROL

Antimicrobials that have been used in drinking water to control AIS include tiamulin (important to avoid a toxic combination with ionophores), lincomycin or oxytetracycline. Treatment of infected laying flocks requires discarding eggs during the antibiotic withdrawal period. The diet should also be examined for its wheat content as well as all products that may cause wet litter problems.

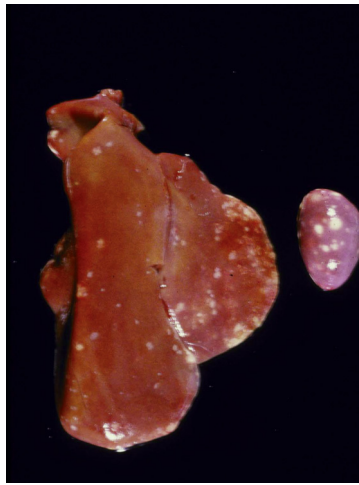
Control of AIS is not specific and is based on strict biosecurity to avoid entry of the pathogen in a flock and to prevent its spread between flocks.

REFERENCES

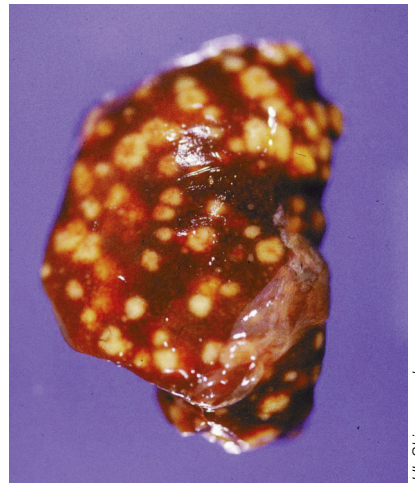- Boye M et al. Survival of *Brachyspira hyodysenteriae* and *B. pilosicoli* in terrestrial microcosms. *Vet Microbiol*, 2001,81:33-40.
- Burch DGS et al. Treatment of a field case of avian intestinal spirochaetosis caused by *Brachyspira pilosicoli* with tiamulin. *Avian Pathol*, 2006,35: 211-216.
- Hampson DJ et al. Zoonotic transmission of *Brachyspira pilosicoli* [letter]. *EID*, 2006,12: 869-870.
- Hampson DJ & Thomson JR. *Brachyspira* research – special issue on colonic spirochaetes of medical and veterinary significance. *J Med Microbiol*, 2004, 53:263-265.
- Hampson DJ & Swayne DE. Avian intestinal spirochaetosis. In “*Diseases of poultry*”. Ed. Saif YM, 12th Ed, Blackwell Publishing, Iowa, IA, 2008, pp 922-940.
- Jordan FTW & Hampson DJ. Some other bacteria. In *Poultry diseases*. Ed Pattison M et al, 6th edition. 2008, Elsevier, pp 243-256.
- Oxberry SL et al. *Serpulina pilosicoli*, water birds and water: potential sources of infection for humans and other animals. *Epidemiol Infection*, 1998,121: 219-225.
- Phillips ND et al. A wheat-based diet enhances colonisation with the intestinal spirochaete *Brachyspira intermedia* in experimentally-infected laying hens. *Avian Pathol*, 2004,33:451-457.
- Shivaprasad HL & Duhamel GE. Cecal spirochaetosis caused by *Brachyspira pilosicoli* in commercial turkeys. *Avian Dis*, 2005,49:609-613.
- Stephens CP & Hampson DJ. Intestinal spirochaete infections in chickens: a review of disease associations, epidemiology and control. *Animal Health Res Rev*. 2001,2:101-110.
- Stephens CP & Hampson DJ. Experimental infection of broiler breeder hens with the intestinal spirochaete *Brachyspira (Serpulina) pilosicoli* causes reduced egg production. *Avian Pathol*, 2002,31:169-175.
- Swayne DE et al. Association of cecal spirochetes with pasty vents and dirty eggshells in layers. *Avian Dis*. 1992,36:776-781.



HL Shivaprasad



HL Shivaprasad

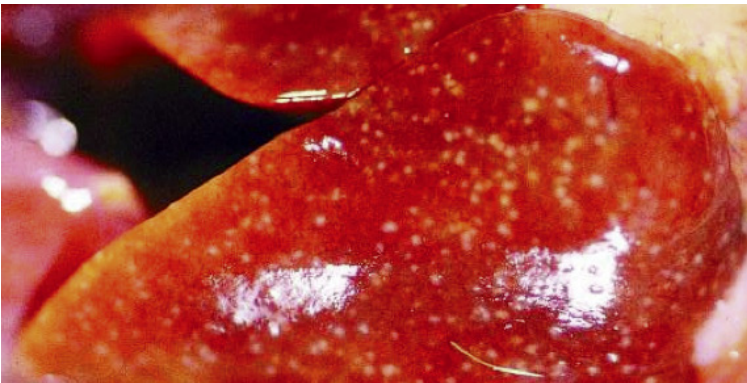


HL Shivaprasad

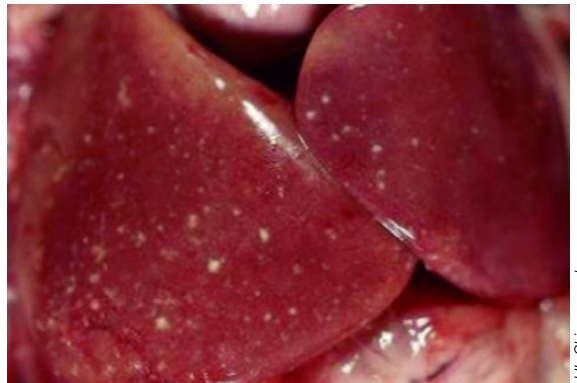Fig.59.1. Liver, spleen and kidneys with pale yellow nodules due to *Yersinia pseudotuberculosis* (Chicken).

Fig.59.2. Yersiniosis primarily involves liver and spleen (Chicken).

Fig.59.3: Liver with numerous pale yellow nodules from a Hornbill infected with *Y. pseudotuberculosis*.

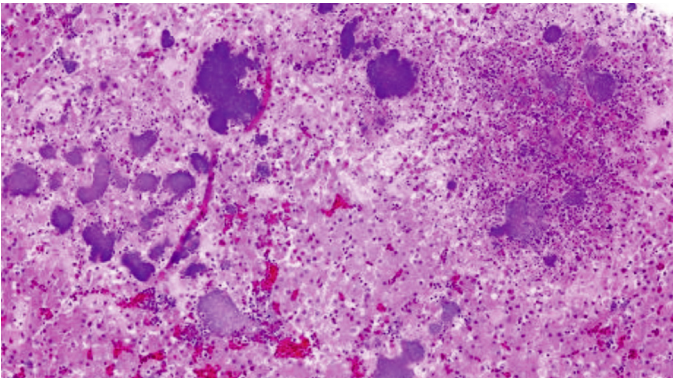


HL Shivaprasad

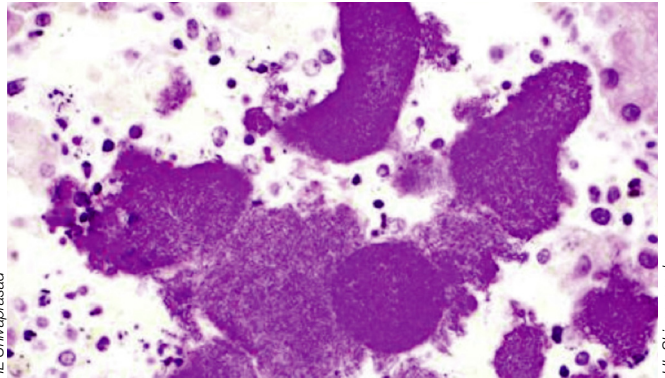


HL Shivaprasad

Fig.59.4 & 59.5: Livers from a cockatoo and scarlet macaw with acute foci of necrosis due to *Y. pseudotuberculosis*.

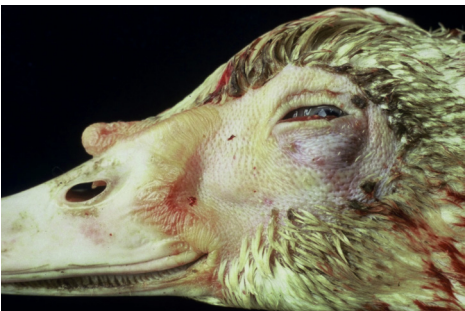


HL Shivaprasad

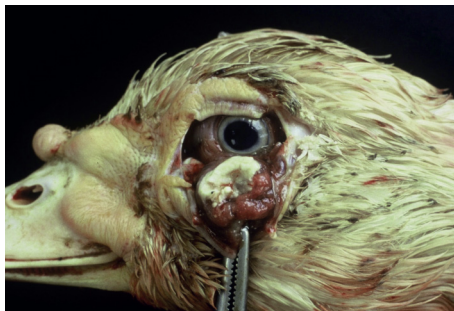

HL Shivaprasad

Fig.59.6 & 59.7: Photomicrographs of liver with acute necrosis of liver with inflammation and numerous bacteria (left) that are Gram negative (right).



LDA 22



LDA 22



LDA 22

Fig.59.8, 59.9 & 59.10: Yersiniosis (Duck). Conjunctivitis and sinusitis. Presence of a yellowish caseous exudate in the opening of the sinus. Splenomegaly (compare with the normal spleen on the right).

Bacterial diseases

59. YERSINIOSIS

INTRODUCTION

Yersiniosis is a septicemic disease of various species of birds caused by the bacterium *Yersinia pseudotuberculosis*. The disease has been reported in turkeys, ducks, and in *Passeriformes* (canaries and finches), *Psittaciformes* (parrots, parakeets), *Columbiformes* (pigeons and doves), *Piciformes* (toucans), *Cuculiformes* (turacos), raptors and other captive and free flying birds. Chickens are also susceptible to yersiniosis. Mammals including humans are also susceptible to *Yersinia pseudotuberculosis*.

ETIOLOGY & EPIDEMIOLOGY

The etiology of yersiniosis is *Yersinia pseudotuberculosis*. Other species of *Yersinia* such as *Y. pestis*, *Y. enterocolitica*, *Y. frederiksenii*, *Y. intermedia* and others have not been associated with disease in birds. *Yersinia* are Gram-negative rod-shaped bacteria than can be motile or non motile, depending on the incubation temperature. Pathogenic *Y. pseudotuberculosis* carries a virulent plasmid of which six serovars have been identified and serovar 1 is most commonly isolated from birds.

Yersinia spp. are ubiquitous in the environment and are worldwide in distribution. They have been isolated from many vertebrates and water. They multiply at low temperatures; therefore, infections are common in the winter and spring. Rodents (rats, mice), hares and rabbits and some wild birds serve as reservoirs. Transmission is probably through contaminated water, feed and environment. Factors such as cold weather, chilling and concurrent diseases can predispose the birds for yersiniosis. Among poultry, sporadic outbreaks have occurred in commercial turkeys.

CLINICAL SIGNS & LESIONS

Clinical signs due to yersiniosis depend on whether the disease is acute or chronic; the chronic form being more common. In general clinical signs include lethargy, diarrhea, dyspnea and dehydration. In chronic infections symptoms include loss of weight, swollen joints, and paresis. In one outbreak of 9-and-12-week-old turkeys, anorexia, watery yellow-green droppings, depression and acute lameness were observed with morbidity ranging from 2 to 15 % with increased mortality due to cannibalism. Conjunctivitis and sporadic mortality were observed in a breeder flock of Muscovy ducks due to several yersiniosis outbreaks eight years apart. The disease reoccurred periodically in spite of treatment with tetracyclines. In acute infections of some species of birds such as wood peckers, toucans

and turacos there may not be any clinical signs but birds are found dead.

Gross lesions due to yersiniosis primarily involve liver and spleen. These organs can be enlarged with either a few pale foci of necrosis or yellow granulomas scattered throughout. Similar foci can also be found in the lungs, heart, kidneys, skeletal muscles and swollen joints. In addition catarrhal enteritis, osteomyelitis and myopathy have been described in turkeys. In passerines, such as canaries and finches, the predominant lesions were enteric, characterized by enlargement of the cecal tonsils and adhesions between the intestinal wall and the pancreas.

Histologically acute lesions generally consist of mild to severe necrosis of the parenchyma accompanied by fibrinosuppurative or fibrinoheterophilic inflammation usually associated with numerous colonies of Gram-negative bacteria of bacilli morphology. In chronic infections these necrotic foci and inflammation will be surrounded by multinucleated giant cells.

DIAGNOSIS

A presumptive diagnosis can be made based on clinical signs, gross and microscopic lesions. Gram stain of smears from lesions can provide a tentative and quick diagnosis. Gross lesions in liver and spleen and other organs have to be differentiated from other bacterial diseases, such as mycobacteriosis, salmonellosis, etc. *Y. pseudotuberculosis* can be isolated readily from most lesions such as liver, spleen, bone, joints, lungs, intestine and other organs.

TREATMENT & CONTROL

Y. pseudotuberculosis is ubiquitous in the environment and water. Steps should be taken to reduce their numbers: biosecurity implementation, total confinement of birds, bird and rodent proofing of the houses and aviaries are essential for preventing yersiniosis. Treating chronic infections can be extremely difficult. Prompt diagnosis and use of tetracyclines have been beneficial in reducing mortality in outbreaks of yersiniosis in turkeys and ducks.

Antimicrobial testing of isolates of *Y. pseudotuberculosis* has shown that antibiotics such as ampicillin, penicillin, ceftiofur, enrofloxacin, spectinomycin, tetracyclines, sulfonamides, neomycin, ormetoprim/sulfa, and gentamicin can be effective in treatment. However, sensitivity tests should be performed on each isolate before antibiotics can be used.

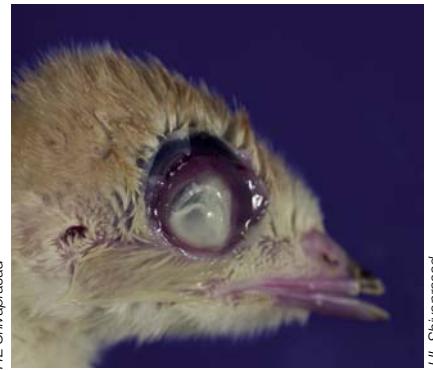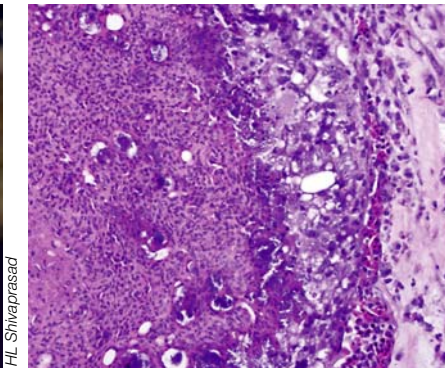

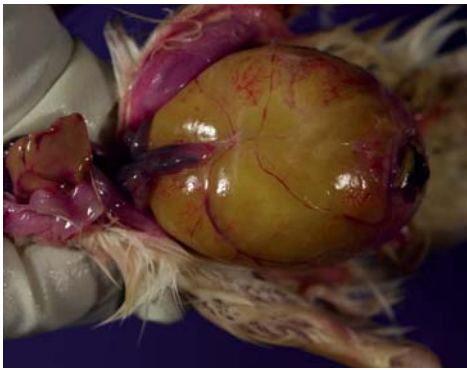
Fig.60.1: *Pseudomonas* is commonly associated with hatchery and incubation problems and yolk sac infections. Severe omphalitis (umbilicus and yolk sac inflammation) due to *P. aeruginosa* in a 3-day-old chick.

Fig.60.2: Yolk sac of 3-4-day-old chick with severe fibrinosuppurative inflammation interspersed by bacterial colonies of *P. aeruginosa*. H & E.

Fig.60.3: Severe ophthalmitis due to *P. aeruginosa* in a 2-week-old turkey poult.

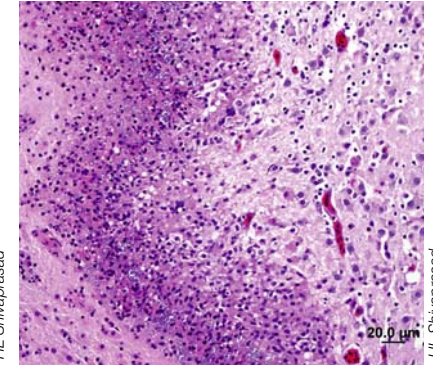
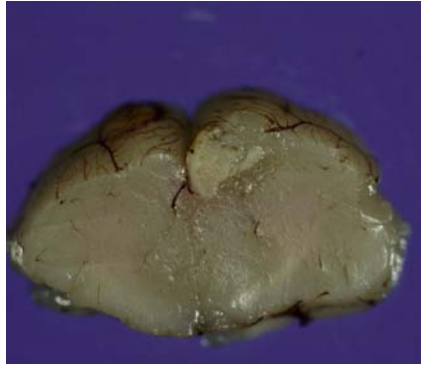
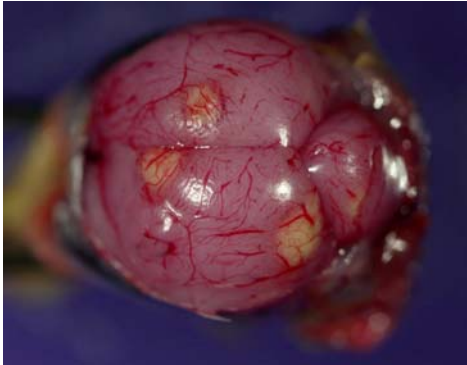
Fig.60.4: Multiple pale yellow foci in the brain of ducklings due to *P. aeruginosa*.

Fig.60.5: Cut surface of the brain from the same bird showing pale yellow focus due to *P. aeruginosa*.

Fig.60.6: Brain of a duckling showing severe encephalitis associated with colonies of *P. aeruginosa*. H & E.

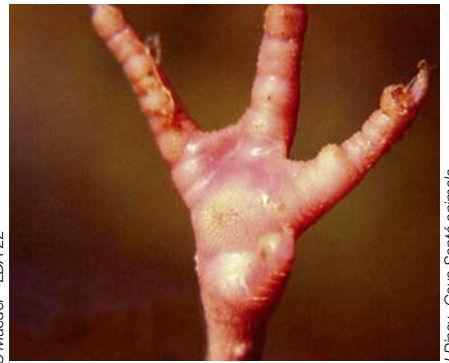
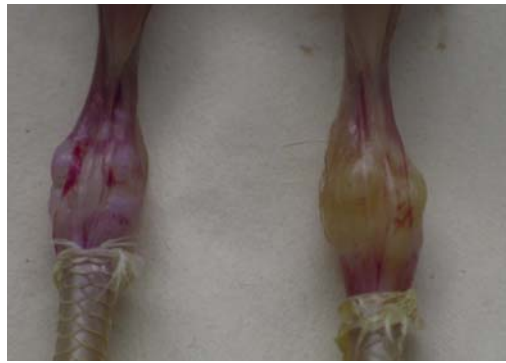
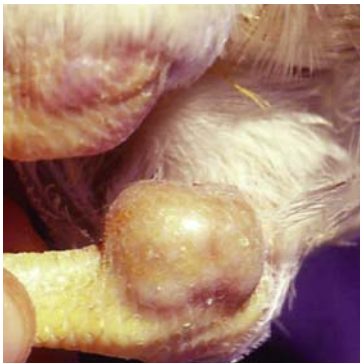Fig.60.7 & 60.8: Pseudomoniasis. Arthritis and peri-arthritis in broilers. Tibiotarsal joints are the most commonly affected.

Fig.60.9: Pseudomoniasis. Pododermatitis and inflamed foodpad.

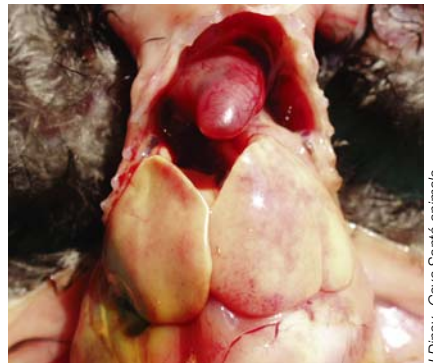
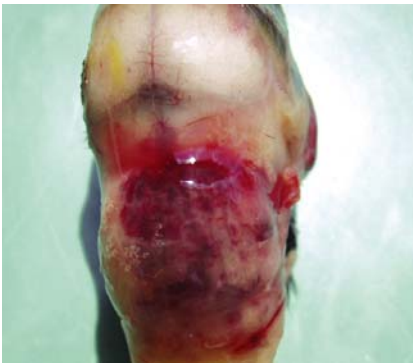
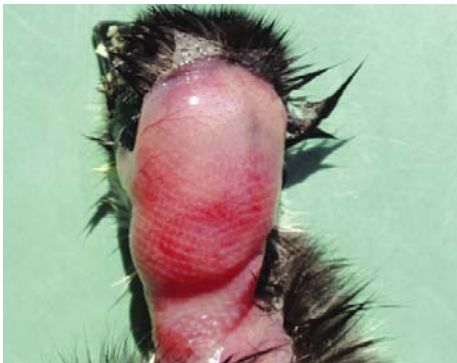
Fig.60.10 & 60.11: *Pseudomonas* spp. infection via a contaminated injectable Marek's vaccine. About 24 h after the vaccination, nervous signs are appearing: incoordination, ataxia, etc. Automatically vaccinated chickens exhibit subcutaneous edema and hemorrhage in the region of the neck, sometimes involving the head.

Fig.60.12: Pseudomoniasis. In the liver, hyperemia, subcapsular hemorrhages and dystrophy are detected.

Bacterial diseases

60. PSEUDOMONIASIS

INTRODUCTION

Pseudomonas can cause localized or generalized disease in chickens and turkeys of all ages. In poultry *Pseudomonas* is most commonly associated with hatchery and incubation problems and yolk sac infections. *Pseudomonas* can also cause infection in other species of birds, such as ducks, geese, pheasants, ostriches, pet and captive birds.

ETIOLOGY & EPIDEMIOLOGY

Pseudomonas aeruginosa is the most common species that causes infections in poultry and other birds. *Pseudomonas* is a motile, Gram-negative, non-spore forming aerobic rod-shaped bacteria. Other species such as *P. fluorescence* has been associated with death of turkey embryos and *P. stutzeri* has been isolated from chickens with respiratory disease. *Pseudomonas (Burkholderia) pseudomallei* infections have been reported from Australia in psittacines that had septicemic lesions.

Pseudomonas organisms are ubiquitous in nature and are most commonly found in contaminated water and soil. *Pseudomonas* is generally considered an opportunistic bacterium that can cause various clinical signs and pathology. Young birds as well as stressed and immunodeficient birds are very susceptible to *Pseudomonas*. Other factors such as concurrent infections with viruses and bacteria can influence infection. Severe outbreaks have also occurred due to the use of contaminated vaccines and antibiotics as a result of poor hygienic conditions during mixing and handling of these products.

Pseudomonas is one of several bacteria that are commonly isolated from dead embryos, newly hatched chicks, poults, ducklings and others. Contact with infected birds, continuous intense management of broilers and turkeys with different ages and without periodic change of litter and cleaning and disinfection influence the spread of bacteria. *P. aeruginosa* has also been isolated from the surface of eggs and skin of processed broiler chickens.

CLINICAL SIGNS & LESIONS

Clinical signs due to *Pseudomonas* spp. in poultry depend on whether the disease is localized or systemic. These include ruffled feathers, anorexia,

stunting, depression, weakness, respiratory signs, swelling of the head, swollen joints or foot pads, lameness, opisthotonus, diarrhea, corneal opacity and swollen conjunctiva. Sudden death without any apparent clinical signs is also common. Morbidity and mortality can vary from 2 to 10% but can be much higher depending upon management factors and concurrent diseases.

Gross lesions due to *Pseudomonas* are not specific and may include yolk sacs which may have watery yellow or caseous exudate, swollen joints with fibrinous exudate, edema and fibrin in the subcutis, fibrinous exudate in the anterior chamber of the eyes, pericardium, air sac, and capsule of the liver; necrotic foci in the liver, spleen, kidneys and occasionally in the brain. Nasal gland adenitis associated with *P. aeruginosa* has been reported in ducks. Histologically the lesions of a *Pseudomonas* infection generally consist of mild to severe fibrinosuppurative or fibrinoheterophilic inflammation mixed with large numbers of rod-shaped Gram-negative bacteria.

DIAGNOSIS

Tentative diagnosis of *Pseudomonas* infections can be made based on careful analysis of the history in combination with clinical signs, gross and microscopic lesions. Demonstration of Gram-negative rods in the smears from lesions can provide a tentative and quick diagnosis. Definitive diagnosis can be made by isolation on suitable media and identification of the organisms. *Pseudomonas* spp. can be isolated from various lesions such as yolk sac, pericardium, air sacs, joints, liver, lungs, skin and other organs.

TREATMENT & CONTROL

Steps should be taken to identify and eliminate the source of *Pseudomonas* spp. Cleaning and disinfection of the incubators, hatchers, equipment and the environment are fundamental to the control and prevention of *Pseudomonas* spp.

Due to the antimicrobial resistance of *Pseudomonas* spp., sensitivity tests should be performed frequently. Some of the antibiotics that may be helpful in reducing losses include gentamicin, streptomycin, amikacin, enrofloxacin.

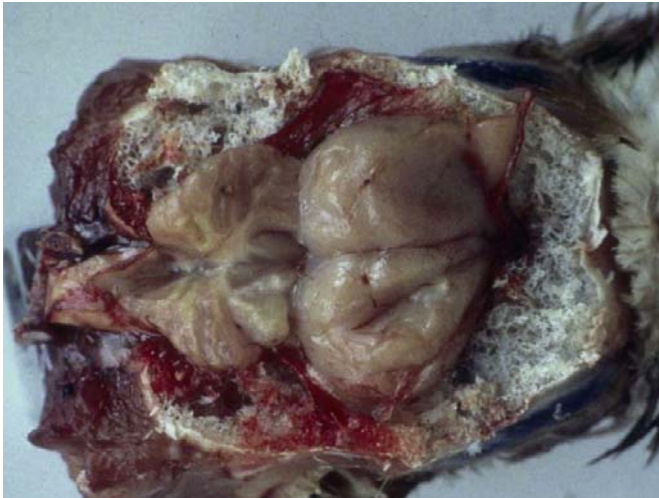


LDA 22

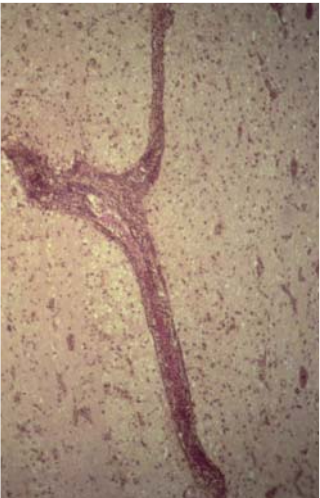


LDA 22

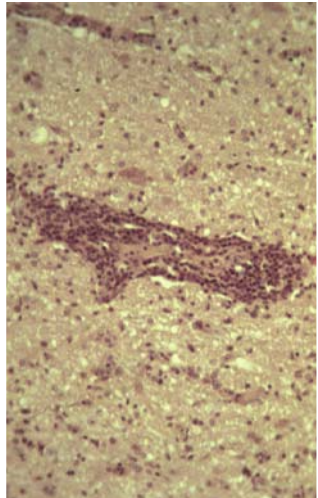
Fig.61.1 & 61.2: Listeriosis (Chicken). Birds affected by the encephalitic form present depression and torticollis (left), and paralysis with lateral decubitus (right).



LDA 22



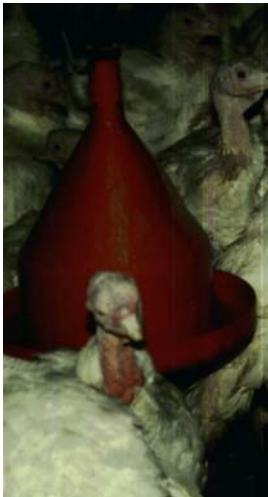LDA 22



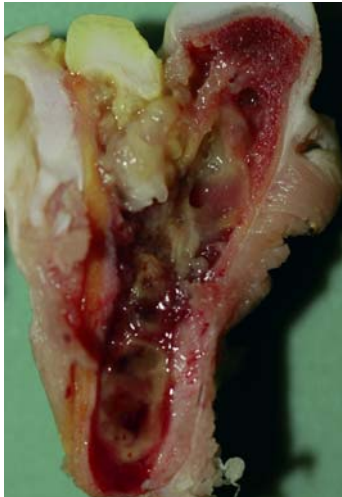LDA 22

Fig.61.3: Listeriosis (Chicken). Necrotic foci can be seen in the brain.

Fig.61.4 & 61.5: Listeriosis (Chicken). Microscopically, lymphoid perivascular cuffing is seen in this bacterial encephalitis.

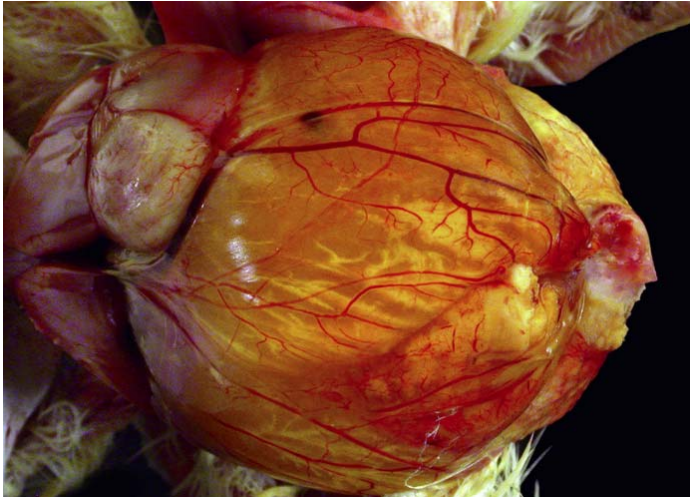


D Venne



MT Casaubon Huguenin

Fig.61.6 & 61.7: *Archanobacterium pyogenes*. This pyogenic organism can be isolated from skin lesions (facial cellulitis in a turkey, left), osteomyelitis (Fig.61.7, right) or sepsis.



HJ Barnes

Fig.61.8: A wide variety of bacteria have being isolated from yolk sac infections, *Escherichia coli* being frequently encountered.

Bacterial diseases

61. OTHER BACTERIAL DISEASES

INTRODUCTION

Other bacterial diseases that are not covered under specific chapters can sporadically cause disease in poultry, but their impact on poultry production is often limited. Some can have an impact on public health (e.g., *Bacillus anthracis*, *Brucella*, *Listeria*, *Coxiella*, *Francisella*, etc.) (see Chap.V.83). Others include reclassified bacteria (*Gallibacterium*) or newly recognized species (*Coenomia* and *Pelistega*).

LISTERIA MONOCYTOGENES

Outbreaks of listeriosis occur sporadically in poultry. *Listeria monocytogenes* is a Gram-positive, nonsporing bacillus or cocobacillus. It is ubiquitous and found in soil, silage, rotting vegetation, surface water, and in poultry meat and in the intestine of diseased and apparently healthy birds.

The infection of poultry is of public health importance because it can be a source of infection for humans through droppings and meat. It is important to realize that the organism will continue to grow in some prepared foods kept at low temperatures, making it a significant foodborne disease. Bird droppings can also be a source of infection for ruminants.

Infection can follow ingestion, inhalation or wound contamination. Young birds are more susceptible than adults and outbreaks can be associated with a stress (e.g., beak trimming, cold and wet environment).

Septicemic and encephalitic forms of listeriosis are recognized in birds. Mortality can vary from very few to up to 40% of an affected flock. Emaciation and diarrhea are observed with the septicemic form. The encephalitic form leads to incoordination, ataxia, torticollis, paralysis and opisthotonos.

The gross lesions associated with septicemia are varied and include myocarditis with pale necrotic foci, hydropericardium, focal hepatic necrosis, nephritis, airsacculitis, salpingitis, enteritis, and conjunctivitis. With the encephalitic form, small necrotic foci can be seen in the cerebellum, mid-brain and medulla. Microscopically, Gram-positive bacteria can be observed in the lesions. Encephalitis with perivascular cuffing is typical of this bacterial disease.

Signs and lesions are not pathognomonic. Confirmation of disease can be achieved via isolation of *L. monocytogenes*, demonstration of specific antigen or DNA detection. Since antibodies to *L. monocytogenes* are widespread in the blood of apparently normal animals, serological testing is not used for detecting infection.

Differential diagnosis includes septicemic and neurologic diseases (e.g., Newcastle disease, avian influenza, fowl cholera, fowl typhoid, *Pseudomonas aeruginosa* infection) and also intoxications.

OTHER MISCELLANEOUS BACTERIA

Acinetobacter spp. is occasionally recovered from dead-in-shell embryos and weak chicks or poults, from outbreaks of septicemia in chickens, ducks or turkeys (with necrosis and green discoloration of liver), and from arthritis in pigeons and ducks.

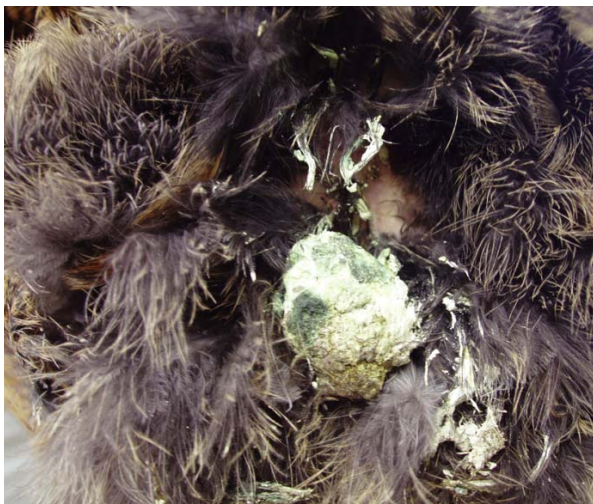Aegyptianella pullorum, closely related to *Anaplasma* spp., is the cause of a tick-borne disease (transmitted by a tick of the genus *Argas*) observed in tropical and subtropical areas in a variety of domestic and wild birds. Clinical signs include increased mortality and severe anaemia (with ascites and right ventricular failure).

Aeromonas spp. is among bacteria recovered in dead-in-shell embryos and weak chicks, or in lesions of arthritis, cellulitis, diarrhea, and systemic infections. *Aeromonas* is of public health significance because it can cause gastroenteritis, septicemia or myonecrosis in people.

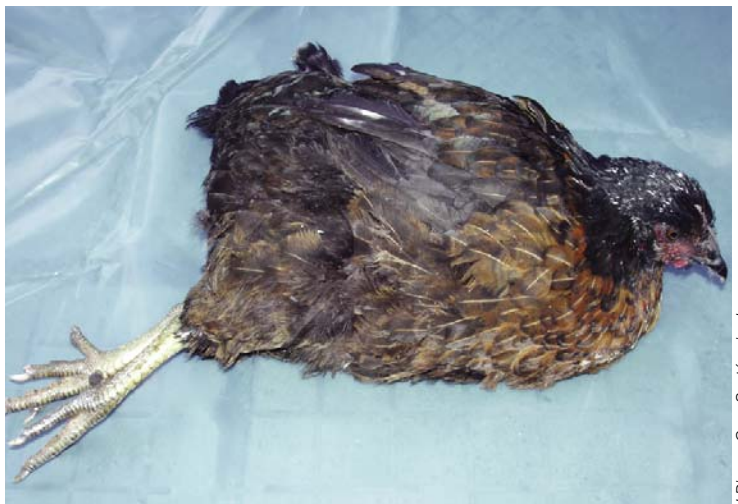Arcanobacterium pyogenes (formerly called *Corynebacterium* and later *Actinomyces*) can be found in serous outbreak of osteomyelitis in turkeys or septicemia and skin lesions in caged layers.

Bacillus spp. can be found in embryo mortality and yolk sac infections in chickens. *Bacillus cereus*, an organism that can cause a foodborne illness in people, can infect turkey hens during artificial insemination.

Borrelia anserina, transmitted by the fowl tick (*Argas persicus*), causes spirochaetosis in avian species (including domestic species, mainly in young fowl) in tropical and subtropical areas.

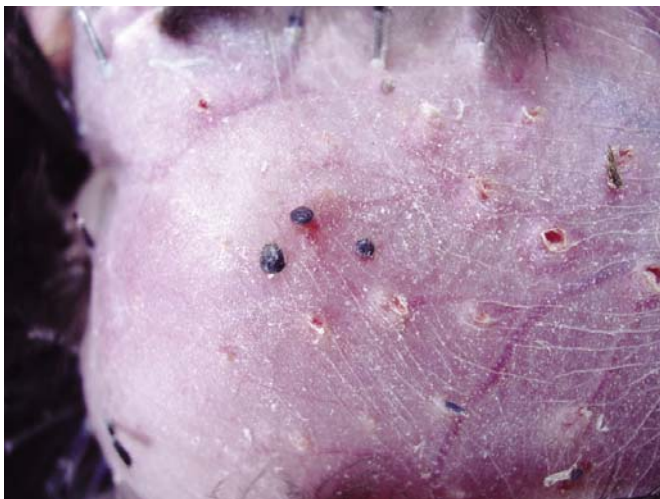

I Dinev - Ceva Santé animale



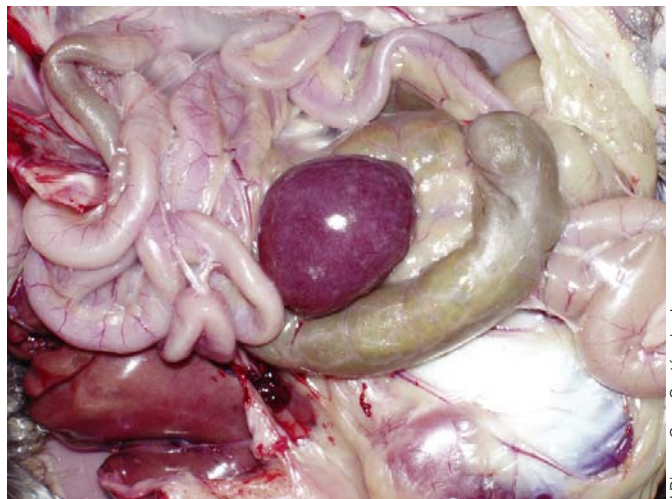
I Dinev - Ceva Santé animale

Fig.61.9 & 61.10: Spirochaetosis. This septicemic disease caused by *Borrelia anserina* is characterized by depression and greenish diarrhea with a considerable amount of urate (on left) and progressive paralysis at a later stage of the disease (on right).



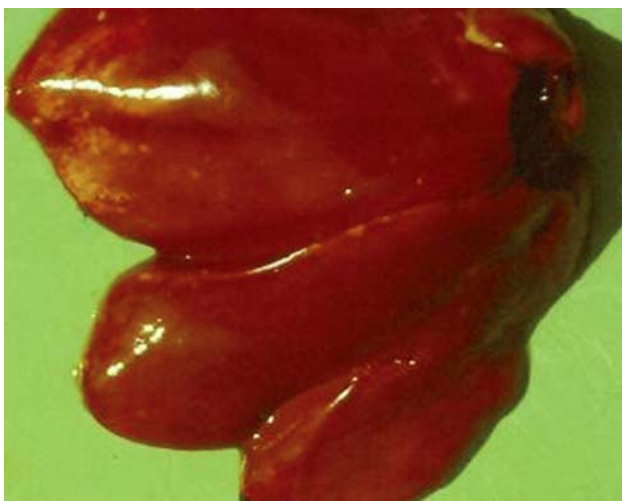I Dinev - Ceva Santé animale

Fig.61.11: Spirochaetosis. After removal of feathers, ticks (*Argas persicus*) can be found adhering to the skin.



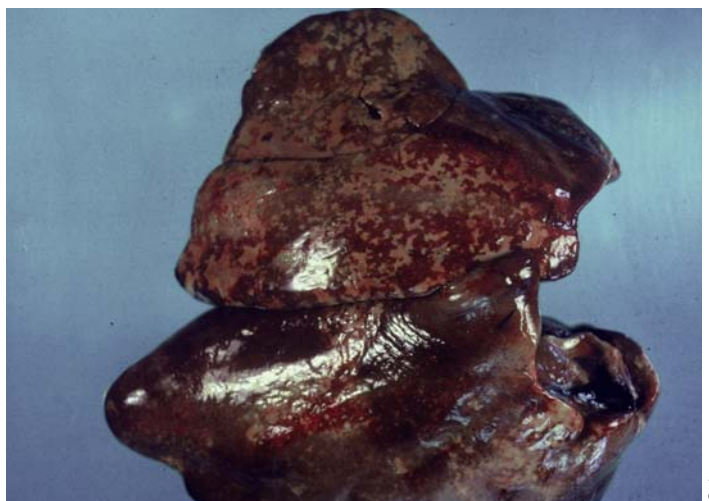
I Dinev - Ceva Santé animale

Fig.61.12: Spirochaetosis. Marked enlargement and mottling of spleen is typical of spirochetosis but may not be obvious if birds are infected with low virulent strains of *Borrelia anserina* or early in the disease.



I Dinev - Ceva Santé animale

Fig.61.13: Spirochaetosis. Livers are often enlarged and contain small hemorrhages, pale foci, or marginal infarcts.



Solway

Fig.61.14: Vibronic hepatitis.

Clinical signs include anorexia, fever, depression, cyanosis of the head and anaemia. Marked enlargement and mottling of spleen is typical of spirochaetosis. Hepatitis, nephritis and pericarditis can also be present. The spirochetes can be found in stained blood smears. Penicillin and a number of other antibiotics are usually very effective.

Birds can also develop asymptomatic infections with *Borrelia burgdorferi*, causing Lyme disease in people. Wild birds, as carriers, play an important role in the transmission of Lyme borreliosis. In Slovakia, between 21% and 52% of captured wild birds tested positive for *Borrelia burgdorferi* in 2006 with the proportion infected depending on bird species and region.

Citrobacter is one of many environmental bacteria that are occasionally isolated from unhatched eggs, weak chicks and yolk sacs or respiratory infections.

Caenonia causes exudative septicemia in ducks and geese.

Coxiella burnetti, the causal agent of Q fever in humans, can also infect different animal species including birds.

Enterobacter, normal inhabitant of the digestive tract, can infect eggs and young birds (embryo loss, omphalitis) or turkeys (cellulitis).

Gallibacterium spp., a member of the family *Pasteurellaceae*, was isolated from salpingitis, septicemia and/or pneumonia in ducks, pigeons, turkeys, geese, pheasants, chickens, ostriches and psittacines.

Hafnia alvei has been identified as a cause of septicemia in pullets and laying hens.

Helicobacter pullorum, from the enterohepatic group *Helicobacter*, was isolated from «vibrionic hepatitis» in layers. *Helicobacter pullorum* may have public health significance (association with gastroenteritis, bacteremia, liver and gallbladder diseases in humans). Other *Helicobacter* species found in birds (*H. Canadensis*, *H. anseris* and *H. brantae*) are suspected of being possible human pathogens.

Klebsiella is an environmental contaminant that occasionally causes disease in poultry (embryo

mortality, yolk sac infections, respiratory, ocular, systemic or/and reproductive diseases).

Lawsonia intracellularis causes proliferative enteropathy in many animal species, especially pigs. The disease has been reported in ratites.

Moraxella olosensis has been isolated from turkeys with a disease similar to fowl cholera and from layers with salpingitis.

Mycobacterium avium subsp. *paratuberculosis* can infect chickens under experimental conditions. Birds can serve as reservoir for the bacteria causing paratuberculosis in ruminants.

Neisseria spp., found in soil as saprophyte, can be implicated in respiratory diseases of chickens and turkeys (*N. weaveri*). It may also affect ostriches and cause a venereal disease in geese.

Nocardia spp., found in soil as saprophyte and causing granulomatous lesions, is rarely isolated in poultry. A systemic nocardiosis has been reported in pigeons.

Pelistegea europea has been isolated in cases of respiratory disease in pigeons.

Planococcus halophilus has been isolated in layers with hepatic necrosis.

Proteus inhabits the lower intestinal tract. *Proteus* can penetrate the eggshell after fecal contamination and cause embryonic mortality, yolk sac infection, and mortality in young chickens. *Proteus* can also be implicated in cases of septicemia in quails, in reproductive lesions in layers, and in cellulitis or respiratory lesions in chickens.

REFERENCES

- Abdul-Aziz T & Barnes HJ. Miscellaneous and sporadic bacterial infections. In “*Diseases of Poultry*”. 13th ed., DE Swayne Ed., Wiley Blackwell 2013, pp 1017-1027.
- Gronesova P et al. Prevalence of avian influenza viruses, *Borrelia garinii*, *Mycobacterium avium*, and *Mycobacterium avium* subsp. *paratuberculosis* in waterfowl and terrestrial birds in Slovakia, 2006, *Avian Pathol*, 2008,37: 537-543.
- Jordan FTW & Hampson DJ. Some other bacteria. In “*Poultry diseases*”. Ed Pattison M et al, 6th edition. 2008, Elsevier, pp 243-256.

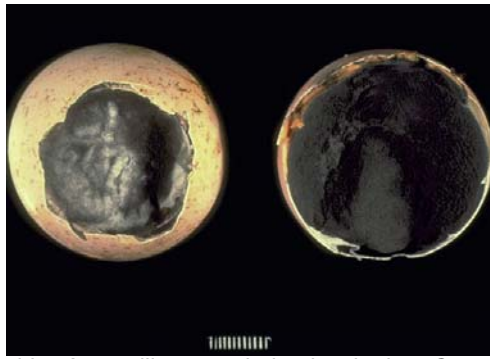
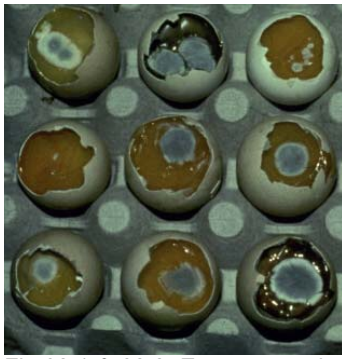


Fig.62.1 & 62.2: Eggs contaminated by *Aspergillus* spp. during incubation. Green to dark mycelium is seen in the air cell.

Fig. 62.3: Young chicks showing clinical signs of aspergillosis (brooder pneumonia) gasping (left) and nasal bleeding (right).

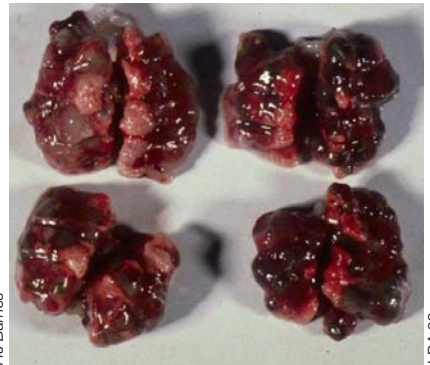


Fig. 62.4: Aspergillosis (brooder pneumonia). Respiratory difficulties (dyspnea).

Fig.62.5: Adult turkey showing clinical signs of aspergillosis with respiratory difficulty and cyanosis.

Fig.62.6: *Aspergillus* nodules in the lungs of three day-old chickens.

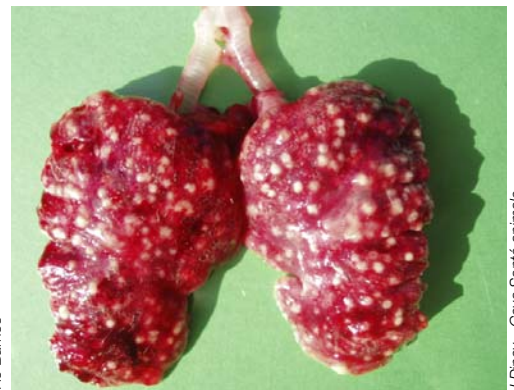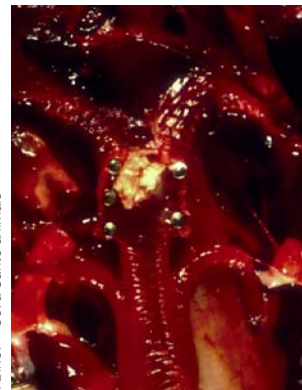
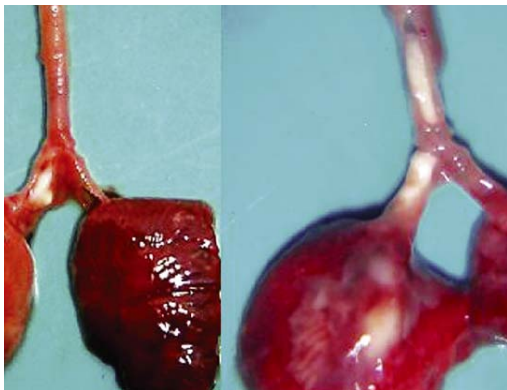


Fig.62.7: Acute form of aspergillosis, serous fibrinous pneumonia, plugs of coagulated fibrinous exudate in trachea and bronchi, near the bifurcation.

Fig.62.8: Obstruction of trachea can be seen with *Aspergillus* nodules.

Fig.62.9: Pulmonary aspergillosis is characterized by multiple grey whitish or yellowish dense nodules.

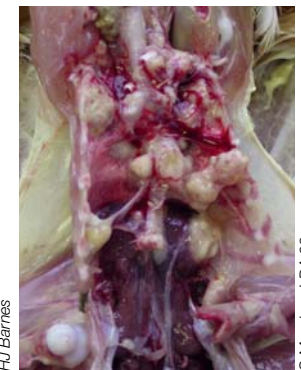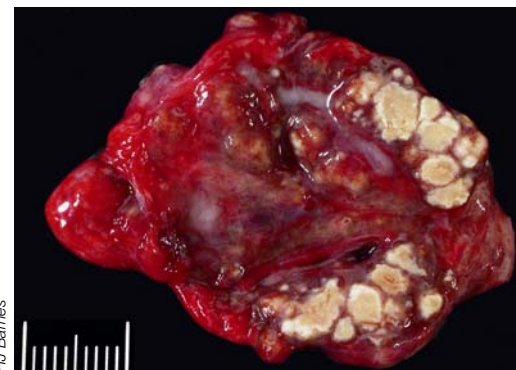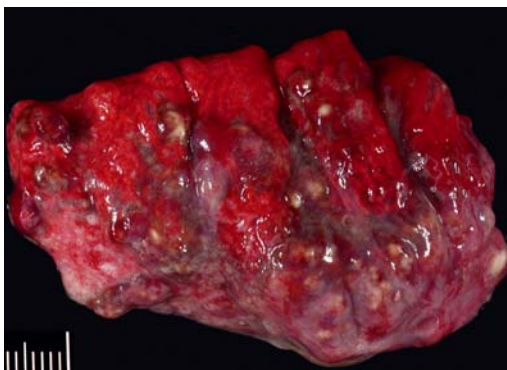


Fig.62.10, 62.11 & 62.12: Respiratory aspergillosis in the lung showing large and extensive caseous nodules.

Other diseases

62. FUNGAL DISEASES

INTRODUCTION

Important fungal diseases of poultry invade organs and damage tissues (invasive fungi) or produce toxins in the feed, causing toxicosis (*cf.* next chapter on mycotoxicoses). Except for the only contagious and zoonotic disease, dermatophytosis (known as ringworm or tinea in humans) affecting the skin, mycoses are not transmissible diseases. Aspergillosis is the most prevalent mycosis of birds, affecting the respiratory tract, followed by candidosis, principal fungal infection of the digestive tract of poultry. Ochrochonosis (dactylariosis) is relatively rare and causes sporadic fungal encephalitis in birds. In avian species, zygomycoses (infections by *Mucor*, *Rhizopus*, *Absidia*, *etc.*) are uncommon (some observations of airsacculitis, ventriculitis or proventriculitis). Finally, some rare fungal infections of poultry may represent a risk to people (histoplasmosis, cryptococcosis).

ASPERGILLOSIS

Definition

Aspergillosis in birds affects primarily the lower respiratory tract (synonyms: brooder pneumonia, mycotic pneumonia, pneumomycosis). Less common localizations are the eye, brain, skin, joints and viscera. Systemic infection can also occur. Aspergillosis can be acute or chronic. Acute disease is usually characterized by outbreaks in young birds with high morbidity and mortality. Chronic disease, observed in adult birds, is economically important. Aspergillosis is a relatively common disease associated with poor management conditions found in confined as well as free-range poultry productions. Turkeys and chickens are more frequently affected though all species of birds are susceptible (guinea-fowl, game birds, *etc.*).

Etiology & epidemiology

Aspergillus fumigatus is the most common etiologic agent, but *A. flavus*, *A. niger*, *A. glaucus* and *A. terreus* can also be isolated by order of decreasing frequency. These organisms are common worldwide soil saprophytes that grow on organic matter in warm (>25°C) humid environments including embryonated eggs with shell damage in incubators and hatchers, ventilation systems, litter and feed.

The organism grows well on most common laboratory media; however, Sabouraud's dextrose, for example, is more selective.

Factors having an impact on the incidence and severity of the condition include cold stress, high ambient ammonia and dust concentrations, overcrowding, concurrent debilitating factors and immunosuppression. The natural resistance of healthy birds can be overwhelmed by massive exposure.

Aspergillosis is not a transmissible disease. Infection is acquired by spore inhalation. The infection often originates from the hatchery. Spores (conidia) of *A. fumigatus* enter the air cell of eggs *via* shell cracks (or microcracks after *in ovo* injections) followed by fungal growth in the air cell (air cell mycosis). Infected eggs with dead embryos will appear green when candled. Hatchery contamination originates from infected eggs that are opened during incubation or hatching. Contamination within the hatchery can also originate from the air ducts or other equipment.

Aspergillosis can also result from the inhalation of spores from contaminated feed or litter. Fungal growth in wet litter produces large numbers of spores that can be released as the litter dries. This is why other cases of aspergillosis may appear some time after young birds are found to be affected or, much later, in adults.

The spores are small enough (2-3 µm in diameter) to bypass the physical barriers of the upper respiratory tract (although they are found on the conjunctival, nasal, and tracheal epithelia) and are deposited deep in the lower respiratory tract (parabronchial and air sac epithelia) where they germinate and form granulomas at these sites. Subsequently, they disseminate *via* the bloodstream to other organs or tissues. This route of exposure explains the lesions found in the brain, pericardium, bone marrow, kidney and other soft tissues. Cutaneous lesions are rare in avian species. Fungal proliferation tends to be confined within the expanding granulomas where the organism is sporulating asexually.

Chronic disease is often associated with pulmonary granulomas impeding pulmonary blood flow causing right-ventricular dilatation and ascites.

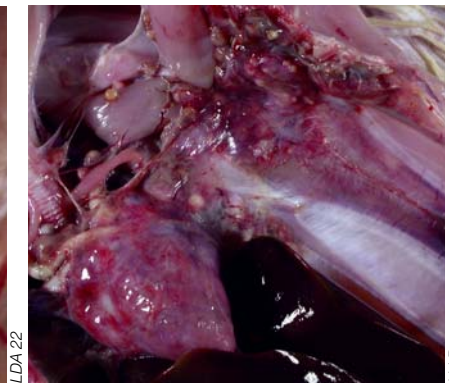
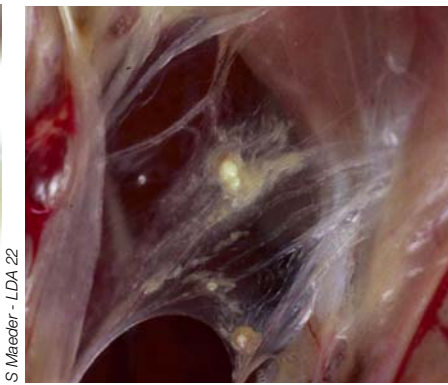
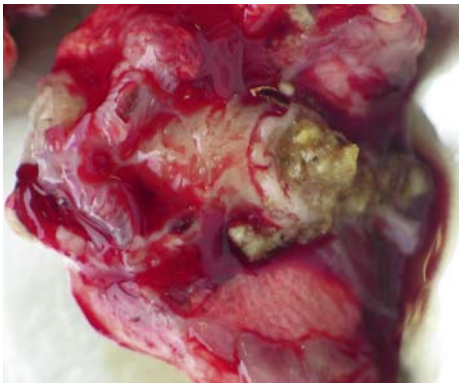


Fig.62.13: *Aspergillus* nodules can invade most of the pulmonary tissues.

Fig.62.14 & 62.15: Caseous nodules due to aspergillosis in an air sac.

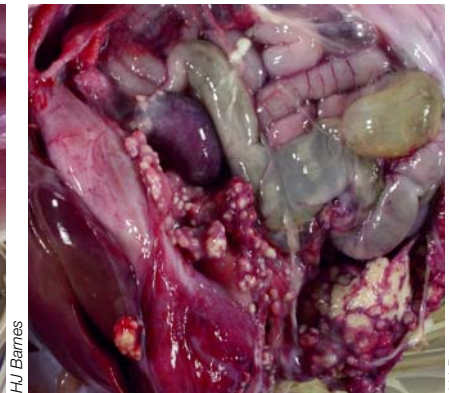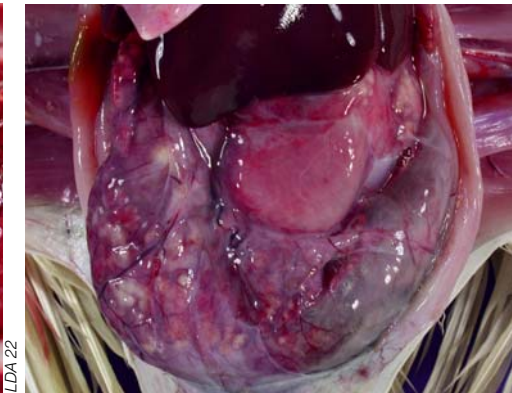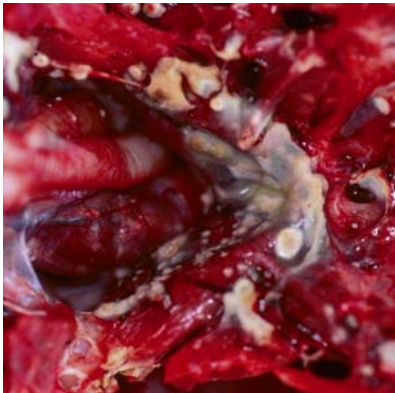


Fig.62.16, 62.17 & 62.18: Aairsacculitis (62.16) and peritonitis (62.17 & 62.18) with *Aspergillus* granulomas.

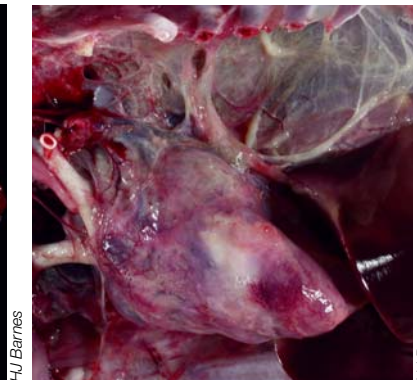
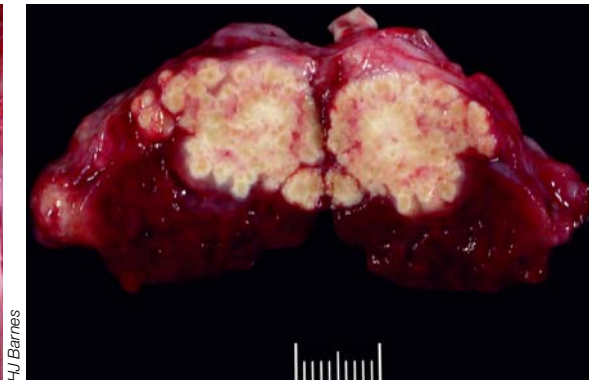
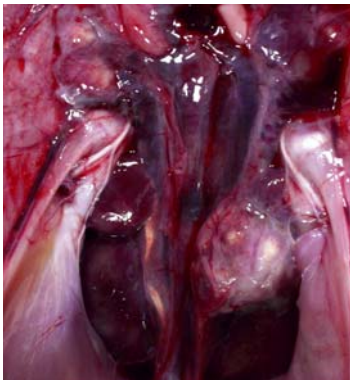

Fig.62.19 & 62.20: Kidney aspergillosis.

Fig.62.21: Heart aspergillosis.

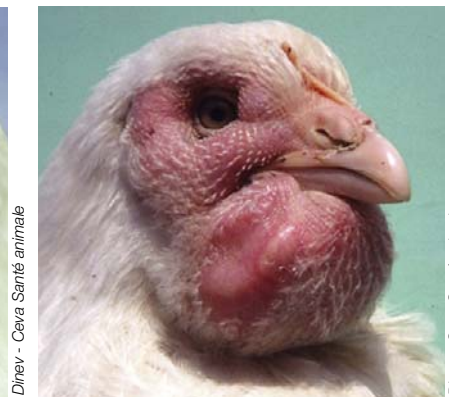
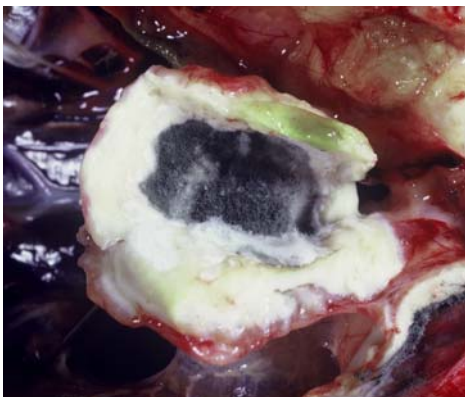


Fig.62.22. Sometimes, maturing *Aspergillus* sp. conidia can be seen in air sacs (Guinea-fowl).

Fig.62.23 & 62.24: *Aspergillus* granulomatous dermatitis. Swelling can involve the entire head and neck.

Pathogenic species of *Aspergillus* spp., particularly *A. fumigatus* and *A. flavus*, produce toxins that can be involved in the pathogenesis of aspergillosis in poultry. For example, gliotoxin, produced by various isolates of *A. fumigatus*, is immunodepressive and cytotoxic. *Aspergillus fumigatus* also produces a number of proteolytic enzymes that degrade host tissues.

Clinical signs & lesions

In birds contaminated at the hatchery, clinical signs appear three to five days post-exposure with respiratory signs: dyspnea, polypnea, open-mouth breathing (gaspings) due to progressive airway obstruction. Death follows quickly. Dyspnea is without rales or other respiratory sounds. In the acute respiratory form, the mortality rate varies between 5 and 50% in the first one to three weeks of age. Survivors are weakened, often showing chronic respiratory signs with 5% mortality. They may become lethargic and stunted. Other clinical signs are related to the localization of infection: torticollis and other central nervous system abnormalities, conjunctival swelling.

In chronically infected adult birds, the disease may remain subclinical but with progressive respiratory difficulties. Occasionally, aspergillosis-induced exudate lodged in the trachea and the syrinx can lead to asphyxiation.

An *Aspergillus* granulomatous dermatitis may emerge following postvaccinal complications.

Lesions are found in the respiratory tract (trachea, bronchi, lungs and air sacs). Gross lesions vary from small plaques to nodules of 1 mm to 9 mm in size that are white to yellow. Lesions in the air sacs may show mycelia producing conidiophores with conidia. These sporulating colonies of *A. fumigatus* are blue-green and are visible to the naked eye. Granulomas can also be found in the brain, eyes and viscera. In older birds, lung lesions are generally more important and their center often contains a characteristic pigmented mycelium.

Eye infections are usually unilateral and begin with lacrimation followed by conjunctivitis.

Microscopically, *Aspergillus* hyphae are routinely observed in hematoxylin/eosin-stained sections, but special fungal stains (periodic acid-Schiff, for example) are useful to confirm their presence.

Diagnosis

Neither clinical signs nor lesions are pathognomonic enough to confirm the diagnosis. Aspergillosis must be differentiated from other respiratory and mycotic diseases (particularly dactylariosis).

Clinical signs of respiratory disease during the first two weeks of life with air sac plaques or intrapulmonary nodules are highly suggestive of aspergillosis, but similar respiratory signs may be caused by field or vaccine strains of some viral infections.

Bacterial infections (*Staphylococcus*, *Salmonella*, *Mycoplasma*, fowl cholera, chlamydiosis, *Mycobacterium* or mixed infections) can produce granulomas or exudative fibrinous (or purulent) airsacculitis difficult to differentiate macroscopically from those produced by *A. fumigatus* or other fungal agents. Clinically, chronic aspergillosis in adult birds is similar to many other chronic respiratory diseases.

Although it is sometimes possible to observe the growth of the mycelium and sporulation on caseous nodules or plaques, especially in air sacs, confirmation should be obtained by cultural isolation and identification of the causative fungus. Hyphae may be seen microscopically on a slide made from a smear or imprint of lesions after the addition of one or two drops of 10% potassium hydroxide (KOH) and gentle heating to hasten clearing. In histologic sections, special stains are useful for the detection of fungi. For the identification of conidiophore morphology, the fungus, granulomas or plaques should be cultured on a more selective medium (Sabouraud dextrose agar).

Treatment & control

When aspergillosis is diagnosed in a flock, the objective is to reduce and eliminate exposure to spores. Clinically affected birds should be culled. Treatment is usually not attempted because it is cost prohibitive. Only valuable birds may be treated with nystatin or amphotericin-B or other antimycotic agents. Ketoconazole, miconazole, itraconazole and related drugs have also been found effective. Often antibiotics are given simultaneously to prevent secondary bacterial infections. Mortality can be reduced by treating the litter (enilconazole, thiabendazole, etc.) but it is best to remove the contaminated feed or litter.

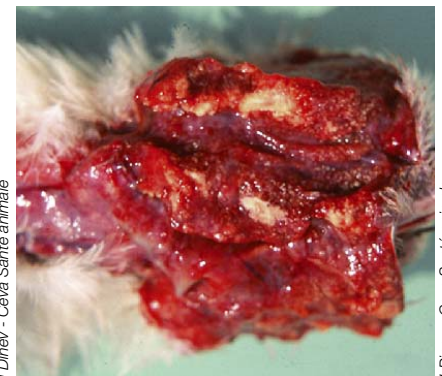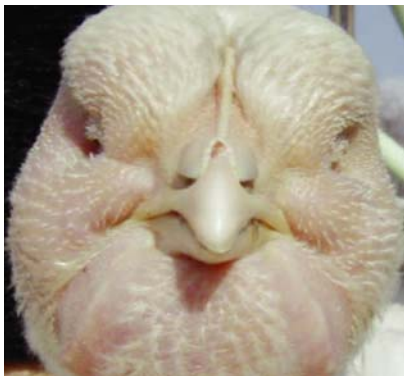


Fig.62.25, 62.26 & 62.27: *Aspergillus* granulomatous dermatitis. Head edema may be severe. In some cases, the skin takes on a blue-greenish color. At a later stage, after regression of the edema, granulomatous formations are visible in the subcutaneous tissues.

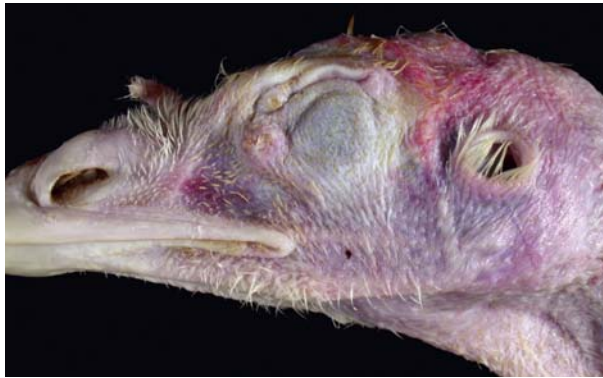

Fig.62.28: Eyelid aspergillosis (Turkey).

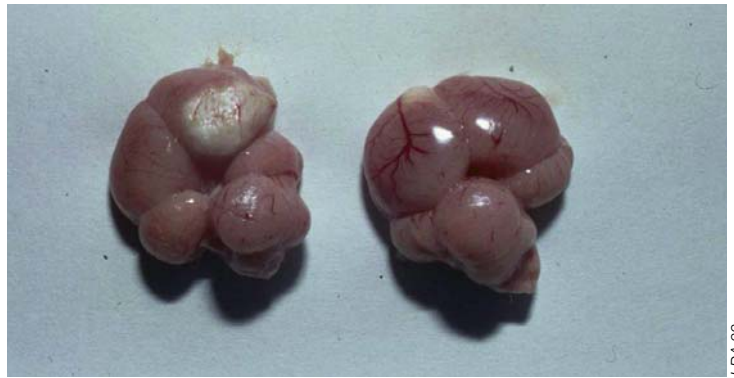

Fig.62.29: *Aspergillus* brain abscess.

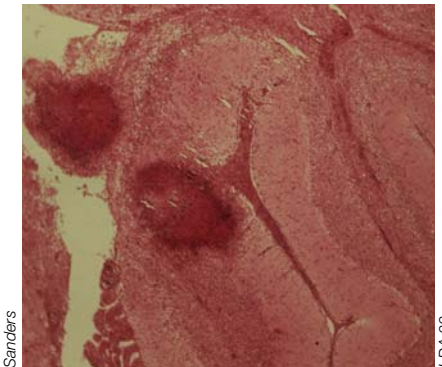
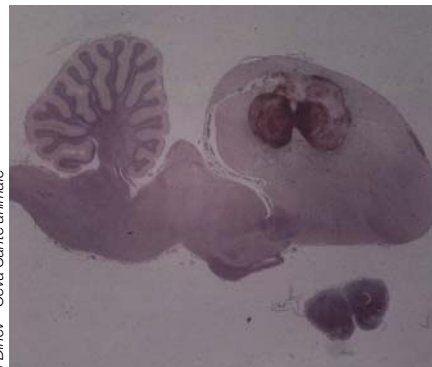
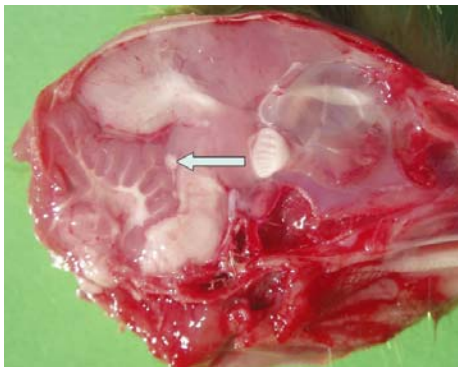


Fig.62.30, 62.31 & 62.32 : *Aspergillus* brain abscess. Macroscopic and microscopic appearance.

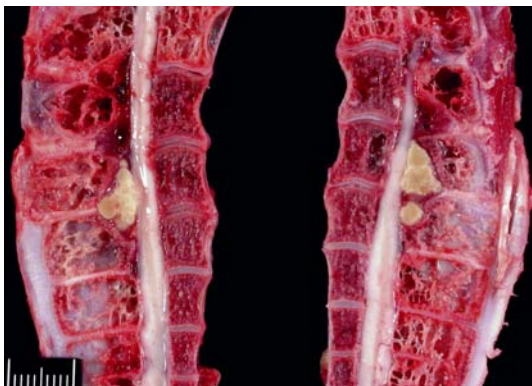


Fig.62.33: Spine aspergillosis.

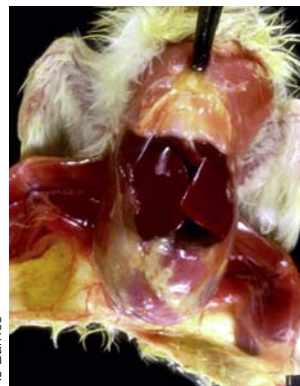

Fig.62.34. Ascites is a frequent sequela of pulmonary aspergillosis (One-week-old chicken).

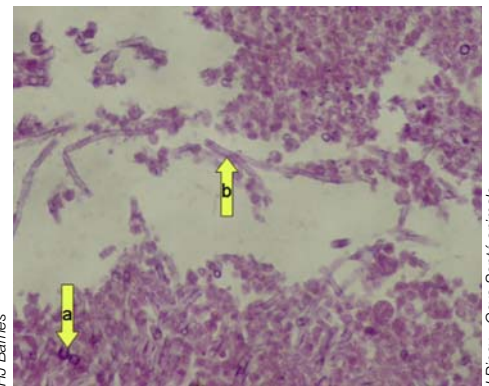


Fig.62.35: Aspergillosis can be confirmed by microscopic examination of lesions. Mold spores (arrow a) and hyphae (arrow b).

Prevention is currently the preferred approach to control this disease. As vaccination is not commercially feasible, the prevention is essentially based on reducing exposure to the fungus and associated risk factors. Prevention starts at the hatchery where fungicidal disinfectants have been used successfully. Hatching eggs should be stored where they may not be contaminated by dust and “egg sweating” (water condensation on the egg surface) should be avoided. Hatchery equipment, ventilation and air ducts should be cleaned, disinfected and monitored with periodic cultures. Moldy and/or dusty litter and feed should be avoided, particularly on breeder farms.

OCHROCONOSIS (DACTYLARIOSIS)

Ochroconosis is a sporadic fungal encephalitis of young birds described in chickens, turkeys and quails. It is caused by *Ochroconis (Dactylaria) gallopava*. This disease is relatively rare but, in addition to lesions of the nervous system, pulmonary lesions similar to aspergillosis can be seen. Sources of infection are found in environments characterized by high temperatures (>43°C) and low pH (<5). The origin of the contamination is often litter made of wood shavings or sawdust, but it can also be observed in hatcheries. After spore inhalation, the neurological disease appears following the spread of the fungus via the bloodstream to the central nervous system.

Clinical signs are consistent with central nervous system lesions (torticollis, tremors, incoordination, paresis). The principal lesion is confined to the brain (meningeal or necrotic encephalitis) but pulmonary granulomas or ocular lesions, identical to those of aspergillosis, are seen occasionally.

Ochroconosis must be differentiated from encephalomalacia due to vitamin-E deficiency, infectious avian encephalomyelitis, Newcastle disease, bacterial meningitis and aspergillosis.

Histologically, neurological lesions differ from aspergillosis by having more malacia, hemorrhage and numerous giant cells.

Prevention measures are essentially the same as for aspergillosis (proper litter, feed and hatchery management).

CANDIDIASIS (Moniliasis, crop mycosis, thrush)

Definition

Candidiasis is a mycosis caused by yeasts of the genus *Candida*, principally *C. albicans*. Oral, esophageal or crop candidiasis occurs frequently but observable clinical signs are rare. The disease is more likely the result of an opportunistic infection than a primary infection. It is associated with a concurrent disease, a nutritional deficiency, immunosuppression or altered microflora after antibiotic therapy.

Etiology & epidemiology

Candida albicans is the most prevalent causal agent. It is ubiquitous in the environment and is often present in the upper gastrointestinal tract of normal birds. Candidiasis can be observed in many avian species (chickens, turkeys, guinea fowl, geese, pigeons, quail, peacocks, game birds, etc.). The disease is more common in birds under three weeks of age, suggesting an acquired or age-related resistance.

The occurrence of avian candidiasis is sporadic, but outbreaks can be costly. One of the most common predisposing factors is prolonged antibiotic administration, which suppresses normal bacterial flora, giving *Candida* a competitive advantage to gain access to nutrients, thus allowing its proliferation. Other predisposing causes include lack of appropriate sanitation, heavy parasitism, vitamin deficiency, diet rich in carbohydrates, and immune suppressing or debilitating infectious diseases. *Candida* is acquired by ingestion and invades superficial epithelial layers. This invasion stimulates epithelial hyperplasia and formation of a pseudomembrane or diphtheritic membrane.

Clinical signs & lesions

Clinical signs are not particularly specific. When candidiasis occurs as a secondary infection, the clinical signs associated with the primary agent may dominate the clinical picture. Affected chicks or poults show a reduced growth due to a decrease in feed intake (the crop is empty). Mortality directly caused by candidiasis is low to nonexistent.

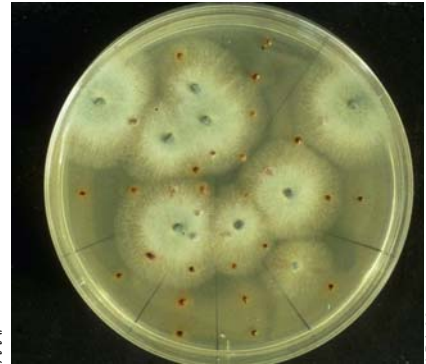
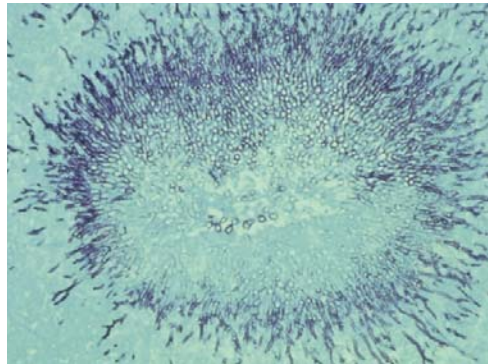
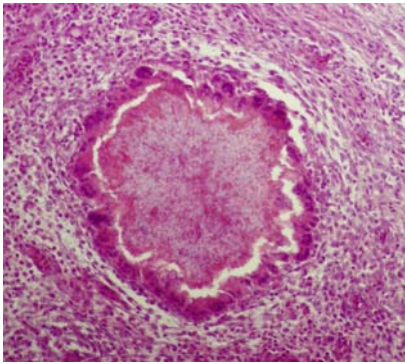


Fig.62.36: Characteristic microscopic appearance of the granulomatous structure of an *Aspergillus* nodule. Multinuclear giant cells in periphery looking like a crown.

Fig.62.37: Chronic pulmonary aspergillosis. Mycelia are better demonstrated with fungal stains as shown here (Gomori methenamine silver stain x70).

Fig.62.38: Aspergillosis. Culture of 40 chick lung fragments (growth of 9 thalli).

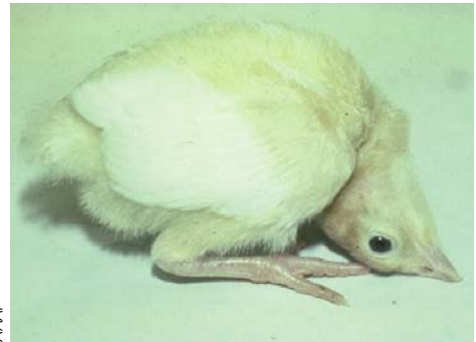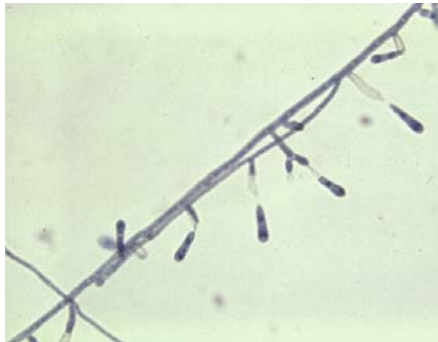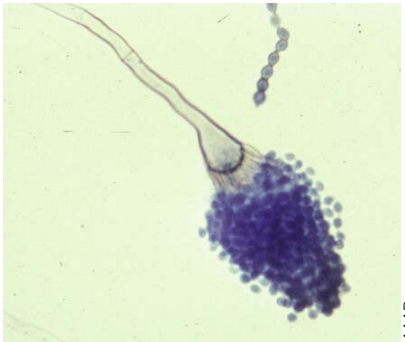


Fig.62.39: *Aspergillus* spp. Characteristic conidiophore with flask-shaped vesicle. Variations occur within *Aspergillus* spp., therefore a mycologist should be consulted for species identification. (methylene blue stain, x 300).

Fig.62.40: *Ochroconis (Dactylaria) gallopava*, mycelium and characteristic spores (methylene blue stain, x 500).

Fig.62.41: Neurogenic torticollis in a poulty caused by *Ochroconis gallopava*. Similar signs are found in birds with aspergillosis when the brain is involved.

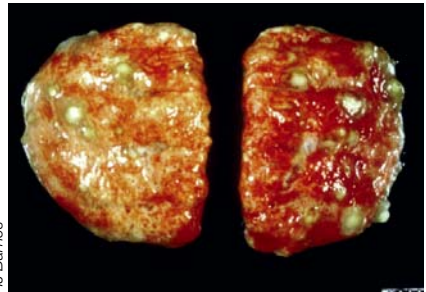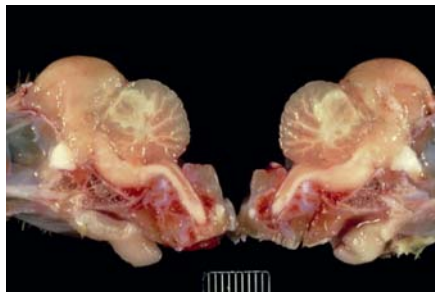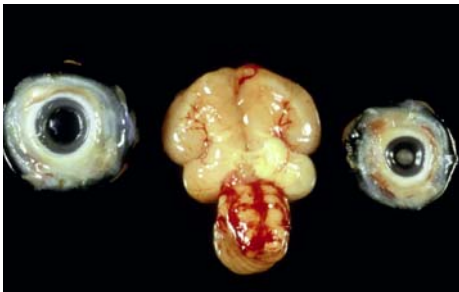


Fig.62.42 & 62.43: *Ochroconosis* (Turkey). Mycotic encephalitis with localization near the optic nerve with eye atrophy (on right in Fig.62.42) or in the cerebellum (Fig.62.43).

Fig.62.44: Pulmonary dactylariosis (Turkey).

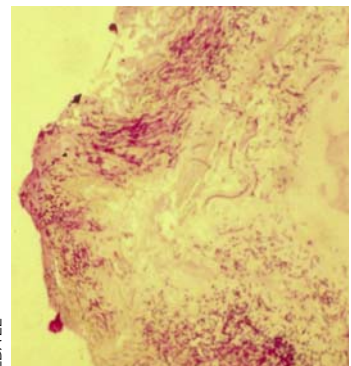
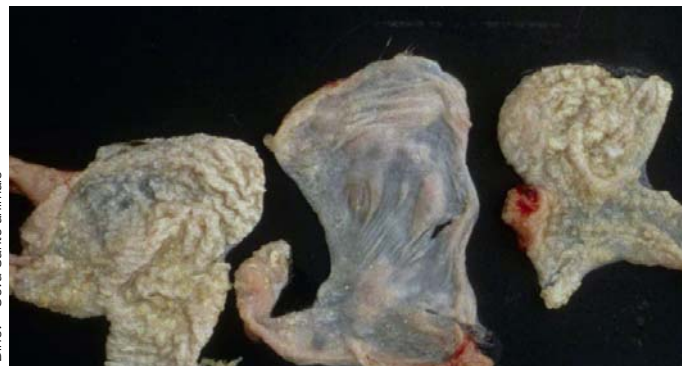
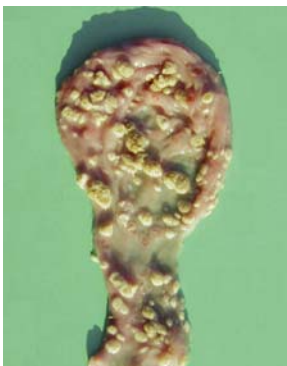
Fig.62.45: Candidiasis of the crop. Foci localized on the mucosa.

Fig.62.46: Candidiasis of the crop (Guinea fowl) resembling a towel. Comparison with a healthy crop (center).

Fig.62.47: Histology of candidiasis of the crop (Guinea fowl). Specific staining of the cell wall of *Candida albicans* (PAS).

Lesions are essentially located in the crop and, less frequently, the proventriculus, oesophagus, mouth, pharynx, and rarely the intestine. The surface of the crop is coated with multiple foci or confluent mats of white cheesy adherent material that cannot be washed away like mucus. An inflammatory response to mucosal candidiasis is mild unless ulceration is present.

Diagnosis

Pseudomembranes and diphtheritic membranes in the first part of the digestive tract are highly suggestive of candidiasis. Differential diagnosis includes ingestion of toxic products, trichothecene mycotoxins and severe oral trichomoniasis. Histologic examination of the affected mucosa or of yeasts after scraping (mixed with KOH 10% and gentle heat to hasten clearing) can confirm candidiasis. Culture on Sabouraud dextrose agar or other fungal culture media is possible but many disease-free birds may be positive.

Treatment & control

Candidiasis is best prevented by controlling predisposing factors, including excess use of antibiotics. Adequate sanitation is also an important prevention measure. Some compounds can control temporarily this fungal disease (gentian violet, nystatin) but they are not approved in many countries. Parconazole is used in guinea fowl.

OTHER FUNGAL INFECTIONS

Dermatophytosis (*Favus*)

This disease is not economically significant in commercial poultry but is occasionally seen in backyard flocks or pet birds, and more rarely in turkeys. The infection is chronic and localized. *Favus* is caused by *Microsporium gallinae* (*Trichophyton gallinae*), *Microsporium gypseum* and *Trichophyton simii*. It is transmissible to other animals (rarely to humans).

Lesions slowly expand concentrically and are seen in unfeathered areas (comb, wattle, shanks); the superficial invasion of the stratum corneum by hyphae results in epidermal hyperplasia and hyperkeratosis.

Diagnosis is made by visualization of hyphae of *Microsporium* or spores in skin lesions, followed by culture on selective dermatophyte media (or Sabouraud dextrose agar).

Topical antifungals or systemic antifungal therapy may be attempted in valuable birds. Otherwise, infected birds should be culled.

Histoplasmosis

Histoplasmosis is an infectious, but not contagious, mycotic disease of humans and animals. *Histoplasma capsulatum* is ubiquitous in the environment. Infection is acquired by inhalation of conidia.

REFERENCES

- Brown T et al. Fungal diseases. In *Poultry Diseases*, sixth Edition. Eds Pattison M et al., Saunders Elsevier. 2008, pp 428-442.
- Charlton BR et al, Fungal infections. In *Diseases of poultry*, Ed Saif YM et al, Blackwell Publishing Ltd, Oxford, 2008, pp 989-1008.
- Dinev I. *Diseases of Poultry, a colour Atlas*. Ceva Santé animale. First edition, 2M Print House Ltd, 2007.
- Julian RJ & Goryo M. Pulmonary aspergillosis causing right ventricular failure and ascites in meat-type chickens. *Avian Pathol.* 1990, 19, 643-654.
- Latge JP. *Aspergillus fumigatus* and aspergillosis. *Clinical Microbiology Review.* 1999, 12 : 310-350.
- Shivaprasad HL. Fungal diseases. In *Avian disease manual*. 7th ed. M. Boulianne M. AAAP. pp 140-146.
- Yamada S et al. Avian dermatitis caused by *Aspergillus fumigatus*. *J Jpn Vet Med Assoc.* 1977, 30:200-202.

Mycotoxin	Raw material or feed	Maximum concentration (mg/kg)
Aflatoxin B1	All raw material intended for farm animals	0.02
	Complete feeds for poultry	0.02
	Complementary feedstuffs for poultry	0.02
Ochratoxin A	Complementary feedstuffs and complete feeds for poultry	0.1
Fumonisin B1+B2	Complementary feedstuffs and complete feeds for poultry	20
Deoxynivalenol	Cereals and cereals based products	12
	Corn by-products	8
	Complementary feedstuffs and complete feeds	5
Zearalenone	Cereals and cereal based products	2
	Corn by-products	3

Tabl.63.1: European regulations and recommendations concerning maximum tolerable levels for some mycotoxins in raw materials or feeds intended for poultry.




Fig.63.1: *Aspergillus flavus*. Thallus observed with a binocular microscope.

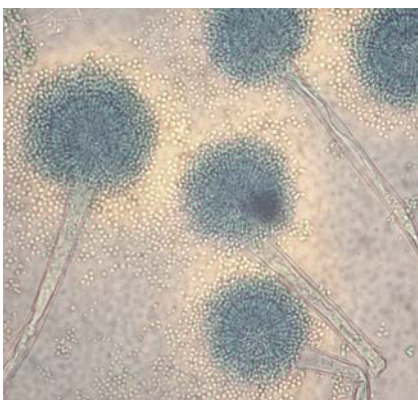


Fig.63.2 & 63.3: Conidial heads of *Aspergillus flavus* (x400), a species producing aflatoxin B1 and cyclopiazonic acid.

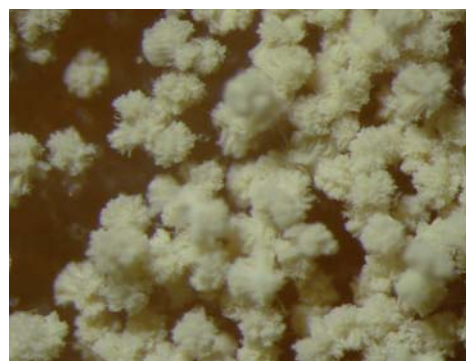
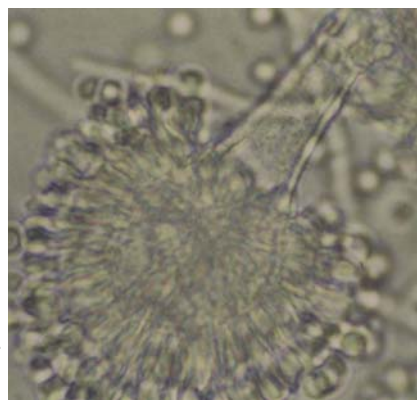


Fig.63.4: *Aspergillus ochraceus*, ochratoxin A producing species, observed under a binocular microscope (x50).

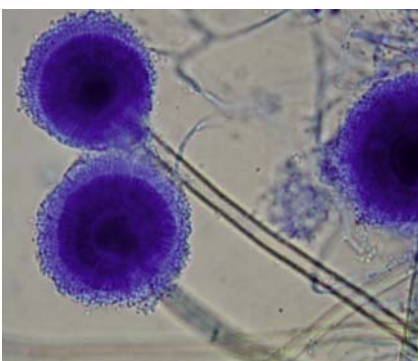

Fig.63.5 & 63.6: Microscope observation of *Aspergillus ochraceus*, an ochratoxin A producing species (x400).

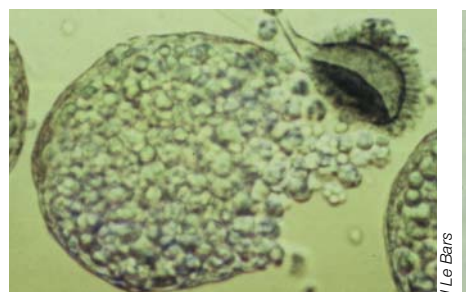
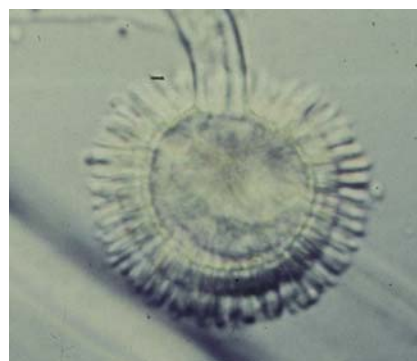


Fig.63.7: *Aspergillus glaucus*. Asci and ascospores in cleistothecium.

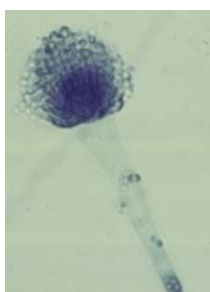

Fig.63.8: *Aspergillus fumigatus*.

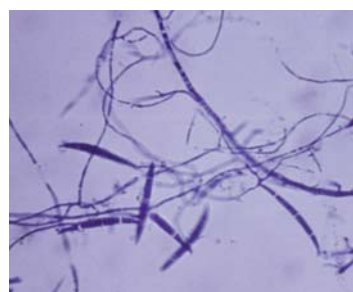
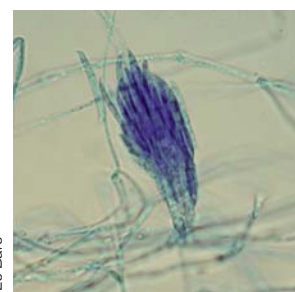


Fig.63.9 & 63.10: Macroconidia of *Fusarium graminearum*.



Other diseases

63. MYCOTOXICOSIS

INTRODUCTION

Mycotoxicoeses are intoxications resulting from the ingestion of feed contaminated with toxins produced by fungi (including phytopathogenic fungi and molds growing on feed during storage). Mycotoxicoeses are neither infectious nor contagious, but they are closely related to feedstuff.

In the feed industry, because of manufacturing procedures (e.g., feedstuffs conservation, detoxification, analysis), of the dilution effect of large batches and regulations (see Tabl.63.1), mycotoxin levels are generally insufficient to cause acute mycotoxicosis with typical clinical signs. However, the uncontrolled growth of molds, with or without the synthesis of mycotoxins is more likely to be responsible for lower production performances. This can have a direct and significant economic impact but is often difficult to diagnose because of the insidious ways these molds affect poultry. The absence of treatment also stresses the need to prevent as much as possible fungal growth throughout the feed manufacturing process, from the field to the feeders.

THE TOXINOGENIC AGENTS

Microscopic fungi are particularly adapted to grow on feedstuff because of their mycelial development and intense sporulation that ensure their wide dissemination. The mycoflora of feeds contains about a thousand species and the initial contamination of feedstuffs by mold spores is unavoidable.

The development of a specific mycoflora is closely related to its physiological characteristics and hydrothermal conditions during storage of raw materials and compound feeds. Thus, the mycoflora can change during feed storage: the (discrete) development of xerophilic species (*A. gr. glaucus*) releases water that can be used by more hydrophilic species (*A.flavus*, *A.ochraceus*, *A. fumigatus*, *A.niger*, *Penicillium* spp, *Absidia*, etc.). Some technological processes can greatly change the mycoflora of feedstuff. For instance, granulation of a ration causes, due to thermal shock, a severe reduction in fungal contamination.

General consequences of fungal contamination

Mold growth in feed can have many consequences:

- changes in the appearance and organoleptic

qualities,

- changes in technological properties,
- decrease in nutritional value.

These qualitative changes are rarely assessed, but they may play a role in poor performances observed in birds fed moldy feed.

Beside these qualitative changes, molds can also have adverse effects on bird health due to:

- mycosis (*A. fumigatus*, *A. flavus*) and related allergies,
- mycotoxin contamination.

Mycotoxin contamination

General considerations

The growth of toxigenic fungal species is necessary but not sufficient to produce mycotoxin contamination. Furthermore, due to their stability, mycotoxins may still be present in feed after the producing fungus has been killed, especially following a thermal treatment.

Mycotoxins are secondary metabolites of diverse composition that may be divided in different families of toxic chemical products (aflatoxins, trichothecenes, etc).

For a given toxigenic species, there may be a wide variation in the toxigenic potential of different strains. Some mycotoxins are closely linked to specific fungal species (aflatoxins), while others can be produced by different species and genera (ochratoxins). Finally, a single species can produce several mycotoxins (aflatoxins and cyclopiazonic acid by *A. flavus*). This explains the frequent multi-contamination of a ration but also makes it impossible to establish direct and systematic links between a raw material, a fungal species and mycotoxins. Each case or clinical suspicion requires a specific assessment.

Role of environmental factors

Conditions leading to toxin production are more limited than those allowing fungal growth. Humidity and temperature are of particular importance. Similarly, increased CO₂ content has a greater depressant effect on toxin production than on fungal growth. By contrast to fungal growth, mycotoxin synthesis is also much more dependent

Mycotoxins	Fungi	Main sources*	Favorable conditions and geographical distribution
Aflatoxins**	<i>Aspergillus flavus</i> , <i>A. parasiticus</i>	Peanut, cotton, corn	Damp heat: 1. tropical areas 2. poor storage conditions
Ochratoxin A	<i>P. viridicatum</i> , <i>A. ochraceus</i>	Barley, oats corn, wheat	Cool climates, dampness during storage
Trichothecenes**			
- T2 toxin	<i>F. tricinctum</i>	Cereals	Cold and temperate climates
- Diacetoxycirpenol	<i>Fusarium</i> spp.		
- Deoxynivalenol	<i>Fusarium</i> spp.		
Fumonisin	<i>F. verticillioides</i>	Corn	Temperate to warm climates
Zearalenone**	<i>Fusarium</i> spp.	Corn, sorghum	Temperate climates. Alternation cold/mild conditions

Tabl.63.2: Main mycotoxins in poultry feed.

(*): Ranked according to frequency of natural contamination.

(**): Contamination begins in the field.

Mycotoxins	Poultry species	mg/kg body weight
Aflatoxin B1	Duckling	0.35-0.56
	Young guinea fowl	3.92
	Chicken	6.5-16.5 *
Ochratoxin A	Chicken	3.4
	Chick	10.7
	Young turkey	5.9
	Japanese quail	16.5
T2 Toxin	Chicken	4.97
	Chick	5.25
	Hen	6,27
Diacetoxyscirpenol	Chick	3.82
Citrinin	Turkey	56
	Duckling	57
	Chicken	95

Tabl.63.3: Lethal dose 50 of several mycotoxins after a single administration by oral route and depending on the poultry species

(*): variation depending on the strain.

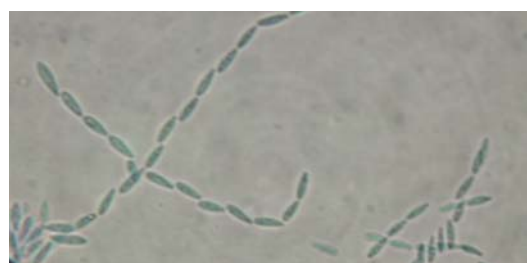

Fig.63.11: Microconidia catenary, characteristic of *Fusarium verticillioides*, contaminating corn and producing fumonisins.

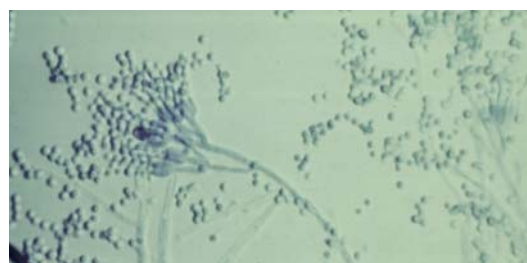


Fig.63.12: *Penicillium verrucosum* var *cyclopium*. Xerophilous species that can cause a lack of appetite.



Fig.63.13 : Aflatoxicosis. In broilers, reduced growth rate, paralysis and recumbency are observed.

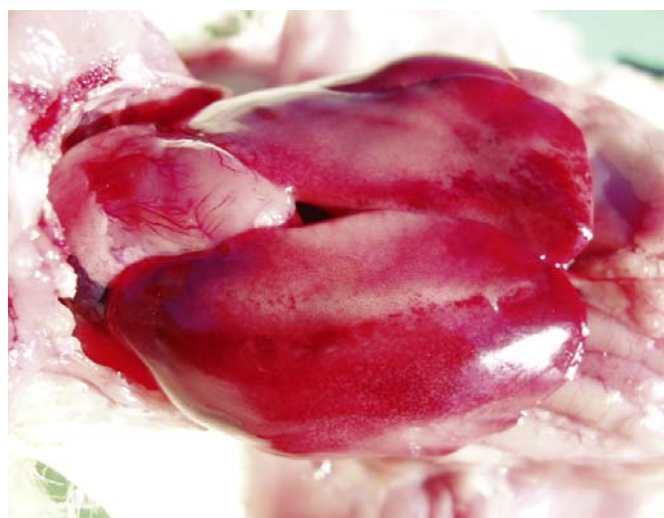

Fig.63.14: Aflatoxicosis in poultry is primarily a liver disease.

on the chemical composition of the feedstuff. For most mycotoxins, key needs can roughly be classified as follows, in decreasing order of importance: carbohydrates, lipids, proteins. Thus, cereals are more favorable to toxin production than soybean, rapeseed, *etc.*, and proteins of animal origin. Finally, all the toxins mentioned in this chapter are stable in feeds and resistant to conventional thermal treatments.

Mycotoxin contamination occurrence

Mycotoxin contamination can occur throughout the production chain from the field to the feeders. Some contamination can occur before harvest (e.g., *Fusarium* toxins), others occur during storage (e.g., ochratoxin A) depending on hydrothermal conditions. The mixing of raw materials having different levels of humidity and affinity for water favors fungal growth. Grinding ensures spore dispersal and, by making nutrients easily available to molds, accelerates the alteration in nutrient content of feed.

MYCOTOXICOSIS

Hundreds of different mycotoxins have been identified, but it is generally accepted that only about 30 have, due to their toxicity and prevalence, a real importance in animal and human health. In this chapter, only the main avian mycotoxicoses are presented.

In general, poultry are considered among the most resistant bird species to the deleterious effects of mycotoxins. Consequently, maximum tolerable levels for poultry feeds are often higher than those allowed for other species (see Tabl.63.1). However, it appears that there are differences in sensitivity between avian species that are not taken into account by regulations (see Tabl.63.3).

The ingestion of large amounts of toxins present in the feed may trigger acute clinical signs that are often pathognomonic. However, most often, toxin concentrations are such that only non-specific sub-acute signs are observed, mainly characterized by lower production performances. Of course, it is also important to assess the possibility that some mycotoxins may be present in poultry products (meat or eggs) in residual levels.

Aflatoxicosis

This intoxication results from ingesting feed containing aflatoxins (mainly AFB1) produced by *Aspergillus flavus* or *A. parasiticus*. In poultry,

clinical signs and lesions vary according to bird species, age, quantity of toxin ingested and the duration of exposure. Poultry species can be ranked in decreasing order of sensitivity: ducks, turkeys, geese, guinea fowl, pheasants, quails, chickens. Young birds are more susceptible than adults. Some breeds or strains are more resistant than others. Males are more susceptible than females to both acute and chronic intoxications.

Acute intoxication is observed after ingestion of feed containing several mg of AFB1 per kg of feed. It can sometimes lead to death without prior clinical signs in the most susceptible birds. Otherwise, the main signs observed in ducks and turkeys (the most sensitive species) are: apathy, ruffled feathers, diarrhea, ataxia, opisthotonos and sometimes convulsions, bruises, and slow growth rate. At *post-mortem* examination, the liver is enlarged and then hardened with the appearance of small necrotic and hemorrhagic foci. The spleen, pancreas and kidneys are also enlarged, while an atrophy of the bursa of Fabricius is noticed. Histological examination of the liver reveals extensive hemorrhagic necrosis with nuclear enlargement and disappearance of nucleoli of hepatic cells.

Chronic intoxication occurs when birds are exposed for several weeks (minimum one week) to feed containing several hundred µg/kg of AFB1. Clinical signs are limited to fatigue, anorexia and lower production performances: reduced growth rate, drop in egg production, decreased hatchability. Histological examination reveals necrosis of the hepatic parenchyma, followed by a regeneration phase, characterized by the proliferation of bile duct cells.

An important feature of AFB1 is *the cumulative effects*. Thus, in guinea fowl, the LD50 is nearly the same whether the toxin is administered in a single dose (3.9 mg/kg of body weight) or over a 20-day period (5.2 mg/kg). Once the AFB1 molecule enters the hepatocyte, it is rapidly metabolized and therefore does not accumulate in the organs. Traces of a hydroxylated derivative (AFM1) have been found in eggs (at concentrations about 1000 times less than in the feed). This intense metabolism is responsible for the toxicity of aflatoxin B1 because some metabolites appearing in the liver have highly toxic effects on essential cellular functions.

Aflatoxins also cause a decrease in non-specific resistance and cellular mediated immunity. Therefore, they increase bird susceptibility to some bacteria (e.g., *Salmonella Gallinarum*), fungi (e.g., *Candida albicans*) and parasites (e.g., *Eimeria*

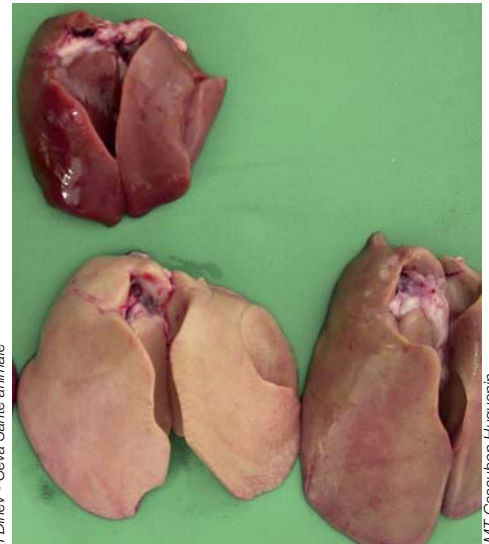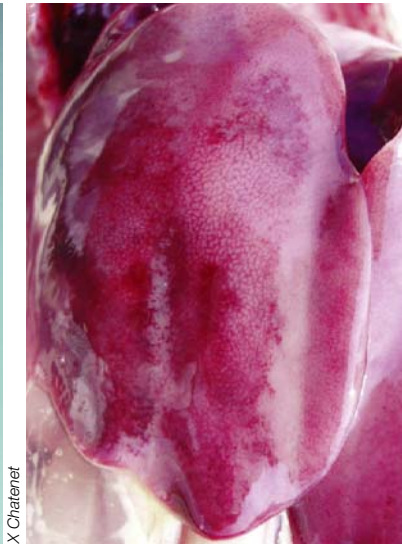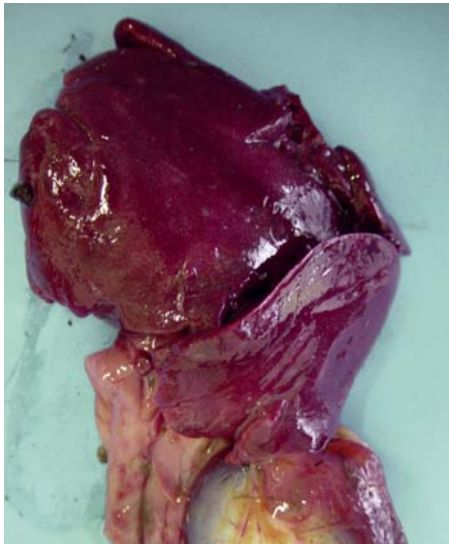


Fig.63.15, 63.16. & 63.17: Lethal aflatoxicosis causes liver discoloration from dark red due to congestion and necrosis to yellow, due to fat accumulation in the hepatocytes. Multiple hemorrhages and a characteristic reticular appearance of the capsular surface are also observed.

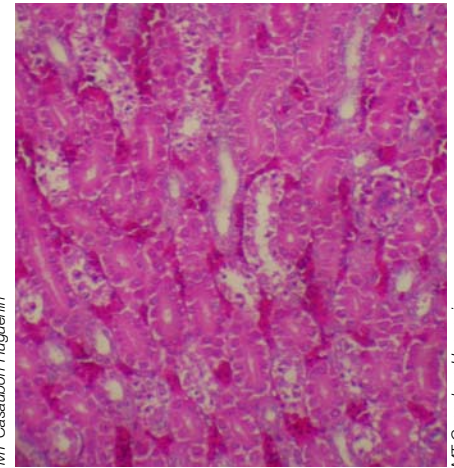
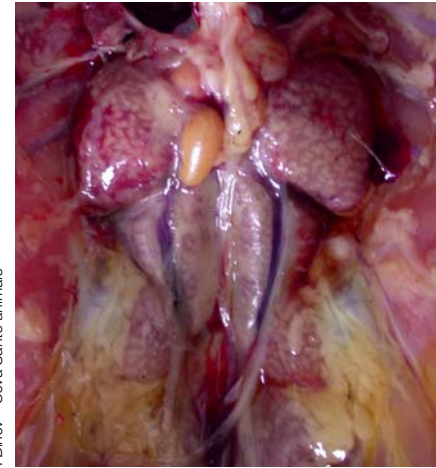
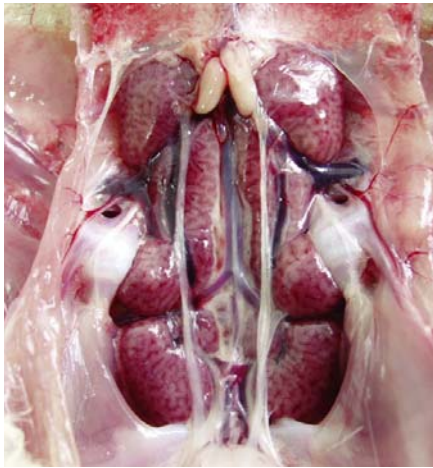


Fig.63.18 : Aflatoxicosis. In severe intoxications, the kidneys are enlarged and filled with urates. Fig.63.19 & 63.20: Ochratoxicosis. Ochratoxin A produces acute proximal tubular epithelial necrosis in the kidneys and inhibits normal renal uric secretion (visceral gout).

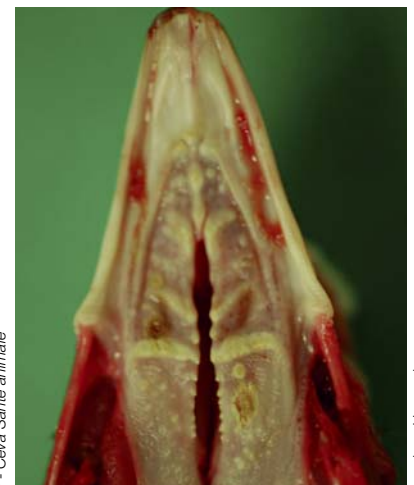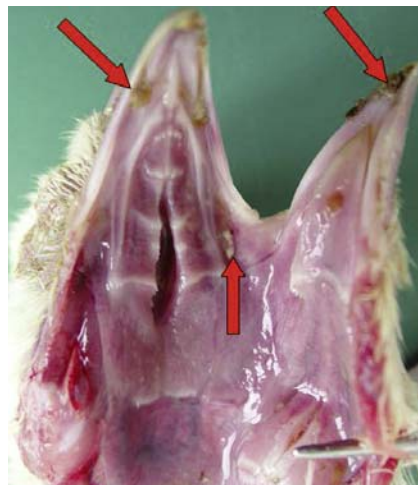


Fig.63.21: Trichothecene mycotoxicosis (T2 toxin). Abnormal feathering: feathers are narrow because of radiomimetic injury to the developing barb. Fig.63.22 & 63.23: Trichothecene mycotoxicosis (T2 toxin). The caustic properties of the trichothecenes produce extensive necrosis of the oral mucosa.

tenella) and have been implicated in vaccination failures.

Other secondary complications have also been reported in poultry: brittle bones, bruises associated with carcass trimming and downgrading, etc.

Ochratoxicosis

Ochratoxins are produced by fungal species that belong to the *Aspergillus ochraceus* group and the genus *Penicillium*. These toxins are mainly linked to minor cereals, such as barley and oats, produced in cool climates (Northern Europe, Canada). Ochratoxin A (OTA) is **nephrotoxic** to most animal species.

An acute intoxication has been reported after exposing bird to concentrations ranging from 2 to 10 mg/kg of feed, which is very high compared with levels of contamination reported in naturally contaminated feeds. Birds are found prostrate, ataxic, with muscle tremors and impaired reflexes. Mortality can exceed 50%. Lesions are observed in the kidneys (pale, hemorrhagic and enlarged) and liver (pale).

Chronic forms of intoxication are observed after bird exposure to diets containing 0.3 to 4 mg of OTA/kg of feed for several weeks. Again, these concentrations are high compared to concentrations commonly observed in naturally contaminated feeds. The main clinical signs are reduced growth rate and poor feed conversion ratio. Renal damage observed in all species after exposure to concentrations around a milligram of OTA per kg of feed can result in polydipsia and production of wet droppings in abnormally large amounts.

Other adverse effects have been reported: lack of pigmentation, coagulopathy, hematoma formation leading to a depreciation of carcass quality, brittle bones, rupture of the intestines during slaughter. Affected poultry appear more susceptible to secondary infections. Indeed, impaired phagocytosis and a regression of the bursa of Fabricius and thymus are observed in these birds.

Ochratoxin A residues are mainly found in the kidneys (useful for *post-mortem* diagnosis). The recorded levels are lower in the liver, and significantly much lower in meat and eggs.

Trichothecene toxicosis

This family of fungal metabolites (including more than 100 molecules discovered to date) contains

the main toxins produced by *Fusarium* species that are pathogenic to many plants. This toxinogenesis occurs in the field before harvest or before cereal grain drying and storage.

Some trichothecenes are highly toxic to poultry. Acute toxicity of T-2 toxin in broiler chicks and laying hens causes asthenia, inappetence, diarrhea and panting. The abdominal cavity of affected birds contains a chalky material that covers most of the viscera. Sublethal doses lead to reduced weight gain and feed intake. After several days or weeks of consumption of contaminated feed (from 0.5 to 1 ppm of T2 toxin), chicks, chickens and hens show necrotic lesions of the oral and gastrointestinal tract mucosa.

Chronic intoxication in poultry is associated with the following observations:

- growth retardation and feathering abnormalities,
- drop in egg production and decreased hatchability
- onset of oral lesions, coagulopathy, hemorrhages in many organs,
- liver cells necrosis and atrophy of lymphoid tissues (bursa of Fabricius). These lesions may explain the reduction in the immune response of affected birds and the increase in secondary infections.

Fumonisin toxicosis

Since their discovery in the late 80s, these toxins have been extensively studied to characterize their impact on the health and performances of animals. Fumonisin B1 is the most frequent and toxic compound of this family produced by fungal species belonging to the genus *Fusarium* and contaminating almost exclusively corn (*F. verticillioides* and *F. proliferatum*). The synthesis of these toxic compounds takes place around the harvest period, when outdoor conditions are mild ($\approx 20^{\circ}\text{C}$) and humid.

Poultry are often considered relatively resistant to these compounds as toxic effects are observed at levels rarely seen in naturally contaminated grains (several tens or even hundreds of mg/kg) and are generally limited to growth retardation or poor feed conversion ratio. However, recent studies have shown large variations in poultry species' sensitivity to these compounds, as already demonstrated in mammals (horses and pigs are very sensitive, ruminants are resistant). Ducks are much more sensitive to fumonisin than other avian species. For example, when ducks are fed a diet containing 20 mg/kg of fumonisin B1 (maximum dose recommended by the European legislation),

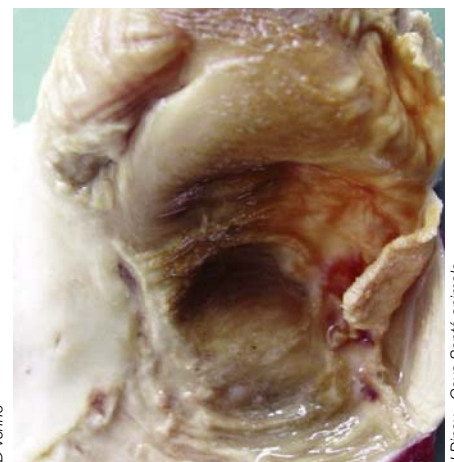
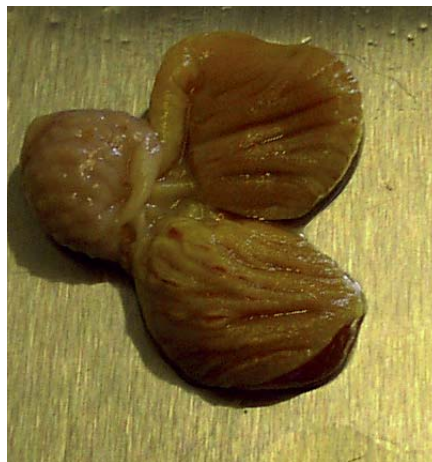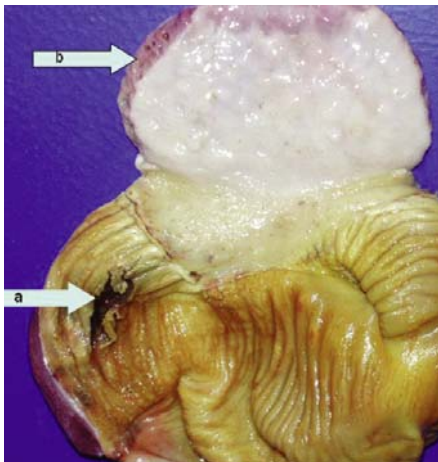


Fig.63.24, 63.25 & 63.26: The caustic properties of trichotheceles is also the cause of erosions and ulcers in gizzard cuticulum (arrow a). Note the thickened wall of the proventriculus (arrow b).

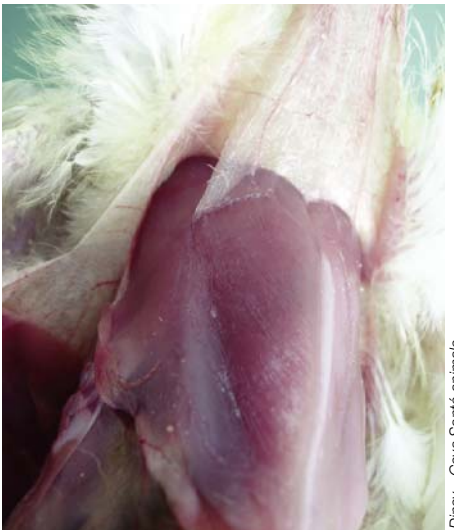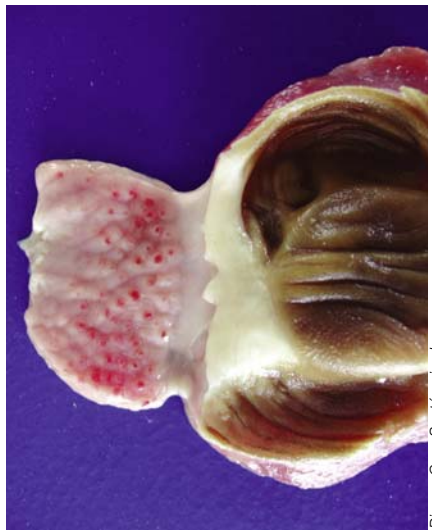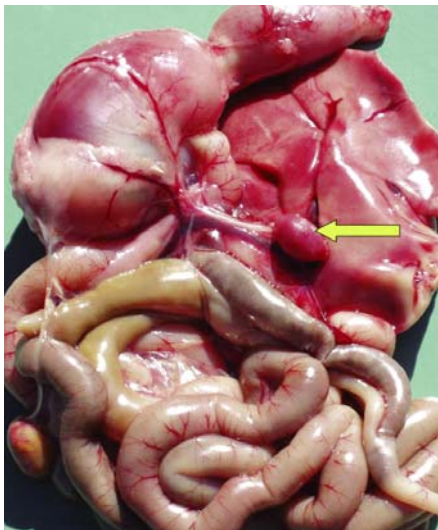


Fig.63.27: Marked spleen atrophy is commonly seen; it is a sign of the immunosuppressive effect of mycotoxins (arrow).

Fig.63.28: Trichothece mycotoxicosis. Hyperemic and hemorrhagic mucous coat of the proventriculus is commonly observed.

Fig.63.29: Trichothece mycotoxicosis. A large part of dead bodies appears dehydrated.

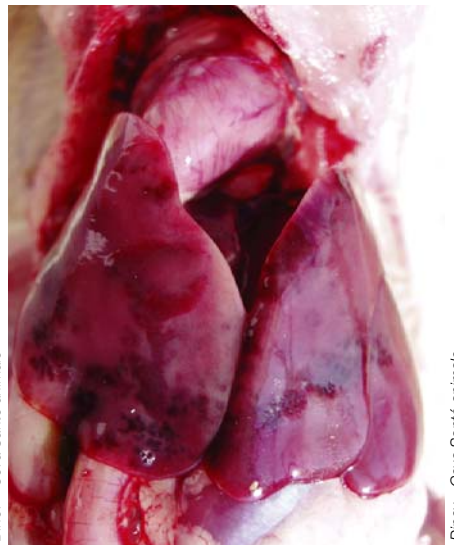
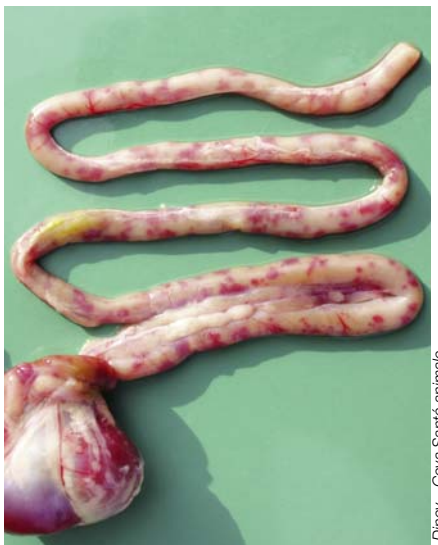
Fig.63.30 & 63.31: Trichothece mycotoxicosis. The lesions also include reddening and hemorrhage of intestinal mucosa. Often, the mucous coat of the duodenum and the initial part of the ileum are affected.

Fig.63.32: Trichothece mycotoxicosis. Hemorrhages are seen in the liver.

an increase in mortality occurs as well as significant economic losses due to the impact on the quality of *foie gras* (weight reduction, discoloration, change in melting rate).

Moreover, at regulatory concentrations, it seems possible to find mycotoxin residues in the liver of exposed birds (ducks and turkeys).

Other mycotoxins of interest

Cyclopiazonic acid (CPA) is a compound produced by fungal species belonging to the *Penicillium* (*P. cyclopium*) and *Aspergillus* genera (including *A. flavus*). The exposure of chickens to feed containing 50 mg of CPA/kg causes a significant reduction in weight gain. At higher levels, nervous disorders such as ataxia, apathy or muscle spasms are observed. It should be noted that the retrospective investigation of turkey X disease that led to the identification of aflatoxins, suggests that cyclopiazonic acid plays a role in this disease. Indeed, the administration of pure aflatoxin B1 failed to reproduce the nervous signs observed with turkey X disease while they occur following exposure to high doses of cyclopiazonic acid.

Citrinin, produced by different species of the *Aspergillus* and *Penicillium* genera, is sometimes associated with OTA, especially in minor cereals (e.g., barley and oats). This toxin is much less stable especially in the presence of proteins and heat treatments. As with OTA, the target organ is the kidney: degeneration and necrosis of tubular epithelium.

Fusarochromanone is a cause of tibial dyschondroplasia primarily in turkeys. This deformation may lead to breast blisters in heavy birds, which results in carcass downgrading. Although it does not seem to affect laying hens *per se*, it has a negative impact on hatchability (for concentrations above 0.2 ppm).

Zearalenone, produced by *Fusarium graminearum*, is estrogenic in many animals, mostly pigs. Poultry are traditionally considered resistant to this toxin. Indeed, concentrations greater than several tens of mg/kg are required to observe clinical signs, which is very much higher than the concentrations encountered in naturally contaminated feeds. Poultry species differences in sensitivity can be noted, turkeys appearing to be the most sensitive. These variations in sensitivity could be linked to differences in the metabolism of the toxin and the nature and proportions of resulting metabolites

(α -zearalenol more toxic vs β -zearalenol less toxic than zearalenone).

Impact of multi-contaminations

If the toxicity of the main mycotoxins in poultry is now relatively well documented, there is little data on the possible impact of a feed simultaneously containing several mycotoxins. Yet the particularities of mycotoxinogenesis mentioned earlier make that the simultaneous exposure to several mycotoxins is probably the most common case scenario in the field. Therefore, it would be of particular interest to evaluate the possible synergistic or additive effects of several mycotoxins when ingested simultaneously. This might help explain why, in cases of natural feed contamination, deleterious effects are often observed with toxin concentrations that are below the ones typically reported in the literature and that have been determined based on experimental intoxications using a single mycotoxin at a time. The large number of possible combinations makes it difficult to address this issue experimentally. However, recent studies suggest that a mixture of mycotoxins at below recommended levels (when such information is available), may result in the appearance of clinical signs in exposed poultry. The conditions are mainly characterized by a decrease in production performances (reduced weight gain) and other more subtle changes (modification of the morphology of the small intestine, changes in the secretion of some neurotransmitters) that could be involved in reducing feed intake or efficiency.

LABORATORY ANALYSIS

As previously reported, the clinical signs observed with mycotoxicosis under field conditions are often not specific. The diagnosis is hampered by the difficulty in interpreting laboratory results. We can distinguish three major types of investigation: assessment of the global fungal flora, identification of specific fungal species, and the quantification of mycotoxins. The nature of the information provided by each type of investigation is different and it is important to select the appropriate tests depending on the situation encountered in the field.

Sampling

The type of samples sent to the laboratory will depend on the context of the analysis: feed quality control or suspicion of mycotoxicosis. Whatever the context, it should take into account the heterogeneity of feed contamination. Indeed, fungal

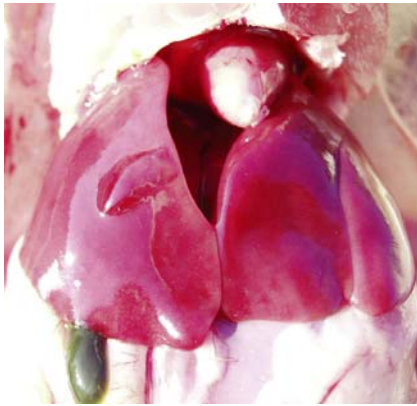


Fig.63.33: Trichothecene mycotoxicosis. Massive subcapsular liver hematomas causing sudden death in broilers.

Fig.63.34 & 63.35: Fumonisin intoxication. There is often diarrhea associated with delayed growth (Fig.63.34). In Fig.63.35, Two mallard ducks, one received, on right, a control and uncontaminated diet for 5 weeks and, on left, the other one received a diet containing 128 ppm of fumonisin B1.

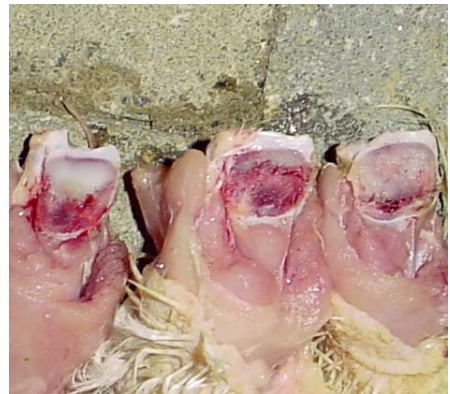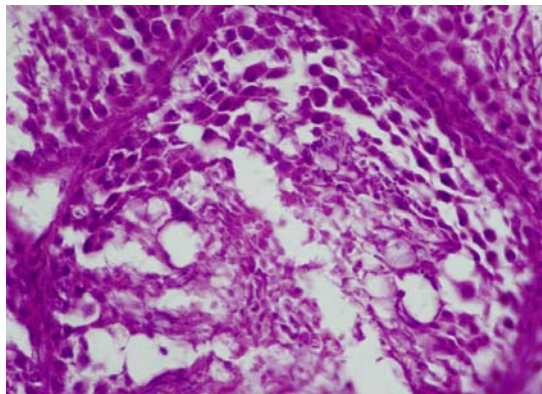

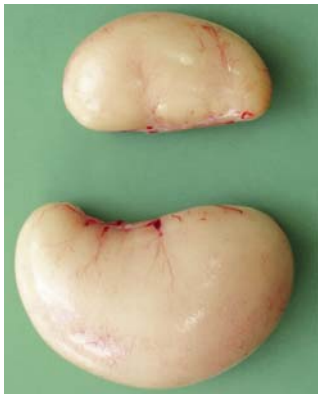
Fig.63.36 & 63.37: Intoxication by zearalenone. The effect is identical to that of estrogenic hormones and result in a reduction in size of testes (on top/control). Microscopically the testes show a fatty infiltration and atrophy of the germinal epithelium.

Fig.63.38. Fusarochromanone is suspected in tibial dyschondroplasia in broiler chickens although the majority of naturally occurring tibial dyschondroplasia does not appear to be due to this toxicosis.

Section IV

growth and mycotoxin production will only occur where hydro-thermal conditions are favorable to fungal metabolism: corn weakened by insect infestation, cold zone of the silo, damp areas, *etc.*

To assess overall feed quality, random sampling is done in order to obtain a representative sample of the batch of feed being evaluated.

If mycotoxicosis is suspected, sampling will instead focus on «at risk» material, which is the feed most likely implicated in the observed problem: visibly moldy area, feed distributed at the onset of clinical signs.

Analyses

The evaluation of the overall fungal flora can be done by fungal count. This analysis is particularly interesting to follow a feed production process and identify a source of contamination. Ergosterol

measurement is often used as an indicator of total fungal biomass. This biomarker is interesting because it resists to heat treatments that could destroy the mycoflora. Moreover, ergosterol content above 10 mg/kg of feed has often been associated with poor production results (quails and ducks), although no direct relationship with the presence of mycotoxins could be established. These results could be related to a reduction in nutritional value and/or digestibility of the ration due to fungal development.

The identification of fungal species that are present in a feed sample is often an important step in a mycotoxin investigation, especially when clinical signs are not suggestive of a specific mycotoxin. The identification of potentially toxinogenic species may guide the investigation towards specific mycotoxins. This work is also a valuable diagnostic tool when toxins are poorly understood or when no particular analytical method is available.

The direct quantification of specific mycotoxins in feed may generate results that are difficult to interpret. Indeed, given the large number of different mycotoxins, simply testing for known toxins does not always produce valuable information. The heterogeneity of mycotoxin contamination of feed may also explain contradictory results.

The direct search for mycotoxins in feed is fully justified when:

- testing the quality of feed in compliance with regulations;
- clinical signs are suggestive of a precise mycotoxicosis;
- there is a demonstrated contamination with potentially toxigenic strains.

Methods for quantification of mycotoxins using High Performance Liquid Chromatography -Mass Spectrometry (HPLC-MS) are rapidly expanding. Indeed, with a single extraction procedure, they can simultaneously test for several mycotoxins in a given sample. They are also sensitive and very specific.

CONCLUSION

Under field conditions, cases of acute mycotoxicosis with characteristic clinical signs are rare. Subacute forms of intoxication are more frequent but also more difficult to diagnose. Nevertheless, they can cause significant economic losses. To prevent such conditions, a fungal prevention program must be in place throughout the feed production chain. In high risk situations (e.g., favorable climate conditions for fungi), the application of fungistatic agents in raw materials and/or feed can, without eliminating already formed mycotoxins, increase shelf life by limiting mold development. In particular cases (presence of aflatoxins), the

addition of toxin binders to contaminated feed may reduce the deleterious effects of these toxins in birds.

REFERENCES

- AFSSA. Evaluation des risques liés à la présence de mycotoxines dans les chaînes alimentaires humaines et animales. AFSSA, Paris, 2009, 338 pp.
- Bailly JD et al. Evaluation of a fluorodensitometric method for analysis of ergosterol as a fungal contamination marker in compound feeds. *J. Food Protect.*, 1999,62:686-690.
- Bailly JD & Guerre P. Mycotoxicosis in poultry. In *Mycotoxins in farm animals*. Oswald IP. *Transworld Res. Net.*, India, 2008, pp 1-28.
- Bailly S., Bailly JD. Mycotoxines et mycotoxicoses : les analyses de laboratoire. *Bull. GTV*, 2010,53:63-70.
- Devegowda G & Murthy TNK. Mycotoxins : their effects in poultry and some practical solutions. In "The mycotoxin blue book", Diaz D., Nottingham Univ Press, Nottingham, 2005, p 25-56.
- Moreau C. *Moisissures toxiques dans l'alimentation*. Masson éd., Paris 1974, 471pp.
- Le Bars J. Toxigenesis as a function of the ecological conditions of the grain/microorganisms system. In "Preservation and storage of grains, seeds and their by-products", Multon JL, Lavoisier pub., N. Y. and Paris 1988, p 347-366 .
- Le Bars J. Gestion des risques mycotoxiques en alimentation animale. Eastern Nutrition Conference, *Anim. Nutr. Assoc.* Canada, Montreal, May 2000, p 225-246.
- Steyn PS. The biosynthesis of mycotoxins, *Acad. Press, N.Y. and London* 1980, 432pp.
- Willye TD, Morehouse LG. *Mycotoxicoses of domestic and laboratory animals*. M. Dekker inc., N.Y. and Basel 1978.

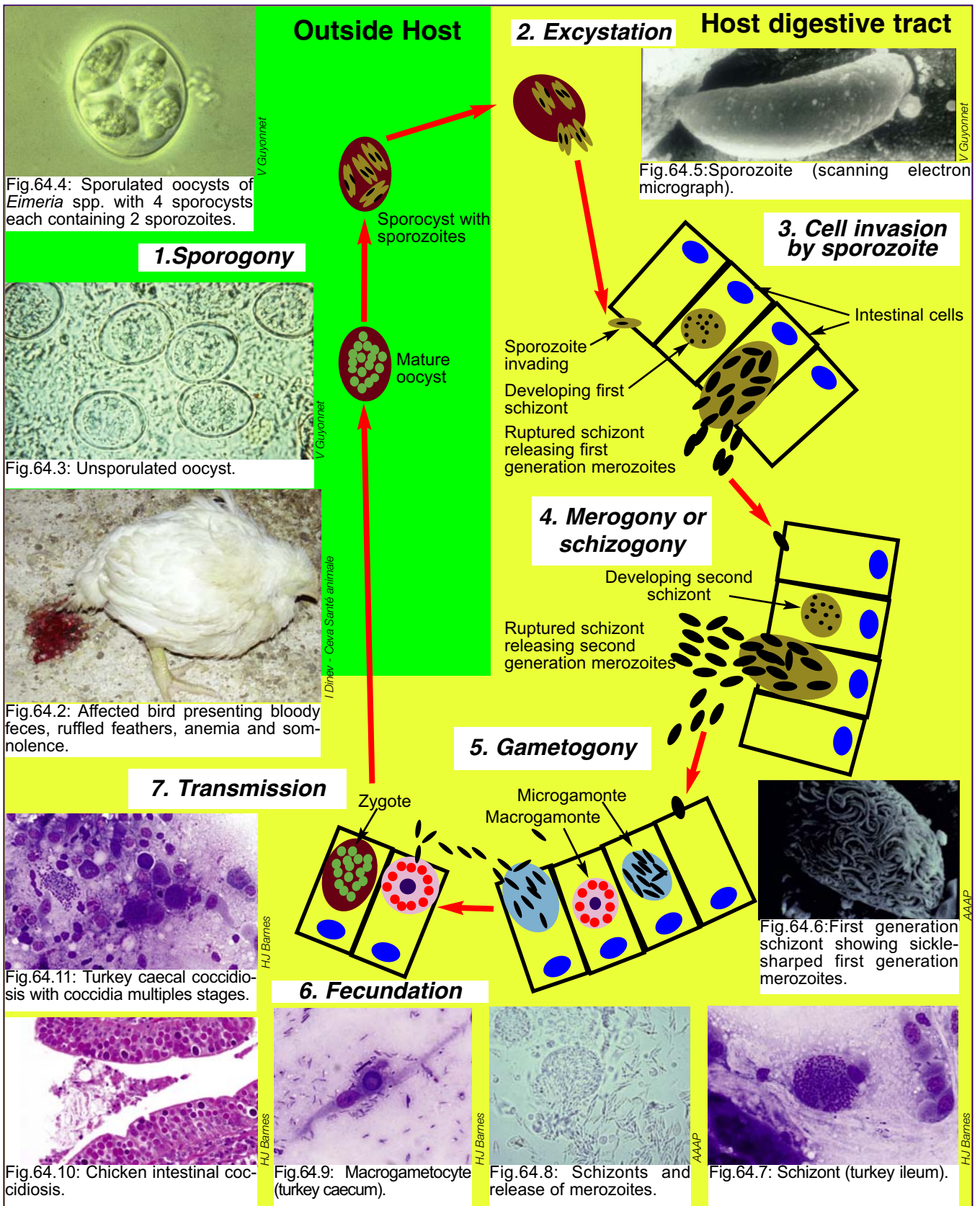


Fig.64.1: Life cycle of *Eimeria tenella*: 1) sporogony: unsporulated oocysts mature outside the host and sporulated oocysts; 2) excystation: upon ingestion by the host, release of the sporozoites from the sporulated oocysts by mechanical and enzymatic actions; 3) cell invasion by sporozoites; 4) merogony or schizogony: asexual multiple divisions of parasites (meronts of 1st, 2nd and 3rd generations); 5) gametogony (macro = female, micro = male); 6) fecundation: zygote transforms into an oocyst; 7) transmission: release of oocysts into the lumen of the intestine after cell rupture and excretion with the feces.

Other diseases

64. COCCIDIOSIS

INTRODUCTION

Coccidiosis is caused by various *Eimeria* species affecting mostly the digestive tract of poultry. With a global distribution of these parasites, the economical impact for this disease is estimated at over US\$ 1 billion, due to production and animal losses as well as the cost of the widespread usage of prophylactic medications and vaccines. It is widely accepted that the poultry industry would not have developed so rapidly in the 1950's without the discovery of effective anticoccidials. With most of the research conducted in broilers and breeder birds, our knowledge of coccidiosis in species like turkey, duck, guinea fowl, quail or pheasant is limited.

ETIOLOGY & EPIDEMIOLOGY

Taxonomy

The parasites responsible for coccidiosis in poultry belong to the family of the *Eimeriidae*, all obligate intracellular parasitic protozoa. The structure of the sporulated oocyst allows for the distinction between *Eimeria* spp. and other parasites like *Cryptosporidium* spp. *Eimeria* sporulated oocysts contain 4 sporocysts and each sporocyst 2 sporozoites. *Eimeria* spp. are extremely species specific for their host, with some species affecting only chickens, other only turkeys or guinea fowl. A number of species have been identified in chickens (7), turkeys (5), quail (1), guinea fowl (2), geese (4), pigeons (2) and pheasants (4).

Life cycle of *Eimeria* spp.

Seven distinct phases have been identified:

1) Sporogony: mature oocysts are eliminated with fecal materials and can remain in the litter for long periods of time. Under the right conditions of temperature (15-30 °C) and moisture, the oocysts will sporulate in about 48 hours and transform into a characteristic structure made of 4 sporocysts, each containing 2 sporozoites. At this stage, the sporulated oocysts are ready to infect a new host upon ingestion;

2) Excystation: release of the sporozoites through a process involving both the mechanical action of the gizzard and the enzymatic action of the digestive tract (bile and proteolytic enzymes such as trypsin,

chymotrypsin and elastase);

3) Cell invasion: upon release in the digestive tract, the sporozoites enter the epithelial cells of the intestine or ceca in a zone well defined for each species of *Eimeria*. Inside the cells, the sporozoites will transform into trophozoites;

4) Merogony or schizogony: during this phase, the parasite (schizont) will multiply by a process of asexual multiple division called merogony and each schizont will release upon cell rupture several thousand merozoites. Depending on the species of *Eimeria*, this process will be repeated between 2 to 4 times with the invasion of new epithelial cells;

5) Gametogony: at a certain time, the merozoites invading the host cells become gametocytes, either males or females. The male gametocytes multiply by a process of asexual multiple division and release microgametes into the lumen of the gut. Conversely, the female gametocytes do not multiply any further and mature into macrogametes inside the host cells;

6) Fecundation: after the penetration of the microgametes inside the macrogametes, a thick wall builds up around the zygotes, transforming into oocysts;

7) Transmission: oocysts (unsporulated) are released by the rupture of intestinal cells and are excreted with the feces. Overall, the ingestion of a sporulated oocyst can potentially lead to the production of about 2-3 millions new oocysts in 5 to 7 days.

A number of factors, either related to the parasites or the host, will affect this life cycle. Depending on the *Eimeria* species, these parasites will colonize specific regions of the intestinal tract, at a depth varying with the species considered. The period between the ingestion of the sporulated oocysts and the release in the feces of the first unsporulated oocysts, also called prepatent period, is specific for each *Eimeria* species. Likewise, the period required for the sporulation of oocysts is also species specific. These two elements can be used as an aid to the identification of the *Eimeria* species involved. However, the prepatent period can also be modified by genetic selection, as demonstrated by the precocious lines (shorter prepatent period) developed as vaccinal strains. The specificity of the invasion sites can also be altered with some

Host	<i>Eimeria</i> species	Normal development site
Chicken	<i>Eimeria acervulina</i>	Small intestine (duodenum and first 1/3)
	<i>Eimeria praecox</i>	Small intestine (duodenum)
	<i>Eimeria maxima</i>	Small intestine (around Meckel diverticulum)
	<i>Eimeria necatrix</i>	Small intestine (middle), caecum (oocysts)
	<i>Eimeria mitis</i>	Small intestine (second 1/2)
	<i>Eimeria brunetti</i>	Small intestine (distal section), large intestine, rectum
Turkey	<i>Eimeria tenella</i>	Caecum
	<i>Eimeria adenoides</i>	Caecum, rectum
	<i>Eimeria gallopavonis</i>	Small intestine (distal section), large intestine, rectum
	<i>Eimeria meleagrimitis</i>	Small intestine (first 1/2)
	<i>Eimeria meleagridis</i>	Caecum
Quail	<i>Eimeria dispersa</i>	Small intestine (middle section)
	<i>Eimeria bateri</i>	Small intestine
Guinea fowl	<i>Eimeria grenieri</i>	Small intestine, caecum (oocysts)
	<i>Eimeria numidae</i>	Small intestine, large intestine
Goose	<i>Eimeria anseris</i>	Small intestine (middle and distal sections)
	<i>Eimeria fulva</i>	Small intestine (second 1/2) and caecum
	<i>Eimeria nocens</i>	Small intestine (second 1/2), caecum and rectum
	<i>Eimeria truncata</i>	Kidney
Pigeon	<i>Eimeria columbarum</i>	Small intestine (jejunum and ileum)
	<i>Eimeria labbeana</i>	Small intestine
Pheasant	<i>Eimeria colchici</i>	Small intestine (middle and distal sections), caecum
	<i>Eimeria duodenalis</i>	Small intestine (duodenum)
	<i>Eimeria phasiani</i>	Small intestine and caecum
	<i>Eimeria pacifica</i>	Caecum

Tabl.64.1: Main *Eimeria* species in poultry.

<i>Eimeria</i> spp.	Prepatent period (hours)	Sporulation time (hrs)	Avg. Oocyst size (µm)
Chickens			
<i>E. acervulina</i>	97	17	18.3 x 14.6
<i>E. maxima</i>	121	30	30.5 x 20.7
<i>E. necatrix</i>	138	18	20.4 x 17.2
<i>E. mitis</i>	93	15	15.6 x 14.2
<i>E. praecox</i>	83	12	21.3 x 17.1
<i>E. brunetti</i>	120	18	24.6 x 18.8
<i>E. tenella</i>	115	18	22.0 x 19.0
Turkeys			
<i>E. adenoides</i>	103	24	25.6 x 16.6
<i>E. gallopavonis</i>	105	15	27.1 x 17.2
<i>E. melagrimitis</i>	103	18	19.2 x 16.3
<i>E. meleagridis</i>	110	24	24.4 x 18.1
<i>E. dispersa</i>	120	35	26.1 x 21.0

Tabl.64.2: Minimum prepatent period (time from the ingestion of sporulated oocysts to the production of oocysts in feces, time expressed in hrs), sporulation time (time required for oocysts to transform into the typical infestive oocyst structure with 4 sporocysts, each containing two sporozoites, time expressed in hours) and oocyst dimensions for the *Eimeria* spp. in chickens and turkeys.

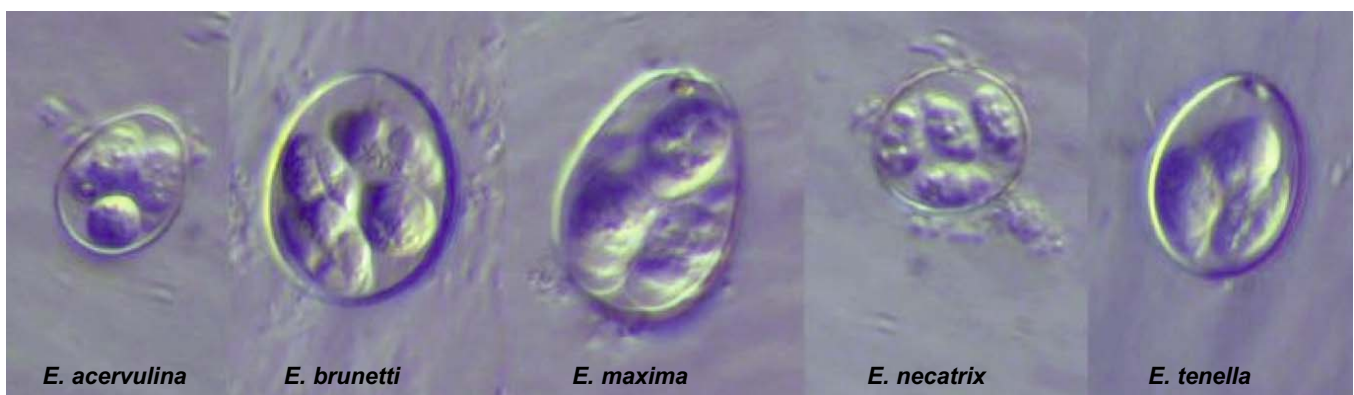


Fig.64.12, 64.13, 64.14, 64.15. & 64.16: Comparative sizes of oocysts of 5 *Eimeria* species pathogenic in chicken.

JM Répérant

species able to develop in embryonated eggs (for research purpose only) or in unusual hosts.

The immune status of the hosts will also affect the normal development of the life cycle of the parasites.

Eimeria spp.: host and site specificity

One of the characteristics of *Eimeria* spp. is their strong host specificity. The mechanisms involved with this specificity may be linked to the nutrition and biochemistry of the parasites, to the genetic profile of the host or to some specific host defense mechanisms. The site specificity of the infestation is another characteristic of these parasites, with different species invading different sites along the digestive tract. The distribution of the invasion sites is often specific enough to allow the identification during *post-mortem* examination of the species involved. Some species will develop mostly superficially in epithelial cells (*Eimeria praecox*) throughout their life cycle while others will invade deeper layers such as the cells of the Lieberkühn crypts and the lamina propria (*Eimeria necatrix* and *E. tenella*).

COCCIDIAL IMMUNITY

This immunity is marked by a reduced severity of the clinical signs as well as a decreased number of parasites completing their life cycle with the production of oocysts. In some cases, the reduction in clinical signs is not linked to a reduction of the lesions observed. The immunity to coccidiosis is divided into innate mechanisms, best demonstrated by the strict host specificity of these parasites and acquired immunity. The acquired immunity is species specific and in the case of *Eimeria acervulina*

and *E. maxima* even strain specific. *Eimeria* spp. vary in immunogenicity: *E. maxima* and *E. praecox* are extremely immunogenic with the completion of one life cycle sufficient to trigger a strong immunity; conversely, *E. tenella* (3-4 cycles) and *E. necatrix* (4-5 cycles) are much less immunogenic. The immunity will be the strongest after repeated contacts with the parasites, even if only a few oocysts at a time (principle of trickle immunity).

The asexual stages of development are considered essential for the development of immunity but variations exist between species. When the host has developed a solid immunity, the sporulated oocysts will typically excyst and the sporozoites invade the cells; however, their development will usually stop after 24-48 hours. When the immunity is less established, some cycles of merogony and even gametogony can occur; oocysts can even be released in the feces although for shorter period of time (patent period reduced). The length of the immune protection will depend on the species and the frequency of re-exposure to new parasites. The coccidial immunity is mostly cell-mediated with the initial stage triggered by the presentation of parasitic antigens on the surface of macrophages to lymphocytes. The role of CD8⁺ lymphocytes is complex with a direct action via the secretion of lymphokines and lymphotoxines and with an indirect role in the recruiting of macrophages. The roles of macrophages and natural killer cells are also important. Humoral immunity has only a limited role and there is no correlation between immunoglobulin levels in the plasma and the degree of protection against coccidiosis. Secretory IgA and IgM may play a role at the intestinal wall level and contributes to the protection against cell invasion. In spite of much research over the past 20 years, the immune mechanisms are still not clearly established.

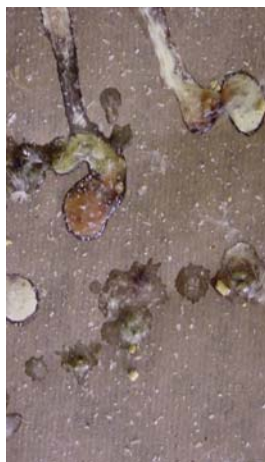
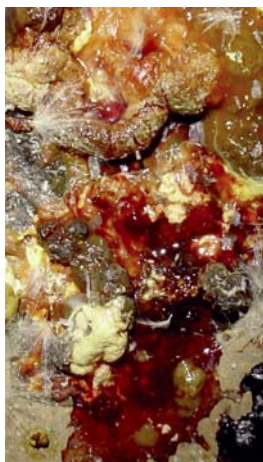

Fig.64.17 & 64.18: The presence of dysentery (*E. tenella* on the left), diarrhea or mucoïd feces (*E. acervulina* on the right) alert the farmer.



Fig.64.19: With less pathogenic *Eimeria* species, the only sign can be poor growth.

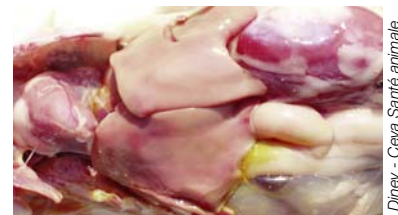

Fig.64.20: Coccidiosis. Anemic appearance of internal organs.

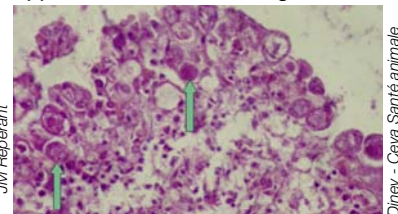
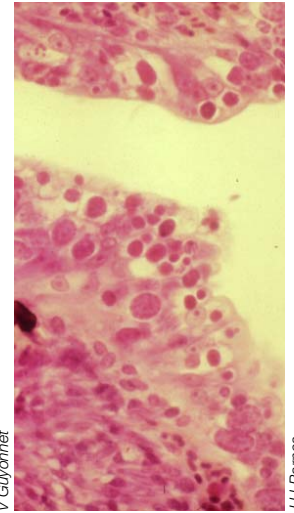
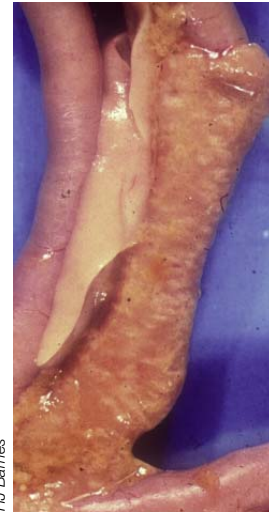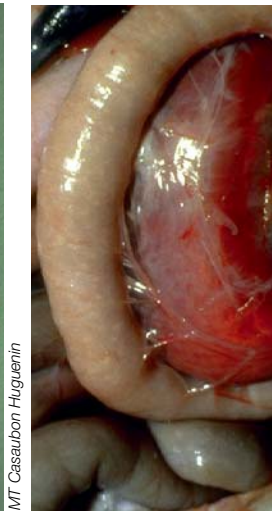

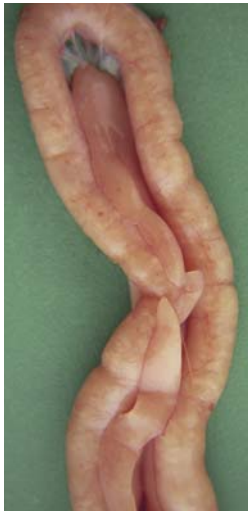
Fig.64.21: *Eimeria* organisms in the epithelial intestinal cells (arrows).



Fig.64.22: *E. acervulina*. Zone parasited.



Zoetis

MT Casaubon Huguenin

HJ Barnes

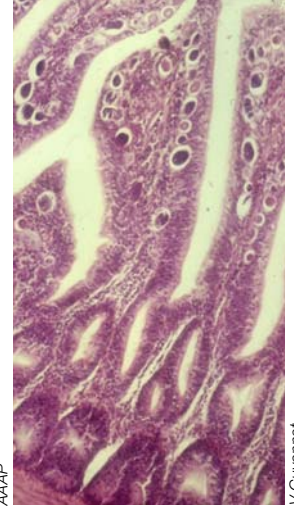
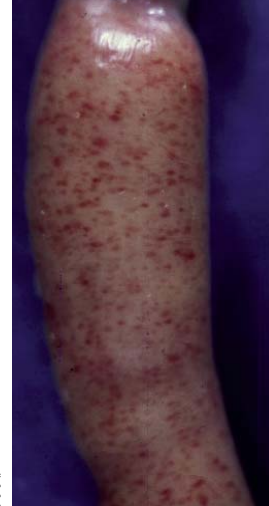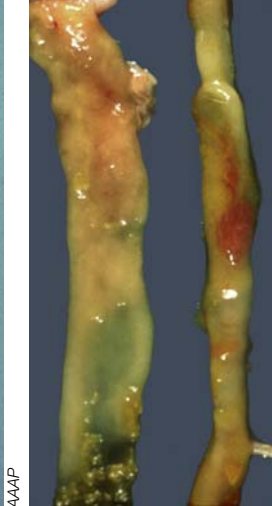
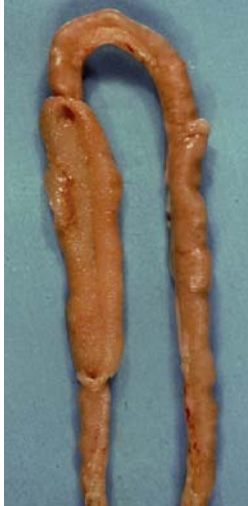V Guyonnet

HJ Barnes

Fig.64.23 to 64.26: *E. acervulina*. Lesions along the duodenum loop. When severe, the lesions will extend to the jejunum. Typical white steaks, oriented transversally (ladder-like) along the duodenum (Fig.64.25). The thickening of the intestinal mucosa observed is due to the aggregation of gametocytes and oocysts (Fig.64.26).



Fig.64.27: *E. maxima*. Zone parasited.



Zoetis

AAAP

AAAP

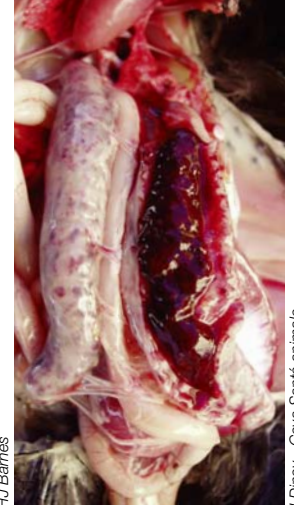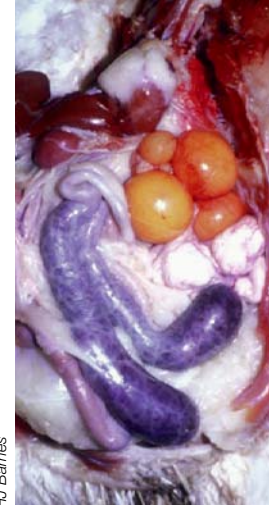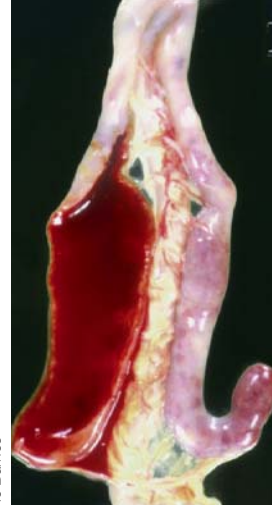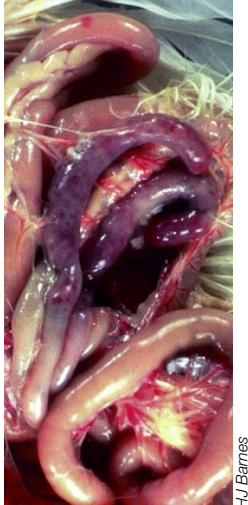AAAP

V Guyonnet

Fig.64.28 to 64.31: *E. maxima*. Characteristic orange tinge to the mucus in the mid-intestine section. Petechies, seen 4 to 6 days after ingestion of oocysts, appear deep in the submucosa and are best seen from the serosal surface. Macrogametes, zygotes and oocysts on day 6 post-inoculation (Fig.64.31).



Fig.64.32: *E. tenella*. Zone parasited.



Zoetis

HJ Barnes

HJ Barnes

HJ Barnes

I Dinev - Ceva Santé animale

Fig.64.33 to 64.36: *E. tenella* is the best known of poultry coccidia with easy recognizable lesions and spectacular losses in commercial broilers (Fig.64.33 & 64.34: broiler breeders aged 7 weeks) or layer pullets (Fig.64.35). Lesions are characterized by thickening of the cecal walls and blood visible in the opened caecum (Fig.64.36).

CLINICAL SIGNS & LESIONS

The severity of the clinical signs and lesions will vary depending on the species of *Eimeria* involved (with often more than one species involved) and the extent of the damages produced on the intestinal wall. The age of the hosts, their nutritional status, their immune status, and the presence of other pathogens will also affect the severity of these clinical signs and lesions. A reduced weight gain or even a loss of weight is one of the most common and early observation, even in the absence of clear clinical signs. This weight loss is attributed to a reduction in the absorption and conversion of nutrients as well as a decrease in feed consumption. Water consumption is often reduced 4 to 5 days after infection. A decrease in the intestinal pH also contribute to a change in the intestinal flora, with an increase in coliforms and anaerobes like *Clostridium perfringens* and a decrease of lactobacillus and bifidoc bacteria, leading often to concurrent signs of colibacillosis and necrotic enteritis.

In chickens, depending on the *Eimeria* spp. involved and the severity of the infection, a mucoid or hemorrhagic diarrhea may be observed along with the unthriftiness of the birds. In turkeys, the clinical signs are often less noticeable and the diarrhea will seldom be hemorrhagic. Signs are seen only in animals less than 8 weeks old. In other species of poultry, the clinical signs are not characteristic of the disease.

The most significant lesions are linked to cellular infiltration, epithelial cell losses, epithelial hyperplasia and vascular damages. These lesions will vary from species to species.

***Eimeria acervulina*:** The lesions observed in the small intestine (duodenum and jejunum) are due to the atrophy of the villi and a cellular hyperplasia of the *lamina propria*. The regeneration of the epithelial cells is accelerated while that of the cells in the crypts is reduced. White streaks, oriented transversally along the intestine (often described as ladder-like) represent a thickening of the intestinal mucosa due to the aggregation of gametocytes and oocysts.

***Eimeria maxima*:** The thickening of the mucosa observed is due to the development of large gametocytes in the epithelial cells and their diffuse distribution along the mucosa. Petechiae are also observed and give this characteristic orange tinge to the mucus.

***Eimeria tenella*:** The lesions observed are due to the large size (up to 60 µm) of the 2nd generation schizonts, located in cells migrating towards the *lamina propria*. The rupture of capillaries will often precede the release of merozoites. Hemorrhages appear around 72 hrs after inoculation and hemorrhagic or whitish lesions (1-5 mm) can be observed in the ceca 120 hrs after inoculation. If the birds survive, the lesions will slowly disappear but the cecal content will typically remain caseous.

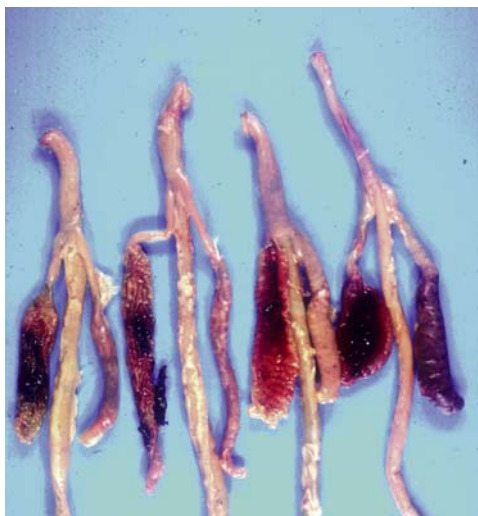


Fig.64.37: *E. tenella*. Lesions increasing in severity often described as lesion score 1, 2, 3 and 4 (from left to right).

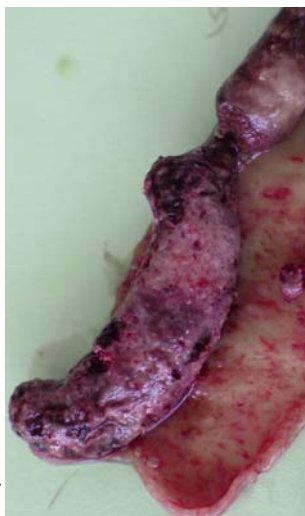

Fig.64.38 & 64.39: *E. tenella*. The cecal pouch may become distended and greatly enlarged with clotted blood and peace of cecal mucosa in the lumen. Typical white caseous content in the ceca will be observed after the lesions are resorbed.

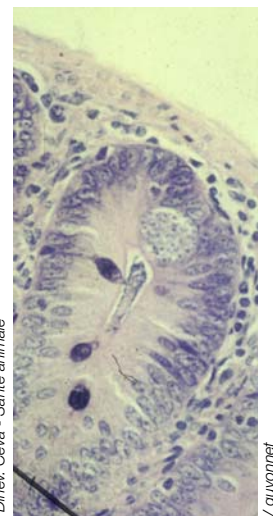
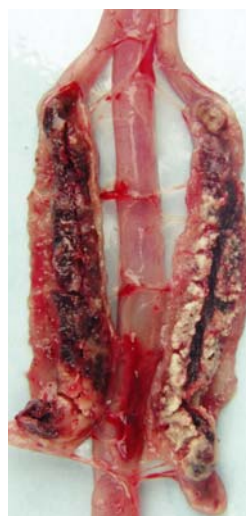
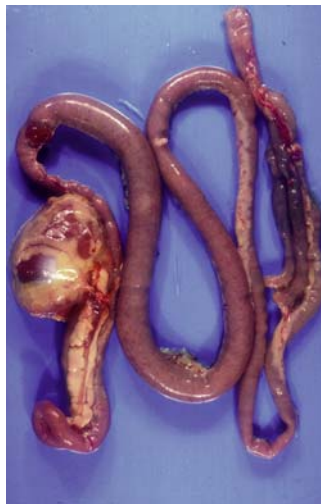
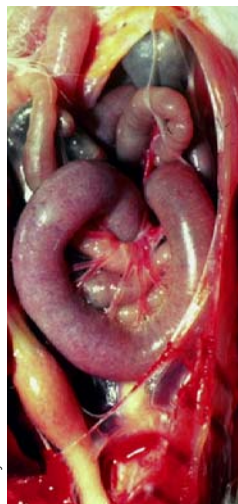Fig.64.40: *E. tenella*. Lesions are due to the large size of second schizonts located in cells migrating towards the *lamina propria*.



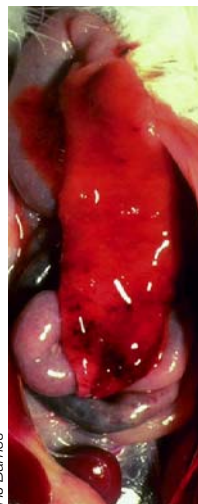Fig.64.41: *E. necatrix*. Zone parasited.



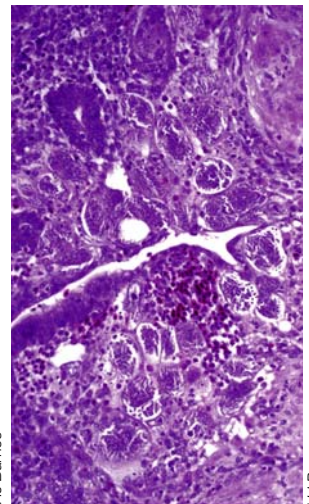
Zoetis



V Guyonnet



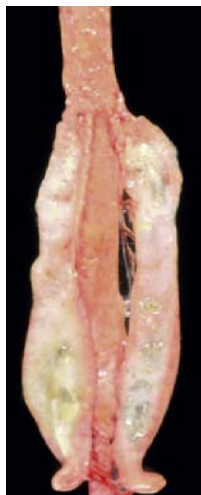HJ Barnes



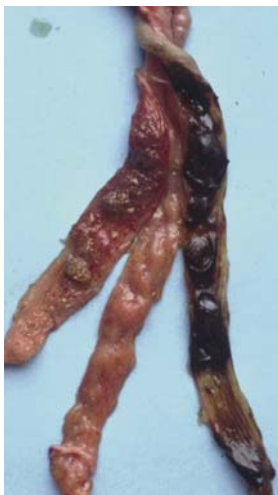HJ Barnes

Fig.64.42, 64.43 & 64.44: *E. necatrix*. Lesions present the typical «salt and pepper» characteristics (juxtaposition of petechiae and plaques of large second generation schizonts) on the serosal surface along with a ballooning of the area. Considerable blood and mucus is visible upon the opening area.

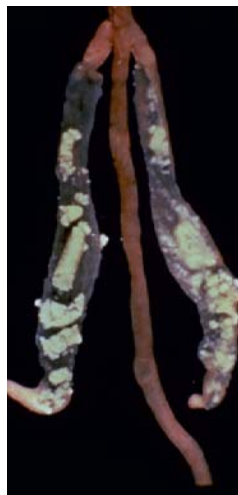Fig.64.45: *E. necatrix*. Lesions are due to the large second generation schizonts located in the cells of lamina propria.



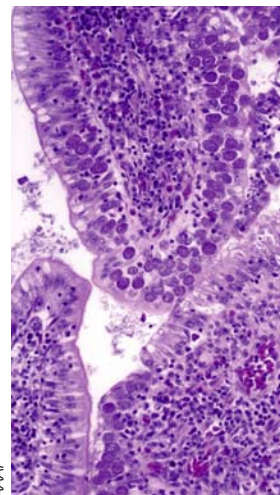
HJ Barnes



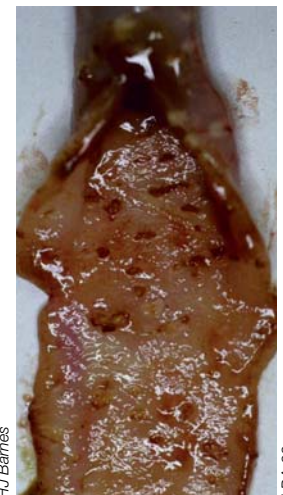
LDA 22



AAAP



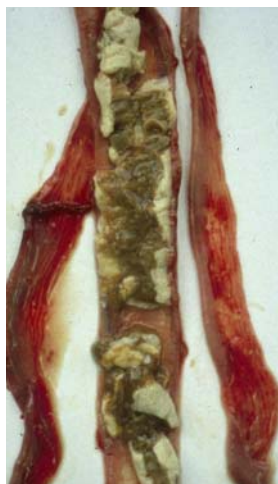HJ Barnes



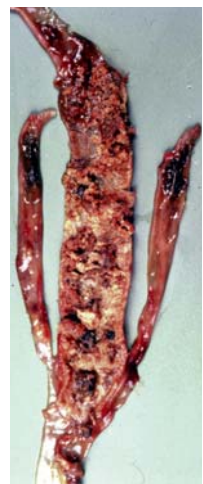LDA 22

Fig.64.46 to 64.49: *E. adenoeides*. The caeca (both mucosal and serosal surfaces) may appear white in color. Loose or solid white caseous cores in the caeca usually contain large number of oocysts. The lesions are due to the large second generation schizonts located in the epithelial cell of the caeca (Fig.64.49).

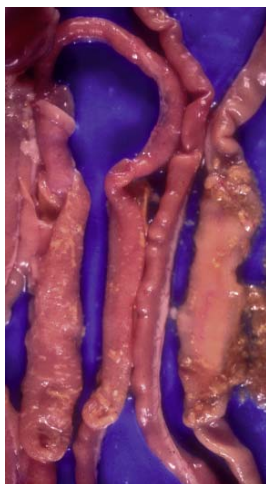Fig.64.50: *E. meleagrimitis*. Ulceration of the jejunum.



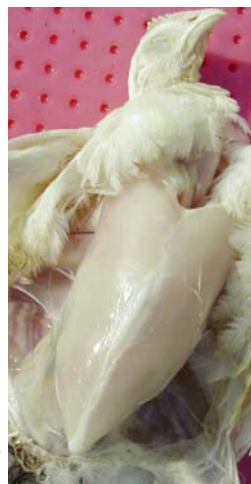Zoetis



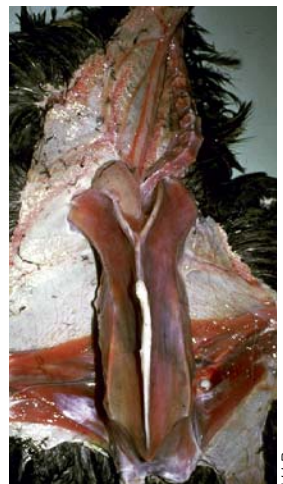Sanders



V Guyonnet



Dinev - Ceva Santé animale



HJ Barnes

Fig.64.51: *E. gallopavonis*. Necrotic ileitis.

Fig.64.52: *E. brunetti*. Heavy necrotic infection with badly damaged of the mucosa.

Fig.64.53: Mixed infection are often seen in the field with the juxtaposition of lesions from *E. acervulina* and *E. maxima* in the upper and middle intestine.

Fig.64.54 & 64.55: Coccidiosis can lead to dehydration, anaemia and the emaciation can be important like in Fig 64.55 with *E. acervulina*.

***Eimeria necatrix*:** Like with *Eimeria tenella*, the lesions are due to the large 2nd generation schizonts, located in the cells of the *lamina propria*. These lesions are most visible on the serosal surface, 5 days after inoculation and give the intestine the typical “salt and pepper” aspect with the juxtapositions of petechiae and white zones containing large schizonts. Oocysts are formed in the ceca where they do not produce any lesions.

***Eimeria adenoides*:** The lesions are due to the large 2nd generation schizonts, located in the epithelial cells of the ceca. Petechiae can be observed as early as 4 days after inoculation. A caseous plug, white to grey in colour, is often present in the ceca.

***Eimeria gallopavonis*:** The lesions are due to the large gametocytes. The ileum mucosa is oedematous, ulcerated and presents at its surface a caseous necrotic coat containing numerous oocysts. The white nodules on the mucosa are similar to the lesions seen with *E. acervulina*.

***Eimeria meleagridis*:** The mucosa of the small intestine (duodenum) is congested with the infestation of villi. These lesions are similar to those observed with *E. maxima*.

In pheasants, guinea fowls or pigeons, the lesions are often those of a mucoid or necrotic enteritis.

DIAGNOSTIC PROCEDURES

While the clinical signs are not characteristic, some lesions observed during *post-mortem* examinations are specific enough to diagnose coccidiosis and the species involved. The presence of oocysts must be associated with clinical signs or lesions to confirm the diagnosis. One of the problems for the clinician will be to determine whether coccidiosis was the initial cause of the enteritis or a consequence of another pathology.

Differential diagnosis will be required to distinguish between possible causes of enteritis of infectious (parasites like *Cryptosporidium* spp., *Histomonas*, ascarids, *Capillaria*; viruses like enterovirus, reovirus, rotaviruses, adenovirus; bacteria like *Salmonella* spp., *Escherichia coli*, *Clostridium perfringens*, *Clostridium colinum*, *Mycobacterium avium*) and non-infectious origin (intoxications to nitrofurans or sodium chloride, toxins, mycotoxines and biogenic amines). Coccidiosis is often suspected when feed conversion is negatively affected. However, some factors related to the feed, the environment and the health status of the flock will also affect the feed conversion and must be evaluated. A solid diagnosis

will be the result of the *post-mortem* observation of specific lesions along with the scrapping of intestinal surface and the observation of unsporulated oocysts. The size of oocysts (length and width) will further assist in the differentiation of *Eimeria* spp. involved.

TREATMENT & CONTROL

Treatment

Few products are available for the treatment of coccidiosis. Any treatment will be effective only if given very early on. The use of vitamin packs (vitamin A, E and K) may facilitate the recovery.

Control

Hygiene: Sanitary measures like the removal of dirty litter (wet and caking spots), the cleaning and disinfection of equipment and buildings at the end of each grow-out period will greatly contribute to the reduction in the contamination of the environment. Only few disinfectants, often toxic to humans, can effectively destroy the oocysts and are therefore not commonly used. Regardless of these sanitary measures, the majority of broiler producers will rely on prophylactic measures with the use of anticoccidials in the feed and/or vaccines.

Drugs: Traditionally, anticoccidials have been divided into two categories based on their effect on the parasites: coccidiostatic (development of the parasites is stopped without the destruction of the parasites) and coccidiocidal (destruction of the parasites). As a few products presented both types of activity depending on the *Eimeria* spp. considered or the duration of their administration, another classification was defined based on the mode of action and/or mode of production of these molecules. Therefore, anticoccidials are also referred as chemicals or synthetic products and ionophores or fermentation products. A number of products are available worldwide and each product will present some well established strengths and weaknesses. Since there are slight variations in dosage and duration of administration allowed by various countries, you should review your local legislation for more details. Anticoccidials may be used as a single product throughout the life of the birds (straight programmes) or as a combination of products given one after the other during the life of the birds (shuttle programmes). For straight programmes, ionophores are used in the majority of cases, as the best compromise between the control of the disease and the growth performance of the birds. In shuttle programmes, a wide variety of combinations have appeared over the years with the use of two to four different products. One of the

Molecule	Mechanism of action	Dosage (ppm)	Advantages	Disadvantages
Amprolium	Thiamine antagonist	125-250	Safe; can be used in breeders and layers	Limited activity on certain species; development of resistance
Amprolium + Clopidol	Thiamine antagonist Electron transfer inhibitor	125-250 125-250	Improved spectrum of activity Safe for many animal species	Development of resistance Resistance; low efficacy against <i>E. acervulina</i>
Clopidol + Méthylbenzoquate	Electron transfer inhibitor	100 8.35	Safe for many animal species	Resistance issue when used in straight continuous programme
Decoquinate	Electron transfer inhibitor	30	Extremely safe	Resistance issue when used in straight continuous programme
Diclazuril	Nucleoside analog	1	Spectrum of activity; safe in many animal species	Late activity against <i>E. maxima</i> ; resistance issue over long periods; cross-resistance with toltrazuril
Halofuginone	Unknown	3	Spectrum of activity	Resistance issue when used in straight continuous programme; low activity against <i>E. acervulina</i>
Nicarbazine	Unknown	100-125	Activity against <i>E. tenella</i> ; Reduction of oocyst production; fewer resistance issue over the years	Performance parameters affected; reduced resistance to heat stress; reduced egg production; discoloration of egg shells
Robenidine	Oxydative phosphorylation inhibitor	33	Lesion control; reduced oocyst production	Resistance issue; fishy taste of meat at higher levels
Toltrazuril	Nucleoside analog	25-75	Safe; water soluble (treatment)	Late activity against <i>E. maxima</i> ; cross-resistance with diclazuril
Sulfonamides	Folic acid antagonist & inhibitors	various	Spectrum of activity; water soluble (treatment)	Toxicity; resistance
Zoalene	Unknown	40-125	Well tolerated in broilers; used in pullets	Weak activity against <i>E. acervulina</i> and <i>E. brunetti</i> ; resistance issues

Tabl.64.3: Molecules, mechanism of action, dosage, advantages and disadvantages of the main chemical anticoccidials in chickens. **In each country, consult the local legislation for approval in a given species and dosage recommended.**

most popular programme is the combination of a chemical product during the first 2-3 weeks followed by an ionophore product 2-3 weeks but the reverse option is also frequently used. The combination of two products given at the same time is also used, as a means to improve anticoccidial control and limit performance issues. Often, straight programmes will be used for a period of the year and shuttle programmes for the rest of the year. All these systems highlight the complexity of the prevention of coccidiosis. The monitoring of the performance of these programmes is critical to their long term effectiveness as the parasites will develop resistance to anticoccidials (often observed with chemical products) or increased tolerance to anticoccidials (often the case with ionophores), allowing more and more parasites to complete their full life cycle. In turkeys, anticoccidials are usually administered during the first 8 weeks of life. The use of anticoccidial in other species is often not allowed (refer to your local legislation for more details).

Vaccines: The first anticoccidial vaccines appeared in the 50's and their usage was mostly limited to broiler breeders, layers raised on the floor and turkeys. Currently, the use of vaccines has increased tremendously, expanding to a broader use in broilers. Vaccines are usually made of live strains of several *Eimeria* spp. (*E. acervulina*, *E. maxima* and *E. tenella* are most commonly used), either natural strains isolated from the field or strains whose pathogenicity was reduced by various means (the repeated selection of the first oocysts produced lead to the development of precocious lines for each *Eimeria* spp.) Most vaccines are given during the first week of age, either by spraying at the hatchery, by water administration, by spraying on the feed or by incorporation into a gelatinous material placed at the hatchery in the boxes delivering the chicks. Regardless of the method used, a specific management of the flock and its environment will be required to achieve a low background cycling of the parasites in the birds, allowing for the development of immunity

Molecule	Mechanism of action	Dosage (ppm)	Advantages	Disadvantages
Monensin	Osmotic imbalance Na ⁺ /K ⁺	80 (Japan) 100-121 (Europe) 90-121	Dosage flexibility; safe in turkeys	Toxic for horses, dogs and cats; reduced feed consumption at higher dosages; nutritional interaction (Na)
Salinomycin	Osmotic imbalance Na ⁺ /K ⁺	50 (Japan) 40-66 (USA) 60	Excellent spectrum of activity; good production performance	Toxic for turkeys, horses and dogs; limited efficacy against <i>E. tenella</i> below 50 ppm
Lasalocid	Osmotic imbalance Na ⁺ /K ⁺	75 (Japan) 75-125 (USA)	Good activity against <i>E. tenella</i> ; increased water consumption	May cause wet litters; performance issue over extended usage
Narasin	Osmotic imbalance Na ⁺ /K ⁺	60-80 (USA) 70	Good spectrum of activity; better tolerated than monensin	Weak activity against <i>E. tenella</i> ; toxic for turkeys and horses
Maduramicin	Osmotic imbalance Na ⁺ /K ⁺	4-6	Excellent activity against <i>E. tenella</i>	Limited activity against <i>E. acervulina</i> and <i>E. maxima</i> ; may caused wet litters
Semduramicin	Osmotic imbalance Na ⁺ /K ⁺	20-25	Excellent spectrum of activity; safe in turkeys and horses	Reduced feed consumption at higher dosages
Nicarbazine + Narasin	Unknown Osmotic imbalance Na ⁺ /K ⁺	30-50 30-50	Activity against resistant strains	Performance parameters affected; reduced resistance to heat stress; reduced egg production; discoloration of egg shells
Nicarbazin + Maduramicin	Unknown Osmotic imbalance Na ⁺ /K ⁺	40 3.75	Activity against resistant strains	Same as for nicarbazin + narasin

Tabl.64.4: Molecules, mechanism of action, dosage, advantages and disadvantages of the main ionophore anticoccidials in chickens. **In each country, consult the local legislation for approval in a given species and dosage recommended.**

without negatively affecting production parameters. At times, treatment in the water may be required to reduce the proliferation of the parasites. Killed vaccines or sub-unit vaccines have been researched for the past 30 years without much success and are not used in broilers under commercial conditions.

CONCLUSION

Due to the characteristics of the parasites and the management conditions in poultry production, the eradication of coccidiosis is not possible. With the ever increasing cost of developing new molecules and the pressure to use less medication in food-producing animals, the control of coccidiosis must rely on the current prophylactic methods combined with proper flock management.

REFERENCES

- Chapman, H.D. et al., Sustainable coccidiosis control in poultry production: the role of live vaccines, *Int J Parasitology*, 2002,32:617-629.
- Johnson J & Reid WM. Anticoccidial drugs: lesion scoring techniques in battery and floor-pen experiments with chickens. *Experimental Parasitology*, 1970,28:30-36.
- Lillehoj H & Okumura M. Host immunity and vaccine development to coccidian and Salmonella infections in chickens, *J Poultry Sci*, 2003,40:151-193.
- Long, PL, In “*Coccidiosis of man and domestic animals*”, CRC Press, pp. 1-349.
- McDougald L, Fitz-Coy SH. Coccidiosis. In “*Diseases of Poultry – 12th edition*”, Blackwell Publishing, p. 1068-1091.

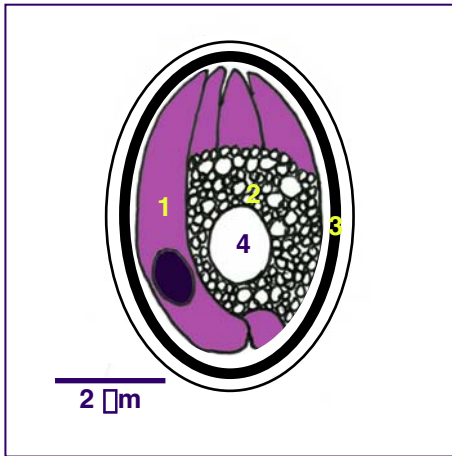


Fig.65.1: Oocyst of *Cryptosporidium baileyi* (According to Current et al, 1986). Unlike coccidia of the genus *Eimeria*, *Cryptosporidium* oocysts are not sporocyst; the four vermiform sporozoites are free.

- 1: sporozoite
- 2: residual body
- 3: wall
- 4: globule

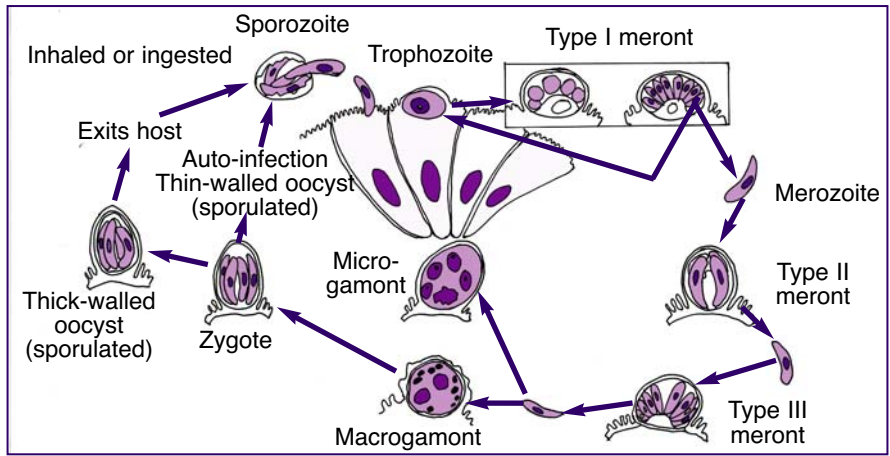


Fig.65.2: Life cycle of *Cryptosporidium baileyi* (According to Current et al., 1986). It can be divided into six major stages after ingestion or inhalation of oocysts in the environment:

- 1) Excystation (release of infective sporozoites entering the epithelial cells of the intestinal tract and/or respiratory disease confined to the microvilli);
- 2) Merogony (asexual multiplication within epithelial cells);
- 3) Gametogony (formation of male and female gametes);
- 4) Fertilization (union of gametes);
- 5) Oocyst wall formation (to produce a resistant form in the environment);
- 6) Sporogony (formation of infective sporozoites within the oocyst).

Section IV

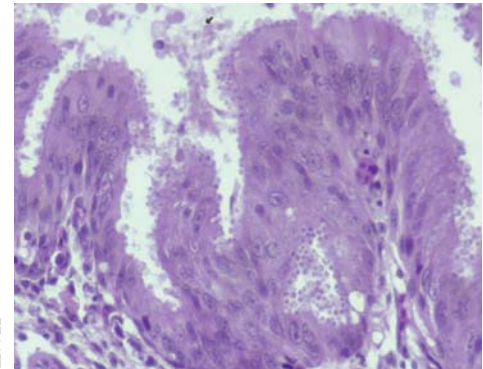
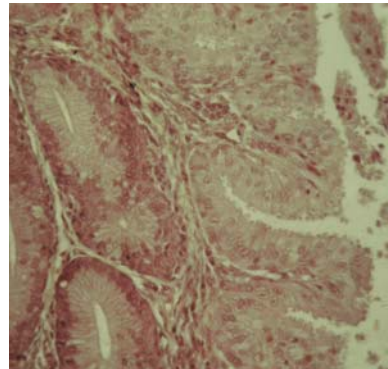
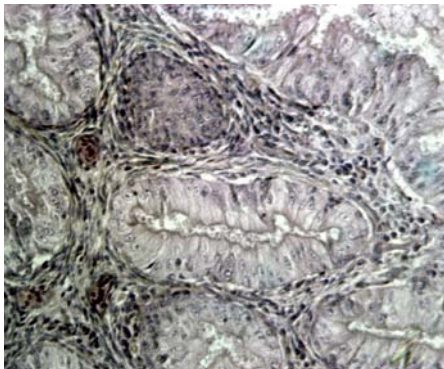


Fig.65.3 & 65.4: Bursa of Fabricius of chicken infected with *C. baileyi*. Epithelial metaplasia and presence of *C. baileyi* on the surface of the epithelium.

Fig.65.5: Presence of *C. baileyi* on the surface of epithelial cells of bronchi (hematoxylin-eosin-safran) (Hen).

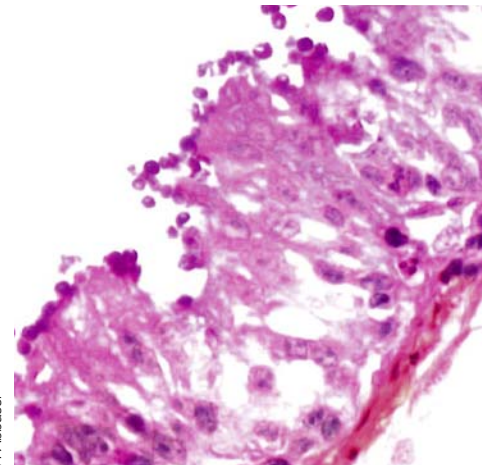
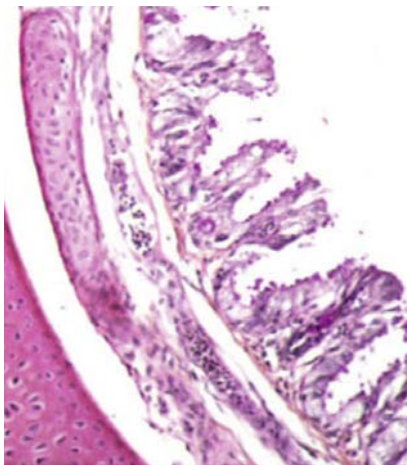
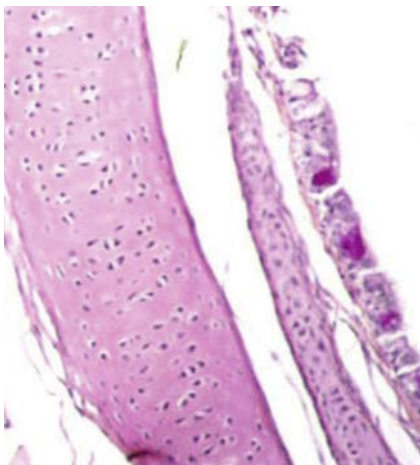


Fig.65.6, 65.7 & 65.8: Histological lesions of the trachea of infected chickens with *C. baileyi* oocysts (periodic acid-Schiff stain). In comparison with the trachea of a control bird (left), we observe epithelial hyperplasia and the presence of *Cryptosporidia* on the surface of the epithelium.

Other diseases

65. CRYPTOSPORIDIOSIS

INTRODUCTION

Cryptosporidiosis is caused by protozoa of the genus *Cryptosporidium*, of the phylum *Apicomplexa*, which develop within microvilli of epithelial cells of the respiratory tract and gastrointestinal tract of vertebrates. In birds, *C. Baileyi* (intestinal and respiratory tropism) and *C. meleagridis* (intestinal tropism) are mainly known. Also included is *C. galli*, encountered in cage birds and chickens, that develops in the proventriculus. In chickens, turkeys and quails, these parasites are primary pathogens producing a respiratory and/or intestinal disease. These avian *Cryptosporidia* do not show host specificity and other birds can be infected (geese, ducks, cage and game birds).

Although human cryptosporidiosis is a zoonosis, there is no evidence that *C. Baileyi*, the avian species, is the cause of infection in non-avian species. Similarly, *C. parvum*, predominant pathogen in humans, is not known in poultry. However, it seems that *C. meleagridis* is in fact identical to *C. parvum*.

ETIOLOGY

Cryptosporidium baileyi and *C. meleagridis* can be identified based on the morphology of their oocysts: an ovoid shape measuring 6.2 x 4.5 µm and 5.2 x 4.6 µm, respectively.

Life cycle of *Cryptosporidium* spp.

The life cycle of *Cryptosporidium* is like other true coccidia (see chapter IV.64). There are two types of oocysts according to the type of wall. Thick-walled oocysts are passed in droppings or respiratory secretions to infect other hosts, while thin-walled forms are responsible for endogenous self-infections by *in situ* rapid excystation and infection of new cells. The prepatent and patent periods of *C. baileyi* are 2 to 7 days and 4 to 32 days, respectively. Those of *C. meleagridis* are 3 to 5 days and 6 to 16 days, respectively. These periods vary with age of the birds.

Development sites

The genus *Cryptosporidium*, particularly the species *C. baileyi*, has no organ specificity. During natural infection, *Cryptosporidia* are found in different anatomical sites, especially the bursa of Fabricius, cloaca and respiratory tract. The immune status and intercurrent infections have an

effect on the distribution of the parasite. For example, the inoculation of *C. baileyi* oocysts in chickens co-infected with the virus of Marek's disease results in the development of the parasite in the respiratory tract, kidneys, esophagus, crop, proventriculus, bursa of Fabricius and cloaca.

Immunity

There is an age-related non-specific immunity (young birds are more susceptible) as well as a specific immunity. Co-infection of chickens with the infectious bursal disease virus or a live Marek's disease vaccine can delay the development of such immunity. Immunity can be completely inhibited in chickens previously infected with a wild strain of the virus of Marek's disease: chickens then shed chronically the parasite. Procedures such as bursectomy and thymectomy or the use of inhibitors of cell-mediated immunity (inoculation of cyclosporine A) suggest that serum antibodies play a minor or negligible role in the resistance against avian cryptosporidiosis caused by *C. baileyi*, by contrast to cell-mediated immunity. However, immunization of breeder hens at the onset of egg-laying provides partial protection against a parasitic infection in chicks, resulting in a 54% reduction in parasite excretion.

Although *C. baileyi* causes lesions as it develops in the bursa of Fabricius, the parasitic infection does not interfere with the development of vaccinal immunity against Marek's disease. Similarly, *C. baileyi* infection does not appear to affect the antibody response directed against the infectious bursal disease virus.

EPIDEMIOLOGY

Cryptosporidium infection is reported worldwide in several avian species. Chickens are most often contaminated by inhalation or ingestion of oocysts present in their environment. This contamination induces invasion of the cloaca, the bursa and/or respiratory tract by the parasite. This indirect contamination is made possible by the high resistance of oocysts in the environment (oocysts are also remarkably resistant to the majority of common disinfectants). In addition, a small number of oocysts (100 oocysts) is sufficient to cause intestinal or respiratory infection. The infection spreads rapidly within flocks, especially floor-reared flocks. Infection occurs through direct

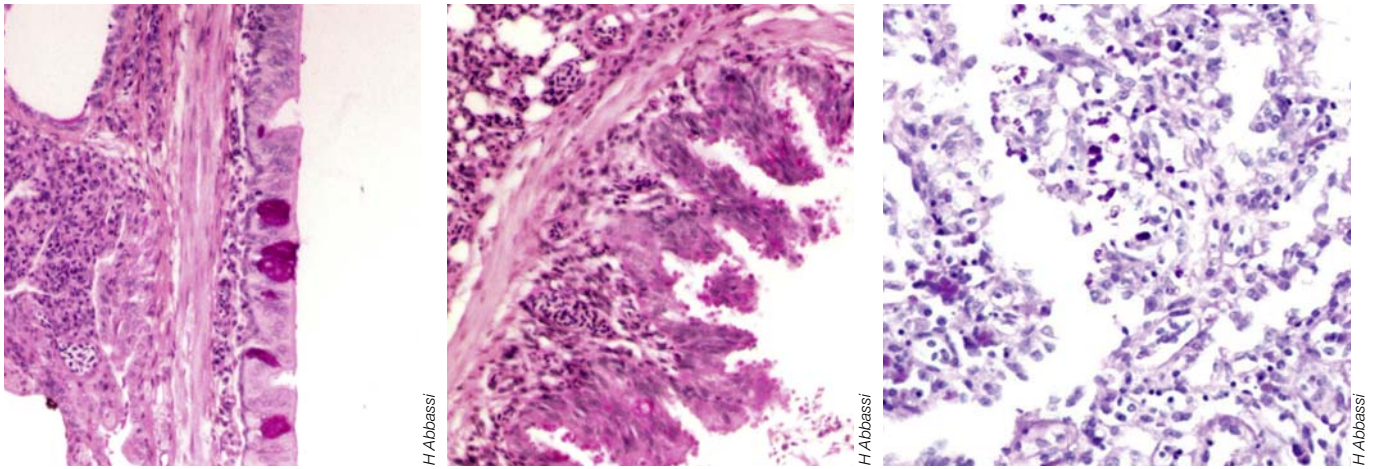


Fig.65.9, 65.10 & 65.11: Histological lesions in the lungs of chickens infected with *C. baileyi* oocysts. Compared with a control (left), note the bronchial epithelial hyperplasia and infiltration of the connective tissue by inflammatory cells (middle). Note also the moderate inflammation in parabronchi that is associated with the presence of the parasite (right).

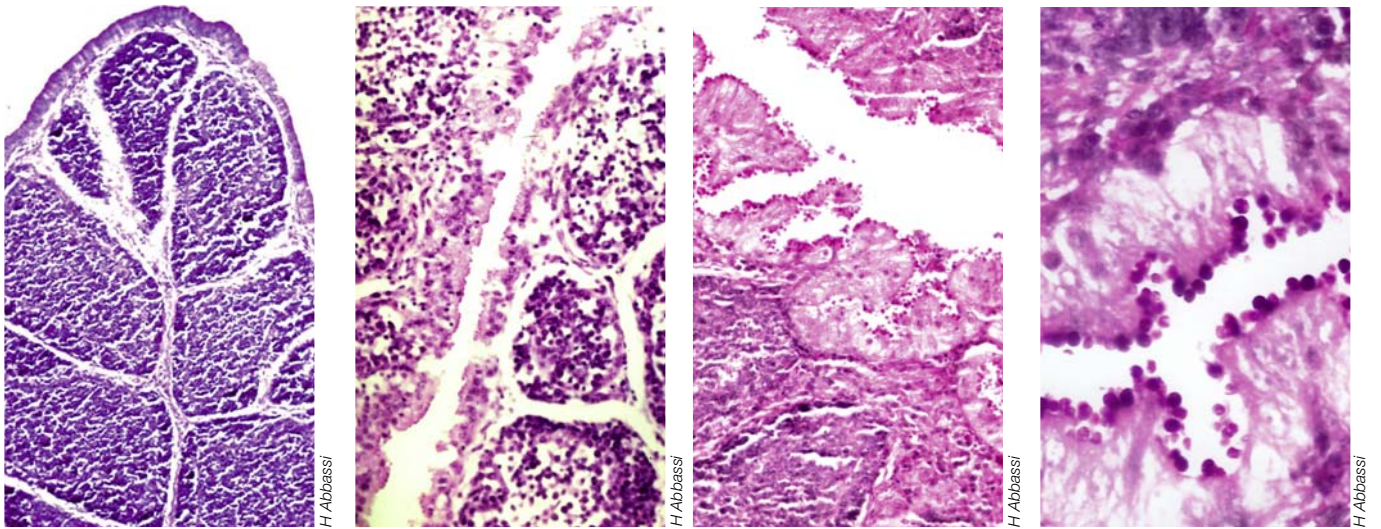


Fig.65.12, 65.13, 65.14 & 65.15: Histological lesions of the bursa of Fabricius of chickens infected with *C. baileyi* oocysts. Compared with a healthy control (left), note the epithelial hypertrophy and the underlying inflammatory response. With higher magnification, *Cryptosporidia* are more visible (right).

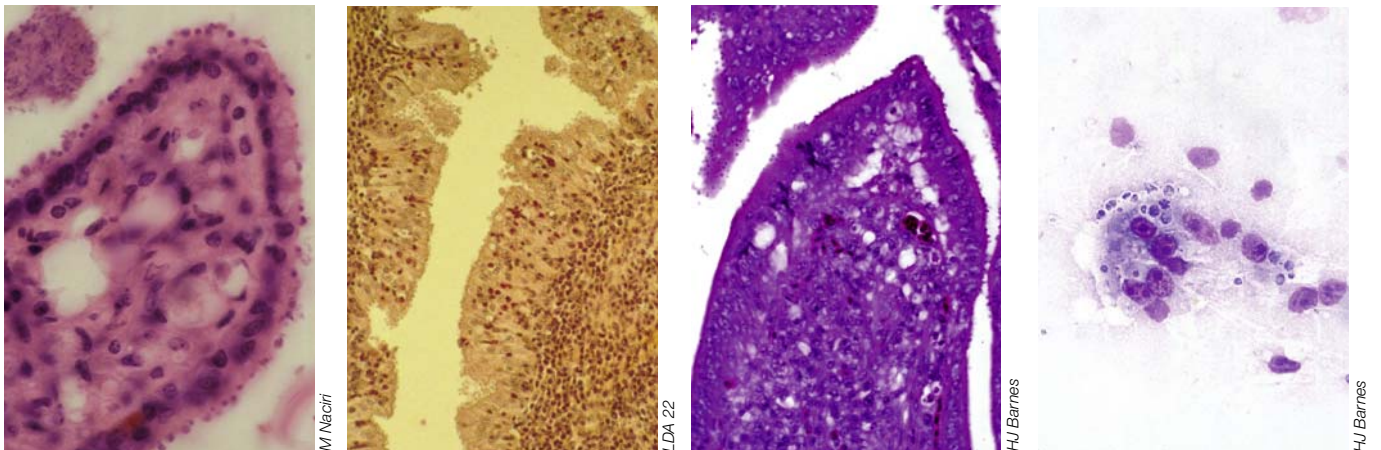


Fig.65.16 & 65.17: Intestinal cryptosporidiosis (Chicken). On left, ileum of chicken experimentally infected with *C. Baileyi*. On right, natural infection. Note the different stages of development of *Cryptosporidium* on the surface of the intestinal epithelium.

Fig.65.18 & 65.19: Intestinal cryptosporidiosis (turkey jejunum). Presence of *C. meleagridis* on the surface of the intestinal epithelium (left). These *Cryptosporidia* can be observed on a mucosal scraping (dipping microscope).

contact between healthy chickens and infected chickens excreting oocysts in their droppings and respiratory secretions.

Since *C. baileyi* can infect a wide variety of avian species, wild birds can act as biological vectors. Rodents (mice, rats), susceptible to infection by *C. meleagridis*, could serve as biological and/or mechanical vectors. Like coccidia of the genus *Eimeria*, coleoptera and insects can also serve as mechanical vectors.

CLINICAL SIGNS & LESIONS

Under field conditions, cryptosporidiosis occurs in poultry usually in the respiratory or intestinal form and more rarely the renal form. *Cryptosporidium baileyi* mainly induces respiratory signs while *C. meleagridis* is associated with enteric signs.

Respiratory form

The respiratory form is described in chickens, turkeys, quails, ducks, pheasants and budgerigars. It is characterized by sinusitis upon infection of the upper respiratory tract (similar lesions as for swollen head syndrome) or rales, sneezing, cough and dyspnea when the lower respiratory tract is affected.

On *post-mortem* examination, bronchopneumonia and sometimes airsacculitis with the presence of exudate and excess mucus in the trachea, nasal and sinus cavities are observed. Histologically, the respiratory epithelium shows typical lesions with inflammatory infiltrates. The cilia may be diminished or absent.

The severity of respiratory disease and histological lesions caused by *C. baileyi* inoculated by the intratracheal route may increase in the presence of *Escherichia coli* or infectious bronchitis virus inoculated by the same route. In specific pathogen-free (SPF) chickens coinfecting with *C. baileyi* (oral inoculation) and a strain of Marek's disease virus, a massive and sustained colonization of unusual sites, in particular in the respiratory system, is observed. In addition to respiratory signs, birds experience a loss in body condition, growth retardation, an elevated premature mortality, and they may shed the parasite for longer periods of time, even permanently.

Gastrointestinal form

In birds, *Cryptosporidium* spp. can invade the salivary glands and esophagus, proventriculus, small intestine, ceca, colon, cloaca and bursa of Fabricius. The pathogenicity of the genus *Cryptosporidium* in birds has been described for the first time in turkeys with severe diarrhea due to *C. meleagridis*. Since then, the clinical disease has also been reported in chickens, quails, pigeons, finches and other cage birds.

The clinical signs are characterized by a watery diarrhea, lethargy, growth retardation and a low pigmentation score. At necropsy, a distension of the intestinal wall with mucus and gaseous content is observed. Microscopic lesions generally consist of a detachment of enterocytes, atrophy and fusion of villi, crypt hyperplasia and an infiltration of the lamina propria by macrophages, heterophils, lymphocytes and plasma cells. The bursa of Fabricius and the cloaca show hypertrophy and epithelial hyperplasia accompanied by an underlying inflammatory response and mild atrophy of the follicles of the bursa of Fabricius. Various parasitic stages can be observed lining the mucosal surface of the infected tissue or organ.

The oral inoculation of *C. baileyi* oocysts in chickens or turkeys does not usually cause clinical signs or gross lesions. Young birds may be weakened and a transient reduction in weight gain over a one to two week period post-inoculation may occur. The parasite causes microscopic lesions in the bursa of Fabricius and cloaca. Simultaneous inoculation of *C. baileyi* and *C. meleagridis* causes a reduction in weight gain and an increase in feed conversion ratio.

Renal form

The clinical signs of the renal form of the disease, observed in egg-layers and cage birds, are not well known because they are usually masked by other signs caused by concurrent diseases. Macroscopically, the kidneys are enlarged and pale, sometimes with white foci in the parenchyma and urate crystals on the surface of the tubules. Microscopically, the ductal epithelial cells, collecting tubules and sometimes distal convoluted tubules are enlarged and hyperplastic and contain *Cryptosporidia*. Infiltrates of lymphocytes and

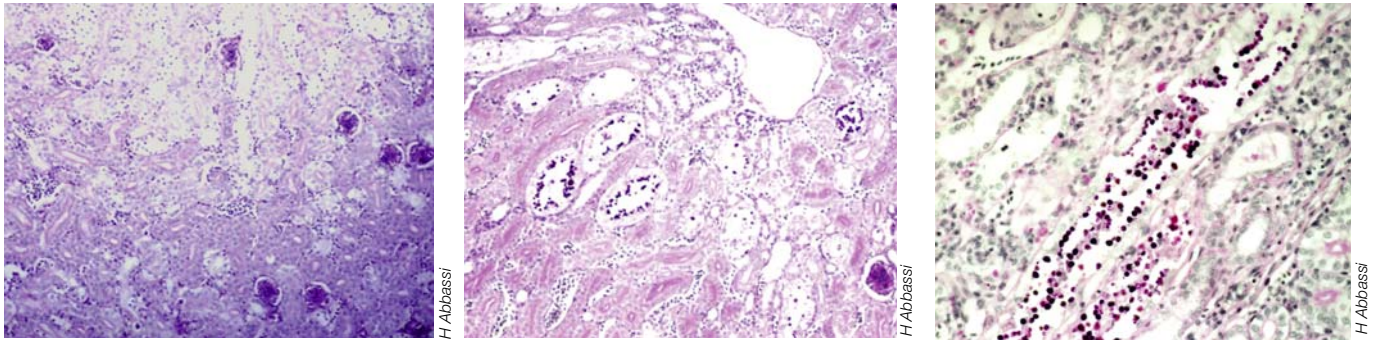


Fig.65.20, 65.21 & 65.22: Renal cryptosporidiosis (Chicken). The inoculation of *C. baileyi* oocysts via the oral route in young chickens previously infected with a strain of Marek's disease virus resulted in this form of the disease. This was confirmed by renal tissue scrapings examined under direct microscopy and on histological sections. Subacute interstitial nephritis and acute urethritis were observed histologically. Compared with a healthy control (left), note the presence of *Cryptosporidia* in collecting ducts and distal convoluted tubules (cross-section in the middle). *Cryptosporidia* are present along the collecting ducts (longitudinal section, right).

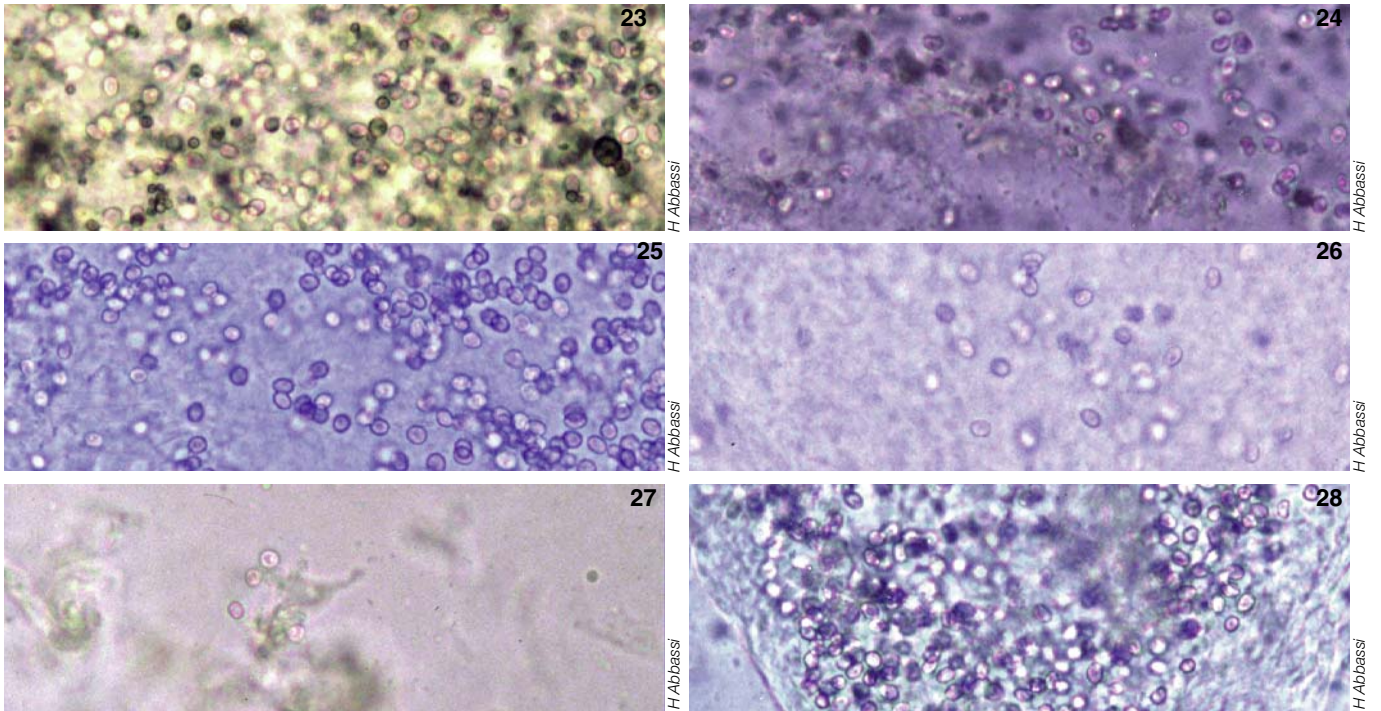


Fig.65.23 to 65.28: Demonstration of fresh *C. baileyi* oocysts by "Microscopic slide flotation", method using the modified Sheather solution, in droppings (Fig.65.23), larynx (Fig.65.24), trachea (Fig.65.25), lung (Fig.65.26), air sac (Fig.65.27) and the bursa (Fig.65.28), respectively from left to right and top to bottom. *C. baileyi* oocysts appear as oval particles surrounded by a thick wall and having a pinkish tinge.

macrophages are present in the interstitial tissue surrounding the collecting ducts. The more intense infection of the distal part of the renal tract suggests an ascending infection coming from the cloaca, and is likely to be due to a decrease in local immunity.

DIAGNOSIS

Although cryptosporidiosis is accompanied by clinical signs, they are not sufficiently specific for a differential diagnosis with other respiratory or gastrointestinal diseases. That is why the diagnosis of avian cryptosporidiosis is based on several methods.

Detection and identification of endogenous stages

Histological sections stained with hematoxylin and eosin allow seeing the different stages of development of the parasite in the form of dark and basophilic spherical bodies of variable size (2-6 μm). Endogenous stages can also be identified from mucosal scrapings.

Direct detection of oocysts in the droppings or respiratory exudates or harvested organs

The identification techniques of *Cryptosporidium* oocysts include concentration procedures coupled

with standard light microscopy or phase contrast examination, after acid-fast staining, negative staining or staining with auramine-O for examination by fluorescence microscopy. These techniques allow distinguishing *Cryptosporidium* oocysts from yeast cells that are often present in samples.

Concentration techniques most commonly used are based on procedures using flotation of oocysts in dense solutions like Sheather, zinc sulfate or saturated sodium chloride solutions. Swabbing of the trachea or cloaca is a very effective method for obtaining samples from live birds.

A semi-quantitative microscopic slide flotation method (MSF) was developed in 2000 to detect *C. baileyi* in the droppings and organs of chickens. This simple and quick technique consists of putting two drops of a modified Sheather solution on a microscope slide. A sample of droppings or of the scraping of the mucosa of the affected organ is then added and mixed with the solution. A cover slip is put on the mixture and the slide is left standing for one to two minutes before examination with a light microscope.

Because of the small size of these parasites, transmission electron microscopy is also useful to reveal developmental stages and oocysts within the host cells.

Detection of *Cryptosporidium* antigen

More sensitive techniques of direct or indirect immunofluorescence can detect oocysts when they are in low numbers in samples. Similarly, the detection threshold is lowered considerably by using molecular biology techniques including gene amplification by the use of PCR (Polymerase Chain Reaction).

Serological diagnosis

Previous exposure to *Cryptosporidium* spp can be demonstrated by testing for serum antibodies specific to this parasite by indirect immunofluorescence or ELISA. These antibodies may also be detected in faeces, bile, tears and saliva. However, the results of serological studies should be taken with caution, especially if other means of diagnosis are not associated because of cross-reactions between *C. baileyi* and *C. parvum* and also between *Cryptosporidium* and other protozoa such as gregarines. Furthermore, we have demonstrated experimentally the possibility of a parasitic development without detecting humoral response due to a infectious bursal virus infection.

TREATMENT & CONTROL

At present, there is no effective product for the prevention or treatment of avian cryptosporidiosis. Only biosecurity measures may be recommended, the only effective disinfectants being ammonia (50%) and especially sodium hypochlorite (50%). *Cryptosporidium* oocysts being sensitive to drying and moist heat, steam cleaners are an effective way to disinfect contaminated cages (oocysts are destroyed at temperatures >35°C).

REFERENCES

- Abbassi H et al. Renal Cryptosporidiosis (*Cryptosporidium baileyi*) in specific pathogen-free chickens experimentally coinfecting with Marek's disease virus, *Avian Dis*, 1999,43:738-744.
- Abbassi H et al. Interaction of Marek's Disease virus and *Cryptosporidium baileyi* in experimentally infected chickens, *Avian Dis*, 2000,44:776-789.
- Abbassi H et al. Effect of *Cryptosporidium baileyi* in specific pathogen free chickens vaccinated (CVI988 /Rispen) and challenged with HPRS-16 strain of Marek's disease virus. *Avian Pathol*, 2000,29:625-636.
- Abbassi H et al. Rapid detection and quantification of *Cryptosporidium baileyi* oocysts in feces and organs of chickens using a microscopic slide flotation method, *Parasitol Res*, 2000, 86:179-187.
- Current WL. Techniques and laboratory maintenance of *Cryptosporidium*. In «*Cryptosporidiosis in man and animals*». CRC Press, 1990, pp 31-49.
- De Graaf DC et al. A review of the importance of cryptosporidiosis in farm animals, *Int J Parasitol*, 1999,29:1269-1287.
- Fayer R et al. Avian cryptosporidiosis. «*Cryptosporidiosis in man and animals*». CRC Press, FL 1997, pp1-33.
- Lindsay DS & Blagburn BL. Cryptosporidiosis in birds. In «*Cryptosporidiosis in man and animals*». CRC Press, FL, 1990, p 133-148.
- McDougald LR. Cryptosporidiosis. In «*Diseases of Poultry*» Ed. DE Swayne, Wiley-Blackwell ed, Ames 2003, p 1167-1171.
- O'Donoghue PJ. Cryptosporidium and cryptosporidiosis in man and animals. *J Parasitol*, 1995,25:139-195.
- Ryan U. Cryptosporidium in birds, fish and amphibians. *Exp Parasitol*, 2010,124:113-120.
- Sréter T & Varga I. Cryptosporidiosis in birds- A review. *Vet Parasitol*, 2000, 87: 261-279.
- Xiao L et al. Cryptosporidium taxonomy: Recent Advances and Implications for Public Health, *Clin Microbiol Rev*, 2004,17:72-97.

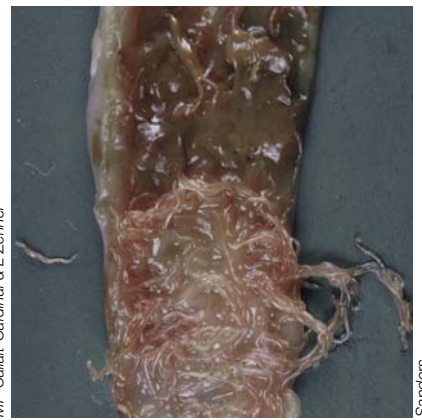
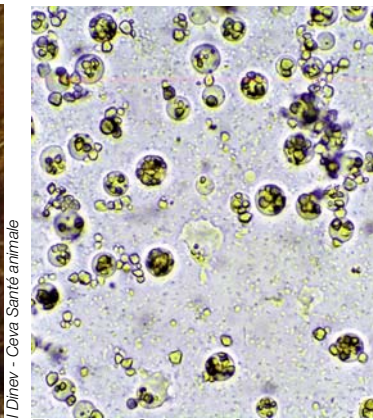


Fig.66.1: Histomoniasis. A possible feature is the blackening of the skin of the head (blackhead), due to cyanosis.

Fig.66.2: Culture of *Histomonas meleagridis* showing the amoeboid and flagellated forms.

Fig.66.3 : The main vector is *Heterakis gallinarum* through its eggs, where *H. meleagridis* can be found in the larvae.

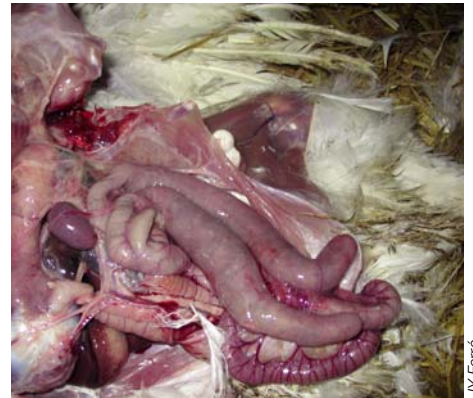
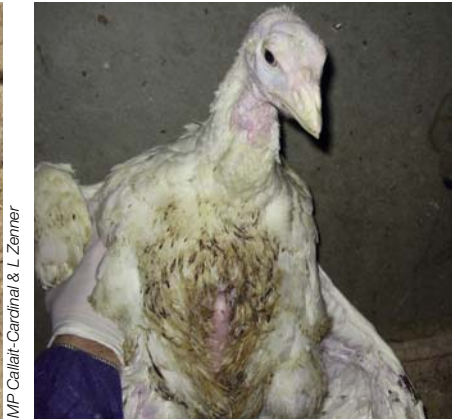
Fig.66.4: Bright sulfur-yellow diarrhea often constitutes the first sign of histomoniasis.

Fig.66.5: Infection with *H. meleagridis* is associated with wasting and stunting (Turkey).

Fig.66.6: Initial lesions in ceca. Bilateral enlargement of ceca with thickening of walls (Turkey).

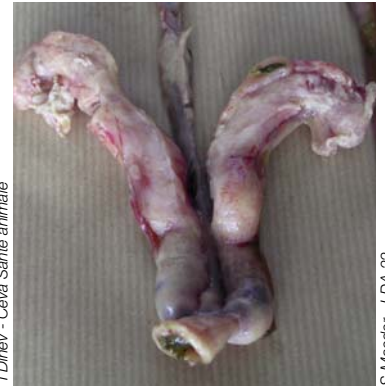
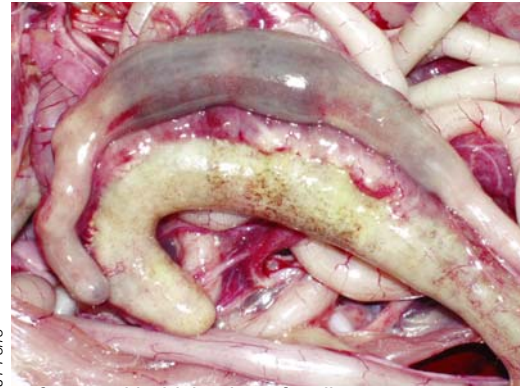
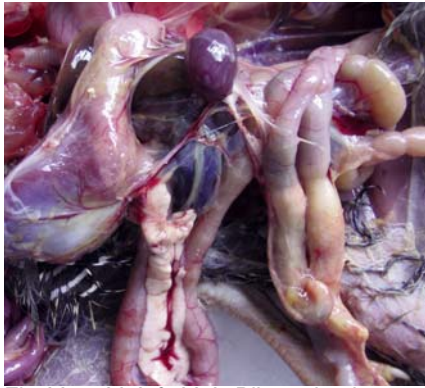Fig.66.7, 66.8 & 66.9: Bilateral enlargement of ceca with thickening of walls.

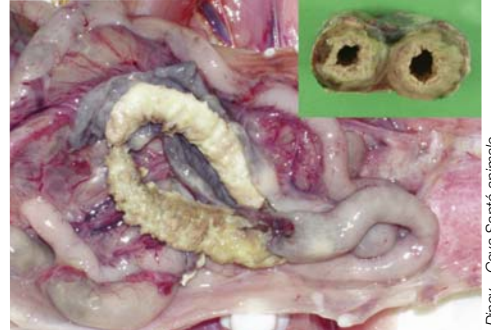
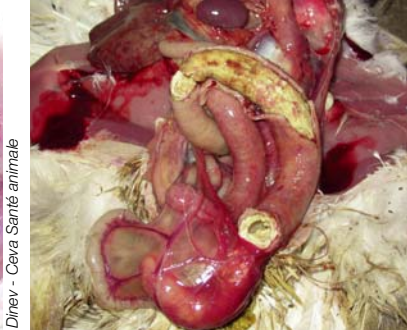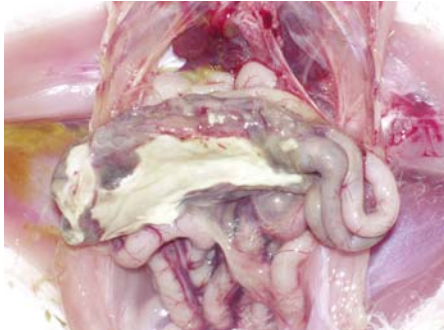


Fig.66.10: Typhlitis may lead to peritonitis.

Fig.66.11 & 66.12: In chronic cases, a dense caseous core is found in the ceca, contributing to the thickening of the intestinal wall (top right of fig 68.12: a cross section of the ceca).

Other diseases

66. HISTOMONIASIS

INTRODUCTION

Histomoniasis, also known as histomonosis, is a parasitic and infectious typhlohepatitis affecting mostly turkeys. The acute form of the disease is associated with a bright sulfur-yellow diarrhea and is often fatal. Sometimes, there is cyanosis of the head, hence the name «Blackhead disease». It is characterized by caseonecrotic lesions in the ceca and liver.

ETIOLOGY & EPIDEMIOLOGY

The pathogen is a flagellated protozoan, *Histomonas meleagridis*, which exists in two forms in the definitive host: an amoeboid form lacking a flagellum when found in tissues; a flagellated form when the pathogen is in the lumen of the ceca. The amoeboid form is roundish or oval with a diameter between 6 and 16 microns, and with short blunted pseudopodia. The nucleus is usually the only internal structure that can be observed without staining. The flagellated form is similar to the amoeboid form but it has a flagellum and digestive vacuoles.

Its life cycle is linked to a nematode, *Heterakis gallinarum*, also a parasite of poultry ceca. The transmission of *H. meleagridis* between hosts occurs through the nematode's eggs that are very resistant in the environment. Ingested eggs, containing *H. meleagridis* trophozoites, release the protozoan in the cecal cavity where it multiplies by binary fission. Histomonads replicate in the cecal tissues, causing a severe necrosis. The parasite then moves to the liver through the bloodstream. In the ceca, it coexists with *Heterakis* adults in which they may enter through the mouth, reaching their eggs in females where it is later found in the infective larvae. Eggs of *Heterakis* not only ensure a long survival in the environment for *H. meleagridis*, but it also protects the parasite from the bird's upper digestive tract. Embryonated eggs of *Heterakis* can be ingested by earthworms (paratenic hosts) which store and carry the *Heterakis* eggs containing histomonads. The possibility of transmission by more direct routes, either orally or through cloacal-drinking (reflexive intake of fluids through the cloaca), is currently suspected as mechanisms to quickly transfer protozoans between birds during an outbreak.

Histomoniasis is a disease that affects numerous Galliformes, but can also affect Anseriformes. The species most frequently involved is the turkey, but the disease can also affect chickens, guinea fowls, pheasants, partridges, quails and peacocks. Variations in sensitivity according to the strain of *H. meleagridis* have been reported in turkeys.

CLINICAL SIGNS & LESIONS

The incubation period, corresponding to the phase of parasite multiplication, is 7 to 10 days.

An early clinical feature is the onset of bright sulfur-yellow diarrhea, resulting from inflammation of the ceca. Other clinical signs are feces stained feathers, anorexia, somnolence, abnormal gait and head carried low. From the 12th day, turkeys are very emaciated. The bird's head may appear to be reddish to blackish.

The evolution of the disease can be fatal with significant mortality occurring around the 14th day post-infestation, and sometimes as early as on the 11th or 12th day. The peak of mortality occurs normally around the 17th day and may persist until the end of the fourth week post-infestation. It may be aggravated due to secondary diseases, especially respiratory conditions. Survivors present growth retardation.

The lesions occur early, preceding the onset of clinical signs. They are observed mainly in the ceca and liver.

Only one or both ceca may be affected. The entire cecum or only the blind ended portion may be involved. After tissue invasion by parasites, cecal walls are thickened and congested. An abundant exudate secreted by the mucosa, from which *Histomonas* can be isolated, can distend the organ. Ceca are enlarged, irregular and firm on palpation. At the opening of the ceca, ulcerative and caseonecrotic lesions and a grayish-yellow cheesy core are observed. This firm core comes from the dehydration of the exudate, in which the flagellates are difficult to identify. The ulcerative process may erode the cecal wall, which then causes generalized peritonitis. When the disease is chronic, it is possible to observe adhesions between the cecum and adjacent bowel loops or even the abdominal wall.

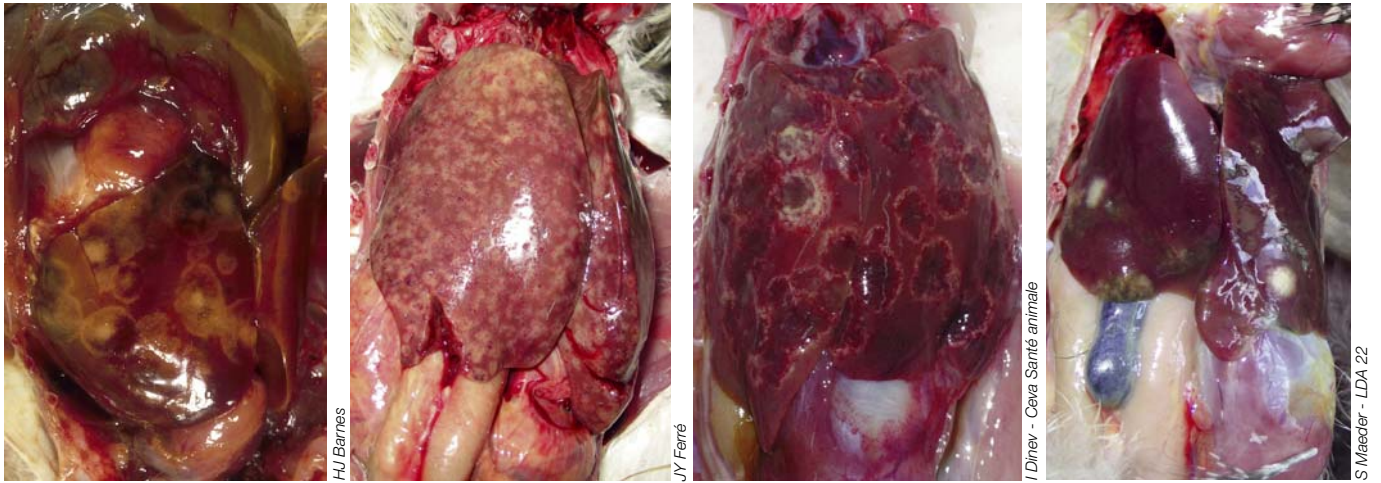


Fig.66.13, 66.14, 66.15 & 66.16: In the liver, necrotic zones of various size and color. Well delineated necrotic target-like lesions with raised edges and a depressed center are yellowish to greyish/reddish (hemorrhages). They vary in size (often 1-2 cm in diameter, but they may coalesce, creating larger lesions).



Fig.66.17: Histomoniasis. Section of the liver.

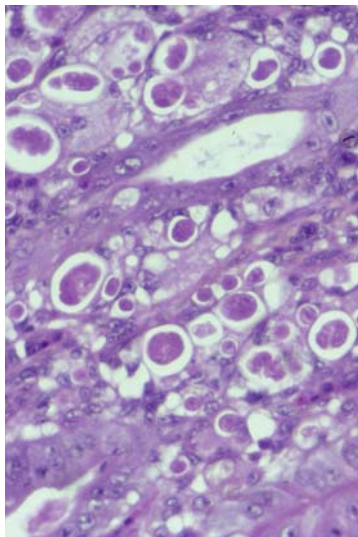


Fig.66.18 & 66.19: A section of an infected cecum (left) shows the small rounded forms of the parasite. *Histomonas* may be difficult to identify histologically in liver lesions (right) except during the acute stage of the disease.

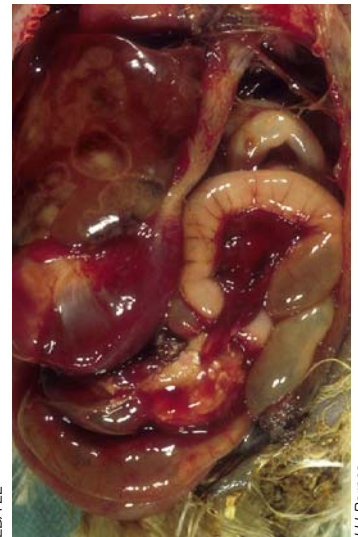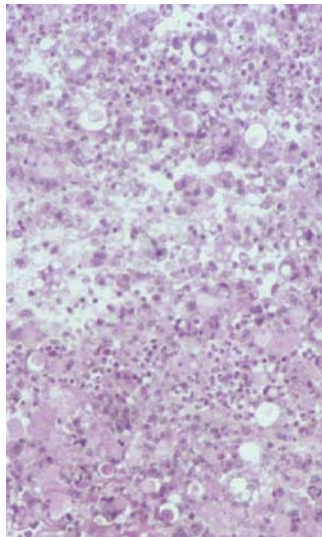


Fig.66.20: Diagnosis is made on the basis of the typical macroscopic lesions.

Section IV

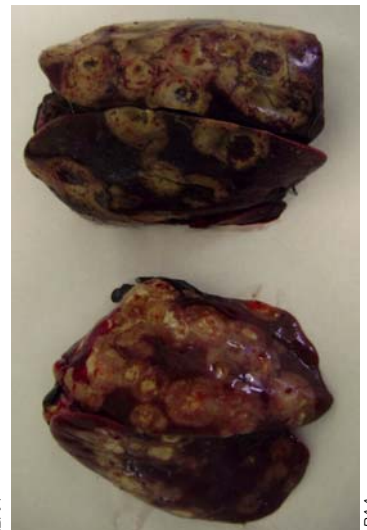
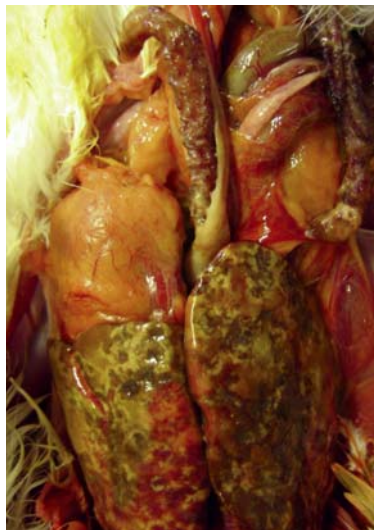

Fig.66.21, 66.22 & 66.23: Histomoniasis occurs occasionally in chickens with the same lesions as in turkeys, guinea-fowls, etc.

Liver lesions generally appear in turkeys around the 9th or 10th day post-infestation, but they may also be absent. They are variable in severity and they may be associated with the intensity of the clinical expression and the age of the turkey. Typically, there are necrotic target-like lesions with raised edges and a depressed center. Their number is variable and they range in size from a few millimeters to several centimeters in diameter, which gives the liver a very characteristic mottled appearance. One can also observe hypertrophy and discoloration of the liver.

Other organs such as kidneys, lungs and spleen, have sometimes rounded foci of necrosis, hemorrhages or nodules, but without the presence of the parasites.

DIAGNOSIS

Clinical diagnosis is based on epidemiological evidence (young birds, outbreak presentation, *etc.*) and clinical signs. Necropsy findings showing unilateral or bilateral cecal lesions associated with liver damage are pathognomonic.

The differential diagnosis must consider all diseases that cause typhlitis and hepatitis: coccidiosis, avian tuberculosis, salmonellosis, pasteurellosis, necrotic enteritis, Marek's disease, cecal trichomoniasis, *etc.*

The diagnosis can be confirmed by observation of the parasite by direct microscopic examination. This can be done on a sample of fresh feces or by quickly scraping the cecal content immediately after death. Examination of liver tissues is more difficult. A histological preparation of hepatic tissue from the periphery of the lesions may permit observation of the parasites. The *in vitro* culture of the parasite is possible but involves highly complex procedures. Finally, it is possible to use PCR on fecal or tissue samples as well as ELISA.

TREATMENT & CONTROL

Several molecules are effective against *Histomonas*: nitroimidazoles (dimetridazole,

ipronidazole, ronidazole, *etc.*) are more effective than nitrofurans (Nifursol). Dimetridazole has been used for prophylaxis as well as treatment at doses between 100 and 200 ppm. Nifursol has mainly been used as preventive measure when added to the feed at 50 to 75 ppm.

Currently, all these molecules are no longer permitted in many countries, including in Europe and North America. Anticoccidial drugs, including roxarsone, and antibiotics currently available on the market are not effective against histomoniasis. *In vitro* and *in vivo* essays with benzimidazole derivatives (albendazole and fenbendazole) also did not achieve acceptable results.

Prophylaxis is therefore based mainly on biosecurity measures. One of these measures is the separation of species, especially chickens and turkeys. Hence, a free-range location used for chickens should not be used for turkeys. It is also advisable not to mix poults and older turkeys. We can recommend deworming against *Heterakis*. One must also prevent contamination of feed and especially water by droppings to reduce transmission through the oral route. Proper litter management, keeping it dry, may also reduce the transmission of the parasite by cloacal drinking.

REFERENCES

- AbdulRahman L & Hafez HM. Susceptibility of different turkey lines to *Histomonas meleagridis* after experimental infection. *Parasitol Res.* 2009,105:113-116.
- Huber K et al. Detection of *Histomonas meleagridis* in turkeys cecal droppings by PCR amplification of the small subunit ribosomal DNA sequence. *Vet. Parasitol.* 2005,131:311-316.
- Liebhart D & Hess M. Oral infection of turkeys with *in vitro*-cultured *Histomonas meleagridis* results in high mortality. *Avian Pathol.* 2009,38:223-227.
- McDougald LR. Blackhead disease (histomoniasis) in poultry: a critical review. *Avian Dis.* 2005,49:462-476.

PRINCIPAL SYSTEM AFFECTED	PARASITES
Digestive	Protozoa : Coccidia, <i>Trichomonas</i> , <i>Histomonas</i> Nematodes : <i>Ascaris</i> spp., <i>Capillaria</i> spp., <i>Tetrameres</i> spp., <i>Dyspharynx</i> , <i>Gongylonema</i> , <i>Strongyloides</i> , <i>Subulura</i> , <i>Trichostrongylus</i> , <i>Hartertia</i> Trematodes Cestodes
Circulatory	Protozoa : <i>Leucocytozoon</i> , <i>Plasmodium</i> , <i>Haemoproteus</i> , <i>Trypanosoma</i>
Muscular	Protozoa : <i>Sarcocystis</i> , <i>Toxoplasma</i>
Respiratory	Protozoa : <i>Cryptosporidium</i> Nematode : <i>Syngamus</i>
Nervous	Protozoa : <i>Toxoplasma</i> Nematode : <i>Oxyspirura</i>

Tabl.67.1: Main parasites according to the affected systems and their clinical effects.

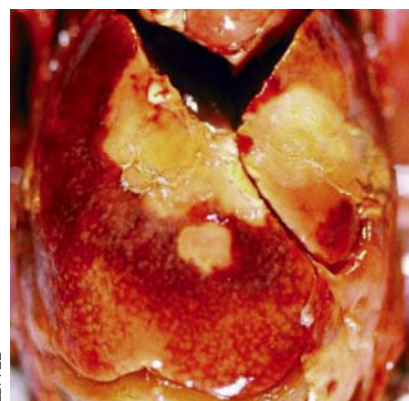
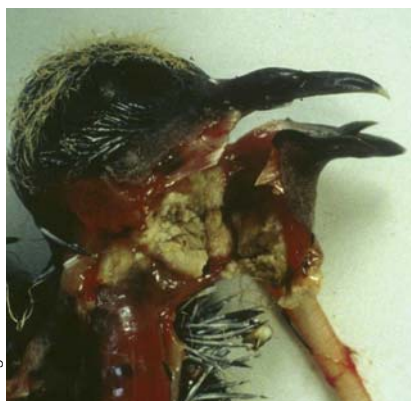
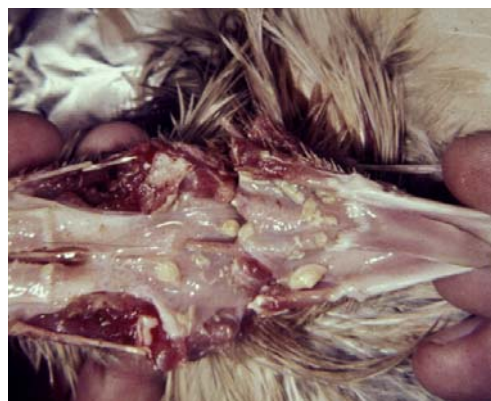
Fig.67.1 & Fig.67.2: Trichomoniasis. Caseous nodules in the oral cavity of a chicken (left) and a pigeon (right).

Fig.67.3: Trichomoniasis (Pigeon). Liver damage.

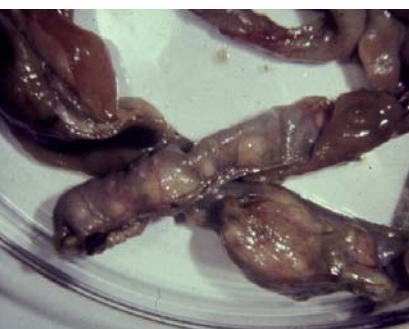
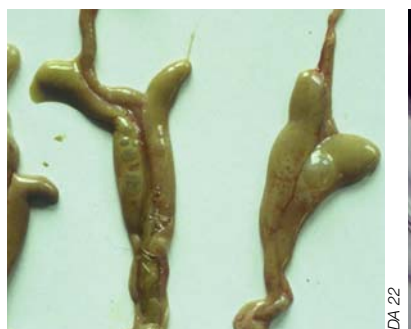
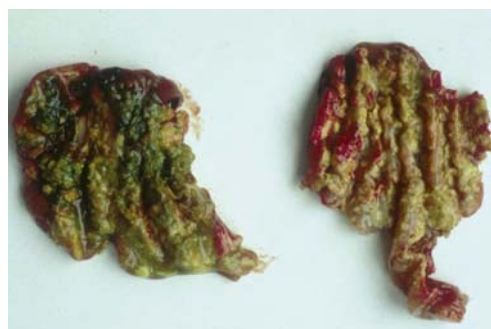Fig.67.4: Trichomoniasis (Pigeon). Necrosis of the crop.

Fig.67.5 & Fig.67.6: Intestinal trichomoniasis. Typhlitis in a guinea fowl (left) and caseous nodules in the intestine of a pigeon (right).

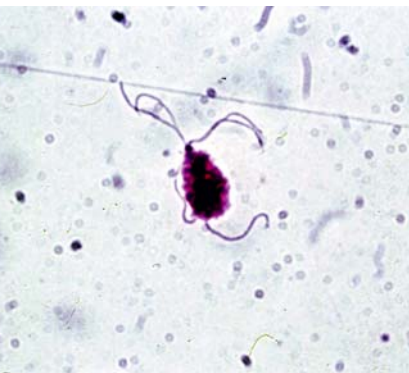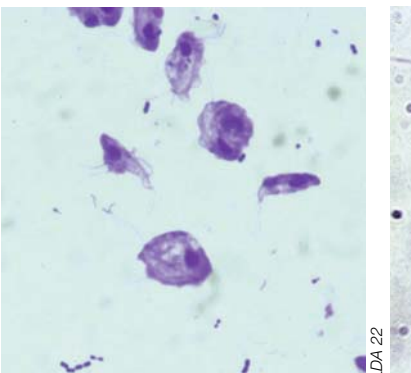
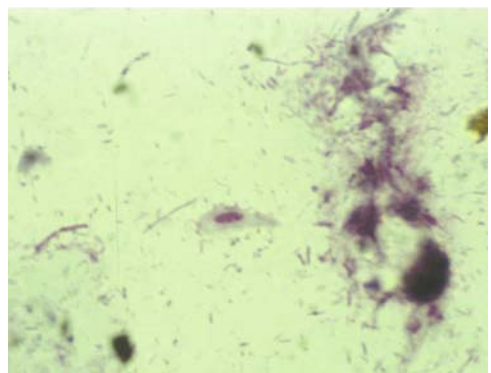


Fig.67.7: *Trichomonas gallinae* (Guinea fowl). Parasite colored with May Grunwald Giemsa.

Fig.67.8 & 67.9: *Tetratrichomonas gallinarum* revealed by direct microscopic examination from smears from a turkey poult (left) and a duck (right).

Other diseases

67. INTERNAL PARASITES

INTRODUCTION

Many species of endoparasites have been described in poultry and many of them have a significant impact on their health. Some of them, such as fungal diseases, coccidiosis, cryptosporidiosis and histomoniasis (blackhead) are the subject of specific chapters (see Chap.IV.62, IV.64, IV.65 & IV.66 respectively).

PROTOZOA

Coccidiosis (see Chap.IV.64)

Cryptosporidiosis (see Chap.IV.65)

Histomoniasis (see Chap.IV.66)

Other protozoan infections of the digestive tract

Trichomoniasis

Trichomonas gallinae primarily affects pigeons and occasionally turkeys, chickens or other birds, especially raptors feeding on pigeons, around the world. Pigeons are the primary carriers and transmission occurs through contact with infected oral secretions (or recently contaminated water for chickens and turkeys). Wet, crowded conditions will encourage transmission. Squabs usually become infected with their first taste of «pigeon milk» from the crops of adults and usually remain carriers throughout their lives. The flagellated protozoan invades the mucosal surface of the buccal cavity, pharynx, esophagus and crop, causing «oral canker» with yellow necrotic lesions and sometimes a profuse caseous exudate. Sometimes there is systematic spread of infection with involvement of the viscera, including the liver. Infected birds will become listless, cease to feed and lose weight, have ruffled feathers, and eventually die. Diagnosis of this flagellated infection is best made by direct microscopic observation of the living organisms in wet smears of the buccal cavity (from live birds or fresh carcasses because of the low resistance of the organism in the environment).

Other trichomonads are commensal of the avian gastrointestinal tract, like *Tetratrichomonas gallinarum* found in the ceca and the cloaca, and they can be misidentified as *T. gallinae* ou *Heterakis*. Outbreaks have been identified in young game birds and turkey poults, characterized by foamy yellow droppings as well as mortality.

Asymptomatic carriers and sick birds must be removed from the flock to control the disease. Drugs with activity against other related protozoa (*Histomonas*, *Entamoeba*, *Giardia*) are active against trichomoniasis, however none are approved for use in poultry.

Hexamitiasis (spironucleosis)

Hexamitiasis is caused by the protozoan *Spironucleus meleagridis*, commonly known by the generic name *Hexamita*. The disease is seen in poults and in young game birds, peafowls and ducks. Hexamitiasis is now rarely seen in commercial turkeys but remains common in young birds (game, backyard or ornamental) in flocks with poor sanitation. Pigeons can also be affected by *Spironucleus columbae*.

Poults infected with hexamitiasis have watery diarrhea that may progress to listlessness, convulsions, and coma. At necropsy, watery distension of the small intestine is observed with a large number of *Hexamita* present in the intestinal mucus and in intestinal crypts under direct microscopic examination. By histological examination *Hexamita* can be found intracellularly within the cells of the intestinal mucosal epithelium and *lamina propria*. Heavy infections of *Hexamita* in the small intestine of game birds result in a substantial reduction in absorption across the intestinal wall with subsequent diarrhea, listlessness, and weight loss.

Cochlosoma anatis

This protozoan found mainly in the ceca of the duck can also be pathogenic in poults, causing catarrhal enteritis.

Blood-borne protozoal parasites

Plasmodium (avian malaria)

This protozoan, transmitted by mosquitoes, is the parasite of erythrocytes and endothelial cells of many domestic and wild birds throughout the world. Several species have been described including *P. gallinaceum*, *P. juxtannucleare*, *P. durae*, *P. fallax* and *P. lophurae*, the first three being the most pathogenic. The consequences of infection vary, but can cause severe anemia. There is also

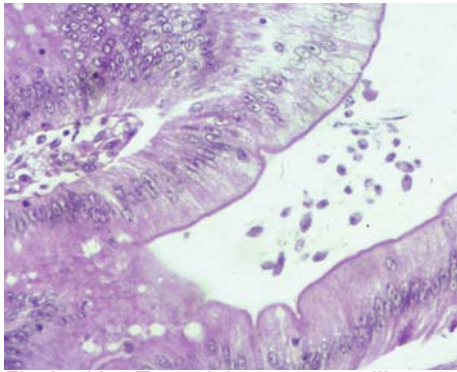


Fig.67.10: *Tetratrichomonas gallinarum* present in the intestinal lumen of a turkey poult.

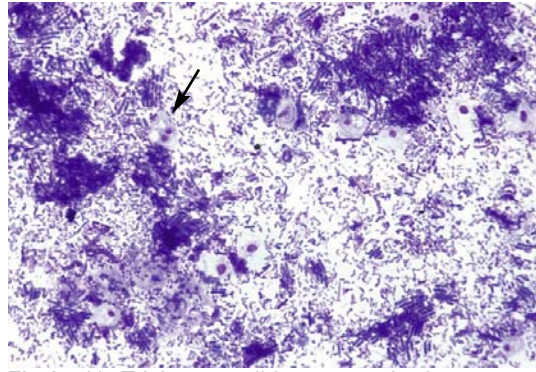


Fig.67.11: Trichomonadida present in the ceca of young poults aged 30 days and affected by poult enteritis mortality syndrome (PEMS). Note the protozoan division with two nuclei (arrow).



Fig.67.12: Hexamitiasis (Pigeon). Mucoïd enteritis.

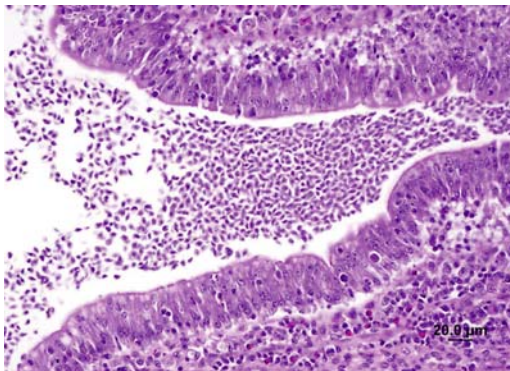


Fig.67.13: Numerous *Cochlosoma anatis* present in the intestinal lumen of a turkey poult.

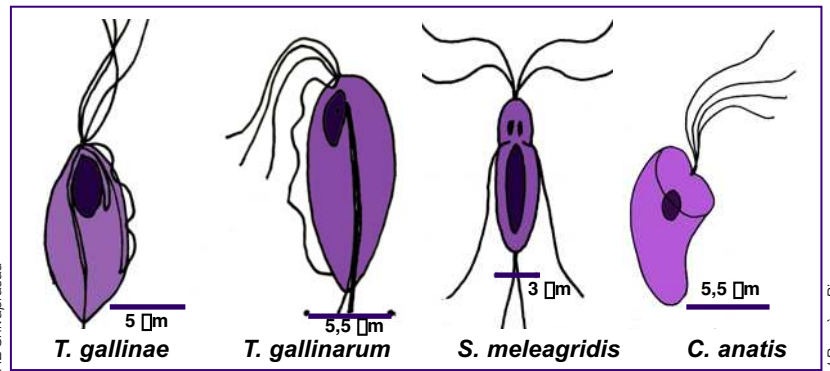


Fig.67.14: Morphological aspects and relative sizes of *Trichomonas gallinae*, *Tetratrichomonas gallinarum*, *Spiroucleus meleagridis* and *Cochlosoma anatis* (according to Barnes 2000, in Clark et al, 2003).

Section IV

Cestodes & trematodes	Main definitive host	Intermediate host	Length of the adult worm (mm)
<i>Amoebotaenia cuneata</i>	Chicken	Earthworm	3
<i>Choanotenia infundibulum</i>	Chicken	Houseflies, beetles	50-200
<i>Davainea proglottina</i>	Chicken	Snails, slugs	4
<i>Echinostoma revolutum</i>	Duck, chicken, turkey	Various species of aquatic snails	10-22
<i>Hymenolepis cantaniana</i>	Chicken	Beetles	20
<i>Hymenolepis carioca</i>	Chicken	Stable fly, dung beetles	40
<i>Prosthogonimus macrorchis</i>	Chicken, duck	Aquatic snails and dragonfly	5-7
<i>Raillietina cesticillus</i>	Chicken	Beetles	50-150
<i>Raillietina tetragona</i>	Chicken	Ants	100-250
<i>Raillietina echinobothrida</i>	Chicken	Ants	200-340

Tabl.67.2: Main cestodes and trematodes parasitizing poultry.

apathy, a distended abdomen, enlarged pale liver and pancreas, ocular hemorrhages and sometimes, nervous disorders. A blood smear stained with Giemsa allows the observation of parasites in erythrocytes and dark granules. This avian malaria is not a zoonosis.

Haemoproteus

Many species of this genus have been reported mainly in birds found in aquatic environments, but also in other birds. Chickens are not susceptible to this infection. Flies of the family *Hippoboscidae* and mosquitoes of the genus *Culicoides* act as vectors of some species. The erythrocytes and endothelial cells of the pulmonary blood vessels harbor forms responsible for sexual reproduction while those responsible for the asexual reproduction are rather located in the liver, spleen and kidneys.

Leucocytozoon

Several species of *Leucocytozoon* belong to this genus and invade the interior of the blood cells, hepatocytes and endothelial vascular cells of various organs. Even if *Leucocytozoon* is found throughout the world, most species have limited geographical distribution and target specific species of domestic and wild birds depending on the region. Transmission occurs by species belonging to the genus *Culicoides* and *Simulium*, these vectors acting as intermediate hosts. Infected cells burst, which induces hemorrhages, anemia and a more or less significant reduction in growth, but may result, in some cases, in high mortality rates. The diagnosis is made from a blood smear and at necropsy.

Trypanosoma

Several species infect wild and domestic birds, including *T. avium* and *T. gallinarum*. Their pathogenicity is minimal or nil.

Other protozoa

Toxoplasma

Chickens and turkeys, like other wild and domestic birds or mammals can be infected with *T. gondii*, especially in backyard farms potentially contaminated with cat feces (directly or via dung beetles and earthworms). Infection of adult birds go unnoticed

but young birds seem to be more affected to the point of presenting weakness, emaciation, diarrhea, ataxia progressing towards death. The importance of this infection is mainly due to the fact that it is a zoonotic disease that can be transmitted through undercooked meat or fecal contamination of feline origin.

Sarcocystosis

Sarcocystis can parasitize free range chickens (*S. horvathi*) and several other species of domestic and wild birds, especially ducks (*S. anatina* and *S. rileyi*). Long considered as non-pathogenic in birds as well as mammals, the pathogenicity of these parasites is now recognized in cases of a massive infestation with invasion of skeletal and cardiac muscle tissues. Other locations can be noted: esophagus, brain, lungs, and liver. The diagnosis is easy in the presence of numerous cysts visible at necropsy on the muscles and can be confirmed by histological examination (muscle, brain, esophagus, etc.). *Sarcocystosis* is a zoonosis, but it is mostly associated with the consumption of undercooked pork or beef.

CESTODES

These parasites are found, at the adult stage, within the intestine. Their length generally reaches a few centimeters (4 mm to 40 cm) and their flat and segmented form facilitates their identification as a group. Their development cycle necessarily involves an intermediate host, usually an insect, earthworm, a copepod or a snail, which explains the rarity of these parasites in closed flocks.

Several genera are well represented with *Davainea*, *Raillietina*, *Cotugnia*, *Amoebetaenia*, *Choanotaenia*, *Metroliasthes*, *Hymenolepis* and *Fimbriaria*. The infection of birds occurs through ingestion of an intermediate host carrying an infectious form of the parasite, which grows directly in the intestine and reaches maturity in about three weeks.

Most of these parasites are not very pathogenic unless parasitic loads are high. Weight loss with a decrease in feed intake and a decrease in egg production will be more pronounced in young birds. Two species stand out in this group. *Davainea proglottina* introduces its scolex deep into the duodenal villi, causing hemorrhage and necrosis that may progress towards death especially in young

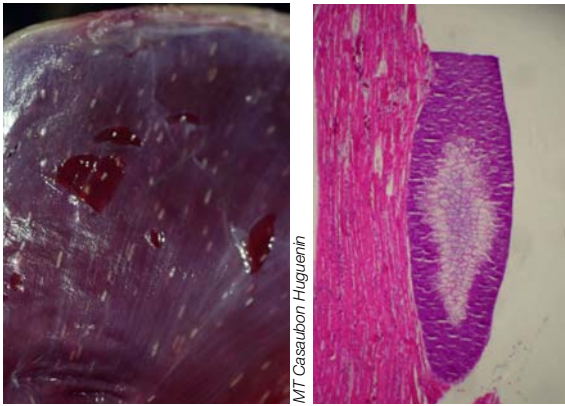


Fig.67.15 & 67.16: *Sarcocystis* spp. (Cockatoo). Characteristic appearance of intramuscular cysts.

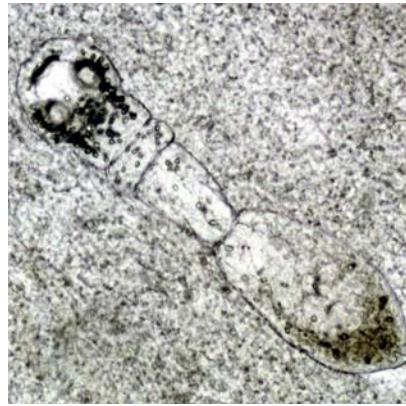

Fig.67.17 & 67.18: *Davainea proglottina* (Hen). Parasite observed in direct microscopy (left) and at necropsy (presence of small whitish spots on the intestinal mucosa (right)).

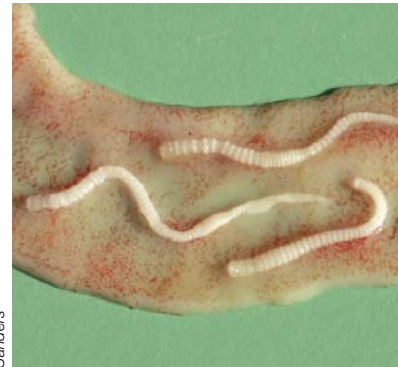
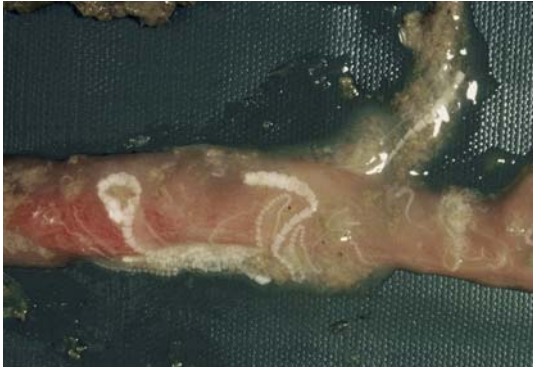
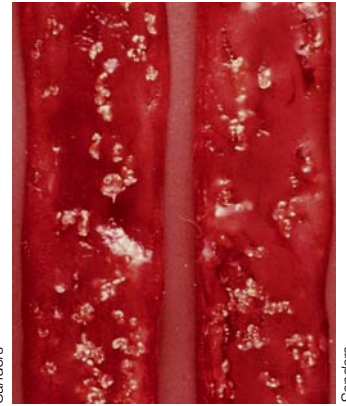Fig.67.19, 67.20 & 67.21: Intestinal taeniasis (Hen). This taeniasis may be more or less important. Most commonly encountered tapeworms are *Raillietina cesticillus* and *Choanotenia infundibulum*.

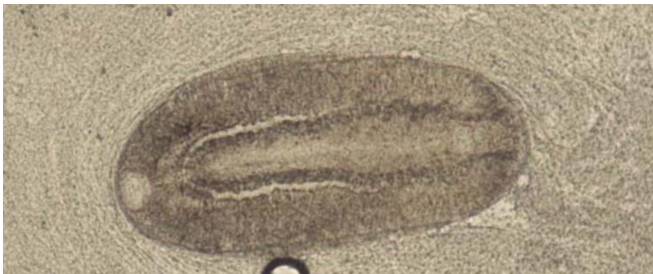


Fig.67.22: *Catatropis* spp. (Swan). Direct microscopic examination showing this elongated trematode (as wide in front as in the posterior end) parasitizing mainly anseriformes.




Fig.67.23: *Echinostoma* spp. (Swan). Direct microscopic examination showing the crown of thorns (arrow) around the anterior sucker of this trematode parasitizing mainly anseriformes.

Species	Predilection site	Intermediate host	Definitive hosts
<i>Eucoleus annulatus</i> (<i>Capillaria annulata</i>)	Esophagus, crop	Earthworm	Chicken, turkey, game birds
<i>Eucoleus contortus</i> (<i>Capillaria contorta</i>)	Esophagus, crop	None or earthworm	Duck, goose, chicken, turkey, game birds, other birds
<i>Aonchotheca</i> (<i>Capillaria</i>) <i>bursata</i>	Small intestine	Earthworm	Chicken, turkey, game birds
<i>Aonchotheca</i> (<i>Capillaria</i>) <i>caudinflata</i>	Small intestine	Earthworm	Chicken, turkey, goose, pigeon and wild birds
<i>Capillaria obsignata</i>	Small intestine	None	Chicken, turkey, goose, pigeon and wild birds
<i>Capillaria anatis</i>	Ceca	?	Especially in ducks and geese

Tabl.67.3: *Capillaria* species parasitizing poultry (Modified from AJ Trees, 2008).

birds. *Raillietina echinobothrida* attaches to the mucosa and induces the formation of multiple caseous nodules in the wall of the last portion of the small intestine. However, tapeworms most commonly encountered are *Raillietina cesticillus* and *Choanotenia infundibulum*.

TREMATODES

Several genera infect birds found in aquatic environments throughout the world, including *Echinostoma*, *Echinoparyphium*, *Hypoderaeum*, *Notocotylus*, *Catatropis* and *Postharmostomum*. These are generally small parasites often measuring less than one centimeter. They are inhabitants of the gastrointestinal tract, mainly ceca and cloaca, while *Prosthogonimus* parasitizes the genital tract, causing pelvic inflammatory disease and egg drop. Development primarily involves aquatic snails and infection occurs by ingestion of the intermediate host or aquatic plants on which the infectious form is encysted. The prepatent period is short, in the range of one to two weeks.

In large numbers and mainly in young birds, trematodes irritate the intestinal mucosa causing enteritis and weight loss. Secondary infections may increase mortality rates. Diagnosis is made by the detection of characteristic eggs in droppings or adults at necropsy.

NEMATODES

Nematodes of the upper digestive tract

Capillariidae

These worms have a filamentous form without any morphological feature, measuring a few mm to 80 mm in length. The eggs they produce have the characteristic shape of a lemon, colorless, a thick wall slightly striated and a cap at each end. Their dimensions vary slightly from one species to another and are between 40 and 60 µm long by 20 to 30 µm wide.

These parasites of the digestive tract are located in the esophagus and crop or in the small intestine or ceca depending on the species (see Tabl.67.3). Eggs expelled into the environment reach the infective stage within 3 to 4 weeks. These eggs persist for a long time in the environment and can infect birds directly or, for some species, use the earthworm as an intermediate host or other invertebrate species.

Most domestic and wild birds harbor one or more of these species. The most significant are *Aonchotheca (Capillaria) caudinflata*, *Capillaria obsignata*, *Eucoleus annulatus (Capillaria annulata)* and *E. contortus (Capillaria contorta)*. Their geographical distribution is generally worldwide.

The parasite, once ingested by the host, burrows or penetrates its anterior portion in the intestinal wall, causing small hemorrhages, catarrhal inflammation, thickening of the wall and even bloody diarrhea for species housed in the intestine. Clinical signs are observed during massive infestations, young birds being most sensitive: apathy, weight loss and, in laying hens, a drop in egg production. Death may occur.

The diagnosis is made by fecal flotation or at necropsy by the recognition of eggs or adult worms respectively.

Tetrameres

These nematodes are small, measuring less than 5 mm. A particular species, *Tetrameres americana*, has a marked sexual dimorphism, the male is thin and whitish, while the round female appears bright red. Parasites settle in the glands of the proventriculus. Specificity varies according to species, *T. americana* and *T. fissipina* infect the majority of domestic birds while *T. pattersoni* is found only in quails, but two species are also found only in chickens, *T. mohtedai* in India and *T. confusa* in Brazil. *Tetrameres crami* infects domestic and wild ducks. The geographical distribution also varies depending on the species, *T. americana* is limited to North America and Africa. Earthworms, grasshoppers and some aquatic crustaceans (*Daphnia*, *Hyaella*, *Gammarus*) play the role of intermediate hosts.

Females being hematophagous, erosions and anemia appear. The wall becomes thickened and swollen. The infection rarely proves fatal, mainly in chickens. The diagnosis is performed at necropsy, females appearing as dark red spots on the mucosa. Eggs have a thicker shell, measuring 42-50 x 24 µm, and contain an embryo formed upon the excretion with droppings.

Echinura uncinata

This parasite, found in the esophagus, the crop, gizzard and small intestine of domestic and wild Anseriformes may be pathogenic. It has *Daphnia* as intermediate host.

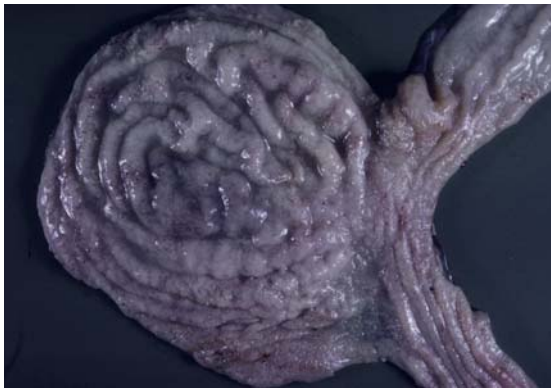

Fig.67.24: Capillariasis of the crop and esophagus (turkey). Inflammation of mucosa causes its thickening and can result in paralysis.

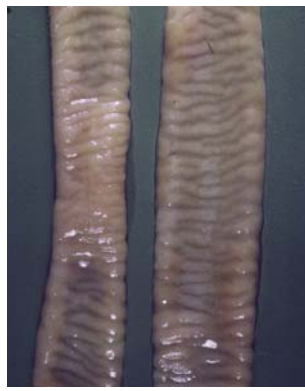

Fig.67.25: Intestinal capillariasis. Thickening and striated appearance of the intestinal mucosa.

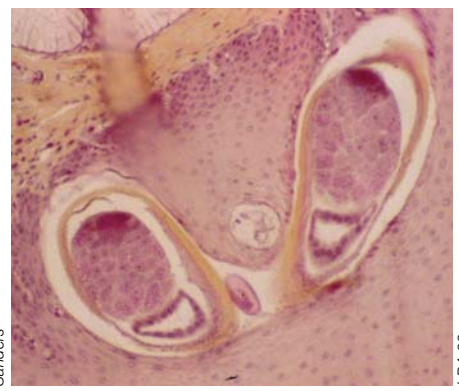


Fig.67.26: Capillariasis of the crop (Duck). Presence of the parasite in the epithelium.

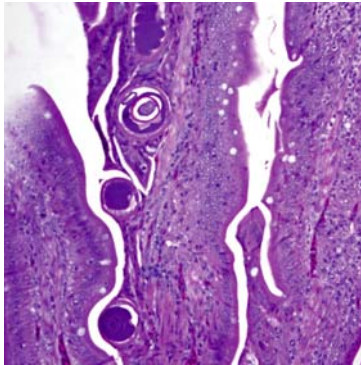


Fig.67.27: Intestinal capillariasis (Pigeon). Presence of the parasite in the intestinal epithelium.

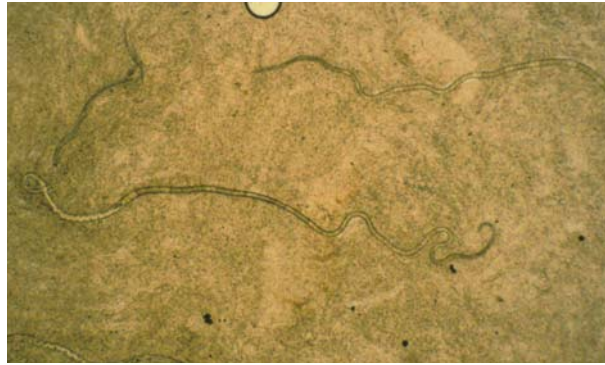
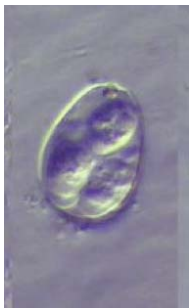
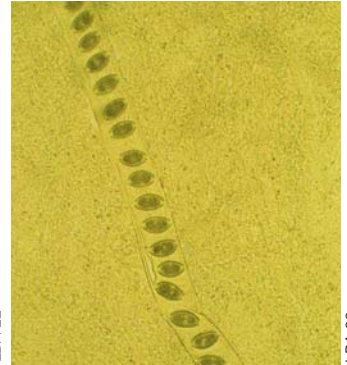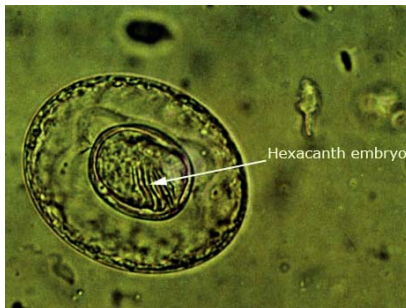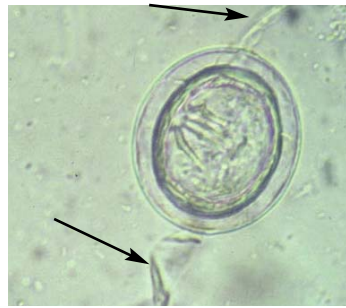Fig.67.28 & 67.29: Adult capillary (Hen) from direct examination (left). Note the high magnification (right) for the observation of eggs in the female worm.



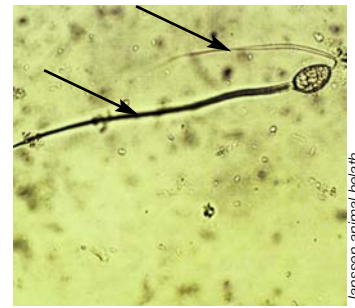
Eimeria maxima.
30 x 20 µm



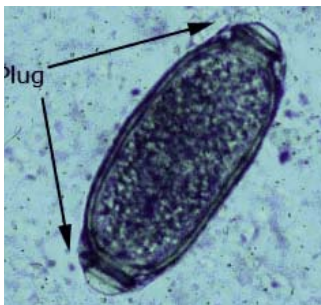
Raillietina spp.
25 x 50 µm
Contains hexacanth embryo



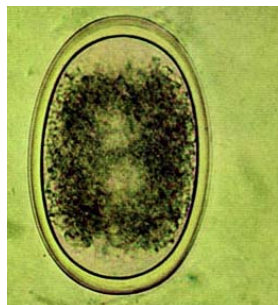
Choanotaenia infundibulum
47 x 54 µm
Characteristic elongated filaments (arrows)



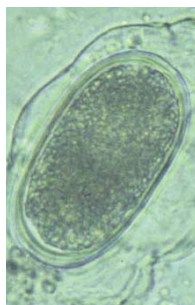
Notocotylus attenuatus
20 x 22 µm
Two long filaments (200µm) (arrows)



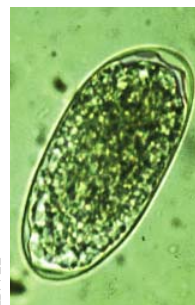Capillaria spp.
43/65 x 20/35 µm
Lemon aspect
Polar caps protruding



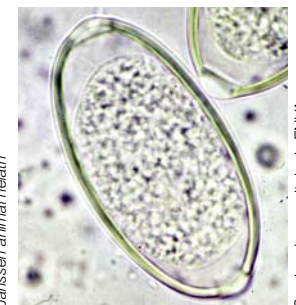
Ascaridia spp.
68/90 x 45/50 µm
Thick shell composed of three membranes



Heterakis spp.
59/75 x 31/48 µm
Smooth thick shell



Trichostrongylus tenuis
65/75 x 35-42 µm
Thin shell



Syngamus trachea
78/100 µm x 43/60 µm
Cap to each pole

Fig.67.30 to 67.38: Morphological aspects of eggs relevant to major internal parasites of poultry.

Gongylonema ingluvicola

This thin nematode 18-55 mm long can be confused with capillaries in the chicken, turkey, partridge, pheasant and quail but is less pathogenic. Beetles including *Copris minutus* play the intermediate host role. The parasite bogged down in spiral position in the mucosa or submucosa, making its ends protrude into the lumen of the organ. It is found everywhere except South America. In large numbers, the mucosa of crop becomes thick and cornified, facilitating regurgitation.

***Dispharynx nasuta* (syn *spiralis*)**

This spiral-shaped nematode measuring less than a centimeter in length is observed in many species of domestic birds in Asia, Africa and America. The intermediate host is a louse. Located mainly in the proventriculus, they cause an inflammatory reaction that may develop into ulcers and towards death.

Other upper gastrointestinal nematodes

- *Libyostrongylus stronglassii*, bloodsucking parasite of the proventriculus of the ostrich, causing diphtheroid proventriculitis;
- *Amidostomum anseris*, parasite of the gizzard in ducks, geese and pigeons;
- *Amidostomum skrjabini*, parasite of the gizzard in ducks and pigeons;
- *Cheilospirura hamulosa* and *Cheilospirura spinosa* are parasites found in the gizzard of different species.

Nematodes of the small intestine***Ascarididae***

These nematodes, a few centimeters long, are whitish in color with a posterior end tapering to a point. *Ascaridia galli* (female length: 12 cm) mainly affects domestic and wild galliformes while *Ascaridia dissimilis* (length: 7 mm) parasitizes especially turkeys. Their geographical distribution is worldwide.

The ideal conditions for the development and survival of the egg are wet and cold (development to infective stage in 2-3 weeks), instead of dryness and heat. After ingestion, the larvae burrow into the wall of the intestinal mucosa before returning to the intestinal lumen in order to become adults. The prepatent period lasts 4-8 weeks, and the normal life span should be about one year.

The eggs present a characteristic oval shape with smooth but thick walls and their size allows differentiating *Ascaridia* eggs (77-94 x 43-55 µm) from *Heterakis* eggs (66-79 x 41-48 µm). *Post-mortem* examination also helps in confirming the diagnosis.

Clinical signs are observed primarily during ascariasis in birds aged from one to two months. Differences in susceptibility have been observed depending on bird lineage. A heavy infestation can cause anemia, intermittent diarrhea, anorexia and weight loss. One can also note a decrease in egg production and a change in behavior. Sometimes it is possible to find ascaris in an egg. Feed deficiencies and tissue damage predispose the bird to secondary infections. A large number of worms can cause intestinal obstruction and death.

The control of the disease is based on biosecurity measures including proper litter management and rotation of pasture areas (for birds reared outside) considering that the parasite's eggs may survive up to one year.

Other roundworms can be observed such as *Porrocaecum crassum* and *Contracaecum spiculigerum* present in the small intestine of ducks and other aquatic anseriformes. These two species are not considered pathogenic.

Other nematodes present in the small intestine***Hartertia gallinarum***

This *spirocercidae* looks like *Ascaridia galli* and measures 40 to 100 mm in length. It is sometimes found in the small intestine of chickens in South Africa, West Africa and Asia. It causes diarrhea, weight loss and decreased egg production.

Aonchotheca (Capillaria) bursata***Aonchotheca (Capillaria) caudinflata******Capillaria obsignata***

Ornithostrongylus quadriradiatus among pigeons and doves, causing catarrhal enteritis and anemia.

Deletrocephalus dimidiatus*, in rheas.*Nematodes primarily presents in the ceca*****Heterakis***

Heterakis gallinarum is relatively small (length: 1.5 cm) and affects many backyard birds as well as wild galliformes. The *Heterakis* larvae settle directly in the lumen of the ceca. Earthworms can play the role of intermediate host. The egg of *Heterakis* can be a

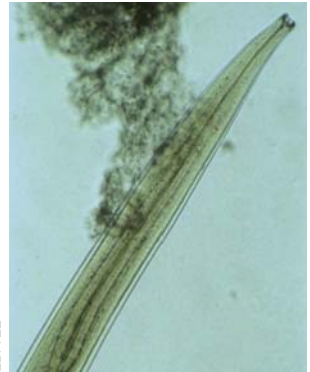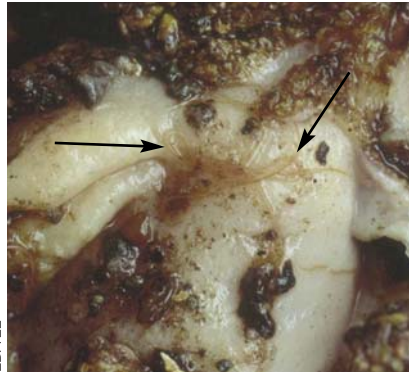
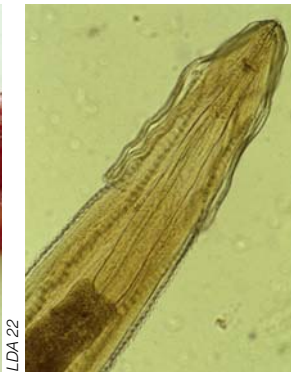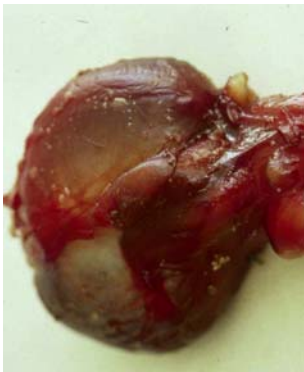


Fig.67.39 & 67.40: *Echinura uncinata* (Duck). Parasitic nodules visible on the gizzard and anterior end of an adult worm.

Fig.67.41 & 67.42: *Amidostomum anseris* (Goose). Nematodes on the mucosa of the gizzard (arrows) and anterior extremity of adult worm.

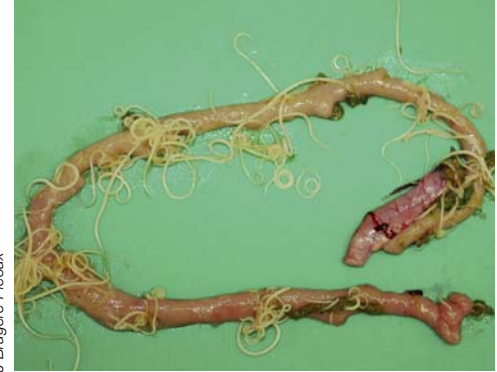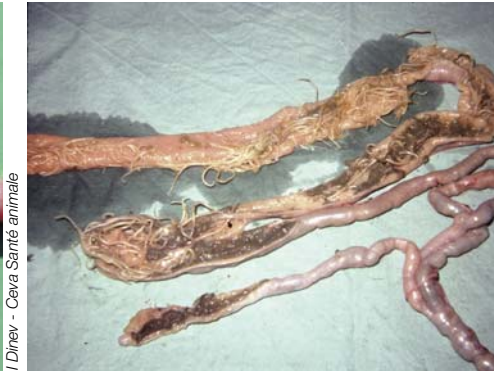

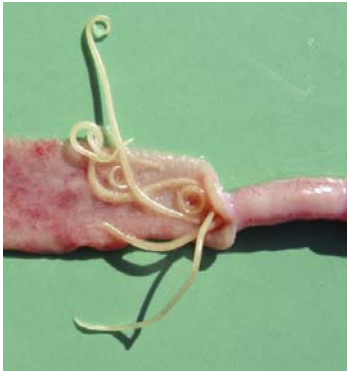
Fig.67.43, 67.44 & 67.45: *Ascaridia galli*. The heavy infestation can cause obstruction or even perforation of the small intestine.

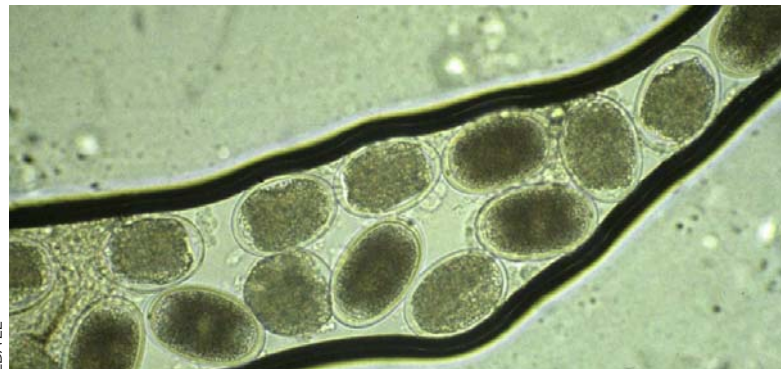
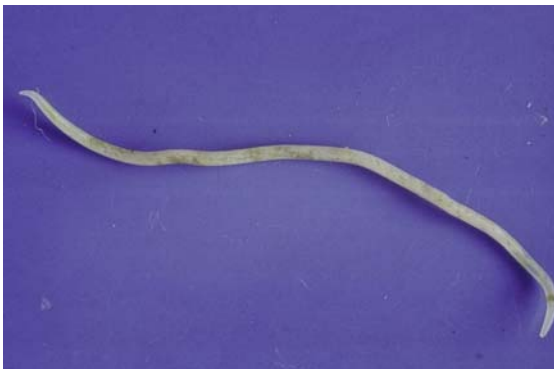
Fig.67.46 & 67.47: *Ascaridia galli*. Adult worm and microscopic observation of eggs by transparency.

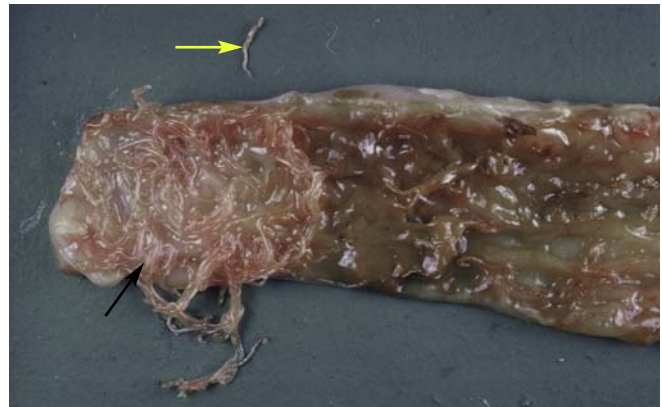
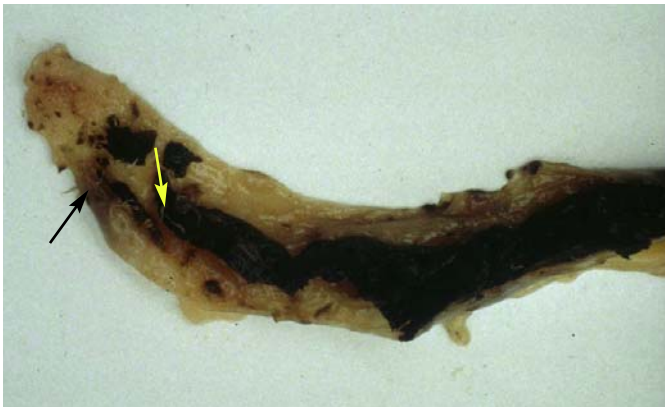
Fig.67.48 & 67.49: *Heterakis* spp. Verrucous typhlitis and presence of adult worms in the lumen of the ceca (arrows).

vector for the protozoan *Histomonas meleagridis*, the agent of histomonosis (also known as histomoniasis).

Other *Heterakis* can be observed in geese and ducks (*H. dispar*) or in various species of domestic or game birds (*H. isolonche*).

***Subulura* spp.**

S. brumpti, small nematode (7-14 mm in length) having the particularity of a dorsal curvature of the anterior portion, is found in the ceca of chickens, turkeys, ducks, guinea fowls and some other birds, especially in Africa, Asia and the Americas. Various insects like beetles and cockroaches serve as intermediate hosts. It is considered as a mild pathogen. *Subulura suctorica* is found in chickens, turkeys and guinea fowls in South America and Africa. The female can reach 33 mm in length. *Subulura diffe-rens* is found in southern Europe.

Strongyloides avium

This small and thin nematode (less than 2 mm in length) is an inhabitant of the intestine and ceca in chickens, turkeys, geese, quails and some wild birds throughout the world. Female worms produce embryonated eggs by parthenogenesis, and larvae in the environment can penetrate the skin. A heavy infestation induces inflammation with edema and intestinal erosion. The birds will then present apathy, weight loss and bloody diarrhea.

Trichostrongylus tenuis

This small nematode (about one centimeter long) is found in the ceca of chickens, turkeys and ducks throughout the world. Eggs eliminated with droppings become infectious in about two weeks on the ground. The infestation causes anemia and weight loss. Droppings become liquid and tinged with blood.

Aulonocephalus lindquisti

The pathogenicity of this parasite of the quail is not precisely known.

Nematodes of the respiratory tract

Syngamus trachea

This small bloodsucking nematode (5-30 mm in length) is the only parasite housed within the trachea of most domestic birds, although rarely in geese.

The white male and the red female mate permanently and take the shape of a «Y». *Syngamus trachea* has a worldwide distribution.

The worms irritate the respiratory mucosa, causing an abundant production of mucus. The eggs trapped in the mucus move up the trachea to be swallowed and expelled with the droppings. The infectious form (L₃) develops inside the egg, but the earthworm can serve as paratenic host as well as a wide variety of invertebrates such as snails and insects. Once swallowed, the larva makes its way to the alveoli in 4-6 hours through the liver, probably carried by blood. Laying begins 16 to 20 days later and the parasite can survive for nine months in the egg.

Even a light parasite load can induce hemorrhagic tracheitis and excessive production of mucus blocking the airways. The birds shake their heads and cough trying to remove excess secretions, resulting in dyspnea involving either frequent yawning from which the name “gapeworm”. The clinical signs are apathy, anemia and weight loss. They can worsen among young birds with emphysema, edema, and pneumonia which may progress towards death. Some immunity develops in birds from the age of 2 to 3 months.

The diagnosis is easy and can be confirmed at necropsy by observation of parasites in the trachea. Parasites can even be visible through direct observation of the trachea in a live chick (using a light after moving the neck feathers and pulling the skin). Eggs are 43-46 x 70-100 µm, ellipsoidal in shape, with a thick operculated cap visible at each end. Control is mainly based on biosecurity measures.

Cyathostoma bronchialis

Cyathostoma bronchialis, very similar to *S. trachea*, can be observed in ducks, geese and swans and clinical signs are identical. Infections may follow episodes of heavy rainfall, during which earthworms become available.

Nematodes of the eye and associated structures

Oxyspirura mansoni

This nematode, from 12 to 18 mm long, can settle under the nictitating membrane or in the conjunctival sacs and the tear ducts of chickens, turkeys, ducks, guinea fowls and other birds in tropical and subtropical climate areas. It can cause severe

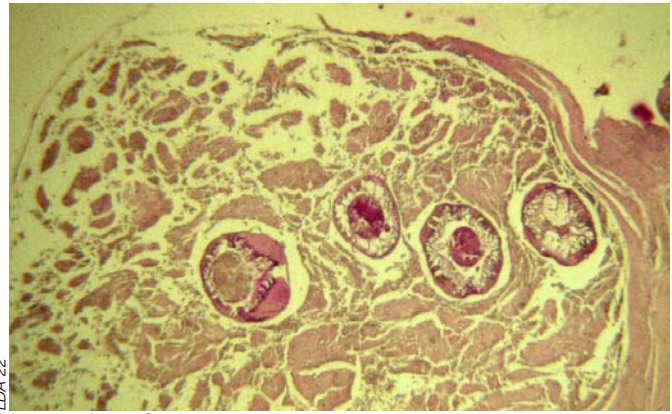
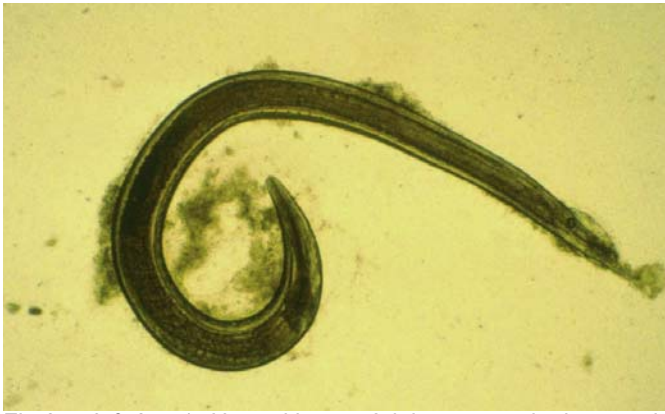

Fig.67.50 & 67.51: *Heterakis* spp. Adult worm and microscopic observation of eggs.

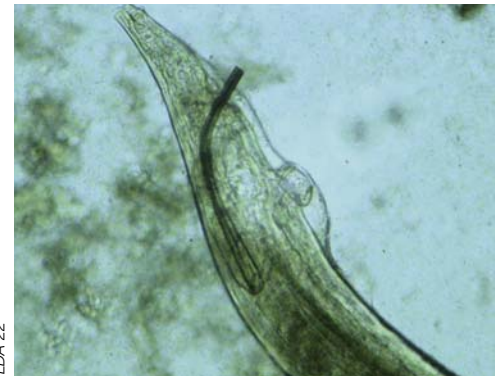
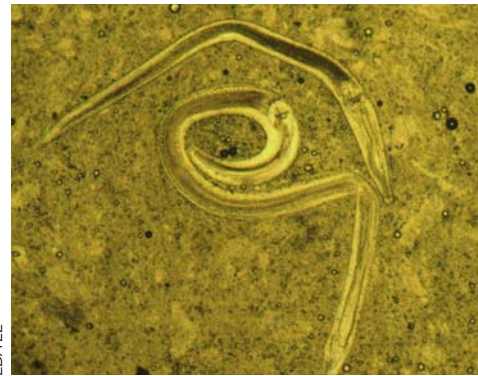
Fig.67.52, 67.53 & 67.54: *Trichostrongylus tenuis*. Presence of adult nematodes in the ceca of a pheasant. Appearance of adult worms (in a goose) and the posterior end of *T. tenuis* (in a pheasant).

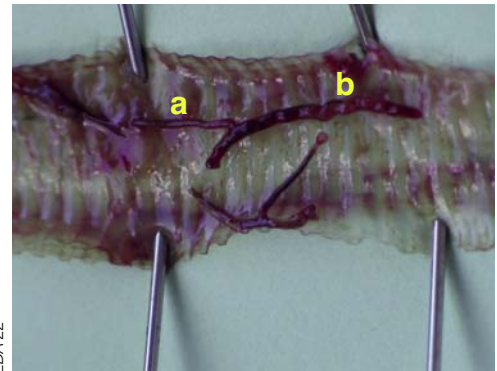
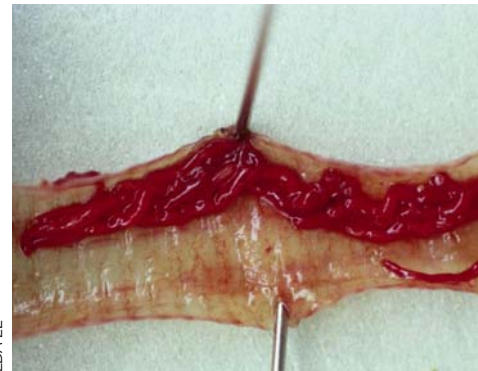
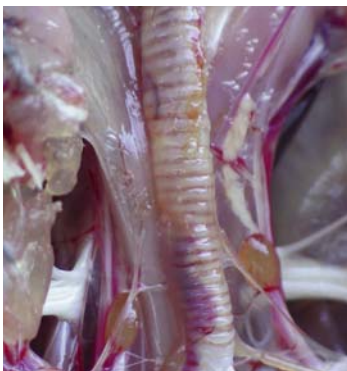

Fig.67.55, 67.56 & 67.57: *Syngamus trachea* (Pheasant). The gapeworms can be seen by transparency in the trachea (right). Infestation can be massive. It is easy to recognize the forked worm because the male (a) and female (b) are always locked in copulation to form a «Y».

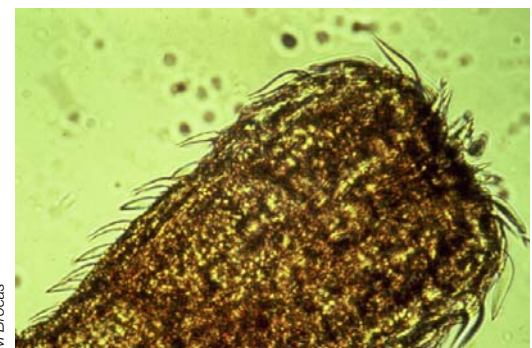
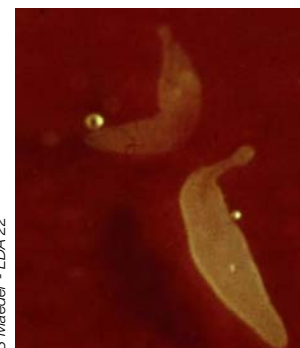
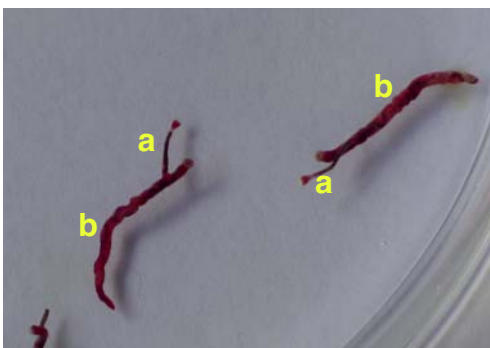

Fig.67.58: *Syngamus trachea* (Pheasant). Forked worm with the male (a) and female (b) locked in copulation to form a «Y». Fig.67.59 & 67.60: *Polymorphus* (*Echinorhynchus*) spp. Adult worms and aspect of the thorny proboscis.

ophthalmia. Diagnosis is made by examination of the eye or by coproscopy.

Oxyspirura petrowi

This parasite of the nictitating membrane is encountered in backyard chickens and game birds.

ACANTHOCEPHALA

The acanthocephalas (thorny-headed worms) live as adults in the intestinal tract of vertebrates. Their intermediate hosts are varied (arthropods, reptiles, amphibians) and several species are known to affect birds: for example, *Oncicola canis* in turkey poults (this parasite of carnivores can be found accidentally in turkeys), *Prosthorhynchus formosus*, low pathogenic in chickens, *Polymorphus boschadis* discovered in ducks in Canada or *Polymorphus (Echinorhynchus) minutus* in waterfowl.

TREATMENT OF HELMINTHIASIS

The treatment of helminthiasis is mainly based on the use of flubendazole, fenbendazole or levamisole. Control of infected soils or water bodies and intermediate hosts can reduce the risk of reinfestation.

REFERENCES

- Clark S et al. Flagelled protozoan infections in turkeys. *World Poultry*, 2003,19:4p. <http://www.poultrymed.com/ftp/pub/flagellated.pdf>.
- Diseases of Poultry*. Ed. Saif et al, Blackwell Publ. Iowa 2008: Yaswinski TA & Tucker CA. Nematodes and acanthocephalans. pp 1025-1056; McDougald LR. Cestodes and trematodes. pp 1056-1066; McDougald LR & Bermudez AJ. Protozoal infections. pp 1067-1117.
- Kilpinen O et al. Influence of *Dermanyssus gallinae* and *Ascaridia galli* infections on behaviour and health of laying hens (*Gallus gallus domesticus*). *Br Poultry Sci*, 2005,46:26-34.
- Moravec F. Proposal of a new systematic arrangement of nematodes of the family Capillariidae. *Folia Parasitologica (Praha)*,1982,29:119-132.
- Thienpont D et al. Le diagnostic des verminoses par examen coprologique. *Janssen Animal health* 2003.
- Trees AJ. Parasitic diseases. In *Poultry Diseases*, sixth Edition. Eds Pattison M et al., Saunders Elsevier. 2008, pp 443-467.
- Wilson JE & Slavin D. Hexamitiasis of turkeys. *Vet Rec*,1955,67:236-242.



Fig.68.1: Lice (Pheasant).

Fig.68.2 & 68.3: *Columbicola columbae* or slender pigeon louse.



Fig.68.4: Isolated mallophage from a pigeon.

Fig.68.5 & 68.6: Ostrich feathers with nits of *Struthiolipeurus struthionis* located adjacent to the shaft.

Fig.68.7 & 68.8: *Struthiolipeurus struthionis*. Female (left) and male (right).




Fig.68.9 & 68.10: *Dermanyssus gallinae*. Engorged female (left) and at the end of digestion (right).

Fig.68.11: *Dermanyssus gallinae*. Male.

Fig.68.12: *Dermanyssus gallinae*. Eggs and larvae.

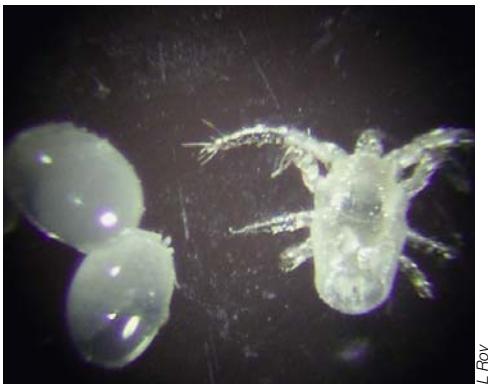


Fig.68.13: *Dermanyssus gallinae*. Eggs and nymphs.

Fig.68.14 & 68.15: *Dermanyssus gallinae*. Parasites gorged with blood in the feces of chickens (low and high magnifications).

Other diseases

68. ECTOPARASITES & POULTRY PESTS

INTRODUCTION

There are two types of mites and ectoparasitic insects in poultry:

- Permanent or stationary parasites (scabies and lice) where contamination is by direct contact between birds; the main source of the parasite being infested birds, the parasite not surviving long in the environment;
- Intermittent bloodsucking parasites, (gamasid mites, ticks, bedbugs, fleas). For these arthropod pests, the source is double, the bird and its environment, the parasites multiplying outside of the bird.

Other poultry pests are rodents (mice and rats).

LICE

Only chewing (biting) lice (*Mallophaga*) may infect poultry. These insects are found in farms with poor hygiene conditions, most often during the cold season. The size of the main species is less than a millimeter up to 5 mm. Their color is generally pale, sometimes yellowish or brownish, depending on the species. They feed on feathers and/or skin, although some of them may ingest the blood that flows from the wounds they have caused or related to pecking.

More than 40 species have been described in domestic poultry. *Menacanthus stramineus* or chicken body louse (yellow louse in chickens and turkeys) is the most common and most pathogenic species because of its high abrasive power. This louse is often located around the vent.

Other species have been described including:

- *Menopon gallinae*, small body louse in chicken;
- *Cuclotogaster heterographus*, the head louse of poultry;
- *Goniodes dissimilis*, brown chicken louse;
- *Goniocotes gallinae*, poultry fluff louse;
- *Goniodes gigas*, large chicken louse;
- *Lipeurus caponis*, poultry wing louse;
- *Goniodes meleagridis*, turkey louse;
- *Chelopistes meleagridis*, large turkey louse;
- *Goniodes numidae*, Guinea fowl feather louse;
- *Lipeurus numidae*, slender Guinea fowl louse;
- *Trinoton querquedulae*, duck louse;
- *Trinoton ansericum*, geese louse;
- *Columbicola columbae*, slender pigeon louse.

These infestations are seen more commonly in poultry. An infestation can even involve several species. Since the transmission is by direct contact, parasitic loads can be particularly high and induce significant damage to birds.

Females lay several hundred whitish eggs that they glue to the base of feathers. These nits, forming the «parasitic scum», are visible to the naked eye. The eggs hatch about a week later and the nymphs emerge, taking about three weeks to mature. Permanent parasite, the life span is about one month while the survival rarely exceeds one week after separation from the host.

The discomfort due to pruritus and the pathogenicity of lice cause various lesions (loss of feathers, crusts, excoriations). The growth rate is reduced, egg production decreases (up 40%), the plumage deteriorates and mortality increases in young chicks.

The treatment is individual and involves the application of insecticides on two occasions with an interval of 10 to 14 days, the second application destroying the parasites protected in the egg at the time of the first treatment. Products used must be authorized and used with caution to avoid residues in the environment and/or the food chain. In addition, it is important to clean the premises and replace the litter, paying special attention to the nests. As cross-contamination is possible, it is important to control other bird species coming into contact with the treated birds as well as to decontaminate transport cages. The practice of beak trimming prevents grooming and thereby promotes parasitism.

MITES

Hematophagous mites

Two hematophagous mites are particularly harmful ectoparasites: *Dermanyssus gallinae* or poultry red mite and *Liponyssus (Ornithonyssus) sylviarum* (Northern fowl mite). Heavy infestations (especially with *Dermanyssus*) can cause severe anemia accompanied by a drop in egg production. *Ornithonyssus* is considered as a permanent parasite while *Dermanyssus*, a bloodsucking parasite feeding at night, withdraws to the immediate




Fig.68.16, 68.17, 68.18 & 68.19: Regular monitoring requires the observation of several strategic points known to harbor mite aggregates: spaces between two solid elements of the structure (perch, egg belts, etc.) and under dry droppings of chickens (see Fig.68.13 & 68.14).




Fig.68.20 & 68.21: It is necessary to treat before the appearance of red spots on the eggs or anemia in birds showing a significant proliferation of red mites.

Fig.68.22 & 68.23: The synergistic predatory action of *Androlaelaps casalis* (left) and *Cheyletus eruditus* (right) allows effective biological control against *Dermanyssus gallinae*.



Fig.68.24, 68.25 & 68.26: Scaly leg mite at different stages (Chicken). Compare with the normal leg over the affected leg Fig.68.25.

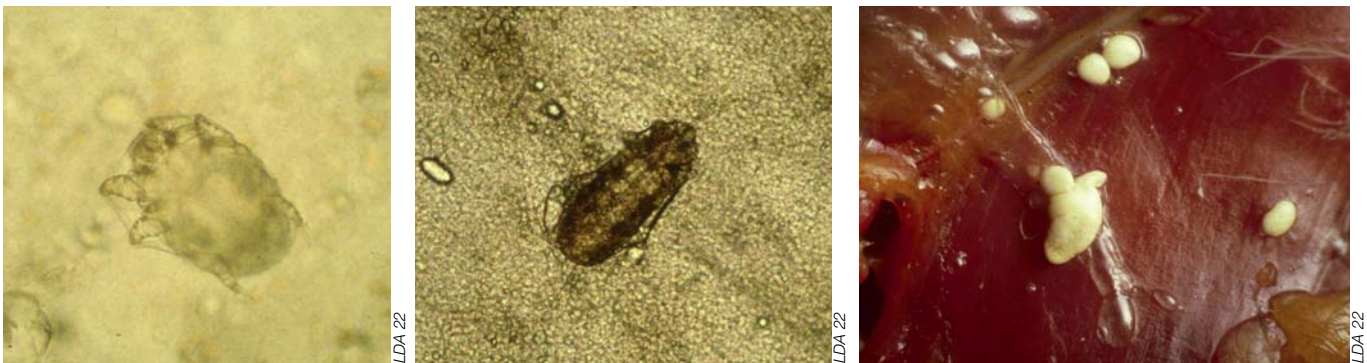

Fig.68.27: *Knemidocoptes mutans*.

Fig. 68.28 & 68.29: Other mites can behave as endoparasites such as *Laminosoptes cysticola* (left), a parasite of connective tissues (right).

environment of the birds during the day. It is therefore important to differentiate these two hematophagous mites for the implementation of appropriate control measures. These infestations are found in domestic birds as in wild birds.

Poultry red mite (*Dermanyssus gallinae*)

It is the most common ectoparasite in poultry worldwide. Parasite of domestic and wild birds, it is often found in caged layer flocks. It feeds at night, staying only 30–60 minutes on the host. The mite's egg production is optimal at 25–30°C and the parasite can survive without feeding for nine months at a temperature of 5 to 25°C. Like many hematophagous species, this parasite is a suspected carrier of several viral and bacterial pathogens (Newcastle disease, St. Louis encephalitis, avian pox, Western equine encephalitis, *Salmonella* including *S. Enteritidis*, *Escherichia coli*, *Shigella* spp., *Staphylococcus*, *Borrelia anserina*, *Erysipelotrix insidiosus*, etc.).

This mite is hardly visible to the naked eye but the consequences of infestation are visible due to the change in bird behavior (nervousness, pecking, stress, aggression), decline in production (eggs, lower feed conversion ratio), signs of anemia observed in birds and bloodstains noted on the eggs (by crushing lice present on the equipment collecting eggs), resulting in rejects. Anemia may be severe during a massive infestation and can cause death. Economic losses associated with production losses and treatment costs are estimated at around 0.40 € per hen per year.

It is important to quickly detect the presence of poultry red lice in order to limit economic losses. For this purpose, there are glue traps or corrugated cardboard tubes where the mites will readily penetrate. However, farmers know their usual hiding places in layer hen houses (egg collection belts, cage supporting rods, etc.).

Treatment is based on the use of insecticides authorized for use in layer hen houses and not allowing the development of resistance (In Europe products such as phoxim and spinosad are used successfully). Biosecurity measures are essential to prevent new infestations, especially during the downtime period by cleaning and disinfection with effective acaricides. Finally, biological control is possible with two predatory mites of *Dermanyssus gallinae*: *Androlaelaps casalis* and *Cheyletus eruditus*.

This parasite can also attack the farmer, causing pruritic dermatitis or an allergic reaction with eczema.

Northern fowl mite [*Ornithonyssus (Liponyssus) sylviarum*]

Ornithonyssus sylviarum is also called «American lice» because of its strong presence in North America in many domestic and wild birds. It is also reported in Europe. Although its appearance is almost identical to *Dermanyssus gallinae* and it is also prevalent in winter, *O. sylviarum* behaves more like a typical parasite: it remains, moults and lays eggs on its host. It can only survive a few weeks outside the host. Thus, the traces left by the droppings of mites as well as eggs are visible directly on now blackish feathers of the bird, especially in the vent region where the skin appears cracked with scabs. Young birds are more susceptible to infestation. Rodents and wild birds are reservoirs of these ectoparasites. Unlike treatment for *Dermanyssus*, birds should be treated with an acaricide by spray applications in the vent region to eliminate *Ornithonyssus*.

This parasite can also infect humans.

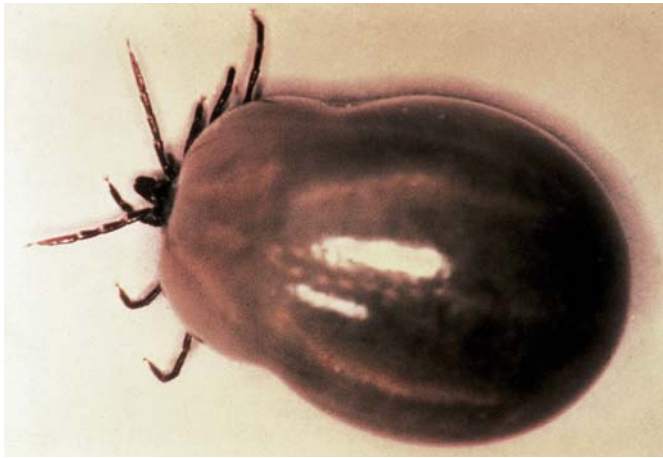Tropical poultry mite [*Ornithonyssus (Liponyssus) bursa*]

The pathogenicity of *O. bursa*, which is only found in tropical and subtropical regions, is identical to the one of *O. sylviarum*.

Mange (scaly leg and depluming mites)

Mange in birds include about 17 species of the subfamily of *Knemodokoptidae* and are mainly genus *Knemidocoptes* (synonym *Cnemidocoptes*), the order of *Sarcoptiformes*. Mange in birds can be compared to mange in mammals caused by ectoparasites of the genus *Sarcoptes* but, unlike mammals, most birds do not always have intense itching. Adults are about 0.3 mm in diameter, with a rounded body shape and short stubby legs. They are permanent parasites and the generation span is completed in two to three weeks.

The species most often found in poultry are *Neocnemidocoptes gallinae* (syn *Knemidocoptes gallinae*) and *Knemidokoptes mutans* while we know *Knemidocoptes pilae* in parrots. The main affected sites vary depending on the parasite involved. Thus,



Service de parasitologie ENNV



J. Alamargot

Fig.68.30 & 68.31: Other ectoparasites. Ticks: e.g., *Ixodes ricinus* (left). Fleas: e.g., *Echidnophaga gallinacea*, relatively pathogenic in tropical and subtropical regions (right).



Bayer



Bayer



Bayer



D. Vanne

Fig.68.32, 68.33, 68.34 & 68.35: *Alphitobius diaperinus*. Enlarged oval-shaped darkling beetles are black or brown-black color with a usually shiny appearance (color may vary depending on age). Adults measure about 5.8 to 6.3 mm.



Bayer



Bayer



Bayer



Bayer

Fig.68.36, 68.37, 68.38 & 68.39: *Alphitobius diaperinus*. Darkling beetles are found in all kinds of structures, but more often in the walls.



Bayer



Bayer



Bayer



Bayer

Fig.68.40, 68.41, 68.42 & 68.43: *Alphitobius diaperinus* (larvae). Darkling beetles are found in all kinds of structures, but more often in the walls. Larvae can drill holes in polystyrene foam, in fiberglass and insulation panels.

K. gallinae mainly affects the head, neck, back, abdomen and upper legs of chickens, pigeons and pheasants. *Knemidocoptes mutans* is manifested by damage to the featherless part of legs in poultry and birds of prey while *K. pilae* first develops on the beak to spread to the head and legs in psittacines.

Other species may be responsible for depluming mange in chickens in the following families:

- *Analgidae*: *Megninia cubitalis*, *M. ortari*, *M. holostra* and *M. ginglymura*;
- *Dermationidae*: *Rivoltasia bifurcata*;
- *Epidermoptidae*: *Epidermoptes bilobatus*.

Depluming mite (*Neocnemidocoptes gallinae*)

Neocnemidocoptes gallinae (syn *Knemidocoptes laevis* var *gallinae*, *K. gallinae*) infests the skin of the back, head, abdomen and upper parts of the legs of chickens, pheasants and geese, causing significant pruritus bringing birds to pluck feathers. The affected skin, particularly in the neck, may become scaly, thickened, and wrinkled. While this depluming mange is less frequently observed than the scaly leg mite, it can be severe and sometimes fatal.

Two other *Neocnemidocoptes*, *N. Columbicola* and *N. columbigallinae*, infest columbiformes and can be pathogenic for the domestic pigeon.

Scaly leg mite (*Knemidocoptes mutans*)

Knemidocoptes mutans mainly affects the skin between the scales of the legs. Mites puncture the skin under the scales for feeding, which causes inflammation with the onset of exudate which hardens and raises the scales. They may even fall while the skin of the legs takes a scaly appearance (scaly leg). Legs and claws are gradually deformed, causing lameness. Clinical signs develop over several months in the absence of treatment, and the birds waste away.

The clinical diagnosis is easy and can be confirmed by observing the mites harvested by scraping.

Treatment of mange

Treatment can be done with ivermectin, sulfur and other miticides. Disinfecting perches, nests and litter also complement treatment.

OTHER ECTOPARASITES

Other ectoparasites can intermittently infest domestic poultry as well as mammals, including man. These are insects of the order *Hemiptera*, such as bedbugs (*Cimex lectularius*) that infest poultry houses like human habitations. Other insects of the order of *Siphonaptera*, such as fleas, attack birds as well as mammals. Most commonly known is *Ceratophyllus gallinae*, the chicken flea, or *Echidnophaga gallinacea* relatively pathogenic in tropical and subtropical regions, especially in young birds. The special feature of *E. gallinacea* is to remain attached to the host for several days to several weeks. Moreover, fleas of mammals (cat, man) may invade poultry barns.

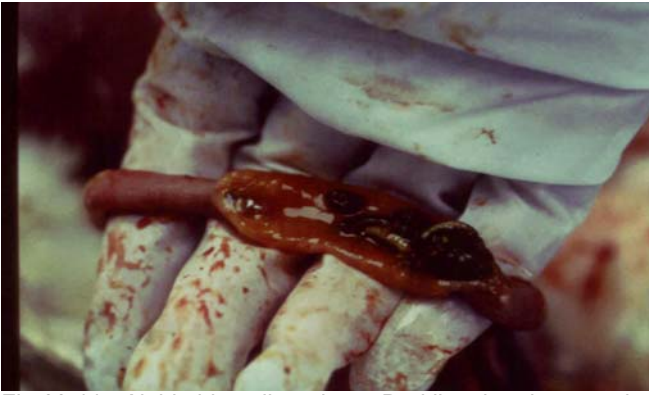Other arthropods in the order of *Acarina* such as chiggers (*Trombicula* spp.), very recognizable by their red-orange color, can also infest poultry houses during specific time periods. There is also the possibility of infestation by ticks of the family of *Argasidae*, called soft ticks (*Argas reflexus*, *A. persicus*, *Ornithodoros moubata*) or the family of *Ixodidae*, or hard ticks (including *Amblyomma* spp., *Ixodes* spp., *Haemaphysalis* spp. and *Hyalomma* spp.). In poultry, these ticks can cause anemia and growth retardation and may also favor the transmission of infectious agents in poultry.

PESTS

The main pests found in poultry houses are mainly beetles (especially *Alphitobius diaperinus*), flies and rodents. Other pests can be mentioned, such as mosquitoes, blackflies, etc.

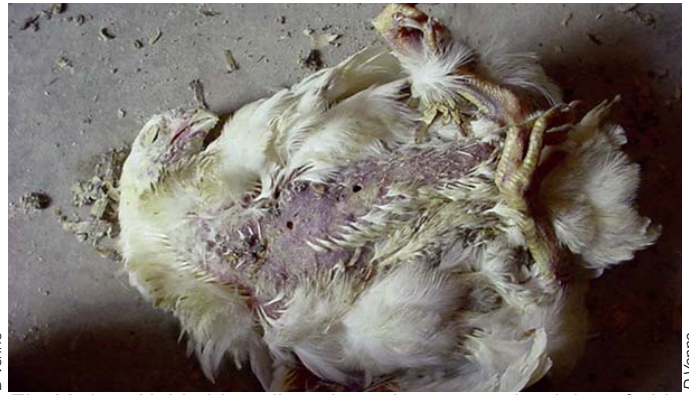Beetles

Darkling beetles of the species *Alphitobius diaperinus* (or mealworm) are pests present in large numbers in the litter, making it lose its insulating properties while making more dust which increases the discomfort of birds. They can also penetrate the insulation materials causing considerable damage. They also have proven to be vectors of pathogens (Marek's disease virus, *Salmonella*, *Escherichia coli*, *Aspergillus*, etc.). *Alphitobius* may also attack very young chicks in poor condition. Only strict biosecurity measures combined with proper insecticide treatment can limit their proliferation.



D Venne

Fig.68.44: *Alphitobius diaperinus*. Darkling beetles can be observed in the intestinal contents of poultry.



D Venne

Fig.68.45: *Alphitobius diaperinus*. Larvae and adults of this omnivorous beetle also feed on corpses.



Bayer



Bayer



Bayer

Fig.68.46, 68.47 & 68.48: Housefly (*Musca domestica*). Pupae (left), pupae and larvae (middle), larvae and adult forms (right).



Bayer



D Venne



Bayer

Fig.68.49, 68.50 & 68.51: Housefly (*Musca domestica*). Adult forms on a wall of a shed used for the storage of manure (left), or on the food (middle). The use of an attractive insecticide for adult flies is a means of control.



Bayer



Bayer



Bayer

Fig.68.52, 68.53 & 68.54: Rodents, especially rats and mice, are significant pests that must be avoided in the environment of poultry houses.

Flies

Associated with poultry farming, flies are a real nuisance to neighborhoods causing public health problems. Flies can provide passive transportation to many pathogens (viruses, bacteria, parasites), or be intermediate hosts for parasites found in mammals or birds (cestodes). This vector role has been increasingly demonstrated in many diseases of livestock and poultry. Production systems with accumulation of droppings for long periods encourage the multiplication of flies. This proliferation increases the risk of spreading diseases between poultry flocks. Finally, their control is difficult.

The main species are:

- the house fly (*Musca domestica*) causing black stains on the material and the walls of poultry houses;
- little house fly (*Fannia canicularis*), flying in circles quite close to the ground;
- *Hermetia illucens* (black soldier fly) more frequent in systems with prolonged accumulation of droppings. Larvae promote liquefaction of manure, causing leakage and loss of fertilizer;
- *Ophyta* spp., *Phornia* spp., *Lucilia* spp., etc.

Manure should be well ventilated and dry to prevent the development of maggots. Avoiding water leaks wetting the litter, promoting biological control (mites, beetles and parasitic wasps, natural predators of flies) or using insecticides are other useful methods.

Rodents

Finally, rodents are particularly dreaded pests in poultry houses for several reasons: they can destroy electrical installations and insulation structures and are attracted by the poultry feed they eat and contaminate, affecting the feed conversion ratio and transmitting diseases.

The main rodents found in poultry houses are rats (*Rattus norvegicus* and *Rattus rattus* living outside

and inside poultry houses respectively) and mice (*Mus musculus*, living mainly inside poultry houses).

The fight against rodents is based on four main actions: (1) elimination of rodents that may be nesting in equipment, (2) proper sanitation and building management, (3) trapping, (4) use of effective rodenticides.

REFERENCES

- Bayer http://www2.bayer.be/emailvision/animal-health/content/News_Brochure_ByeMiteBEFR.pdf.
- Bellanger AP et al. Nosocomial Dermatitis Caused by *Dermanyssus gallinae*. *Inf Control and Hospital Epidemiol*, 2008, 29 <http://www.jstor.org/stable/10.1086/528815>.
- Elanco. http://stoppouxrouges.fr/static/files/download/fr/EGB0090_BR_FR_Elector-blkvrn_HR.pdf.
- Hinkle NC & Corrigan RM. External parasites and poultry pests. In *Diseases of Poultry*. Ed. Swayne DE et al, Wiley-Blackwell Publ. Iowa 2013, pp1099-1116.
- Hopla CE et al. Ectoparasites and classification. *Rev Sci Tech OIE*, 1994, 13 :985-1017. <http://www.oie.int/doc/ged/D8933.PDF>.
- ITAVI. Le pou rouge en élevage de poudeuses. http://www.itavi.asso.fr/elevage/sanitaire/fiche_pou.pdf.
- Kilpinen O et al. Influence of *Dermanyssus gallinae* and *Ascaridia galli* infections on behaviour and health of laying hens (*Gallus gallus domesticus*). *Br Poultry Sci*, 2005,46:26-34.
- Moro CV et al. The poultry red mite (*Dermanyssus gallinae*): a potential vector of pathogenic agents. *Exp Appl Acarol*, 2009, 48: 93-104.
- Mul MF et al. Control of poultry red mite in layer farms using an automated monitoring device. *Congress World Veterinary Poultry Association*, Nantes 2013. Poster.
- Trees AJ. Parasitic diseases. In *Poultry Diseases*, sixth Edition. Eds Pattison M et al., Saunders Elsevier. 2008, pp 443-467.

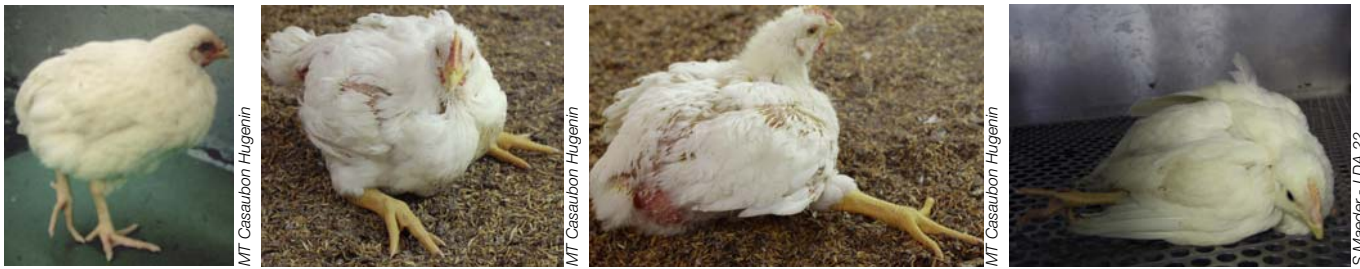

Fig.69.1, 69.2, 69.3 & 69.4: Clinical aspects of diseases of the musculoskeletal system vary from lameness (Fig.69.1) to abnormal decubitus (Fig.69.2), splay legs (Fig.69.3) to paralysis as here with Marek's disease (Fig.69.4).



Fig.69.5, 69.6 & 69.7: These disorders can occur at a young age (splay leg in chicks Fig.69.5) and the same clinical signs can be seen with conditions of various origins like paralysis with crooked toes due to Newcastle disease virus (Fig.69.6) or riboflavin deficiency (Fig.69.7).

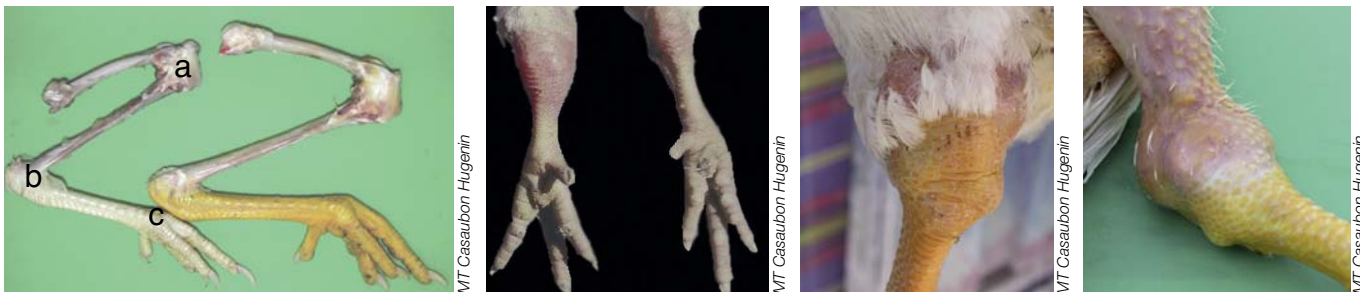

Fig.69.8, 69.9, 69.10 & 69.11: Arthritis. Compared with the femoro-tibiotarsal joint (a), the tibia-metatarsal (b) and metatarsophalangeal (c) joints are most commonly affected in poultry (Fig.69.8). Arthritis can be acute (69.9) or chronic (Fig.69.10 & 69.11).

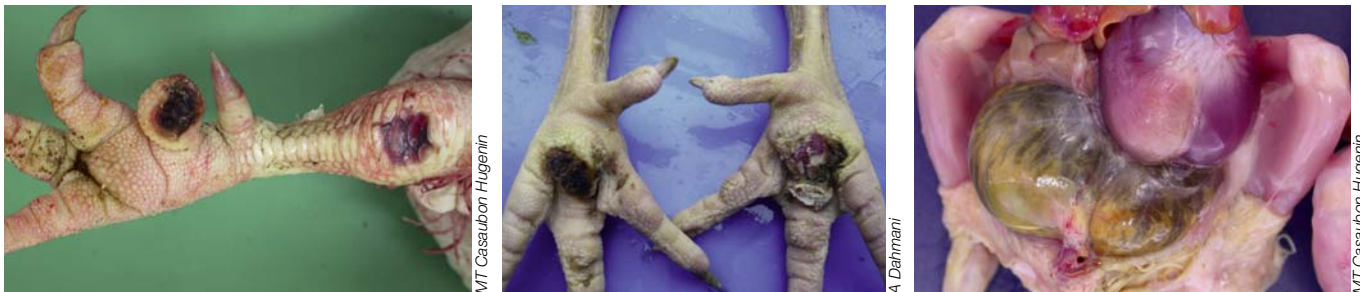

Fig.69.12, 69.13 & 69.14: Arthritis may originate from pressure ulcer (Fig.69.12) or footpad dermatitis (Fig.69.13) that is observed when the litter is too wet. It can also be a complication of omphalitis (Fig.69.14).

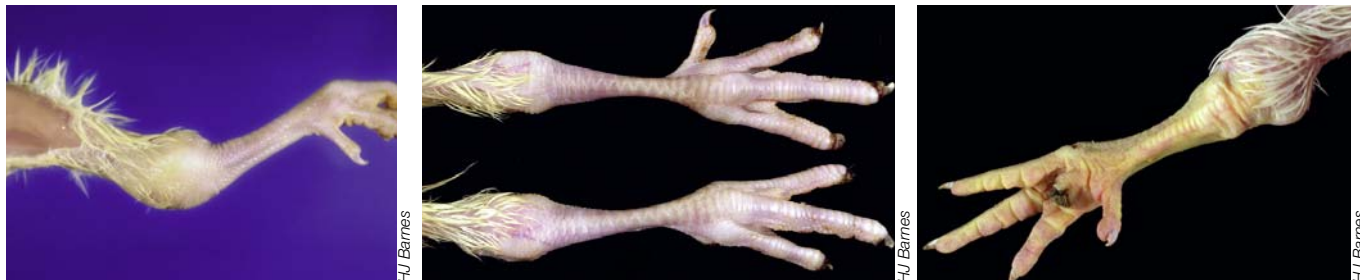

Fig.69.15, 69.16 & 69.17: Arthritis. Following omphalitis, arthritis may then be observed, as here, at 10 days (Fig.69.15) and 12 days (Fig.69.16) of age. It is most often caused by coliforms as in the case of this arthritis associated with footpad dermatitis in a five week-old turkey (Fig.69.17).

Other diseases

69. DISEASES OF THE MUSCULOSKELETAL SYSTEM

INTRODUCTION

The musculoskeletal system comprises components of the nervous, vascular, muscular and skeletal systems. Thus, a lesion in any of these systems may cause locomotion problems. However, the skeleton is most frequently affected in poultry raised under intensive production conditions due to genetic selection, overcrowding, flock management, infections and diet composition. Because of different genetic lines and their ancestral heritage linked to growth rate, broilers are likely to suffer from bone fragility associated with structural damage and inadequate bone mineralization. In laying hens, production reaching almost one egg per day may exhaust bone mineral reserves. Consequently, bones become porous, brittle, and fractures are common. Moreover, high flock density increases the infection pressure, limits opportunities for exercise and subsequently promotes inactivity causing structural disorders of bone tissue. Clinical signs include lameness, apathy, lethargy or prostration with postural abnormalities that may progress to paralysis. It is also a welfare problem. Some cases lead to death by dehydration, starvation, cachexia and/or immunosuppression favoring secondary infections.

In the 1980s, bone deformities and tibial dyschondroplasia were considered the main causes of lameness in broilers. In the late 1990s, the removal of antibiotic growth promoters, followed by an increase in the incidence of mild enteritis with calcium and phosphorus malabsorption, led to impaired bone development.

For a comprehensive musculoskeletal investigation in broilers, the following protocol should be considered:

- dissection (skinned legs and transversal section of the spine);
- dissection of thoracic spine (where leg weakness is attributed to possible spinal pathology);
- identify bone deformities (examination of right/left leg symmetry);
- identify gross tendon or muscle lesions (gastrocnemius tendon, main leg muscles);
- examination of tarsus and hock joints;
- examination of hip joint (femoral head necrosis);
- examination of bone deformities (the most deformed bone is often the tibiotarsus);

- differentiate rickets from tibial dyschondroplasia. Rickets affects all growth plates evenly whereas tibial dyschondroplasia is mainly localized in the proximal tibiotarsus;

- finally, additional tests may be performed: evaluation of the bone Ca and P composition, histology (proximal tibiotarsus), bacteriology, *etc.*

Musculoskeletal diseases include infectious and non-infectious diseases.

INFECTIONS OF THE MUSCULOSKELETAL SYSTEM

Arthritis

Arthritis is usually the result of a systemic infection but it can also develop after trauma or after a prolonged recumbency. It may be acute or chronic.

Acute arthritis presents four main signs: pain, warmth, redness, and increased volume. Pain at the level of nerve endings is caused by pressure exerted on the joint capsule by large exudate and the irritating effects of toxins found in the exudate. Heat and redness are signs of active hyperemia or arterial dilation that develops early in the inflammatory process. On palpation, the consistency is soft, the skin is stretched and liquids dangle under the fingers. Later, the inflammatory process becomes chronic, redness and heat disappear and volume, pain and exudate decrease while the latter is found in hard nodules.

Microbes causing arthritis may reach the synovial capsule via the bloodstream from a previous infection established in another organ. This is the case, for example, with omphalitis. Arthritis can also result from an established infection in a nearby tissue such as a breast blister or footpad dermatitis that occurs when the litter is too wet (as a result of overcrowding or leaky nipple waterer or drinkers, or after an episode of diarrhea or diuresis).

The exudate formed by the articular fibrous envelope infiltrates the surrounding tissue, passes through the synovial membrane adhering to the fibrous envelope and accumulates in the joint cavity. The volume of synovial fluid containing microorganisms and exudate increases and synovial fluid loses its physical and chemical properties,

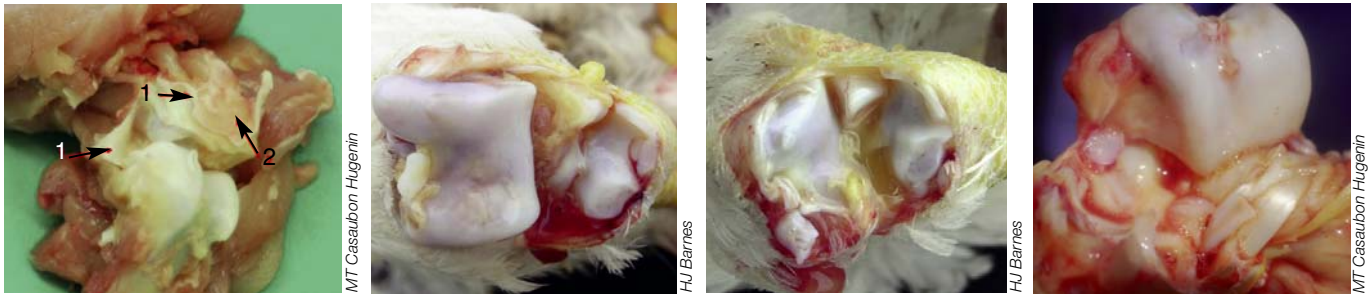

Fig.69.18, 69.19, 69.20 & 69.21: Arthritis. Compared with a joint exhibiting a normal synovial membrane (1) and a fibrous envelope (2) (Fig.69.18). Chondritis associated with arthritis (Fig.69.19, chicken hock). Synovial fluid increases in volume and appears cloudy (Fig.69.20, turkey hock) to slightly hemorrhagic (Fig.69.21).

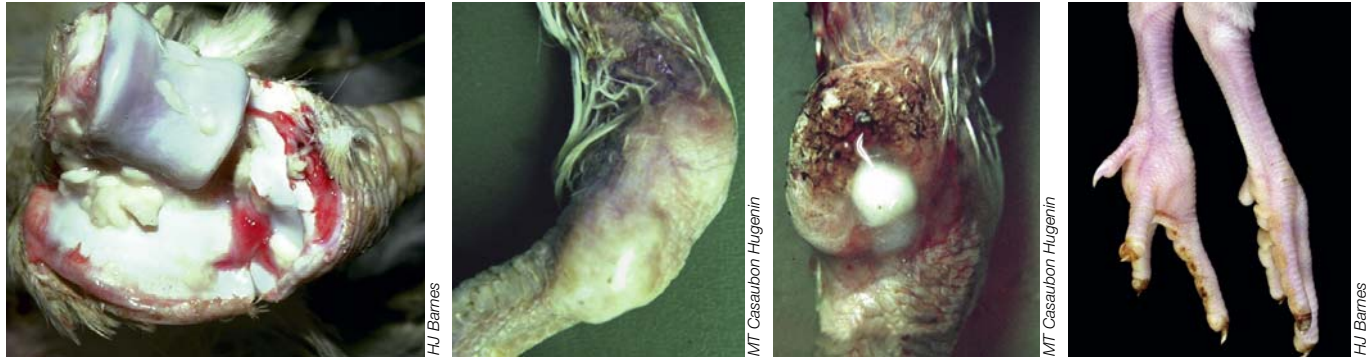


Fig.69.22, 69.23, 69.24 & 69.25: Purulent arthritis. These arthritides may be associated with salmonellosis (Fig.69.23 and 69.24), or a staphylococcal infection (Fig.69.25), etc.

Section IV

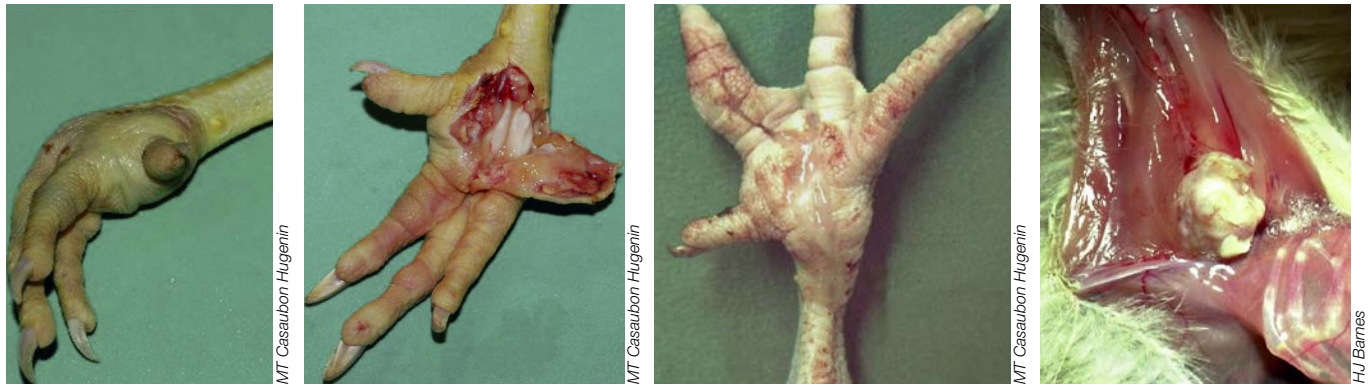

Fig.69.26 & 69.27: Purulent footpad arthritis.

Fig.69.28: Mycoplasmosis (*M. synoviae*). Infectious synovitis.

Fig.69.29: Purulent hip arthritis (Turkey).

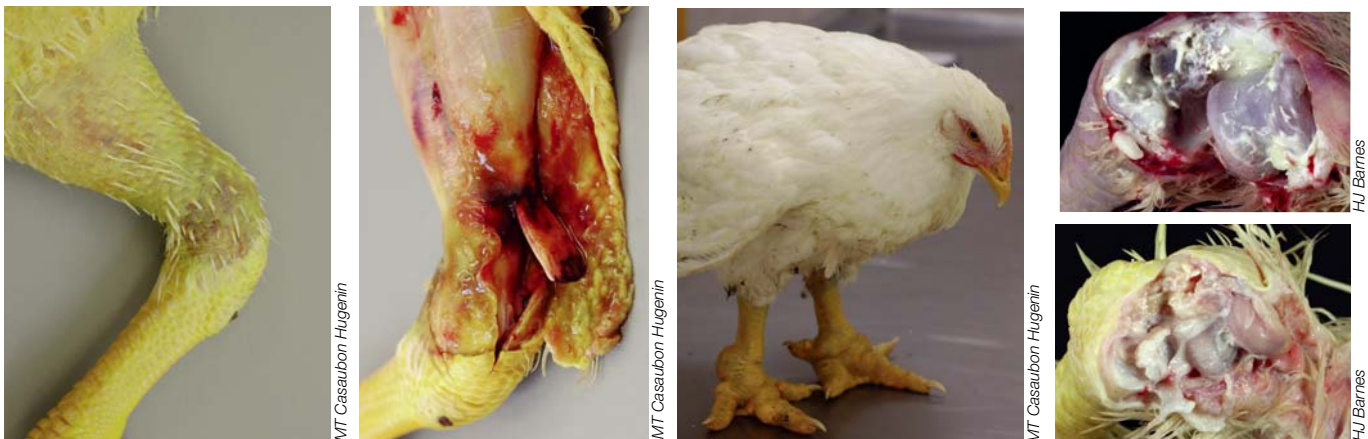

Fig.69.30 & 69.31: Viral tenosynovitis virus (reovirus) and rupture of the gastrocnemius tendon (see Chap.II.27).

Fig.69.32, 69.33 & 69.34: Arthritis must be differentiated from podal (Fig.69.32) or hock (Fig.69.33 & 69.34) articular gout where chronic inflammation is associated with urate deposits in joints (see Chap.IV.71).

becoming toxic and causing the degeneration of articular cartilage. Thereafter, the cartilage becomes opaque, porous, brittle and detached fragments or splinters of bone can be found. The infection can spread to the bones, producing osteitis, osteomyelitis and/or epiphyseal fractures. Other nearby tissues may also be affected such as ligaments, tendons and their sheaths (tenosynovitis) as well as neighboring muscles (myositis).

The main bacteria isolated from arthritis are: *Salmonella*, *Pasteurella multocida*, *Mycoplasma gallisepticum*, *M. synoviae* or *M. meleagridis*, *Staphylococcus aureus*, *Streptococcus* spp., *Enterococcus caecorum* or *Escherichia coli*.

Mycoplasma (see Chap.III.41)

Mycoplasma synoviae and *M. meleagridis*, encountered in mild upper respiratory tract diseases, are mainly responsible for joint damages (including infectious synovitis) particularly affecting tibio-metatarsal and metatarsophalangeal joints but also causing swollen footpads and a sternal bursitis or breast blister. The exudate is primarily serofibrinous, translucent and gelatinous. With the bacterial infection, it becomes creamy, yellowish and, after dehydration, cheesy. These lesions cause irreversible ankylosis due to fibrous adhesions formed between the articular capsule, sheaths, ligaments and tendons involved in this pathological process.

Reoviruses (see Chap.II.27)

Reoviruses are not only responsible for viral tenosynovitis or viral arthritis in chickens but they are also associated with a malabsorption syndrome affecting chickens and turkeys between two to three weeks of age. This malabsorption results in many nutritional deficiencies including minerals, vitamins and proteins. That is why this syndrome can cause stunting and osteodystrophies such as rickets, perosis, chondrodystrophy and twisted legs. An infected bird can present both intestinal malabsorption and tenosynovitis lesions or may be affected by only one of the two conditions. Tenosynovitis affects mainly 12 to 16 week-old poultry. A sero-hemorrhagic arthritis of the tibio-metatarsus, sometimes with a rupture of the gastrocnemius tendon may be observed.

Osteitis & osteomyelitis

It can be the complication of arthritis or septicemia. In the latter case germs usually encountered in the bone enter through nutrient arteries going directly into the bone marrow cavity and supplying blood to Volkmann's canals (transverse) and Haversian (longitudinal) which nourish bone and periosteal tissue. They are often complicated myelitis (osteomyelitis).

Femoral head necrosis

It is one of the most common causes of severe lameness in broilers. The pathology is a bacterial osteomyelitis. It is more common in broilers over 22 days of age. Clinical signs are: severe lameness that may be unilateral, with bruised wing tips as the bird is using its wings for support. Some *Staphylococcus* strains are frequently found in such cases.

Spinal osteomyelitis

The abdominal air sac associated with the free thoracic vertebrae is also a site of focal osteomyelitis. This leads to collapse of the spinal cord and paralysis due to spinal cord compression. Isolated bacteria are usually *Staphylococcus* spp or *Enterococcus caecorum*. They infected the air sacs during hatching or soon after. Therefore, control is mainly through egg and hatchery sanitation.

Osteopetrosis (see Chap.II.34)

Osteopetrosis is rarely observed. It is attributed to strains of avian leukosis/sarcoma virus. It is characterized by an abnormal growth of bone resulting in a pericortical accumulation of immature bone and in the rise of serum alkaline phosphatase activity.

Hock joint and gastrocnemius tendon infections

In general, most lame breeders have lesions to the gastrocnemius tendon and/or an inflammation of the hock joint. *Staphylococcus* spp. is commonly isolated, although it is not rare to fail to isolate any microorganism from a ruptured gastrocnemius tendon. Typically, outbreaks of this type of affection occur with:

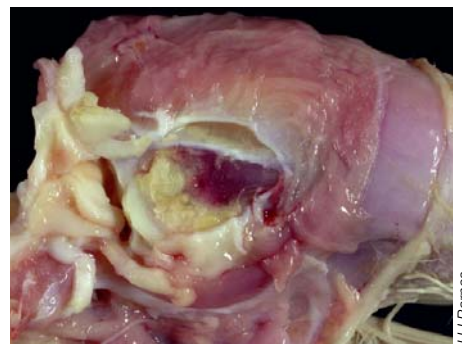
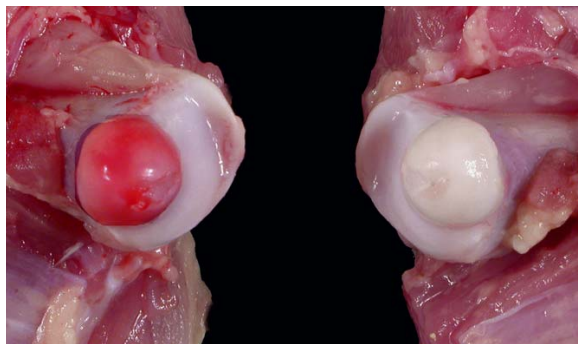
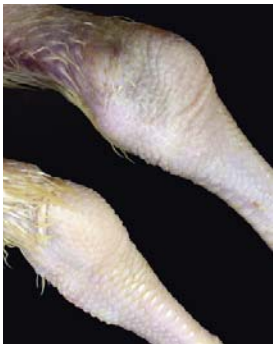
Fig. 69.35 & 69.36: The differential diagnosis of arthritis also includes hemarthrosis. Hock hemarthrosis in a 22 day-old poult (Fig. 69.35) and femoral head hemarthrosis in a three week-old chicken (Fig. 69.36, compared with a normal femoral head on right).

Fig. 69.37: Osteomyelitis (5 week-old chicken).

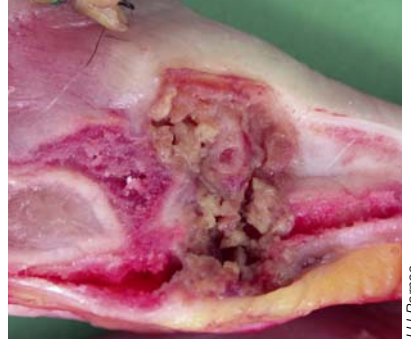
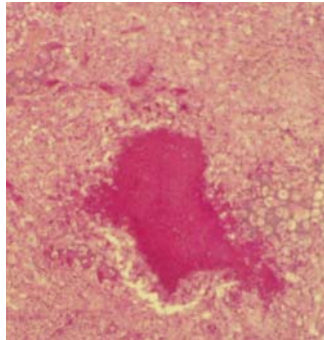
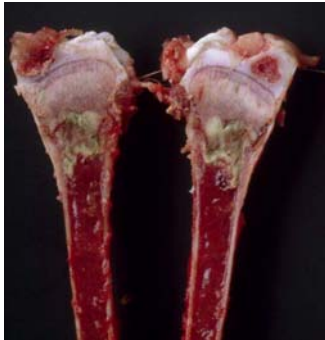
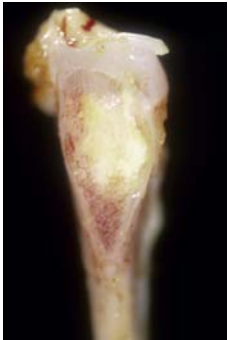
Fig. 69.38, 69.39 & 69.40: Osteomyelitis observed in turkey poults. Bacterial granuloma observed on histological examination of the bone marrow (hematoxylin & eosin).

Fig. 69.41: Necrotic osteomyelitis of the costochondral region.

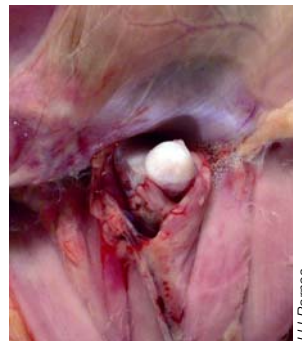
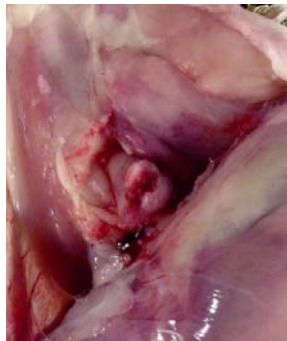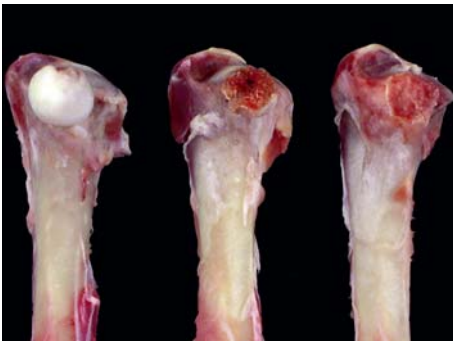

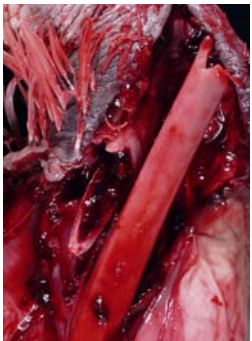
Fig. 69.42. Pathological fracture (Turkey).

Fig. 69.43, 69.44 & 69.45: Necrosis of the femoral head in 45 week-old turkeys (Fig. 69.43, compared with the normal femoral head on left) and in chickens (Fig. 69.44, compared with the normal femoral head of a chicken, Fig. 69.45).

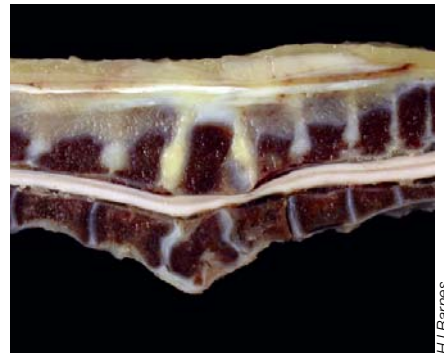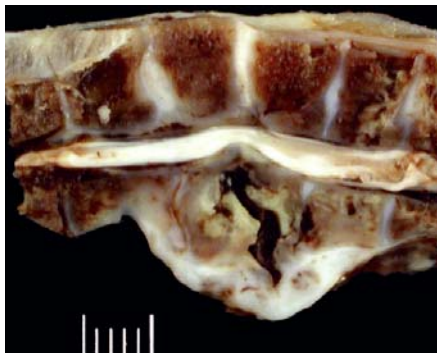

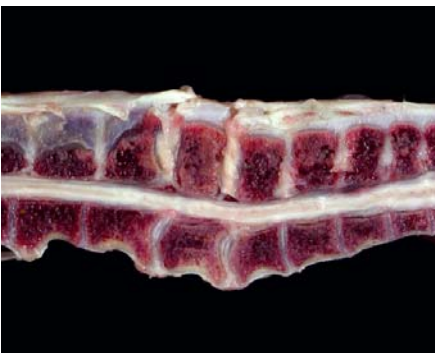
Fig. 69.46, 69.47 & 69.48: Spinal osteomyelitis and spondylolisthesis (Chicken). In comparison with a normal back seen in Fig. 69.46, spinal osteomyelitis compresses the spinal cord (Fig. 69.47). This condition must be differentiated from spondylolisthesis observed in a 40 day-old chicken and caused by the displacement of the T₄ vertebra (Fig. 69.48).

- inadequate flock management and environmental conditions (causing chronic stress and/or joint and tendon trauma);
- chronic debilitating diseases, such as coccidiosis;
- inadequate skeletal growth during the first six weeks leading to poor conformation and excessive load on the tendon and joints.

Probably the most common cause is an inadequate diet or feeding regimen with or without the immunosuppressive stress induced by poor water supply conditions. Outbreaks of tendinitis may occur whether flocks have been vaccinated or not with a killed or live reovirus vaccine.

Amyloidosis

Amyloidosis is characterised by the deposition of proteinaceous material between cells in various tissues and organs of the body. Brown egg-laying chickens are particularly susceptible to amyloid arthropathy associated with *Enterococcus faecalis*. Other bacteria such as *Escherichia coli*, *Salmonella* Enteritidis, *Staphylococcus aureus*, *S. hyicus* and *Mycoplasma gallisepticum* also have been implicated. Another condition in which amyloidosis is encountered is hepatitis E infection (see Chap.II.38). There is no treatment for amyloidosis but prevention of chronic infections or stress in birds reduces its incidence.

NON INFECTIOUS MUSCULOSKELETAL DISEASES

Knowledge of normal bone morphology and how it changes during growth is required to understand the pathogenesis of bone abnormalities. A long bone includes a diaphysis with, at each end, a metaphysis, a growth plate (physis) and an epiphysis covered by a layer of articular cartilage. The avian growth plate is more irregular than in mammals. Long bones grow by endochondral ossification: within the growth plate, there is chondrocyte proliferation and hypertrophy. The cartilage matrix of the hypertrophic chondrocytes is then mineralized, removed and replaced by bone. Considerable variation in thickness is seen between growth plates in the same bird because of differences in bone growth rate.

Non-infectious musculoskeletal disorders include mainly nutritional diseases (osteodystrophies) or multifactorial conditions (hereditary and/or congenital affections, feed and environment) as well as muscular or cutaneous disorders.

Osteodystrophies

These conditions have a nutritional origin: vitamin D, biotin, riboflavin, manganese, folic acid, niacin, pyridoxine and/or pantothenic acid or calcium/phosphorus imbalance (Ca:P/1:2). This leads to impaired bone development with deformation and greater fragility. Sometimes it is not inadequate feed intake but rather the result of an intestinal malabsorption syndrome or the presence of indigestible chemical compounds in the diet. It can be an enteropathy such as chronic coccidiosis, a functional insufficiency of the pancreas or liver or excess intake of lipids reducing the intestinal absorption of Ca.

To maintain a constant level of calcium in the blood, the body has two homeostatic mechanisms: intestinal absorption and release of minerals stored in the bones. The calcium in the diet can only be absorbed through the intestines by means of the vitamin D₃. Hypocalcemia triggers the homeostatic mechanism of calcium release from the bone by stimulating the release of the parathyroid hormone bringing, from bone marrow monocytes, the formation of osteoclasts, which are polynuclear giant cells that demineralize the bone by the process of osteoclasts. These osteoclasts destroy bones under several circumstances: when it is necrotic; as part of the physiological processes ensuring the maintenance of calcium blood levels; bone remodeling or resorption of medullary bone to ensure eggshell mineralization in hens. If osteoclasts exceeds osteogenesis, the bone becomes porous, brittle and fragile.

Some nutritional subcarences can cause nonspecific, and often underestimated, osteodystrophies due to the absence of clinical signs. Osteodystrophies of nutritional origin are mainly osteoporosis in laying hens associated with the excessive loss of calcium due to eggshell mineralization, and rickets or osteomalacia caused by vitamin D deficiency.

Osteoporosis

Osteoporosis in laying hens is defined as a decrease in normal mineralization of structural bone (osteopenia), resulting in increased fragility and susceptibility to fractures. The condition, observed for the first time in caged laying hens with brittle bones and unable to stand, was called «cage layer fatigue». Bone fragility is responsible

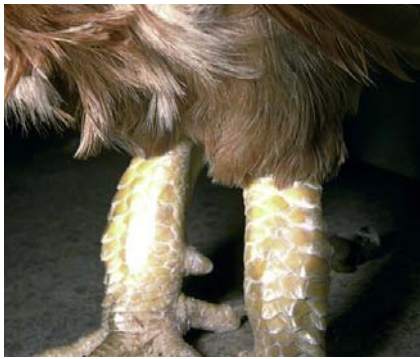

Fig.69.49: Osteopetrosis. The condition can be symmetrical or unilateral and involves mainly the tarsometatarsus and the tibiotarsus.

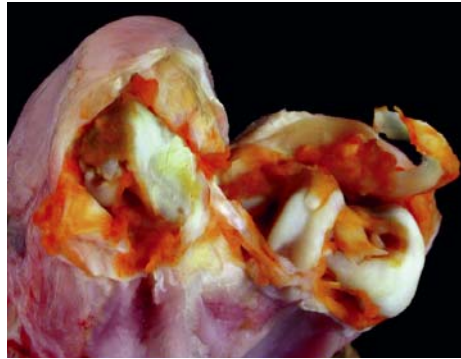


Fig.69.50: Amyloid arthropathy (35 week-old broiler breeder hen).

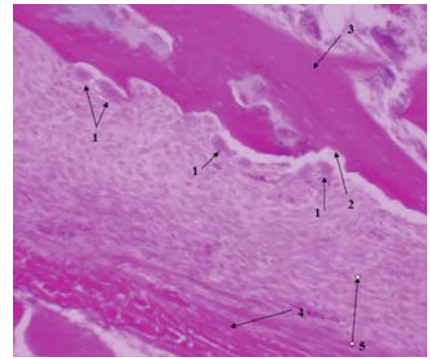


Fig.69.51: Osteoporosis. Osteoclasts (1) attack the bone and leave a cavity (Hawship's lacunae) (2). Osteoclastic bone resorption causes excessive bone mass loss (3) and an increase in osteogenic periosteal layer (5) limited by a fibrous casing (4).



Fig.69.52: 26 week-old hen in sternal recumbency. Cage layer fatigue is associated with osteoporosis.

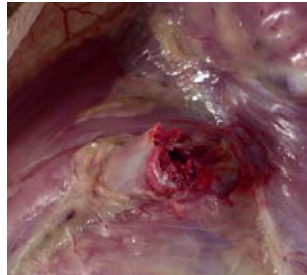

Fig.69.53: Femur osteoporosis (42 day-old pullet).

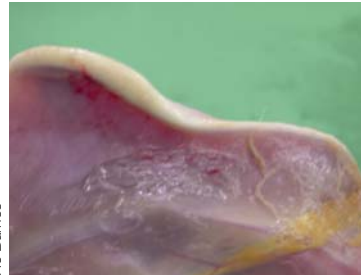

Fig.69.54 & 69.55: Osteoporosis. Deformation of sternum (left). Eggs with soft or brittle shell (right).



Section IV

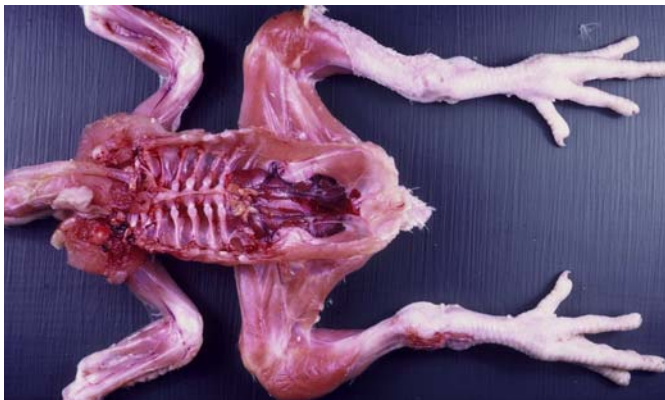


Fig.69.56: Rickets (Chicken). The enlarged joints and «costal beads» are characteristic.

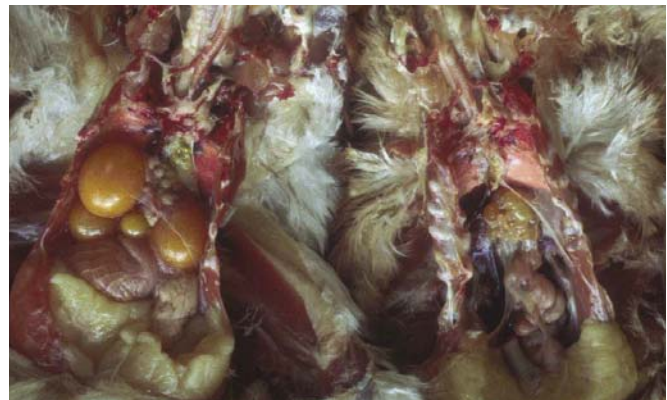
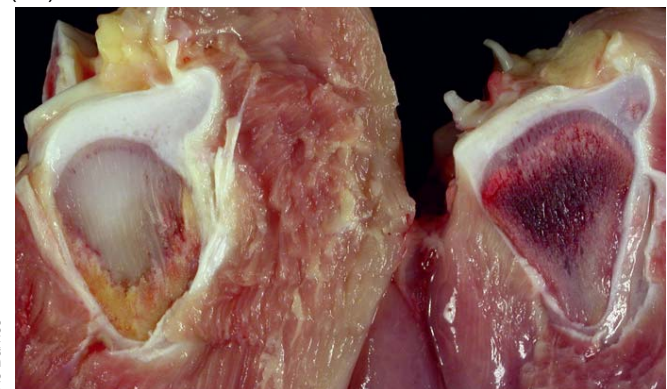


Fig.69.57: Osteomalacia (Hen). Collapse and infolding of ribs and involution of the ovary (right). Compared with a normal hen (left).

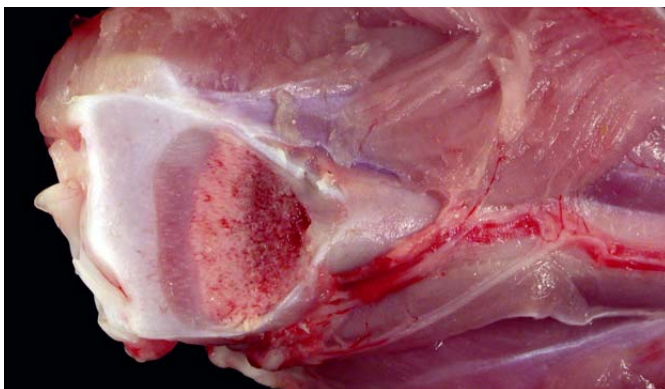

Fig.69.58 & 69.59: Tibiotarsus lesions (rickets and chondrodystrophy). Chronic rickets (4 week-old turkeys) in fig.69.58 with thickening zone of proliferation of the growth plate and accumulation of non-mineralized cartilage. In Fig.69.59, compare a normal bone (right) with dyschondroplasia (left) where, unlike rickets, mineralization and the growth area remain unchanged.



for up to 30% of fractures in commercial flocks. The incidence may reach up to 90% during catching, transportation and processing.

There are multiple factors associated with osteoporosis: excessive production and consequently loss of calcium for eggshell formation; calcium, phosphorus and vitamin D deficiencies; age, genetics, laying cages, etc.

The main clinical signs are a prostration or paralysis in severe cases, a drop in egg production, very thin and fragile eggshell or soft-shell and low hatchability. The bones become porous due to the demineralization process related to the osteoclasts occurring to restore normal serum calcium levels. The parathyroid glands are enlarged, the breast is deformed, the bone cortex is thin, the ribs may be deformed by small fractures, the bones become brittle and fractures are common even in the absence of a real trauma. Hens remain prostrated either after paralysis due to a fracture or a displacement of the T₄ vertebra damaging the spinal cord, or due to the pain caused by bone demineralization. Many birds have regressive ovaries and are dehydrated, while some birds die suddenly with an egg in the oviduct.

Good skeletal development is important in layers, particularly in the first 6 weeks of life. If excessive Ca is provided before it is necessary, the bird's metabolism may, for a period of time, be refractory to Ca absorption when it is most needed. Therefore, Ca intake must not be excessive during the growing period. Calcium demands from bone origin should be expected two weeks before the first egg is laid (coinciding with the onset of follicular activity and the rise in oestrogen levels). Sources of Ca that enable the slow release of Ca, such as oyster shell in the diet, are recommended.

Rickets (see Chap.IV.71)

In rapidly growing chicks and poults, vitamin D₃, Ca and/or P deficiencies or imbalances result in rickets. A malabsorption syndrome can cause this disease, as well as an imbalance between dietary Ca and P. Subclinical rickets may frequently go unreported but may be associated with poor chick/poult performance, a poorer gait and an increase in bone deformities. Efforts to reduce environmental P contamination in poultry litter by reducing P levels in the diet have increased the incidence of hypophosphatemic rickets. In cases of Ca and vitamin D₃ deficiency, the parathyroid

glands are hyperplastic and the zone of proliferation in the growth plate is thickened with a weak and irregular invasion of cartilage. In cases of P deficiency, the parathyroid glands are small and there is a prominent zone of hypertrophic cartilage with normal vascularisation.

Beaks, claws, bones and the sternum become soft and flexible, due to a lack of mineralization. The joints are enlarged (beading of costochondral joints, known as "rickety rosary"). Birds tend to spread their legs and stay immobile.

Osteomalacia

In laying birds, moderate vitamin D₃ deficiency causes osteomalacia giving also osteoporosis. The bones are light, porous and fragile. Egg production can stop and eggshells are soft and thinner. A reduction in hatchability and an increase in embryonic mortality are observed.

Diseases of the skeletal system of multifactorial origin

Although a genetic component is often a consideration due to the exceedingly rapid growth of modern breeds, it is often difficult to pinpoint the specific cause of bone, ligament, or tendon defects or abnormalities. Other environmental and nutritional factors influence the onset or severity of these various diseases.

Chondrodystrophy

Chondrodystrophy is characterized as a general disorder of the growth plates of long bones that eventually impairs their extension while mineralization and appositional growth remain unchanged. It is distinctly different from rickets where mineralization is impaired. In the past, the condition was called perosis (which is now specifically linked to the condition «slipped tendon»).

Chondrodystrophy was first described as «Turkey syndrome 65» in 1965 in the UK. This syndrome was attributed to *Mycoplasma meleagridis* infection. This *Mycoplasma*, as others (*M. gallisepticum* and *M. iowae*), impairs the supply of nutrients to the growth plate of the cartilage, leading to chondrodystrophy. Other factors are suspected: deficiencies (manganese, choline, niacin, vitamin E, folic acid and pyridoxine), genetics, very high brooding temperatures, etc.

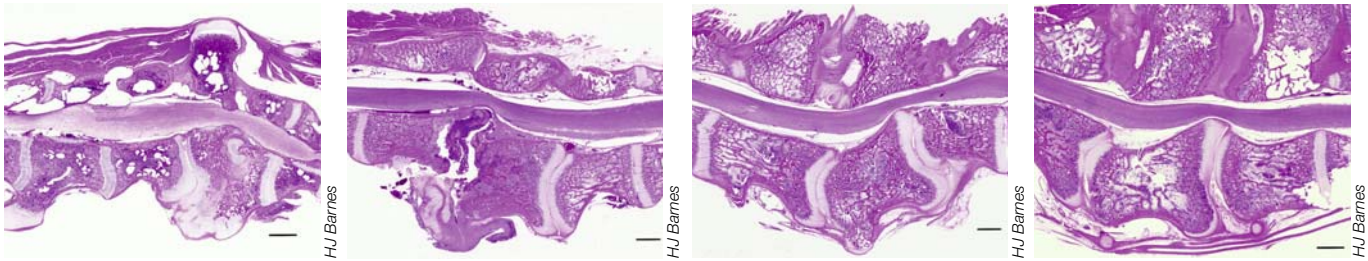


Fig.69.60, 69.61, 69.62 & 69.63: Spinal chondrodystrophy (Fig.69.60) causing paresis or paralysis is difficult to differentiate clinically from a spinal abscess (Fig.69.61), spondylolisthesis (Fig.69.62) or any syndrome with pinching of the spinal cord (Fig.69.63).

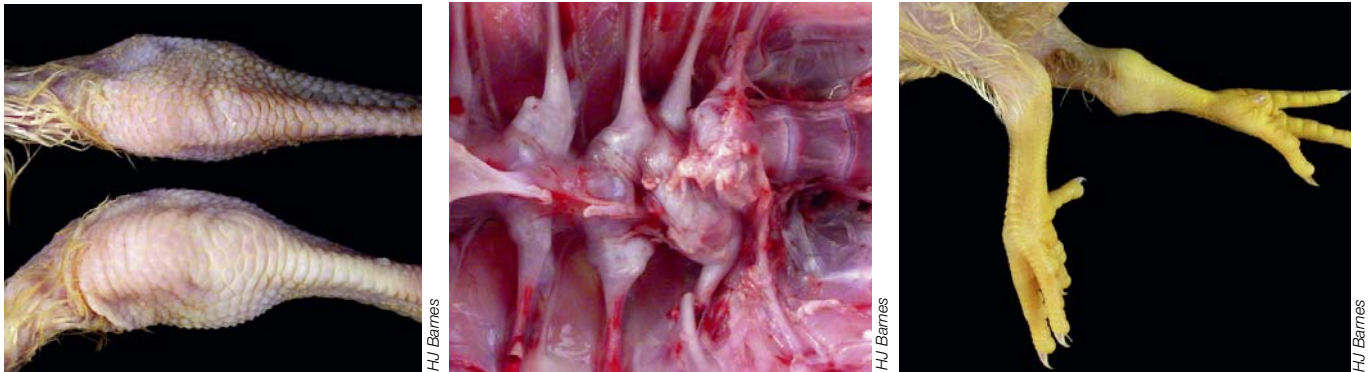

Fig.69.64: Articular chondrodystrophy (normal joint top). Fig.69.65: Spinal chondrodystrophy. Fig.69.66: Valgus (8 day-old chick).

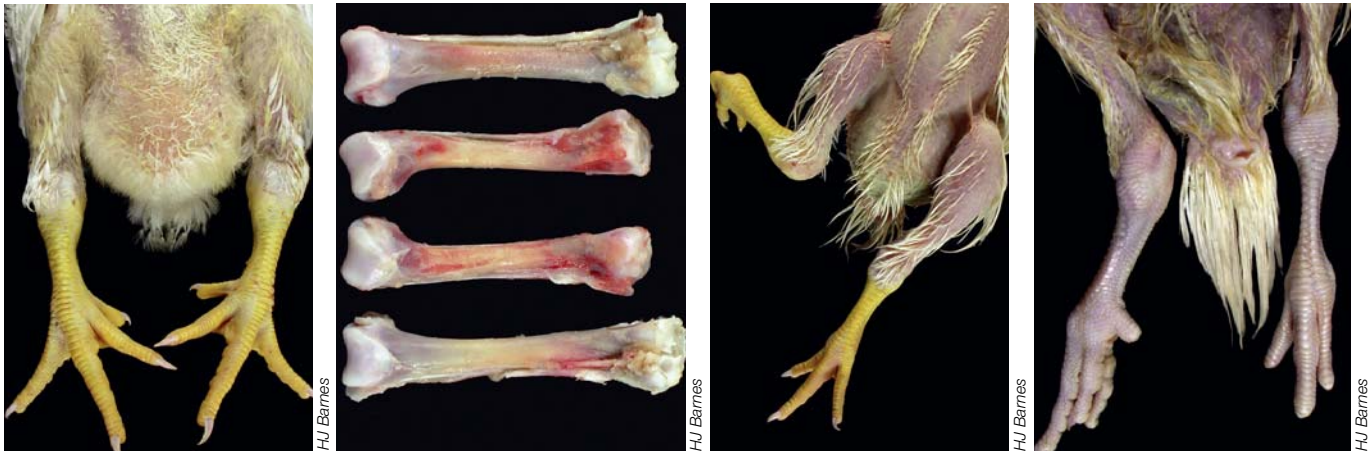

Fig.69.67 & 69.68: Bilateral varus deformity (Chicken). Comparison with the more elongated and undistorted normal bones. Fig.69.69 & 69.70: Tibial rotation in a five week-old chicken (left) and a 15 day-old turkey (right). Tibial rotation must be differentiated from displacement of the gastrocnemius tendon because the tendon remains in place in most cases of tibial rotation.

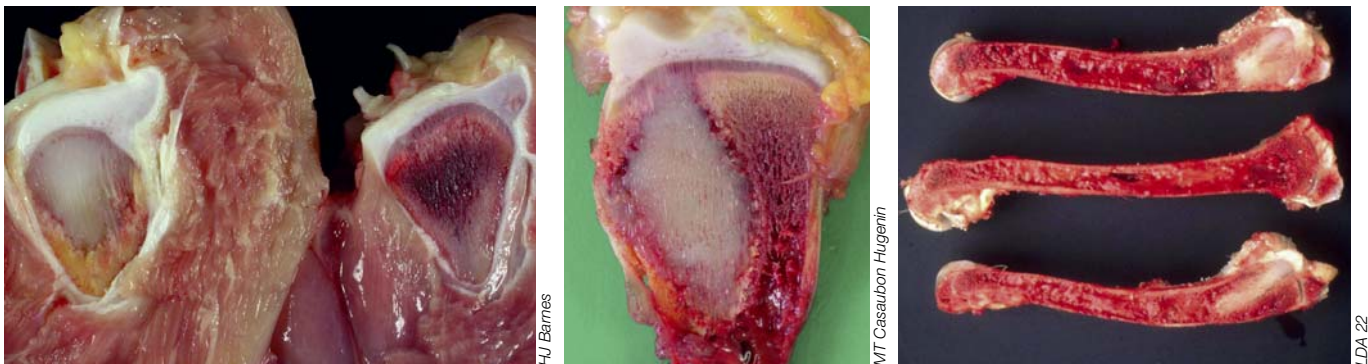


Fig.69.71, 69.72 & 69.73: Tibial dyschondroplasia (Chicken). A cone of abnormal cartilage forms in the metaphysis. This condition is most common in the proximal tibiotarsus and tarsometatarsus. Compare with normal bone (on right in fig.69.71 and in the middle in fig.69.73). If the abnormal mass of cartilage is small, the condition will be subclinical. However, more severe lesions are accompanied by marked anterior and lateral bowing of the tibiotarsus causing abnormal gait or lameness. The bone may fracture spontaneously or at processing. Occasionally, necrosis develops around the cartilage plug.

Chondrodystrophy results in short, thick and usually misshapen long bones and enlargement of the hock joint. It can lead, as a secondary response, to valgus or varus deformation. In severe cases, displacement of the gastrocnemius tendon may occur.

Angular (valgus-varus) deformity & tibial rotation

Valgus (or *varus*) deformity is a long bone distortion of the distal tibiotarsal joint frequently found in broilers and turkeys. The lesion may already be present at hatching. Affected birds are mainly males. *Valgus* deformities are more frequent than varus deformation. When angulation is severe, the birds walk with difficulty. Birds with severe angulation hardly move, remaining on their hocks, causing skin lesions and leading to carcass condemnations at the slaughterhouse. Although angular deformity is the most prevalent problem, tibial rotation is also occasionally observed. Tibial rotation must be differentiated from slipped tendon, because the tendon normally remains in place with this rotation.

Tibial dyschondroplasia

Tibial dyschondroplasia occurs as an abnormal persistent accumulation from the growth plate in which maturation of prehypertrophic and hypertrophic chondrocytes is retarded or stunted. The failure to remove the cartilage can happen either in a portion of the growth plate or in the entire growth plate in the most severe cases. The cause is multifactorial: genetic selection (rapid growth is the major cause of tibial dyschondroplasia), inadequate calcium/phosphorus ratio in the diet, metabolic acidosis through excess chloride in feed, and incorrect acid-base balance. Other conditions, such as mycotoxicosis, will also cause tibial dyschondroplasia. Dyschondroplasia can be observed in other bones than the tibia.

Spondylolisthesis

Spondylolisthesis of broiler chickens is characterized by a posterior paresis and paralysis due to the displacement of the fourth thoracic vertebra resulting in a pinched spinal cord. This condition, also named «kinky back», is considered to be a developmental problem influenced by conformation and rapid growth rate.

Degenerative joint disease

Degenerative changes in coxofemoral, femoro-tibial or intertarsal joints can be seen in mature male turkeys and in mature meat-type chickens. The spine of laying hens can also be affected. Degeneration of the articular cartilage causes pain and lameness.

Spontaneous bone fracture

Bone fractures are one of the causes of downgrading and trimming of poultry carcasses at slaughter, particularly leg fractures. Clinically, leg fractures cause lameness and increased mortality. To minimize the incidence of fractures, care should be taken when catching birds before shipping to the slaughter plant.

Spraddle or splay legs

Spraddle or splay legs occur in young birds (from hatching to two weeks of age) that are on slippery surfaces (e.g., cardboard).

Diseases of tendons

Perosis (slipped tendon)

Perosis is a subluxation of the gastrocnemius tendon and is secondary to long bone shortening caused par growth plaque damage (chondrodystrophy) following nutritional deficiencies, particularly in manganese. Biotin, folic acid, niacin and pyridoxin deficiencies may also be involved. In early cases, the hock is flattened, widened, and slightly enlarged. In advanced cases the distal portion of the hock deviates sharply from its normal position, usually laterally.

Rupture of the gastrocnemius tendon

Lameness due to the rupture of the gastrocnemius tendon causes considerable economic losses in broiler breeder chickens older than 12 weeks (sometimes as early as 7 weeks of age). This rupture is associated with tenosynovitis but in many cases the rupture appears to have a non-infectious origin. A bilateral rupture leads to a characteristic hock sitting posture with toes directed ventrally, with the birds using their wings to get around. Large hematomas with degraded hemoglobin turning the skin green over the lesion are at the origin of the nickname «green legs» for this disease.

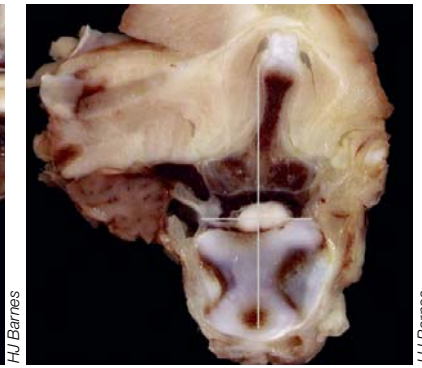
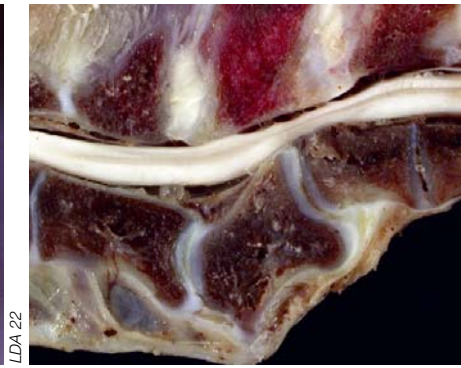


Fig.69.74 & 69.75: Spondylolisthesis (Chicken). Affected birds are ataxic or may assume a hock-sitting posture with their feet slightly raised off the ground and they use their wings to move. Spondylolisthesis can affect 2% of broilers between 3 and 6 weeks of age in some flocks.

Fig.69.76: Spinal rotation (58 day-old chicken).

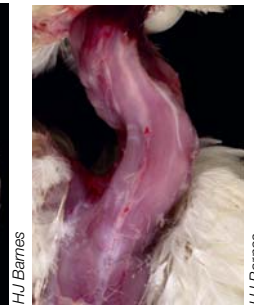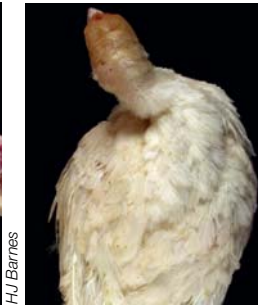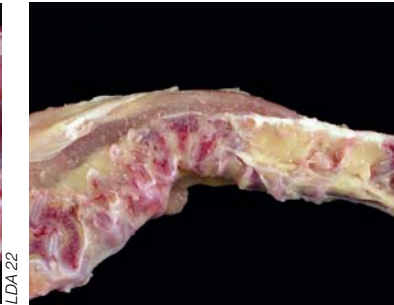


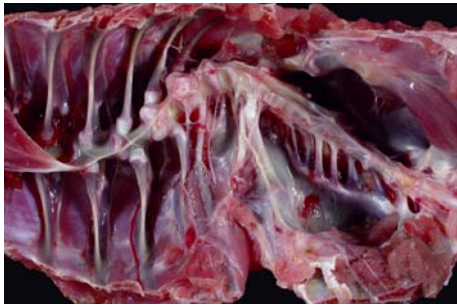Fig.69.77, 69.78, 69.79 & 69.80: Other spinal deformities can occur sporadically in commercial poultry: scoliosis (Fig.69.77, 27 week-old broiler breeder rooster), lumbar kyphosis (Fig.69.78, Chicken), wry neck (Fig. 69.79 & 69.80, 30 day-old turkey).

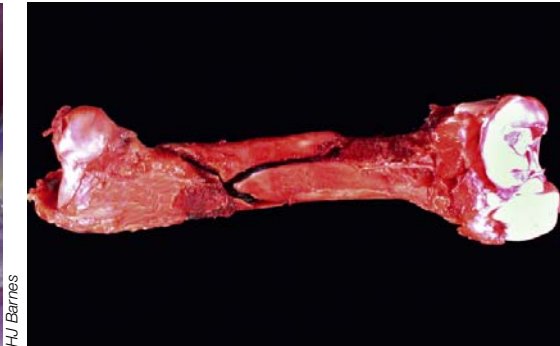
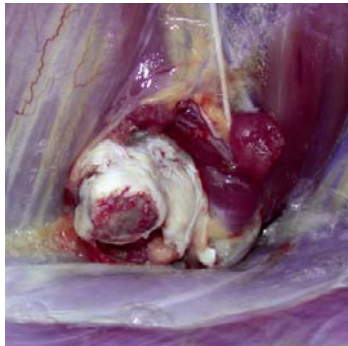
Fig.69.81: Degenerative coxofemoral joint disease (62 week-old broiler breeder). This condition may result from primary damage to the articular cartilage or as sequelae of osteochondrosis.

Fig.69.82: Pathologic fracture (turkey femur). Fracture may occur spontaneously or during catching or transportation. Osteoporosis is the main predisposing factor. Growing males, with a more porous cortex, may be more susceptible than females.

Fig.69.83: Spraddle or splay legs (Chick). This lateral deviation of the legs (at the knee and sometimes at the hip) may be unilateral or bilateral.

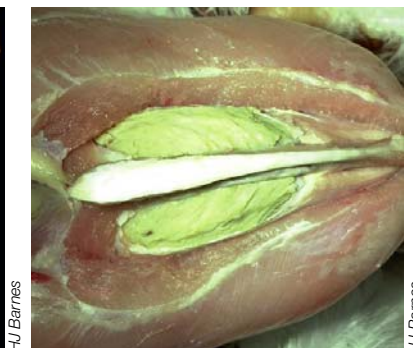
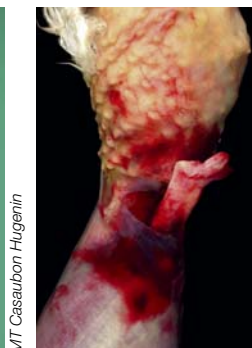
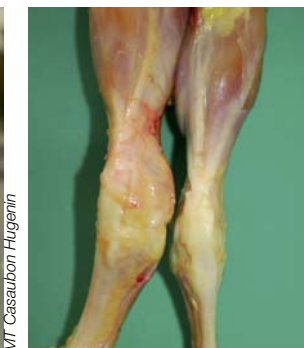Fig.69.84 & 69.85: Perosis (slipped tendon). In early cases the hock is flattened, widened, and slightly enlarged. In advanced cases the leg from the hock distally deviates sharply from its normal position, usually laterally. The gastrocnemius tendon has slipped from the trochlea.

Fig.69.86: Rupture of the gastrocnemius tendon (31-week-old breeder hen).

Fig.69.87: Deep pectoral myopathy (green muscle disease). At first the muscle is edematous and hemorrhagic before becoming green. The lesion may be unilateral or bilateral.

Ligament failure and avulsion

Lameness can also be attributed to lesions of the capital femoral ligament, posterior cruciate and other ligaments of the femoro-tibial joint or inter-tarsal joint of broilers and turkeys. These ligament ruptures are often due to trauma.

Diseases of muscles

Muscular dystrophy (vitamin E-selenium deficiency) (see chap.IV.71)

Deep pectoral myopathy (Oregon disease) (see Chap.V.75)

This lesion results from ischemia of the supracoracoid muscle followed by necrosis after a strenuous exercise, such as excessive wing flapping. This is more likely to be found at slaughter in heavy birds. Predisposition to this condition may be related to inadequate muscle vasculature, but not to body weight or breast width.

Ionophore toxicity

Ionophore toxicity causes a severe myodegeneration of the adductor leg muscle, resulting in reluctance to walk and lameness. Problems are seen with ionophore-based coccidiostats as a consequence of feed mixing errors. Tiamulin may potentiate the myodegeneration properties of ionophores.

Pododermatitis (see Chap.IV.71)

The pain associated with this local footpad injury results in lameness and reluctance to move.

Complications include sternal bursitis, arthritis, osteomyelitis and/or tendinitis.

REFERENCES

- Casaubon MT. Patología aviar- Aparato esquelético. <http://www.medvet.umontreal.ca/etudes/enseignement-ligne/patho%5Faviaire/Aparato%5Fesqueletico/index.asp>
- Crespo R & Shivaprasad HL. Developmental, metabolic and other noninfectious disorders. In "*Diseases of poultry*", Ed. Swayne DE, 13th ed., Wiley-Blackwell Publ. 2013, pp 1233-1270.
- Julian RJ & Riddell C. Noninfectious disorders of the skeleton of domestic chickens and turkeys. *Slide study set # 8*, AAAP,1996.
- Julian RJ. Production and growth related disorders and other metabolic diseases of poultry – A review. *The Vet J.* 2005,169:350-369.
- Klein-Hessling H. Chondrodystrophy in turkeys and broilers. *World Poultry*, 2006,22,:35-36.
- Lescoat P et al. Lois de réponses des volailles de chair à l'apport de phosphore. *INRA Prod. Anim.* 2005:18, 193-201.
- Leterrier C et al. Troubles locomoteurs et qualité osseuse chez les volailles de chair. *INRA Prod. Anim.* 1998,11:125-130.
- Mongin P & Sauveur B. Interrelationship between mineral nutrition, acid-base balance, growth and cartilage abnormalities. In "*Growth and poultry meat production*". Boorman KN & Wilson BJ eds. *Bri Poultry Sci*, Edinburgh, 1977, pp 235-247.
- Shivaprasad HL. Nutritional diseases. In "*Avian diseases manual*". Ed. M. Boulianne. 2013, pp184-192.
- Teegarden D et al. 2000. Characterization of a 25-hydroxyvitamin binding protein from intestinal cells. *Biochem. Biophys. Res. Comm.* 275:845-849.
- Thorp BH. Diseases of the muscular system. G. In "*Poultry diseases*" sixth edition Saunders Elsevier 2008, p 470-489.

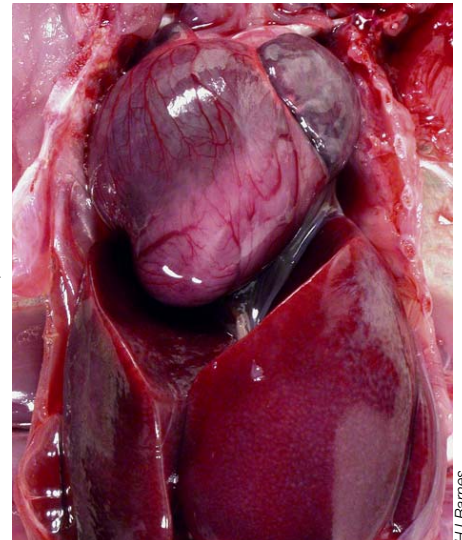
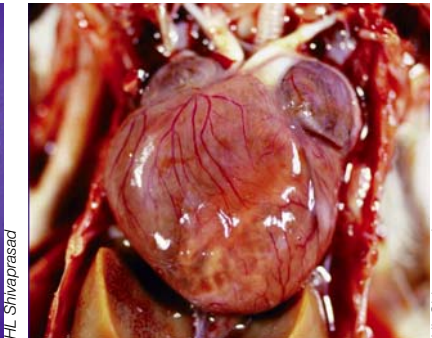
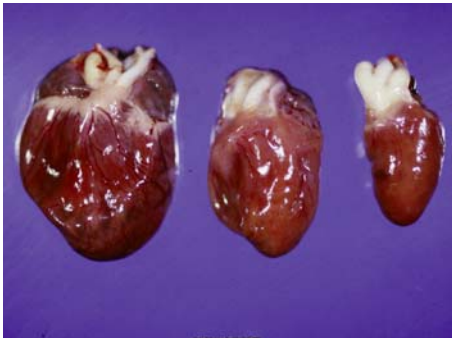


Fig.70.1: Different degrees of dilated cardiomyopathy (DCM) or round heart disease in two-week-old turkey poults compared to normal heart on the right.

Fig.70.2: Severe DCM in a 7-week-old turkey.

Fig.70.3: Round heart disease in a 16 day-old turkey found dead. Note the general enlargement of the heart, especially the right side. Poult also has enlarged liver and ascites.

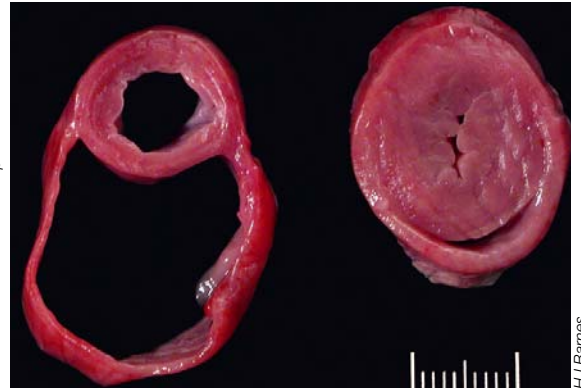
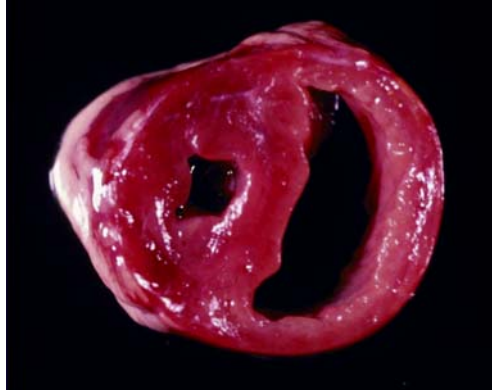
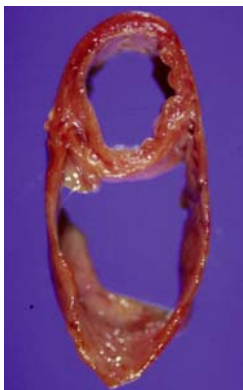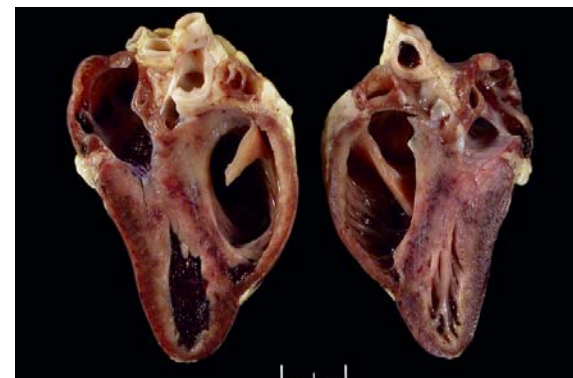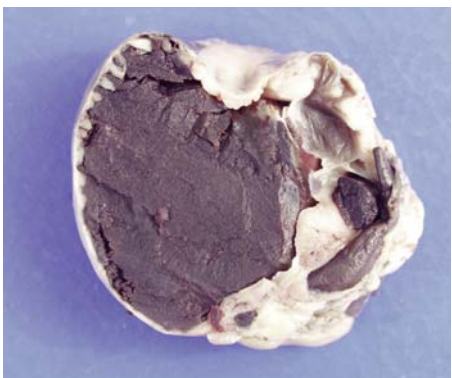Fig.70.4: Severely dilated left and right heart in a 4 week-old turkey with DCM.

Fig.70.5: Severe hypertrophy of right ventricle in a broiler chicken with ascites syndrome.

Fig.70.6: DCM (6 week-old turkey culled because small size and difficulty getting to food and water). Transverse section through the enlarged heart showing dilatation and hypertrophy particularly of the right ventricle compared with a transverse section of a normal heart on right.



70.7: DMC (transverse cross section of fixed heart). Hypertrophy of the right ventricle at later stage with an extremely thinned wall.

Fig.70.8: PHS (39 day-old broiler found dead). The right heart is distended and there were extensive fibrin clots in the abdomen. Ascites was present but did not completely fill the body cavity.

Fig.70.9: Characteristic penguin posture in birds suffering from ascites.

Section IV

Other diseases

70. CARDIOVASCULAR DISEASES

INTRODUCTION

Many cardiovascular diseases are important causes of death in poultry and other species of birds: dilated or spontaneous cardiomyopathy, also called round heart disease, aortic rupture, sudden death syndrome in turkeys and pulmonary hypertension leading to right ventricular failure, also called ascites syndrome in chickens. Other cardiovascular diseases also occur in association with systemic or local disease caused by infectious, nutritional, toxic or unknown causes.

CARDIAC DISEASES

Dilated cardiomyopathy in turkeys (round heart disease)

Dilated cardiomyopathy (DCM) has commonly been called round heart disease. It is a sporadic condition and occurs wherever turkeys are raised.

Etiology & pathogenesis

The cause of dilated cardiomyopathy (DCM) is not known. But the condition has been strongly associated with genetics. It has been suggested that selection pressure for rapid growth in turkeys exhibit differences in gene expression during the development of the heart predisposing the turkeys to DCM. The underlying biochemical change is the abnormal structure of troponin T, an essential protein in the Ca^{++} regulation of striated muscle during contraction. DCM in turkeys has been used as a model to study DCM in humans. Incidence of DCM increases in rapid growth poults as well as with altitude and cold weather. DCM has also been associated with hypoxia during incubation. Furazolidone is toxic for turkey poults in concentrations as low as 300 ppm in the feed, and produces a syndrome that is similar to DCM.

Clinical signs & lesions

The highest rate of mortality due to spontaneous DCM occurs in young poults, commonly peaking at 2 weeks of age and decreasing at 3 weeks of age. But DCM can be seen in some flocks up to 10-12 weeks of age. Mortality in flocks ranges from 0.5% to 3.0% and occasionally up to 22.0%. DCM affects both male and female poults but males are more susceptible. Affected poults may die sud-

denly or slowly develop the cardiomyopathy. The affected birds are markedly smaller than their flock mates, with ruffled feathers, cyanosis and dyspnea.

On post-mortem examination, affected young turkeys can have mild to severely enlarged hearts due to dilatation of the right ventricle or both ventricles. Often, the right ventricle is more dilated than the left and rounded apex may be present. Hydropericardium and ascites may or may not be present in all cases. All organs are markedly congested including acute or chronic passive congestion of the liver and pulmonary edema and congestion. Microscopically, except for increased myofiber size there are no significant changes in the heart. But liver can have lesions ranging from vacuoles in the cytoplasm of hepatocytes diffusely scattered throughout to centrilobular degeneration and necrosis of hepatocytes in acute stages and fibrosis in chronic stages.

Treatment & control

There is no treatment for DCM. A lighting program designed to reduce growth rate at an early age reduced the incidence of spontaneous cardiomyopathy.

Dilated cardiomyopathy or round heart disease in chickens

This condition is probably similar to DCM of turkeys but its incidence has decreased in recent years. Round heart disease is an acute cardiac failure due to myocardial degeneration in chickens commonly between 4 and 8 months of age. Hearts of affected chickens are pale and enlarged, with hypertrophy confined to the left ventricle. The apex of an affected heart may be dimpled.

Pulmonary hypertension or ascites syndrome in broiler chickens

Pulmonary hypertension syndrome (PHS), also known as ascites syndrome, occurs worldwide and is a significant cause of mortality in many broiler flocks.

Note that ascites is a sign or lesion that may result from one or more of four physiological changes that cause an increased production or decreased

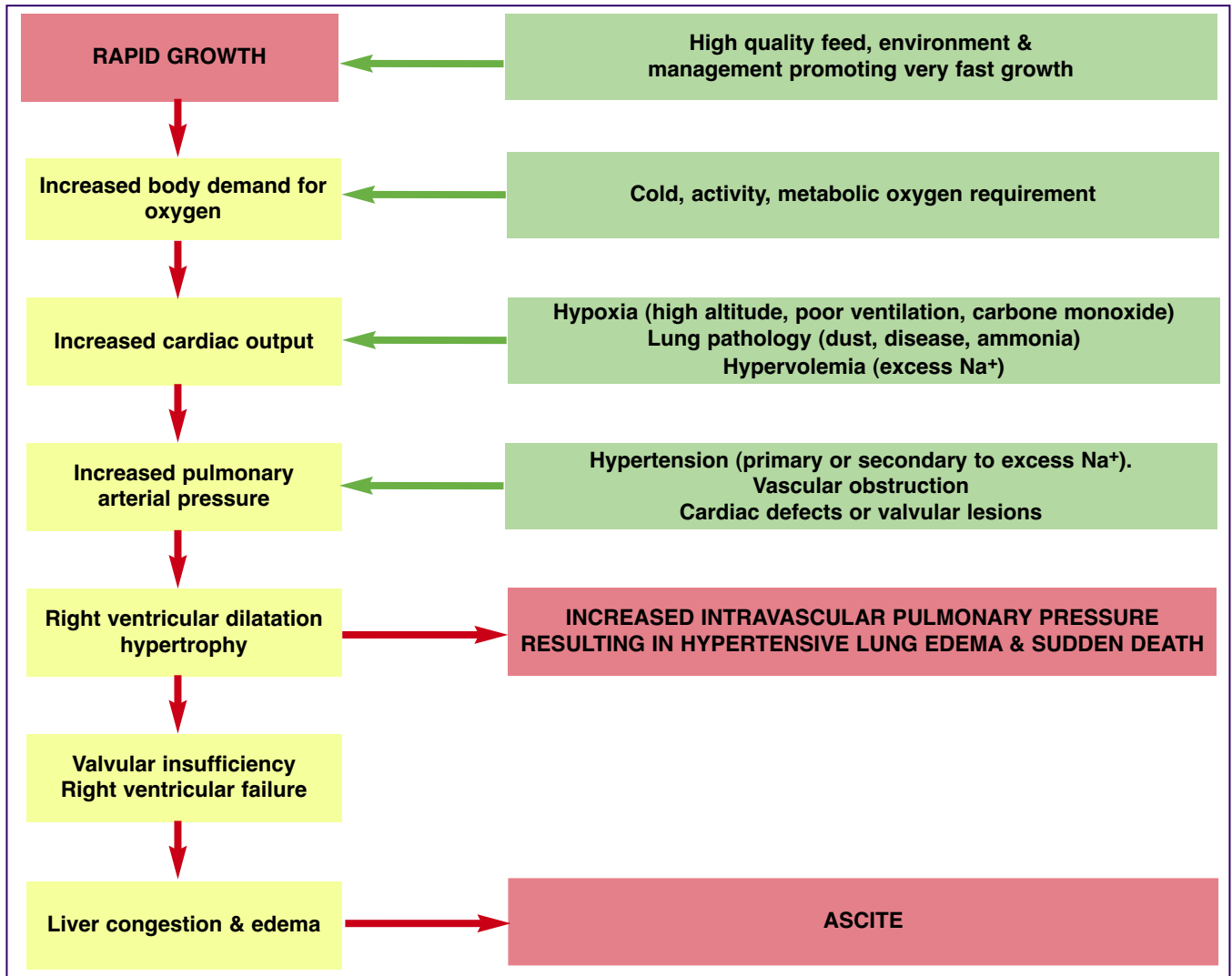


Fig.70.10: Physiopathology of PHS and ascites (adapted from Julian, 1987).

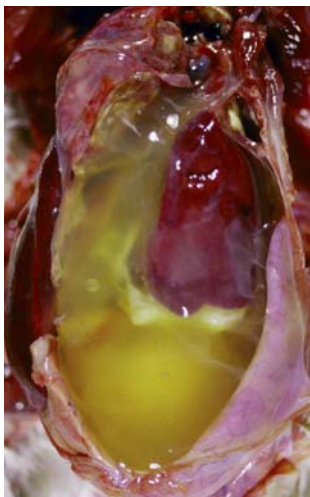


Fig.70.11: PHS. Severe ascites in a 3 week-old broiler chicken with ascites syndrome.

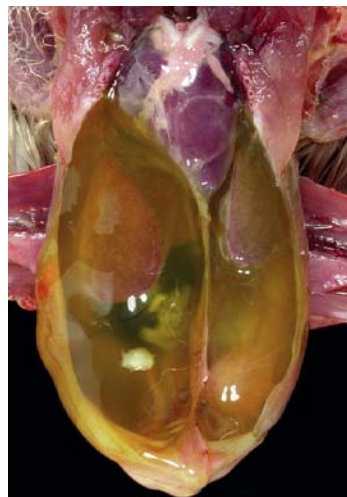

Fig.70.12: PHS (18 day-old broiler chicken). Right heart failure with enlarged heart (right heart dilation), massive ascites (ascitic fluid had clotted), shrunken liver with rounded margins, and generalized congestion.

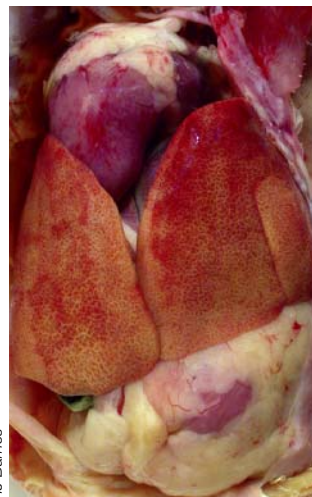


Fig.70.13: PHS (27 day-old broiler). Ascites, hydropericardium, hepatic degeneration, and large retained yolk sac. Note the classic "nut-meg liver" typical of chronic passive congestion due to right-sided heart failure.

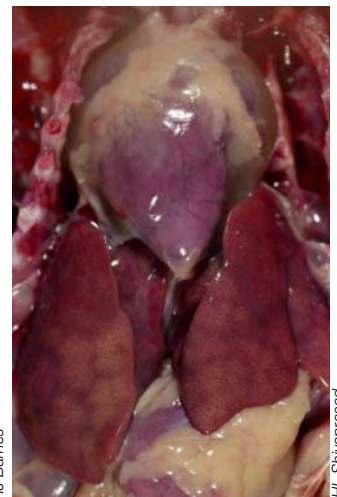


Fig.70.14: PHS. Hydropericardium and passive congestion of the liver (note irregular surface) in a broiler chicken with ascites syndrome.

removal of peritoneal lymph. Ascites may result from (1) obstruction of lymph drainage as occurs in peritoneal carcinomatosis secondary to carcinoma of the ovary and occasionally of the oviduct, (2) decreased plasma oncotic pressure (as occurs in anaemia or hypoproteinaemia), (3) fluid leakage secondary to increased vascular permeability following oxidative or chemical damage, but by far the most frequent cause of ascites in birds is (4) increased portal pressure, secondary to right ventricular failure (RVF) or liver damage. As RVF can cause liver damage, the heart should always be examined carefully for evidence of RVF to separate the two causes of ascites that occur because of increased portal pressure.

Etiology & pathogenesis

PHS was first reported in flocks of broiler chickens reared at high altitude in South America but it is now described worldwide at low altitude. The pathogenesis of ascites syndrome secondary to right ventricular heart failure and associated to PHS is multifactorial (see Fig.70.10). Experimentally the two major factors that increase the incidence of PHS are hypoxia and increased metabolic rate. In the field the most important environmental factors are high altitudes and cold temperatures. Genetic susceptibility may explain that modern broiler chickens are more susceptible to hypoxia because of its small lung relative to its body size, thicker blood-gas barrier, and larger and less deformable red blood cells.

Clinical signs & lesions

Affected birds are smaller than normal and listless with ruffled feathers and pale shrunken comb. Severely affected birds have abdominal distension, may be reluctant to move and are dyspnoeic and cyanotic. Some birds may die suddenly before ascites develops. At necropsy, an accumulation of straw-colored ascitic fluid with or without fibrin clots can be observed in the abdominal cavity. There is a marked hypertrophy and dilation of the right ventricle which might also have evolved into a bilateral hypertrophy and dilation depending on the age and severity of the condition. Hydropericardium may be present. Lesions in liver vary from congested or mottled to shrunken with a grayish capsule and irregular surface. Lungs are congested and edematous. In addition thickening of the aortic and atrioventricular (AV) valves (valvular endocardiosis) including the right AV valve can be found. Microscopically the lesions in the heart, liver and lungs are similar to DCM of turkeys.

Treatment & control

There is no treatment but the condition can be prevented by lowering the oxygen requirement. Slowing the metabolic rate reduces or prevents ascites. The difficulty is to find a program that will maintain feed efficiency while reducing metabolic rate without economic loss. Perhaps genetic selection against ascites syndrome can decrease the incidence.

Sudden death syndrome in broiler chickens

Sudden death syndrome (SDS) (named also heart attack or flip-over) describes a condition in which healthy broiler chickens die suddenly for no discernible cause. The term flip-over was used because birds dead from the syndrome are commonly found on their back. The incidence can vary from 0.5 to 4%.

The cause of sudden death syndrome is unknown. Genetic, nutritional, and environmental factors may affect the incidence. This condition is strongly associated with a rapid growth in well-managed broiler flocks. The incidence is higher in birds fed crumble-pelleted feed compared with those fed mash feed. High stocking density can also increase the incidence of SDS. Birds that later died of SDS had a higher heart rate or cardiac arrhythmia than the rest of the flock.

SDS occurs from 1 to 8 weeks of age, with the greatest losses occurring from 2 to 3 weeks of age. It occurs more commonly in males than females. Affected birds show no clinical signs or unusual behaviour before death. Most birds die on their back. Carcasses from these birds are in excellent body condition with a full digestive tract. Liver is enlarged, pale and friable, with an empty gallbladder. Heart ventricles are contracted and empty. Congestion and edema of the lungs may be present.

Lowering the energy intake of the birds will often decrease mortality from SDS and this may be achieved by a number of management strategies, including feed formulation, changing pellet to mash and feed restriction by lighting programs. Genetic selection in environments using nutritionally dense pelleted feeds with extended dark periods (more than 8 hours) may be beneficial in reducing losses from SDS but can have negative effect on body weight.

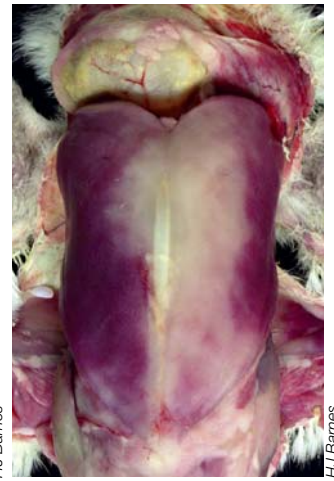
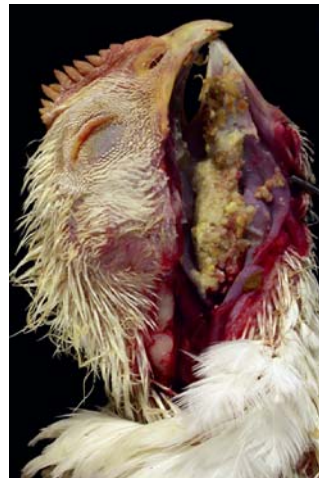
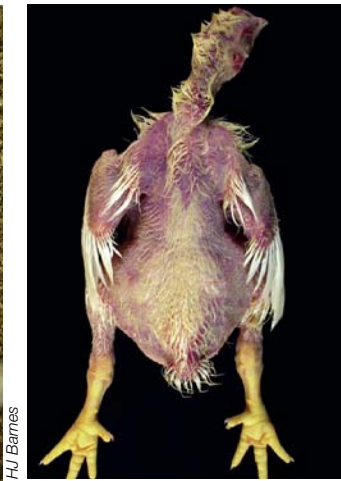Fig.70.15, 70.16, 70.17 & 70.18: Sudden death syndrome in broilers ("Flip-over" in 2 week-old broiler). Carcass is in excellent condition (Fig.70.16) and the bird seems well, with a full digestive tract (Fig.70.17). Typical pattern of hypostatic congestion on the back for a bird that died on its back can be seen in fig.70.16. Congestion is greater over the upper back, lower neck, shoulders, and wings. Lumbar area is pale.(Note that slow feathering of male broiler chickens makes it possible to see the pattern of hypostasis). In Fig.70.18, surrounding the keel is a pale area that transitions into congested areas along either side.

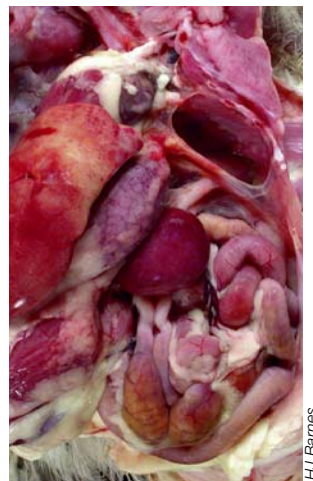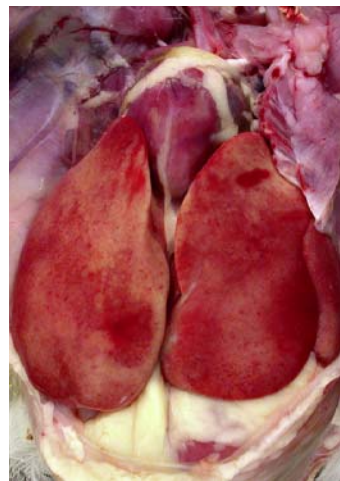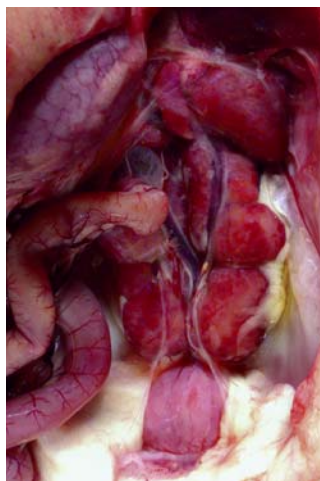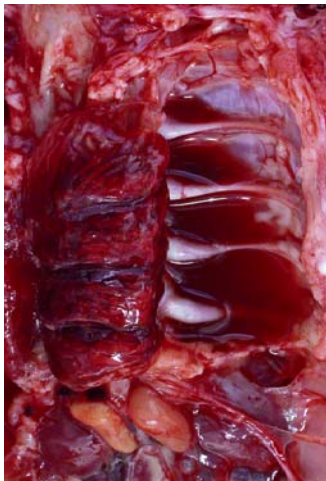


Fig.70.19: Sudden death syndrome in 19 day-old broiler. The only change seen at necropsy was congested and edematous lungs.

Fig.70.20, 70.21 & 70.22: Sudden death syndrome in 2 or 3-week-old broilers (Flip over). Generalized congestion, enlarged kidneys, liver and spleen.

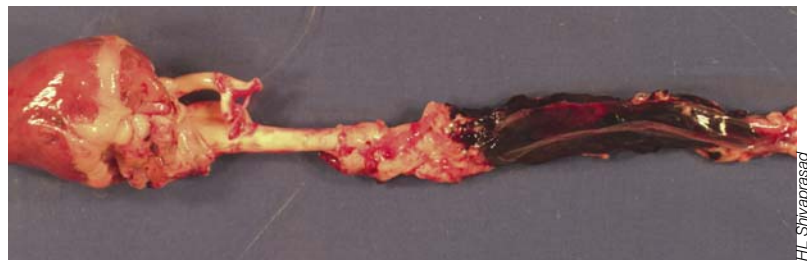
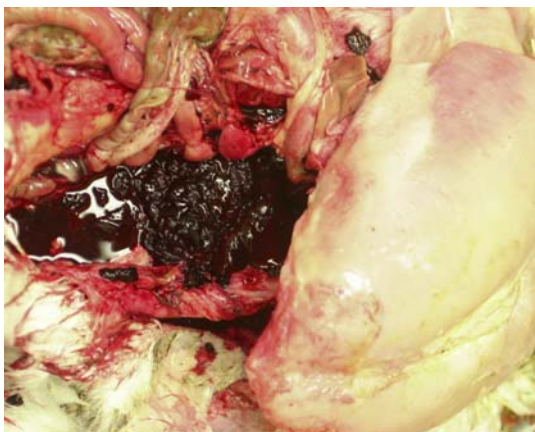


Fig.70.23: Aortic rupture (11 week-old male turkey). Pale carcass and blood in the abdominal cavity.

Fig.70.24: Hemorrhage around the aorta in a turkey with aortic rupture.

Hypertrophic cardiomyopathy

This condition occurs sporadically in broiler chickens and turkeys. The cause of this condition is not known. Hypertrophic cardiomyopathy is a response to volume and pressure. The heart muscle responds to an increased workload as all muscles do, by hypertrophy. In broiler chickens, a volume overload may quickly lead to an increased pressure load on the right ventricle (RV) because of the restricted space for blood flow in the lung. In a volume overload the ventricular wall does not become thicker but the mass of ventricle does increase.

More frequently, a pressure increase occurs because of increased blood flow, but also because of increased resistance to flow as the result of constriction, stenosis or obstruction of arteries, arterioles and capillaries, or because of increased blood viscosity. In this case hypertrophy causes thickening of the ventricle wall. In pressure-induced hypertrophy of the left ventricle (LV), stroke volume may become so small that the heart rate increases to the point where LV no longer have time to fill and the heart is unable to supply the blood flow required by the body. This concentric hypertrophy may be the cause of sudden death in turkeys.

PATHOLOGY OF THE BLOOD VESSELS

Aortic rupture in turkeys

Aortic rupture or dissecting aneurysm first described in the USA in 1952 occurs worldwide. It is characterized by sudden death mostly in fast growing male turkeys due to internal hemorrhage. A similar condition, coronary artery rupture has also been described in turkeys. Aortic rupture has also been observed in chickens, ostriches and emus.

Etiology & pathogenesis

The condition occurs in turkeys between 7 and 24 weeks of age. The highest mortality usually occurs between 12 and 16 weeks and in most flocks usually reaches 1-2%. The condition is sporadic but tends to occur periodically with higher incidence in one year in some flocks and none for several years. Mortality as high as 20% in a span of a few weeks has been observed in some turkey flocks. The cause of aortic rupture is not known. But its occurrence mostly in males suggests that it

could be due to an underlying genetic cause. Copper is important in collagen synthesis and copper deficiency or increased zinc may play a role in aortic rupture. But extensive analysis of the livers from turkeys that have died of aortic rupture revealed normal copper and zinc levels. Others such as increased protein and fat in the diet have also been suggested as contributing factors to the occurrence of aortic rupture. Development of intimal plaques and absence of an intramural *vasa vasorum* around the abdominal aorta (less elastic) that might lead to the degeneration of the arterial wall and high blood pressure in young male turkeys may also be a precipitating factor. Copper deficiency has been associated with aortic rupture in ostriches.

Clinical signs & lesions

Affected turkeys with aortic rupture die suddenly in a wing-beating convulsion. The birds are in good body condition but there may be blood oozing from the mouth. At necropsy, the carcasses are pale with large amounts of blood in the abdominal cavity. Lungs may be congested and hemorrhagic and blood may be present in the trachea. Careful dissection of the descending aorta starting at its origin at the heart will reveal a longitudinal slit or an irregular tear most commonly at the origin of the coeliac artery. But the tear can occur anywhere between the origin of the aorta and ischiatic arteries. Rupture can also occur in other arteries such as the coronary artery, ischiatic artery or renal artery. It is probable that the perirenal hemorrhages (see below) that occur in turkeys is another manifestation of aortic rupture. In case of rupture of the coronary artery there is blood in the pericardial sac and focal hemorrhage at the coronary groove of the aorta suggesting rupture of the transverse branch of the coronary artery. Microscopic lesions of aortic and coronary artery rupture include subintimal thickening, displacement of the internal elastic *lamina*, and degeneration, disorganization and paucity of the elastic fibers and increased collagen in the *subintima* and *tunica media*. Special stains such as Verhoeff - Van Geisson for elastin and Masson Trichrome for collagen are helpful in confirming the changes.

Treatment & control

There is no known treatment for aortic rupture. Treatments with reserpine and aspirin have been tried in turkeys with variable results. Copper supplementation in the feed has been suggested for ratites.

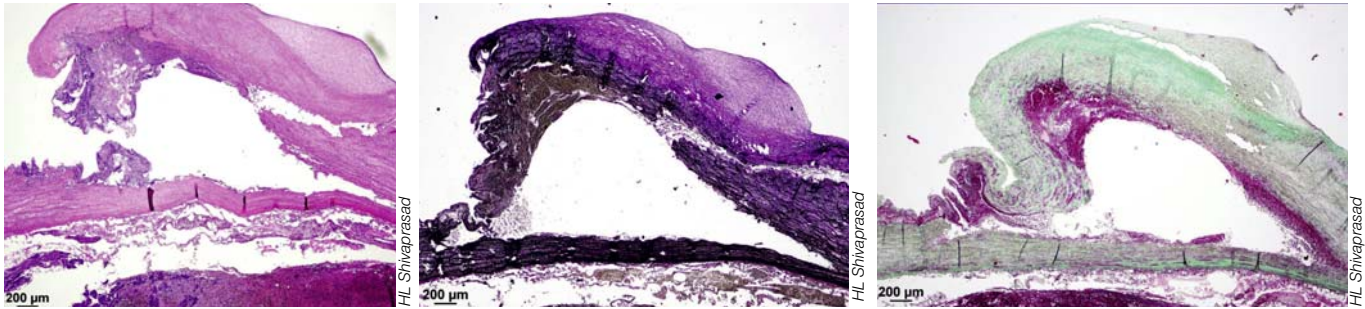


Fig.70.25, 70.26 & 70.27: Photomicrographs of aneurism and aortic rupture of the abdominal aorta, hematoxylin & eosin (Fig.70.25), decreased elastic fibers, Verhoeff-Van Gieson stain (Fig.70.26) and increased collagen, Masson trichrome (Fig.70.27).

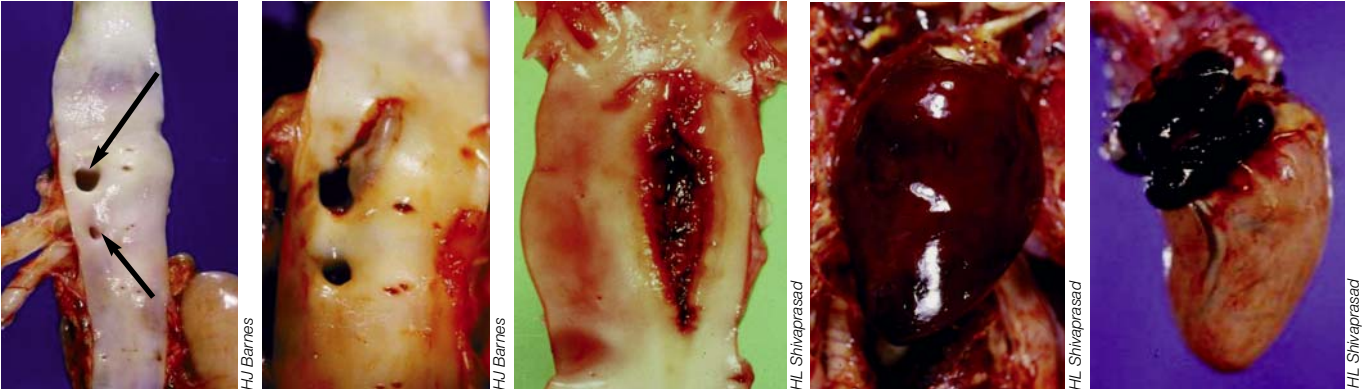


Fig.70.28: Normal aorta with coeliac artery (arrow) and anterior mesenteric artery (arrow). Note testis below. Fig.70.29: Aortic rupture (14 week-old male turkey). Longitudinal tear at the origin of coeliac artery. Fig.70.30: Aortic rupture in a six month-old ostrich. Fig.70.31: Hemopericardium due to coronary rupture in a male turkey. Fig.70.32: Hemorrhage in the coronary groove of the heart due to coronary rupture in the turkey.

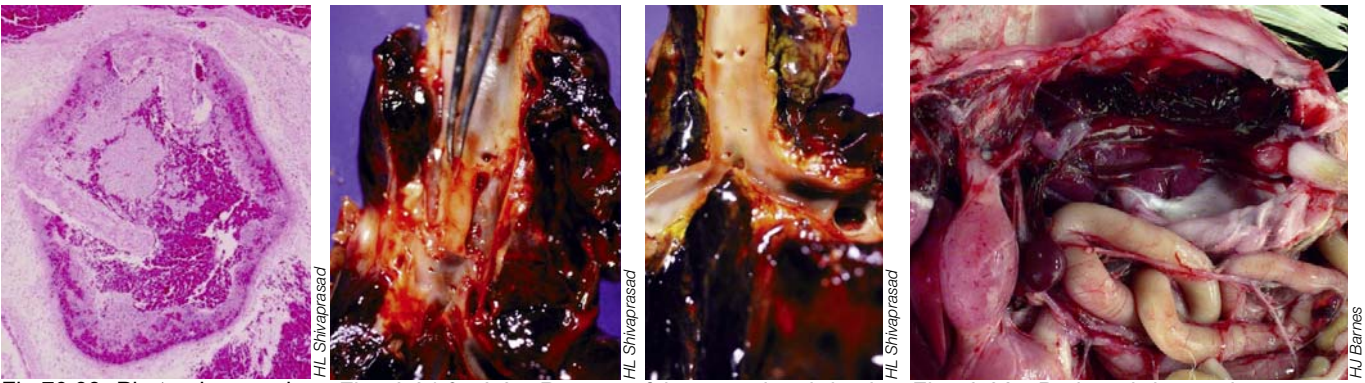


Fig.70.33: Photomicrographs of rupture of the coronary artery and hemorrhage (hematoxylin & eosin). Fig.70.34 & 70.35: Rupture of the posterior abdominal aorta (Fig.70.34) and left ischiatic artery and severe perirenal hemorrhage in turkeys (Fig.70.35). Fig.70.36: Perirenal hemorrhage syndrome (10 day-old turkey). Extensive hemorrhage covers the surface of the left kidney.

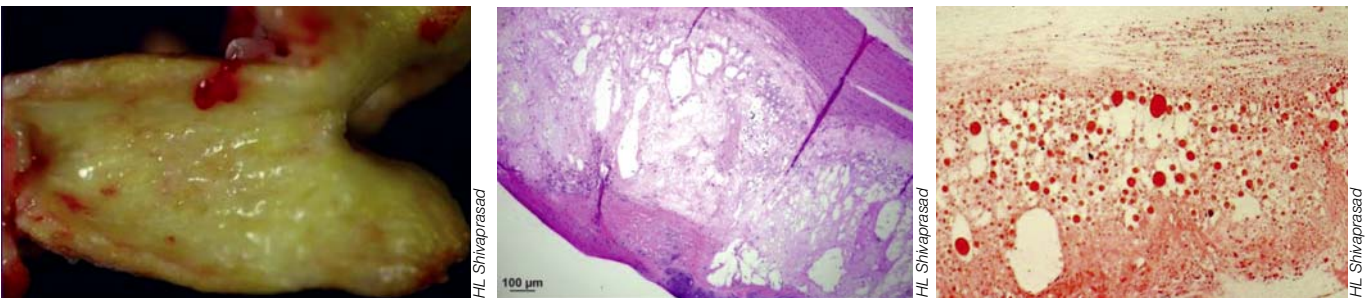


Fig.70.37: Severe atherosclerosis of the aorta in an amazon parrot. Notice the thick wall and rough intima and yellow color of the aorta. Fig.70.38 & 70.39: Atherosclerosis (amazon Parrot). Aorta severely thickened due to infiltration of lipid-laden cells (hematoxylin & eosin) (Fig.70.38) and strongly positive for lipid (oil red O stain) (Fig.70.39).

Sudden death syndrome in turkeys associated with perirenal hemorrhages

Sudden death in turkeys associated with perirenal hemorrhage (SDPH) is a significant cause of mortality in male turkeys between 8 and 14 weeks of age. Mortality can vary between 0.8% to 6.0%. This syndrome has also been described as hypertensive angiopathy.

The cause of death in SDPH may be an acute congestive heart failure secondary to cardiac hypertrophy. Male turkeys have greater left and total ventricular weight than those of females which might explain why the syndrome has been observed only in males. The renal hemorrhage may result from severe passive congestion, which may be compounded in part by closure of the renal valve in the renal portal circulation. This syndrome is most likely another manifestation of aortic rupture where perirenal hemorrhage is also seen. Fast weight gain, continuous lighting programs, overcrowding, and hyperactivity have been suggested as factors that may influence the incidence of SDPH.

The dead turkeys are in good condition, with feed in their crop and the gastro-intestinal tract. They have congested and edematous lungs, splenomegaly, congested livers and digestive tracts, and clotted blood surrounding the kidneys. Slowing the growth rate, increasing room temperatures, step up/step down lighting programs have been shown to reduce the incidence of SDS in turkeys.

Atherosclerosis

Atherosclerosis is a common disorder of the aorta and other major arteries of the domestic poultry, psittacines, raptors and occasionally pigeons. It is more common in males than females and at any age but lesions are more severe in older birds. The amount of lipid in the lesion is variable. Numerous macrophages and occasional mineral deposits are also found in the atherosclerotic plaques. This condition has been reproduced in chickens with Marek's disease virus.

Degenerative and inflammatory changes in the heart

Degenerative changes in the myocardium due to hypoxia, toxicities nutritional deficiencies, and infectious causes in chickens, turkeys, ducks, etc., have been reported. Degeneration of cardiac myocytes is occasionally seen due to ionophore toxicity such as monensin in mature chickens but rare

in young chickens or turkeys. Gross lesions include pale patchy areas in the myocardium and microscopically degeneration of myofibers and infiltration of mononuclear cells. In general ionophores in excess primarily cause various degrees of degeneration and necrosis of the skeletal muscles. Other causes of myocardial degeneration include lead, furazolidone, leaves and fruits of avocado plant (*Persea americana*), leaves of oleander plant (*Nerium oleander*) and uric acid (from rapeseed). Sodium toxicity can lead to dilation of both ventricles in poults and right heart hypertrophy in chicks, hydropericardium and pulmonary congestion and edema. Deficiency of vitamin E and selenium can also cause degeneration of myofibers in the heart especially in ducks and pelicans.

Inflammation of the heart is very common in various species of poultry and others due to infectious agents such as bacteria, fungi, parasites and viruses. The lesions include pericarditis, myocarditis, hemorrhage and occasionally granuloma's which all can be either a manifestation of a generalized disease or occasionally localized to the heart like vegetative valvular endocarditis. Bacterial causes include *Escherichia coli*, *Salmonella* spp., *Pasteurella multocida*, *Listeria monocytogenes*, *Riemerella anatipestifer*, *Ornithobacterium rhinotracheale*, *Mycoplasma* spp., *Mycobacterium* spp., *Staphylococcus aureus*, *Streptococcus* spp., *Erysipelothrix rhusiopathiae*, *Chlamydia psittaci* and others. Multiple pale yellow nodules can be seen in the myocardium in chickens due to *S. Pullorum* and *S. Gallinarum*. Fungi of *Aspergillus* spp. can also produce similar lesions in the heart of chicks and poults.

Vegetative valvular endocarditis is most frequently caused by *Streptococcus* spp. but it may also be due to *Staphylococcus* spp., *Pasteurella multocida*, *Erysipelothrix rhusiopathiae*, *Escherichia coli* or other bacteria. The lesions occur most commonly on the left atrioventricular and aortic valves and it is associated with infarcts in the liver, spleen, heart, brain, etc., or with ascites if the lesion is on the right atrioventricular valve.

Myocarditis or lesions in the heart accompanies many viral infections of birds; avian paramyxovirus (Newcastle disease), highly pathogenic avian influenza virus (HPAI), avian encephalomyelitis virus (AE), goose and Muscovy duck parvoviruses, reovirus in turkeys and to an extent in chickens, West Nile virus in ducks and geese and other species of birds, Group I Adenovirus, serotype 4 (hydropericardium syndrome/Angara disease in chickens), herpesvirus in ducks (duck

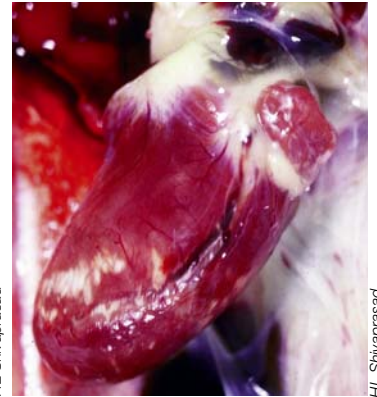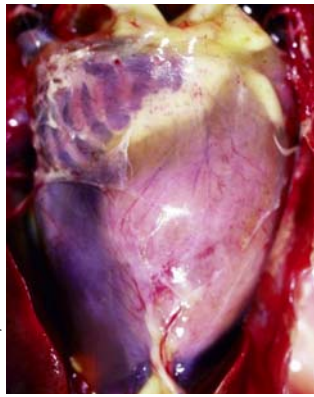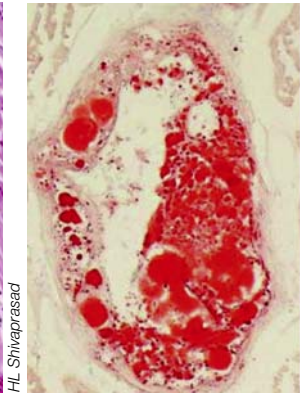
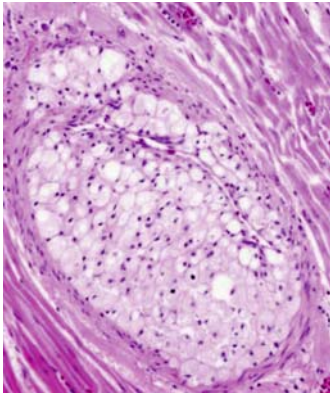


Fig.70.40 & 70.41: Atherosclerosis (Amazon Parrot). Severe atherosclerosis of the coronary artery due to infiltration of lipid-laden cells and narrowing of the lumen (hematoxylin & eosin) (Fig.70.39) and positive for lipid (oil red O stain) (Fig.70.40).

Fig.70.42 & 70.43: Hydropericardium (Fig.70.41) and severe pale areas of degeneration (Fig.70.42) in the myocardium in ducks due to selenium deficiency.

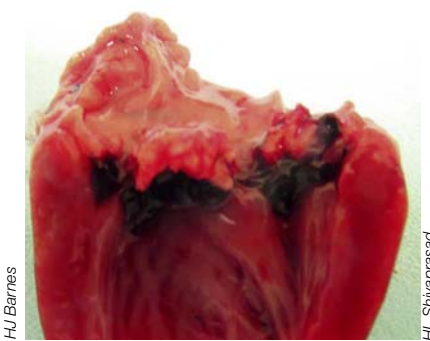
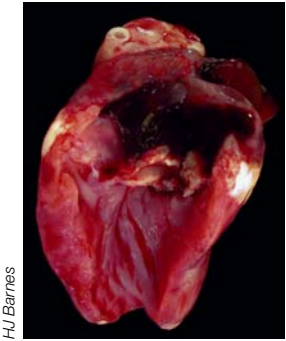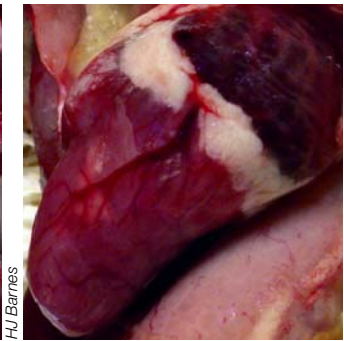

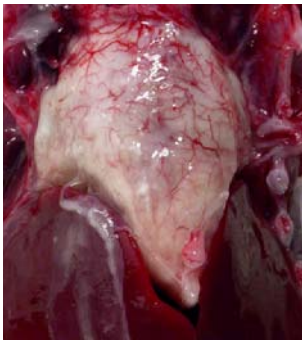
Fig.70.44: Pericarditis (4 week-old turkey) in acute colisepticemia.

Fig.70.45 & 70.46: Severe vegetative valvular endocarditis 22 day-old broiler found dead). Pale raised foci present in the myocardium and vegetative lesions seen here were on the left auriculo-ventricular valve.

Fig.70.47: Severe vegetative valvular endocarditis of the left heart in a 3 week-old chicken due to *Streptococcus gallolyticus*.

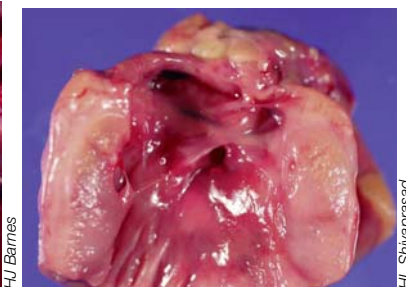
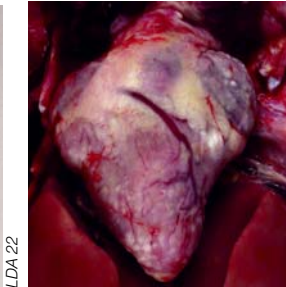
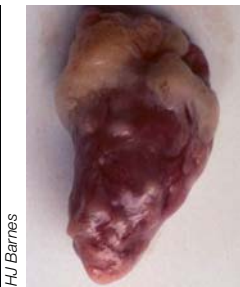
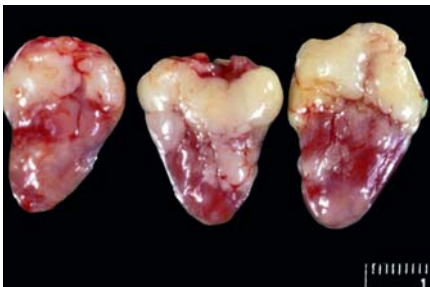
Fig.70.48 & 70.49: Misshapened hearts with pale yellow nodules in the myocardium and thickened pericardium in chickens due to *Salmonella Pullorum*. These gross lesions might resemble lymphomas or granulomas caused by other infection.

Fig.70.50: Heart of a 8 week-old chicken with numerous small lymphomas due to Marek's disease.

Fig.70.51: Pale areas of lymphoma in the myocardium of a chicken due to Marek's disease.

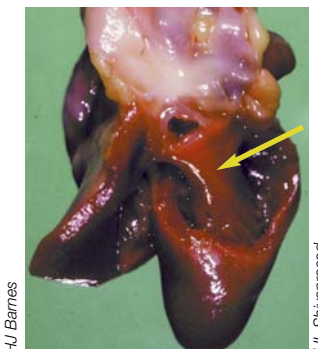
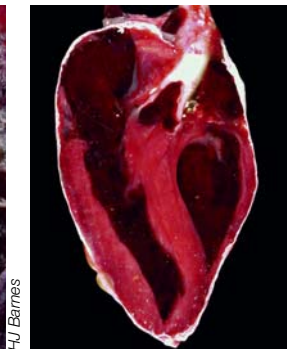
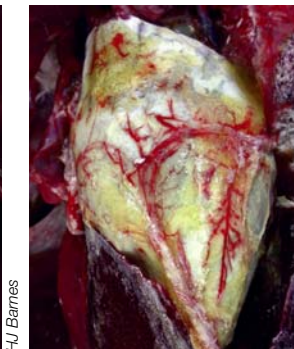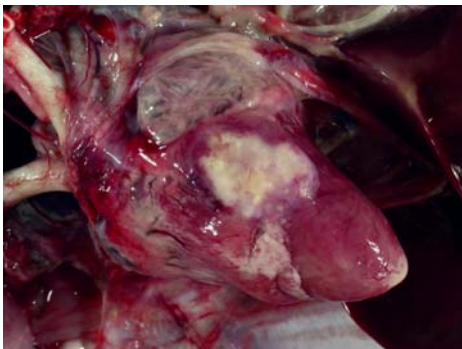


Fig.70.52: Heart aspergillosis (12 week-old male turkey). Marked pericarditis with lesion extending into the right ventricle.

Fig.70.53 & 70.54: Heart gout (35 week-old male turkey).Visceral urate deposits may resemble pericarditis.

Fig.70.55: Ventricular septal defect (arrow) in the heart of a 3 week-old chicken.

virus enteritis), alphaviruses (Western equine encephalitis, Eastern equine encephalitis, Highlands J virus) in turkeys, bunyavirus in ostriches and avian bornavirus in various species of birds. Similarly viruses like Marek's disease virus [(avian leukosis virus (ALV) and reticuloendotheliosis virus (REV)] can cause either nodular or diffuse lymphoma in the heart of chickens and turkeys. Myocarditis and hypertrophy of cardiomyocytes have also been demonstrated in chickens due to ALV-A retrovirus.

Among parasites, protozoa such as *Toxoplasma*, *Leucocytozoon*, *Sarcocystis* and *Haemoproteus* can cause myocarditis in various species of birds. A nematode, *Sarconema eurycerca* has been associated with severe myocarditis in swans. Trematode, *Schistosoma* of *Billaharzia* spp. causes medial hypertrophy of blood vessels in waterfowl.

Miscellaneous conditions

Though infrequent, conditions like, ventricular septal defect (VSD), auricular septal defect (ASD), sub-pulmonic and sub-aortic stenosis, hypoplasia of the ventricles, dextraposition of major vessels and valvular endocardiosis and valvular insufficiency do occur in chickens and other species of birds.

Visceral urate deposition (gout) in the pericardial sac is a frequent occurrence in chickens, turkeys and other species of birds. It is primarily a result of renal failure most commonly due to dehydration.

Accumulation of homogenous eosinophilic material like amyloid and wear and tear pigment like lipofuscin, iron pigment and mineralization within the myocardium take place in various species of birds. Primary tumors of the heart such as rhabdomyosarcoma are rare in birds.

REFERENCES

- Crespo R & Shivaprasad HL. Developmental, metabolic and other noninfectious disorders. In *Diseases of poultry*, Ed. Swayne D, 13th ed., Wiley- Blackwell Publ. 2013, pp 1233-1270.
- Julian RJ. The effect of increased sodium in the drinking water on right ventricular hypertrophy, right ventricular failure and ascites in broiler chickens. *Av Pathol*, 1987, 16:61-71.
- Julian RJ. The avian cardiovascular system. *Slide study set # 25*, AAAP 2002.
- Julian RJ. Production and growth related disorders and other metabolic diseases of poultry – A review. *The Vet J*. 2005,169: 350-369.
- Lister S. Broiler ascites: a veterinary viewpoint. *World's Poultry Sci J*, 1997,53:65-67.
- Morrow C. Management as a cause of disease in poultry. In *Poultry diseases*, Pattison M et al ed., 6th ed., Elsevier, Publ., 2008, pp 536-547.
- Shivaprasad HL & Rimoldi G. Aortic Rupture Associated with Increased Mortality in Male Turkeys. *Proceedings American College of Veterinary Pathologists* 62nd annual meeting. Nashville, TN, USA. 2011.
- Shivaprasad, HL et al. Coronary artery rupture in male commercial turkeys. *Av Pathol*, 2004, 33:226-232.

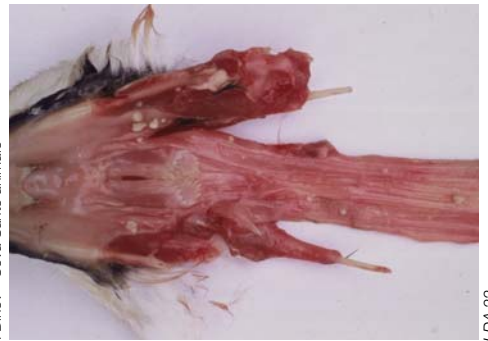
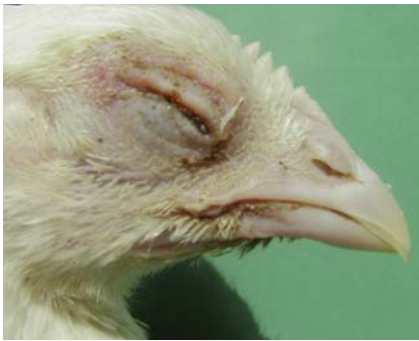
Fig.71.1: Vitamin A deficiency. Birds usually die before the development of eye lesions. Bird surviving over one week with swelling and adhesion of eyelids with a sticky exudate.

Fig.71.2: Vitamin A deficiency (laying hen). Periorbital edema and lack of pigmentation. Inflammation following secondary infections of the conjunctiva and the cornea occurs, affecting also the adjacent sinuses.

Fig.71.3: Vitamin A deficiency (Penguin). 1-3-mm white pustule-like lesions are present in the mucosa of the mouth, pharynx and esophagus. This condition resembles certain stages of fowlpox.

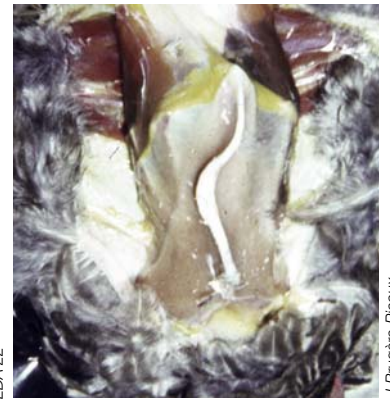
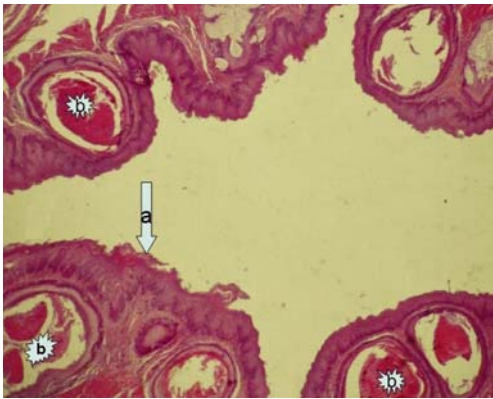


Fig.71.4: Vitamin A deficiency (transverse cross section of esophagus). The nodules seen in Fig.71.3 are resulting from hyperkeratinization (arrow a) and metaplasia (arrow b) of the glandular epithelium.

Fig.71.5: Vitamin D deficiency. Affected poullet in ventral decubitus.

Fig.71.6: Vitamin D deficiency. Affected chicken with a soft sternum forming a S.

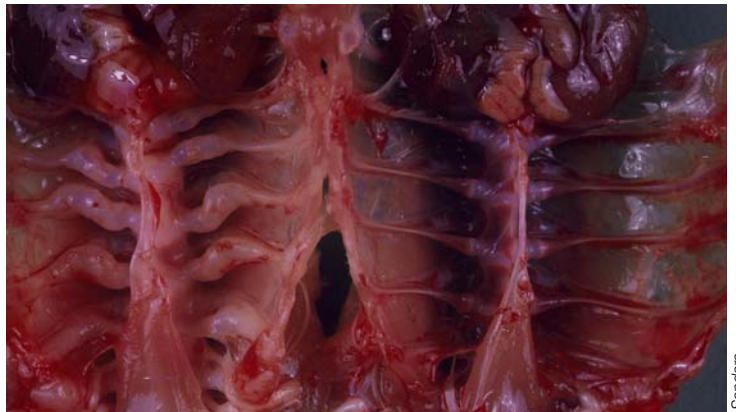
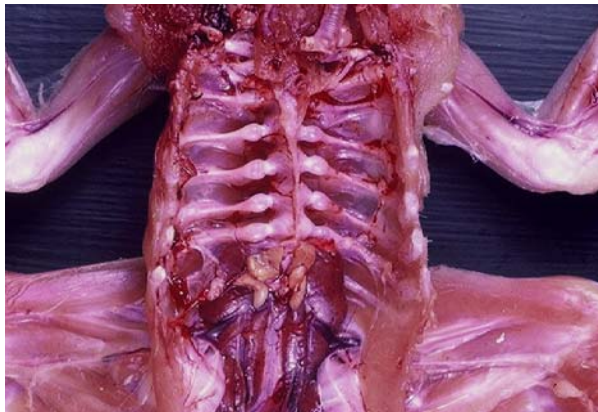


Fig.71.7 & 71.8: Vitamin D deficiency (Chicken). Rickets affecting the ribs. Compare fig.71.8 severely affected ribs (left) with normal ribs (right).

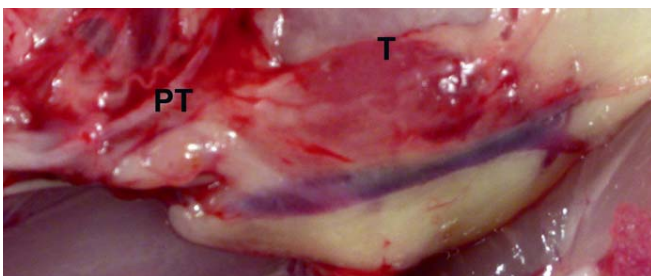


Fig.71.9: Parathyroid hyperplasia. This condition can be observed with rickets.

Fig.71.10: Vitamin D deficiency. Beak is soft and easily bent.

Other diseases

71. NUTRITIONAL DISEASES

INTRODUCTION

Vitamins and minerals are essential elements in poultry nutrition to optimize the health and development of poultry.

VITAMINS

Vitamin A

The most common form of natural vitamin A is retinol. This fat-soluble vitamin is essentially found in the liver and fish oils, and is implicated in the maintenance of membrane integrity and cerebrospinal fluid pressure. It acts as an antioxidant. β carotene, a «provitamin A» found in some plants (e.g. corn), can be converted into vitamin A by birds.

Vitamin A deficiency

In most cases, this deficiency is seen in young birds between one and three weeks of age (depending on the amount of vitamin A stored in the egg). The most common clinical sign of vitamin A deficiency is hyperkeratosis of mucous membranes of the mouth and esophagus. Other signs of this deficiency include epithelial/mucosal metaplasia of the digestive and respiratory tracts, nutritional nephropathy (impacted ureters and visceral urate deposits), decreased appetite and growth rate, ruffled feathers, corneal hyperkeratosis, and nerve lesions. In breeder and layers hens, decreased egg production and hatchability, and embryonic mortality are noted.

Diagnosis is based on the clinical signs and lesions, on the amount of vitamin A found in the diet and/or on vitamin A levels in the liver. Differential diagnosis should include respiratory diseases of poultry.

Prevention is achieved by providing an adequate supply of vitamin A in the ration (10,000 IU/kg) and by avoiding prolonged storage of prepared feeds in order to prevent rancidity.

Hypervitaminosis A

Excessive vitamin A supplementation in the feed can occur because of the relatively low cost of this vitamin. Hypervitaminosis A interferes with absorption of vitamins E and D₃.

Vitamin D

The two main forms of vitamin D are ergocalciferol (vitamin D₂, poorly utilized by poultry) and cholecalciferol (vitamin D₃). Vitamin D₃ is a fat-soluble vitamin found in fish oils. The main function of vitamin D₃, as the renal metabolite 1,25-dihydroxycholecalciferol (following initial hydroxylation in the liver of 25-dihydroxycholecalciferol) is inducing the synthesis of calcium-binding proteins and controlling intestinal absorption and blood translocation of calcium.

Vitamin D deficiency

Although a deficiency limited to vitamin D₃ can theoretically occur, it is almost always complicated with calcium and phosphorus deficiencies. It is important to remember that all birds, including poultry, require vitamin D₃ (3,000 IU/kg). Laying hens are especially vulnerable to vitamin D₃, calcium and phosphorus deficiencies due to the high demand for these nutrients required for egg production.

Vitamin D₃ deficiency associated with inadequate dietary calcium and/or phosphorus causes rickets in growing birds and osteomalacia in laying hens (in cases of severe deficiency, egg production quickly stops) (see Chap.IV.69). In young birds, the junctions of the ribs with the vertebrae and sternum may be enlarged. The bones, beak and claws become soft and pliable. Growth is stunted and feathering is usually poor.

Hypovitaminosis D diagnosis is based on clinical signs and lesions. Careful calculation of the calcium:phosphorus ratio, and vitamin D₃ levels in the ration can confirm the deficiency or the imbalance.

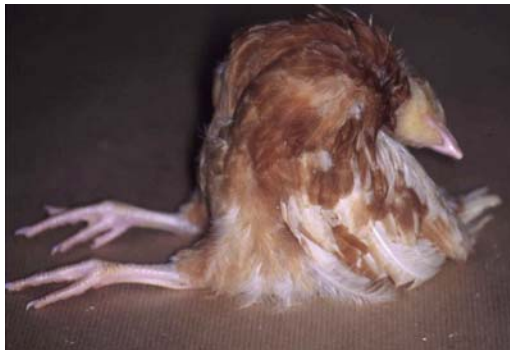Prevention is based on a balanced ration with adequate calcium, phosphorus, and vitamin D₃ levels.

Hypervitaminosis D

An excess in vitamin D₃ can be toxic, leading to calcium deposits in tissues, renal damage, excessive mobilization of eggshell calcium and late embryonic death.



I. Dinev - Ceva Santé animale

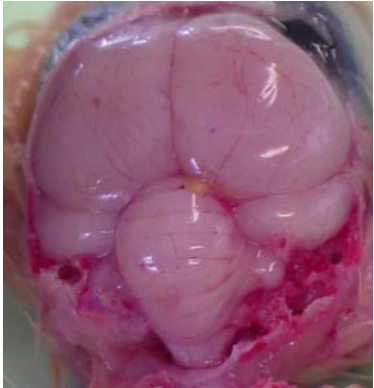


LDA 22

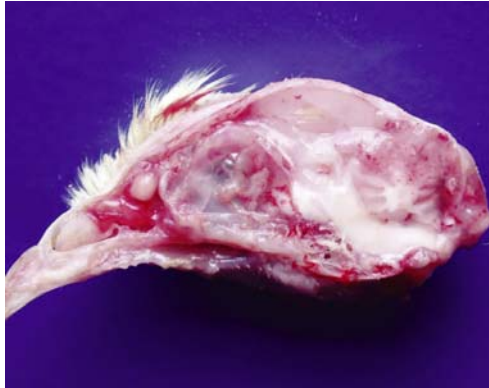

I. Dinev - Ceva Santé animale

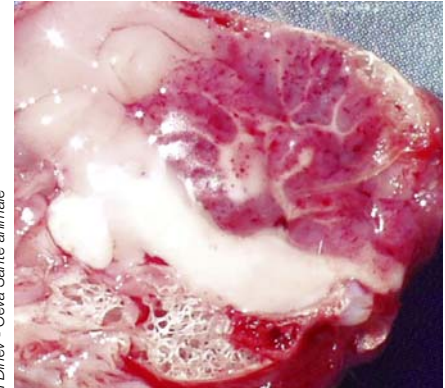
Fig.71.11, 71.12 & 71.13: Nutritional encephalomalacia. Progressive ataxia with frequent stumbling, paresis, prostration and death. Rarely, torticollis or opisthotonos can be observed.



S. Maeder - LDA 22

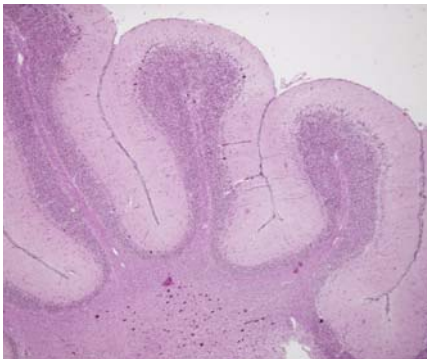

I. Dinev - Ceva Santé animale

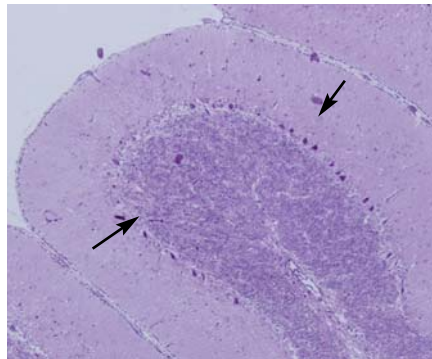


I. Dinev - Ceva Santé animale

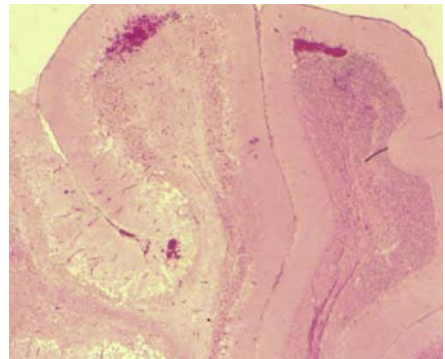
Fig.71.14, 71.15 & 71.16: Nutritional encephalomalacia. Birds with neurological signs have cerebellar swelling, edema, hemorrhage and necrotic areas. In the cerebellum, the hemorrhages vary from hardly perceptible to petechia and sometimes it is possible to observe hematomas. Exceptionally, brain lesions can also be present.



J. Brugère-Picoux

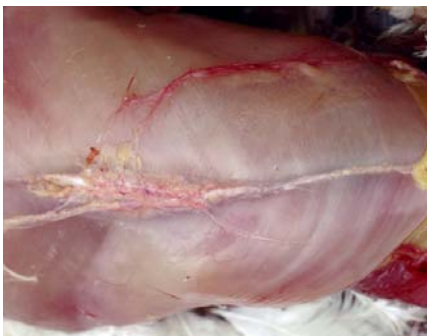

J. Brugère-Picoux

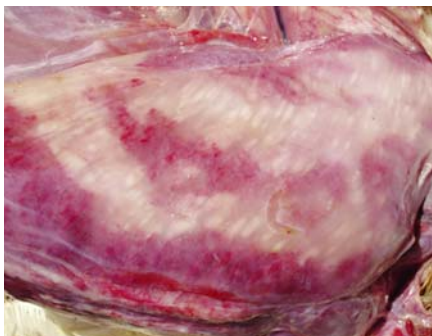

LDA 22

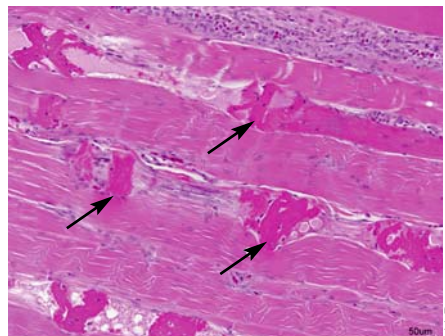
Fig.71.17, 71.18 & 71.19: Nutritional encephalomalacia. Although macroscopic lesions with clinical signs are virtually pathognomonic, the diagnosis should be confirmed by histologic examination of the cerebellum showing severe edema and necrosis. Degenerative neurological changes occur everywhere but are most prominent in Purkinje cells (black arrows) and large motor nuclei. Cells are shrunken and intensely hyperchromatic, and the nucleus is typically triangular. Hemorrhages can be also observed.



HJ Barnes



I. Dinev - Ceva Santé animale



HJ Barnes

Fig.71.20, 71.21 & 71.22: Nutritional myopathy. Presence of light colored streaks easily distinguishable from normal breast muscle fibers. The initial histologic change is hyaline degeneration (arrows). Later, muscle fibers are disrupted. In more chronic conditions, reparative processes dominate the microscopic picture.

Vitamin E

The key form of vitamin E in poultry is α -tocopherol. This liposoluble vitamin is quite widely distributed in plant substances and is a primary antioxidant found in cell membranes. This antioxidant role is related to selenium: selenium is a key component of the glutathione peroxidase (GSH-Px) cell enzyme, an enzyme that protects cell membranes from oxidative damage produced by peroxides derived from unsaturated fatty acids. In chicks, plasma GSH-Px levels are directly related to selenium levels in the diet and to the effectiveness of selenium in preventing exudative diathesis. However, vitamin E also appears to prevent exudative diathesis by acting on the lipid membrane where it neutralizes free radicals, thereby preventing chain-reactive auto-oxidation of the capillary membrane lipids. This protective role ensures erythrocyte stability and capillary blood vessel integrity.

Selenium and vitamin E also play a role in enhancing animal immunity and are involved in fertility (early embryonic mortality associated with vascular lesions) and degenerative changes in muscular and liver tissues.

Vitamin E deficiencies are usually seen in young chicks or poults, but also occur in ducklings and, perhaps, in other birds. Most cases occurs in birds fed rations high in polyunsaturated fatty acids (e.g., cod liver oil, soy bean oil) that oxidize and become rancid. Vitamin E is very unstable in diets rich in oxydized products.

Clinical signs

In general, birds deficient in both selenium and vitamin E show blood vessel damage and changes in capillary permeability: encephalomalacia (crazy chick disease), nutritional muscular dystrophy and exudative diathesis.

Nutritional encephalomalacia: Nervous signs usually begin in two to three week-old chicks and may appear up to five weeks of age (but sometimes as early as seven days and as late as 56 days of age).

Nutritional muscular dystrophy: White streaks in the pectoral and leg muscles or in the gizzard and heart are seen in chicks, poults and ducklings. Clinically, locomotor disorders can be observed.

Exudative diathesis: Capillary wall lesions lead to red/black or blue/black gelatinous subcutaneous edema in the abdominal and thoracic regions. Similar changes are sometimes present in the intermandibular space and periorbital region. Birds with extensive edema may have difficulty walking and stand with their legs apart.

Diagnosis

Diagnosis involves recognition of major clinical signs, macroscopic and microscopic lesions (particularly encephalomalacia and muscular dystrophy), and examination and analysis of feedstuff to assess selenium and vitamin E levels.

Control & treatment

Considering the etiology, encephalomalacia can be prevented by adding synthetic antioxidants to the feed; adding selenium to the feed will prevent exudative diathesis; and adding cysteine, a sulfur-containing amino acid, to the feed will avert muscular dystrophy.

Recommended vitamin E levels are 30 to 150 mg/kg in the feed. Oral administration of a single dose of vitamin E (300 IU) per bird will often cure exudative diathesis or muscular dystrophy. Birds with encephalomalacia do not usually respond well to treatment.

Vitamin B₁ (thiamin)

Vitamin B₁ can be found in almost all plant or animal tissues. This vitamin plays an important role in carbohydrate metabolism *via* several enzyme systems and shows antineuritic properties.

In the field, signs related to vitamin B₁ deficiency are not seen in poultry. However, high temperatures increase requirements and amprolium (an anticoccidial) blocks thiamine metabolism. Experimentally, thiamin deficiency leads to loss of appetite and reduced growth, weakness, polyneuritis, opisthotonos and paralysis.

Vitamin B₂ (riboflavin)

Vitamin B₂ is essential for the growth and health of poultry. It is synthesized by microbial activity in the gut of adult birds. This vitamin is stored in eggs, particularly in the yolk. The use of high-energy poultry diets and ingredients with low vitamin B₂ requires additional feed supplementation.

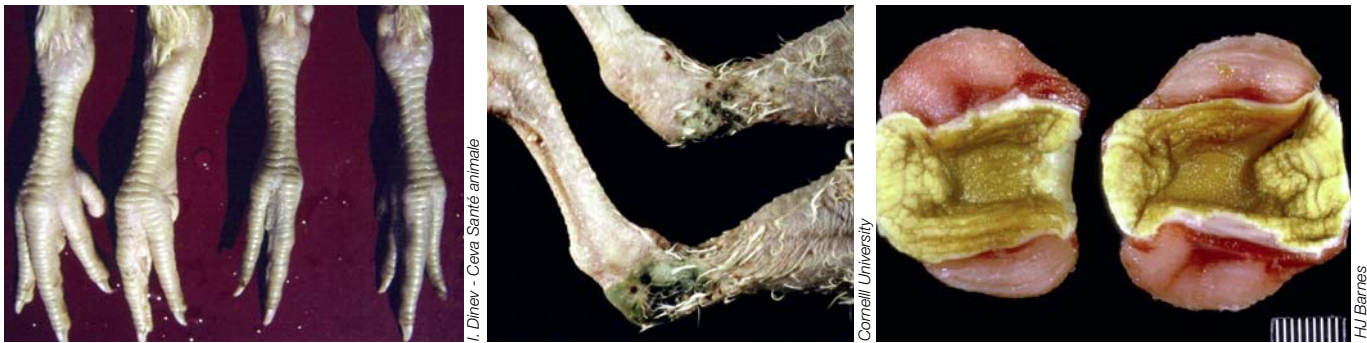

Fig.71.23, 71.24 & 71.25: Exudative diathesis is an edema of subcutaneous tissues associated with abnormal permeability of capillary walls. The skin of the legs is often cyanotic (Fig.71.23). A green-blue viscous fluid is easily seen through the skin. Gizzard muscle degeneration can be observed (Fig.71.25).

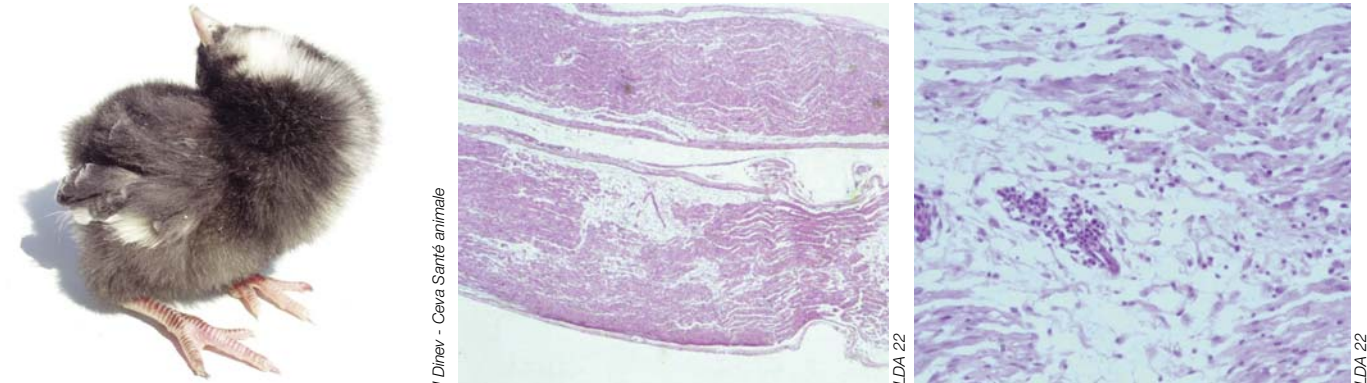


Fig.71.26, 71.27 & 71.28: Thiamin deficiency (Chicken). This typical stargazing posture is due to paralysis of the anterior muscles of the neck. Histologically, polyneuritis is observed.

Section IV



Fig.71.29, 71.30 & 71.31: Riboflavin deficiency (Chicken). Typical signs include poor growth, reluctance to stand and walk, sitting on hocks and toes curled inward or leg paralysis. This curled toe paralysis is due to lesions of the sciatic (and brachial) nerves with degenerative changes in myelin sheaths.



Fig.71.32: Pyridoxine (Vitamin B₆) deficiency (Chicken). Poor feathering. Fig.71.33 & 71.34: Biotin deficiency. In growing chickens and turkeys the first signs of biotin deficiency occur in epidermal tissues. Dermatitis at the corner of the beak (left) and severely affected feet (right).

Antagonists such as aflatoxins may interfere with this vitamin's absorption or transport within the bird.

Clinical signs of a mild vitamin B₂ deficiency are non-specific (reduced growth rate, dermatitis and nervous disorders).

Signs of severe deficiency in poultry are age dependent. In breeders, a reduction in egg production and hatchability occurs. Hatched chicks may be edematous and stunted, showing «clubbed down» (the down feathers do not break out from their feather sheath, resulting in a coil-like appearance), poor feathering, with "curled toe paralysis". Similar degenerative changes in nerve trunks are seen in older birds with «curled toe» if the feed is low in vitamin B₂.

Vitamin B₆ (pyridoxine)

Pyridoxine is involved in amino acid metabolism via numerous enzymes. Due to the multiplicity of metabolic functions, a deficiency can occur without specific signs: reduced appetite and growth, poor feathering, demyelination, chondrodystrophy, *etc.*

Niacin (vitamin B₃, nicotinic acid)

Niacin, in its nicotinamide form, is a critical part of the coenzymes involved in the metabolism of proteins, fats and carbohydrates. Like for vitamin B₆, a deficiency may have several effects. However, niacin is one of the main nutritional deficiencies associated with chondrodystrophy (along with deficiencies in manganese, zinc, choline, biotin, folic acid and pyridoxine).

Pantothenic acid (vitamin B₅)

Pantothenic acid or «chick antidermatitis factor» is an essential component of coenzyme A (CoA), a vital element of energy and fatty acid metabolism. A severe deficiency leads to dermatitis (beak, eyelids, vent and feet) and feather loss. Copper, which affects the rate of production or function of CoA, antagonizes pantothenic acid activity.

Biotin (vitamin H)

Biotin is essential for growth, feed utilization, epidermal tissue maintenance, bone development and reproduction. In poultry, biotin deficiency clinically leads to decreased growth rate, epidermal and bone lesions.

Dermatitis

In growing birds, the first signs of biotin deficiency occur in epidermal tissues (poor feathering, periocular and eyelid epidermitis, footpad dermatitis, *etc.*).

Fatty liver and kidney syndrome in broiler chicks (FLKS)

Fatty liver and kidney syndrome occurs in 10 to 30 day-old broiler chickens. It is a nutritionally induced condition where a marginal deficiency in biotin plays a key role (biotin supplementation may be an effective treatment). A reduction in feed intake and blood sugar can precipitate FLKS. Before the onset of this syndrome, birds appear normal and cannot be distinguished from their flockmates in terms of feed intake or behavior.

The fatty liver and kidney syndrome arises from failure of neoglucogenesis and increased fat deposition. Birds die from hypoglycemia. Biotin deficiency compromises the enzymatic activity of hepatic pyruvate carboxylase, causing the conversion of pyruvate into fatty acids during neoglucogenesis. Affected chicks show severe hypoglycemia inducing body lipid mobilization, which results in extensive lipid infiltration of the liver and kidneys. If biotin is the most important factor, FLKS can also involve the interaction of nutritional, environmental, stress and maternal factors:

- High levels of fat and proteins offer protection by depressing lipogenesis needs;
- Elevated levels of other vitamins increase the incidence;
- Floor rearing promotes availability of faecal biotin;
- Starvation and stress deplete glycogen reserve;
- Age of breeders: eggs from older hens have more biotin;
- Other diseases can cause stress and/or depress intestinal absorption.

General clinical signs include poor growth, scabs around the eyes and beak, chondrodystrophy and occasionally sudden death. The onset is sudden; birds become motionless and remain in sternal recumbence until death, usually within one day and frequently within six to ten hours (mortality may range from below 5% up to 35%). Blood biochemistry shows hypoglycemia and high free fatty acid concentration. Necropsy findings of affected birds show lipid infiltration of the liver, kidneys and heart. Routine histopathology of affected organs reveals hepatic parenchymal and kidney tubule cells filled with fat droplets of various sizes.

Degenerated cells can be observed in necrotic foci. Biotin supplementation in drinking water, and later in the feed, eliminates or greatly decreases the mortality attributable to this syndrome.

Folic acid (folacin)

Folic acid is required for normal nucleic acid metabolism and production of nucleoproteins involved in cell multiplication. Folic acid deficiency in chicks is characterized by poor growth, poor feathering and feather pigmentation, anemia and chondrodystrophy.

Vitamin B₁₂ (cobalamin)

Vitamin B₁₂ is involved in the cellular metabolism of proteins, carbohydrates and lipids, and is physiologically closely associated with folic acid.

Deficiency results in poor growth, embryonic death and decreased hatchability (if breeder hens are deficient, hatchability may drop to zero in about 6 weeks).

Choline

Choline is present in acetylcholine and body phospholipids. The most consistent signs of choline deficiency are chondrodystrophy, poor growth, increased fat deposition in the liver (leading to fatty liver) and reduced hatchability in breeders.

ESSENTIAL INORGANIC ELEMENTS

Calcium & phosphorus (see Chap.71.69)

Calcium and phosphorus metabolism are closely related, particularly in bone formation (and eggshell formation in adult hens). Calcium ions play a role in excitation of nerve cells, neuromuscular transmission, muscular contraction and blood

clotting. Phosphorus is also involved in the transfer or conservation of free energy during biochemical reactions and in the maintenance of acid-base balance.

The utilization of calcium and phosphorus depends on the presence of adequate amounts of vitamin D in the diet. There are also numerous interactions between major mineral elements (Ca, P, Mg, Na, K) leading to certain bone abnormalities such as tibial dyschondroplasia.

A calcium and/or phosphorus deficiency in growing birds leads to rickets. This deficiency can also be due to malabsorption arising from an intestinal disease.

In adult birds, calcium and/or phosphorus deficiency will cause osteomalacia, leading to osteoporosis. Laying hens with calcium deficiency produce thin or soft-shelled eggs. Cage layer fatigue can be a consequence of osteoporosis: caged layers are suddenly paralysed and stay down (spinal cord compression is usually the cause of paralysis).

Excess dietary phosphorus is detrimental to eggshell strength. Excess calcium in the feed of growing birds will cause nephrosis and visceral urate deposition. Low levels of dietary phosphorus exacerbate the effect of excess calcium.

Magnesium

Magnesium is essential for carbohydrate metabolism and activation of many enzymes. It is essential for bone formation (carbonate). Eggshells contain about 0.4% magnesium.

Birds fed magnesium-deficient diets grow slowly and become lethargic. In cases of severe magnesium deficiency, hypocalcemia associated with hypomagnesemia lead to bone disorders.

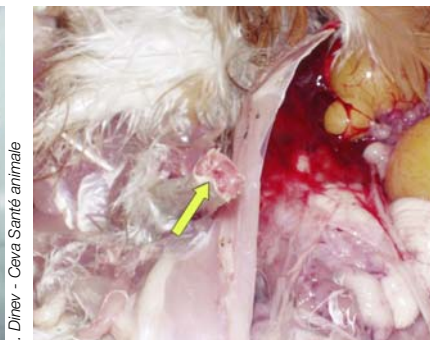


Fig.71.35, 71.36 & 71.37: Cage layer fatigue. This condition is observed in caged laying hens that are producing well, are in fair body condition and suddenly become recumbent. Eggshell becomes thin, bones are severely thinned (yellow arrow) and spontaneous fractures, especially of the tibia and the femur can occur. These problems are attributable to osteoporosis and involve other etiologic factors than a simple calcium deficiency.

Excess dietary magnesium affects the growth rate of young broilers, causes a reduction in egg size, and is associated with eggshell thinning and diarrhea in hens.

Sodium chloride (salt)

Sodium and chloride ions play a role in the maintenance of membrane potentials, and in fluid, ionic and acid-base balances. Deficiencies in these ions therefore produce disturbances in cellular function and water distribution, resulting in stunted growth, dehydration, neuromuscular dysfunction and death. Chloride deficiency also causes nervous signs in chicks. In laying hens, sodium deficiency causes an abrupt drop in egg production, reduced egg size and cannibalism (especially with cloacal prolapse following oviposition).

Excess dietary salt can be toxic (lethal dose is approximately 4g/kg of body weight). Signs of salt intoxication include intensive thirst, diarrhea, progressive muscular weakness, inability to stand, convulsions and death. Sodium excess results in ascites, hydropericardium, right ventricular hypertrophy and right ventricular failure in broiler chickens. High levels of salt may also cause a drop in egg production and the excretion of diluted droppings producing wet litter.

Potassium

Potassium is primarily found in the body's cellular compartment and plays an essential role in the maintenance of membrane potential and intracellular fluid balance. Potassium is necessary for numerous biochemical reactions and for normal heart function.

A fall in potassium level may occur following severe stress or can be the result of elevated temperatures (with increased loss of potassium in urine). The main effect of potassium deficiency is an overall muscle weakness (poor intestinal tone, cardiac and respiratory muscle weakness).

Dietary balance of macrominerals

Dietary mineral balance has a direct effect on acid-base balance and certain developmental, metabolic and physiological functions in poultry. Cation-anion balance can be assessed by calculating the dietary undetermined anion (dUA): $dUA = (Na+K+Ca+Mg) - (Cl+P+S)$ in which all values are expressed in mEq/kg of feed. Valences are assumed to be +1 for Na and K, +2 for Ca and Mg,

-1 for Cl, -1.75 for P, and -2 for S (P and S assumed to be inorganic). Other evaluations emphasize the balance between the main electrolytes (Na+K+Cl).

dUA does not provide an assessment of feed quality, but rather a prediction of the quantitative effect of the feed on the acid-base balance.

Diets rich in anions, particularly Cl, tend to cause metabolic acidosis and result in Ca metabolism disorders (tibial dyschondroplasia, reduced eggshell calcification).

Excess calcium combined with phosphorus deficiency in the feed results in alkaline urine excretion, which increases the risk of urolithiasis. Excess dietary sodium bicarbonate promotes visceral urate deposition. Treatment to reduce uroliths consists in increasing dietary acids. However, a very low dUA can have adverse effects on bone development and eggshell quality.

High levels of electrolytes (Na, K, P) in the feed increase water intake and produce wet droppings causing wet litter problems.

Manganese

Manganese activates several enzyme systems and is an essential component of pyruvate carboxylase, which also contains biotin and controls the rate of gluconeogenesis. Manganese deficiency results in poor growth, skeletal deformities, decreased egg production (eggshell is thin, porous and soft) and reduced hatchability (may reach up to 50%). Newly hatched chicks present ataxia, tetanic spasms and their head may be drawn forward or retracted over their back. Ataxic chicks may grow normally and reach maturity, but fail to recover completely.

Zinc

Traces of zinc are necessary for life: zinc affects growth, development, reproduction, and through its involvement in many enzymes, it affects almost all metabolic functions.

Deficiency results in poor growth, frayed feathers, scaly skin (particularly legs and feet) and chondrodystrophy with enlarged hocks. In breeder hens, there is a reduction in egg production and hatchability.

Excess dietary zinc levels induce molting in laying hens and lesions in the proventriculus, pancreas and thyroid gland.

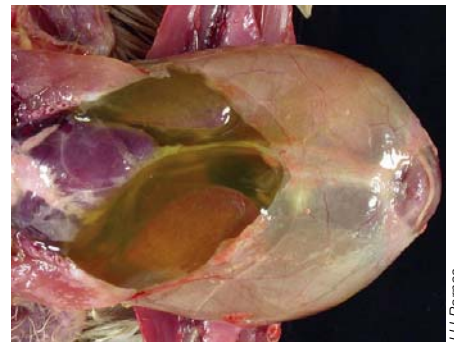


Fig.71.38 & 71.39: Deprivation of sodium in laying hens causes an abrupt drop in egg production, reduced egg size and cannibalism (especially the cloaca when birds are in oviposition).

Fig.71.40: Ascites. Excess sodium results in ascites, hydropericardium, right ventricular hypertrophy and right ventricular failure in broiler chickens.

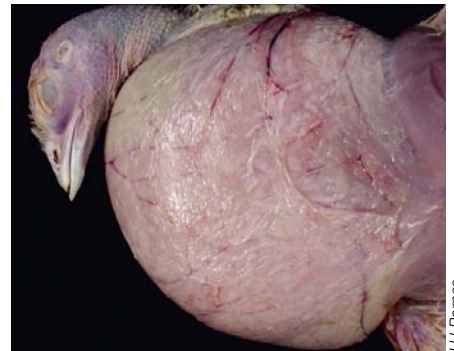
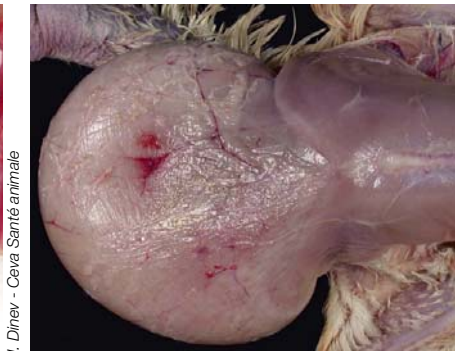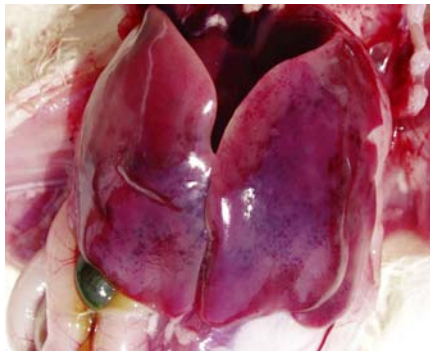


Fig.71.41: Acute selenium intoxication leads to high death rates and massive liver hemorrhages.

Fig.71.42 & 71.43: Pendulous crop (55 day-old turkey hen).

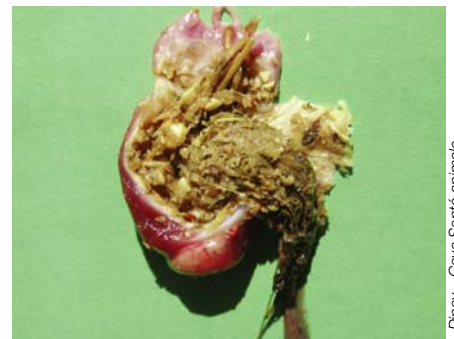
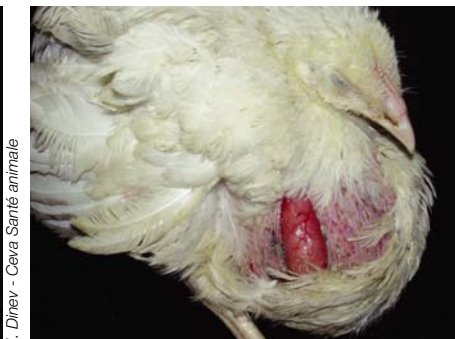

Fig.71.44 & 71.45: Crop impaction caused by accumulation of hard, fibrous feed or litter. The retained content causes putrefactive necrotic processes, affecting the wall of the crop and the covering skin.

Fig.71.46: Gizzard impaction (Poult). The intestine is empty but the gizzard is filled with hard fibrous masses.

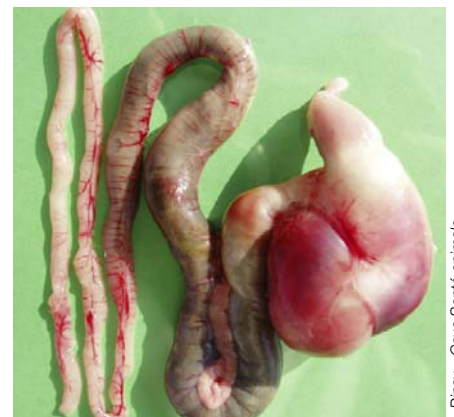
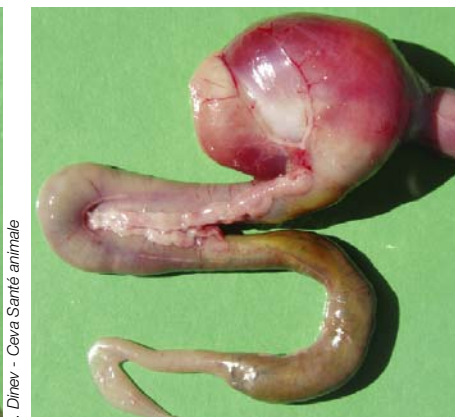
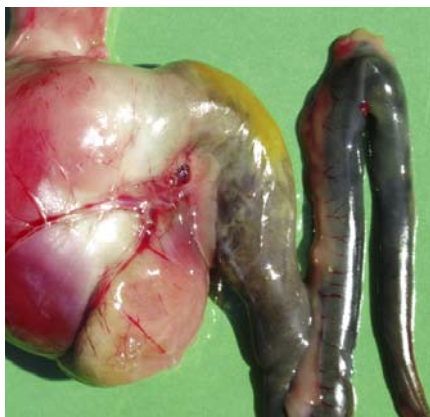Fig.71.47, 71.48 & 71.49: Gizzard impaction (Poult). In some cases the indigestible fibrous masses enter the first part of the duodenum and also the small intestine.

Selenium

There are two major sources of selenium in poultry. Organic selenium, mainly in the form of selenomethionine (SeMet), can be found in many feed ingredients in various concentrations. Inorganic selenium, mainly selenite or selenate, is widely used as dietary supplement. There is a major difference in the metabolism and the efficiency of these two forms of selenium, SeMet being more effective. Compared with inorganic selenium, dietary selenium supplied in its organic form improves the selenium and redox status in broilers, leading to greater resistance to oxidative stress.

In diseases associated with selenium deficiency, such as exudative diathesis, encephalomalacia and muscular dystrophy, selenium and vitamin E have a mutual sparing effect in preventing these diseases (see Vitamin E). Nutritional pancreatic atrophy can also be observed.

Excess of organic selenium, usually as SeMet, results in impaired protein metabolism (SeMet is readily incorporated into proteins instead of methionine). These aberrations result in poor growth rate, watery diarrhea, weakness, cerebellar edema, poor hatchability, hepatotoxicity and/or feather loss.

DISEASES OF THE DIGESTIVE SYSTEM

Pendulous crop

Pendulous crop occurs at a low incidence in chicken and turkey flocks. In severely affected birds, the crop is greatly distended and full of feed, bedding particles, and fluid that is often foul smelling. Birds continue to eat but digestion is impaired. They lose weight and die. The crop mucosa may be ulcerated. There is no muscle tone.

Feed with too coarse fibers, lesions caused by foreign bodies, absence of feed or water that leads to overconsumption when available, and excessive water intake during hot weather may influence the incidence of this condition.

Impaction

Impaction of the crop, proventriculus, or gizzard is occasionally reported in poultry (particularly in turkeys), waterfowl and ratites. This condition occurs when birds eat indigestible fibrous material or litter. In ratites, impaction is commonly due to foreign bodies. Affected birds are emaciated with empty intestinal tract but the affected organ is full of a solid mass of intertwined fibrous material.

DISEASES OF THE LIVER

In contrast with mammals, where lipogenesis occurs mainly in adipose tissue, bird lipogenesis happens in the liver. For this reason, hepatic fat storage is normally observed during two periods of a bird's life: in the first week or two after hatching and at point of lay in hens (to allow the development of the ovary). Note that fatty liver is deliberately produced in ducks and geese as a commercial product (*foie gras*) but in this case, fatty liver is reversible. Liver lipogenic disorders in birds involving excessive fat accumulation are: fatty liver and kidney syndrome (FLKS) (see biotin deficiency), fatty liver hemorrhagic syndrome (FLHS) and hepatic lipidosis of turkeys.

Fatty liver hemorrhagic syndrome (FLHS)

Fatty liver hemorrhagic syndrome is a metabolic disorder that occurs sporadically in commercial layers, particularly in birds kept in cages during hot weather conditions. Dietary energy excess results in a positive energy balance and excessive fat deposition in the liver.

Etiology & pathogenesis

Excess dietary energy induces FLHS regardless of the source. Fat accumulation in the liver and heat stress contributes to the high prevalence of this condition. It is more frequent in overweight birds. Birds housed in cages are more likely affected because they are unable to exercise and burn off the extra dietary energy. Fatty liver hemorrhagic syndrome is most frequently observed in birds apparently healthy and at peak of lay. The excess lipids can affect the hepatic parenchyma. Lysis of reticulocytes and necrosis of hepatocytes with excess fat deposits can explain the hemorrhages.

Other risk factors of FLHS are:

- Nutritional (excess dietary energy leading to obesity in birds, composition of dietary lipids, diet low in lipotropic factors such as choline, methionine and vitamin B12, which favors fat infiltration in the liver while high levels of selenium, vitamin E, and other antioxidants reduce lipid peroxidation and FLHS incidence; aflatoxin has also been considered a possible cause, however it produces different liver lesions);
- Rearing conditions (high temperature, lack of exercise, stress);
- High estrogen, low thyroid hormone levels in the blood;

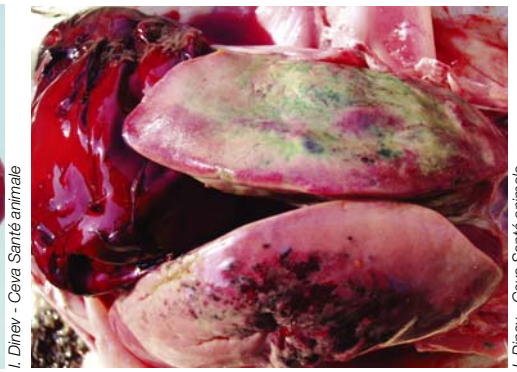
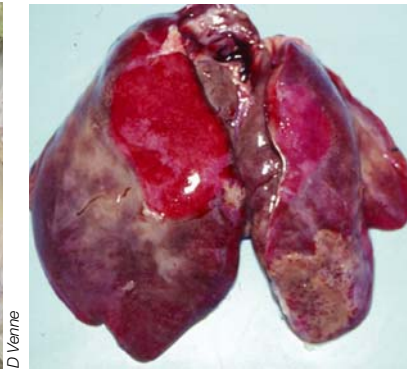
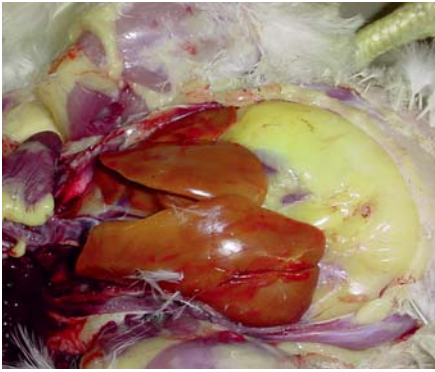


Fig.71.50, 71.51 & 71.52: Fatty liver-hemorrhagic syndrome. Hepatic steatosis and excess of abdominal fat (left). Clinically healthy birds in the same flock may also have hematomas in the liver, either recent and dark red (middle) or older and green to brown (right).

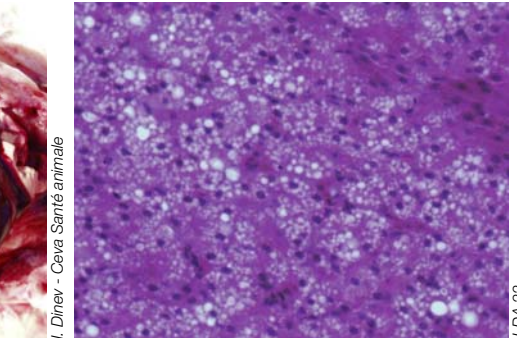
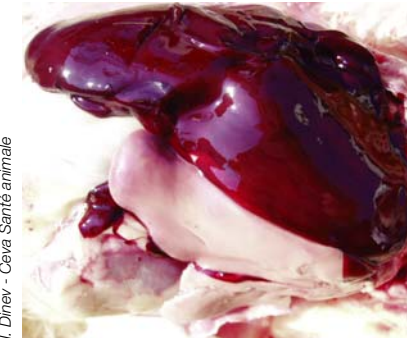
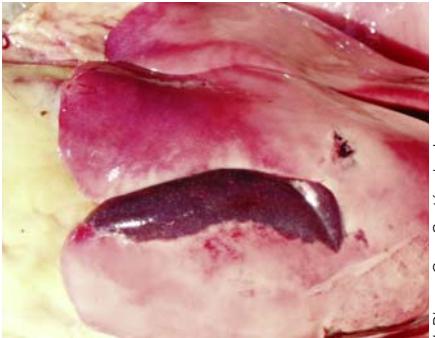


Fig.71.53 & 71.54: Fatty liver-hemorrhagic syndrome. Subcapsular parenchymal hemorrhage can be seen. When the birds are discovered after sudden death, hemorrhages are observed in the liver and may be subcapsular or not.

Fig.71.55: Fatty liver-hemorrhagic syndrome (liver). Important hepatic steatosis and obesity are the main etiologic factors of this syndrome.

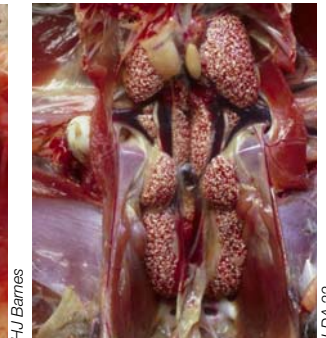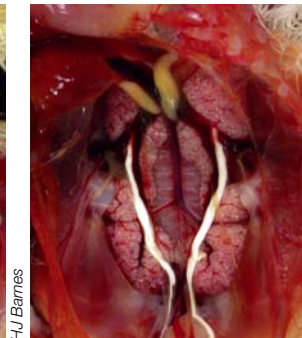
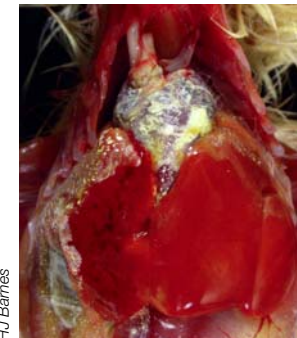
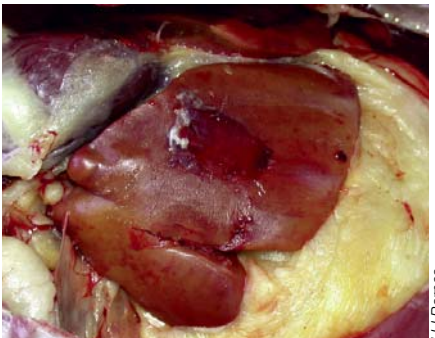


Fig.71.56: Hepatic lipidosis of turkeys. 65 week-old breeder hen with fatty liver hemorrhage.

Fig.71.57 & 71.58: Visceral urate deposition over the heart (left) and the kidneys (right) in a four day-old chick. Note the ureters distended with uroliths.

Fig.71.59: Visceral urate deposition over the kidneys (Fowl).

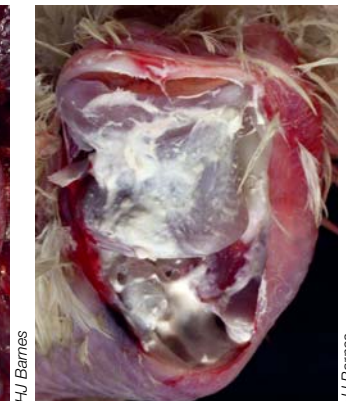
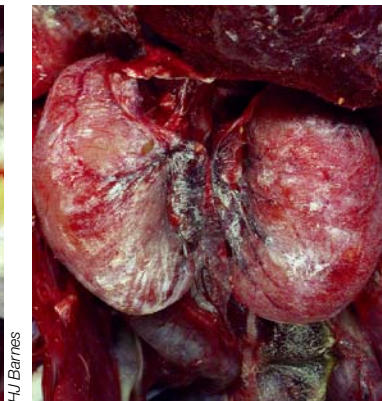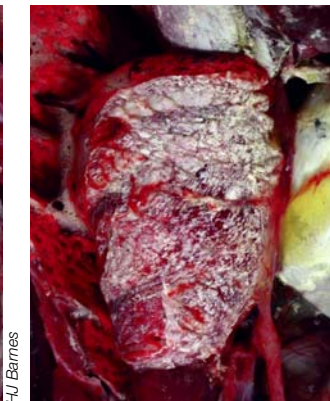

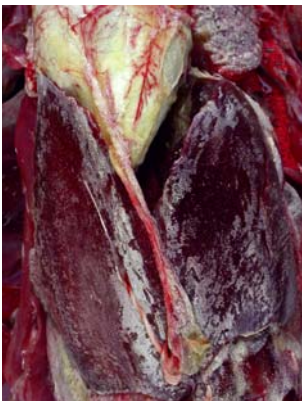
Fig.71.60, 71.61, 71.62 & 71.63: Visceral urate deposition over the liver, the lung and the testis and articular urate deposition in a 35 week-old broiler breeder male.

- Genetic (the average lipid content in the liver of different strains of layers varies from 25% to about 50%).

The combined actions of these different factors produce enlarged and friable livers easily prone to bleeding.

Clinical signs

The first sign of FLHS is a small increase in mortality (up to 5%). Hens become increasingly obese (25-30% above normal weight) with a drop in egg production (30% or more). Some birds die suddenly with pale comb and wattles.

Birds with this disease will have large amounts of fat in the liver and around organs in the abdominal cavity. Dead birds have large blood clots in the abdomen near the liver. The liver appears yellow, enlarged, pale and friable; it may have smaller hematomas within the parenchyma. Sometimes the hepatic capsule does not rupture and a large hematoma remains in the liver of surviving hens. Most hens have active ovaries.

Blood biochemistry confirms the hepatic disease (increased AST and other liver enzymes). Laying hens have higher levels of calcium and phosphorus. The lipid content of the liver generally exceeds 40% dry weight and may reach 70%.

Treatment & control

First action should be to reduce the amount of dietary energy in order to reduce the incidence of obesity in laying hens. This can be achieved by replacing some of the corn by lower energy feedstuffs such as wheat bran. If a complete layer ration is prepared, addition of vitamins can be of benefit.

The only successful remedy for this condition is body fat control, which can be achieved by regulating total energy intake.

Hepatic lipidosis of turkeys

Hepatic lipidosis of turkeys, also named acute hepatic necrosis, has been reported in turkey breeder hens between 12 and 24 weeks of age.

The cause is unknown although nutritional and management factors can be involved: low protein diet, deficiency in lipotropic factors (methionine and cysteine), high ambient temperature, light

reduction at about 16 weeks, picornavirus-like particles suggestive of avian encephalomyelitis, *etc.*

Clinical signs are an abrupt increase in mortality (up to 5%) during one to two weeks. The liver is enlarged and has a variable number of contrasting pale yellow and dark red zones.

DISEASES OF THE URINARY SYSTEM

An overload of the kidney leads to organ dysfunction with precipitation of insoluble products within the kidney itself or other organs such as urate deposits (gout) or urolithiasis.

Urate deposition (gout)

Uric acid is made in the liver and is the final product of nitrogen metabolism in birds. Urate deposits are secondary to the abnormal accumulation of urates and must be considered as a clinical sign of severe renal disorder. Clinicians use the terms «visceral gout» or «articular gout» but gout is a historical misnomer: the correct term is urate deposition or hyperuricemia. However, we are also using these common field expressions below.

Visceral urate deposition (visceral gout)

Visceral urate deposition is a common finding during necropsy in poultry and is characterized by precipitation of urates in the kidneys and on serous surfaces of the heart, liver, mesenteries, air sac and/or peritoneum. In severe cases, surface of muscles and synovial sheaths may be involved and precipitation may occur within the liver, spleen and other organs.

Visceral gout is generally due to a failure of urinary excretion: obstruction of ureters, renal damage or dehydration (particularly after water deprivation, the most common cause). Other causes of visceral gout are infectious (nephritic strains of infectious bronchitis virus, renal cryptosporidiosis) and non infectious (vitamin A deficiency, mycotoxin, treatment with sodium bicarbonate, feeding pullets with rations high in calcium and proteins, *etc.*).

Articular urate deposition (articular gout)

Articular gout, unlike visceral gout, is a sporadic problem of little importance in poultry. It is characterized by *tophi*, which are deposits of urates around joints, particularly those of the feet (looking like bumble foot). It is probably due to a

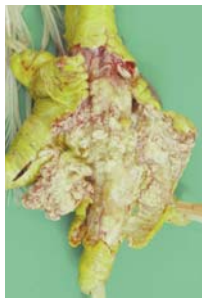
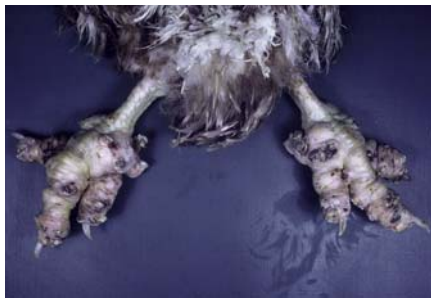

Fig.71.64 & 71.65: Articular urate deposition (articular gout) in adult fowl with enlargement and deformities of toes and feet. At opening, the periarticular tissue is white due to urate deposition.

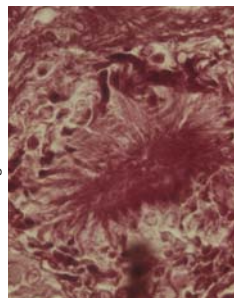


Fig.71.66: Urate crystal (*tophi*) seen at microscopic observation.

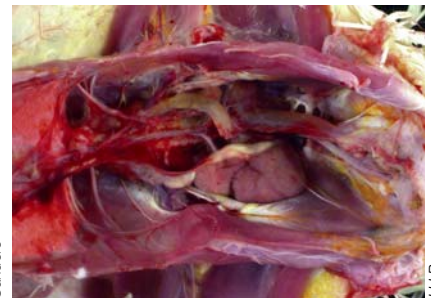

Fig.71.67: Urolithiasis (96 week-old layer). Note the severe atrophy of the anterior lobes of the kidney and the compensatory enlargement of the posterior right lobe.

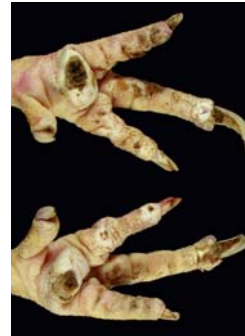

Fig.71.68 & 71.69: Contact dermatitis (Chicken). Pododermatitis. The lesions can be scored: 0 (normal), 1 (slight plantar injury), 2 (lesion of the greater part of the pad) and 3 (ulceration of the pad) (See also Fig.71.34).

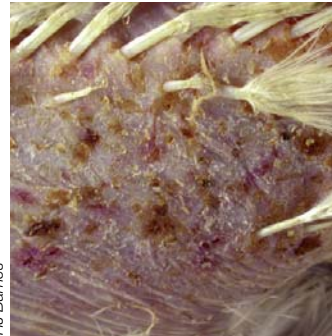


Fig.71.70: Contact dermatitis (42 day-old broiler).

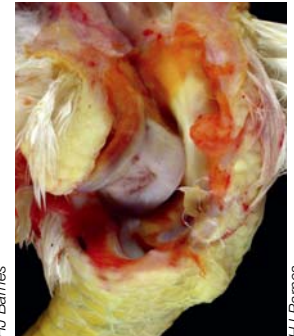

Fig.71.71: Hock amyloid arthropathy (35 week-old broiler breeder hen).

metabolic defect in the secretion of urates by kidney tubules following a high protein diet.

Urolithiasis

Urolithiasis is primarily seen in pullets and caged laying hens and causes increased mortality and decreased egg production. Urolithiasis is characterized by severe atrophy of one or both kidneys, distended ureters often containing uroliths, and various degrees of renal and visceral urate deposits. Formation of uroliths may be due to high levels of urinary calcium and decreased hydrogen ions in the urine. Various nutritional or metabolic related factors have been identified:

- Excess dietary calcium, in particular if combined with low available phosphorus (phosphorus acts as a urinary acidifier and helps prevent stones from forming in the kidneys);
- Excess in dietary protein (30-40%) can produce urolithiasis in birds under experimental conditions;
- Dietary electrolyte imbalances: NaHCO_3 is sometimes used to improve eggshell quality or combat the effects of heat stress, but it may also contribute to urolithiasis by making the urine more alkaline, which, with high levels of calcium, is an ideal medium for the formation of kidney stones;
- Feeds contaminated by nephrotoxic mycotoxins such as ochratoxin A;

- Water deprivation;
- Vitamin A deficiency over a long period of time can cause damage to the lining of the ureters.

If gout does occur in a flock, increasing the urine's acidity to dissolve existing kidney stones can reduce mortality. Use of ammonium chloride or ammonium sulfate can achieve this. After 4-6 weeks at the maximum treatment level, if the desired results have been obtained, a gradual reduction may be attempted. However, continuous treatment will likely be needed for the rest of the flock's life.

Avoid any diet that increases urine alkalinity in combination with high calcium levels.

DISEASES OF THE CIRCULATORY SYSTEM (see Chap.IV.70)

BONE DISORDERS (see Chap.IV.69)

DISEASES OF MUSCLES AND TENDONS (see Chap.IV.69)

DISEASE OF THE INTEGUMENTARY SYSTEM (contact dermatitis)

Also known as «footpad dermatitis in poultry», «foot burn», «hock burn», «breast burn» in

chickens, «breast buttons» in turkeys, contact dermatitis is characterized by erosive lesions affecting the skin on the plantar aspect of the feet, the posterior surface of the hocks, thighs, or the sternum. This condition occurs in any type of poultry raised on deep litter.

Although the incidence in footpad dermatitis can be high, these lesions do not contribute directly to carcass downgrading; but they may result in lameness and lower body weight. Once the skin is broken, painful ulcers can develop and, in severe cases, lesions can act as an entry point for secondary infections. Contact dermatitis is a serious welfare problem in poultry. In addition to being a welfare issue, it is also an indication that there are litter management problems or diet imbalances affecting profitability.

Etiology

The biggest factor is wet or damp bedding and a number of studies have shown that high moisture in litter can, by itself, be enough to cause contact dermatitis in birds. It is also influenced by dietary factors (methionine, biotin, Zn, Cu and Mo deficiency, low protein digestibility, and high unsaturated fats, excess of dietary salt increasing water consumption generating wet litter) and diarrhea. A high or low litter pH (ammonia in the environment or addition of high acid levels in the feed) will also increase the corrosive effect of litter.

Clinical signs & lesions

Footpad dermatitis appears as dark black scab filling ulcers on the footpad. The incidence of contact dermatitis is usually measured by observing the plantar surface of the feet where ulceration of the skin can occur. In general, it starts as hyperkeratosis, erosions and skin discoloration that may progress to ulcers. In the most serious cases, we may observe necrosis of the epidermis, pain, locomotion problems, and ulcerations with inflammatory reactions of the underlying tissues. The associated lesions can vary in size and depth.

Control

Good litter management is critical (use of nipple drinkers reduces the incidence of this condition). Wood shavings appear to be a good litter substrate.

AMYLOIDOSIS

Amyloidosis is characterized by deposition of proteinaceous material between cells in different

tissues and organs. Birds of all ages are susceptible to amyloidosis, but it is most common in adults, although it can occur in ducks as young as four weeks of age. Ducks are the most susceptible type of poultry.

Brown layers are particularly susceptible to amyloid arthropathy caused by *Enterococcus faecalis* and by *Mycoplasma synoviae*. Other bacteria such as *Escherichia coli*, *Salmonella* Enteritidis, *Mycoplasma gallisepticum* and *Staphylococcus aureus* have also been associated with amyloidosis in chickens, following severe disturbances in protein metabolism. Amyloidosis is also associated with hepatitis E virus and mycobacteriosis.

No specific clinical signs or gross lesions are associated with systemic amyloidosis. Amyloid deposition may be found in any tissue. Liver, spleen, intestine and kidney are the most commonly affected organs. The affected organ is pale and enlarged with stretched capsule and rounded margins. Severe lesions are associated with ascites, which is most common in ducks.

REFERENCES

- Brugère-Picoux J & Brugère H. A propos de la stéatose hépatique chez les volailles. *Rec Méd Vét*, 1974,150:1023-1030.
- Crespo R & Shivaprasad HL. Developmental, metabolic and other non infectious disorders. In *Diseases of poultry*, Ed. Swayne DE, 13th ed., Wiley-Blackwell Publ. 2013, pp 1233-1270.
- Garland PW & Pritchard S. Nutritional diseases. In "*Poultry diseases*" sixth edition Saunders Elsevier 2008, p 510-535.
- Haslam SM et al. Factors affecting the prevalence of foot pad dermatitis, hock burn and breast burn in broiler chicken. *Br Poult Sci*,2007,48:264-75.
- Klasing KC. Nutritional diseases. In *Diseases of poultry*, Ed. Swayne DE, 13th ed., Wiley-Blackwell Publ. 2013, pp 1205-1232.
- Mayne RK et al. Footpad dermatitis develops at an early age in commercial turkeys. *Br Poult Sci*, 2006,47:36-42.
- Morrow C. Management as a cause of disease in poultry. In "*Poultry diseases*" sixth edition Saunders Elsevier 2008, p 536-547.
- Riddell C et al. Case Report: Fatty liver and kidney syndrome in a Broiler Flock. *Avian Dis*, 1971,15, 398-405.
- Schwartz LD. Poultry Health Handbook 4th Ed. Pennsylvania State University,1994 (19).
- Shivaprasad HL. Nutritional diseases. In "*Avian diseases manual*". Ed. M. Boulianne. 2013, pp184-192.
- Tremblay A & Bernier G. Maladies d'origine nutritionnelle et métabolique. In "*Manuel de pathologie aviaire*", Ed. Brugère-Picoux J & Silim A. Maisons-Alfort, 1992, pp 343-354.

Virus	Bacteria	Protozoa
Turkey coronavirus	<i>Escherichia coli</i>	<i>Cryptosporidium</i>
Turkey astrovirus	<i>Salmonella</i> spp.	<i>Cochlosoma</i>
Rotavirus	<i>Campylobacter</i> spp.	<i>Trichomonas</i>

Tabl.72.1: Infectious agents associated as causes of PEMS.

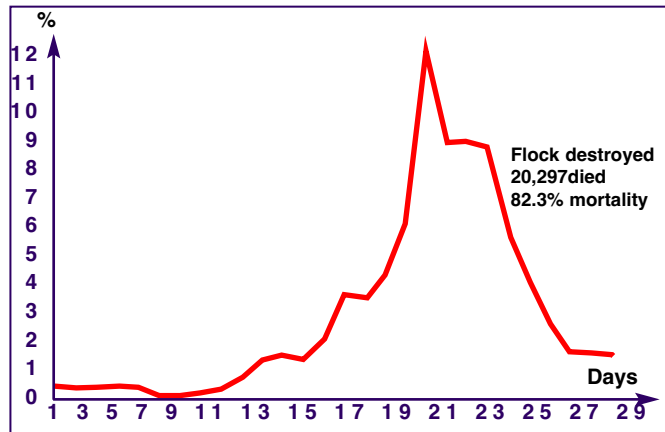


Fig.72.1: Typical mortality curve for a severely affected flock. This was the "index" case. Mortality at 6 weeks was 43%. Normally a flock like this badly affected would have been destroyed when mortality reached approximately 50%, but this flock was held longer to obtain samples and for study. Mortality during a 7-hour-period on day 19 was 5%. A flock with total mortality due to PEMS of 96% has occurred.

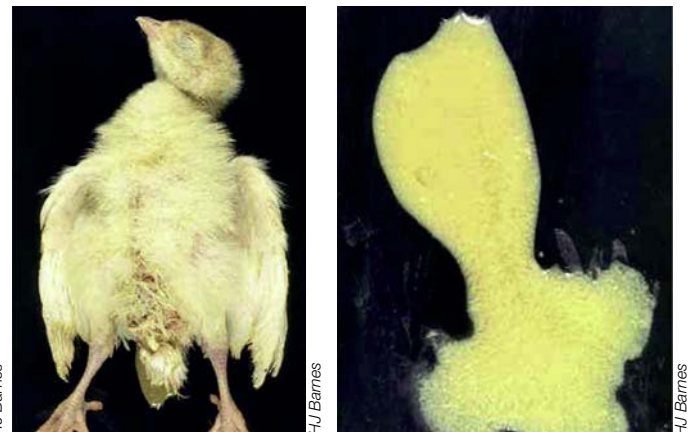

Fig.72.2 & 72.3: Experimental poult day 3 post exposure (PE). Note fecal staining of feathers and watery brown droppings leaking out the vent. Mortality on day 3 is uncommon; peak mortality occurs on days 5-7 PE. Typical droppings (from the dead poult of Fig.72.2). Note the fluorescent nature of the droppings indicative of a high protein content.

Section IV

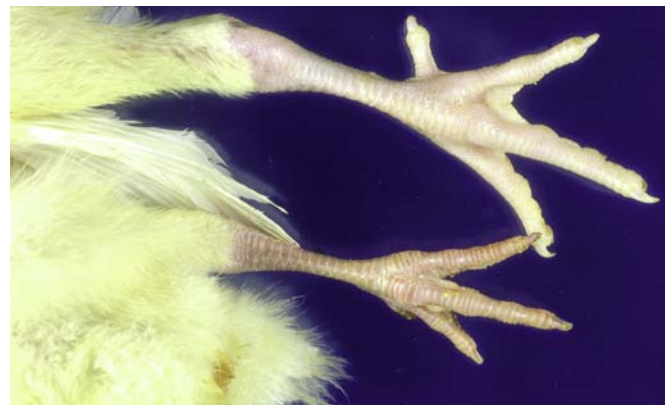

Fig.72.4: Dehydration and marked decrease in body weight rapidly follow onset of diarrhea. Affected bird (bottom) compared with control (above). Note smaller size, dark shanks, and diarrhea.



Fig.72.5: PEMS. Marked lack of uniformity in the turkey flock.

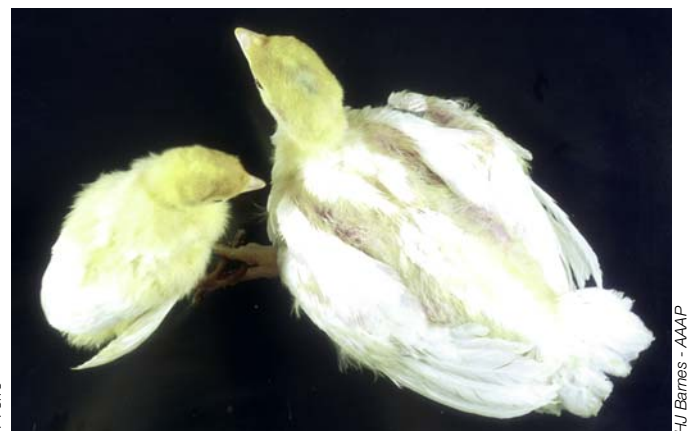

Fig.72.6 & 72.7: Severe stunting is seen in PEMS survivors. Both poults have the same age. French cases of PEMS observed in the field (Fig.72.6). In Fig.72.7, 21-day-old small poult is the only survivor out of a group of 14 (93% mortality) poults exposed by contact and weighing 28% of the unexposed control on right.

Other diseases

72. POULT ENTERITIS MORTALITY SYNDROME

INTRODUCTION

Enteric disorders have been among the most costly health problems affecting the turkey industry worldwide. Poultry enteritis mortality syndrome (PEMS) is part of the Poultry enteritis complex (PEC). It was first defined in the early 1990's in Southeastern United States, but historical data suggest that it might have been present earlier and elsewhere, just not reported. From 1994 to 1996, PEMS was quite predictable in terms of date at first occurrence (21st week of the year), prevalence, severity, and geographical distribution. At the farm level, one could also predict recurrence in previously affected farms. By 1997, two different patterns of disease were recognized based on the degree of severity of the syndrome, defined by the mortality rate. In both cases, the disease affected poults mainly between 7 and 28 days of age. Today, age at risk is no longer limited to the first month of life; indeed, it now covers the entire brooding period (>1 week - up to 6 weeks):

Spiking Mortality (SMT)

- Mortality $\geq 1\%$ per day for at least 3 consecutive days
- Mortality $\geq 9\%$ during a three-week period

Excess mortality (EMT)

- Mortality does not reach or exceed 1% per day for 3 consecutive days
- Mortality exceeds 2% but is less than 9% during a three-week period

ETIOLOGY

There is not a simple etiology associated with this syndrome. There is a consensus that PEMS is caused by more than one agent, probably a virus in association with other viruses (e.g., coronavirus) and/or bacteria (e.g., *Escherichia coli*) and/or protozoa (e.g., *Cochlosoma*, pironucleus, cryptosporidia). A clinical trial conducted in the mid-90's suggests that PEMS contaminated material is not able to cause severe mortality (SMT) after a relatively short period of storage (possibly only a few hours).

Agents capable of causing stunting may persist for at least 10 weeks. This finding is consistent with the hypothesis that some PEMS agents may be harbored in one or several reservoirs outside the turkey house and may be reintroduced to subsequent flocks *via* vectors. This would explain why depo-

pulated and disinfected premises can be the site of new PEMS outbreaks. Pests such as flies and darkling beetles are potential vectors for agents involved in PEMS.

It has been demonstrated that PEMS can be transmitted by direct contact between infected chickens (no clinical signs) and susceptible turkeys. However, efforts to determine the presence of PEMS agents in chicken flocks using turkey sentinels have been fruitless. This is interesting because it has been established experimentally that turkey coronavirus can grow in chickens, and co-infecting poults with turkey coronavirus and an enteropathogenic *Escherichia coli* reproduces PEMS under experimental conditions.

EPIDEMIOLOGY

This syndrome, observed mainly in high density turkey producing regions, is seasonal. Most of the cases in the Southeastern United States are reported between May and September of each year, when temperatures and humidity increase. However, outbreaks in Texas have occurred during winter time. The prevalence of the disease increased from 1991, when it was first recognized, to 1996. The severity of the disease reached a peak during that year. Many flocks were destroyed after mortality exceeded 50%. On one occasion, the grower elected to keep the flock until it reached market age. He was left with 4% of his flock (96% mortality), and these birds were severely stunted. However, 1997 and 1998 saw a drop in the number and in the severity of PEMS outbreaks. In 1998, the incidence varied between 6 and 14% of all flocks at risk from late May until mid-August. Since the early 2000s, very few cases resembling the "spiking mortality" observed in 1996 have been reported. Field veterinarians from Canada, Brazil, Portugal, France, and Israel believe that PEMS has been occurring in their respective country.

In an investigation conducted on 52 North Carolina farms, it was determined that the hatchery of origin, the removal of used litter by a contractor, rodent control measures, and pets in the production area were associated with PEMS affected farms. Rodent control measures may be a consequence more than a risk factor for the disease; indeed flies, beetles, and/or other arthropods are suspected to be vectors. Factors found not to be associated with



Fig.72.8: PEMS. Occasional survivors have abnormally brittle feathers, which gives the "helicopter" appearance seen here and also described in runting/stunting.

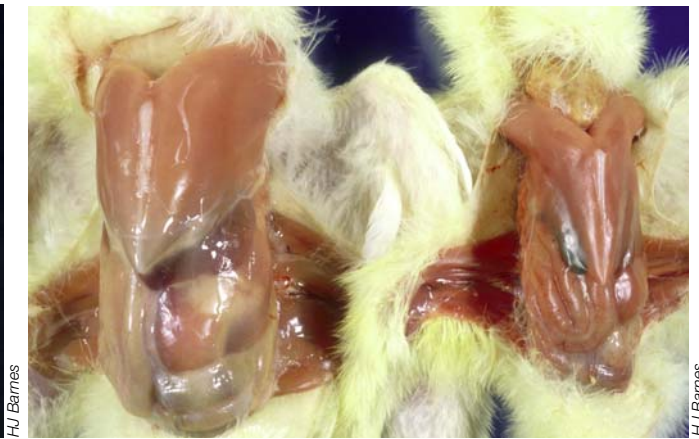

Fig.72.9: PEMS. Note loss of muscle mass compared to normal control (left). Not only is the affected turkey (right) failing to grow and develop, it apparently is consuming its own tissues to survive.

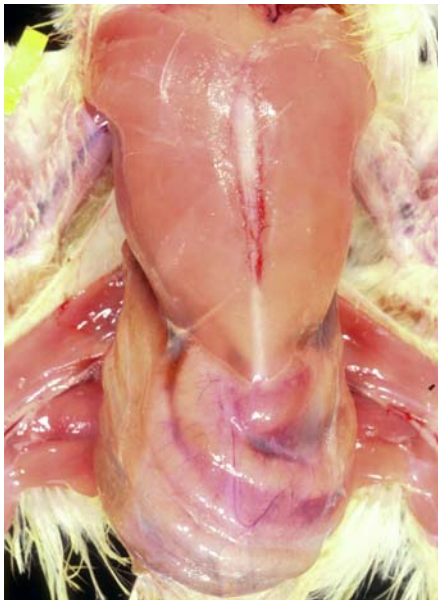

Fig.72.10: PEMS. Appearance of dead bird early in the course of disease. The abdomen is distended because of swollen, fluid-filled intestines. Dehydration and stunting are not apparent yet.

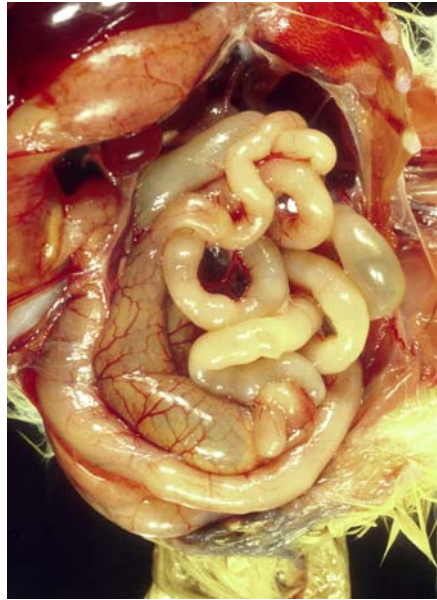

Fig.72.11: Abdomen opened to show the pale, thin-walled, fluid-filled intestines typically seen in poult with PEMS. These changes are not specific but can also be seen in many forms of enteritis in young turkeys.

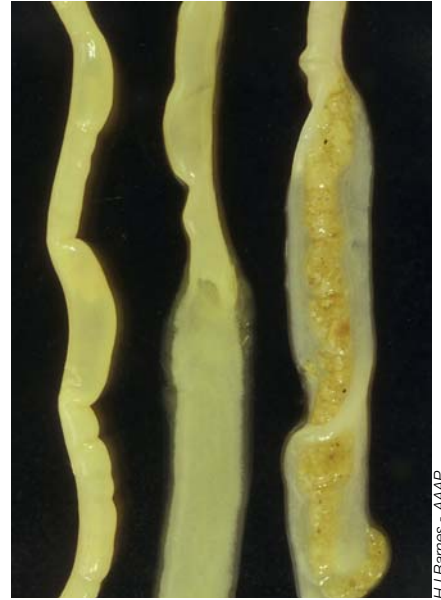

Fig.72.12: Acute enteritis, day 4 PE. Saccular, fluid-filled, pale, thin intestines are typically seen in enteritis affecting poult including PEMS. A soft yellow-brown cast is present in one section.

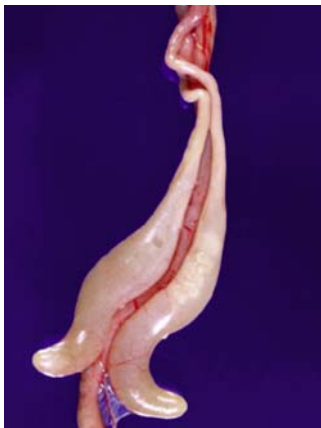

Fig.72.13: Experimental PEMS, day 7 PE. Ceca markedly distended with watery, pale brown fluid.

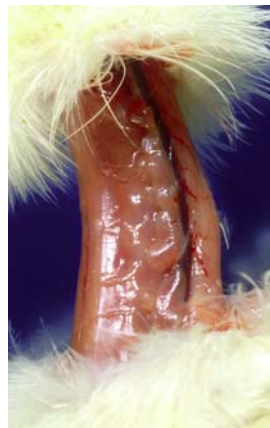
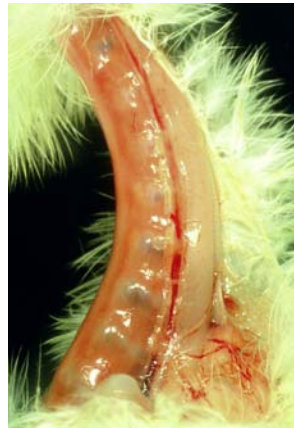
Fig.72.14, 72.15 & 72.16: Thymus of birds with PEMS. Note the marked atrophy of Fig.72.15 by comparison with normal thymus of Fig.72.14.



Bursal atrophy occurs also in poult with PEMS (Fig.72.16), spleen can be also atrophied but the thymus is generally the most severely affected of the lymphoid organs.

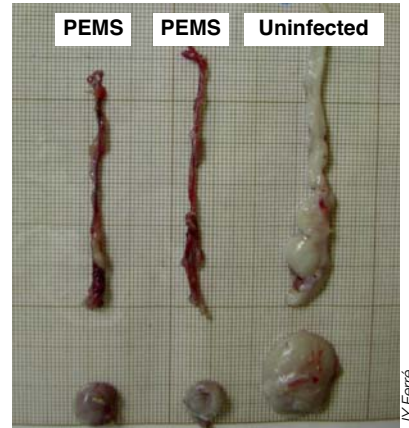


Fig.72.15: Thymus of birds with PEMS. Note the marked atrophy of Fig.72.15 by comparison with normal thymus of Fig.72.14.

PEMS included: breed, the integrated company with whom the growers had a contract; proximity to cattle or hogs; distance of turkey houses from roads or trees; and the method of dead bird disposal. However, farm location was a significant risk factor. Flocks located within a mile (1.6 km) of an affected flock were at greater risk of contracting PEMS compared to flocks located farther away. Flocks on multiple age farms were also more likely to get PEMS than flocks on all-in/all-out production sites.

It was also demonstrated that mortality associated only with PEMS was limited to the brooding period. Excess mortality observed later in the grow-out period was essentially due to turkey coronavirus infection. Although reports in the field suggest that the disease is more severe in females than in males, this observation is very likely due to the difference in flock management for these two groups. Once PEMS is on a farm, other conditions appear to be more prevalent than usual. In Texas, the most common diseases associated with PEMS were colibacillosis, salmonellosis, rickets, and protozoal enterotyphlitis. There is no evidence that PEMS is vertically transmitted, and there is no public health concern associated with this disease.

CLINICAL SIGNS

Features of the disease include diarrhea, dehydration, weight loss, anorexia, growth depression, and death. Growth depression often exceeds 40%; and PEMS survivors show no compensatory growth. Onset of the disease is sudden with morbidity approaching 100%. Initially the flock stops eating, is restless (large group of poults may be observed running in circles) and noisy. Diarrhea quickly follows the initial signs, leading to a quick deterioration of litter and housing conditions. It is mainly an osmotic type diarrhea because of maldigestion and malabsorption. Diarrhea may be less obvious in SMT flocks because most affected birds die suddenly.

After a few days, a different odor from a normal flock can readily be perceived. Survivors are withdrawn with ruffled feathers (known as helicopter birds because many feathers are at different angles from one another). Birds are chilled and tend to huddle together near heat sources.

Mortality climbs rapidly exceeding 1%/day for several days in SMT cases. Mortality may exceed 10%/day in severe outbreaks; after 3 to 5 days, it will decline but remain above normal for several more days.

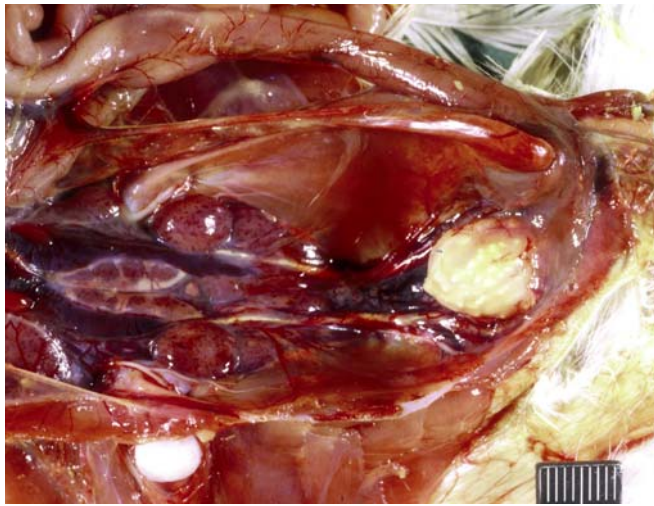LESIONS

There are no pathognomonic lesions allowing the diagnosis of PEMS. Typical PEMS birds show lesions observed with acute severe diarrheal disease. Affected poults are often dehydrated, emaciated with marked muscle atrophy, and some birds may have osteoporosis or rickets. Birds are stunted with soiled and poor feathering, crusted foot pads, and a distended abdomen with a pasty vent. Pale brown droppings are observed on the litter. Other observations include enlarged gallbladder filled with thick, dark bile; prominent adrenal glands; litter found in the gastrointestinal tract instead of feed; occasionally crop mycosis; thin-walled, dilated intestine containing fluid and gas; distended ceca with watery brown material and gas; swollen kidneys (occasionally) with excess urates in the ureters; cloaca distended with diarrheal material and urates. PEMS birds are hypercalcemic and hypophosphatemic. These significant metabolic alterations are associated with malabsorption. Survivors exhibit severe growth depression (stunting), often weighting less than half of non affected birds.

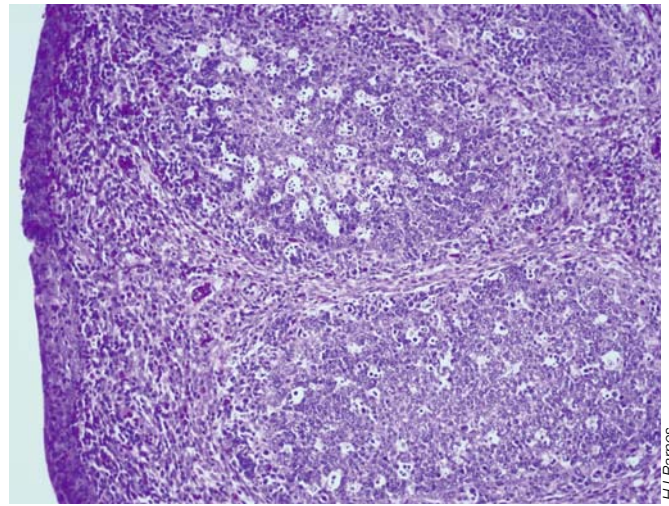
The thymus in these birds undergoes atrophy and may be extremely small. A less severe atrophy is noted for the bursa of Fabricius and the spleen. Firm caseous material may be found in the bursa of Fabricius of about 10% of affected birds (bursal core). Several studies have clearly demonstrated that the integrity of the immune defense mechanisms (humoral, cellular, and macrophages) is greatly disturbed in PEMS affected birds. Immune dysfunction is considered to be a major factor responsible for the severity of the disease.

The most typical microscopic lesions of PEMS are found in the intestinal and bursal mucosae. Epithelial cells appear to be the target cells for viral infection. An acute enterotyphlitis can be observed with villous atrophy and crypt epithelial hyperplasia. The *lamina propria* is infiltrated with a mixed cell population, often including necrotic macrophages. Heterophils are found in the lumen, as well as a proteinaceous exudate.

The epithelial cells of the bursa are swollen and pale. These are shed with a proteinaceous exudate and heterophilic inflammation. Instead of a tall pseudostratified epithelium, one observes a transitional or, occasionally, a stratified squamous epithelium. An increase in apoptosis in the bursal follicles results in lymphoid depletion. The bursal core found in some of the affected birds is made of

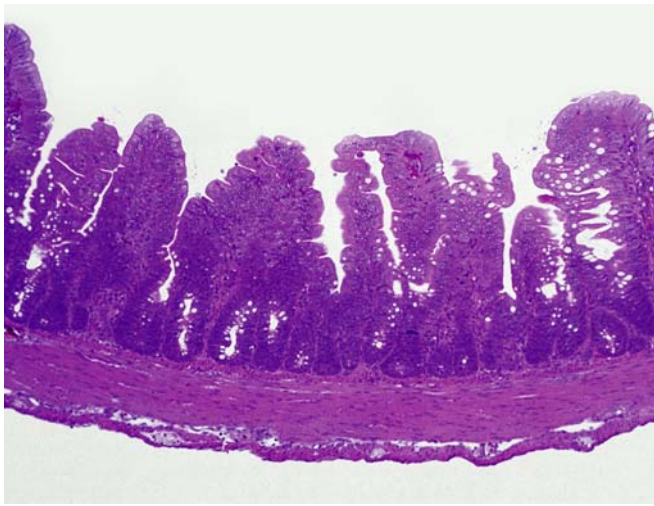


HJ Barnes

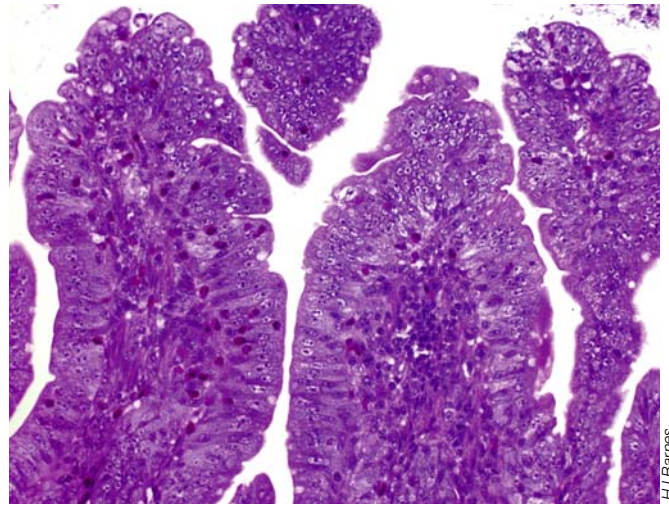


HJ Barnes

Fig.72.17 & 72.18: Firm caseous material in the bursa of Fabricius (bursal core) because particularly of epithelial changes induced by turkey coronavirus. Histology shows cell necrosis and hyperplasia with heterophilic infiltration (hematoxylin & eosin).

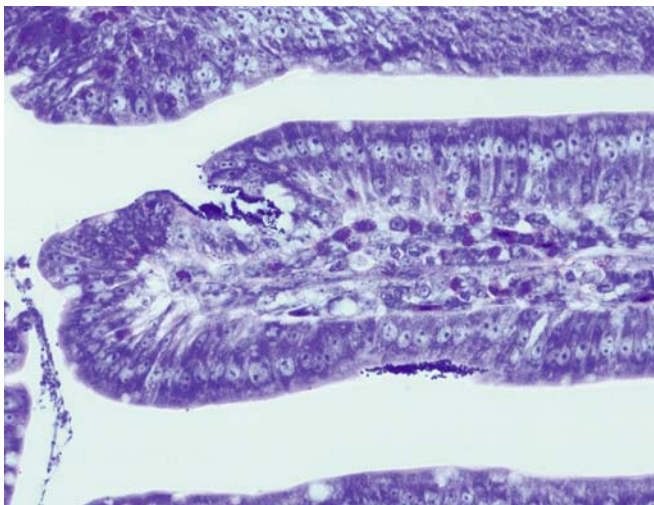


HJ Barnes

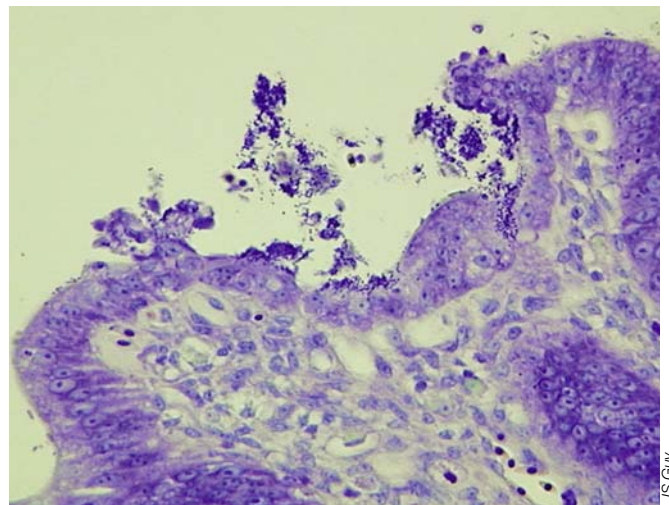


HJ Barnes

Fig.72.19 & 72.20: Experimental PEMS, day 4 post-exposure (PE). Villi are contracting giving them a pleated appearance. Excess protein is present in the lumen (hematoxylin & eosin).



HJ Barnes



JS Guy

Fig.72.21 & 72.22: Enteritis. Experimental PEMS with enteropathogenic *Escherichia coli* (EPEC), Giemsa stain.

Section IV

luminal exudate, bacteria, and heterophils. Finally, lymphoid depletion is evident in the spleen and thymus.

DIAGNOSTIC

Because PEMS is believed to be the consequence of the interaction of more than one infectious pathogen, there is no formal diagnostic test available. The diagnosis is based on the mortality pattern, the absence of an identifiable cause for the observed clinical signs, and the presence of lesions and clinical signs consistent with PEMS. Some known agents occasionally associated with the syndrome can be identified, such as turkey coronavirus (immunofluorescence, PCR, serology).

Electron microscopy, cultures, PCR, cytology and wet smears (for protozoa) are all diagnostic techniques that may be used to identify infectious pathogens associated with PEMS. Sentinels placed into affected flocks have been used to obtain diagnostic material from birds in the early stage of the disease. It can also be reproduced by feeding feces or intestinal material from affected birds to susceptible poults. Reproducing the disease in this manner facilitates the collection of early samples, optimizing the probability of virus identification.

TREATMENT

Current intervention strategies have drug and management components. These are basically the same for PEMS and TCV.

Given the viral nature of PEMS, no “silver bullet” exists. Supportive care is needed at the early onset of clinical signs. This includes water soluble multiple vitamin preparations with vitamin E at twice the recommended level (because of its antioxidant properties, which help stabilize the intestinal villus epithelial cells); and water soluble antibiotherapy when elevated mortality is observed due to coinfection. Impression smears of the intestines should be performed to determine whether gram-positive or gram-negative bacteria are dominant. Gram-positives appear to be more frequently observed.

Once the disease is present, antibiotherapy may lessen mortality but will not prevent morbidity, in particular stunting. Broad-spectrum antibacterials are not recommended within the first 10 days of age because of their possible impact on the normal intestinal microflora.

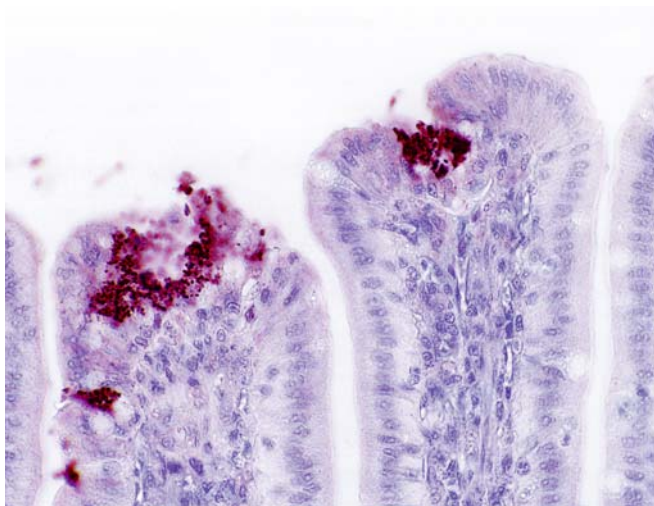
Probiotics have been used without much success. If coccidia are predominant, the current anticoccidial program must be reviewed.

Palliative care is not complete without sustained efforts to optimize the environment. A slight increase of the ambient temperature (1-2°C) is often needed because the birds are chilled. Indeed, higher mortality has been observed at 34 *versus* 36.5°C during brooding, even under dry conditions. When litter moisture increases, mortality also increases at 34 and 36.5°C. Every effort should be made to keep the litter as dry as possible (using ventilation, tilling, top dressing with fresh litter if needed). Finally, any action that will increase feed intake should have a positive effect. Some have top dressed the feed with sparkling products used in cake preparation; others have moved the feed line up and down or have activated it more frequently to attract the birds attention. No scientific data exist to corroborate any of these. However, any attempt to keep the birds focused on the feed, and not on the litter, is worth trying. Efforts to reduce the impact of PEMS by adding sucrose and potassium phosphate in the drinking water has only delayed PEMS mortality.

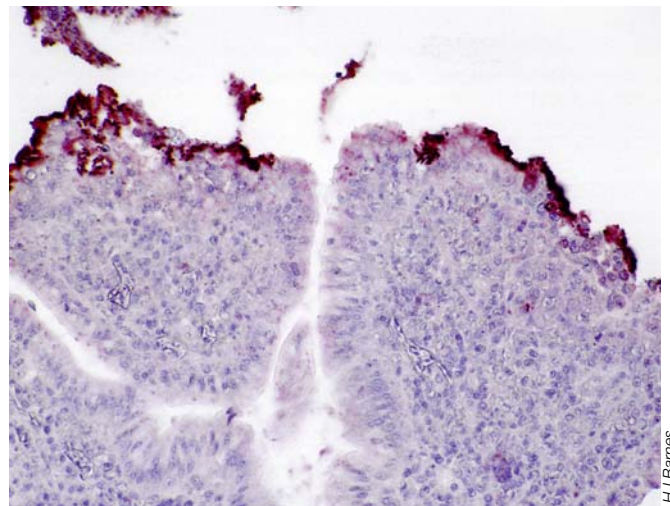
Treatment of affected flocks with the WHO rehydration formula (3.5g NaCl, 2.5g NaHCO₃, 1.5g KCl, 20g dextrose/liter) could be used for providing balanced electrolytes and energy. However, adding carbohydrates such as dextrose to the drinking water of poultry can promote bacterial proliferation unless it is promptly consumed. Cleaning waterers and providing chlorinated water is crucial because birds are more susceptible to bacterial infections. Finally, stunted birds weighing less than 50% of the flock average should be culled.

CONTROL

Enteric disorders of turkeys are multifactorial; often the result of the interaction of infectious, management, environmental, and nutritional factors. PEMS is no exception. The best way to control PEMS is to prevent its occurrence. Given the infectious nature of the disease, major efforts have gone towards improving biosecurity (in particular, limiting movement of people from farm to farm). A downtime between flocks of at least 2 weeks after cleaning and disinfection is recommended. Dead bird disposal and pest control (rodents, wild birds, pets, flies, darkling beetles) must be reviewed and upgraded, if at all possible.

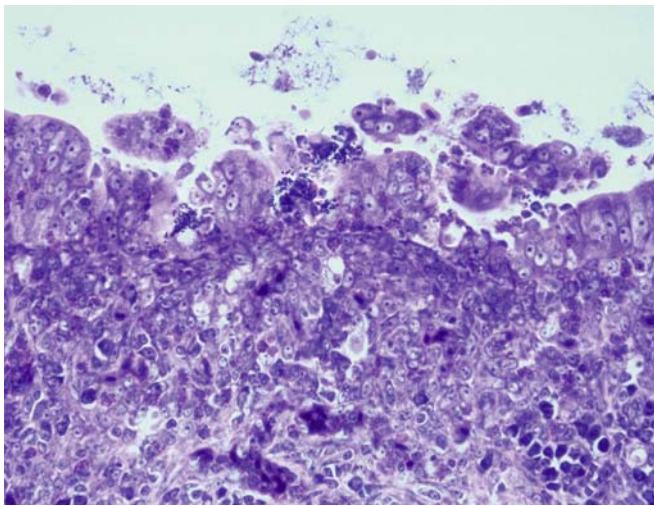


HJ Barnes



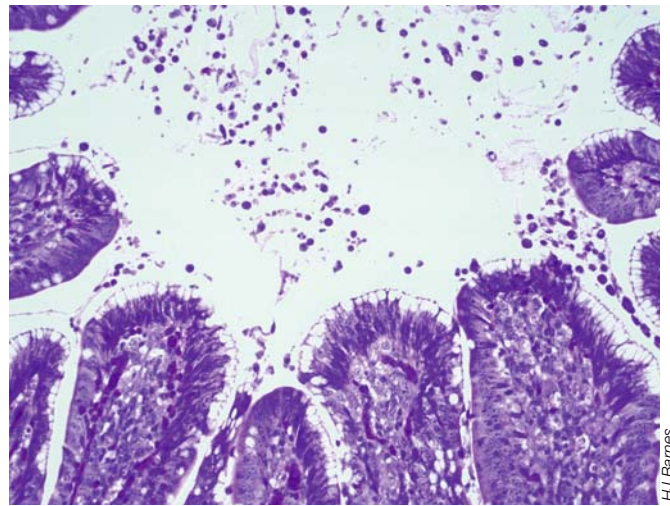
HJ Barnes

Fig.72.23 & 72.24: Enteritis and typhlitis (dual infection with EPEC and TCV). Immunoperoxidase staining of TCV in jejunum (Fig.72.23) and cecum (Fig.72.24).



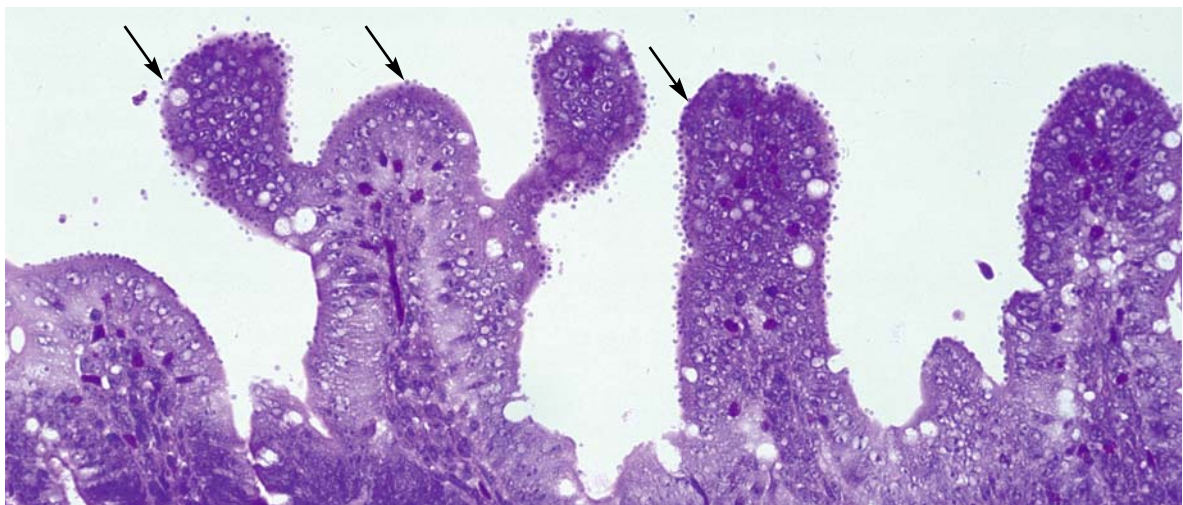
HJ Barnes

Fig.72.25: Typhlitis. PEMS reproduced experimentally by dual infection with TCV and EPEC.



HJ Barnes

Fig.72.26: PEMS. Enteritis (jejunum) with vacuolated enterocytes.



HJ Barnes

Fig.72.27: Cryptosporidia (arrows) are commonly associated with severe outbreaks of PEMS.

A regional approach to the problem involving all companies and individuals producing turkeys in an endemic area may be needed to substantially reduce the incidence in the region. This includes: disease notification to all involved personnel, on-farm quarantines (could be regional), and depopulation (farm and regional).

Clinical evidence shows that eggs from new breeder hens (<7 weeks in production) should not be used for at risk farms because smaller poults are more susceptible to PEMS.

The feed itself should be of top quality. A feed lower in protein (24-26%) in the starter feed is recommended. This protein level contributes to maintain the upper small intestinal pH, which may help preserve intestinal integrity. The quality of fat in the diet should also be stressed because fat rancidity *per se* can be sufficient to trigger diarrhea in turkeys. A poult's response to PEMS is influenced by nutrition. To be effective at all, diet modifications should be made early in the outbreak. Poults fed complex diets containing several protein sources seem to perform better. Highly digestible, nutritious ingredients (i.e., fish meal [if well stabilized with antioxidants], dried whole egg powder) can alleviate some of PEMS' impact. However, this may not be economically and technically practical. Such diets are costly and it is virtually impossible for most feedmills to produce small special batches of feed for isolated PEMS cases. However, changes in pellet size and texture of crumbles may be possible and beneficial. A good

interaction between service people, veterinarians and nutritionists is paramount to shorten delays in improving the environment, management, and nutrition/feed presentation for PEMS affected birds.

REFERENCES

- Barnes HJ & Guy JS. Poultry enteritis-mortality syndrome. In: *Diseases of Poultry*, 11th ed., Saif YM et al (eds.). Iowa State University Press, Ames, Iowa, 2003, 1171-1180.
- Carver DK et al. Mortality Patterns Associated with Poultry Enteritis Mortality Syndrome (PEMS) and coronaviral enteritis in turkey flocks Raised in PEMS-Affected Regions. *Avian Dis*, 2001, 45:985-991.
- Edens FW & Doerfler RE. Controlling poultry enteritis and mortality syndrome. *World Poultry*, 1999, 15:48-50.
- Guy JS. Virus infections of the gastrointestinal tract of poultry: a review. *Poult. Sci.* 1998, 77:1166-1175.
- Guy JS et al. High mortality and growth depression are experimentally produced in young turkeys by dual infection with enteropathogenic *Escherichia coli* and turkey coronavirus. *Avian Dis*, 2000, 44:105-113.
- Swayne DE et al. (eds). *Isolation and Identification of Avian Pathogens*, 4th ed., Am Assoc Avian Pathol, Kennett Square, PA, 1998, 311 pgs.
- Vaillancourt J-P et al. Syndrome entérique mortel du dindonneau. *Bull Acad Vét de France*, 1998, 70:243-250.

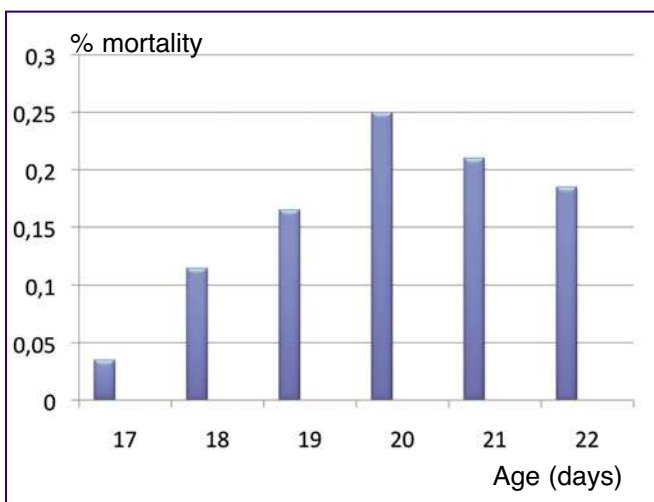
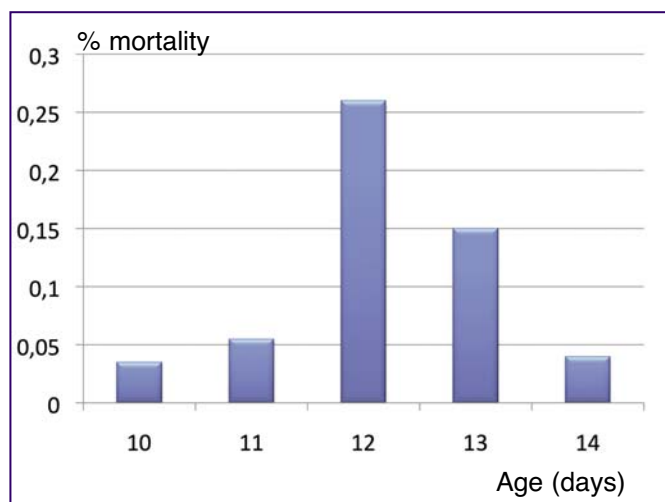


Fig.73.1 & 73.2: Daily percent mortality in two different broiler flocks affected with HSMS (adapted from Dinev I & Kanakov D. 2011).



Fig.73.3 & 73.4: Hypoglycemia-spiking mortality syndrome of chickens (HSMS). Chicks are seen huddling, recumbent and uncoordinated (trembling); often prostrated with legs extended.

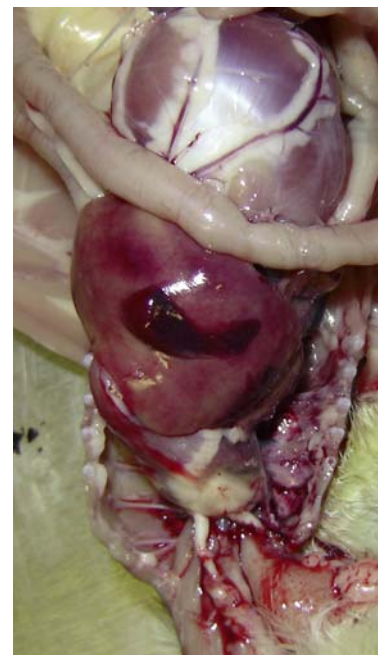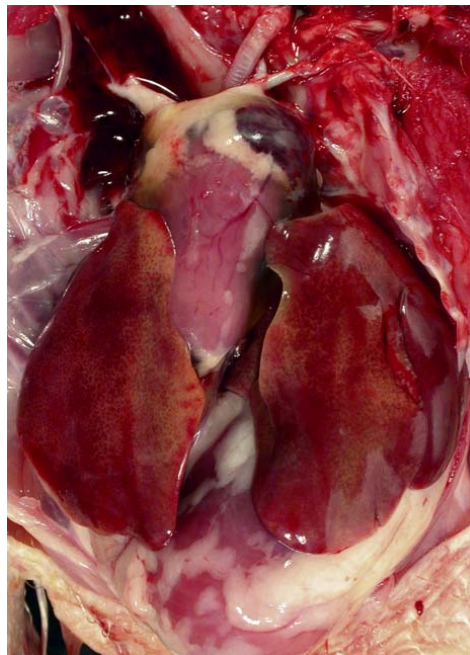
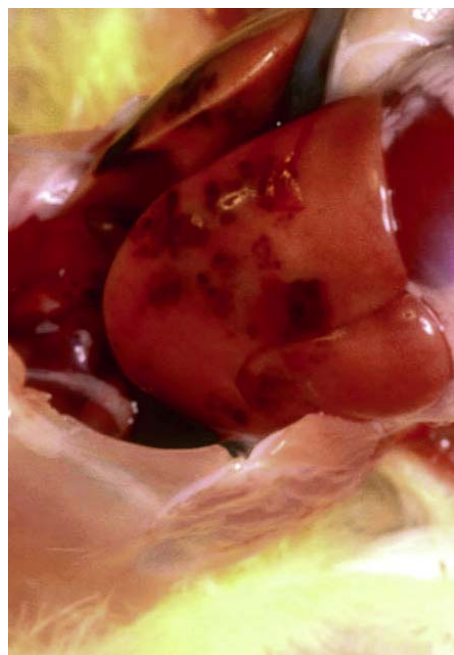


Fig.73.5, 73.6 & 73.7: Hypoglycemia-spiking mortality syndrome of chickens (HSMS). Hemorrhages in the liver. The hemorrhage may be intrahepatic and/or subcapsular.

73. HYPOGLYCEMIA – SPIKING MORTALITY SYNDROME OF BROILER CHICKENS

INTRODUCTION

First reported in chicken flocks in the United States in 1986, this disease is currently called hypoglycemia-spiking mortality syndrome of chickens (HSMS) because its etiology has yet to be clearly defined.

Over the years, the condition has been recognized in other countries. In a similar way as for Poultry enteritis mortality syndrome (formerly known as spiking mortality in turkeys), two distinctive forms of HSMS have been described: type A, severe but of short duration; and type B, milder but occurring over a longer period of time. Two hypotheses have been presented to explain these different clinical expressions: 1) there is a single causal agent, but clinical signs are dependent on other risk factors; 2) there are more than one causal agent producing a similar syndrome.

ETIOLOGY

To date, the etiology remains uncertain. Different inoculations of digestive material and tissues have been able to reproduce the disease, suggesting that at least one type of HSMS is caused by an infectious agent. The agent can be replicated in SPF chicken embryos, inoculated via the yolk sac route. These embryo-passaged tissues have been passed through 0.45 micron filters and successfully used to replicate HSMS via oral inoculation of day-old chicks. However, it has not been possible to isolate and replicate it in cell cultures. Some investigations indicate that an arenavirus, or other viral agent similar to it, could be involved. It is also plausible that infectious agents, such as the infectious bronchitis virus or avian encephalomyelitis virus, mainly play a role as predisposing factor to the disease.

Although increased mortality during the first three weeks may be seen with nicrobazin under hot conditions, this anticoccidial's side effect does not result in hypoglycemia.

EPIDEMIOLOGY

Typically, mortality exceeds 0.5% daily for at least three consecutive days during the second or third week of age (see Fig.73.1 & 73.2). Fast growing males are often most affected.

Nutritional factors may contribute to the problem, in particular diets with a high content in animal byproducts sensitive to oxidation.

A 10 to 12-day incubation period has been recorded under experimental conditions.

It has been shown that feeding darkling beetles from the litter of an affected flock to disease-free birds can cause the syndrome. It is not known whether beetles are acting simply as mechanical or biological vectors, or even as carriers of the agent(s) causing HSMS.

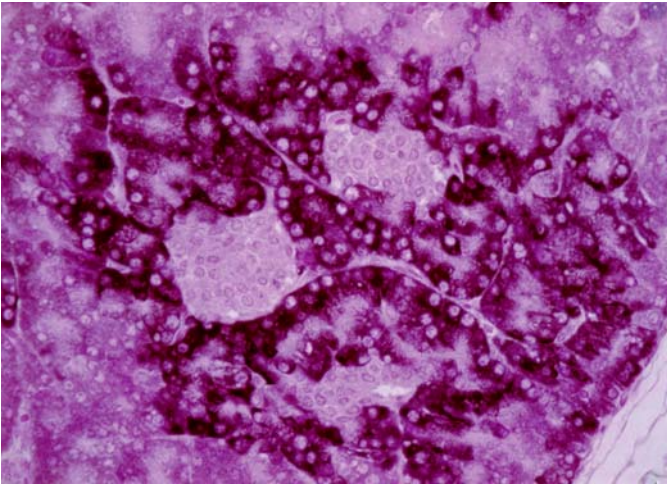
CLINICAL SIGNS

Chicks are seen huddling, recumbent and uncoordinated (trembling); often prostrated with legs extended. Blindness, loud vocalization and litter eating are also frequently observed. Birds become comatose prior to dying. Orange mucoid diarrhea may be observed. As with PEMS affected poults, surviving chicks will remain stunted.

LESIONS

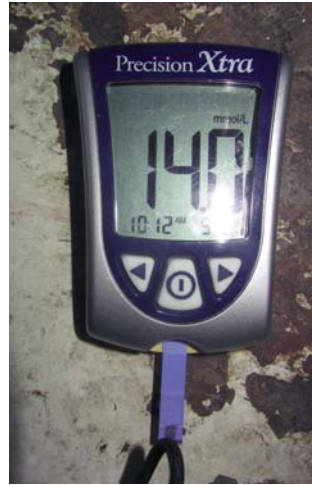Macroscopic and microscopic lesions are nonspecific. Occasionally, hemorrhage and necrosis are observed in the liver. A mild enteritis is noted with excess fluid in the lower intestines and orange mucoid material in the jejunum. In one report by Dinev and Kanakov (2011), these gut lesions were observed in about 25% of the affected birds.

When liver lesions are present, histopathology shows necrotic hepatocytes secondary to fibrinoid necrosis of hepatic arteries. Lymphoid depletion and necrosis may be observed in the bursa of Fabricius.




J.F. Davis

Fig.73.8: Formalin-fixed sections of pancreas from a chicken with HSMS, processed using immunohistochemistry with polyclonal antibody produced against an arenavirus. Staining (black) in acinar and islet cells was enhanced using nickel chloride.



D. Verne



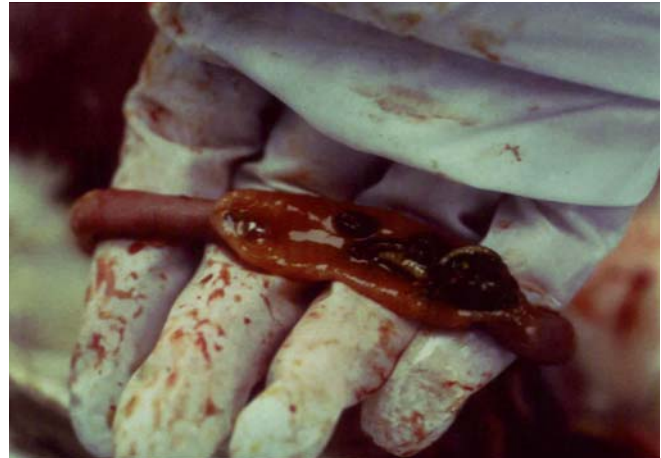D. Verne

Fig.73.9 & 73.10: HSMS. Hypoglycemia. Normal blood values are between 11 and 20 mmol/L as in Fig.73.9. In HSMS birds blood glucose is <150 mg/dL (or 8.33 mmol/L) (Fig.73.10). Often, blood glucose values are less than 50mg/dL in severely affected chicks.



Bayer

Fig.73.11: *Alphitobius diaperinus*. Enlarged oval-shaped beetles are black or brown-black color and appearance usually shiny (color may vary depending on age). Adults are about 5.8 to 6.3 mm.



D. Verne

Fig.73.12: *Alphitobius diaperinus*. Darkling beetles can be observed in the intestinal contents of poultry.



Bayer



Bayer

Fig.73.13 & 73.14: Since darkling beetles are suspected of playing a role in disease transmission, their control should be emphasized on farms with flocks with a history of HSMS, especially in litter where adults (Fig.73.11) and larvae (Fig.73.12) can be found.

DIAGNOSIS

A spike in mortality rate between 7 and 21 days (most often between 12 and 18 days) is suggestive of the syndrome. Diagnosis is established with confirmation of hypoglycemia (blood glucose <150 mg/dL or 8.33 mmol/L) in diseased birds. Often, blood glucose values are less than 50 mg/dL in severely affected chicks.

Immunohistochemistry, using a polyclonal antibody produced against an arenavirus, has produced positive staining in pancreatic acinar and islet cells (see Fig.73.8).

TREATMENT

No specific treatment is available. Supportive care focuses on reducing stress such as temperature excesses (too hot, too cold), wide temperature variation, poor ventilation (including excess levels of ammonia), and feed and/or water deprivation. Improving the birds' environment and nutrition, including supplements such as electrolytes and vitamins (e.g., vitamin E) has been credited in reducing mortality associated with HSMS.

CONTROL

No vaccine is available. In addition to improving the microenvironment of the birds, field and

experimental studies have shown that a long daily dark period can prevent this condition. Exposure to 100% light will cause a melatonin deficiency. Melatonin is involved in immune response, so a deficiency of melatonin may make birds more susceptible to infection with the HSMS agent. A daily long period of darkness triggers melatonin release and a shift from glycogenolysis to gluconeogenesis, which allows an alternate pathway for glucose production from the liver.

Finally, since darkling beetles are suspected of playing a role in disease transmission, their control should be emphasized on farms with flocks with a history of HSMS.

REFERENCES

- Davis JF. Hypoglycemia - Spiking Mortality Syndrome of Broiler Chickens In: *Diseases of Poultry*, 13th ed., Swayne DE, Glisson JR, et al. (eds.). Wiley-Blackwell, Ames, Iowa, 2013, 1325-1327.
- Dinev I & Kanakov D. 2011. Spiking mortality syndrome in broiler chickens clinical and morphological examinations of the cases recorded in Bulgaria. *Acta Veterinaria*, 2011,61: 49-55.
- Peebles ED et al. 2012. Effects of nicarbazin on the blood glucose and liver glycogen statuses of male broilers. *Poultry Sci*, 2012,91:2183-2188.

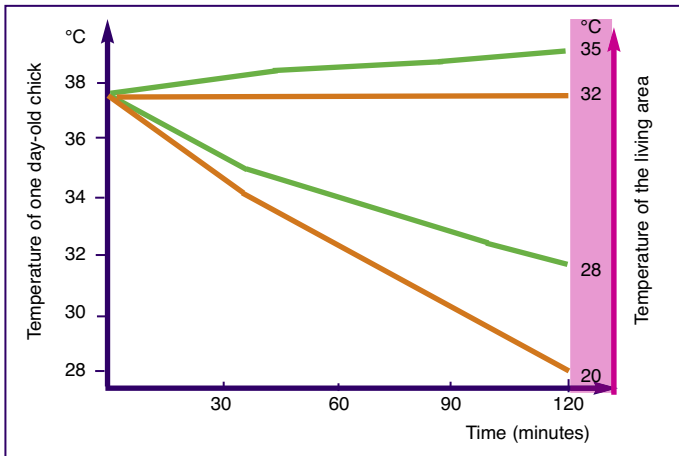


Fig.74.1: Effective thermoneutral temperatures in broilers (according to ITAVI, 1997). At 20°C the bird's internal temperature drops to 35°C in 30 minutes (the legs of birds are cold) and then at 30°C in one hour (the birds are lethargic). The lethal limit of 28°C is reached after 2 hours of exposure. At 35°C and beyond, the bird's temperature rises gradually (the lethal temperature is 47°C). Within the thermoneutral zone (between 31°C and 33°C), the bird's internal temperature is stable.

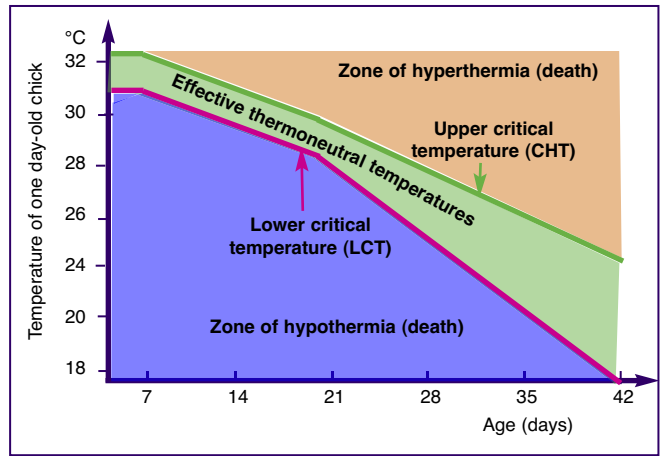


Fig.74.2: Effective thermoneutral temperatures in broilers (according to ITAVI, 1997). Thermal comfort is reached when birds are placed in a thermoneutral zone; hence maintaining their temperature constant. Below the lower critical temperature (LCT) or above the upper critical temperature (CHT), the birds solicit their regulatory mechanism in order to slow down the development of hypothermia or hyperthermia.

Section IV



Fig.74.3: Body temperature is a good indicator of comfort.



Fig.74.4: Controlling the temperature allows defining the comfort zones.

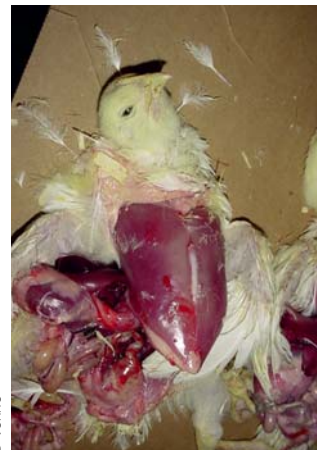

Fig.74.5, 74.6, 74.7 & 74.8: Ventilation failure caused by a frozen fan can kill birds that will show cyanotic lesions.

Other diseases

74. ENVIRONMENT & PATHOLOGY

INTRODUCTION

More than 2,400 years ago, the theories of Hippocrates, integrating for the first time health and disease in the system of natural phenomena (the disease is due to «the air, waters, places, seasons, *etc.*») have revolutionized conceptions of medicine. These theories were challenged in the second half of the nineteenth century with the discovery of microbiology. If at first, these two points of view seem opposed, they are not incompatible. A specific infectious agent may determine the nature of the disease, but the development of this disease is influenced by other factors affecting the individual (or group of individuals), but also the pathogens themselves. These factors are what we call the environment. They are often associated with the concept of stress (or aggression). They may have many origins including temperature, relative humidity, litter which may release many harmful gases, dust and aerosols, air movement, light, noise, air pressure, static electricity, air ionization and trauma.

TEMPERATURE

The temperature in poultry buildings can have many effects on the health of birds. It must be lower than their internal temperature which normally exceeds 38°C.

Hyperthermia

When temperature rises, birds seek shelter with heavy breathing and open beak (panting). They look for well-ventilated areas of the building, for contact with cold objects while standing up with open wings. They also increase their water consumption while reducing feed intake. Death observed during severe hyperthermia is due to circulatory collapse and/or respiratory or metabolic diseases.

The effect of temperature depends on the age of the birds and many other factors (humidity, lack of ventilation, *etc.*). In young chicks, transient hyperthermia can cause high mortality linked to depression and dehydration. Broilers may have stunted growth. In layers, high heat can cause a drop in egg production. Currently, the best practices for the prevention of hyperthermia are implemented through engineering solutions (see Chap.I.7).

Hypothermia

Hypothermia during incubation (<26°C) can later promote ascites in broilers. In older birds, more energy and therefore more bird feed will be used to maintain body temperature during winter.

Action on mucous membranes of the respiratory tract

Improper temperature is detrimental to the health of birds. Indeed, high temperatures cause an increase in the activity of goblet cells, which results in a decrease in ciliary beat and ends with an abrasion of the ciliary carpet following the drying of mucous membranes; while low temperatures cause a local vasoconstriction and reduced irrigation of the respiratory mucosa.

Impact on immune function

In the 19th century, Pasteur noticed that immersing the legs of birds in cold water decreased their natural resistance to anthrax by *Bacillus anthracis*.

HYGROMETRY

Relative humidity is measured as the ratio of the amount of water vapor in a volume of air to the amount of water vapor saturating the same volume of air under similar temperature and pressure conditions.

Relative humidity (RH) impacts many environmental parameters. For example, the concentration of suspended dust particles is more elevated when RH levels are lower than 60%; the viability of infectious agents is also affected by RH.

A relative humidity greater than 75% can also play a role on the sensitivity of birds to pathogens of the respiratory tract such as *Bordetella avium* in turkeys or Newcastle disease virus in chickens. Moreover, poor poultry house insulation will increase the negative effect of heavy condensation associated with high humidity during cold weather. Recommended values vary from 60 to 70%. Birds will have more difficulty fighting against heat under very humid conditions.

Ammonia levels	Adverse Effects
20 ppm continuously for 6 weeks	Pulmonary edema, congestion and hemorrhage Increased susceptibility to respiratory disease due to ciliostasis
40 ppm	Deciliation and decreased clearance of <i>Escherichia coli</i> in the lungs and air sacs
25-50 ppm	Reduction in body weight (0.17 kg or 0.38 lbs less at 49 days), feed efficiency and increased airsacculitis in birds exposed to the infectious bronchitis virus
50-100 ppm	Keratoconjunctivitis, corneal ulceration and blindness

Tab.74.1: Adverse effects of ammonia (according to Malone & Johnston, 2011).

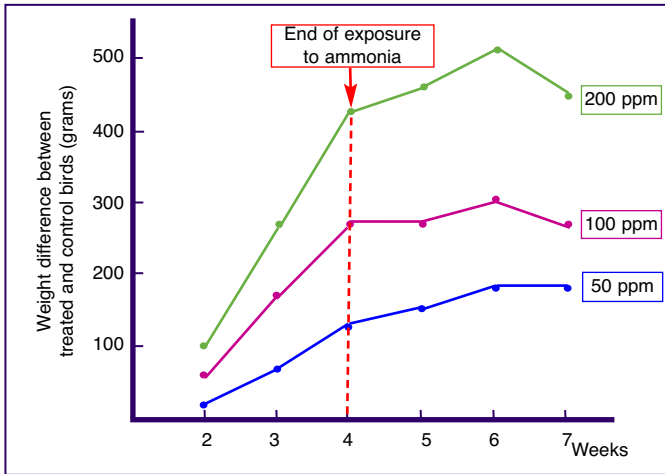


Fig.74.9: Delayed growth linked to ammonia levels starting at 50 ppm in broilers (according to Reece et al, 1980). Young chickens exposed from one day of age for four weeks to levels of 50, 100 or 200 ppm, present a significant weight loss that persists after cessation of exposure to this poisonous gas.

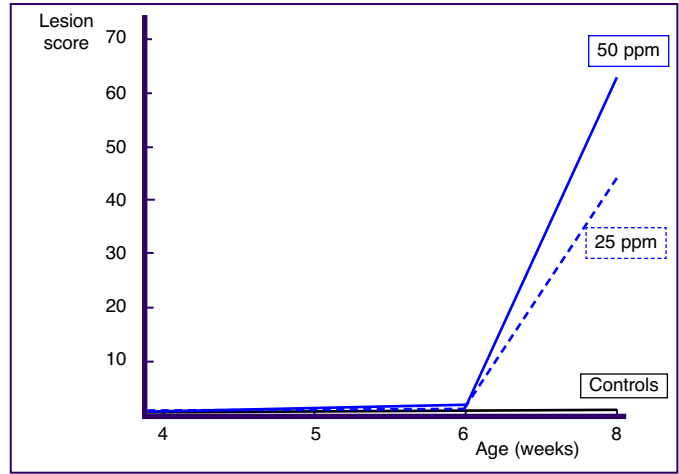
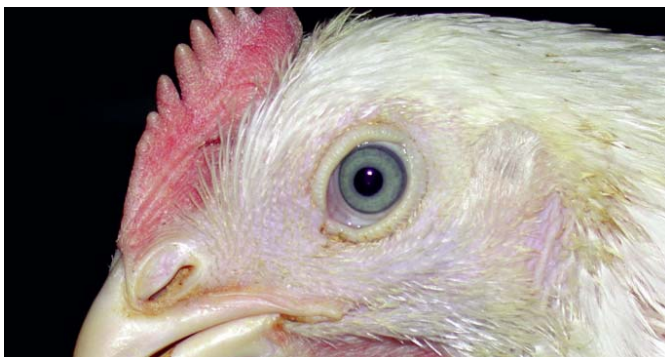
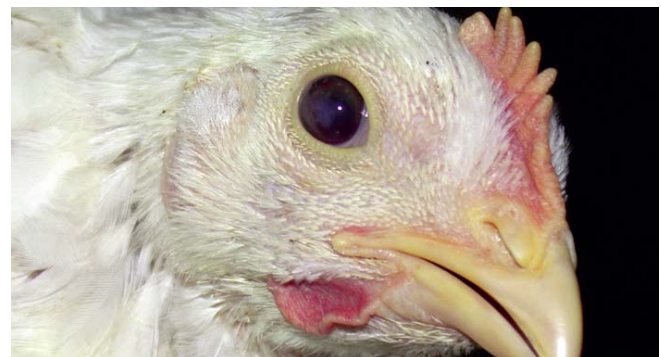
Fig.74.10: Importance of airsacculitis lesions observed in 8-week-old chickens after exposure to ammonia (from the age of 4 weeks) and vaccination against infectious bronchitis (at the age of 5 weeks) in a flock free of mycoplasma (according to Kling & Quarles, 1974).

Section IV

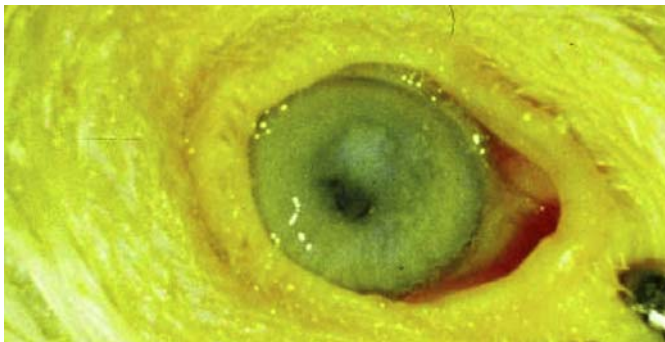


H.J Barnes

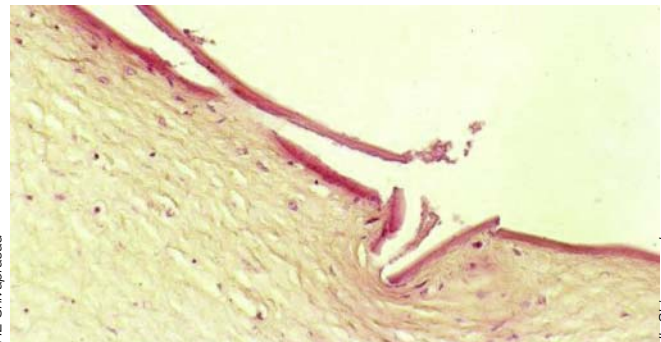


H.J Barnes

Fig.74.11 & 74.12: Blepharitis and keratoconjunctivitis due to an excess of ammonia.



H.L. Shivaprasad



H.L. Shivaprasad

Fig.74.13 & 74.14: Ammonia toxicity (Chicken). Corneal corrosion and ulceration.

GAS

Litter plays a very important role in the development of many toxic gases such as ammonia (NH₃), carbon dioxide (CO₂) and hydrogen sulfide (H₂S).

Ammonia

It is an irritant gas produced by the microbial decomposition of uric acid in bird droppings, especially under high humidity conditions. High concentrations of ammonia (usually 50 ppm but sometimes up to 200 ppm) can be observed during winter as a result of a decrease in ventilation in order to keep the heat in poultry buildings. The irritating odor of ammonia can be detected by humans at a concentration as low as 25 ppm.

Ammonia can be considered a primary etiological agent acting directly on the respiratory system or as a factor predisposing to respiratory diseases. Specific clinical signs may be observed, but some levels may lead to subclinical problems resulting mainly in a decline in production.

Ammonia, primary etiologic agent

Ammonia can be the primary cause of a respiratory disease. The first clinical sign associated with this disease is keratoconjunctivitis. This ocular disease (often with tracheitis) could be reproduced with exposure to ammonia concentrations of 60 to 200 ppm over a five-week period. Cases of airsacculitis and sternal bursitis with weight loss (resulting in downgrading or carcass condemnations) can be observed in chickens exposed to levels of 25-50 ppm.

The microscopic examination of the respiratory system of birds exposed to high levels of ammonia has shown, starting at a dose of 100 ppm, catarrhal inflammation characterized by a loss of cilia, an increase in the number and the size of the mucous glands associated with excess mucus production and inflammatory lung lesions with areas of carnification. More detailed studies carried out using a scanning electron microscope showed impairment of the tracheal mucociliary system starting at 10 ppm in turkeys exposed to concentrations of 10 to 400 ppm of ammonia from one day of age. The irritating effects of ammonia can be observed as soon as the first week with increased mucus production and viscosity. This results in the agglutination of the eyelashes. In addition, there is a loss of ciliary apparatus dependent on the

length of exposure and the ammonia level. It is very significant after 7 weeks in an environment containing 40 ppm. These lesions show a decrease in the natural defence mechanism of the respiratory system («mucociliary escalator») enabling the penetration and accumulation of pathogens (viruses and bacteria). The pulmonary ultrastructure is more severely affected than the trachea in one-week-old chickens exposed to ammonia concentrations ranging from 25 to 100 ppm for 1 or 4 days. Thus, examination of parabronchi shows an increase in the thickness of the atria walls (by a factor of 2-3 times compared to control birds), presumably due to infiltration by inflammatory cells. This results in a narrowing of capillary air-carrying pathways and a disturbance of the thermolysis. This demonstrates the importance of ammonia in the etiology of respiratory diseases (or decrease in production) observed in poultry houses where environmental conditions are poor, especially with ammonia levels at or exceeding 25 ppm.

Ammonia responsible for a decline in production

This decrease in production observed in growing birds or in laying hens could be due to a change in blood pH with a decrease in thermolysis and lower CO₂ production (with a decrease in respiratory frequency and amplitude). This results in a reduction in energy requirements and a decrease in feed consumption («nutritional stress related to the environment»). In young birds, a reduction in appetite with growth retardation was observed at concentration levels as low as 50 ppm.

In laying hens, the onset of egg production can be delayed by 15 days with a decrease in egg production. This decrease is especially significant with high concentrations of ammonia such as 200 ppm for 17 days where the rate of lay was 66% instead of 72%. The influence of environmental factors such as ammonia is especially important at the beginning of the laying period (when the birds are most vulnerable).

Ammonia predisposes to the development of respiratory diseases

The deleterious action of ammonia promotes the invasion of the respiratory tract by various pathogens, especially viruses, mycoplasma or other bacteria. This is the case, for example, with Newcastle disease or infectious bronchitis virus and *Escherichia coli*.



Fig.74.15, 74.16 & 74.17: Assessing ammonia levels in the field.

Section IV

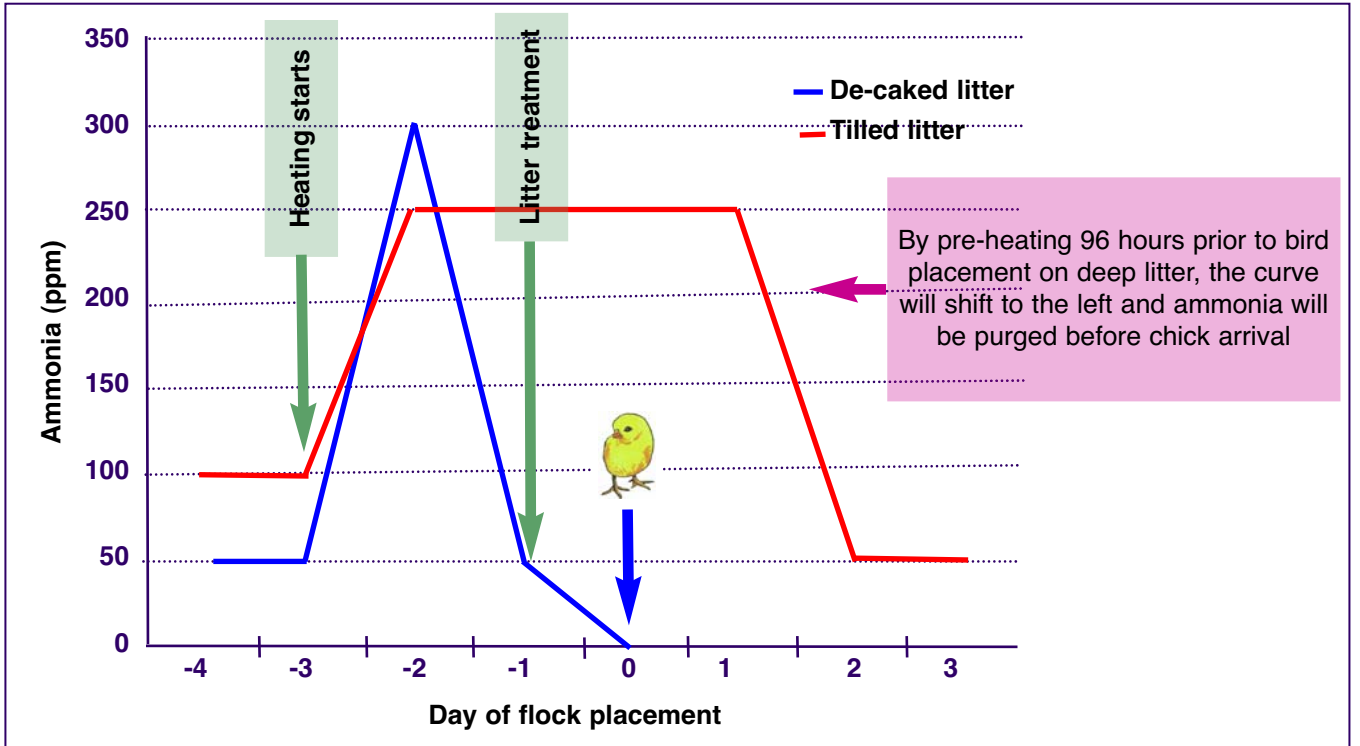


Fig. 74.18: Litter preparation and elimination of ammonia by pre-heating the poultry house following litter replacement (according to Malone & Johnson, 2011).

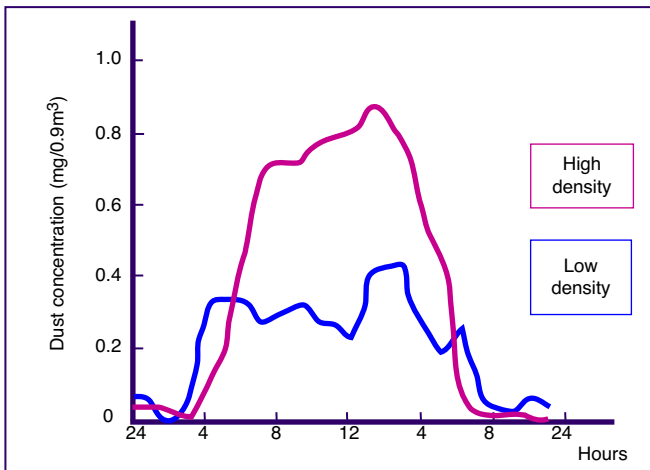


Fig.74.19: Variation of physical pollution (dust) in a turkey farm over a period of 24 hours (according to Anderson et al, 1968).

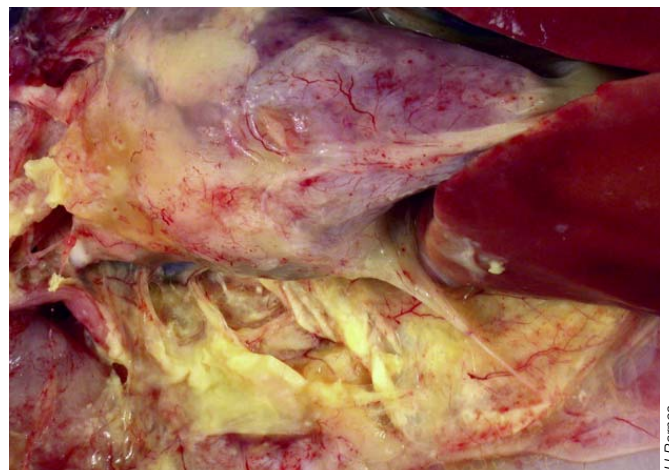


Fig.74.20: Aisracculitis (28 week-old chicken). Dust and ammonia promote the development of lesions in the air sacs and their infection by infectious pathogens.

Carbon dioxide

Carbon dioxide is a normal constituent of air at a concentration of 300 ppm (0.03%). An increase in CO₂ concentration in ambient air, usually associated with a decrease in ventilation, acts primarily on the respiratory function. It is also a factor in assessing ventilation. Higher concentrations of 3,000 and 6,000 ppm have no effect on the growth of birds, but at a rate of 12,000 ppm, by four weeks of age, an average weight loss of 8% was observed in chickens and it persisted after exposure, with an average loss of 3.5% at the end of grow-out. Moreover, if chickens were exposed at a concentration exceeding 5,000 ppm during the week prior to slaughter, there was a negative effect on carcass value.

Carbon monoxide

It is a toxic gas that may appear in poultry production as a result of incorrect settings of the heating system causing incomplete gas combustion due to the lack of oxygen. This phenomenon associated with a lack of ventilation can be fatal in chicks at rates of 400 to 1500 ppm. This type of accident has also been reported in chickens exposed to concentrations of 2000 ppm with a mortality rate of 63-75% in two to four hours. It was also shown that a concentration of more than 750 ppm of carbon monoxide for a week before slaughter depreciates the value of carcasses.

Hydrogen sulfide

It is a gas produced by the decomposition of organic matter. Heavier than air, it accumulates in lower unventilated areas of the house. Olfactory perception of this gas is detectable at very low concentrations but is not a sufficient warning threshold as it gradually fades until it disappears at high concentration (olfactory fatigue effect). A case of fatal poisoning has been reported in a flock of laying hens where concentrations of 140 to 200 ppm were measured near the openings of the manure pit (mortality rate of 5 to 6%).

Methane

It is a gas that comes from litter fermentation. It accumulates in the upper levels of the poultry house. This gas is not toxic, but in high concentrations (50,000 ppm), it can cause explosions.

DUST & AEROSOLS

Physical purity of the atmosphere depends on its particulate matter status, the composition and the particle size being highly variable. We will consider as dust solid particles ranging in size from 0.1 microns (the size of a virus particle) to more than 100 microns (bacterial or fungal spores aggregates at the limit of visibility) and even centimeters (straw particles). Thus, a polluted atmosphere may be invisible to the naked eye. The term «aerosol» refers primarily to airborne liquid particles of 0.01 microns to 10 microns, exceptionally up to 50 microns.

Origin of solid or liquid particles suspended in the air

Dust can come from poultry equipment, especially litter, such as straw chopped too finely (less than 5 cm in length). An excessively powdery feed can also be harmful, especially when the distribution system is accompanied by vigorous stirring of the feed. The birds are also sources of dust: skin squames, feathers or fluff, dried droppings. The saliva or nasal discharge of birds with respiratory disease will promote the dispersion of infectious droplets in poultry houses.

Particle size and penetration into the bird's respiratory tract

Particles can be classified into viable particles (contaminants) and non-viable (sterile: organic or mineral materials).

The size of viable particles affects their ability to penetrate and contaminate various parts of the respiratory tract. Thus, in the chicken, larger particles (3.7 to 7 microns) will be found in the upper

regions of the respiratory tract. Particles measuring 1.1 microns are deposited mainly in the lung and the posterior thoracic and abdominal air sacs. Finally, the finer particles (0.312 microns) which can pass the mucociliary barrier will be located preferentially in the posterior and anterior air sacs, the air stream moving from the posterior air sacs to the anterior air sacs.

Factors involved in the physical pollution of poultry houses

Sedimentation velocity of the particles is governed by Stokes' law:

$$V_s = \frac{2r^2(d_1 - d_2)g}{9\eta}$$

V_s : particle's settling velocity

g : the gravitational constant

r : radius of the particle

d_1 : the density of the particle

d_2 : the density of the milieu relative to water

η : viscosity of the milieu (dynamic viscosity)

Consequently, the diffusion of particles in the atmosphere depends on their size, their density and the relative humidity, but also in a poultry house, on the birds' agitation and the turbulence due to ventilation. For example, the rate of sedimentation of particles measuring 10 microns or 100 microns will be respectively 30 cm/min or 30 cm/s in a calm atmosphere.

Variations may be observed during the day depending on the birds' activity. An increase in bird density also promotes an increase in the number of particles suspended in the air, especially for those having a size greater than 0.5 microns. In egg laying hens on deep litter, 55-68% of the dust will emanate from the litter while in caged layers, 80 to 90% of the dust will be feedborne. For example, it was observed that the number of organisms per m³ of air was 100 to 1000 times less in a flock kept on mesh (10⁶-10⁷ microorganisms/m³) than in a flock on deep litter (10⁸-10⁹ microorganisms/m³).

A relative humidity below 60%, especially with cold ambient temperature, promotes an increase in the number of particles suspended in the air. The effect of ventilation on physical air pollution is complex. It is especially important to avoid the dispersion of particles by turbulence and to allow the removal of suspended particles (positive pressure systems).

Manual of poultry diseases

Effects of dust and aerosols on birds

Dust and aerosols can be vectors of microorganisms

Dust may spread coliforms responsible for chronic respiratory disease (CRD): colisepticemia can be observed in the week following a peak in the concentration of coliforms in ambient air.

Dust or aerosols can carry other pathogens than *Escherichia coli* such as *Salmonella*, *Mycoplasma*, Newcastle disease, infectious bronchitis, infectious laryngotracheitis or Marek's disease viruses. Thus, some commercial vaccines against avian respiratory diseases (Newcastle disease, infectious bronchitis) may be administered *via* aerosol; dust has even been studied as possible vaccine carrier.

The survival of infectious or parasitic agents in ambient air is dependent on intrinsic but also extrinsic factors related to the environment: temperature, relative humidity, light, pH, *etc.* For example, the survival of *Escherichia coli*, which can be over 32 weeks in dry bedding, is significantly reduced (84 to 98% within two to seven days) by wetting the litter. Strains of *Mycoplasma gallisepticum* and *Mycoplasma meleagridis* could be found six hours after the creation of an aerosol (in the proportion of 1% or 0.1%), with the ambient air remaining contaminated for more than 24 hours.

The importance of relative humidity on the viability of mycoplasmas could also be shown, especially *Mycoplasma gallisepticum* at a temperature of 27°C: the survival of this microorganism is especially high with a relative humidity below 25% or above 80%. However, this mycoplasma appears very sensitive at relative humidity ranging between 40 and 60%.

The most pathogenic viruses in poultry are protected by an envelope (Marek's disease, infectious bronchitis, Newcastle, infectious laryngotracheitis disease). Their lipoprotein envelope generally provides them with a better survival rate in a relatively dry atmosphere.

Dust may also promote the development of respiratory disease by its irritant action

This was observed with colibacillosis in chickens and *Mycoplasma meleagridis* in turkeys. In turkeys, a high particle concentration can more than double the incidence of airsacculitis in flocks infected with *Mycoplasma meleagridis*, whether the morbidity rate is low (2%) or high (47%).

Finally, some dust may cause an allergic reaction

This phenomenon, well known in mammals (e.g., humans and cattle), is much less observed in birds.

VENTILATION

Ventilation is key to controlling the ambient environment. To establish optimal ventilation in a poultry house, the key factor is the retention or elimination of heat of bird origin. Ammonia concentration in the ambient air is the determinant factor defining the level of ventilation.

Optimal ventilation depends on many factors such as temperature, the total volume of air, the frequency of air replacement, bird density, relative humidity, the amount of noxious gases, *etc.*

When calculating ventilation requirements, rather than body weight (BW), it is better to take into account the metabolic weight of the bird ($\text{kg BW}^{0.75}$) because the bird's gaseous exchanges are closely related to the metabolic weight. Many equations exist to calculate the necessary ventilation values for optimum ambient temperature. There are limiting values. Thus, for broiler chickens, the minimum and maximum values are respectively $1.5 \times 10^{-4} \text{ m}^3/\text{s}/\text{kg BW}^{0.75}$ and 1 to $1.5 \times 10^{-3} \text{ m}^3/\text{s}/\text{kg BW}^{0.75}$.

Some formulas are difficult to apply commercially in the field. An estimate using $\text{m}^3/\text{s}/\text{ton}$ of feed ingested per day (MSTD) has been proposed:

$$1 \text{ MSTD} = 7.5 \times 10^{-5} \text{ m}^3/\text{s}/\text{kg BW}^{0.75}$$

For example, the lower limit of the ventilation value is equal to 2 MSTD for broilers. Similarly, one can determine the air velocity depending on the optimal biological temperature in hens: 0.2 m/s (14°C), 0.5 m/s (25°C) or 1.2 m/s (26°C).

Finally, the suppression of the ventilation in a poultry house causes thermal stress in four hours during cold weather or in one hour during warm weather with, in the latter case, a relative humidity of 100%.

LIGHTING

Keeping broilers in the dark reduces their activity. This is used to catch birds before shipment to the slaughterhouse, but also as a way to limit energy expenditure. In extreme cases, the lack of light can cause transient paralysis in hens (caged layer paralysis).

A sudden change in light intensity (either way) can also be stressful to birds.

NOISE

Noise can be stressful to poultry, resulting in reduced production, especially in egg layers.

ATMOSPHERIC PRESSURE

Low atmospheric pressure associated with altitude can promote pulmonary hypertension syndrome, the cause of ascites in broilers (see Chap.IV.70).

STATIC ELECTRICITY

Static electricity may be generated by the friction of air on fan blades or on metallic cage structures. A potential difference equal to 1.5 volt between a laying cage and the ground can trigger an increase in feed consumption and nervousness, and a decrease in egg production. Grounding cages can resolve most of these problems.

AIR IONIZATION

The ionization of air molecules can act on the integrity of the respiratory mucosa of birds. Non-metallic dusts having an adverse effect on the body are positively charged. The level of environmental sanitation appears to be determined by the proportion of negative ions in the air. These «beneficial» negative ions may have a bactericidal action.

TRAUMA**Too finely ground feed related to oral lesions**

Some raw feed can cause damage from being too finely ground. Larger feed particles allow a mechanical cleaning of the oral mucosa. Lesions,



M Bouzouala

Fig.74.21. Ventilation is one of the major elements to master in order to avoid heat stress resulting in this case in breathing difficulties.



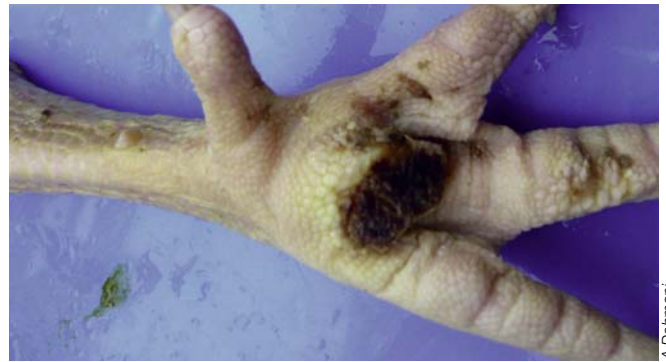
A Dahmani

Fig.74.22. Excessive heat can cause excessive feather loss.



A Dahmani

74.23: Feather pecking and cannibalism may originate from related factors and may be evidence of a flock management problem (diet, lighting, red mites, etc.).



A Dahmani

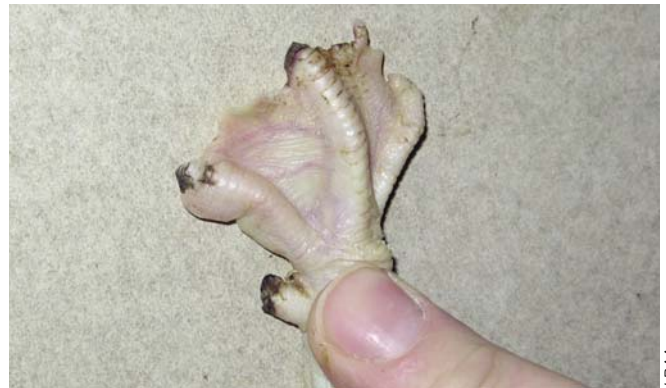Fig.74.24: Contact dermatitis. It is mainly due to wet or damp litter with a pH that is too high or too low. It is influenced by dietary factors.



LBAA



LBAA



LBAA



LBAA

Fig.74.25, 74.26, 74.27 & 74.28. Poorly distributed ducklings in a building indicative of a comfort problem. In this case, inadequate wire mesh flooring is causing foot lesions. Ducklings seek less traumatic support for their legs (feeders, drinkers, cardboard).

beginning under the tongue, on the palate and extending throughout the oral cavity, are bilateral and are covered with an adherent feed dust. An ulcer can be observed. There are no lesions at the commissures of the beak or the proventriculus as with mycotoxicosis.

Hazardous material in the environment

During the construction of a building, it is important to remove any metal that might be ingested by the bird; avoid metal in the litter (e.g., nails) which is often the cause of perforation of various parts of the digestive tract (especially the gizzard). Similarly, poultry equipment, especially wire fencing, should not have sharp edges that could injure the birds.

Problems originating from interventions

For example, trimming the beak should be performed early (less than 2 weeks of age) to avoid any complications.

REFERENCES

Anderson DP et al. Influence of dust and ammonia on the development of air sac lesions in turkey. *Am J Vet Res*, 1968,29:1049-1058.

Brugère-Picoux J & Sayad N. Environnement, stress et pathologie respiratoire chez les volailles. Une revue. Note 1. Facteurs physiques. *Rev Méd Vét*, 1987, 138 :333-340.

Brugère-Picoux J & Sayad N. Environnement, stress et pathologie respiratoire chez les volailles. Une revue. Note 2. Facteurs chimiques et biologiques. *Rev Méd Vét*, 1987, 138 :423-431.

Institut technique d'Aviculture (ITAVI). La température de l'air, 6p. <http://www.itavi.asso.fr/elevage/batiment/STA1997/La%20temp%E9rature%20de%20l'air.pdf>.

Kempf I. et al. Mycoplasmoses à *Mycoplasma gal-lisepticum*. Réalisation d'un modèle expérimental. Rôle de l'ammoniac comme facteur d'exacerbation. *Avian Pathol*, 1988,

Kling HF & Quarles CL. Effect of atmospheric ammonia and the stress of infectious bronchitis vaccination on leghorn males. *Poultry Sci*, 1974,53:1161-1167.

Malone G & TM Johnson. Litter management for the 21st Century. In *A practical guide for managing risk in poultry production*, Ed. Owen RL, AAAP, Jacksonville, Florida, 2011, pp155-189. Morrow C. Management as a cause of disease in poultry. In *Poultry diseases*, Pattison M et al ed., 6th ed., Elsevier, Publ., 2008, pp 536-547.

Reece FN et al. Ammonia in the atmosphere during brooding affects performance of broiler chickens. *Poultry Sci*, 1980,59:486-488.

INTRODUCTION

Detection of abnormalities on carcasses sent to slaughterhouses has a double purpose: to detect the presence of hazardous contaminants for human health and to detect any condition that would make carcasses unfit for human consumption for commercial or organoleptic reasons.

In the European Union, control of fresh meat includes a number of inspection tasks in slaughterhouses:

- gathering information about the flock;
- *ante-mortem* inspection;
- assessing animal welfare;
- *post-mortem* inspection;
- handling of specified risk materials, other animal by-products and laboratory tests.

The *post-mortem* inspection on carcasses and offal takes place immediately after slaughtering. The inspection is carried out by a veterinary official (veterinarian in charge) but also by official inspectors or slaughterhouse staff according to rules in the regulation. However, even with this assistance, the veterinarian in charge has to conduct a daily inspection of the viscera and body cavities of a representative sample of birds. A detailed inspection of a random sample from each batch of the same origin has to be performed as well as an inspection of some of the carcasses declared unfit for human consumption following *post-mortem* inspection.

Any official inspecting carcasses may conduct further examination if there are reasons to suspect that the meat from the birds being processed could be unfit for human consumption.

For poultry reared for the production of *foie gras* (fatty liver) and slaughtered at the farm, *post-mortem* inspection must take place at the cutting plant where the carcasses are transported directly from the farm with a certificate.

The presence of certain abnormalities of the viscera or of the carcasses leads to the declaration of unfitness for human consumption. This is the case when *post-mortem* inspection reveals any of the following conditions:

- birds dying before slaughter;
- birds with a systemic disease such as septicemia, pyemia, toxemia or viremia;
- birds with a systemic parasitic infestation;
- pathophysiological changes, anomalies in consistency, insufficient bleeding, organoleptic anomalies
- emaciated birds;
- fecal contamination or other contaminations;
- disease listed by the World organisation for animal health or OIE (assuming diagnosis is known and lesions are present).

Below are the main abnormalities observed on carcasses or offal when slaughtering poultry.

ABNORMALITIES OF THE RESPIRATORY SYSTEM

Aspergillosis

Etiology: Aspergillosis is a fungal infection caused by a fungus of the genus *Aspergillus*. This disease is frequently associated with contaminated litter by spores. Rarely, the infection is acquired at the hatchery.

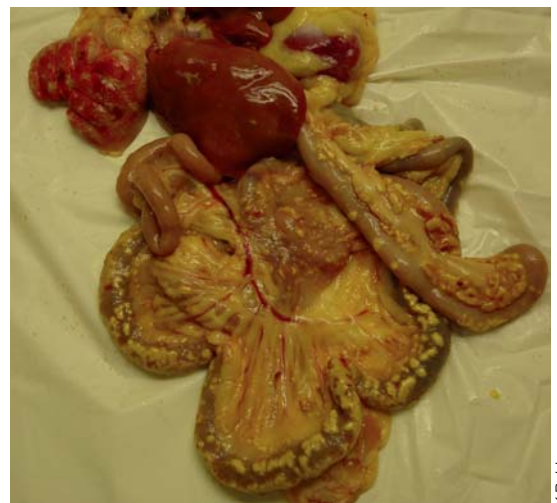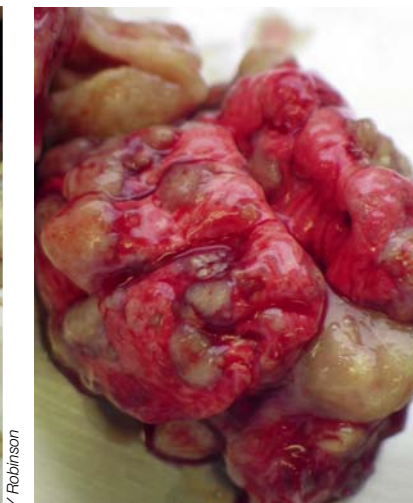


Fig.75.1 & 75.2: Aspergillosis. Whitish and multifocal coalescing nodules distributed in the lungs.

Fig.75.3: Aspergillosis. Whitish to yellowish plaques coalescing on the serosa of the intestines.

Health measures

75. SLAUGHTERHOUSE CONDEMNATIONS

Macroscopic characteristics: At *ante-mortem* inspection, affected birds may have respiratory problems, such as dyspnea or tachypnea. At *post-mortem* examination, the lesions are characterized by the presence of multiple whitish nodules in the lungs and air sacs. The lesions may sometimes be limited to the bronchi and may not be visible on the lungs, except when an incision is performed. At a later stage, air sacs present large purulent areas. Chronically affected birds may be emaciated.

Action to be taken: The whole carcass and offal are condemned only when the condition is generalized. Otherwise, if the carcass is in good condition, portions of the affected organs are trimmed and the carcass is accepted for human consumption.

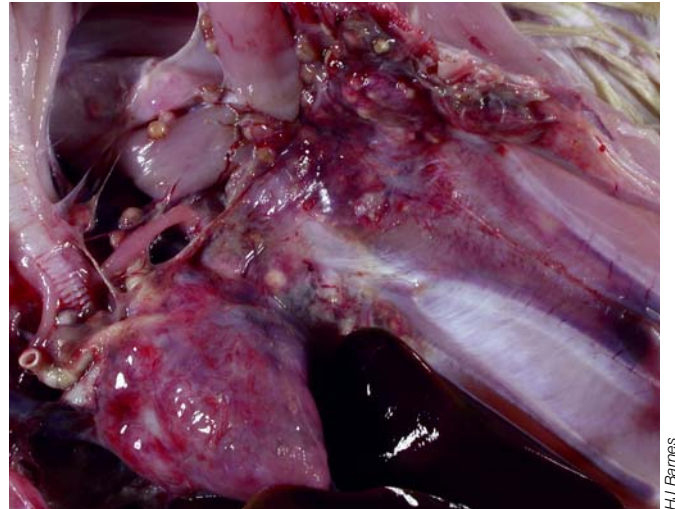


Fig.75.4: Airsacculitis (aspergillosis). Presence of aspergillus nodules on air sacs (Turkey).

Airsacculitis

Etiology: Airsacculitis may be seen with several diseases. The specific etiology for any given case may be difficult to determine during *post-mortem* inspection. It can be either a *Mycoplasma* or another bacterial infection (colibacillosis, salmonellosis, pasteurellosis, *etc.*).

Macroscopic characteristics: The lesions of airsacculitis can be acute or chronic. When the infection is acute, the air sacs may be congested and present hyperemia, petechial hemorrhages, and a sero-hemorrhagic exudate. In the chronic stages of the infection, the air sacs are thickened and

become opaque and whitish. It is also possible to note the presence of purulent or caseous material. The lesions may spread to other organs (pericardium, peritoneum, liver, *etc.*). The carcass may have either a congestive or a cachectic appearance.

Action to be taken: In the absence of carcass abnormalities (congestion or emaciation), moderate airsacculitis without accumulation of exudate causes no withdrawal. The presence of a fibrinous or caseous exudate leads to the condemnation of the affected areas. However, when airsacculitis is associated with perihepatitis or pericarditis, the whole carcass and offal should be condemned.

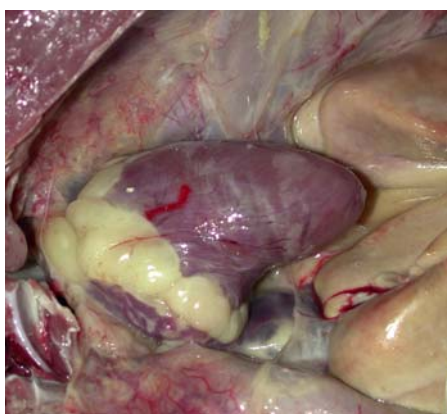

Fig.75.5: Acute airsacculitis (Duck).

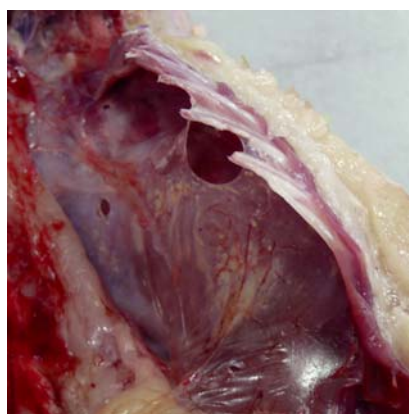


Fig.75.6: Airsacculitis (Duck). Congestion of air bags and purulent deposits.

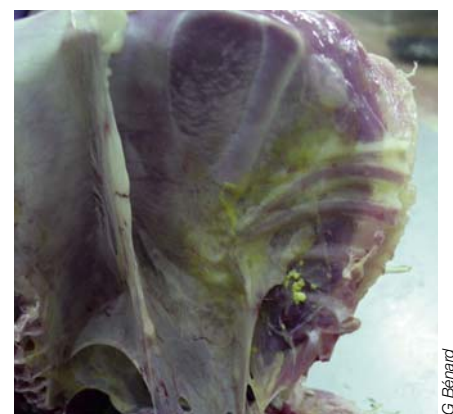

Fig.75.7: Purulent airsacculitis (Duck).

ABNORMALITIES OF THE DIGESTIVE SYSTEM

Pendulous crop

Etiology: Several factors predispose to the distension and the descent of the crop: vagal paralysis, excessive consumption of water and a partial stasis of the proventriculus and gizzard. In turkeys, a hereditary predisposition is also possible as well as stasis associated with an infection by *Candida*

albicans.

Macroscopic characteristics: The crop is distended with food and water. It can also be injured and have ulcers. There is a lack of muscle tone.

Action to be taken: The whole carcass is condemned when contaminated by the content of the crop or when the condition is associated with an abnormal smell. Septicemic or emaciated carcasses are also rejected.

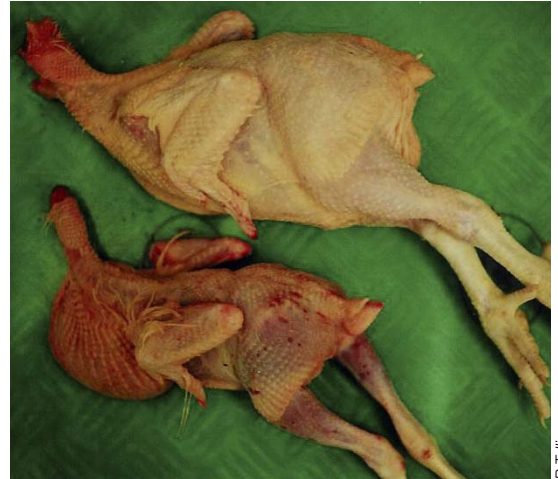
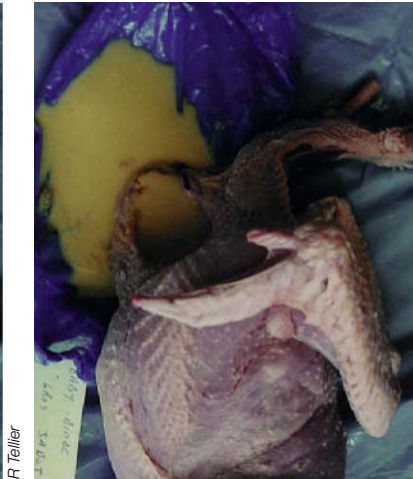
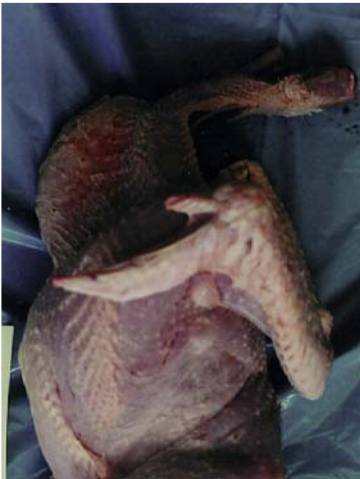Fig.75.8 & 75.9: Impaction of the crop (Turkey). Appearance before and after opening of the crop.

Fig.75.10: Impaction of the crop (Chicken). This anomaly is associated with stunting.

Section V

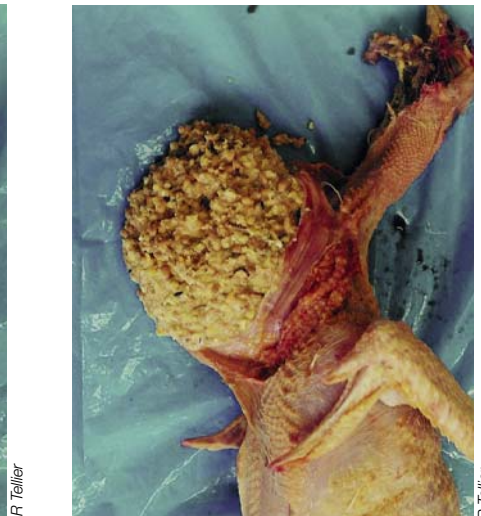
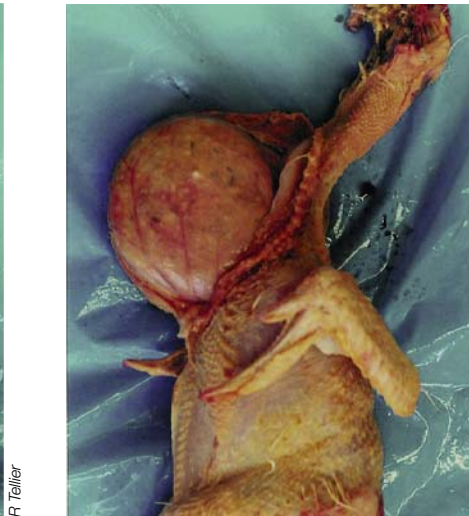
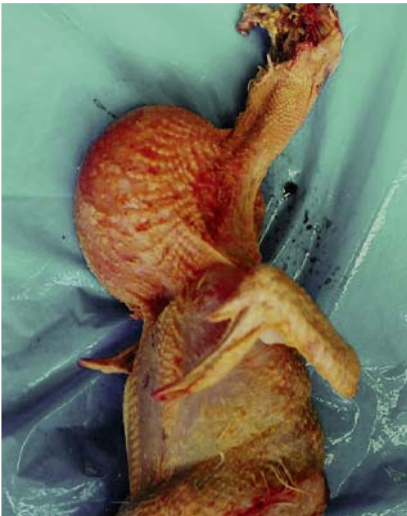

Fig.75.11, 75.12 & 75.13: Impaction of the crop (Chicken). Aspects before and after opening. Presence of many *Heterakis* in the crop.

Necrotic hepatitis

Etiology: Necrotic hepatitis is associated with an inflammatory process. Several bacteria or viruses are associated with liver lesions: *Clostridium perfringens*, *Escherichia coli*, *Salmonella*, *Pasteurella haemolytica* and adenoviruses. Frequently, *Campylobacter jejuni* and *Campylobacter coli* are isolated from livers with necrotic lesions. However, these bacteria can also be isolated from macroscopically normal livers. It should be noted that these two bacteria are found in the normal intestinal flora of birds. The pathogenesis of the infectious process is unknown, but chickens exposed to stress or to immunosuppressive factors may develop a

bacteremia. Thus, *Campylobacter* can migrate from the intestine to the liver and be responsible for hepatocyte necrosis.

Macroscopic characteristics: This disease is often not detected at *ante-mortem* inspection. At *post-mortem* inspection, small whitish foci are present on the surface of the liver. A systemic disease such as jaundice or emaciation can be associated with necrotic hepatitis.

Action to be taken: In cases of cachexia and jaundice, the whole carcass is condemned. When the lesion is localized, the carcass may be supplied for human consumption after rejection of the affected organs.

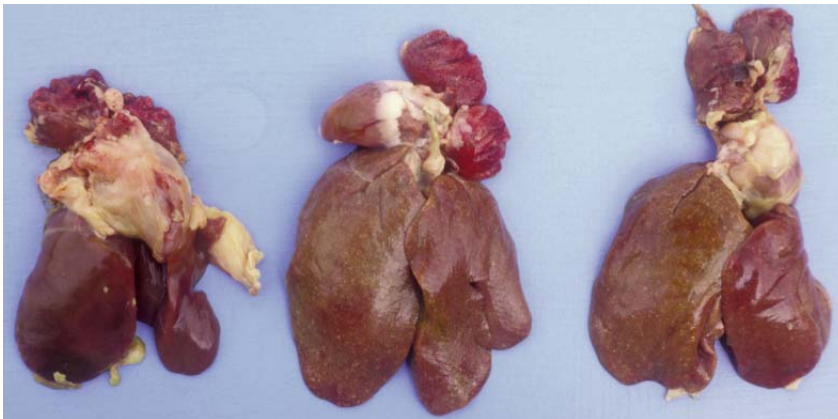

Fig.75.14: Necrotic hepatitis. Normal liver on left and the other two livers have multifocal white spots of few millimeters in diameter distributed over the entire liver. The affected livers are enlarged and pale.

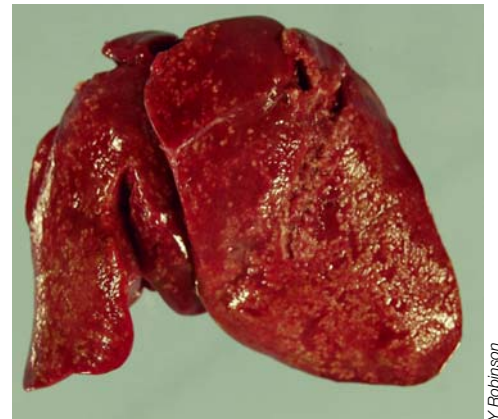


Fig.75.15: Necrotic hepatitis. Note the whitish pinpoint lesions on the surface of the liver.

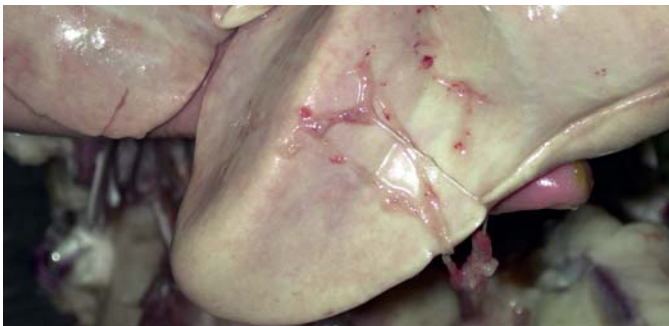

Fig.75.16: Deposition of fibrin on the visceral surface of the liver of a duck.

Perihepatitis

Etiology: It usually has the same infectious origins as airsacculitis. It can also be a consequence of enteritis or peritonitis.

Macroscopic characteristics: Fibrinous exudate is found on the liver capsule.

Action to be taken: The liver is rejected.

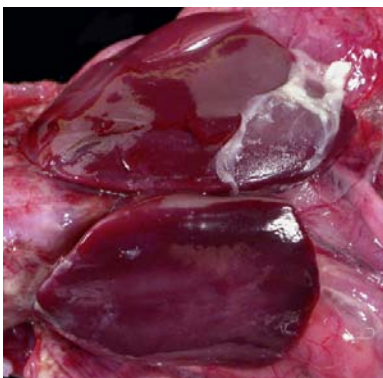


Fig.75.17: Colibacillosis perihepatitis (Turkey).

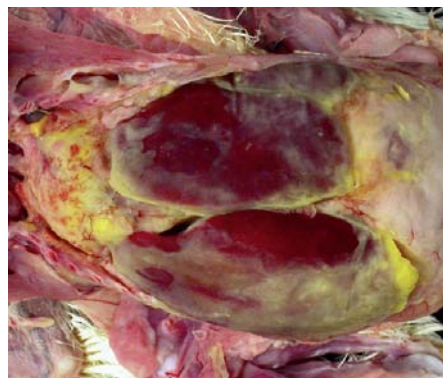
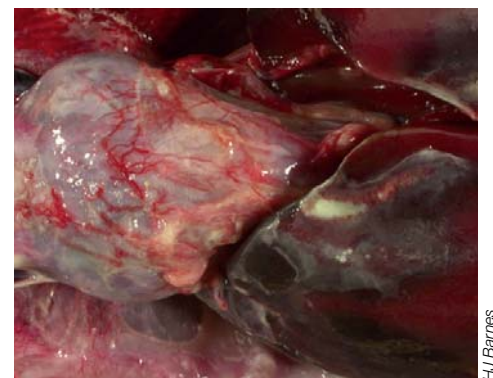
Fig.75.18 & 75.19: Coliform perihepatitis (Chicken). During colisepticemia, there are also other lesions such as pericarditis.



Coelomite or peritonitis

Etiology: It has the same origins as infectious airsacculitis and may be the result of a septicemia or an abdominal egg laying.

Macroscopic characteristics: Presence of a purulent exudate in the internal body cavity. In the case of abdominal egg laying, there is a mass of fibrinous material deposited in concentric layers around the egg yolk. Peritonitis may be accompanied by ascites. **Action to be taken:** The whole carcass is condemned.

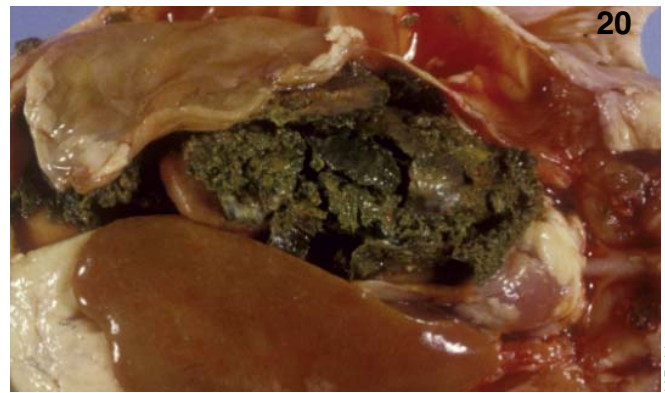


Fig.75.20: Peritonitis. Marked accumulation of fibrino-caseous exudate in the body cavity. Rupture of the gallbladder.

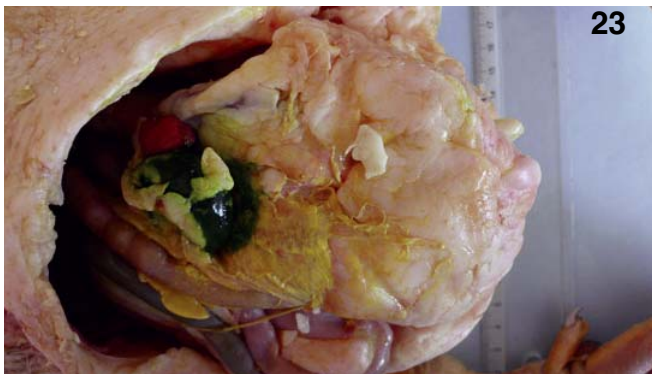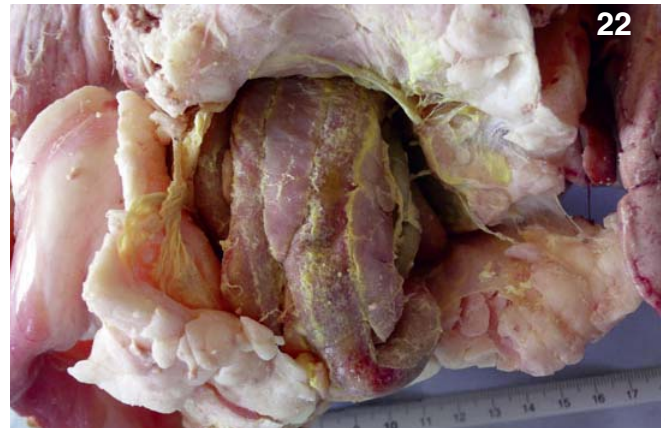

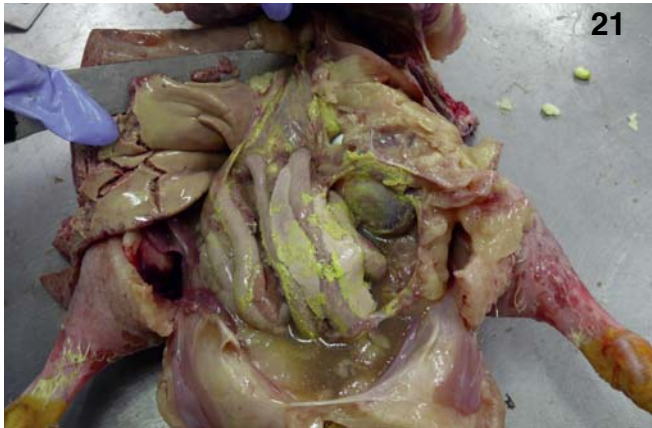
Fig.75.21, 75.22 & 75.23: Fibrinous peritonitis in ducks.

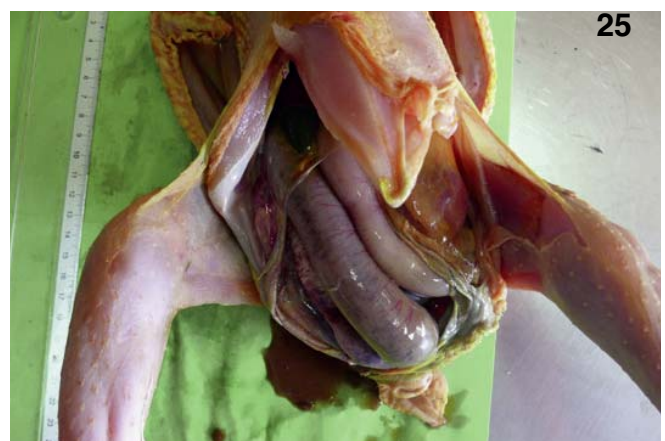
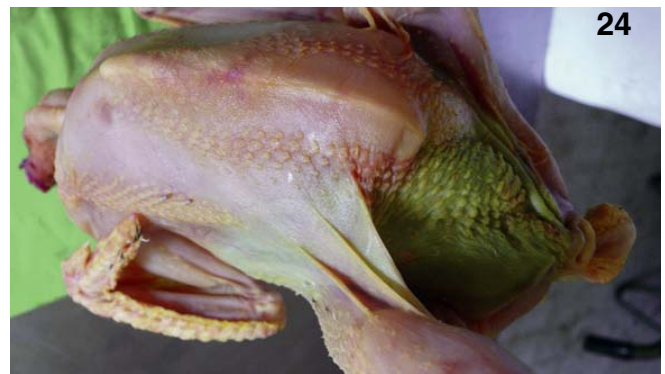

Fig.75.24 & 75.25: Enteritis. Top: greenish abdomen. Bottom: intestinal dilatation and presence of ascites with brownish liquid.

Enteritis

Etiology: Several pathogens may be associated with these lesions such as *Clostridium perfringens*, *Escherichia coli*, *Salmonella* spp.

Macroscopic characteristics: The skin of the abdominal cavity may present a more or less intense green color at the end of the slaughtering process. When the cavity is opened, the intestines are distended, swollen, congested and may have an abundant liquid content. The presence of lesions in other organs may influence the etiologic diagnosis.

Action to be taken: The whole carcass is condemned.

Jaundice

Etiology: Jaundice is characterized by increased levels of bilirubin in the blood and deposition of bile pigments in the tissues. There are numerous causes: poisoning, hepatitis, parasitic diseases.

Macroscopic characteristics: Jaundice is characterized by a yellowish discoloration of the skin, mucous membranes and sclera. Icteric birds can also be emaciated.

Action to be taken: A carcass with jaundice is condemned.

ABNORMALITIES OF THE CARDIOVASCULAR SYSTEM

Pericarditis

Etiology: It has the same origins as infectious airsacculitis.

Macroscopic characteristics: The pericardial sac is more or less thickened and contains an exudate.

Action to be taken: When the lesions are limited to the heart, the heart is rejected. When pericarditis is accompanied by other lesions, the whole carcass and offal are condemned.




Fig.75.26: Jaundice. Compare with the normal carcass corresponding to the same lot of chickens on the left.

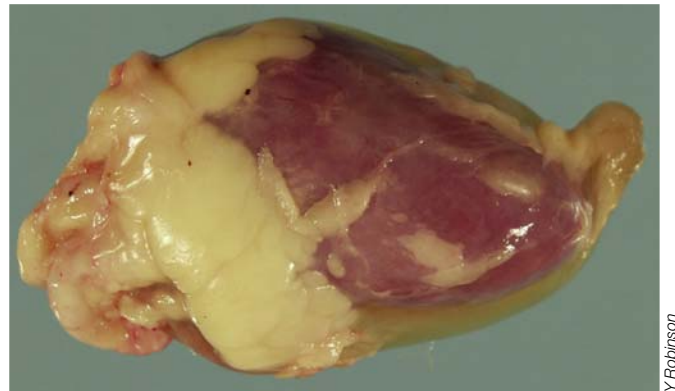


Fig.75.27: Pericarditis. Accumulation of clear yellow fluid in the pericardial sac.

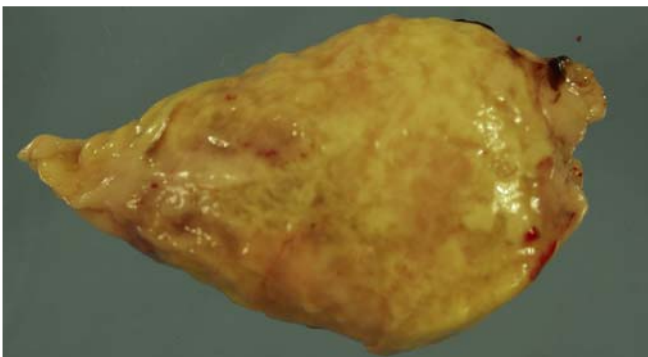


Fig.75.28: Pericarditis. Opacification of the pericardium with a fibrinous exudate accumulation in the pericardial sac

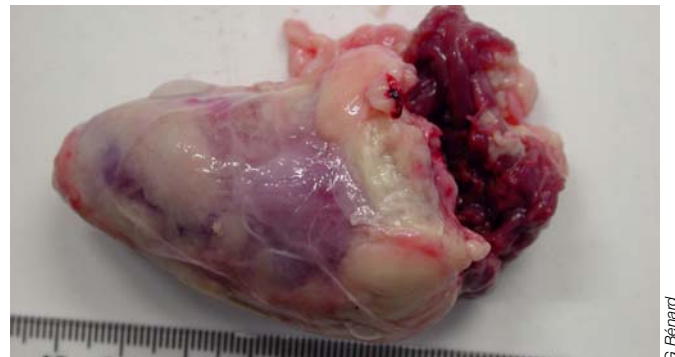

Fig.75.29: Pericarditis (Duck). Adhesion of the pericardium to the myocardium.

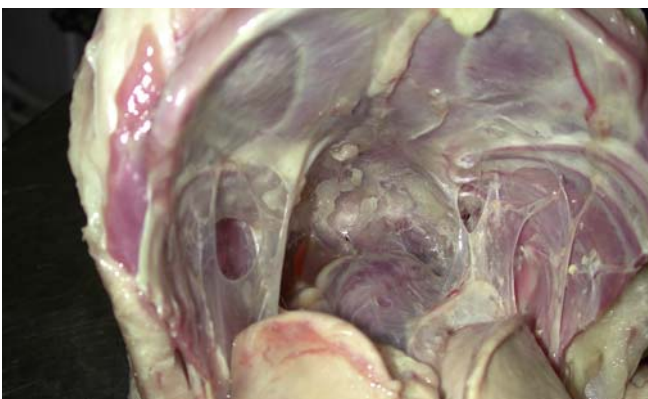


Fig.75.30: Pericarditis and sacculitis (Duck). Opacification of the air sacs and pericardium.

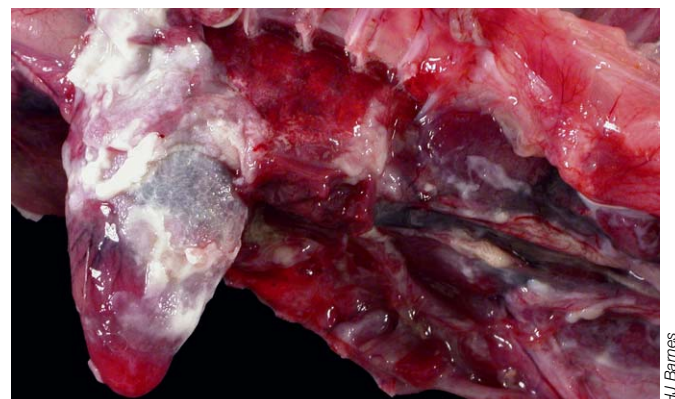
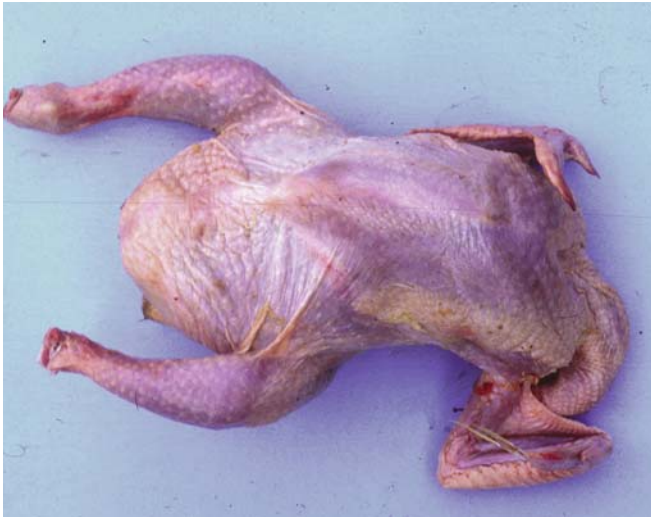

Fig.75.31: Pericarditis may appear as young as 4 weeks of age with colibacillosis (Turkey).

Ascites

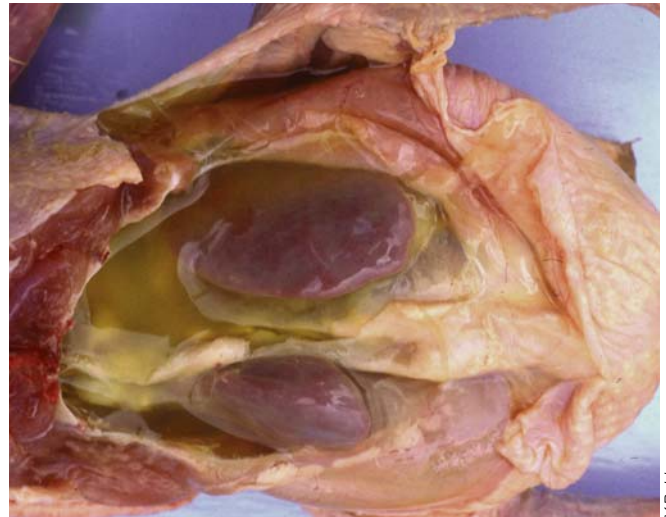
Etiology: Ascites is defined by the accumulation of serous fluid in the body cavity. In broilers, it is mainly associated with pulmonary hypertension due to the rapid growth of the birds. Rearing conditions such as temperature and air quality (dust concentration, level of carbon dioxide and oxygen) also influence the incidence of ascites. Other factors should be considered: diet, genetics, high altitude, rickets and respiratory diseases. Ascites can be the result of peritonitis.

Macroscopic characteristics: At ante-mortem inspection, birds present various degrees of abdominal distension. They can also be smaller and have breathing difficulties or even appear cyanotic. The lesions associated with ascites vary from mild to severe. They begin with hypertrophy or dilatation of the right ventricle with a congestion or edema of the lungs. Hydropericardium can then be observed, followed by an accumulation of fluid in the body cavity. The liver may have an irregular surface.
Action to be taken: Ascites leads to the condemnation of the carcass.



Y Robinson

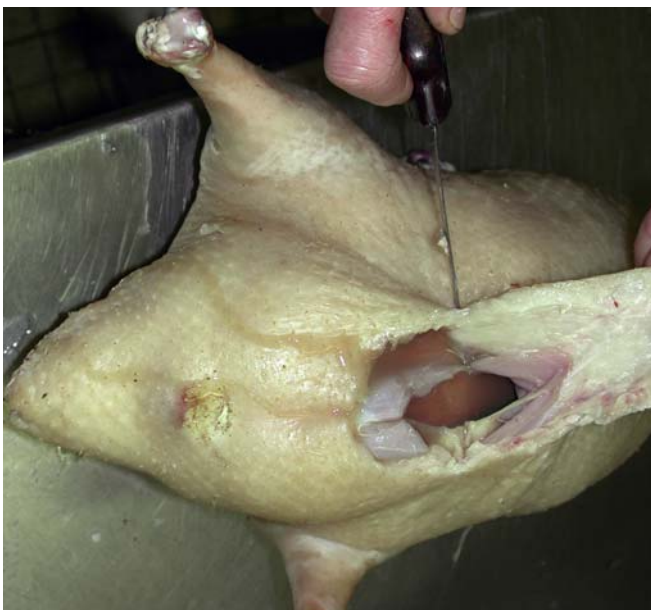Fig.75.32: Ascites. Carcass with the coelomic cavity dilated and a bluish discoloration of the abdominal wall.



Y Robinson

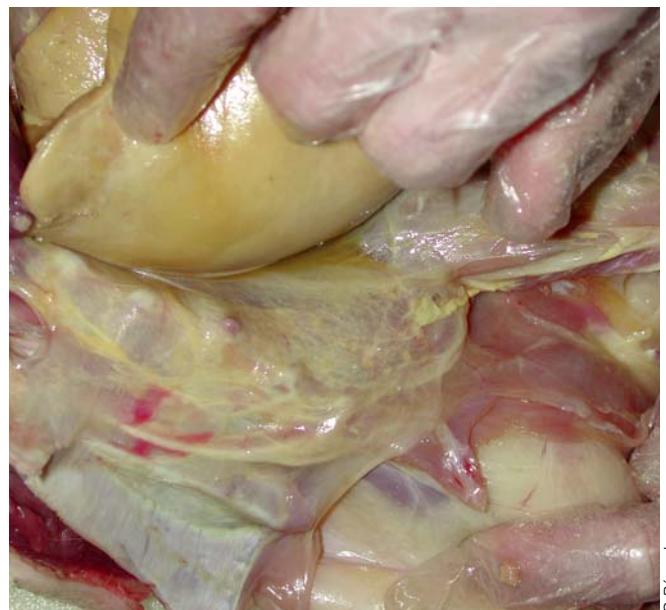Fig.75.33: Ascites. There is an accumulation of clear yellow liquid seen when opening the carcass.

Section V



G Bénéard

Fig.75.34: Ascites (Duck).



G Bénéard

Fig.75.35: Ascites associated with peritonitis.

ABNORMALITIES ASSOCIATED WITH THE HEMATOPOIETIC SYSTEM

Tumors

Etiology: Tumors can be seen, but due to the young age of most of the slaughtered birds, they are rare. The most common are lymphoid tumors associated with Marek's disease and, more rarely, with lymphoid leukemia.

Macroscopic characteristics: Presence of white nodules or diffuse infiltration manifested by an important enlargement of the liver and the spleen. In the particular case of Marek's disease, tumors of the feather follicles are mostly observed at the slaughterhouse after plucking.

Action to be taken: The affected carcasses are condemned.

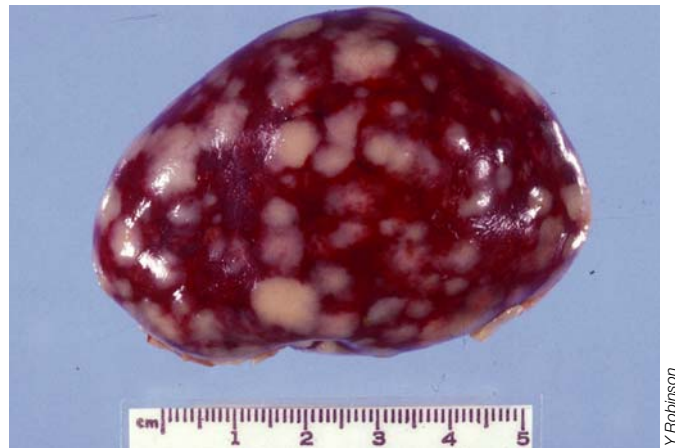

Fig.75.36: Marek's disease (or lymphoid leukemia). Spleen with numerous irregular whitish and multifocal coalescing foci of 1-8 millimeters in diameter.

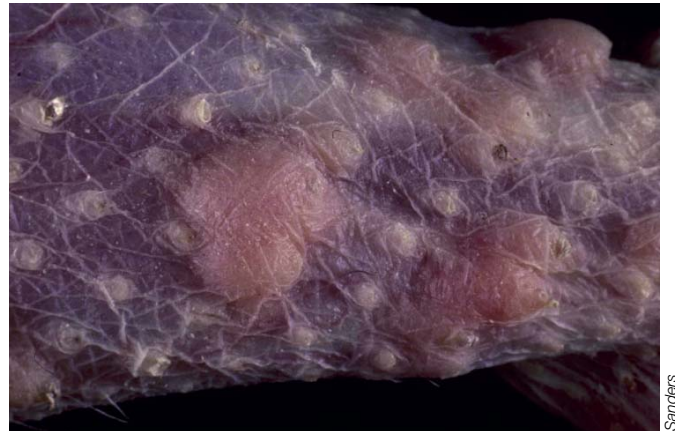

Fig.75.38: Marek's disease. Tumors of the feather follicles are mostly observed at the slaughterhouse after plucking.

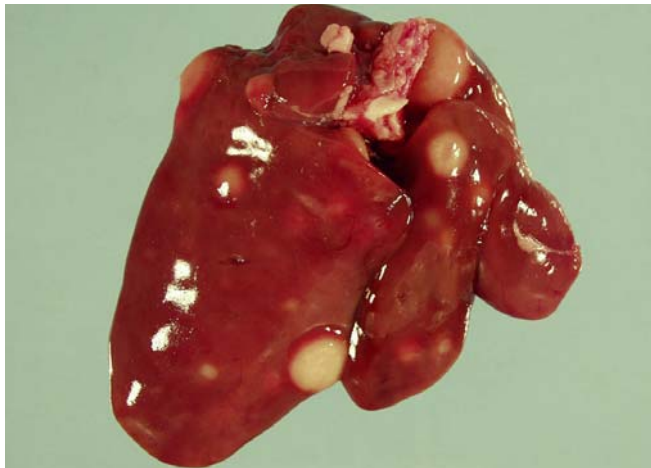

Fig.75.37: Marek's disease (or lymphoid leukemia). Spleen with numerous irregular whitish and multifocal coalescing foci of 1-8 millimeters in diameter.

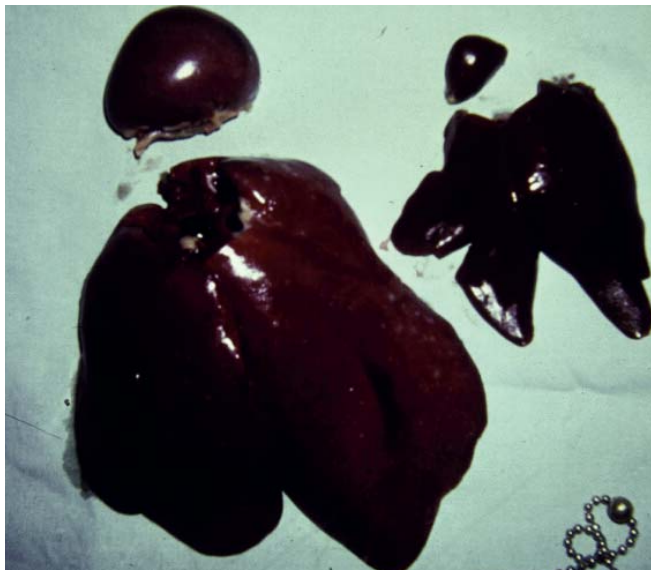

Fig.75.39: Marek's disease (or lymphocytic leukemia). The diffuse form of both diseases results in hepatomegaly and splenomegaly which are often severe; compare with the normal liver and spleen on right.

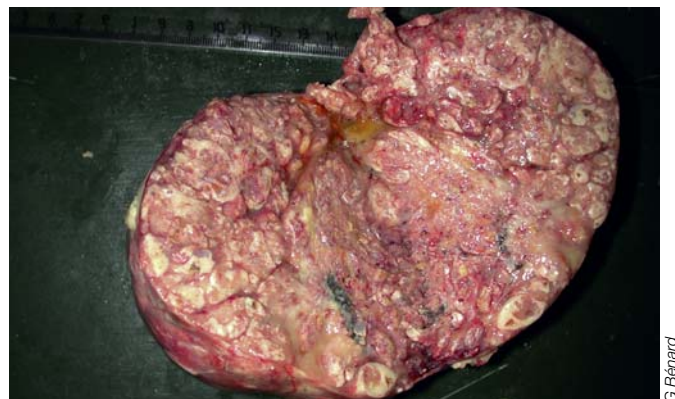
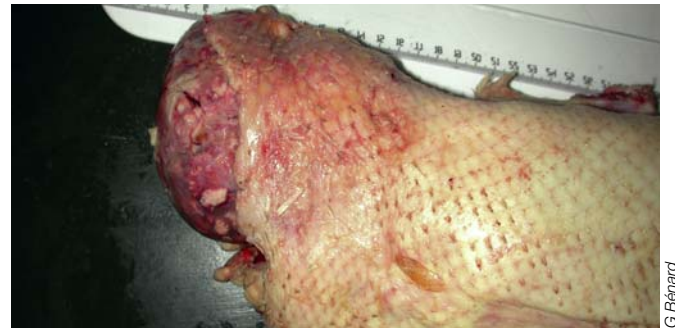
Fig.75.40 & 75.41: Teratoma (Duck). Appearance of the carcass before and after section of the tumor.

Y Robinson

Sanders

Y Robinson

G Bénard

J Brugère-Picoux

G Bénard

ABNORMALITIES OF MUSCLES AND BONES

Fractures

Etiology: When it occurs before slaughter, they are accompanied by a hemorrhage. If they result from an abnormality related to a problem with the slaughter line after bleeding, the hemorrhage will be absent.

Macroscopic characteristics: The broken bone may or may not puncture the skin. Hemorrhagic infiltration is more or less extended to the adjacent tissues.

Action to be taken: The affected areas are trimmed. In the absence of hemorrhage or perforation of the skin, the carcass may be sent for further processing.

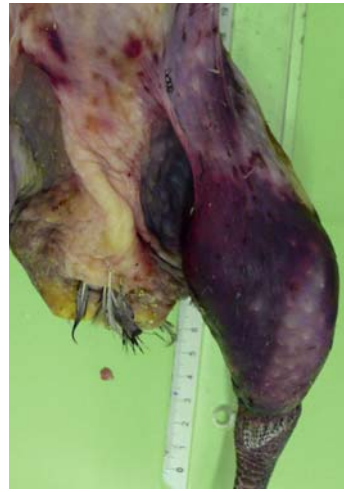

Fig.75.42: Fracture of tibiotarsus before slaughter (Guinea fowl).

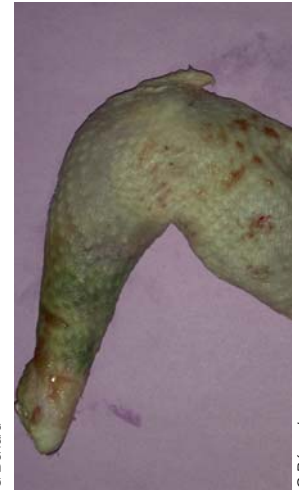

Fig.75.43: Fracture of tibiotarsus before slaughter. Subcutaneous hematoma.

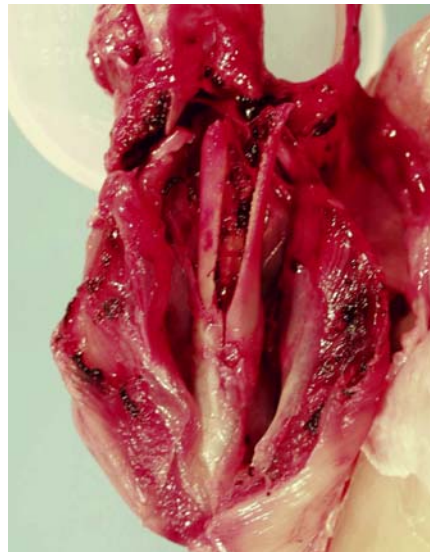
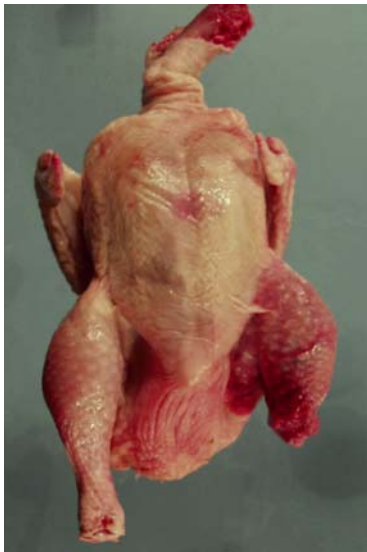
Fig.75.44 & 75.45: Fracture of tibiotarsus before slaughter. The left leg has a reddish color. At the opening, the fracture of the tibiotarsus is observed with marked muscle laceration and blood clots.

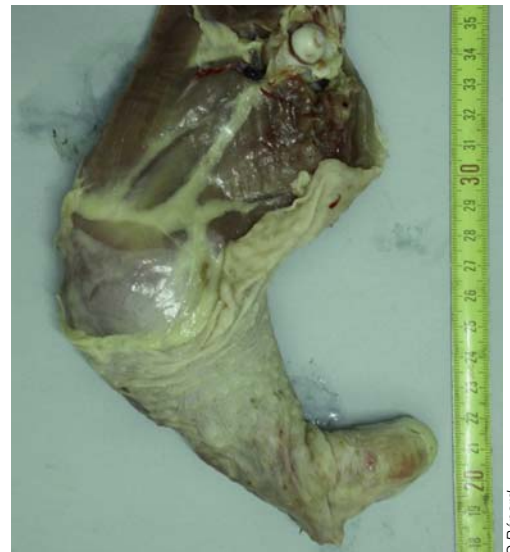

Fig.75.46: Fracture of tibiotarsus after slaughter. No visible hemorrhagic lesions.

Arthritis and synovitis

Etiology: They are most often caused by a viral (reovirus) or a bacterial (including *Staphylococcus* and *Mycoplasma*) infection. The lesion may be localized (coxo-femoral or tibiotarsal articulation), but it can also be generalized and affect other joints and/or synovial sheaths.

Macroscopic characteristics: Deformation of the joint area is noted. When cutting the joint, the synovial fluid may be hemorrhagic or purulent. Cartilage damage varies according to the etiology and chronicity of the infection.

Action to be taken: The affected parts are trimmed. If the infection is generalized, the whole carcass and offal are condemned.

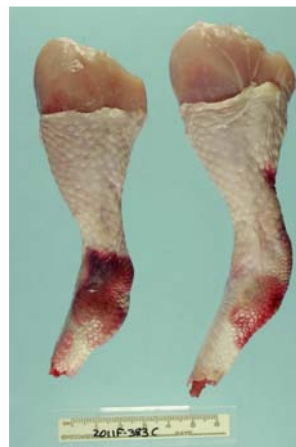

Fig.75.47: Arthritis and synovitis. Dark red discoloration of the skin and swelling of the tibiotarsal region.

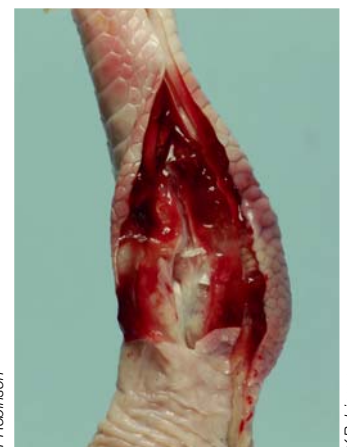

Fig.75.48: Arthritis and synovitis. Major bleeding and subcutaneous edema in the tibiotarsal region.

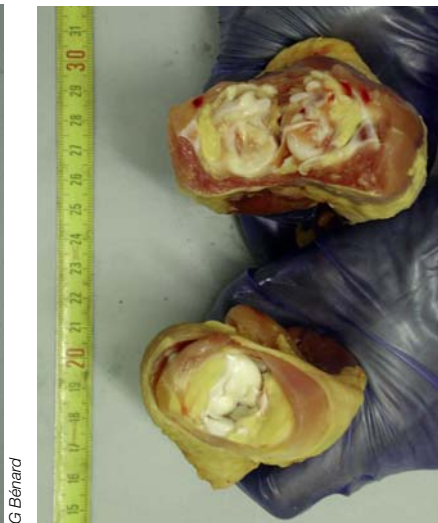
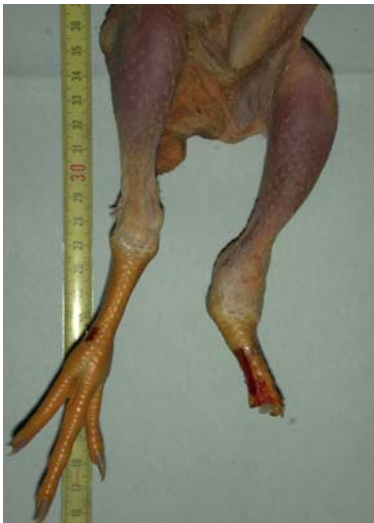
Fig.75.49 & 75.50: Arthritis and synovitis. Arthritis in a chicken before and after opening of the joint.

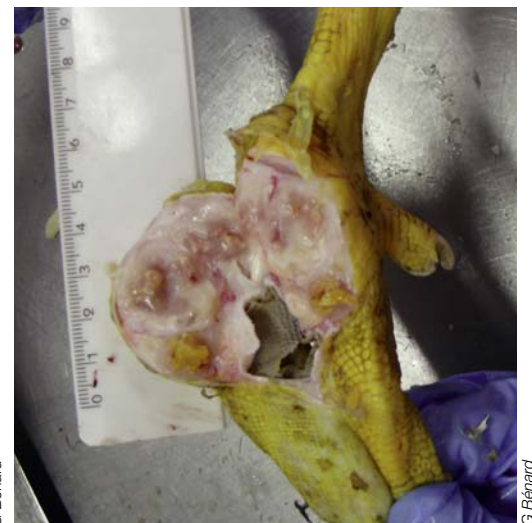


Fig.75.51: Arthritis and synovitis. Septic arthritis (concretion of pus visible).

Perosis and rickets

Etiology: These diseases usually have a nutritional origin (see Chap.IV.69 & IV.71).

Macroscopic characteristics: Deformation of the bones (external deviation of the tarsus in case of perosis) and/or the joints, distortion of the wishbone (for rickets).

Action to be taken: In case of severe deformity, the affected parts are trimmed. The whole carcass should be condemned if it is in poor condition.

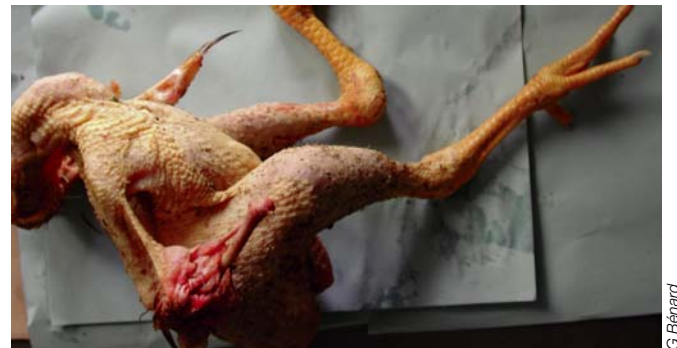

Fig.75.52: Perosis (Chicken).

Deep pectoral myopathy (Oregon disease)

Etiology: It results from ischemic necrosis of the supracoracoideus muscle after intense exercise, such as excessive wing flapping. Necrosis of the muscle follows. This lesion is found mainly in breeding flocks (broilers and turkeys).

Macroscopic characteristics: At first, the muscle is swollen, pale and edematous. Then, the necrotic muscle appears green and becomes brittle and dry,

hence the name green muscle disease (or Oregon disease). There is also muscle atrophy. The lesion may be unilateral or bilateral. Usually, the general condition of the bird is not affected.

Action to be taken: The lesion is considered sterile. It is not easy to detect it when the carcass is sold intact. After cooking, the greenish color persists. Chronic lesions can be detected by palpation. The affected muscle is rejected.

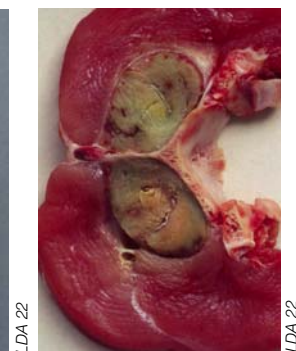
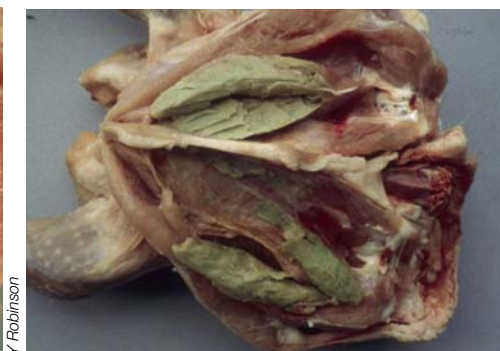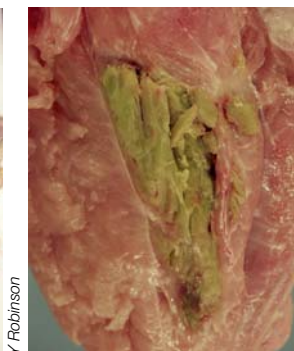


Fig.75.53, 75.54, 75.55 & 75.56: Deep pectoral myopathy (Oregon disease). Muscular ischemia resulting in a well circumscribed greenish discoloration within the pectoral muscle (supracoracoideus muscle). Left: cross section (Turkey).

ABNORMALITIES ASSOCIATED WITH THE REPRODUCTIVE SYSTEM

Salpingitis

Etiology: Inflammation of the oviduct is relatively common in pullets. *Escherichia coli* are often involved, as well as *Mycoplasma*.

Macroscopic characteristics: The infection is often

limited to the oviduct and is manifested by the presence of yellowish purulent material. Sometimes the oviduct ruptures and peritonitis follows. The lesion may also be accompanied by airsacculitis.

Action to be taken: The organ is condemned and the rest of the carcass is considered fit for human consumption if there are no systemic effects. Otherwise, the whole carcass and offal are condemned.

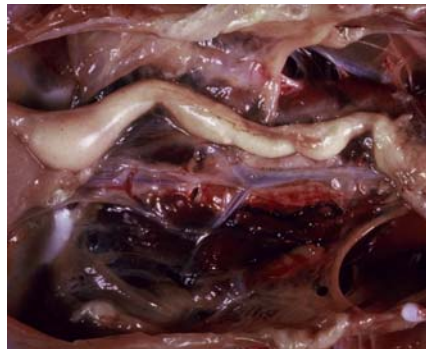
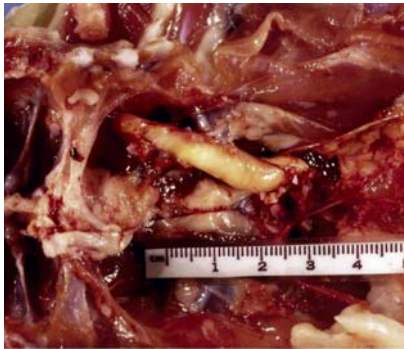


Fig.75.57 & 75.58: Salpingitis. Oviduct with a white tubular structure filled with caseous material.

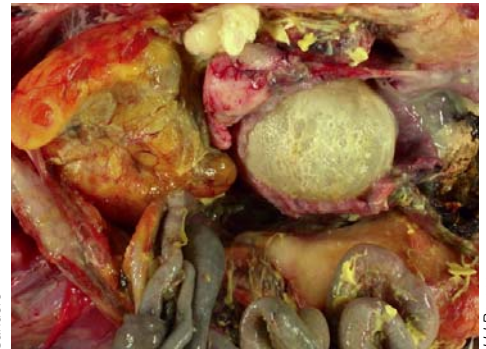

Fig.75.59: Salpingitis and oophoritis associated with peritonitis (Fowl).

ABNORMALITIES OF THE SKIN AND SUBCUTANEOUS TISSUES

Cellulitis

Etiology: In most cases, *Escherichia coli* are isolated from lesions of cellulitis. In 60% to 90% of cases, it is the only microbial agent present. *Streptococcus dysgalactiae*, *Pasteurella multocida*, *Pseudomonas aeruginosa*, *Enterobacter agglomerans* and *Proteus vulgaris* can also be isolated.

Macroscopic characteristics: Cellulitis is an inflammation of the subcutaneous tissue accompanied by fibrinous or fibrinopurulent exudate. Typically, unilateral or bilateral lesions are located in the peri-cloacal and abdominal regions. They are characterized by a yellowish to brownish discoloration of the skin. The lesions may appear as early as 8 hours after experimental inoculation with *E. coli* and are clearly visible after 24 hours. They normally cover an area from 1 to 10 cm in diameter (0.4 to 4 inches), but can reach up to 15 cm (6 inches). Pericarditis, airsacculitis, osteomyelitis, arthritis and perihepatitis may also be observed in carcasses affected by cellulitis. High bird density

and lack of hygiene are predisposing factors. At the *ante-mortem* inspection, birds with cellulitis do not show clinical signs. The diagnosis is performed during the *post-mortem* inspection. Cellulitis is a major cause of condemnation resulting in significant economic losses. The same strain of *E. coli* can cause systemic lesions and cellulitis. Therefore, a carcass simultaneously affected with cellulitis and concomitant systemic infection could be a public health issue. In many cases, the visceral infection is independent of cellulitis. The human pathogenic potential of strains responsible for cellulitis is unknown. However, some strains are genetically similar to those causing sepsis and meningitis in humans.

Action to be taken: Lesions less than 16 cm² (2.5 square inches) are often trimmed (criteria vary depending on a country's regulations). However, the bacteria can be present beyond visible lesions. Thus, localized lesions without systemic involvement can be trimmed and the carcass should be considered fit for human consumption. The whole carcass is condemned when the lesions are localized and accompanied by systemic signs or when extensive lesions make trimming difficult.

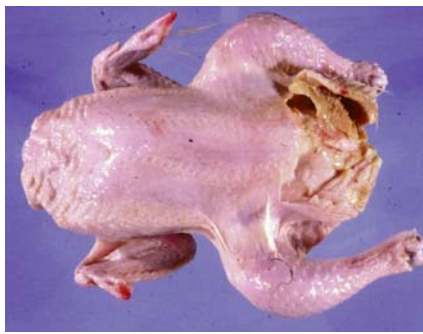
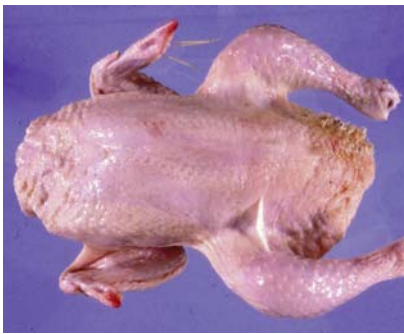
Fig.75.60 & 75.61: Cellulitis. Focal thickening and discoloration of the skin in the peri-cloacal area. When opening the lesion, a marked fibrino-caseous exudate accumulated in the peri-cloacal area can be seen.

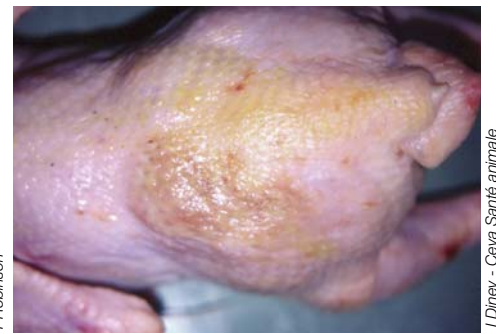


Fig.75.62: Cellulitis (Chicken). Yellow-brownish skin lesions.

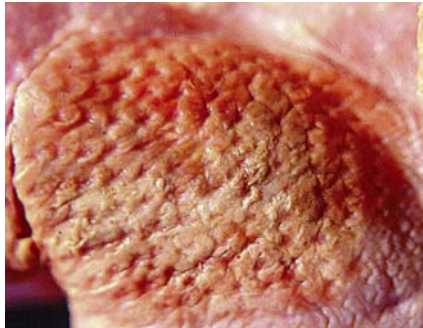
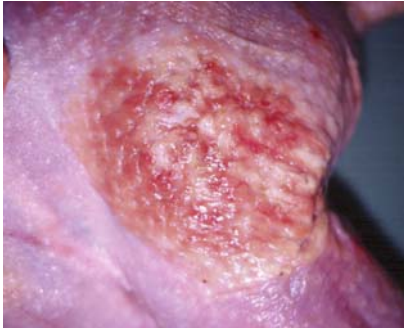

Fig.75.63 & 75.64: Cellulitis (Chicken). The areas most affected are the back and thighs. Sometimes you can notice a slight protuberance compared with the adjacent normal skin.

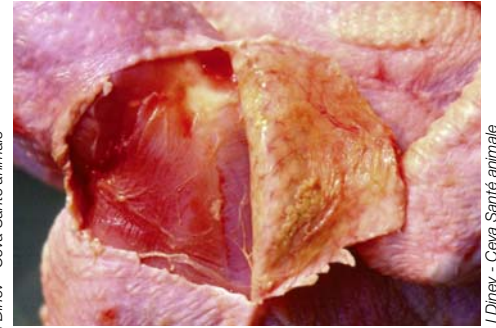


Fig.75.65: Cellulitis (Chicken). The subcutaneous tissue often has fibrin plaques.

Skin abscesses

Etiology: They can be observed following secondary infection of breast blisters or a bumble foot. Other cutaneous locations may be observed when there is pecking in the flock.

Macroscopic characteristics: The lesion is

characterized by a fibrous mass containing dry purulent material, but it may extend to the subcutaneous connective tissue leading to a phlegmon.

Action to be taken: For localized lesions, trimming is done. If the infection is generalized, the whole carcass should be condemned.

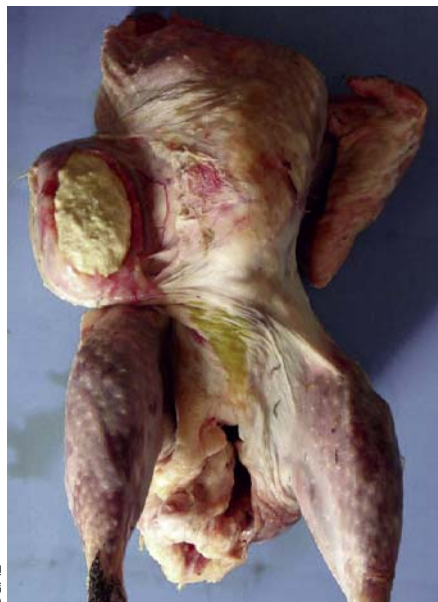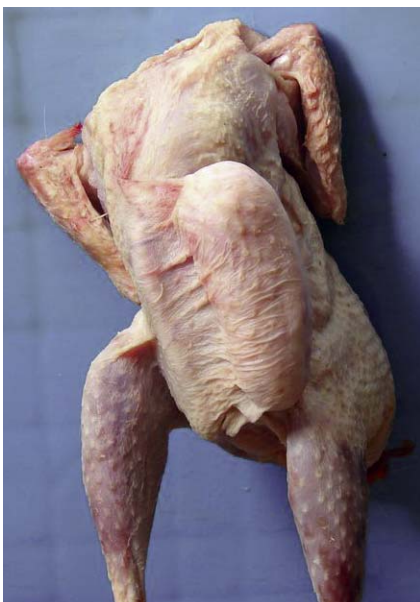


Fig.75.66 & 75.67: Abscess of the keel (Guinea fowl) before and after opening.

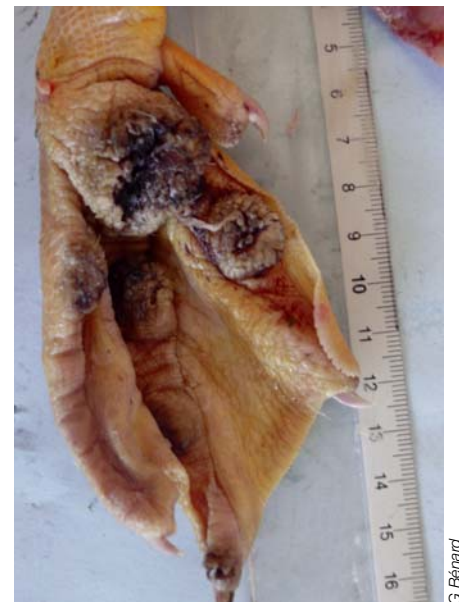

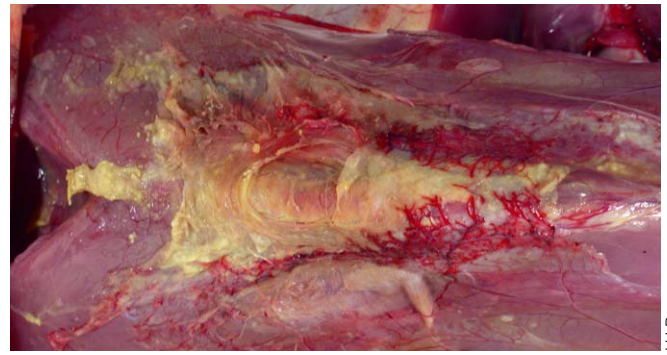
Fig.75.68: Foot abscess (Duck).

Breast bursitis

Etiology: It is associated with repeated injuries to the breast bone area.

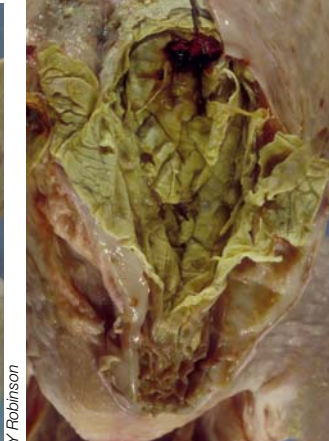
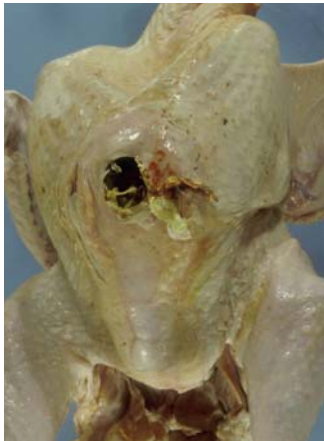Macroscopic characteristics: Presence of blisters of variable size which can sometimes be hemorrhagic and can become infected.

Action to be taken: If the lesions are localized, breast blisters should be trimmed. Sometimes the affected tissue adheres to the bone, and a large area has to be trimmed.



H.J Barnes

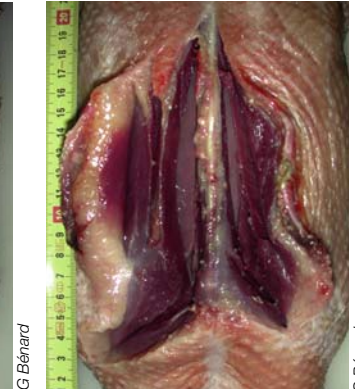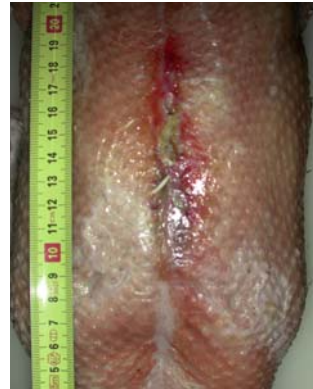Fig.75.69: Sternal bursitis (Chicken). This bursitis is associated with arthritis and synovitis.



Y Robinson

Y Robinson

Fig.75.70 & 75.71: Marked dilatation of sternal bursa with perforation. Presence of fibrino-caseous exudate in sternal bursa.



G Bénard

G Bénard

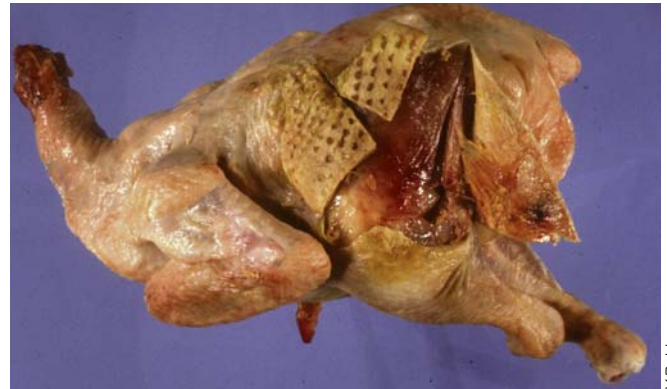Fig.75.72 & 75.73: Sternal dermatitis with purulent damage.

Dermatitis

Etiology: They are most often caused by a bacterial infection, in particular by *Clostridium* spp. or *Staphylococcus* spp. (see Chap.IV.51 & IV.57). It can also be caused by a viral disease (cutaneous form of Marek's disease).

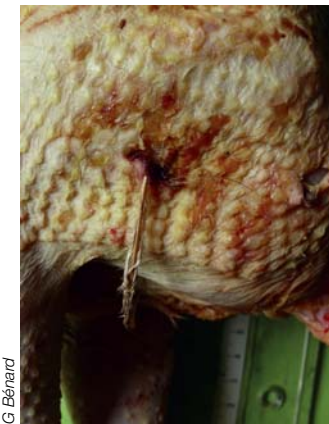
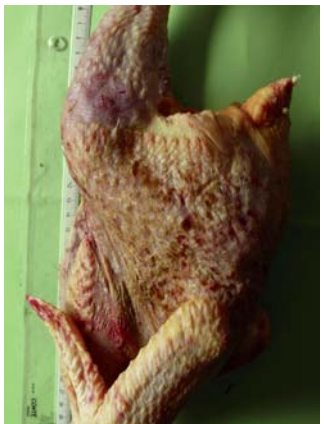Macroscopic characteristics: The appearance of the lesion is variable depending on the pathogen involved. A serofibrinous or necrotic inflammation is found on the legs, the flanks or the wings.

Action to be taken: The whole carcass is condemned.



Y Robinson

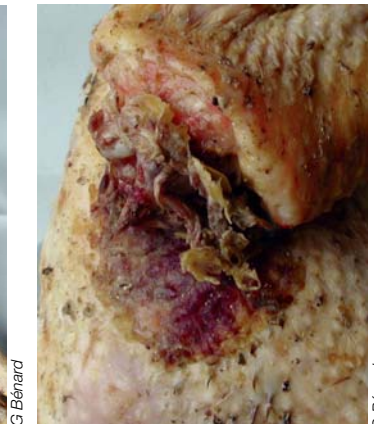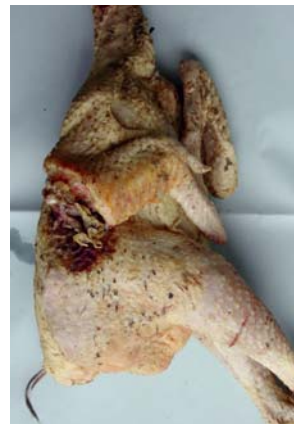Fig.75.74: Dermatitis. Cooked appearance and thickening of the skin in the thigh area. Note the extension of the inflammation to the subcutaneous adjacent tissue.



G Bénard

G Bénard

Fig.75.75 & 75.76: Dermatitis with necrosis of the carpal joint.



G Bénard

G Bénard

Fig.75.77 & 75.78: Necrotic dermatitis. More detailed view of gangrene on the right.

Section V

Bruises, scratches, bruises and hematomas

Etiology: The visible injuries on the skin ranging from bruises to tears can occur mainly during crating, transportation and hanging of the birds on the slaughter line.

Macroscopic characteristics: Bruises or hematomas present areas from red to green depending on the age of the lesion. The skin may show lacerations which may be septic if the trauma occurs

prior to transportation to the slaughterhouse. Tear and hematoma may be accompanied by damage to underlying tissues (muscle and adipose tissues), which will result in the removal of affected parts.

Action to be taken: Depending on the extent of the damage, trimming, partial condemnation or total condemnation can occur. Bruises and scratches with secondary infection normally lead to the condemnation of the entire carcass.

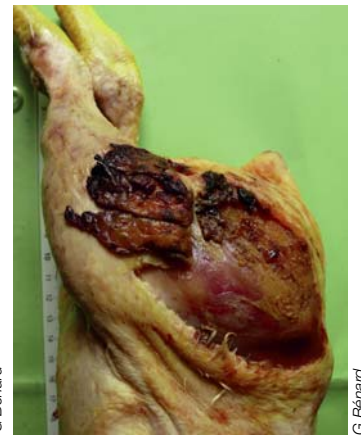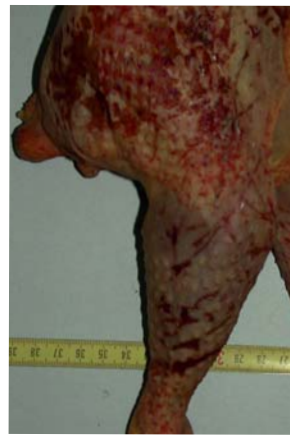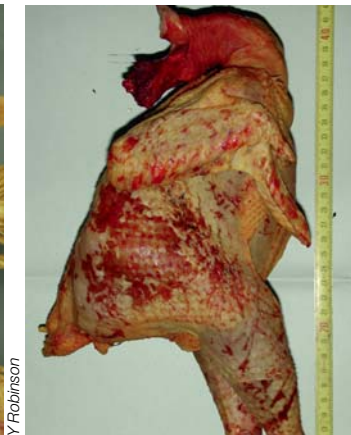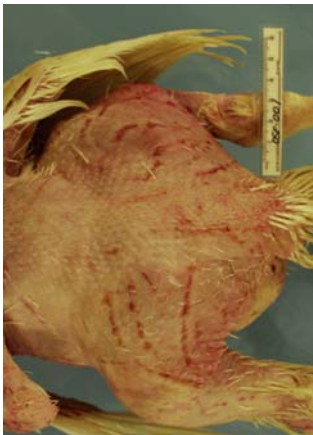


Fig.75.79: Skin lacerations on a broiler.

Fig.75.80 & 75.81: Traumatic skin lesions (Fowl). Detail on right.

Fig.75.82: Cutaneous bruises in a broiler.

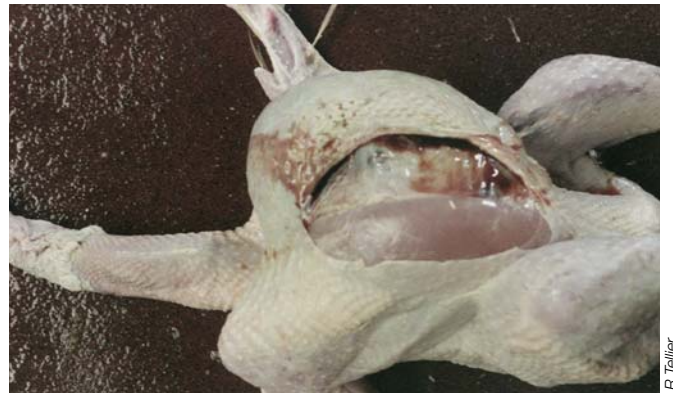

Fig.75.83 & 75.84: Subcutaneous hematoma in a turkey before and after opening.

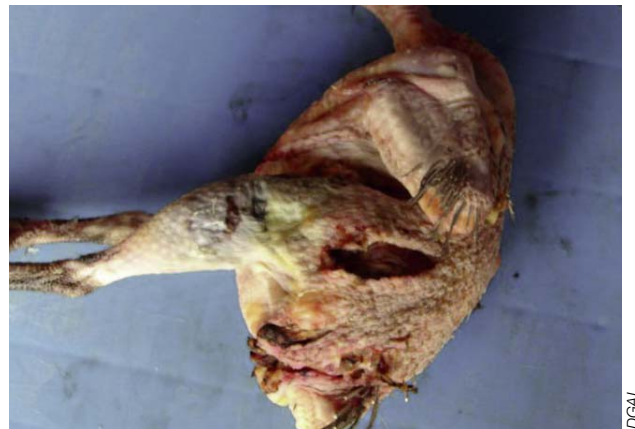
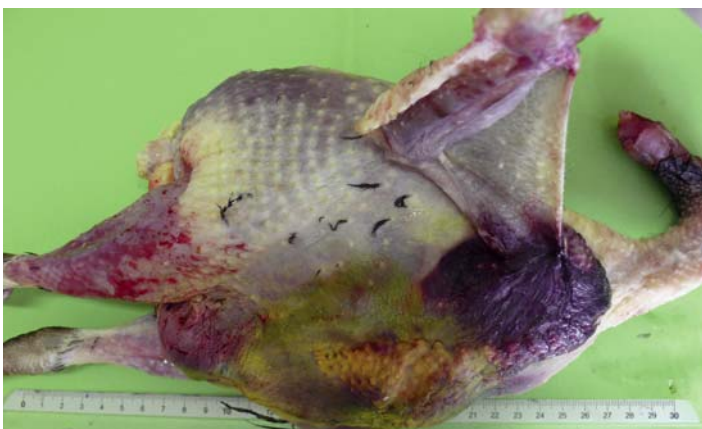
Fig.75.85: Subcutaneous hematoma.

Fig.75.86: Scratches and pecking on a guinea fowl with surinfection.

Subcutaneous emphysema

Etiology: This condition may be related to a systemic infection caused by anaerobic bacteria (*Clostridium*) or trauma (rupture of an air sac).

Macroscopic characteristics: The carcass appears «puffy» on the slaughter line.

Action to be taken: The carcass is condemned.

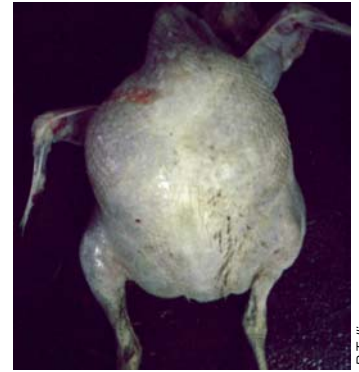
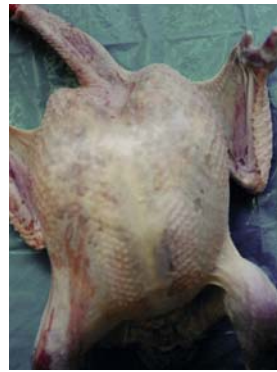
Fig.75.87 & 75.88: Subcutaneous emphysema of the carcass (Turkey).

MULTIPLE OR EXTENSIVE DEFECTS

Birds dead before slaughter

Birds dead on arrival are not allowed on the slaughter line. Birds may die during transportation or while waiting to be slaughtered. They are condemned.



Fig.75.89: Chicken dead on arrival.

Cyanosis (dark colored carcass)

Etiology: Cyanosis may result from stress during transportation (crowding and hot temperature) or may be associated with respiratory diseases. It seems that cyanotic carcasses have a higher pH than normal carcasses.

Macroscopic characteristics: The carcass is usually darker and bluish, especially the skin, the muscles and the mucous membranes.

Action to be taken: The decision is based on the degree of coloration of the skin and the general aspect of the carcass. Very dark carcasses are condemned due to organoleptic considerations.



Fig.75.90: Cyanosis. The carcass on the right is normal, the other two carcasses have a darker bluish discoloration of the pectoral muscles, uniform discoloration for the carcass in the center; less so for the carcass on the left.

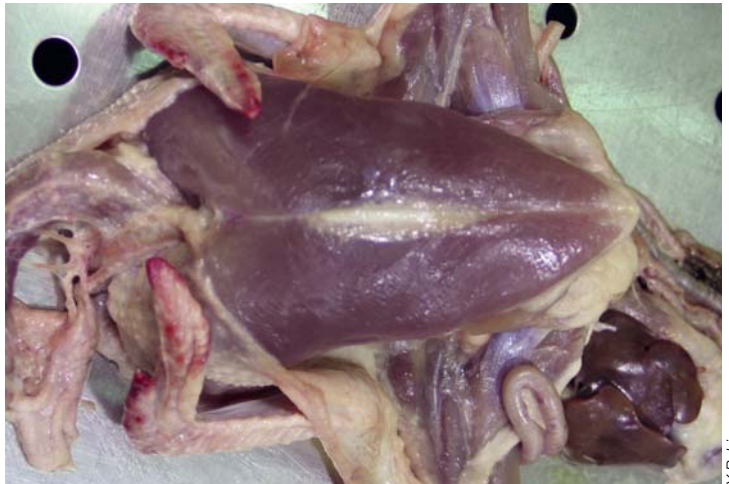

Fig.75.91: Cyanosis of a carcass.

Wasting, emaciation

Etiology: This is a poor condition of the whole carcass due to nutritional deficiencies or because of a debilitating disease.

Macroscopic characteristics: Carcasses appear emaciated (decrease in the volume of muscles, absence of fat and protrusion of the breastbone).

Action to be taken: This anomaly results in total condemnation of the carcass.

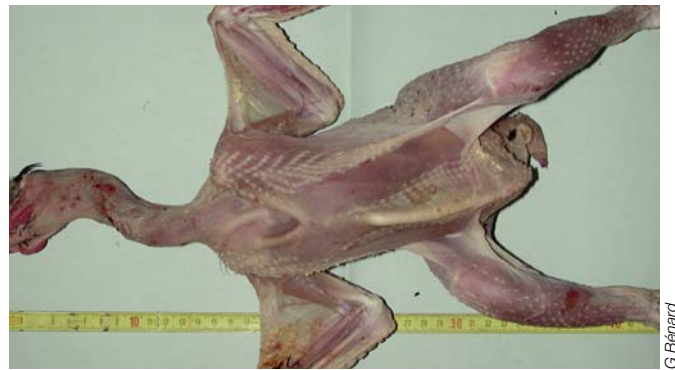

Fig.75.92: Emaciation (Chicken).

G Bénard

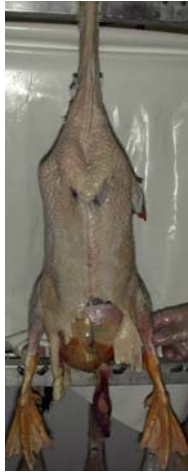

Fig. 75.93: Emaciation (Duck).

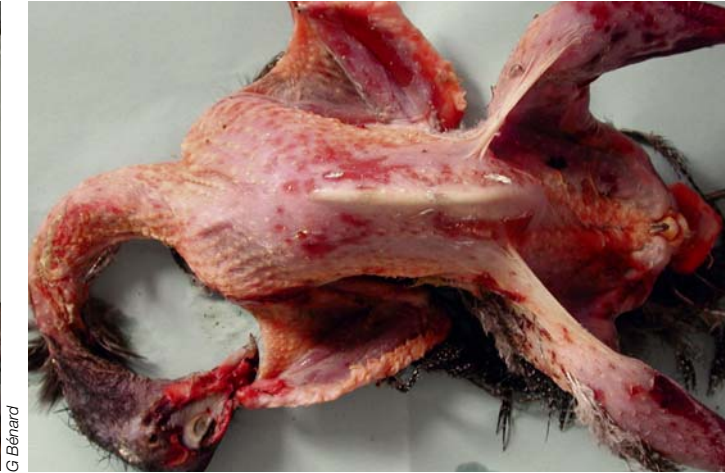

Fig.75.94: Emaciation (Guinea fowl).

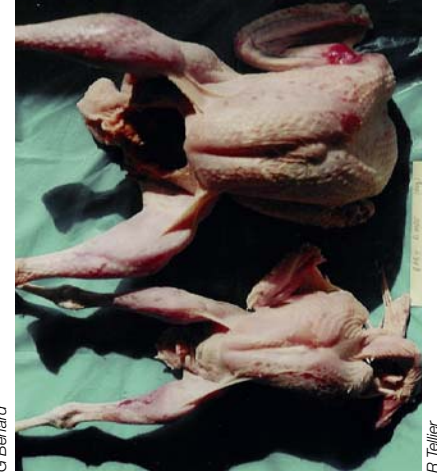

Fig.75.95: Bottom: Emaciated turkey (compared to a normal turkey on top).

R Teller

Septicemia or toxemia

Etiology: Various etiologies are recognized (*Escherichia coli*, *Salmonella*, *Pasteurella*, *Clostridium*, etc.).

Macroscopic characteristics: Depending on the causative agent and the duration of the disease, offal and carcasses have various lesions (petechial hemorrhages, necrosis, etc.).

Action to be taken: The whole carcass and offal are condemned.

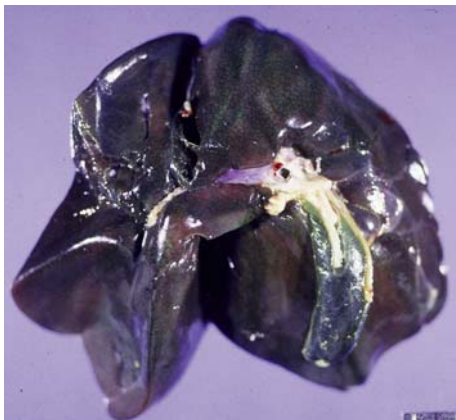


Fig.75.97: Liver septicemia (staphylococcosis).

HL Shrivaprasad

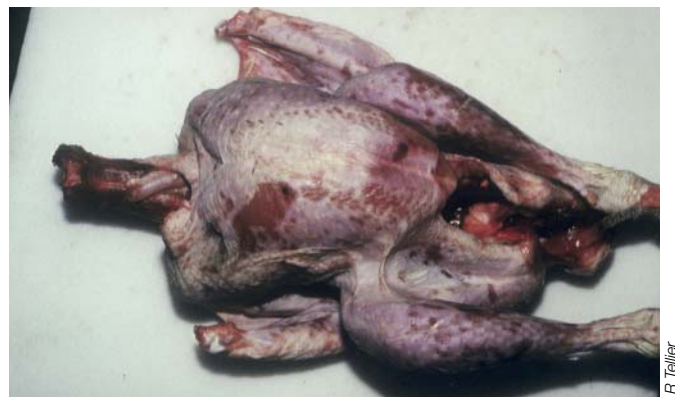

Fig.75.96: Severe congestion of a carcass (Turkey).

R Teller

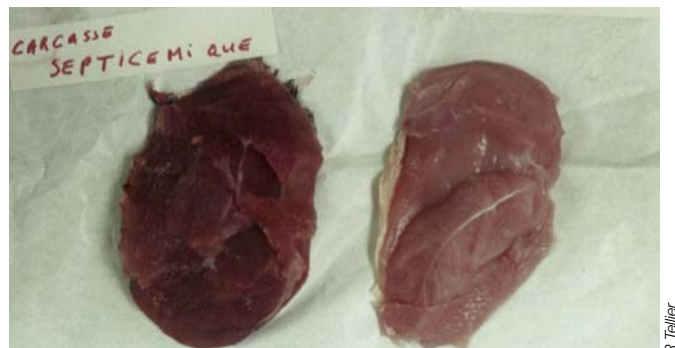

Fig.75.98: There is also a more pronounced coloration of the muscles (Turkey).

R Teller

PROCESSING DEFECTS

Inadequate bleeding

Etiology: Inadequate bleeding may be due to a technical problem (the bird was not bled or blood could not flow properly).

Macroscopic characteristics: A cherry red colored skin is observed on either a portion of or on the entire carcass. It is usually seen in the neck area.

Action to be taken: The shelf life of the meat is reduced. Carcass and offal are unfit for human consumption.

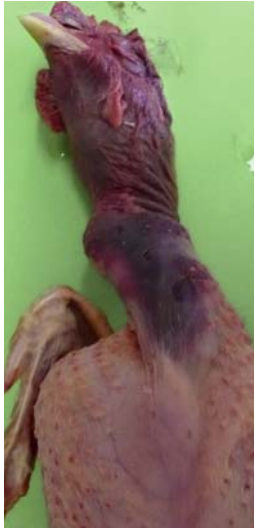

Fig.75.99: Carcass not bled.

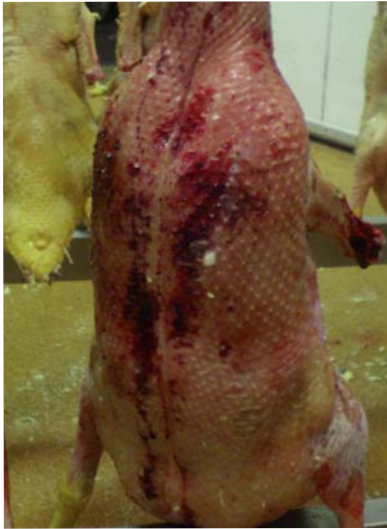

Fig.75.100: Carcass inadequately bled (Duck).

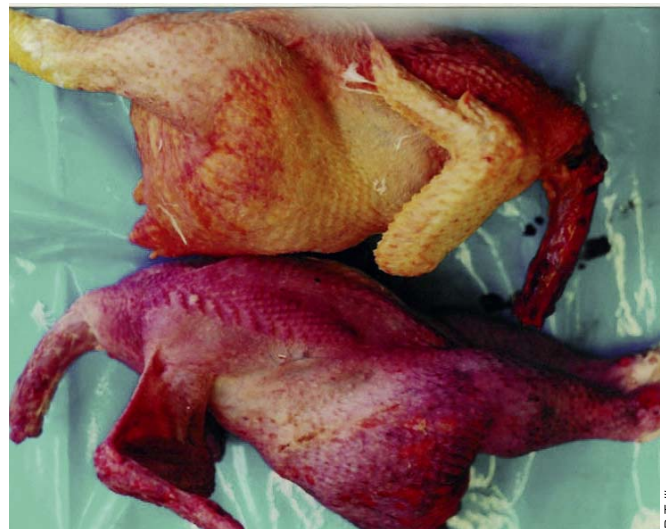

Fig.75.101: Chicken inadequately bled and chicken not bled.

Carcass contamination

Etiology: The carcasses may be contaminated following the rupture of segments of the digestive tract: pendulous crop, intestine, gall bladder, etc.

Macroscopic characteristics: Presence of food debris or fecal material in the cavities or on the skin.

Action to be taken: It is possible to clean the carcasses if the contamination is limited. The carcass is condemned if there is an important contamination with bile, feces and/or food debris. In some countries, cleaning is not allowed and the carcass is condemned.

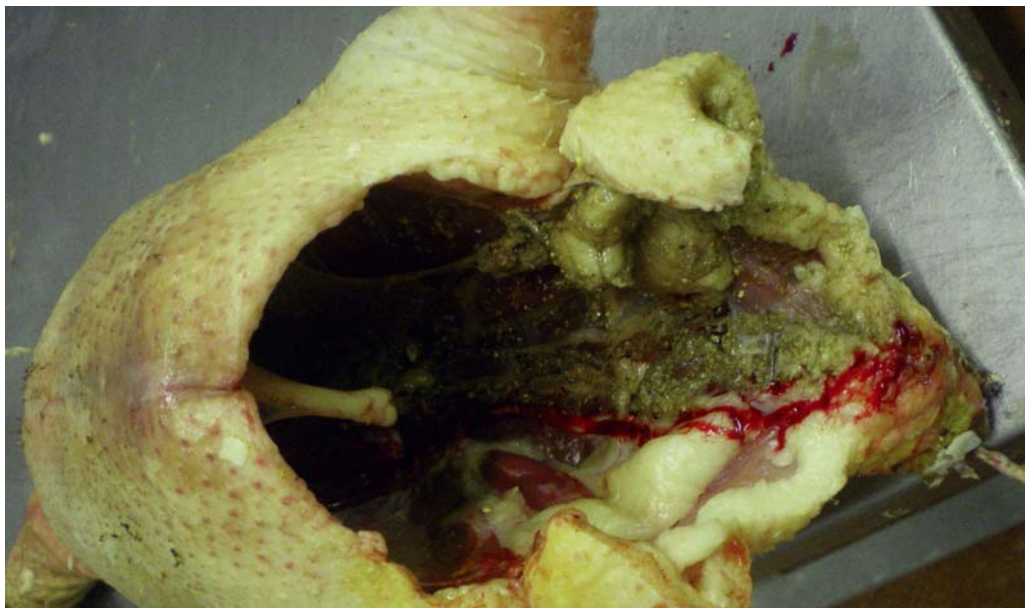


Fig.75.102: Contaminated coelomic cavity (Duck).

Section V

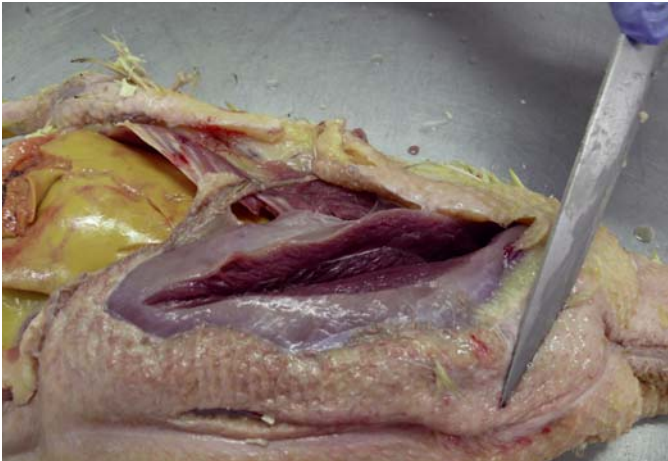Abnormalities related to plucking and overscalding

Etiology: It is a malfunction of the scalding bath and/or plucking equipment. It can also be a problem with the size of carcasses particularly with cachectic birds.

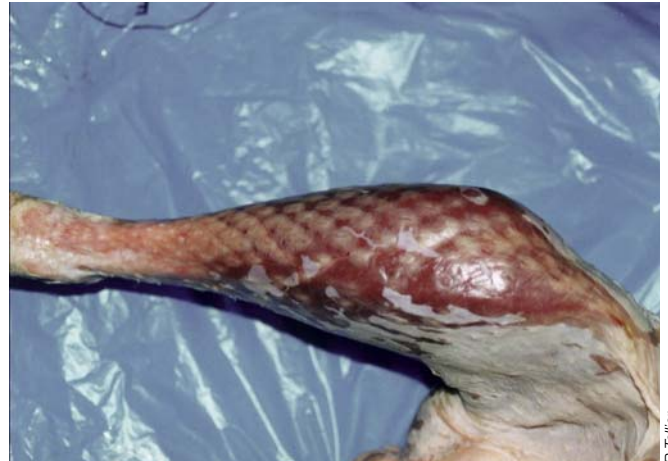Macroscopic characteristics: Presence of feathers

and/or tearing of the skin. In the case of prolonged scalding, there is a change in skin color (slimy, whitish color of the skin, underlying muscles with a cooked appearance).

Action to be taken: It is important to review the slaughter line process. Decision depends on the extent of abnormalities.

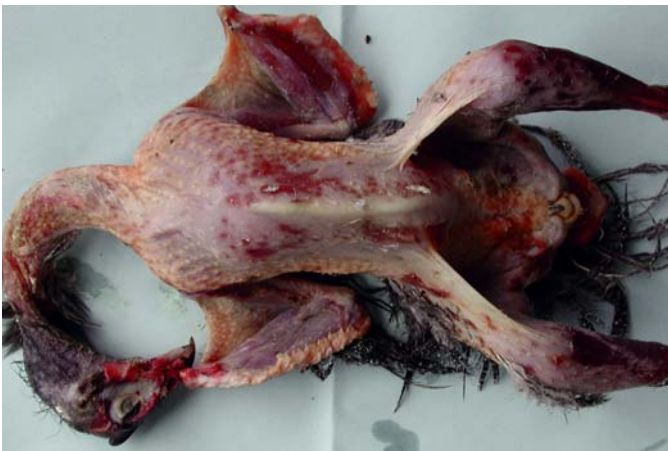

G Bénard

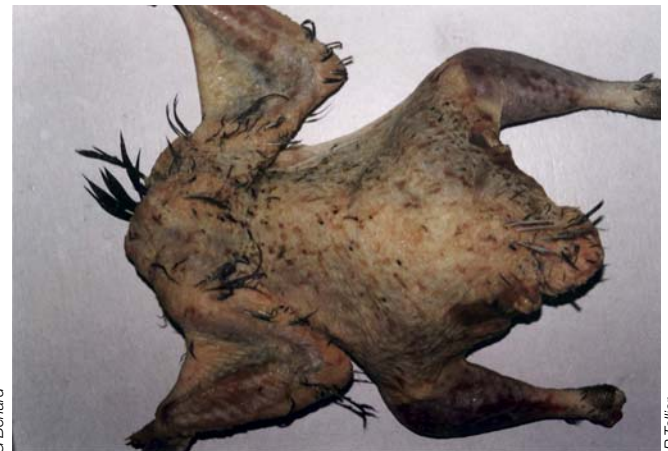

R Teller

Fig.75.103 & 75.104: Overscald.



G Bénard



R Teller

Fig.75.105 & 75.106: Inadequate plucking (Guinea fowl).

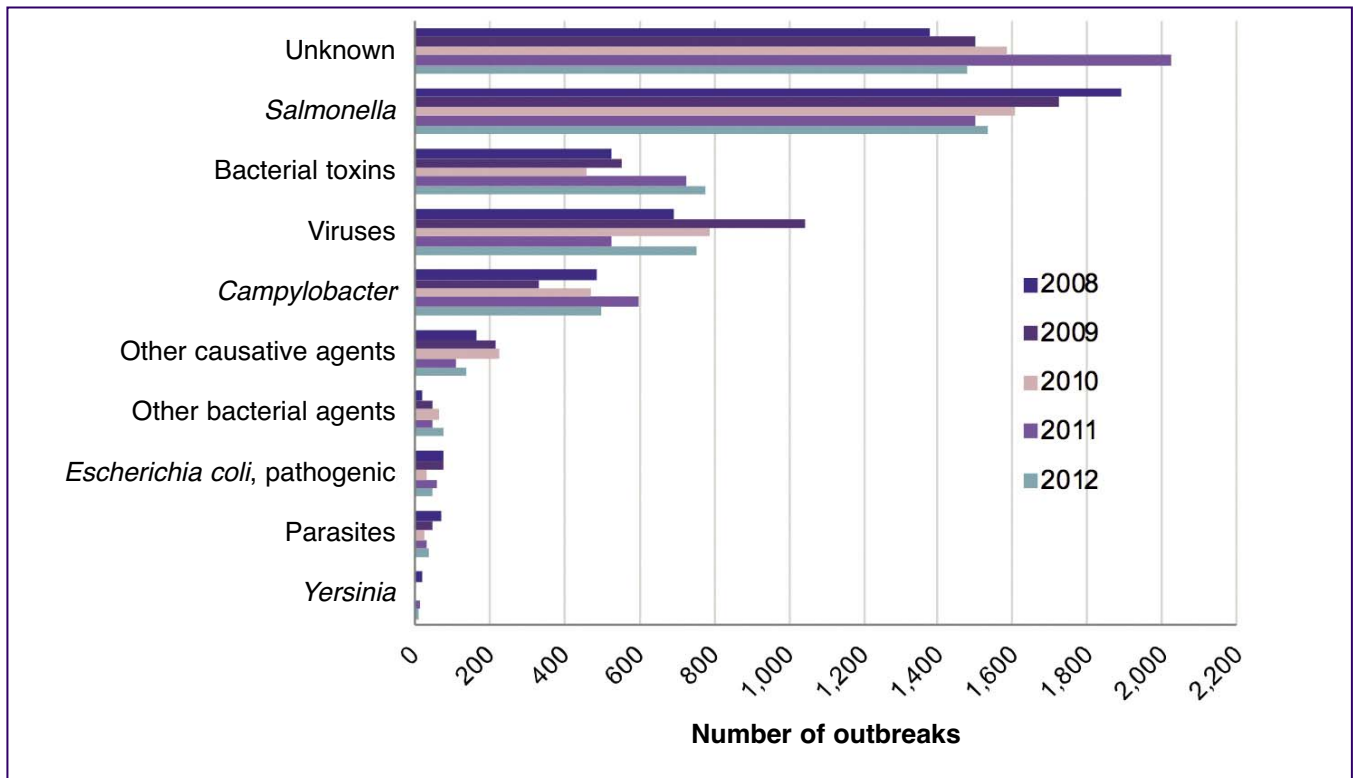


Fig.76.1: Total number of foodborne outbreaks in the EU, 2008-2012 (EFSA & ECDC, 2014). Bacterial toxins include toxins produced by *Bacillus*, *Clostridium* and *Staphylococcus*. Foodborne viruses include calicivirus, hepatitis A virus, flavivirus, rotavirus and other unspecified viruses. Other causative agents include mushroom toxins, marine biotoxins, histamine, mycotoxins, atropine and other unspecified agents. Parasites include primarily *Trichinella*, but also *Cryptosporidium*, *Giardia*, *Anisakis* and other unspecified parasites. Other bacterial agents include *Listeria*, *Brucella*, *Shigella*, *Vibrio* and *Francisella*. Pathogenic *Escherichia coli* includes also verotoxigenic *Escherichia coli*.

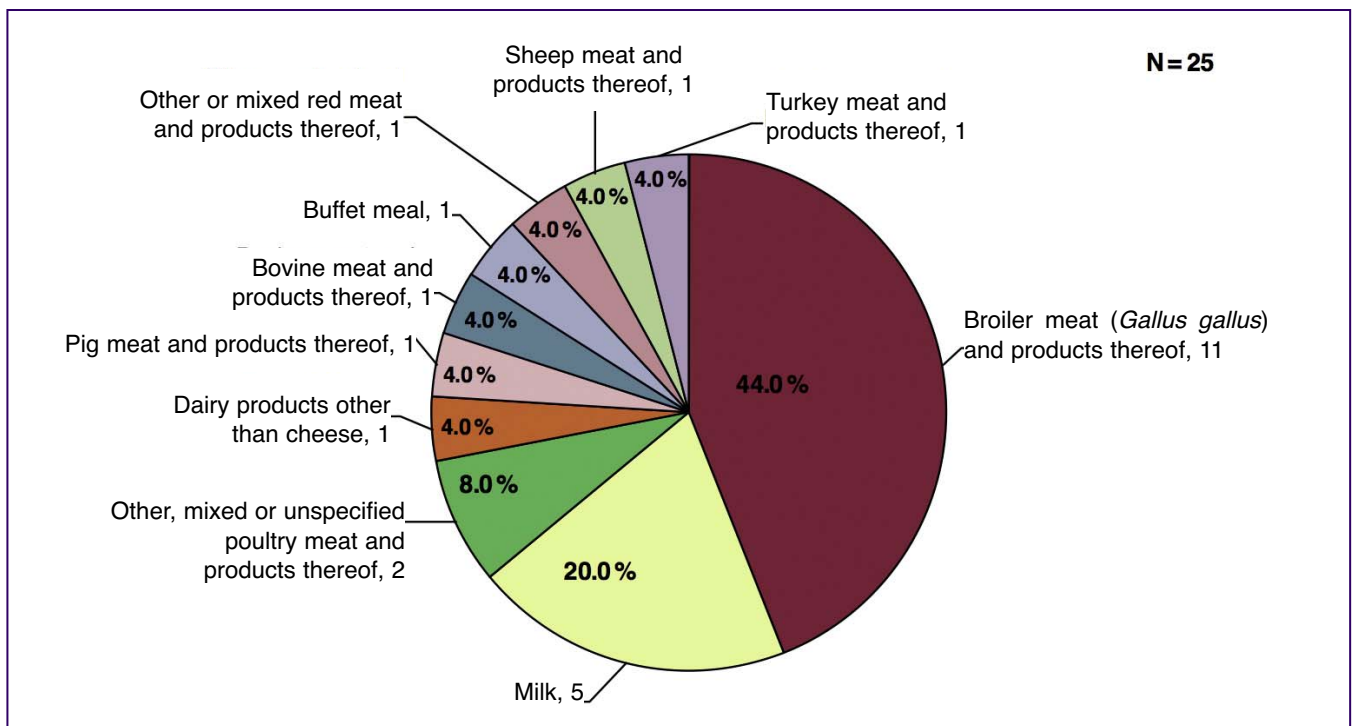


Fig.76.2: Distribution of food vehicles in strong-evidence outbreaks caused by *Campylobacter* in the EU, 2012 (EFSA & ECDC, 2014). Data from 25 outbreaks are included: Belgium (1), Denmark (3), Finland (3), France (5), Germany (5), Netherlands (1) and United Kingdom (7). Number after the label refers to the number of outbreaks.

Health measures

76. TOXI-INFECTIONS

INTRODUCTION

Several types of micro-organisms can be found on the carcasses following the various steps in the processing of birds, from the time they leave the farm to the moment they are shipped from the processing plant. These include micro-organisms that may be responsible for spoilage of the meat, as well as foodborne disease-causing micro-organisms. Regarding this latter category of micro-organisms, poultry are recognized as the principal source of some of the most frequent foodborne-disease causing bacteria. What makes the situation even worse is the fact that most if not all the infected birds act only as carriers of the various micro-organisms and do not show any clinical signs of disease during the grow-out period. Among the numerous recognized agents of foodborne disease, the following genus and species have been found associated with poultry: *Aeromonas*, *Campylobacter*, *Clostridium perfringens*, *Escherichia coli* O157:H7, *Listeria monocytogenes*, *Salmonella*, *Staphylococcus aureus* and *Yersinia enterocolitica*. Among this list *Campylobacter* and *Salmonella* are the bacteria we most frequently associate with poultry. They will be discussed in more details than the other micro-organisms.

AEROMONAS (see Chap.III.61)

Although in this bacterial genus several species are recognized as potential cause of foodborne disease, and that various reports in the literature mention that this micro-organism can be isolated from raw poultry, there is no mention of specific association with foodborne disease outbreak.

CLOSTRIDIUM PERFRINGENS (see Chap.III.51)

According to American statistics, turkey and chicken based meals account for approximately 15% of the reported *C. perfringens* type A foodborne outbreaks. Typically, a *C. perfringens* foodborne outbreak affects a large number of people and the meals involved are prepared in advance and held until serving. If the meat was initially contaminated and there is a temperature abuse following insufficient cooking to kill the temperature resistant spores of *C. perfringens*, these spores will germinate and proliferate in the food. After ingestion the bacteria will release their exotoxin which will induce the clinical signs.

ESCHERICHIA COLI O157:H7 (see Chap.III.45)

The specific serogroup of this bacterial species is recognized as the most frequent cause of hemorrhagic colitis in humans and may lead to haemolytic-uremic syndrome. Cattle are considered to be the principal animal reservoir of this bacteria and ground beef is considered the main food source for transmission of this micro-organism. However, retail meat from other animal species, including poultry, have been found to be contaminated with this micro-organism but confirmed disease outbreaks associated with poultry have not been reported. The possibility of cross-contamination with beef during cutting at retail has been evoked.

LISTERIA MONOCYTOGENES (see Chap.III.61)

This bacteria is widely distributed in the environment and has been implicated in several outbreaks of foodborne disease. Listeriosis has a high mortality rate and is found mainly among pregnant women, foetuses and immunocompromised persons. Dairy products, vegetables, seafood, fish products and meat, including poultry, have been recognized as food that can harbour this bacteria. In some studies, it was found that up to 60% of the poultry samples were positive for the presence of *L. monocytogenes*.

STAPHYLOCOCCUS AUREUS (see Chap.III.57)

Poultry and egg products are recognized as potential vehicles of this frequent foodborne intoxication agent. Although animals can be one of the source of the bacteria, food handlers are most frequently the culprits for introducing the agent in the food. Thus, in studies reporting the isolation of *S. aureus* from various processed food it is possible that the strain involved might be of human origin. The exotoxin secreted by this micro-organism is very heat-resistant and can still produce an effect even if the bacteria that secreted the toxin have been killed.

YERSINIA ENTEROCOLITICA (see Chap.III.59)

Although this foodborne disease causing micro-organism is generally associated with swine, it has also been isolated from chicken. However, pigs are the only animal species from which the isolates most commonly associated with human disease have been isolated with some frequency. This

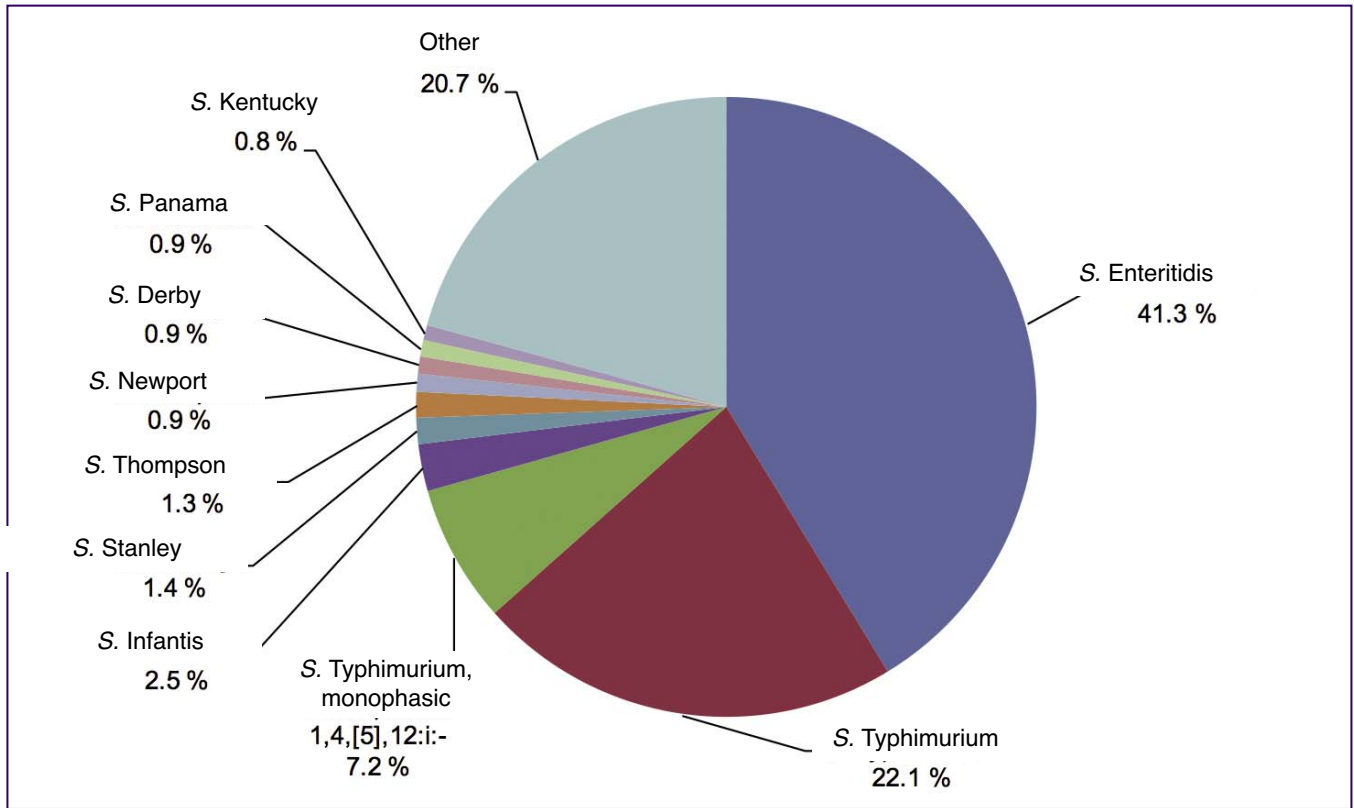


Fig.76.3: Distribution of the 10 most common *Salmonella* serovars in humans in the EU, 2012 (N=82,409) (EFSA & ECDC, 2014).

Section V

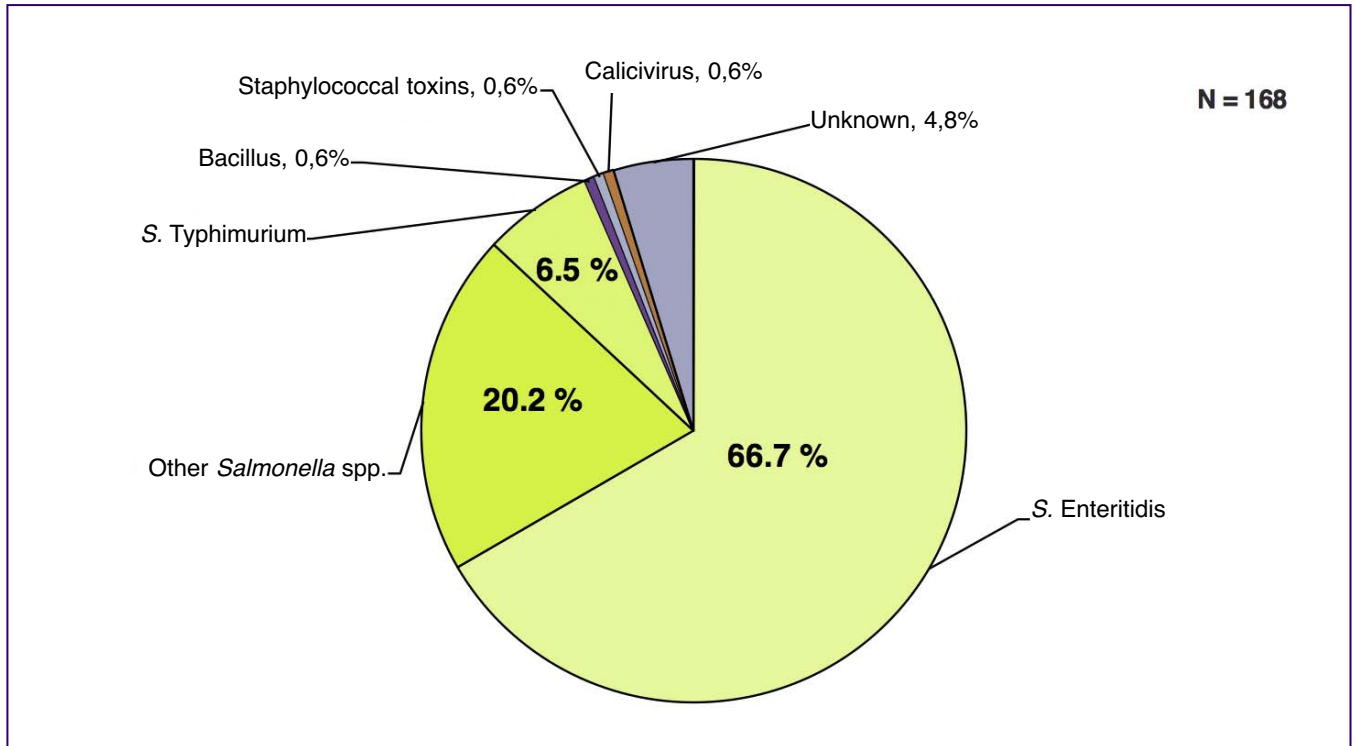


Fig.76.4 : Distribution of strong-evidence outbreaks, implicating eggs and egg products, by causative agent in the EU, 2012 (EFSA & ECDC, 2014).
 Data from 168 outbreaks are included: France (33), Germany (3), Netherlands (1), Poland (51), Slovakia (3), Spain (74) and United Kingdom (3).

micro-organism is considered a psychrotroph, which means that it has the ability to grow at refrigerator temperatures.

CAMPYLOBACTER (see Chap.III.53)

Before the early 1980's, data relating to the genus *Campylobacter* and foodborne diseases are almost nonexistent. In the following years, the thermophilic species of *Campylobacter* have been recognized as important etiologic agents of foodborne diseases surpassing in some countries *Salmonella* as the number one cause of foodborne disease. Since both *Campylobacter* and *Salmonella* can be found in the intestinal tract of birds, the step of poultry evisceration is, as it is with other animal species, a critical step in the process. However, the size and the structure of the abdominal cavity of the birds make this operation much more difficult to execute in a hygienic manner.

Campylobacter jejuni is the species most commonly associated with poultry. It is found in the intestinal tract of asymptomatic carrier birds. Prevalence studies have indicated that the number of carcasses contaminated by this organism can be as high as 90 to 95%. This, combined with the fact that the infectious dose for humans is low (ca. 500-1 000 cells depending on the strain) has certainly had an impact on the number of sporadic cases of human campylobacteriosis. Typically these occur most often in the summer months and will usually follow ingestion of improperly handled or cooked food, primarily poultry products. The outbreak cases of human campylobacteriosis have often been linked to ingestion of raw milk. Sporadic cases of campylobacteriosis are much more frequent than outbreak cases.

Campylobacter jejuni are micro-organisms that are susceptible to adverse environmental conditions and will not survive for long periods of time outside of a host. The bacteria survive but will not grow below 30°C, they are sensitive to drying, low pH and high-oxygen conditions.

SALMONELLA (see Chap.III.43)

In many industrialized countries, poultry production, either meat or eggs, is associated with foodborne disease caused by *Salmonella*. Several changes have been proposed regarding the nomenclature of the genus *Salmonella* but no final decision has been rendered by the taxonomy governing bodies. The most frequently encountered scheme, and the one that will be used in this text, is to have the name of the serovar following the designation of the genus (e.g., *Salmonella* Typhimurium).

Some serovars of *Salmonella* are recognized to be species-specific and will generally cause diseases with systemic clinical signs (e.g., *Salmonella* Typhi in human; *Salmonella* Dublin in cattle; *Salmonella* Choleraesuis in swine; *Salmonella* Pullorum in chicken). The other serovars of *Salmonella*, generally referred to as non typhoid salmonellae or paratyphosis, will cause mainly gastrointestinal diseases.

As was mentioned with *Campylobacter jejuni*, *Salmonella* are frequently found in the intestinal tract of asymptomatic carrier birds. Carcasses become contaminated during the evisceration procedure and cross-contamination of carcasses can occur afterwards. One notable exception is *Salmonella* Enteritidis (phage types 4 and 8, mainly) which has been involved in systemic disease in several patients. One additional concern with this specific serovar of *Salmonella* is the possibility of transovarian transmission which will result in the presence of the bacteria in the egg yolk before it is laid. Raw or undercooked eggs can thus be involved in causing foodborne salmonellosis.

Various factors will affect the number of micro-organisms required to cause foodborne salmonellosis in human. These include the serovar and the specific isolate involved, the immunological status of the recipients and the contaminated food vehicle. In reported outbreaks, infectious doses ranged from less than 10 bacteria to as high as 10¹¹ bacteria.

REFERENCES

- Council for Agricultural Science and Technology. *Task Force Report. Foodborne pathogens: risks and consequences*. CAST, Ames, IA. 1994, 87 p.
- Doyle MP. *Foodborne bacterial pathogens*. Marcel Dekker, Inc. New York, N.Y.1989, 796p.
- Doyle M et al.. *Food microbiology: fundamentals and frontiers*. ASM Press, Washington DC. 1997, 768 p.
- EFSA (European Food Safety Authority) and ECDC (European Centre for Disease Prevention and Control), 2014. *The European Union Summary Report on Trends and Sources of Zoonoses, Zoonotic Agents and Foodborne Outbreaks in 2012*. EFSA Journal 2014;12(2):3547, 312 pp. doi:10.2903/j.efsa.2014.3547
- Hubbert WT, Hagstad HV. *Food safety and quality assurance: foods of animal origin*. Iowa State Univ Press, Ames, IA. 1991, 152 p.
- Miller-Jones J. *Food Safety*. Eagan Press, St.Paul, MN. 1992, 453 p.
- National Academy of Sciences. 1985. *Meat and poultry inspection*. NatAcad Press. Washington, D.C. 209 p.
- Petersen GV et al. *Veterinary aspects of meat quality*. Publication No. 138. Veterinary Continuing Education. N Z Veterinary Association. 1991, 248 p.

Beta-lactam	Properties
<i>Natural penicillin</i> (benzylpenicillin)	Bactericidal (time-dependent killing), strong acids, low lipophilicity, many Gram (+)
<i>Aminopenicillins</i> (ampicillin, amoxicillin)	Bactericidal (concentration-dependent killing), strong acids, Gram (+) and Gram (-)
<i>Cephalosporins</i> (ceftiofur, cefoxitin, dicloxacillin)	Bactericidal (time-dependent killing), strong acids, many Gram (+) and Gram (-)

Tabl.77.1: Cell wall active agents.

	Properties
<i>Polypeptides</i> (colistin)	Bactericidal (concentration-dependent killing), strong or polar bases, very low lipophilicity, Gram (-)
<i>Polyether ionophores (ion carriers)</i> (monensin, lasalocid, maduramicin, narasin, salinomycin, semduramicin)	Anticoccidial, weak acid, high lipophilicity, Gram (+) particularly <i>Clostridium</i> .

Tabl.77.2: Cell membrane (altering permeability or facilitating cations across membrane) agents.

	Properties
<i>Sulfonamides</i> (sulfadimidine, sulfamerazine, sulfadiazine, sulfamethoxazole, sulfadoxine, sulfadimethoxine, sulfachlorpyrazine, sulfaquinoxaline, sulfamethoxy-pyridazine)	Bacteriostatic (time-dependent killing), weak acids, moderate/high lipophilicity, Gram (+) and Gram (-), anticoccidial
<i>Diaminopyrimidine derivatives</i> (trimethoprim)	Bactericidal (time-dependent killing), weak bases, moderate/high lipophilicity, Gram (+) and Gram (-)

Tabl.77.3: Antifolate agents.

	Properties
<i>Aminoglycosides</i> [apramycin, gentamicin, neomycin, streptomycin, dihydrostreptomycin, kanamycin, amidosidine (o paromomycin)]	Bactericidal (concentration-dependent killing), weak bases, low lipophilicity, mainly Gram (-)

Tabl.77.4: Aminoglycosides.

	Properties
<i>Tetracyclines</i> (chlortetracycline, doxycycline, oxytetracycline, tetracycline)	Bacteriostatic (co-dependent killing), amphoteric compounds, high lipophilicity (doxycycline), Gram (+) and Gram (-)
<i>Aminocyclitols</i> (spectinomycin)	Bacteriostatic, weak bases, Gram (+) and Gram (-)
<i>Lincosamides</i> (lincomycin)	Bacteriostatic (time-dependent killing), weak bases, high lipophilicity, Gram (+), <i>Mycoplasma</i>
<i>Macrolides</i> (erythromycin, spiramycin, tylosin, tylvalosin, tilmicosin)	Bacteriostatic (time-dependent killing), weak bases, high lipophilicity (spiramycin) Gram (-), <i>Mycoplasma</i>
<i>Pleuromutilins</i> (tiamulin)	Bacteriostatic (time-dependent killing), weak bases, high lipophilicity, Gram (+), <i>Mycoplasma</i>
<i>Orthosomycins</i> (avylamicin)	Bacteriostatic, Gram (+), low/moderate lipophilicity

Tabl.77.5: Antiribosomal agents.

Quinolones	Properties
Danofloxacin, difloxacin, enrofloxacin, flumequine, sarafloxacin, oxolinic acid	Bactericidal (concentration-dependent killing, high lipophilicity, Gram (+) and Gram (-)

Tabl.77.6: Topoisomerase inhibitors.

Health measures

77. PHARMACOLOGICAL CONSIDERATIONS

INTRODUCTION

There are marked anatomical and physiological differences among bird species and mammals. Therefore, variations can be expected in both the rate and the extent of absorption, distribution and elimination (metabolism and excretion) of drugs. Whilst the treatment of bacterial diseases of poultry relies on similar general principles as for mammalian medication, there are significant anatomical and physiological differences which impact on therapeutic approaches. For this reason, the administration of drugs is not a simple extrapolation of dosage regimens established for mammalian species.

COMPARATIVE ANATOMY AND PHYSIOLOGY WITH RESPECT TO DRUG ADMINISTRATION

The gastrointestinal system is the principal distinguishing feature between birds (granivorous and carnivorous species). Each avian species (i.e., domestic poultry, game and exotic birds) has certain distinguishing features, some of which contribute to variations in the way it metabolizes drugs. For each part of the digestive system, variations may be observed between species depending on the type of diet and feeding practice. What follows are comments specific to some anatomical and physiological features as they relate to drug administration and processing in poultry.

Esophagus & crop

The esophagus connects the pharynx to the proventriculus. Unlike mammals, the avian oesophagus is divided into a cervical and a thoracic part. In many, but not all bird species, the cervical oesophagus expands into a crop. The crop serves as a storage organ that also plays a role in the softening of feed. Because the crop has a keratinised epithelium, the absorption of drugs is normally minimal or absent in this section of the digestive tract. But the availability and absorption of drugs administered orally may be influenced by the flora and pH of the crop. The pH of the crop is about 6. Therefore some drugs added to drinking water may precipitate in the crop, resulting in delayed transit and poor absorption, as is the case with tetracycline. Furthermore, the presence of a *lactobacillus* flora in the crop can inactivate macrolide

antibiotics. Depending on the consistency of the feed, emptying of the crop in chickens varies from 3 to 24 h. This will have a serious impact on the absorption pattern of drugs administered orally.

Stomach (proventriculus & gizzard)

The stomach is subdivided into three portions. The most rostral portion is the proventriculus (true stomach) or glandular stomach. This is followed by the second portion, termed the intermediate zone, and the third portion, the gizzard (muscular stomach) or ventriculus. The cells of the gastric glands secrete pepsinogens (proteolytic proenzymes) and hydrochloric acid. Some weak base drugs may be inactivated (e.g., penicillin G and erythromycin) due to the strong acid component of gastric content. Most drugs ingested as a solution pass rapidly by the crop and stomach to arrive within a few minutes in the intestine. The alkaline pancreatic juice neutralises the acidic content coming from the gizzard and the absorption occurs at the intestinal level.

Intestine (small intestine, ceca, large intestine & cloaca)

As in mammals, absorption in birds mainly takes place in the duodenum and upper jejunum. The rapid transit in the small intestine and the limited development of the distal part of the digestive tract (related to the adaptation to fly) explain the short alimentary tract passage time of about 5–6 h in broiler chickens for those drugs that are not entrapped in the crop with feed. The presence of a bacterial microflora can vary considerably according to the bird species. In ostriches, the microflora is varied and important and colonizes the whole gastro-intestinal track; in chickens, the microflora is more abundant in the colon; in pigeons, the microflora is minimal. As it may occur in the crop, in most birds, indigenous intestinal microflora may inactivate certain drugs by metabolic transformation of a hydrolytic or reductive nature. Apart from intestinal biotransformation, the presence or absence of intestinal efflux pump systems (active transport system for the removal of some antibiotics, such as tetracyclines, macrolides, and quinolones from bacterial cells) will also have an important impact on the bioavailability of orally administered drugs.

Hepatic system

The metabolism of a drug can differ among species (sometimes even among strains of a species), since the relationship between metabolism and excretion is determined by basic metabolism and heredity. Metabolism is reported to have a greater role in avian species (higher metabolic rate and higher body temperature) compared with mammals. The metabolism of drugs mostly exhibits similar pathways in different animal species, but the rate of biotransformation reactions vary substantially due to large variations in catalytic properties. Phase I (oxidation, reduction, and hydrolysis) and phase II (conjugation) reactions have been reported in birds, but for certain drugs the pathways can totally differ in avian species. Few forms of avian cytochrome P₄₅₀ enzymes have been fully characterized. For phase II reactions, in anseriformes (duck, goose) and galliformes (chicken, turkey), the ornithine reaction (production of urea from ammonia) is more important than the glucuronidation pathway (pathway in phase II metabolism leading to drug conjugation). In contrast, ornithine conjugation appears to be absent in pigeons while the glycine conjugation is predominant.

Renal system

The avian cortex contains two types of nephrons, a reptilian-type with no Henle's loop, and a nephron resembling that of mammalian kidneys, containing a well-defined Henle's loop. In general, birds have a lower glomerular filtration rate than mammals of a similar body weight and, if it is constant in mammals, it is intermittent in birds. The ability of avian tubule cells to secrete drugs is not known; however, most waste products (85-95% of uric acid) are eliminated by secretion. Drug reabsorption from the tubular filtrate generally occurs by diffusion, and the amount and rate of drug reabsorption is proportional to the concentration of drug in the filtrate and it also depends on the degree of drug ionization. The avian kidney has a limited ability to concentrate urine, with an average urine-to-plasma osmolar ratio of about two. The urine pH varies from 4.7 to 8.0 (depending on the stage of laying) in female birds and is approximately 6.4 in male birds. The kidneys contain a renal portal system draining the lower regions of the body. The portal vessels supply the peritubular capillary network, so that drugs like penicillins, which are actively secreted, if injected in a hind limb may go to the tubules before going to the systemic circulation.

Respiratory system

Avian lung are small, based on body weight percentage, compared to mammalian lungs. Unlike the mammalian lungs, the avian lungs are relatively rigid and do not change in volume during the respiratory cycle. The systemic availability of drugs administered by nebulization is low.

Anatomical differences in lung structure and the lack of physical activity of a sick bird during treatment will, even under optimal conditions, mean that drugs will reach only 20% of lung tissues and will not reach most of the air sacs. To achieve drug levels in the lungs and air sacs, the particles should be between 1 and 3 μm . In chickens, aerosolized particles between 3 and 7 μm are generally deposited on the mucosa surface of the nasal cavity and trachea. The therapeutic levels of drugs in the respiratory tract can also technically be obtained by intratracheal application; but this is not considered practical in poultry.

ANTIMICROBIAL PHARMACOLOGICAL CHARACTERISTICS

For antimicrobials, information on pharmacological characteristics, including mode of action and kinetic profile, is useful to allow veterinarians to select the best veterinary drug for a given pathogen.

Pharmacodynamic properties

The term antibiotic pharmacodynamics includes the relation between drug concentrations at the site of infection and the antibacterial effect. Knowledge of the pharmacodynamic properties of a particular drug allows clinicians to determine the most appropriate dosing regimen. In general, antibiotics can be divided according to the general properties of the antimicrobials, such as their mode of action (i.e., bactericidal or bacteriostatic), and their concentration and/or time co-dependent effects (i.e., types of killing action). For example, aminoglycosides, fluoroquinolones and polymyxins are concentration-dependent, and most β -lactam agents, macrolides, lincosamides, phenicols, sulfonamides and diaminopyrimidines are concentration-independent and time-dependent). Co-dependent antimicrobials are dependent on both the duration of exposure and the maintenance of drug concentration. However, the distinction between concentration and time-dependent mechanisms of action is not absolute. A distinction

is made between the minimum concentration of an antibiotic needed to inhibit growth (the minimum inhibitory concentration or MIC), and the minimum concentration needed to kill an organism (the minimum bactericidal concentration or MBC). The most widely used indicator of efficacy and potency is MIC. When MIC has been determined against a sufficient number of strains of sensitive microbial species, the median or geometric mean MIC₅₀ and MIC₉₀ values are determined. It is then possible to set a provisional dose through pharmacokinetics /pharmacodynamics integration data, using one or more of the indices: maximum observed concentration (C_{max}):MIC₉₀ ratio (for some concentration-dependent drug classes); area under the concentration-time curve (AUC:MIC₉₀) ratio (for most concentration and co-dependent drugs e.g., fluoroquinolones, macrolides and tetracyclines); and percent time above MIC₉₀ during the dosing interval (T>MIC₉₀). The latter is the proportion of the inter-dose interval for which plasma/serum concentration exceeds MIC₉₀ and is expressed as a percentage of the inter-dose interval. There are scientific data proposing numerical values for these indices (e.g., C_{max}:MIC₉₀ ≥ 10:1 for aminoglycosides; AUC:MIC₉₀ ratio ≥ 125h for fluoroquinolones; T>MIC₉₀ ≥ 50% for beta-lactams). In fact, these values constitute a guide to clinically effective dosage.

Pharmacokinetic features

Pharmacokinetics describes quantitatively the changes in drug concentration in the body over time as a function of administered dose. Generally, it is based on subjecting serum/plasma concentration-time data to mathematical models, which provide further data on absorption, distribution, metabolism and excretion of the drug and its metabolites. However, it is necessary to consider the plasma and tissue pharmacokinetics of drugs in relation to residues in poultry products. The pharmacokinetics is also influenced by the drug lipophilicity. Relevant pharmacokinetic parameters are the volume of distribution (V_d), which relates the drug concentration at a particular time to the drug amount in the body at that time; the maximum observed concentration (C_{max}); the time of C_{max} (T_{max}); the elimination half-life, clearance and area under the concentration curve (AUC). The degree of protein binding of the substance in the plasma and concentrations of the antimicrobial at the site of infection can be of importance. Consistent with the diverse anatomic and physiologic characteristics, pharmacokinetic parameters can differ between different species of birds. From a residue perspective, important pharmacokinetic

variables are C_{max}, T_{max}, AUC, absorption half-life, terminal half-life and bioavailability. In relation to tissue residues, the parameters, clearance, volume of distribution and half-life also have particular importance. For a given dose, if total clearance is high, AUC will be low and this has an impact on residues insofar as AUC in plasma will relate to tissue concentrations (albeit in a complex manner). Clearance is the pharmacokinetic parameter determining dose amount. The terminal half-life on the other hand, determines the interval between doses.

MOST COMMONLY DRUG USED IN AVIAN MEDICINE

Antibiotics

According to the mode of action, the most important antibiotic classes used in poultry are listed in Tabl.77.1 to 77.6.

Anticoccidials or coccidiostats

There are two classes of treatments against coccidiosis:

- (1) Coccidiostats, which arrest or inhibit growth of intracellular coccidia and give rise to latent infection after drug withdrawal;
- (2) Coccidiocides, which kill most of the coccidial stages.

Some anticoccidial drugs may be initially coccidiostatic but eventually become coccidiocidal. Most anticoccidials currently used in poultry production are coccidiocides.

The anticoccidials can be grouped into two major types (see Tabl.77.7). In the first group are polyether ionophore antibiotics which are produced by fermentation with several strains of *Streptomyces* spp. and *Actinomadura* spp.). The second group includes other synthetic compounds (non-ionophoric). No products are currently authorised as histomonostats and used as feed additives in the European Union (EU). In the USA, nitarsone (an organoarsenic compound) is the only feed additive allowed to prevent histomoniasis. However, it is not effective in treating the disease.

A number of strategies have been developed to prolong the useful life of coccidiostats, while still controlling coccidiosis. The programs used for coccidiostats are as follows: (a) continuous, (b) shuttle and (c) rotation. In some cases, birds are given one coccidiostat continuously through succeeding flocks, but two or more coccidiostats (e.g., «shuttle programs») may be given during the life

Ionophoric (polyether ionophores)	Acts on life cycle stage
<i>Monensin</i> (Na ⁺ selective), lasalocid (complex with Ca ⁺⁺), maduramicin, narasin (K ⁺ selectivity), salinomycin (K ⁺ selectivity) and semduramicin	Asexual and sexual stages of the coccidian. Trophozoite/sporozoite
Non-ionophoric	
<i>4-hydroxy-quinolone</i> (decoquinate)	Sporozoites and early schizonts
<i>Guanidine</i> (robenidine)	Multiple stages (first and second generation of schizonts)
<i>Quinazolinone</i> (halofuginone)	Asexual stages (first generation of schizonts)
<i>Benzeneacetonitriles</i> (diclazuril, clazuril, toltrazuril)	Multiple stages (zygotes, gametocytes, schizonts)
<i>Carbanilide</i> (nicarbazin)	Multiple stages (first and second generation of schizonts)
<i>Thiamines</i> (amprolium)	Multiple stages (first generation of schizonts and sexual stages and sporulation of oocysts)
<i>Pyridinol</i> (clopidol)	Sporozoites and early schizonts

Tabl.77.7: Anticoccidial agents.

of a flock, being convenient to provide a particular coccidiostat for a period during which one type of feed is given. Shuttle and rotational programs are used to impede the development of drug resistance. A «shuttle program» involves a change of coccidiostat during a single grow-out period (i.e., one class might be used in starter feed, another in growout, returning to the first for the finished diet followed by a withdrawal diet). A 'rotational program' has as objective to rotate the drugs between grow-out periods (e.g., changing the drug(s) used every four months, after one or two flocks, go to a winter and summer program, *etc.*). These programs take advantage of the different coccidiostat properties with differing mode of action (e.g. between ionophores that share a similar mode of action and non-ionophores), matching spectrum of activity, potency, and drug cost against risk of infection, while slowing the rate of development of resistance. Presently in the EU, there are several antimicrobial coccidiostats for chickens and turkeys that may be as feed additive used under certain conditions; for example ionophores commonly incorporated into feed for chickens: monensin (100-125 mg/kg), lasalocid (75-125 mg/kg), salinomycin (50-70 mg/kg), narasin (60-70 mg/kg), maduramicin (5 mg/kg), and semduramicin (25 mg/kg); for chickens reared for laying (up to 16 weeks of age): monensin (100-120 mg/kg), lasalocid (75-125 mg/kg), up to 12 weeks of age: salinomycin (70 mg/kg); and for meat turkeys: monensin (90-100 mg/kg feed) (up to 16 weeks of age), lasalocid (75-125 mg/kg) (up to 12 weeks of age), maduramicin (5 mg/kg) (up to 16 weeks of age).

Other drugs that may be used in poultry medicine

Antifungals: amphotericin-B, ketoconazole, nystatin, itraconazole, fluconazole.

Endoparasitic: ivermectin, levamisole, flubendazole, toltrazuril, clazuril, piperazine, parconazole, amprolium.

Ectoparasitic: ivermectin, piperonyl butoxide.

Antiinflammatory: salicylic acid, acetylsalicylic acid.

Antivirals: acyclovir.

Further details regarding these drugs can be found in other chapters. Keep in mind that regulations vary over time and across countries.

REFERENCES

- American Association of Avian Pathologists (AAAP) Guidelines to Judicious Therapeutic Use of Antimicrobials in Poultry. <https://www.avma.org/KB/Policies/Pages/AAAP-Guidelines-to-Judicious-Therapeutic-Use-of-Antimicrobials-in-Poultry.aspx>.
- Anadón A et al. Considérations physiologiques et pharmacologiques et thérapeutique aviaire. *Revue Méd Vét*, 1993, 144(10) :745-757
- Anadón A & Martínez-Larrañaga MR. Residues of antimicrobial drugs and feed additives in animal products: regulatory aspects. *Livestock Prod Sci*, 1999, 59, p 183-198
- Anadón A & Martínez-Larrañaga MR. Veterinary Drug Residues. Coccidiostats. In *Encyclopedia of Food Safety*, Ed.Y Motarjemi et al, Elsevier, Oxford (UK), 2013, Volume 3, pp.63-75.
- Anadón A et al. Pharmacokinetics and residues of ciprofloxacin and its metabolites in broiler chickens. *Res Vet Sci*, 2001, 71 :101-109
- Anadón A. et al. Antimicrobials (including coccidiostats) in poultry. *J Vet Pharmacol Ther*, 2009, 32 (Suppl 1): 26-28.
- Anadón A et al. Plasma and tissue depletion of florfenicol and florfenicol-amine in chickens. *J Agric Food Chem*, 2008, 56, 11049-11056.
- Brugère H. Pharmacologie chez les oiseaux. In *"Manuel de Pathologie Aviaire"*. Ed. J Brugère-Picoux & A. Silim. Ed. Chaire de pathologie du bétail et des animaux de basse-cour. Ecole Nationale Vétérinaire d'Alfort, France 1992, p.355-363.
- Puyt JD Antibiothérapie en élevage de volaille. *Bull Groupements Techniques Vétérinaires*, 1995, 5:17-41.

INTRODUCTION

Infectious disease control is best achieved when environmental and management conditions limit stress and exposure to disease organisms; when immunization procedures effectively increase bird resistance to infectious pathogens; and when an appropriate specific medication is used following diagnostic work. Indeed, antimicrobial treatments must be based on at least a presumptive diagnosis. This is particularly important when considering antibiotic medication, given the growing concern over the possible development of antibiotic resistance.

WHEN TO MEDICATE

The decision to medicate is based on several factors: severity of the disease (the proportion of birds showing clinical signs; impact on bird performance: feed conversion, weight gain and uniformity, condemnations; and mortality rate), medication cost, production costs, the value of the birds (breeders vs meat birds), flock age (how close to slaughter), and, finally, the obligation of respecting drug withdrawal times.

ANTIBIOTIC SELECTION

Guidelines and codes of practices sharing common principles on prudent and rational therapeutic use of antibiotics in poultry have been developed over the past 20 years. A good example is the American Association of Avian Pathologists (AAAP) guidelines categorizing antimicrobials in three classes according to their importance in human medicine:

Class I: Important in human medicine; to be held in reserve for treatment in poultry.

Class II: Human medicine use where alternatives exist; exposure in poultry is moderate (erythromycin, penicillin, gentamicin, sulfonamides, ceftiofur, tetracycline class).

Class III: No or minimal use in human medicine; or low exposure in poultry (bacitracin, streptomycin, tylosin, lincomycin, spectinomycin, neomycin).

Whenever possible, veterinarians must first consider antimicrobials with no or minimal use in human medicine (Class III). Based on farm and regional history, susceptibility tests and clinical considerations, the use of Class II antibiotics may be justified. In this case, it should be done according to labelled instructions before considering any extra label use. In rare occasions when Class II and III antibiotics have been considered and all

intervention strategies have been unsuccessful, the labelled use of a Class I antibiotic may be considered.

The reader is referred to the previous chapter on pharmacology (Chap.V.77) for more specific information on antibiotic categories and their characteristics.

MEDICATION ROUTES

As in mammals, medications may be given to poultry by a variety of routes, but if individual birds may be treated (i.e., individual injection or by oral gavage), it is more effective to treat entire groups by mass application to the whole flock by drinking water (main way of administration) or feed.

DRINKING WATER MEDICATION

This method is convenient when flocks have to be treated. The main advantages of medicating through drinking water are precise medication of flocks; convenience of administration; and sick birds that may drastically reduce feed intake will usually still drink. However, water consumption can vary considerably depending of various factors. This must be considered when medicating in order to avoid under or over dosing. If the medication changes the appearance of water, or changes the taste, it may lead to reduce water consumption. Although birds have a limited sense of taste, palatability problems may arise because a drug “flavor” will be more noticeable in water than in feed. Bitter- and salt-tasting substances tend to be rejected. Sweet substances such as sugars (but not saccharin) produce variable responses in individual birds.

Water consumption in healthy birds varies considerably depending on several factors. Age (younger birds consume more water daily per unit of body weight than older birds), production status (laying hens drink more water per unit of body weight than nonlaying hens or roosters), appetite, boredom, high ambient temperature, feed quality (e.g., a diet rich in minerals or proteins), lighting period (longer periods) will increase water intake. Regarding the ambient temperature, the rule of thumb for those using Fahrenheit is: for every 1°F increase in ambient temperature above 70°F corresponds an increase in water consumption of about 4%. In Celsius, it is estimated that an increase in water consumption of up to 6% can be noted for each degree above 20°C.

Health measures

78. ANTIMICROBIAL TREATMENTS

A reduction in water consumption is noted when drinking water temperature is elevated, when ambient temperature is cold, when water has a high mineral content, and, of course, when disease occurs. In diseased birds water consumption will vary even more. As stated above, sick birds eat and drink less than usual, although the decline in water consumption is normally less than the decline in feed intake.

It is important to consider water consumption when medicating, for example when using a sulphonamide, because the therapeutic dose is relatively close to the level that may result in toxicity. The optimum pH of drinking water should be between 5 and 7. Note that pH may influence drug solubility and stability. As a result, drugs given by this method must have a wide margin of safety.

When treating, a fresh solution must be prepared every day. If using an automatic water proportioner (in-line medicator injecting a set amount of a stock solution in the water line), make sure it is working properly and clean it well before use. For bulk tank medication, one adds the volume of medication for that day into the total volume of water to be consumed. It is important to thoroughly mix the medication with water and to ensure that it goes into and remains in solution.

FEED MEDICATION

For therapeutic purposes, incorporation of antimicrobials into feed is less effective because inappetence is common in sick animals. Environmental factors such as high ambient temperatures may also reduce feed intake. It is routine to include anticoccidials in the feed. Most feed medications are subject to withdrawals similar to water medication. As with water, accuracy of mixing and dosing are important. Where there is delay in starting feed medication (time to manufacture and transport the medicated feed; non medicated feed currently in the feed tank), it may be necessary to precede it with water medication, when an urgent response to therapy is required.

When a disease lasts longer than 5-7 days (e.g., *Pasteurella multocida* in breeders), it may be advisable to switch from water medication to feed medication. Indeed, feed-grade antimicrobials are

less expensive than the same drug in a water-soluble formulation.

PARENTERAL INJECTION

Injection provides the most accurate and successful means of drug administration because each bird receives a precise dose. However, it is cost prohibitive in most countries except when the flock is still in the hatchery (*in ovo* or one day of age). Injection with follow-up therapy in feed or water could be considered for treating breeders in parts of the world where costs in personnel make it financially doable.

ADEQUATE THERAPEUTIC LEVEL

To ensure that therapeutic levels are obtained at the site of infection, dosage should usually result in plasma drug concentrations that are several folds higher than the calculated dose-dependent or time-dependent minimum inhibitory concentration (MIC). For dose-dependent drugs, plasma or tissue drug concentrations should exceed the MIC by 10 to 12 fold (e.g., aminoglycosides); for time-dependent drugs, plasma drug concentrations should be above the MIC₉₀ of the infecting bacteria for > 50-75% of the dosing interval (e.g., β -lactams and most bacteriostatic drugs); hence, for these drugs, therapeutic efficacy is enhanced by shortening the dosing interval. Once treatment is finished, whether in feed or water, it is important to clean the tank or bin in order to avoid sub-therapeutic treatment of the current or next flock.

CALCULATING THE DOSAGE OF A MEDICATION

Dosing based on body weight (mg/kg of average body weight (established by weighing 20 to 30 birds) is preferable to dosing based on water consumption. It is best to use a specific example to show how a dosage is calculated for water medication:

Flock of 10,000 six-week-old turkeys (flock size)
Antibiotic used: oxytetracycline (200-gm packets, each containing 80 gm of oxytetracycline)

Estimated water consumption per day: 3,000 liters (note that consumption varies depending on many factors, as stated above).

Average body weight of turkeys (BW): 2.6 kg
Recommended dosage (RD): 55 mg per kg of body weight.

Calculation of daily dosage:

$$\frac{BW \text{ (Kg)} \times \text{Flock size} \times \text{RD (mg per Kg body weight)}}{1,000 \times \text{amount oxytetracycline (gm) per packet}}$$

$$\frac{2.6 \text{ Kg} \times 10,000 \text{ birds} \times 55 \text{ mg}}{1,000 \times 80 \text{ gm}} = 17.875 \text{ (or about 18 packets)}$$

18 packets x 200 gm/packet = 3600 gm in 3000 liters of water = 1.2 gm (3,600/3,000) per liter of drinking water or 4.56 gm (1.2 gm x 3.8 L) per US gallon.

If using an American proportioner that delivers one-gallon stock solution per 128 gallons of drinking water, then the stock solution would be prepared at concentration of 583.68 gm (4.56 X 128), or about 3 packets (583.6/200), per gallon of stock solution. In other countries, the in-line medicator may deliver 1% or 2% of stock solution (i.e., 1 or 2 L per 100 L of drinking water). Using 1% as example, one liter of stock solution would need to contain 120 gm (1.2 gm/liter of drinking water x 100 liters).

When bird consumption is limited (e.g., broiler breeder pullets): pulse dosing (short intensive treatment in which all daily medication is consumed within a 4-6 hr period) may be applied. However, only bactericidal antibiotics with a wide margin of safety for toxicity should be used.

TREATMENTS OF BACTERIAL DISEASES

The diseases listed below represent the most common bacteria infections in poultry where therapeutic antimicrobial intervention may be warranted based on *in vitro* sensitivity, flock history and clinical judgment by the veterinarian.

Colibacillosis

Colibacillosis is the most common bacterial infection in chickens or turkeys, and can be involved in a number of syndromes affecting birds at any time during production. Colistin or neomycin, apramycin, spectinomycin, may be effective against avian *Escherichia coli*. These products can be efficiently used in treating certain less severe coliform infections, if given for at least seven days, especially when potentiated sulfonamides or tetracyclines are contraindicated. Wherever feasible, treatment should be on the basis of a susceptibility test. First choice antimicrobials are potentiated sulfonamides. Tetracyclines, ampicillin, and amoxicillin could also be used. After termination of treatment,

relapses can occur depending on the nature of secondary bacterial infections. In some countries using a fluoroquinolone may be an excellent option when resistance is demonstrated to first and second choice antimicrobials. However, using quinolones in poultry is no longer legal in countries such as Canada and the United States of America; they are still available in the European Union, although with some restrictions. Readers are therefore urged to check current regulations before considering this type of antibiotic in their country. The AAAP suggests using antimicrobials of class III (streptomycin, neomycin) and class II (chlortetracycline, oxytetracycline, tetracycline, and sulfonamides) in chickens and turkeys.

Fowl cholera (pasteurellosis)

First choice antimicrobials are potentiated sulfonamides and aminopenicillins. The AAAP suggests considering only antimicrobials of class II in chickens and turkeys (tetracycline, sulfaquinolone, sulfadimethoxine, erythromycin).

Necrotic enteritis (clostridial infections)

Clostridium (*C. perfringens* and *C. colinum*) are opportunistic and spore-forming bacteria. The antimicrobials of choice are similar as for dysbacteriosis (see below). However, streptomycin or dihydrostreptomycin by oral application can be used as possible alternatives. The AAAP suggests class III (bacitracin, penicillin, lincomycin) and class II (erythromycin) antimicrobials. Several polyether ionophores suppress growth of *C. perfringens*.

Unspecific enteritis (Dysbacteriosis)

Gram-positive bacteria, particularly Clostridia, are thought to be involved in this infection. Antimicrobials of choice are those effective against *Clostridium* spp. Benzylpenicillin should be considered. Macrolides (tylosin) or aminopenicillins (ampicillin or amoxicillin) may represent valid alternatives. Additionally, polyether ionophores can be used for this unspecific diarrhea. Avilamycin is primarily active against gram-positive bacteria and is used in chickens and turkeys to control bacterial enteric infections at a dose 100 mg/kg feed for 21 days.

Staphylococcus spp. & *Streptococcus* spp. infections

Staphylococcus spp. infections in chickens (i.e., replacement pullets) and turkeys causes primarily arthritis, which can also be associated with osteomyelitis and swollen head associated cellulitis, the latter in chickens. Benzylpenicillin can be a good first empiric choice, in particular for streptococcal

infections. Other possible options are tetracyclines, aminopenicillins and macrolides (erythromycin, spiramycin). The AAAP suggests for *Staphylococcus* infections in chickens and turkeys to use antimicrobials of class III (penicillin, lincomycin) and class II (erythromycin).

Erysipelas (*Erysipelothrix rhusiopathiae*)

This disease is not common today in confinement poultry (layers, turkeys and broilers), although infections occasionally occur. Penicillin is the antimicrobial of choice for controlling erysipelas.

Mycoplasmosis

In turkeys and chickens, *Mycoplasma gallisepticum* (MG) is normally controlled by using tylosin, tetracyclines or erythromycin.

Similar strategies should be considered for *Mycoplasma synoviae* as for MG infections. Tiamulin may be considered for *Mycoplasma* infection. However, tiamulin has neurotoxic effects when combined with ionophores and sulfonamides due to interference with drug degradation by the kidneys. Tetracyclines or macrolides (tylosin or tilmicosin) may also be considered. Tiamulin and macrolides are only active against *Mycoplasma* spp. Tetracyclines, lincomycin-spectinomycin may be active against secondary bacterial infections. Enrofloxacin have good efficacy against infection by *Mycoplasma* spp. and major complicating secondary agents. But this Class I antibiotic is banned for use in poultry in a growing number of countries.

Infectious coryza (*Avibacterium paragallinarum*)

Sulfonamides, potentiated sulfonamides and streptomycin should be considered.

Bordetella avium infection

Bordetella avium infection is difficult to treat via drinking water as blood concentrations of the antimicrobial do not readily get to the site of infection. Tetracyclines should be regarded as first option.

Salmonellosis

Paratyphoid diseases are usually a result of fecal contamination in eggs and subsequent exposure to poults, and occasionally chicks. Lincomycin, lincomycin/spectinomycin, neomycin and tetracyclines may be considered. Antimicrobial treatments of *Salmonella* infected flocks as a mean of control are not allowed in Europe.

THE JUDICIOUS USE OF ANTIBIOTICS TO LIMIT THE DEVELOPMENT OF ANTIBIOTIC RESISTANCE

In recent years, increasing antimicrobial resistance of bacteria, both in humans and animals, has led to the need to use antibiotics only when absolutely necessary. The most important zoonotic pathogens for the development of antimicrobial resistance are *Salmonella* spp. and *Campylobacter jejuni*. Acquired resistance is likely to be mainly plasmid-mediated, although several other methods of resistance transfer, including mutation, have been demonstrated. It is important to keep in mind that antibiotics may increase antibiotic resistance not only in targeted pathogens, but also in the normal bacterial flora.

In veterinary medicine, a number of antibiotics considered «critical» in human medicine should be banned or used only under very limited circumstances. These antibiotics are firstly 3rd and 4th generation cephalosporins, for example, ceftiofur which is a 4th generation cephalosporin (4GCs) and fluoroquinolones.

Various methods are proposed to reduce the consumption of antibiotics, in particular the replacement of their use for prevention by other practices (e.g., vaccinations), reducing the use of medicated feed, and the prohibition of using «critical» antibiotics as a first-line prescription.

What follows are the key requirements for successful antibiotic therapy, as proposed in the document “Judicious Use of Antimicrobials for Poultry Veterinarians” published by the *Food and Drug Administration Center for Veterinary Medicine*:

1) Emphasis must be on preventive strategies, such as good management (e.g., adequate bird density, ambient temperature, proper feeding and watering) and sanitation (e.g., disinfection procedures), on-farm and regional biosecurity measures, health monitoring, and immunizations.

2) Other therapeutic alternatives should be considered prior to using antibiotics. For example, adjusting ambient temperature, adding vitamins and electrolytes to drinking water, etc.

3) Having a valid veterinarian-client-patient relationship. This implies that a veterinarian is involved in assessing the health and need for treatment decisions for a given flock, and that the flock owner partners with the veterinarian to implement an agreed upon treatment. To achieve this, it is expected that the veterinarian has adequate knowledge about the flock and its health status, and is in a position to follow-up the case in order to adjust therapy as needed. The diagnosis may be based on the veterinarian’s experience about the farm and the region, including information obtained from any surveillance activities (e.g., ongoing susceptibility testing

of pathogens).

4) The prescribed therapy must meet all the requirements of a valid veterinarian-client-patient relationship.

5) The first option for antimicrobial therapy must be an antibiotic approved for the given species and disease condition. When this is not available, or the approved antibiotic is ineffective, selecting an alternative antibiotic should be based, if at all possible, on studies demonstrating the efficacy of the product under the circumstances under consideration.

6) Veterinarians should work with flock owners and managers to ensure that antibiotics, whether prescribed or over-the-counter, are used judiciously.

7) Antibiotic therapy should be optimized based on current pharmacological knowledge (e.g., pharmacokinetic parameters such as bioavailability, tissue distribution, half-life). Prolonged oral therapy should be avoided because of concerns over the possible development of antibiotic resistance by bacteria inhabiting the gut.

8) Antibiotics considered important in treating refractory infections in humans or animals should be used as a last resort after careful review of all other options and if legally available.

9) Use narrow spectrum antimicrobials whenever possible. Examination of a direct smear stained with Wright's or Gram's stain will help determining the types of pathogens involved (gram + or gram -). Broad spectrum antibiotics may lead to antibiotic resistance in non-target bacteria because of selection pressure on a greater number of them.

10) Whenever possible, culture and susceptibility results should be obtained to assist with antibiotic selection. Although susceptibility profiles may vary between flocks on a given farm, having these data from previous flocks may also be useful to help veterinarians select an antibiotic when it is important to initiate treatment before obtaining contemporary information. Determining susceptibility of the suspected causal pathogen is especially useful when the initial therapeutic regimen fails.

11) Antibiotic treatment must be limited to proper clinical problems. An example of inappropriate use would be treating with an antibiotic an uncomplicated viral infection.

12) It is important for treatment exposure not to exceed the duration required to achieving the desired clinical response. However, it is important to keep in mind that too short a treatment period can result in the recrudescence of the disease. This could lead in a higher probability of antibiotic resistance by the pathogens involved in the second occurrence of the disease. Most treatments last 5 days (3 to 7).

13) Limit antibiotic treatment to diseased or at risk birds, treating the fewest number as possible. For example, it is important to treat only birds in the poultry house(s) where the disease has been observed. Not clinically affected flocks from adjacent houses on the same farm should not be treated. Exceptionally, it may be advisable to treat a flock in the absence of clinical disease or infection when past experience indicates that the risk of disease outbreak is high if no treatment is

initiated.

14) Minimize environmental contamination with antimicrobials. Unused antibiotics must be adequately stored or disposed. Some antibiotics are stable in manure, which may contaminate the environment.

15) Maintaining an accurate database of treatments and outcomes is useful to assess therapeutic regimens.

16) It is important to respect withdrawal time from the feed or water to prevent drug residue in the meat or eggs. A veterinarian may decide on a longer withdrawal period than written on the drug label (e.g., sulphonamides are excreted in the birds' droppings and since birds are coprophagic, sulphonamide exposure may last for a period of time after the drug is removed from the feed or water).

REASONS FOR FAILURE

1) Wrong diagnosis.

2) The pathogens were not susceptible to the selected antibiotic.

3) The bacteria quickly developed resistance.

4) Although the antibiotic may have been adequate for the targeted pathogen, concomitant infection with a pathogen not susceptible to the antibiotic was present.

5) Incompatible antibiotics were administered together. Additive or synergistic effects are observed when two different antibiotics are used in combination. An antagonistic reaction may also occur. Usually, two bacteriostatic drugs together are additive, while bactericidal drugs used jointly are often synergistic. But the efficacy of many bactericidal antibiotics is considerably diminished by simultaneous use of some bacteriostatic drugs.

6) Reinfection by the same pathogen or by others occurred.

7) Difficulty for the antibiotic to reach the site of infection because of its location (e.g., joint cartilage), inflammation, tissue debris, *etc.*

8) The pathogen is intracellular and may avoid phagocytic cells.

9) The birds' defense mechanisms were too affected because of disease and/or malnutrition. In such cases, it is recommended to use bactericidal antibiotics because bacteriostatic drugs only inhibit or reduce bacterial growth and require the bird's immune system to kill the bacteria.

10) Inappropriate route of administration was selected.

11) Incorrect dosage regimen was applied.

12) Expired antibiotic product.

13) Flock owner did not comply with treatment instructions.

14) Risk factors (environmental and management) were not corrected.

15) Incorrect mixing in the feed or water. Mixing acidic (low pH) products with basic (high pH) pro-

Acidic	Neutral	Basic
Amprolium		Bacitracin methylene disalicylate
Chlortetracycline	Neomycin Sulfate	Sulfadimethoxine
Lincomycin hydrochloride	Penicillin G Potassium	Sulfamethazine
Oxytetracycline		Sulfamethazine + Sulfamerazine + Sulfaquinoxaline
Tetracycline		Sulfaquinoxaline
		Tylosin

Tabl.78.1: Range of relative pH of water administered medications (adapted from Clark, 2010).

ducts in water may produce precipitants that will plug the medicator and/or drinker system (e.g., sulfas (basic pH) + acidified water; tetracycline (acidic pH) + alkaline water (sulfa drugs, ammonia) (see Tabl.78.1).

COMPETITIVE EXCLUSION

Competitive exclusion (CE) is the process by which favorable bacteria exclude bacteria that may be detrimental to the bird or that are of public health interest, such as *Salmonella* spp. It implies preventing the establishment of harmful bacteria into the gut. The idea is to provide early in a bird's life good bacteria having an optimal ability to establish and maintain themselves in the gut environment.

In practice, it is mainly used as a prophylactic measure aimed at increasing the resistance of chicks and poults to salmonella infection. It does imply that the young birds being treated are *Salmonella* free, since the good bacteria are not likely to be able to displace *Salmonella* if it had the opportunity to get established first in the gut. To achieve this under commercial conditions, it is imperative to administer the treatment immediately post-hatch, before the chicks or poults may be exposed to *Salmonella* spp.

The main mode of action of CE is the establishment of a physical barrier (good bacteria culture attaching to the gut wall) between the intestinal wall and the lumen of the gut. The establishment of the favorable bacteria increases the production of volatile fatty acids (VFA) and lactate. This lowers the pH in the gut. The lower pH and high VFA concentration produces a hostile environment for unwanted bacteria, such as *Salmonella* spp. and *E. coli*. There are a few application methods: water application; coarse spray; and integrating the cultures with a feed grade gel product. All are usually administered at the hatchery, the gel product being administered to day old birds via the chick/poult box.

Other applications:

a) After anti-microbial treatment: CE may be considered following an antibiotic therapy that may have had a negative effect on the normal flora

of the gut. The manufacturer of the CE product will propose the best timing of application post antibiotic therapy. Very often, it is two to three days following the end of the antibiotherapy.

b) Stress: wide temperature variations, feed deprivation, moving birds, etc. are physiologic stress that can lead to gut imbalance. The application of a CE culture post stress may reduce the risk of opportunistic pathogen taking over the gut.

REFERENCES

- American Association of Avian Pathologists (AAAP) Guidelines to Judicious Therapeutic Use of Antimicrobials in Poultry. <https://www.avma.org/-KB/Policies/Pages/AAAP-Guidelines-to-Judicious-Therapeutic-Use-of-Antimicrobials-in-Poultry.aspx>
- Anadón A et al. Considérations physiologiques et pharmacologiques et thérapeutique aviaire. *Revue Méd Vét*, 1993,144: 745-757.
- Anadón A. et al. Antimicrobials (including coccidiosis) in poultry. *J Vet Pharmacol Ther*, 2009, 32 (Suppl 1): 26-28.
- Aziz,Tahseen A. Principles of antimicrobial medication via drinking water. *World Poultry - Elsevier* Vol18, N°9:53-55.
- Brugère H. Pharmacologie chez les oiseaux. In "*Manuel de Pathologie Aviaire*". Ecole Nationale Vétérinaire d'Alfort,1992,p.355-363.
- Clark S. Medicating Mistakes: Proper Steps When Medicating (v2.3) PTS-100510.2 2010 AlphaPharma, LLC.
- Dawn Merton Boothe; http://www.merckmanuals.com/vet/pharmacology/chemotherapeutics_introduction/guidelines_for_clinical_use_of_antimicrobial_agents.html
- Judicious Use of Antimicrobials for Poultry Veterinarians. The Food and Drug Administration Center for Veterinary Medicine. <http://www.fda.gov/downloads/AnimalVeterinary/SafetyHealth/AntimicrobialResistance/JudiciousUseofAntimicrobials/UCM095575.pdf>
- Hofacre, C.L., Singer R.S., Johnson, T.J. Antimicrobial therapy (including resistance). In the 13th edition of *Diseases of Poultry*; Swayne D.E. et al. editors; Wiley-Blackwell, Ames, Iowa: 40-43.
- Scott Gillingham; http://www.canadianpoultry.ca/principles_of_competitive_exclusion.htm

Drugs	Interaction with ionophores
Chloramphenicol	Monensin, narasin, salinomycin, lasalocide
Erythromycin	Monensin
Furaltadone	Monensin, lasalocide
Flurazolidone	Monensin, lasalocide
Fluoroquinolones	Monensin
Oleandomycin	Monensin
Sulfadimethoxine	Monensin, lasalocide
Sulfadimidine	Monensin
Sulfaquinoxaline	Monensin
Tiamulin	Monensin, narasin, salinomycin, lasalocide

Tabl.79.1. Antimicrobial drug interactions with ionophoric antibiotics in chickens. All ionophores have a narrow safety margin and readily induce cardiomyopathies and muscle damage in susceptible species.

Parameters	Incompatibility
Hardness	Complex formation with tetracyclines and β-lactams. Ca ⁺⁺ decreases the polymyxine E activity
Low pH	Precipitation of sulfonamides and β-lactams
High pH	Precipitation of tetracyclines, colistin and trimethoprim

Tabl.79.2. Incompatibilities with drinking water parameters.

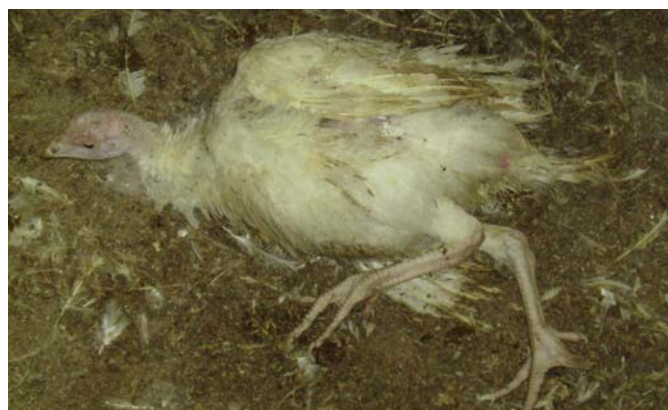

HJ Barnes

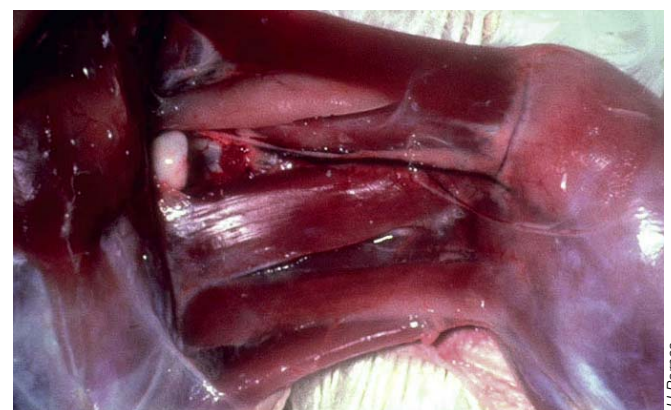

HJ Barnes

Fig.79.1 & 79.2: Acute ionophore toxicity. Signs are associated with muscle damage and vary from anorexia with weakness to complete paralysis. Differential diagnosis includes vitamin E/selenium deficiency, botulism and intoxication by ingestion of *Cassia* seeds.



JY Ferré



HJ Barnes

Fig.79.3 & 79.4: Acute ionophore toxicity. Typically, recumbency with one or both legs stretched out caudally is seen simultaneously in many birds. Birds usually die from dehydration or respiratory failure. In acutely affected turkeys, pallor and atrophy of mainly type I leg muscle fibers can be observed such as in Fig.79.4.

Health measures

79. TOXICOLOGY & RESIDUES IN POULTRY

INTRODUCTION

Toxicity episodes usually occur following deliberate or inadvertent overdosage or improper route of administration, prolonged treatment, incompatible drug combinations, and variations in bird susceptibility (i.e., due to species, individual, age, body condition, growth and egg production rates). Adverse effects such as depressed growth rate, poor feed conversion, reduced egg production, lowered fertility and unacceptable tissue residues should also be considered within the bounds of toxicity.

Drinking water is often the favored mode of drug administration for treatment of clinical disease outbreaks, especially for large production units, although water consumption can vary considerably between birds. Many drugs cannot easily be administered via drinking water. For example, (i) a number of useful drugs has limited solubility, and can only be suspended in water, leading to potential sedimentation problems and water line blockage, and (ii) many medications are not stable (i.e., impurities and/or degradation of products may occur and will affect drug activity) or may also leave water with an unpalatable taste. Furthermore, high ambient temperatures may cause excessive water consumption, leading to drug overdose while reducing feed intake. Lighting schedules can also influence both feed and water consumption. Finally, a critical factor to consider when medicating birds for human consumption is the statutory drug withdrawal period (for meat and eggs).

FACTORS AFFECTING THE DRUG TOXICITY

Many factors can affect the health of treated birds: (1) direct toxicity of the pharmacologically active substances (there are specific avian species susceptibilities); (2) interactions between drugs administered in combination; (3) interactions occurring during feed production because of cross-contamination; (4) incompatibilities between drugs when mixed (*in vitro*) in the compound used for the administration of the medication.

Avian species susceptibility

The susceptibility to drug intoxication varies between different avian species because veterinary

drugs for non-target avian species that are nonetheless administered to birds can lead to adverse reactions. In comparison with domestic fowls, turkeys are more sensitive to streptomycin, salinomycin and phenylarsonic compounds; ducks are more sensitive to dimetridazole and nitrofurans; geese are more sensitive to tetramisole and organophosphate pesticides; pigeons are more sensitive to dinitolmide (DOT), and streptomycin; and Japanese quails and Guinea fowls are more sensitive to monensin.

In vivo drug interactions

The simultaneous administration of drugs such as chloramphenicol, tiamulin, erythromycin, sulfonamides and cardiac glycosides can potentiate ionophoric anticoccidials. Chloramphenicol and tiamulin act synergistically by inhibiting drug-metabolizing enzyme activities in the liver, which in turn results in a lower metabolic conversion of co-medications such as monensin, narasin, maduramycin, or salinomycin.

Chloramphenicol, erythromycin, oleandomycin, tiamulin and sulfonamides have been associated with toxicity when combined with monensin and other polyether ionophores at normal concentrations (see Tabl.78.1). Another example of factors that may have an impact on drug interactions would be the excessive levels of iron (Fe^{++}), calcium (Ca^{++}), and magnesium (Mg^{++}) ions that may reduce the absorption of tetracyclines.

In vitro drug incompatibilities

Drugs may interact prior to administration. Indeed, it is a well-known pharmacology principle that medications may be incompatible with each other in the container used for oral administration. Examples are: (i) chloride can inactivate fluoroquinolones and interfere with vaccines; (ii) inactivation of some antimicrobials will occur when they are in contact with metal containers (e.g. chlortetracycline); (iii) apramycin and gentamicin in solution are rapidly inactivated when mixed or stored in rusty containers; (iv) iron binding with tetracyclines inactivates sulfonamides; (v) hardness and pH of drinking water used for oral medication may produce incompatibilities (see Tabl.78.2).

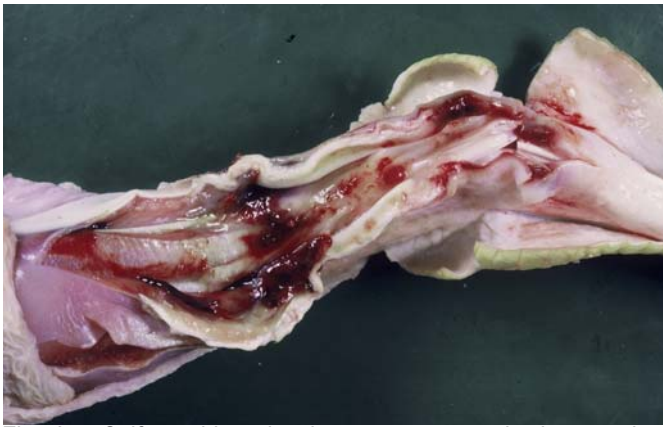


Fig.79.5: Sulfonamide poisoning may occur under hot weather conditions when water consumption rises considerably or when the drug is not uniformly mixed with the feed or also when overdosage occurs. Lesions are widespread hemorrhages.

«Carry-over» or «cross-contamination»

Contamination of compound feed is dependent on a number of factors including human error, production practices and handling procedures in the feed mill, during transportation and on the farm. In feed mills, residual quantities of medicated feeds-tuffs may be retained at various points along the production line, contaminating subsequent feed batches as they are processed. The adhesive strength [adhesion to walls, particle size and density (carrier, substance)] and electrostatic properties of feed additives and premixes aggravate the likelihood of cross-contamination. The consequences of feed cross-contaminations with veterinary drugs and feed additives are (i) toxicity in animals (i.e., non-target animal species) and (ii) drug residues in animal products. Contaminated food may pose a threat to consumers either through exposure to residue concentrations in excess of maximum residue limits (MRLs) (where such limits have been established; incidence of residues in edible tissues and eggs) or through the transfer of antibiotic resistance. Antimicrobials that are most often associated with such contamination are chlor-tetracycline, sulphonamides, penicillin and poly-ether ionophores.

TOXICITY OF ANTI-INFECTIOUS AGENTS

Excessive or incorrect use of antibiotics can significantly alter the normal gastrointestinal flora. This can lead to conditions such as candidiasis or Gram-negative septicemia.

Aminoglycosides

Aminoglycosides are poorly absorbed by the gastrointestinal tract. The intravenous injection of large doses can cause an acute neuromuscular



Fig.79.6: Excess amprolium produces nervous signs such as opisthotonus and cerebro-cortical necrosis due to inhibition of thiamine utilization.

blockade. Young turkeys are more sensitive to the toxicity of dihydrostreptomycin than chickens. Other aminoglycosides such as gentamicin and amikacin at high doses or in dehydrated birds can result in nephrotoxicity and neuromuscular blockade.

Macrolides

They may cause gastrointestinal problems, including diarrhea.

Nitrofurans

This therapeutic group, including nitrofurazone, nitrofurantoin, furaldone and furazolidone, is no longer available for veterinary use in the European Union (EU) because such drugs constitute a human health hazard. In chickens, nitrofurazone produces hyperexcitability, turning in circles, and finally convulsions and death, with no specific *post-mortem* lesions. Treatments slightly exceeding the recommended dose will impair growth in chicks, while larger excessive doses can result in intermittent periods of depression and hyperexcitability leading to death. Poults show ruffled feathers, ataxia, jerky head movements, progressive depression and death. Gross lesions include enteritis in chickens and turkeys, generalized venous congestion and edema in chicks and ascites in poults. Ducklings may die suddenly without previous clinical signs but proventriculitis and gastroenteritis can be seen. The antiprotozoal agent dinitolmide (DOT) should not be used in combination with nitrofurans.

Sulfonamides

A number of sulphonamide drugs have been implicated in the poisoning of poultry, usually because

of excessive doses or prolonged administration. However, there seems to be unidentified factors influencing the outcome of sulphonamide intoxication since, on occasion, the administration of the drug, for a given dose, is harmless under some circumstances but may be toxic under other conditions. Chickens seem to be more susceptible than turkeys or ducks. Main signs are depression, retarded growth, ruffled feathers, and in some cases anemia, jaundice, and death. Egg production is markedly reduced, and egg shells may be thinner than normal, absent, rough and depigmented. Hypersensitivities have also been observed. Among the most common lesions are hemorrhages throughout the body, including the skin, muscles, myocardium, liver, spleen, proventriculus, gizzard and intestinal wall. Hemorrhages may be petechial or, especially in the breast and leg muscles, ecchymotic. The spleen, myocardium, liver, lungs and kidneys may have small, grey nodular foci. The bone marrow is pale and pink in the early stages of the disease and later becomes yellow.

TOXICITY OF ANTIPROTOZOAL AGENTS

Amprolium

Excessive concentrations of amprolium in the feed given to chickens (1000 mg/kg) produce nervous signs such as opisthotonus and lesions such as cerebro-cortical necrosis due to inhibition of thiamine utilisation.

Dimetridazole (DMZ)

This substance is prohibited in the EU. Turkeys fed with 500 mg DMZ /kg showed a decrease in fertility and 1000 mg DMZ /kg fed to turkey breeders reduced egg production, fertility and hatchability. Poults reared on a feed containing 2 g/kg of DMZ showed nervous signs after five weeks of age and over half of the poults had died by eight weeks of age. The affected poults were depressed, or hyperexcitable with incoordination, muscle spasms, respiratory distress and terminal convulsions. Adult ducks fed 460 mg/kg of DMZ had ataxia and incoordination and a marked reduction in egg production, but no mortality. In pigeons, the excessive intake of DMZ in drinking water has been associated with ataxia, neurologic disorders, and death. In goslings treated with 500 mg/L of drinking water, one could observe hyperexcitability, abnormal gait, ataxia, incoordination, recumbency and reduced weight gain; at 1000 mg/L there was significant mortality.

Dinitolmide (DOT)

Excess ingestion in chickens (e.g., 336 mg/kg of feed) produces nervous signs in four to five days and 1000 mg/kg of feed for 14 days leads to incoordination and collapsing of the birds. Layers receiving 1300 mg/kg of feed stop laying eggs in five to six days. Clinical remission may occur 12 to 18 hours after drug removal. There are no gross lesions.

Halofuginone

The growth rate of chickens was decreased when given halofuginone at 6 mg/kg of feed. At 3.2 mg/kg, halofuginone also caused a marked decrease in growth rate of several species of anseriformes (e.g., ducks and geese). Halofuginone as anticoccidial is not recommended for waterfowl, guinea fowl or other game birds.

Nicarbazin

Chickens fed nicarbazin at 250 mg/kg of feed had a reduced growth rate, and higher concentrations have been associated with a very poor growth rate, depression, and some mortality; with some affected birds showing ataxia. In hens, nicarbazin at 100 mg/kg of feed is associated with egg shells showing considerably less pigmentation than normal; and at 400 mg/kg, non-pigmented (white) eggshells are observed within two to three days. Chickens receiving the recommended dose as anticoccidial are more susceptible to heat stress.

Polyether ionophores

Monensin, lasalocid, and narasin have been associated with toxicity in poultry. Toxic levels cause potassium to leave and calcium to enter cells, particularly myocytes, resulting in cell death. Signs of toxicity are related to high extracellular potassium and high intracellular (intramitochondrial) calcium. Clinical signs vary from anorexia, weakness and reluctance to move to complete paralysis in which birds lie in sternal recumbency with their neck and legs extended. Egg production is also decreased. Less severely affected birds may show posterior paralysis with extended legs. Dyspnea has occurred in affected adult turkeys. Ionophore-induced toxicity results in an increase in muscle (AST, CPK) and serum (LDH, ALP) enzyme activities, as well as an increase in serum urea nitrogen and bilirubin levels. Usually, hemoconcentration is noted. Gross lesions are found in the musculoskeletal and cardiovascular systems.



Fig.79.7 & 79.8: Poisoning by ingestion of an organophosphate insecticide. Note the excessive salivation; there are no other macroscopic or microscopic lesions. Poisoning was confirmed by measuring the level of cholinesterase in the brain: the cholinesterase level was 3.5 while it should normally be between 12 and 19.



Fig.79.9: Poisoning by ingestion of an organophosphate insecticide. Nervous signs can be observed but prostration and death can occur without other signs.

TOXICITY OF ECTOPARASITICIDES

Chlorinated hydrocarbons

Toxicity in poultry could occur from overdosage and incorrect usage of these pesticides in those countries where their use in livestock is permitted. Among the more common pesticides used are aldrin, chlordane, endrin, dieldrin, dichlorodiphenyltrichloroethane (DDT) and lindane. Toxicity depends on the chemical nature of the pesticide, dosage and age of birds. Birds are very sensitive; the clinical signs of toxicity are nervous disorders such as hyperexcitability and tremors. In poultry, aldrin-treated grain produces staggering gait, torticollis, lameness and eventually complete paralysis. DDT in chicks causes hyperexcitability, tremors and death. In chickens, endrin, aldrin and dieldrin are 100, 20, and 10 times more toxic than DDT, respectively. Pheasants are more sensitive to endrin, which is 900 times more toxic than DDT. Dieldrin is known to be lethal for chickens, pigeons and pheasants. Partridges and pheasants are similarly affected by chlordane. In layers, feed contamination with DDT results in a significant loss of weight, moulting, nervous signs with ataxia and tremors, and a reduction in egg production and hatchability. In turkeys, DDT produces depression before death.

Organophosphates

Among the more common organophosphates are diazinon, dichlorvos (DDVP), dimethoate, malathion and parathion. With these biochemicals, doses that are non-toxic for one species may be highly toxic for another. Clinical signs are consistent with persistent stimulation of the nervous system, especially the parasympathetic system, including regurgitation, diarrhea, lacrimation, muscular

TOXICITY OF ENDOPARASITICIDES

Imidazothiazoles

In birds, tissue necrosis at injection sites and hepatotoxicity have been reported with levamisole. Vomiting may be observed after parenteral administration in most avian species. Tetramisole at a single oral dose of 300 mg/kg of bodyweight is toxic for geese.

Benzimidazoles

In pigeons, mebendazole at a single oral dose of 150 mg/kg of bodyweight is toxic. Fenbendazole at 50 mg/kg of feed for five days causes neurologic signs and mortality in pigeons and young birds.

twitching and dyspnea. Chronic exposure to certain organophosphate-ester can induce a delayed neuropathy in fowls. Hens treated with organophosphates showed reduced mean plasma acetylcholinesterase activity. In general, birds (chickens, turkeys, ducks and geese) and especially young or small birds are more sensitive to organophosphates than mammals. Decreased hatchability, a drop in egg production and death have also been reported. Goslings seem to be more sensitive than ducks, chickens and turkeys to diazinon toxicity; in young birds, weakness, muscle tremors and death can occur when feed or water sources are contaminated with diazinon. Domestic birds, including ducks, showed signs of toxicity after consuming grains containing trichlorfon and dichlorvos. Fenitrothion at 2000 mg/kg in wheat caused the death of domestic birds, including turkeys and pigeons. The organophosphates compounds should not be combined with carbamates. There are no characteristic gross lesions.

Carbamates

Toxicity is of shorter duration than for organophosphates. Carbaryl may cause death in chicks, poults and ducks. The cholinesterase activity is a more reliable indicator of organophosphate toxicosis because carbamates reversibly bind to acetylcholinesterase.

Avermectins

Some species of birds are very sensitive to avermectins. Ivermectin in birds can produce lethargy, anorexia, and even death.


DRUG RESIDUES IN POULTRY THERAPY

Residues are defined as a residue of substances having a pharmacological action, or their metabolites, and of any other substances transmitted to animal products and likely to be harmful to human health.

Maximum residue level (MRL)

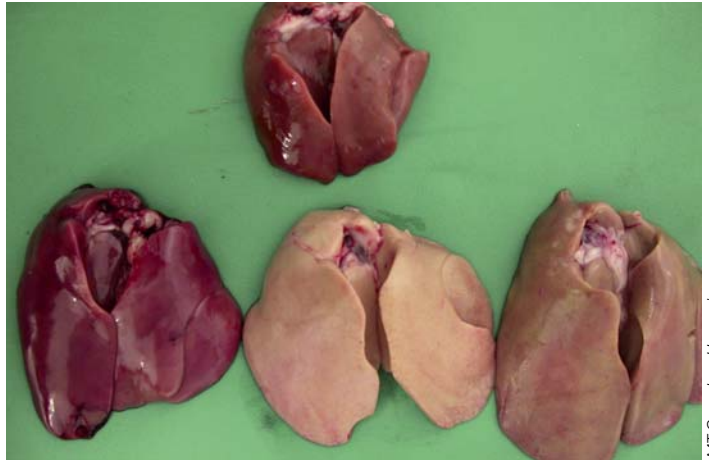
Also referred to as tolerance level in the USA, MRL is the maximum concentration of a residue of a pharmacologically active substance which may be permitted in food of animal origin. In the EU, drugs for which a MRL value should be established are governed by the Regulation (EC) No 470/2009 of the European Parliament and of the Council of 6 May 2009, providing procedures for the establishment of residue limits of pharmacologically active substances in feedstuffs. According

to this regulation, «*the scientific risk assessment (RA) shall consider the metabolism and depletion of pharmacologically active substances in relevant animal species, the type of residues and the amount thereof, that may be ingested by human beings over a lifetime without an appreciable health risk expressed in terms of acceptable daily intake (ADI). Alternative approaches to ADI may also be used. The RA shall concern the following: (i) the type and amount of residue considered not to present a safety concern for human health; (ii) the risk of toxicological, pharmacological or microbiological effects in human beings; (iii) residues that occur in food of plant origin or that come from the environment. If the metabolism and depletion of the substance cannot be assessed, the scientific risk assessment may take into account monitoring data or exposure data*» [Regulation (EC) N° 470/2009]. The standard approach to assessing the safety of residues in food intended for human consumption is based on the determination of the acceptable daily intake (ADI) values that, in turn, are used to establish MRLs. The establishment of an ADI from the determination of a no-observed-effect level (NOEL) and application of an appropriate safety factor provide the hazard identification and characterisation. The ADI approach takes into account effects based on classical toxicology. The ADI can also be determined from microbiological data for substances with microbiological activity. Establishing MRLs for a given drug requires the provision of the following data: knowledge of dosage schedule (amount, dose interval and duration) and administration route; metabolic and pharmacokinetic data in laboratory animals and each of the target food producing species; distribution and residue depletion data for the main edible tissue (i.e., muscle, fat, liver and kidney) in each target species using a radiolabelled drug; validated analytical methods for detection and quantitation of residues, including marker residue; and data defining the effect of residues on food processing. Under EU legislation «*the classification of pharmacologically active substances shall also establish, in relation to each such substance, and, where appropriate, specific foodstuffs or species, one of the following: (a) a MRL; (b) a provisional MRL (pending further data); (c) the absence of the need to establish a MRL; (d) a prohibition on the administration of a substance*» [article 14(2) of Regulation (EC) No 470/2009]. Those substances included in the Annex I, II or III of the Council Regulation (EC) No 90/2377, are listed in the Annex of Commission Regulation (EC) No 37/2010 [Table 1, allowed substances, where is listed the pharmacologically active substance, marker residue, animal species, MRL value, target tissues, other provisions



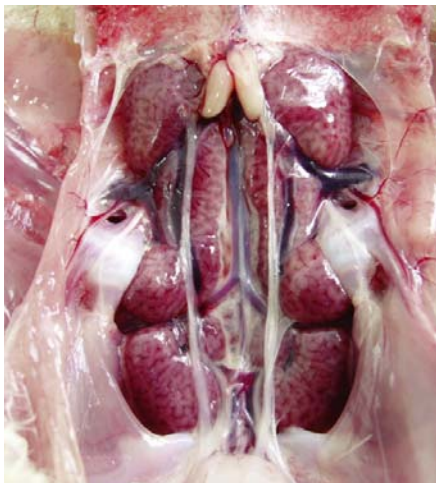MA Mériquez

Fig. 79.10: Vitamin K deficiency of nutritional origin (poor diet) and worsened by the presence of mycotoxins in 77 week-old layers: hemorrhagic eggs. Vitamin K deficiency can be also observed with sulfonamides and anticoccidials or accidental intoxication with rodenticides.



MT Casaubon Huguerin

Fig. 79.11: Aflatoxicosis. The liver is the primary target organ.



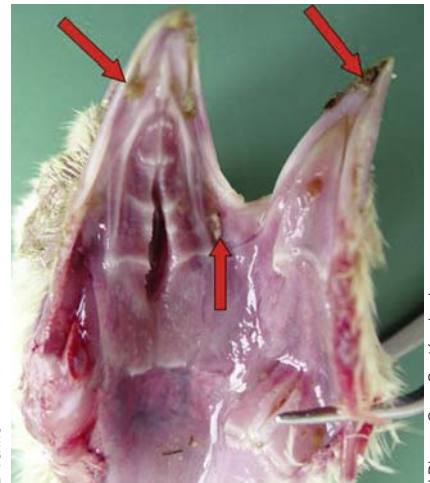
I Dinev - Ceva Santé animale

Fig. 79.12: Aflatoxicosis. In severe poisoning, the kidneys are enlarged and filled with urates.



D Venne

Fig. 79.13 & 79.14: Trichothecenes (T-2 toxin) poisoning. Abnormal feathering (left) and



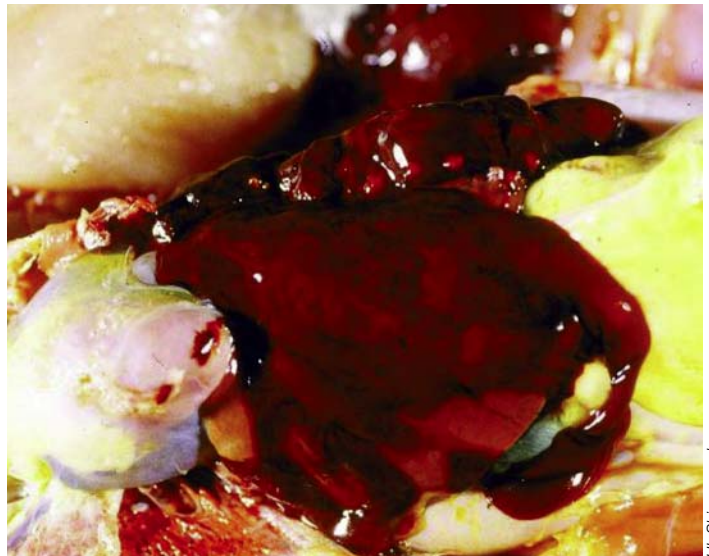
I Dinev - Ceva Santé animale

extensive necrosis of the oral mucosa (right).

Section V



HL Shivaprasad



HL Shivaprasad

Fig. 79.15 & 79.16: Rodenticide poisoning (Peafowl). Diphacinone (green) and zinc phosphide (grey) can be seen in the crop. The anticoagulant effect of this vitamin K antagonist causes hemorrhages in the liver.

(according to Article 14(7) of Regulation (EC) No. 470/2009) and therapeutic classification, and Table 2 (prohibited substances) (where a MRL cannot be established)]. In the EU, a veterinary prescription is required for veterinary products for food producing animals. The exceptional off-label use of authorized medicines is allowed under specific conditions described in the article 11 of Directive 2004/28/EC of the European Parliament and of the Council of 31 March 2004 amending Directive 2001/82/EC on the Community code relating to veterinary medicinal products, which are often referred to as the «cascade». «EU Member States are obliged to take the necessary measures to ensure that, if there is no authorised VMP in a Member State for a specific condition affecting a food-producing species, by way of exception, the responsible veterinarian may, under his direct personal responsibility and in particular to avoid causing unacceptable suffering, treat the animals concerned with (a) a VMP authorised in the Member State concerned for use with another animal species, or for another condition in the same species; or (b) if there is no such product authorized, either: (i) a medicinal product for human use authorised in the Member State concerned, or (ii) a VMP authorised in another Member State for use in the same species or in another food-producing species for the condition in question or for another condition may be used; or (c) if however, there is no such product, a VMP prepared extemporaneously by a person authorised to do so following a veterinary prescription may be used. The veterinarian may administer the medicinal product personally or allow another person to do so under the veterinarian's responsibility». For food producing animals, these provisions apply to animals on a particular holding only, the pharmacologically active substances in the medicinal product used must be listed in the Annex of the Regulation No 37/2010 (Table 1, allowed substances), and «the veterinarian must specify an appropriate period, which shall be at least 7 days for eggs, 7 days for milk, 28 days for meat from poultry and mammals, including fat and offal, and 500 degree-days for fish meat» (Directive 2004/28/EC of the European Parliament).

Drug withdrawal/withholding periods

A critical factor in the medication of all food producing animals is the mandatory withdrawal period, defined as the time during which antimicrobial must not be administered prior to slaughtering the animal for consumption. The withdrawal period is an integral part of the regulatory authorities' approval process and is designed to ensure that no significant

drug residue is present in the bird at slaughter. Drug residues in poultry flocks at time of slaughter or in poultry meat (or eggs) should comply with the MRL values for their target tissues. The withdrawal period is intended to ensure that no harmful residues remain in edible tissues after slaughter. Adherence to the withdrawal period provides assurance that food derived from treated animals will not exceed the MRL for a given drug substance. Failure to respect the pre-slaughter withdrawal period is the main cause of drug tissue residue violations in animal and poultry productions in the EU. Even if the withdrawal period involves only a few days or a few hours, its non-respect may result in residues that can violate the national regulations against sale of adulterated foodstuffs. A withdrawal period, based on the MRL, is fixed by the regulatory authorities and takes into account the use of veterinary drugs in avian species. For the determination of the withdrawal period for avian species, six birds per slaughter session are needed. An appropriate withdrawal period is then established to ensure that the residues in edible tissues are depleted below the MRLs.

A withdrawal period should be established for the substances with MRLs included in Annex (Table 1) of Regulation No 37/2010: (a) Poultry: substances such as danofloxacin, difloxacin, flumequine, erythromycin, tilmicosin, florfenicol, enrofloxacin, thiamphenicol, lincomycin, spectinomycin, flubendazole, toltrazuril, kanamycin, neomycin, spectinomycin, oxolinic acid, colistin, oxacillin, tylvalosin, trimethoprim, phenoxymethylpenicillin; b) Chickens: phoxim, piperazine, sarafloxacin, spiramycin, tiamulin; (c) Turkey: tiamulin (d) Eggs: chlortetracycline, colistin, erythromycin, flubendazole, lasalocid, lincomycin, neomycin, oxytetracycline, phoxim, piperazine, tetracycline, tiamulin, tylosin.

TOXICITY OF SUBSTANCES OTHER THAN DRUGS

The causes of toxicity described above originate from active substances used for the prevention or treatment of diseases of poultry (see also Chap.IV.71 for vitamins and essential inorganic elements); but other intoxications can be observed with non-drug products destined for poultry.

These substances can arise from two different sources. For one, there are natural substances that may be present in some feeds and that have been produced by mycotic agents. These toxic substances are mycotoxins, which are secondary metabolites of fungi. The second possible source is either chemical, generally synthetic products used for crop protection (pesticides) or rodent control (rodenticides), or acci-

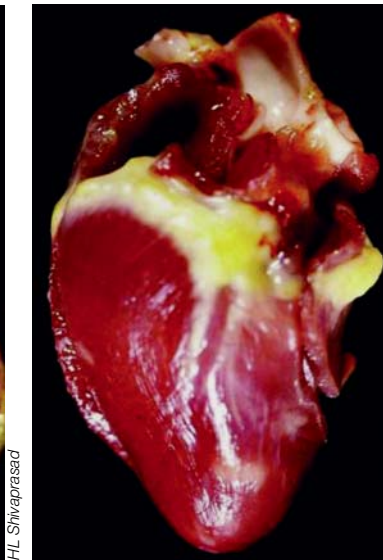
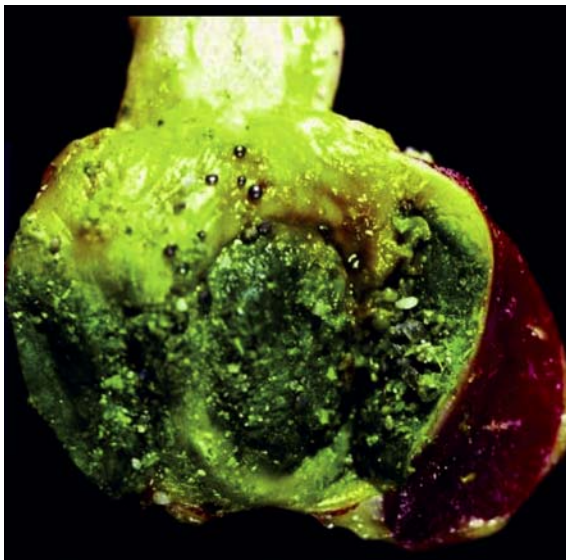


Fig.79.17, 79.18 & 79.19: Lead poisoning (Duck). Lead is the only metallic poison causing significant disease in birds, especially waterfowl ingesting lead shots or contaminated sediments. The material is retained in the gizzard (Fig.79.19) and absorbed slowly. Impaction of the proventriculus secondary to vagus nerve damage can be seen. Myocardial degeneration can be observed (Fig.79.18).

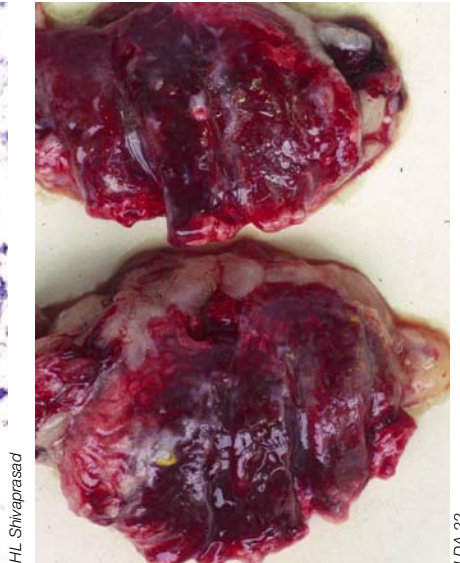
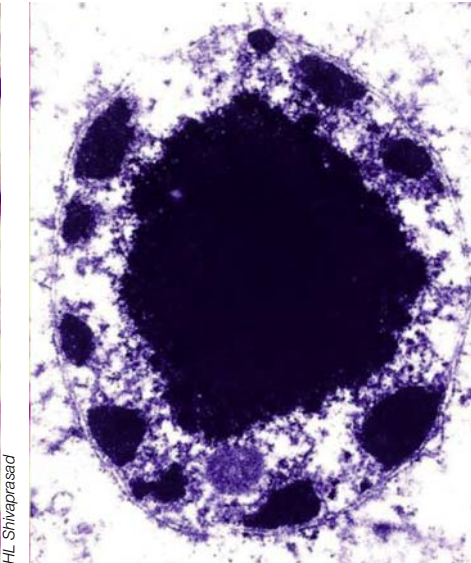
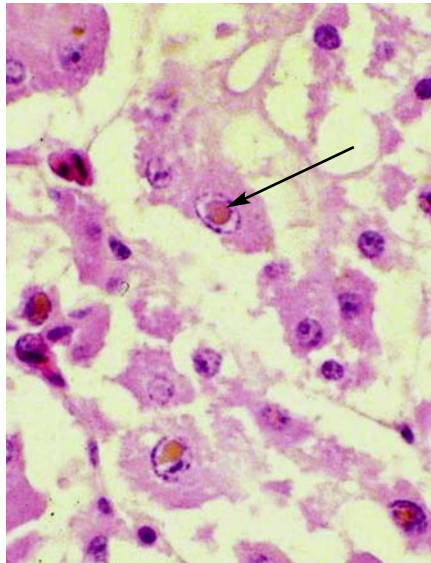


Fig.79.20 & 79.21: Lead poisoning (Kidney). Acid-fast intranuclear inclusion bodies can be seen (arrow, Fig.79.20). Electron-dense inclusion body typical of lead accumulation shown by transmissible electron microscopy (Fig.79.21).

Fig.79.22: Accidental poisoning by chlorine gas (Hen). Pulmonary edema.

Section V

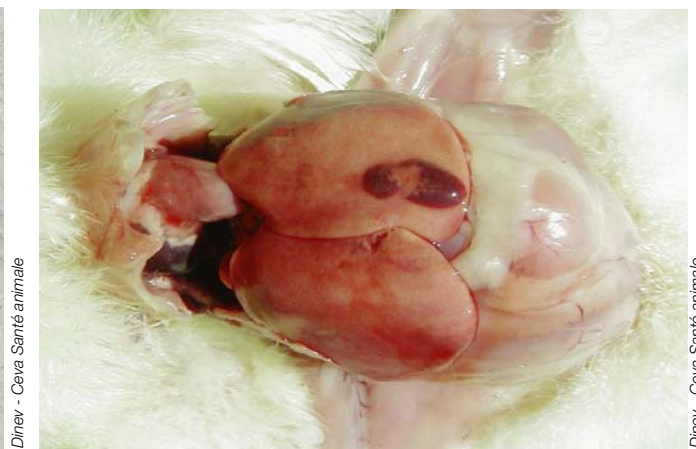

Fig.79.23 & 79.24: Acute propane-butane intoxication. Asphyxia, cyanosis of featherless skin, pulmonary edema and subcapsular hemorrhages in the liver.

dental poisoning by ingestion of toxic substances or inhalation of toxic gases.

Regarding mycotoxins, the main species of fungi belong to the genera *Aspergillus* and *Fusarium* (see Chap.IV.63). Aflatoxins, produced by *Aspergillus flavus*, were first observed in peanut seeds, but they may also be found in cereals (corn, wheat, etc.) and many other plant products. Aflatoxins are proven to be mutagenic, carcinogenic and teratogenic. The first known pathogenic effects were seen with hepatitis in ducks. These mycotoxins are also potent carcinogens (they are classified as category 1 by the International Agency for Research on Cancer (IARC), and they also exert immunosuppressive effects. The most dangerous aflatoxin is B1. Other mycotoxins are produced by *Fusarium* species. An important group is the trichothecenes (e.g., diacetoxyscirpenol, T2 toxin and HT2 toxin). Toxic effects are essentially inhibitions of protein synthesis, with immunosuppression and gastrointestinal lesions. Another group of toxins are Fumonisin (FB1, FB2, FB3, FB4, FA1, FA2, C1 and several others) produced by *Fusarium* fungi, primarily *F. verticillioides* (formerly *F. moniliforme* Sheldon) and *F. proliferatum*. Fumonisin are responsible for varied effects depending on the species, and may be carcinogenic. These mycotoxins are found in corn and therefore contaminate corn-based feed worldwide. FB1 and FB2 are the most abundant and most toxic mycotoxins of this group. Finally, the *Fusarium* species are also producing zearalenone which induces reproductive disorders (infertility, abortion) due to its estrogenic action.

Regarding synthetic chemicals used for safety reasons on crop farms, pesticides are numerous and their use is regulated. They include, for example, insecticides and fungicides. There are many other types of chemicals. These products can lead to residues that are found either on sites where poultry are raised outdoors or in their litter, or possibly in their feed. Prevention of disorders caused by these products is mainly achieved by observing rules regarding their use. This has led to a decrease in usage in Europe and elsewhere. Regarding rodenticides, many products can be used, but anticoagulants (vitamin K) are the most popular. These products are distributed in the form of grains or powder, and depending on how they are applied, they can be ingested directly by poultry or they may contaminate the feed or drinking water. These anticoagulant rodenticides

are classified into two chemical classes: hydroxycoumarins and indanediones. Hydroxycoumarins include bromadiolone (also producing toxic effects on species other than rodents), brodifacoum (chicken must consume considerable quantities of prepared bait to be affected), coumatetralyl, difenacoum, and warfarin (producing moderate toxicity in poultry). The most common anticoagulant rodenticides in the group of indanediones are chlorophacinone and diphacinone.

Finally, note the possibility of accidental poisoning by ingestion of toxic substances (e.g., lead, zinc) or by inhalation of gases that can be toxic in poultry such as carbon dioxide, carbon monoxide, hydrogen sulfide and methane (see Chap.IV.74).

REFERENCES

- Anadón A et al. Considérations physiologiques et pharmacologiques et thérapeutique aviaire. *Revue Méd Vét*, 1993,144:745-757.
- Anadón A & Martínez-Larrañaga MR. Residues of antimicrobial drugs and feed additives in animal products: regulatory aspects. *Livestock Prod Sci*, 1999,59:183-198.
- Anadón A & Martínez-Larrañaga MR. The use of drugs in rabbit meat production. Benefits and risks. *World Rabbit Sci*, 2000,8 (suppl 1) :167-185.
- Anadón A & Reeve-Johnson L. Macrolides antibiotics, drug interactions and microsomal enzymes: implications for veterinary medicine. *Res Vet Sci*, 1999, 66:197-203.
- Anadón A et al. Regulatory aspects for the drugs and chemicals used in food producing animals. In *Veterinary Toxicology*, Gupta RC Ed. Second Ed. Elsevier/Academic Press, San Diego, CA, USA. 2011, pp. 135-157.
- Anadón A & Martínez-Larrañaga MR. Veterinary Drug Residues. Coccidiostats. In *Encyclopedia of Food Safety* (Ed. Motarjemi Y et al. Elsevier, Oxford (UK), 2013, 3, pp. 63-75.
- Flory W et al. The toxicologic investigation of a feed grain contaminated with seeds of the plant species *Cassia*. *J Vet Diagn Invest*, 1992,4:65-69.
- Fulton RM. Toxins and poisons. In *Diseases of poultry*, Ed. Swayne DE, 13th ed., Wiley-Blackwell Publ. 2013, pp 1287-1315.
- Reece RL. Review of adverse effects of chemotherapeutic agents in poultry. *World's Poultry Sci J* 44:193-216.



Fig.80.1: A footbath located outside in contaminated soil (note the feathers) is useless.



Fig.80.2 & 80.3: Disposable plastic boots are not sufficiently strong to be reused.



Fig.80.2 & 80.3: Disposable plastic boots are not sufficiently strong to be reused.



Fig.80.4 & 80.5: The use of rubber boots involves washing and disinfection between each visit and barn. Ideally, boots are designated for each barn and staff.



Fig.80.4 & 80.5: The use of rubber boots involves washing and disinfection between each visit and barn. Ideally, boots are designated for each barn and staff.



Fig.80.6: Despite wearing gloves, hands should be washed and dried.



Fig.80.7 & 80.8: Washing and disinfection of hands are essential biosecurity measures. It should be noted that the disinfectant is usually not effective against *Cryptosporidium* spp.



Fig.80.7 & 80.8: Washing and disinfection of hands are essential biosecurity measures. It should be noted that the disinfectant is usually not effective against *Cryptosporidium* spp.



Fig.80.9: Visitors must wear clean clothes, disposable plastic boots or rubber boots (cleaned and disinfected or farm dedicated), wash hands and eventually wear disposable gloves. A hairnet may also be required.



Fig.80.10 & 80.11: It is not acceptable to leave dead birds accessible to vermin and insects. It is preferable to have a sealed container.



Fig.80.10 & 80.11: It is not acceptable to leave dead birds accessible to vermin and insects. It is preferable to have a sealed container.



Fig.80.12: The ideal is an on-site provided disposal (e.g., incineration), if this method is approved by the state.

Health measures

80. BIOSECURITY & POULTRY PRODUCTION

INTRODUCTION

Biosecurity is defined as any action or health plan designed to protect a population against infectious and transmissible agents. Before addressing the main biosecurity measures, it is important to focus first on four main principles that are the foundation of any good biosecurity program.

First principle. Chain and infection pressure

A sufficient number of microbes must be in contact with a host at risk in order for the disease to spread within a flock. Poultry at risk is a bird without adequate protection against a given infectious pathogen and/or which defence mechanisms (e.g., macrophages, mucus and ciliated epithelium of the bronchi, *etc.*) are compromised or unable to cope with infection. To infect a bird, contact with the agent must also be adequate (infection pressure). This varies depending on the microorganism involved. For example, *Aspergillus* must avoid the defence mechanisms of the upper respiratory track to get to the air sacs. To reach the bird, the microbe must also be transmitted. This can be done by direct contact (bird to bird), indirect contact (*via* contaminated equipment, environment, *etc.*) or *via* vectors (e.g., flies). Finally, to persist on a farm or region, the microbe must have access to a medium that allows for its survival. This is called the reservoir. Vermin, birds or other animals, or any organic material can serve as a reservoir (e.g., feed and water). Every action having a substantial impact

on one or more links in the chain will reduce the risk of disease transmission.

Second principle. The access zone: between the contaminated and the uncontaminated

The place where poultry production occurs on a farm represents the area to be protected against contamination by pathogens. It is therefore necessary to control the access to this area, called the controlled access zone. Moreover, in the absence of contagious diseases in a flock, the place where birds are located (e.g., inside the barn that houses the birds) should be considered a clean or non contaminated area. It is the restricted area, also called the restricted access zone. The area outside this restricted access zone must be considered potentially contaminated.

Third principle. Regional perspective

The intensification of poultry production has indeed created an environment that may promote the spread of contagious diseases. It has been shown that animal performance is negatively affected by the increase in the number of farms per km². A study has shown that the location of the farm and the size of the neighboring farm were the two major risk factors associated with swine herd reinfection to *Mycoplasma hyopneumoniae*. It is therefore clear that any animal activity involves inherent risks of contagious diseases, and the amplitude of these risks increases with regional livestock density. So we must learn to manage these risks by considering each region. It is not enough to establish biosecurity measures within each farm; we must also consider regional activities, such as the movement of people and equipment that may contribute to the transmission of an infectious pathogen and to the maintenance of its reservoir.

Fourth principle. Compliance

The degree of compliance to a given biosecurity measure is the proportion of stakeholders (e.g., farm employees, technicians, *etc.*) who correctly apply this measure. This is the main determinant of the value of the measure being implemented.

Compliance depends on stakeholders' perception of the following:

- Susceptibility of the flock to the disease;
- Importance or severity of the disease;

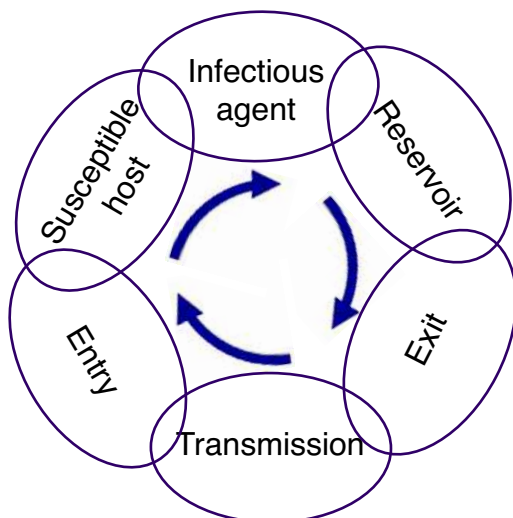


Fig.80.13: Schematic representation of the chain of infection. The arrows indicate the sequence of events required to achieve infection.



Fig.80.14 & 80.15: Optimal biosecurity includes a barrier at the farm entrance. In fig.80.15, an entrance with a double window also allows the fumigation of instruments or equipment for the farm.

Fig.80.16: Properly adjusting the height of water lines is necessary to avoid wet litter.



Fig.80.17, 80.18 & 80.19: Closed watering systems (nipples of fig.80.17) allow a reduction of litter moisture compared to open drinkers (Fig.80.18) unless there is leakage (Fig.80.19).



Fig.80.20 & 80.21: Feed can bring pathogens in the farm. In addition, feed left outside attracts vermin.

Fig.80.22: Vehicles are important mechanical vectors.



Fig.80.23 & 80.24: A source of water and detergent at the farm entrance can reduce the contamination risk from vehicles and more particularly tires.

- Probability that the recommended control measures can effectively prevent or control the disease;
- Physical, psychological and financial factors.

The main determinants of compliance are the level of training of stakeholders (knowledge about why measures must be implemented), the degree of communication between them, the presence of incentives to comply with the measures, and the regular audit of these measures. It has also been demonstrated that compliance was dependent on the environment (ease of application of required biosecurity measures, duration and time of the visit, *etc.*) and certain individual characteristics (personality traits, education and work experience).

MAJOR MEASURES FOR BIOSECURITY

All biosecurity measures must aim at breaking the chain of infection. They must be part of a plan to protect the controlled access zone and, ultimately, the restricted access zone. Some of these measures will have a regional perspective to minimize the transmission of pathogens between farms. Finally, the implementation of these measures should aim at optimizing compliance by all personnel involved on a given farm. It is with the above principles in mind that we present the main measures to be included in a biosecurity program.

Stakeholders at the farm

People may act as mechanical vectors contributing to the transmission of diseases. It is therefore important to focus on the role played by boots, hands and clothing in the transmission of pathogens.

Boots

A footbath is a container filled with a disinfectant and which aims at reducing the microbial load found on boots before and after contact with animals. This biosecurity measure is not unanimously accepted because its usefulness is being questioned. Indeed, unless all organic material found on boots is first removed, the disinfectant in the footbath should be changed after each use, which is impractical.

A more effective approach to reducing the risk of spreading pathogens between barns is to designate a different pair of boots for each one. For visitors, many farms offer disposable plastic boots rather than reusable and washable boots. However, these boots are not sufficiently durable for staff working on the farm. Professionals such as veterinarians may use rubber boots to be thoroughly washed and disinfected between each visit.

Hands

Bacterial load normally found on the skin of a person is between 10^2 and 10^3 cfu/cm². By manipulating birds and equipment located on a farm, hands are exposed to a variety of microorganisms. To reduce this risk, it is important to achieve proper hand cleaning. In human medicine, it has been shown that application of a disinfectant without rinsing is microbiologically more effective and easy to use and saves time compared to washing with soap and water. Furthermore, there is a better compliance than with traditional hand washing. However, in hospitals, hands are usually not visibly soiled unlike under farming conditions. So, under such conditions, it is recommended to wash, rinse, and especially to dry hands. Indeed, after washing with water, it creates an interface due to residual moisture. This allows the translocation of microorganisms between hands and contact surfaces. Thus, in order to avoid cross-contamination, it is important to dry hands after washing.

Wearing gloves could be considered as a solution to limit cross-contamination by hands. It is important to wear single use gloves and to discard them immediately afterwards. Indeed, microorganisms adhere to gloves despite cleaning them with a detergent and drying. We must also ensure that hands are washed after removing gloves.

To encourage compliance to this biosecurity measure, it is essential to design the entrance of each building to facilitate hand washing.

Clothing

Each employee should wear protective clothing and dedicated farm boots and should be assigned to one farm on a given day. Ideally, it is best to change boots and outerwear between each barn. Moreover, when there are several flocks on the same farm, an employee should start with the youngest flock and finish with the oldest, unless a younger flock is suspected or confirmed to be infected with a pathogen. In this case, of course, you should always go from healthy to diseased flocks.

People travelling on several farms in one day should wear at least one clean coverall per farm.

Carcass disposal

It is preferable to dispose of dead birds in a closed container to prevent insects and vermin from getting into contact with dead birds and becoming



Fig.80.25, 80.26 & 80.27: Only certain vehicles are allowed in the protected area: farm tractor, hatchery trucks, delivery of feed or litter and slaughterhouse trucks. These vehicles must be washed and disinfected routinely. The fig.80.26. shows that this is not always the case.



Fig.80.28 & 80.29: An entry with a physical barrier makes boots and clothing changes easier when entering and exiting a barn. The separation can be represented by a bench (Fig.80.28) or a line (Fig.80.29).

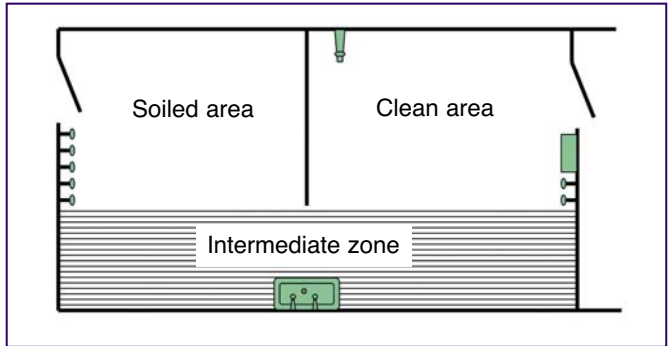


Fig.80.30 Danish entrance with three areas:
 (1) a dirty area where staff leave their boots and coat;
 (2) a transition zone, where they wash hands;
 (3) a clean area, where they don farm boots and outerwear.

Section V



Fig.80.31, 80.32, 80.33, 80.34, 80.35 & 80.36: Cleaning and disinfection of livestock buildings are performed in several steps: removal of litter (80.31 & 80.32), removal of dust and debris (Fig.80.33), cleaning with a detergent (Fig.80.34) before disinfecting (Fig.80.35). Possibly a fumigation can complete disinfection (Fig.80.36).

vectors or carriers of infectious diseases. When carcasses are left on the ground near a farm building, environmental contamination represents a significant risk. It is recommended to position the dead bird container in such a way as to avoid that the rendering truck goes to the controlled access zone. Obviously, it would be ideal to avoid such traffic by eliminating dead birds on the farm by incineration, burying or composting. All these methods are not necessarily allowed in a given region. So you should consult local regulations before opting for one of these options.

Equipment

A farm should, as far as possible, be self-sufficient in equipment (e.g., tools). However, if equipment has to be introduced on a farm, it must be cleaned and disinfected before use, especially if it comes from another farm. This decontamination must be done outside the controlled access zone. When the equipment is leaving the farm, it must be washed and disinfected again.

Water hygiene

The watering system can be a quick way to spread pathogens. It is therefore essential to ensure that an adequate cleaning process is in place to minimize the microbial load in drinking water. An open water system (water container or trough) increases litter moisture, which promotes the growth of some pathogens. Studies have shown that the use of a closed system (with pipes and nipples) leads to a significant reduction in litter moisture, resulting in a significant reduction in the environmental microbial load.

Several studies have demonstrated the benefits of adding sanitizers or chlorinating drinking water (see Chap.V.81). It is also important to regularly clean and disinfect water lines. Indeed, an association has been demonstrated between increased frequency of cleaning water lines and improved flock performances.

Feed sanitation

Unlike drinking water, feed is rarely considered an important source of pathogens. Nevertheless, it represents an important mode of transmission. Some interventions are possible. Heat is the main treatment and it is carried out at the feed mill. A feed additive may also be added such as formaldehyde.

Feed storage is also an important measure of biosecurity. Improper storage (exposure to vermin and other contaminants) has been identified as a risk factor during an outbreak of Newcastle disease.

Vehicles

Vehicles are an important mechanical vector. Some vehicles are equipped with a sanitation system that involves spraying disinfectant on tires for 15 to 60 seconds to reduce the microbial load. The system is activated by the truck driver when arriving and exiting a farm. The impact of this measure is limited if the tires are covered with organic material.

Winter conditions can cause problems for wheel decontamination because disinfectants can freeze. This can be avoided by mixing some disinfectants (e.g., phenol or quaternary compounds) with 50% ethylene glycol (antifreeze) or 70% methanol (windshield washer fluid).

In addition to the decontamination of wheels, it is necessary to pay attention to hygiene inside vehicles transporting birds. One might question the need to observe a downtime period following the decontamination of a vehicle, since a two-day downtime does not significantly reduce the number of bacteria isolated beyond the reduction achieved by cleaning, disinfecting and drying.

Cleaning & disinfection of poultry barns

Cleaning and disinfection of poultry barns are key elements of a biosecurity program. Cleaning should include the surrounding structures and any equipment that you cannot avoid sharing between barns or with another farm. It is also suggested to apply a systematic approach to cleaning; e.g., washing from the back of the building to the front and from the ceiling to the floor. It is important to remove litter and any other organic material that reduce the effectiveness of disinfectants when present. The amount of disinfectant required to disinfect a poultry barn is at least 0.4 liter per square meter. Quantity is important, but the type and concentration of the disinfectant is even more critical. It is necessary to use disinfectants that have been tested on surfaces representing material found on the farm, such as wood, plastic and concrete. The technical application of the disinfectant is another important aspect to consider. Cleaning with water seems more effective at removing debris than dry cleaning. However, using water to remove

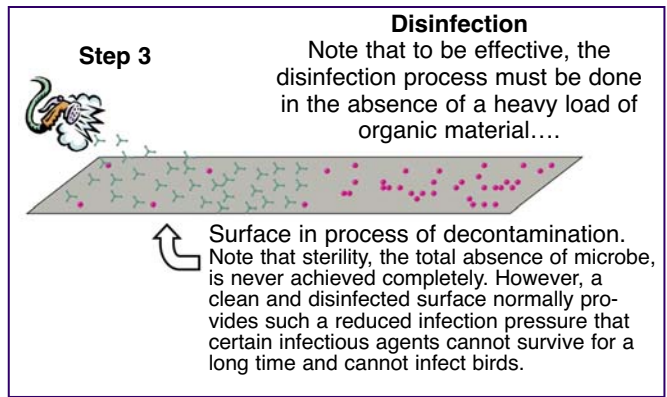
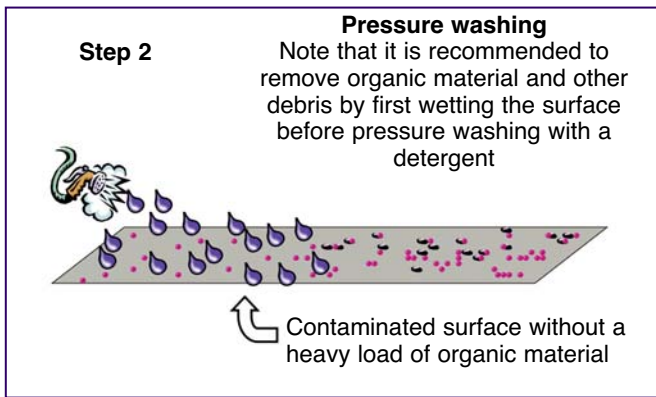
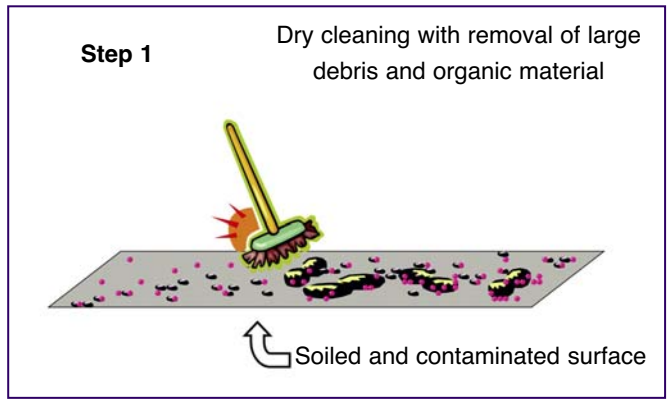
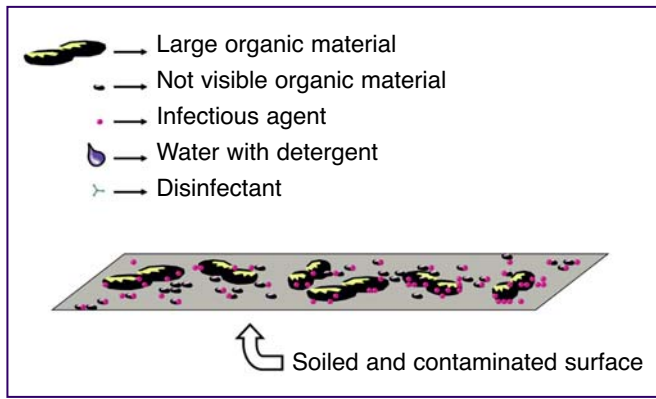


Fig.80.37, 80.38, 80.39 & 80.40: Schematic of washing and disinfection process for soiled and contaminated surface in 3 steps. (Adapted from "Manual de bioseguridad en Granjas Porcinas", Pecuarias, 2001).

Section V

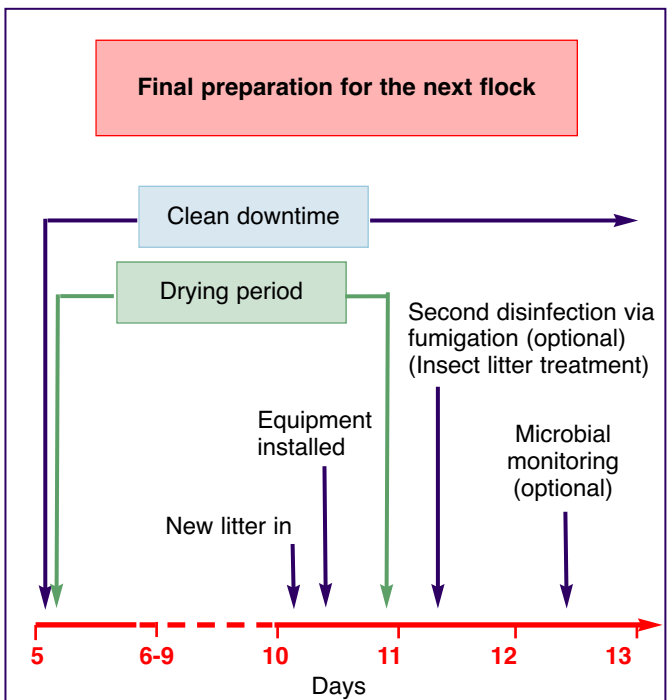
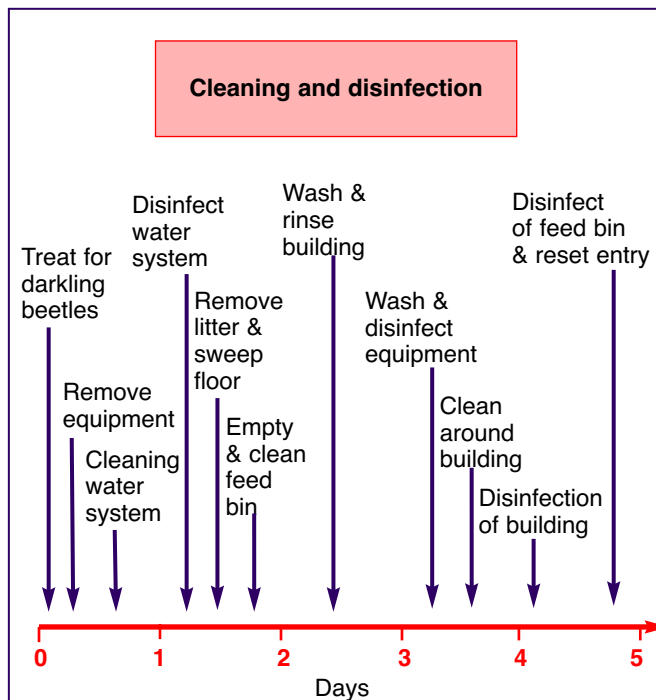


Fig.80.41 & 80.42: Schematic presentation of the different steps of biosecurity measures before the arrival of a new flock. Cleaning and disinfection (Fig.80.41) and final preparation for the next flock (Fig.80.42).

organic material is in fact associated with poorer disinfection results. It seems that plain water favors bacterial growth while providing some protection to these microbes. Thus, disinfectants may have a harder time to reach microorganisms. In order to make the «wet» technique effective, a drying period is needed between cleaning and disinfection.

It is highly recommended to validate the process of cleaning and disinfection, especially after the emergence of an important disease on a farm. Bacterial load on a disinfected surface should not exceed one viable bacterium per square centimeter.

Entrance to a poultry barn

Demarcation between the outside (potentially contaminated) and the inside (not contaminated or clean) is required at the entrance of a barn. For example, an anteroom may be provided with a bench between the «clean» area and the potentially contaminated area. Separation by a bench encourages staff and visitors to change boots and clothing while going from one side to the other one. Compliance is higher with a physical separation such as a bench compared to a line on the floor. However, an even more effective design encompasses a third area, called the transition area. This area helps maintaining a separation between the clean and contaminated areas (i.e., preventing cross-contamination) while providing a more suitable space for hand washing.

Downtime

Downtime is the time between two flocks when the barn is empty. A 14-day downtime, including cleaning and disinfection, is generally recommended between meat-bird flocks to help reduce microbial contamination. In addition to a downtime period, it is strongly recommended to have single age barns. A downtime for the entire farm, called «all-in, all-out» production, is very effective in breaking the chain of infection. It helps reducing environmental contamination.

Manure and litter management

There are different ways to manage manure and litter. Whenever possible, it is best to completely remove litter from a barn after each flock. This practice reduces the infection pressure on the next flock compared to reusing the same litter.

However, particularly in the United States, when birds did not have a health problem, growers reuse the same litter for the next flock. Exposing one-day-old birds to droppings of older healthy birds has a protective effect when the new flock is challenged with bacteria such as *Salmonella*, *Escherichia coli* and *Clostridium*. So there seems to be a competition between pathogenic intestinal bacteria and the normal intestinal flora. Reused litter should however be at least partially dried before placing the new flock in order to reduce the microbial load.

Pest control

Insects & mites

People and equipment may accidentally serve as vectors of some ectoparasites, such as mites, ticks and fleas. It is therefore necessary to control traffic of employees and visitors and to clean and disinfect all material and equipment used in a building to reduce the risk of introducing these arthropods. These measures are particularly important because ectoparasites can survive outside the host for a few days to several weeks. In prevention of, or in response to, an infestation, insecticides (and/or acaricides) are used between each production cycle. When an infestation occurs, it is recommended to treat immediately after the departure of the flock and a second time before the arrival of the next flock. It is strongly recommended to rotate between insecticides (and/or acaricides) in order to decrease the risk that some arthropods develop resistance to specific products.

The farm environment also plays a role in the control of insects and mites. Indeed, the site should always be kept free of unnecessary equipment and material, as these items can harbor vermin and insects that are a source of infection for livestock. Dead birds left in the barn or piled near it promote the development of insects, especially flies, which can be a source of pathogens. Manure management is also important, and even critical to avoid infestation by darkling beetles and their larvae.

The regular inspection and repair of equipment used for feeding and watering reduce production costs by avoiding feed spills outside the barn and in the litter, as well as excess moisture. This maintenance may contribute to reducing populations of insects found in manure and wet bedding. Pipes delivering feed should be cleaned periodically to prevent nesting by insects.



Fig.80.43: The site should always be kept free of unnecessary equipment, as these items can harbor vermin and insects that are a source of infection for livestock.

Fig.80.44: Darkling beetles (in this figure), flies or mites are important vectors of pathogens on the farm.

Fig.80.45: The presence of grass near buildings promotes rodent infestations.



Fig.80.46 & 80.47: An effective pest control is an important component of a biosecurity program. Tubes housing baits are placed at regular intervals.

Fig.80.48: An escaped bird showing a biosecurity breach.



Fig.80.49 & 80.50: Avoid contact between wild and domestic birds.

Fig.80.51: Backyard birds represent a potential reservoir of pathogens.



Fig.80.52 & 80.53: Other domestic species, dogs, cattle, etc. should not be allowed on poultry farm sites.

Fig.80.54: Keeping a visitor log-book can help track contamination.

Rodents

Rodents may be mechanical vectors and even carriers of numerous pathogens (e.g., *Salmonella*). Appropriate pest management includes, when possible, selecting a farm location that minimizes exposure to rodents; buildings and barriers that prevent access to these animals; elimination of areas that may be used as nests or feed sources for these rodents. Monitoring is also important to ensure the effectiveness of a rodent control program. By cutting vegetation around barns, natural ventilation and rodent control are facilitated.

Wild birds

Wild birds pose a significant risk of introducing diseases in poultry. Between 1978 and 2000, about a hundred turkey farms in Minnesota were contaminated by a low pathogenic avian influenza virus originating from migratory ducks. Therefore measures must be in place to limit wild bird access to production sites and prevent direct contact between them and domestic birds.

Pets & other domestic animals

In addition to rodents that are accidental hosts of certain parasites and reservoirs for several infectious pathogens, domestic cats may also contribute to disease transmission. These animals can be carriers of insects (e.g., fleas) and microbes (e.g., *Salmonella*) and thus should not be allowed on a poultry farm. The same goes with cattle. In a study in 1998, cattle were found to be an important source of *Campylobacter* in broiler flocks. It was demonstrated that transmission occurred via the owners' boots. Hence, it is preferable to have only one type of animal per production site. Where this is not possible (e.g., production of turkeys and chickens on the same site), biosecurity measures should be in place to reduce the probability of cross-contamination between different species.

Visitor logbook

If we have learned one thing from the Foot and Mouth disease outbreak in England and the avian influenza outbreak in Italy in the late 90s, it is that time is of the essence. When a disease outbreak occurs, we must be able to quickly locate the possible sources of contamination. This is why a visitor logbook must be kept. It should be clearly visible and easily accessible. The logbook also serves as a reminder of the importance of biosecurity measures.

Location and regional farm density

The stigma attached to contagious diseases is real and acts as a deterrent to sharing information. Just the suspicion of a disease may be sufficient to block exports or interfere with trade agreements. However, recent events have clearly demonstrated that keeping silent can sometimes be much more expensive. Although the risk of legal action is always a consideration, pointing finger has never been an effective disease control method. Briefly, companies and farms in the same region, especially in areas of high farm density (large number of farms per km²), must share certain information in order to control important contagious diseases.

CONCLUSION

Poultry production has evolved over the past decades. Its success has also brought conditions that have favored infectious diseases. That is why, more than ever, biosecurity is a worthwhile investment. The challenge is to convince everyone involved in poultry production. Without a high compliance rate, breaches of biosecurity measures will prevent controlling pathogens important to the poultry industry. However, to strengthen on-farm biosecurity programs, we will need to go beyond compliance to well known measures. Indeed, we also need to learn to communicate. The threat posed by infectious agents is real and will continue to grow, as birds appear more susceptible to disease than in the past and the structure of today's poultry production favors disease outbreaks. Effective communication between all those involved in raising birds is therefore essential.

REFERENCES

- Dorea FC et al. Survey of biosecurity protocols and practices adopted by growers on commercial poultry farms in Georgia, U.S.A. *Av Diseases*, 2010, 54:1007-1015.
- Racicot M et al. Evaluation of the relationship between personality traits, experience, education and biosecurity compliance on poultry farms in Quebec, Canada. *Prev Vet Med*, 2012,103:201-207.
- Racicot M et al. Evaluation of strategies to enhance biosecurity compliance on poultry farms in Quebec: effect of audits and cameras. *Prev Vet Med*, 2012,103:208-218..
- Racicot M et al. Description of 44 biosecurity errors while entering and exiting poultry barns based on video surveillance in Quebec, Canada. *Prev Vet Med*, 2011, 100:193-199.
- Vaillancourt, J-P. Can we talk? *Canadian Poultry Magazine*. 2009, June:16-18.
- Vaillancourt J-P. & Carver D. Biosecurity: perception is not reality. *Poultry Digest*, 1998,57:28-36.

Contaminant, mineral or ion	Levels considered average	Maximum acceptable level	Comments
Bacteria			
Total bacteria (TPC) CFU/mL	0 CFU/mL	1000 CFU/mL	Total bacteria is used as an indicator of system cleanliness. High numbers do not necessarily mean the bacteria present is harmful but it does mean that the system is capable of harboring pathogenic organisms.
Total coliforms	0 CFU/mL	50 CFU/mL	High bacteria levels can impact taste of water resulting in reduced consumption by birds. Shock the well then implement sanitation program such as gas chlorine, bleach, chlorine dioxide, hydrogen peroxide or other sanitizers. Maintain a residual. Presence of any fecal coliform means water is unfit for consumption by poultry or human.
Fecal coliforms	0 CFU/mL	0 CFU/mL	
pH	6.5-7.8	5-8	pH below 5 can be harmful to drinker equipment - causing corrosion to metal components with long term exposure. pH above 8 - impacts effectiveness of most water sanitizers and if high pH is also associated with high alkalinity, may result in reduced water consumption in poultry due to “bitter” taste. If pH is lower than 5 soda ash or caustic soda injection will raise pH. If pH is high, acid injection will be required for neutralization.
Total hardness	60-180 mg/L	110 mg/L	Hardness can also be determined by adding the calcium and magnesium content. Hardness causes scale which can reduce pipe volume and cause drinkers to leak or not work properly. Softeners can remove compensated hardness up to a practical limit of 100 gpg or 1710 ppm/mg/L. If the hardness is above 30 gpg or the sodium to hardness ratio is greater than 33% then the sodium level will be high after softening and reverse osmosis may be required. Phosphate injection will sequester the hardness.
Natural elements			
Calcium (Ca)	60 mg/L		No upper limit for calcium, birds very tolerant of calcium but if values above 110 mg/L may require water softener, polyphosphates or acidifier to prevent scale build-up.
Magnesium (Mg)	14 mg/L	125 mg/L	Higher levels of magnesium may cause flushing due to laxative effect particularly if high sulfate present. Water softener can be used for removal.
Iron (Fe)	0.2 mg/L	0.3 mg/L	Birds tolerant of iron metallic taste but high iron causes leaking drinkers and promotes the growth of <i>Escherichia coli</i> and <i>Pseudomonas</i> and has been linked to botulism. Treatment includes oxidation with chlorine, chlorine dioxide or ozone and then filtration. Other oxidation and filtration technologies are available and effective such as green-sand filtration or resin bed exchange technology.
Manganese (Mn)	0.01 mg/L	0.05 mg/L	Can result in black grainy residue on filters and in drinkers. Treatment includes oxidation with chlorine, chlorine dioxide or ozone then filtration, green sand filtration and softeners will remove manganese. Manganese oxidation is more effective in pH range of >8.
Chloride (Cl)	50 mg/L	150 mg/L	When combined with high sodium levels, creates salty water that can act as a laxative causing flushing and feed passage. Also, salty water can promote the growth of enterococci organisms that can lead to enteric issues. Treatment reverse osmosis, anion exchange resin, lower dietary salt level, blend with non-saline water. Keep water clean and use daily sanitizers such as hydrogen peroxide or iodine to prevent microbial growth.

Tabl.81.1: Water quality standards for poultry.

Health measures

81. UNDERSTANDING AND OPTIMIZING WATER QUALITY FOR POULTRY

INTRODUCTION

Since young, rapidly growing birds typically consume twice the amount of water as feed, it is important to provide a clean, sanitized water source. Water not only serves as a vital nutrient but it also impacts every physiological function in the body. Therefore factors which might alter water quality such as changes in microbial content, pH, nitrogen levels, hardness, alkalinity or mineral content can directly impact water consumption or utilization and bird performance. Water supplies such as wells or reservoirs are dynamic and can change in quality. The following should be used as a guideline for when water supplies should be tested:

- Noticeable change in color, odor or taste.
- Flooding has occurred near well.
- Person or animal becomes sick from waterborne disease.
- Maintenance on water supply system.

- Persistent poor performance.
- Loss of pressure in water system.

WATER QUALITY PARAMETERS

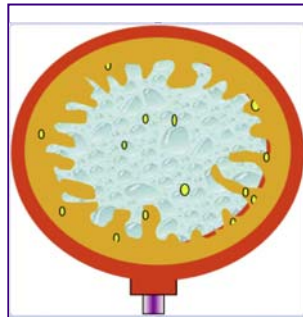
Water quality guidelines for poultry are shown in Tabl.81.1. Note that CFU/mL means colony forming units of bacteria/milliliter of water and mg/L is also the same as parts per million or ppm. While a part per million is quite small, commercially raised birds receiving a balanced diet can be impacted by additional nutrients such as sodium and chloride in the water supply. In addition, water contaminants can also impact the function of drinker systems. Even a small buildup of mineral residue on seals or rims can cause drinkers to leak or fail to activate particularly with young birds. Failure to provide adequate water either through equipment restrictions or poor taste is directly correlated with reduced weight gain, increased feed conversions and reduced egg production.

Sodium (Na)	50 mg/L	150 mg/L	When combined with high chloride levels, creates salty water that can act as a laxative causing flushing. Also, salty water can promote the growth of enterococci organisms that can lead to enteric issues. Treatment - reverse osmosis, lower dietary salt level, blend with non-saline water. Keep water clean and use daily sanitizers such as hydrogen peroxide or iodine to prevent microbial growth.
Sulfates (SO₄)	15-40 mg/L	200 mg/L	Sulfates can cause flushing in birds. If rotten egg odor present, then bacteria producing hydrogen sulfide are present and system will require shock chlorination plus establishment of good daily water sanitation program. Sulfates can be removed by reverse osmosis or anion resin. If hydrogen sulfide is present (the rotten egg smell) than aerating water into a holding tank. Treatment with sanitizers then filtration. Hydrogen sulfide can airlock water lines.
Nitrates	1-5 mg/L	25 mg/L	High nitrate levels can result in poor growth and feed conversions. Presence of nitrates may indicate fecal contamination so also test for bacteria. Can be removed with Reverse Osmosis or anion exchange resin.
Lead	0 mg/L	0.014 mg/L	Long term exposure can cause weak bones and fertility problems in breeders and turkeys. Reverse osmosis, softener or activated carbon will greatly reduce the lead.
Copper	0.002 mg/L	0.6 mg/L	
Zinc		1.5 mg/L	

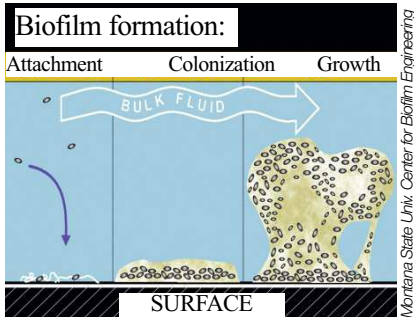
Tabl.81.1: Water quality standards for poultry (continuation).

pH	%HOCl	%OCl ⁻
4	100	0
5	99	1
6	96	4
7	75	25
7.4	52	48
7.5	48	52
8	22	78
9	7	93

Tabl.81.2: Impact of pH on the ratio of hypochlorous (HOCl) to chloric ion (OCl⁻).



SE Watkins



SE Watkins



SE Watkins

Fig.81.1 & 81.2: Biofilms formed in water lines can harbor *Escherichia coli* and *Bordetella*.

Fig.81.3: *Bordetella* in water regulator.

Water pH Treatment	Day 7 (lbs) (g)	Day 21 (lbs) (g)	Day 35 (lbs) (g)	Day 42 (lbs) (g)
Control (8.3)	.359 (162)	1.958 (889)	4.79 (2175)	5.85 (2656)
6 Continuous	.355 (161)	1.954 (887)	4.79 (2179)	5.77 (2629)
5 Continuous	.355 (161)	1.956 (888)	4.77 (2165)	5.92 (2688)
4 Continuous	.361 (164)	1.986 (902)	4.75 (2156)	5.90 (2679)
3 Continuous	.350 (159)	1.986 (902)	4.80 (2179)	5.95 (2701)
5 Intermittent	.346 (157)	1.938 (880)	4.83 (2193)	5.90 (2679)
4 Intermittent	.350 (159)	1.965 (892)	4.83 (2193)	5.89 (2674)
3 Intermittent	.355 (161)	1.990 (903)	4.87 (2211)	5.97 (2710)
SEM	.008	.04	.08	.09
P Value	.9678	.9455	.8951	.6428

Tabl.81.3: Impact of drinking water pH on male broiler average weights
 1. Sodium bisulfate was used as the acidifier.
 2. Continuous treatment- the water acidification was provided from day 0-42.
 3. Intermittent treatment - the water acidification was provided from days 0-7, then 48 hours before and after feed changes, i.e., starter to grower, grower to finisher diets, and last 72 hours.

Treatment	Day 7 (kg:kg)	Day 21 (kg:kg)	Day 35 (kg:kg)	Day 42 (kg:kg)
Control	.884	1.257	1.473	1.667abc
6 Continuous	.903	1.245	1.482	1.682ab
5 Continuous	.930	1.235	1.481	1.643bc
4 Continuous	.889	1.242	1.468	1.651abc
3 Continuous	.895	1.228	1.498	1.684a
5 Intermittent	.953	1.237	1.470	1.649bc
4 Intermittent	.916	1.233	1.466	1.633c
3 Intermittent	.895	1.225	1.469	1.642c
SEM	.029	.001	.013	.013
P Value	.6874	.4794	.7044	.0504

Tabl.81.4: Impact of drinking water pH on male broiler. Adjusted feed conversions.
 1. Weight of all dead birds is used to determine the feed conversion.
 2. Different letters are significantly different at p<0.05.

Section V


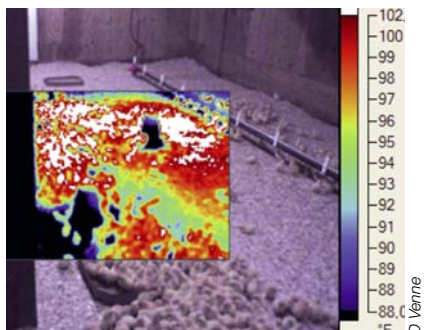


Fig.81.4, 81.5 & 81.6: Elevated temperature promotes the multiplication of bacteria, the evaporation of chlorine, and has a detrimental effect on water consumption. If we compare the quantity of water in containers put directly on the litter about 6 hours after bird placement, it can be shown that chicks consume more water when the containers are in the zone of thermal neutrality (shown with thermal images).



Fig.81.7: Dirty equipment is the best way to bring bacteria in water lines.

Fig.81.8 & 81.9: Condensation favoring the accumulation of bacteria. Compare with a clean water system on the right.

WATER pH

While pH is not a chemical or specific contaminant, it can impact water quality. First, it impacts the effectiveness of disinfectants such as chlorine. A pH greater than 8.0 results in chlorine residual that is primarily chloric ions which are a poor sanitizer. Chlorine is most effective when used in water with a pH below 7.0. The acidic pH range results in a greater percentage of hypochlorous ions which are a strong sanitizer (see Tabl.81.2). Therefore, when the water pH is elevated (pH>8), it may be necessary to acidify the water in order to create a favorable pH for effective sanitation with chlorine. However, acids and chlorine sources should **never** be mixed directly together to create stock solutions. This will cause a chlorine gas release dangerous to personnel. Addition of chlorine and acid to water systems can be accomplished by installing dual injectors and utilizing separate stock solutions.

Water treatments that acidify the water to a pH of 4 or below may provide beneficial protection against bacterial action in the bird's digestive tract, particularly in the crop where the modern broiler tends to store as much food as possible. Although water quality standards list a pH below 5.9 as being detrimental for broilers there is no data that confirms this. A trial conducted at the University of Arkansas in which broilers were given either a continuous or intermittent water supply containing a pH of 3, 4, 5, 6 or city water (pH: 8.3) showed that growth, feed conversion and livability through 42 days of age was unaffected by pH (see Tabl.81.3 & 81.4). Birds on the continuous pH of 3 and 4 did have slightly elevated feed conversions while birds consuming the pH 3 and 4 on an intermittent program had numerically improved feed conversions. Birds on the continuous 4 and 5 pH water did have slightly higher incidence of tibial dyschondroplasia (TD). The pH was adjusted using sodium bisulfate. However the TD incidence could have been a factor of the acid used since sulfate influences electrolyte balance negatively and the cation sodium has the opposite effect. Electrolyte balance or imbalance is a known factor for inducing TD and may have been a bigger contributor to the incidence than pH. Other water acidifiers such as chlorohydric and phosphoric acid may also have a similar impact. Organic acids, while typically considered weak acids and less effective in lowering pH would not have this electrolyte confounding effect.

One important point about pH is the success that many producers have experienced when they have adjusted a high pH of 8 or more to below 7. Although alkalinity and pH are not the same, they are often

associated together in water supplies (alkalinity is a measure of carbonate, bicarbonate, sulfate and phosphate ions). Chickens have two primary taste sensors, salt and bitter. In nature most poisons are associated with bitter or alkaloids. Therefore it may be a natural response for birds to consume less water if there is a bitter taste associated with it and it may be possible to mask this with an acidifier or possibly release the carbonate ions through acidification. It is also important to note that not all acidifiers are compatible with every water supply and there are cases where addition of acid to a water supply caused birds to consume less water. It is very important to monitor water consumption when using new products to assure they do not have a detrimental effect on bird performance.

MINERALS

Birds are fairly tolerant of minerals in water supplies but primary concerns with minerals include microbial growth and impairment of the equipment. Iron serves as the key nutrient for *Escherichia coli*, *Pseudomonas* and even *Salmonella* so water supplies with even low iron levels are at risk of microbial challenges. Sulfur can be converted to hydrogen sulfide by bacteria and this gas has been linked to air locks in water lines. When possible it is best to remove iron, manganese and sulfur through oxidation and filtration. Sodium and chloride can cause poor performance when levels of both exceed 200 ppm. Sodium and chloride can be removed with reverse osmosis. Operations have successfully compensated for high sodium-chloride water levels by reformulating diets with reduced salt levels. Calcium and magnesium are the primary culprits of scale and over time scaling can reduce pipe volume, clog foggers and solidify cool cell pads. It also reduces the effectiveness of cleaners and disinfectants. A water softener can be used to reduce hardness. Do not use water softeners if the water already has a high level of sodium. Nitrates are colorless and odorless and the only way to detect its presence is by testing. As little as 10 ppm nitrate can impact broiler performance causing reduced growth rates and poor feed conversions. Nitrates can be transformed into much more toxic nitrites if the water is exposed to high temperatures (brooding temperatures could confound this) and if bacteria is present in the water.

WATER SANITATION

Providing a clean, safe and sanitized water supply is crucial in assuring flocks perform their best. However, before implementing a daily water sanitation program, it is important to thoroughly clean



Fig.81.10: Line swabbing for microbial culture.



Fig.81.11: Beginning of biofilm in new equipment.



D Venne



D Venne



D Venne

Fig.81.12 & 81.13: The biofilm layer must be peeled off from the drinking system.

Fig.81.14: Mucosal biofilm.

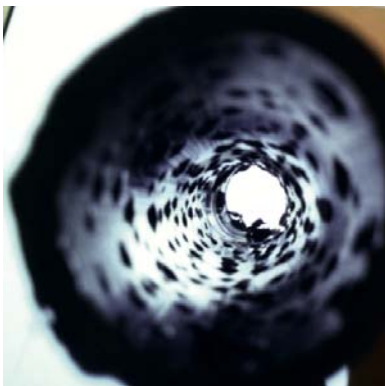


SE Watkins



SE Watkins

Fig.81.15 & 81.16: Not all products are effective in removing built up biofilm. On the left, this line was filled with a weak acid but as compared to the picture on the right (81.16), the solution did not remove any material. In 81.16, the water line was cleaned with a 3% solution of a 50% stabilized H₂O₂ much more effective in disrupting and removing built up material in the system.



SE Watkins



SE Watkins

Fig.81.17: Utilizing strong chemicals in pipelines can have detrimental effects on equipment, so use products like phosphoric acid with caution.

Fig.81.18: If water looks like this, then it must be treated



SE Watkins

Fig.81.19: Water before and after cleaning water lines.

as much of the water distribution system as possible. Line cleaning is necessary before providing birds with sanitized drinking water because even low levels of sanitizer placed in dirty water lines can result in the biofilm sloughing off, which can clog drinkers, restricting water flow to the birds. Another impact of adding sanitizers to water intended for bird consumption is that the sanitizer can actually react with the biofilm and result in off tastes that may drastically reduce water intake. Effectively cleaning the water system (including the drinker lines) helps remove biofilm and scale build-up that can act as a food source and hiding place for harmful pathogens. Many pathogens like *Salmonella* can live for weeks in water line biofilm resulting in a continuous source of contamination.

Where to start

To assure lines are effectively cleaned, the first step is to answer the following series of questions.

1. What is the water source?

Untreated well water (i.e., water that is not treated with any type of daily sanitizer product) is the most vulnerable to the formation of slime or biofilm in the drinker lines. While most municipal or rural water supplies contain a minimum of 0.2 ppm free chlorine which greatly reduces bacteria growth, poultry drinking water is handled differently (slow flow and warmed during brooding) from the water supply that goes to a home. Thus, it is unwise to assume that cleaning of drinker lines is not needed.

2. What is the mineral content of the water supply?

The minerals calcium and magnesium are the sources of scale, a hard white build-up. If the water supply contains more than 60 ppm of either or both these minerals and the water pH is above 7 then chances are good that there is scale in the water system that will have to be removed with an acid cleaner designed for nipple drinker systems. Other common mineral contaminants are iron, manganese and sulfur. Iron results in a rusty brown to red colored residue, while manganese and sulfur can form black colored residues. Natural sulfur in the water should have a smell similar to a match head. If the water smells like rotten eggs, then the culprit is hydrogen sulfide. Hydrogen sulfide is a by-product of sulfur loving bacteria and the lines will need to be cleaned with a strong sanitizer. It might even be necessary to shock chlorinate the well. If the filters at the beginning of the water lines are rusty or black colored, then a strong acid cleaner should be used after the sanitizer flush.

3. What products have been used in the water system?

If additives such as vitamins, electrolytes, sugar based products, mineral based performance enhancers or weak concentrations of water acidifiers have been used frequently, then chances are a biofilm is present. Once a biofilm is established in a water system, it makes the system 10-1000 times harder to clean. It is important to play it safe and use strong sanitizer cleaners.

4. Have there been health issues flock after flock such as *E. coli*, necrotic enteritis or respiratory challenges that do not respond to good management, clean-out or down-time?

The culprit for these problems may be hiding and thriving in the water supply, particularly the water regulators and drinker lines. Cleaning with a strong sanitizer is definitely an intervention that might help.

Choosing a product

After identifying the type of cleaning that will be most beneficial, the next step is to choose a product that will not damage the equipment. Currently there are several acid products that can be used for scale removal. Check with your local animal health product supplier for options. Just remember that in order for the product to be effective in removing scale, it needs to drop the water pH below 5 but should not drop the pH below 4 to prevent equipment damage. While a strong bleach solution might be effective in removing biofilm, the potential damage it can do to the regulators and nipple drinkers makes this a poor option and the same is true for many cleaners that might otherwise be good poultry barn disinfectants. Iodine is not very effective against biofilms so it makes a poor choice. Currently there are several sanitizer products available for cleaning drinker systems, but some of the most effective products which are not damaging to the drinker systems are the concentrated, stabilized hydrogen peroxides. The active ingredients in these products are different from over-the-counter hydrogen peroxide because a stabilizer keeps the sanitizer from converting to water and oxygen before it finishes the cleaning job. There are also several chlorine dioxide products available, but they are most effective if an acidifier is present which may require dual injectors or a way to safely mix the products prior to injection. A third product used by the industry is household ammonia. A quick test on algae showed that running one ounce (29.6 mL) of ammonia in every gallon (3.8L) of water was not



Fig.81.20: Submersible pumps can be used to inject proper concentrations of line cleaners into water systems.



Fig.81.21: Line cleaning using ProxyClean (Hydrogen Peroxide).



Fig.81.22 & 81.23: Calcium on drinker and in the drinking system.



Fig.81.24: Start of scale on a drinker.



Fig.81.25: Calcium scale built up on a plasson drinker.



Fig.81.26: Water contaminated with iron.



Fig.81.27: Iron clogged in water line.




Fig.81.28: Iron in filter.



Fig.81.29: Iron in drinker.



Fig.81.30: Filter with crude in it.



Fig.81.31: Iron issues in drinker.



Fig.81.32: Clean filter and filter clogged with iron and manganese.

nearly as effective as a 3% ammonia solution. However it is strongly recommended that the equipment manufacturer be consulted before using this. The most important fact to remember is biofilms or established growth of bacteria, molds and fungus in water systems can only be removed with cleaners that contain sanitizers. It also should be a product and concentration that will not damage the equipment. Pay close attention to any product safety recommendations and follow them accordingly.

Cleaning the system

After the birds are removed from the house, it is time to clean the system. First flush the lines with water. Use a high pressure flush if available. This will remove any loose sediment from the lines. Also make sure the standpipes are working properly to assure any air build-up that may occur during the cleaning process will be released from the lines.

Next, determine how the cleaner will be injected. If a medicator is used, it may not provide the concentration of required cleaner, therefore use the strongest product available to overcome the dilute injection rate of the medicator. A very effective alternative is mixing the cleaner in a large barrel and then using a small submersible pump (1/12th horsepower) to pump the product either into individual lines or through the water tap where the medicator attaches to the water line. A third option is pumping the cleaner from the well room through a variable rate injection pump which will pump solutions with a concentration greater than 1:128 which is only a 0.72% solution. This is a good idea because it cleans the water lines going to the poultry house, which can be a source of contamination particularly since the larger the pipe, the more water passes through it and therefore the more nutrients are provided to the potential biofilm. This can be a bad idea if the distribution lines are very dirty since it will send the filth into the poultry house water lines and therefore will require extra flushing of the lines. Use this option only if there is a faucet in the poultry barn that can be used to flush the water lines before water reaches the nipple drinker lines. Every 100 feet (30.5m) of a half inch (12.7 mm) water line holds approximately 2.5 gallons (9.5 L) of water. Therefore, in a 400 foot (122 m) poultry house it takes approximately 9.6 gallons (36.3 L) of water per line [380 feet (116 m) of line divide by 100 feet (30.5 m) so 3.8 x 2.5=9.6]. So, for this example, when you add up all of the water lines in the barn, it amounts to 3040 feet of water line (928 m) and this will require approximately 76 gallons (287.7 L) of prepared cleaning solution. Once the drinker lines are filled with the cleaning solution, let it stand as long

as possible with 72 hours being ideal. Also use a broom to sweep the nipple drinkers in order to get the cleaning product down into the drinkers. However check with the product manufacturer to assure this will not damage the equipment. After the lines are cleaned, if mineral build-up is an issue, then re-flush the lines with the acid cleaner.

Keeping the system clean

Cleaning the water lines between flocks is only half the battle. Even with a thorough cleaning, if a significant number of bacteria, fungi or yeasts are still present, then the biofilm has the potential to return completely in 2-3 days. Therefore the last step is to establish a daily water sanitation program. This will benefit both the birds and the water system.

QUICK GUIDE TO CLEANING WATER LINES

1. After birds are removed from house and before the litter is removed, **flush all water lines with water.**

2. Prepare a 3% cleaning solution.

- For barns with water holding tanks, mix three gallons (11.4 L) of hydrogen peroxide (Proxyclean, HydroClean or 35% hydrogen peroxide) into 97 gallons (367.2 L) of water.
- Pump into the lines. May need to increase amount prepared if barns are longer than 500 feet (152.4 m) [every 100 feet (30.5 m) of line holds 2.5 gallons (9.5 L) of water].
- If no holding tanks, prepare stock solution in a 100 gallon (378.5 L) stock tank or barrel. Use submersible 1/4th -1/2 hp pump with water hose long enough to reach medicator connector. Or a variable injection rate pump can be connected.
- Alternative cleaning solution is 2% CID 2000®, (20% stabilized hydrogen peroxide with acetic acid) but leave in lines only 4-6 hours and repeat process.
- Connect submersible pump to water line at medicator and pump the cleaning mixture into the lines.
- Activate nipple drinkers with a broom or by hand to assure cleaner goes into drinkers.
- Leave product in lines for minimum 24 hours with 48 to 72 hours being ideal.
- Flush product from lines with clean water which has a bird drinking level of water sanitizer.



Fig.81.33: Example of the interaction of manganese with chlorine.



Fig.81.34: Fouling of water lines alters the flow of water.

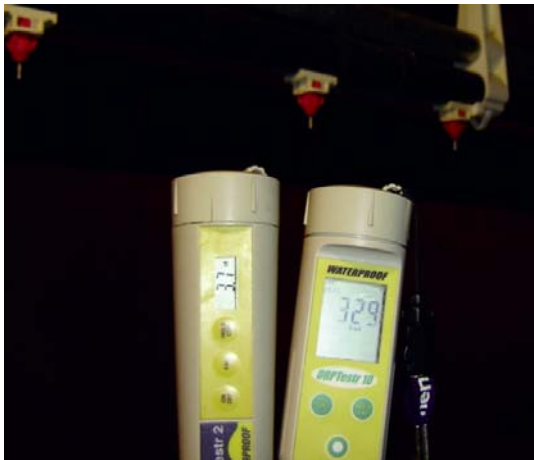

Fig.81.35: Measuring ORP is fast (less than 2 minutes) and provides information on free chlorine residual.

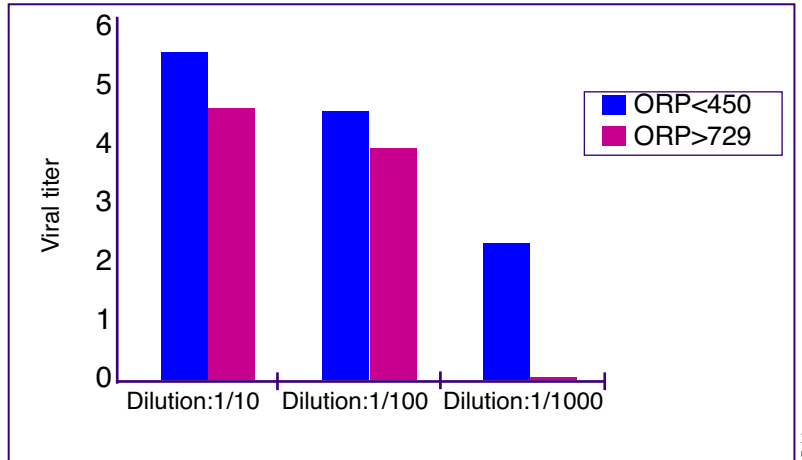


Fig.81.36: Effect of dilution of a vaccine and Oxidation Reduction Potential (ORP) on the survival of Gumboro virus *in vitro*.

Section V



Fig.81.37: Managing water quality is more difficult with open drinkers, but it can be done.



Fig.81.38: Keep medicator buckets clean and covered.

3. For farms with hard water (more than 110 ppm of calcium and magnesium combined)

- Fill lines with a solution of citric acid or other low pH product approved for use with water lines and let stand in lines for 24 hours.
- Acid preparation: mix 4-6 packs (454 grams/pack) of citric acid per gallon of water to make a stock solution (the more scale in water the more acid should be added to the stock solution). The final pH of the water should be less than 6 with 5 pH ideal for scale removal.

4. Final flush

- Prepare a bleach stock solution of 6-10 ounces (177 - 296 mL) bleach in a gallon (3.8 L) of water or 4 ounces (118 mL) of Proxyclean per gallon (3.8 L) of water as the stock solution.
- Use medicator to pump into lines so that this is the last water to enter the lines.
- Make sure medicator is pumping in bleach stock solution as the acid is flushed from the lines.
- Leave in lines until right before birds are scheduled to arrive.

5. Start birds on fresh sanitized water with 3-5 ppm free chlorine residual at the end of the line or drinker farthest from chlorine injection (or the Proxyclean with the goal of 25-50 ppm of H₂O₂ residual). Good starting point stock solution is 4 ounces bleach or Proxyclean in a gallon of water. Add a second injector or medicator and inject an approved acid. It will enhance the effectiveness of the chlorine.

Do not add chlorine when administering vaccines, medications, vitamins or copper sulfate, do not mix chlorine and other products in the same stock solution.

A good water sanitation tool when using chlorine is the Oxidation Reduction Potential (ORP) of water. It measures in millivolts the oxidizing potential of free chlorine residual. A strong oxidizer literally burns up viruses, bacteria and other organic material present leaving water microbiologically safe. An ORP value 650 millivolts or greater indicates good quality water that has effective sanitizing residual.

The ORP meter can be a useful tool for identifying water supplies that don't have adequate chlorine residual and for adjusting the residual without overusing chlorine. It is also important to monitor chlorine residual with the goal of 2-5 ppm of free chlorine in the water supply. Chlorine may be present as both total and free chlorine. Total reflects both the chlorine bound by minerals and organics while free chlorine is the residual still available for sanitation. It is not uncommon to see a difference between these numbers when testing for both and this indicates that something is tying up part of the chlorine. The bottom line is utilize information on pH, ORP and chlorine level to determine if the sanitation program is effective and to also prevent equipment damage through overuse of chemicals.

CONCLUSION

In conclusion, water is the most essential nutrient birds receive yet the quality of bird drinking water is often taken for granted. Providing flocks with a clean, wholesome supply can make a difference in performance.

Should water be a suspect for flock problems, make arrangements to have water tested for total bacteria numbers as well as for mineral content. While total aerobic plate count won't tell exactly what is in the water, it is an indicator of excessive levels of bacteria that should be addressed. By promoting a regular water sanitation program on farm, producers can prevent environments in water systems that could lead to poor bird performance.



Fig.81.39 & 81.40: Chicks and chickens using drinkers.



Fig.82.1: Day old spray vaccination in the hatchery.



Fig.82.2: Field spray vaccination.



Fig.82.3: Drinking water vaccination.

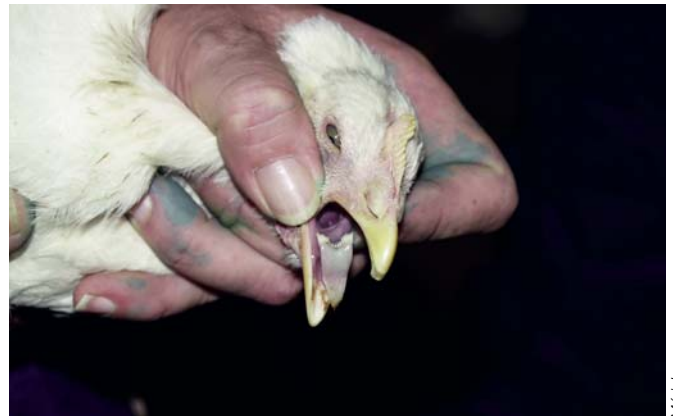

Fig.82.4: Drinking water vaccination check. Tongue should be dyed with colored drinking water.

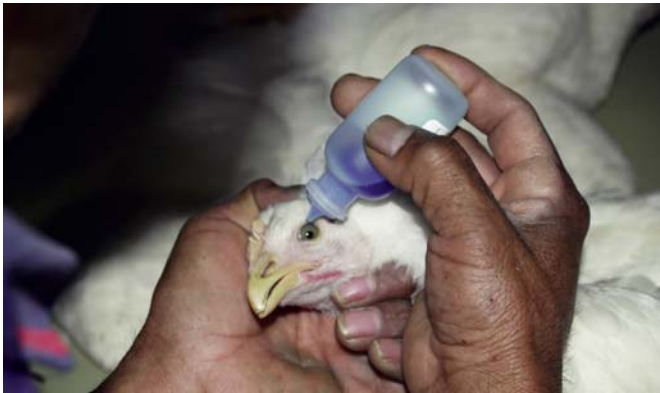

Fig.82.5: Eye drop vaccination.




Fig.82.6: *In ovo* injectors.



Fig.82.7: *In ovo* injections into embryonated eggs at transfer between setter and hatcher in the hatchery.



Fig.82.8: Transfer after *in ovo* injections.

Health measures

82. VACCINATION TECHNIQUES

INTRODUCTION

Several vaccination methods are used to administer vaccines: drinking water, spray/nebulisation, injections, transfixion, *in ovo*. Only an optimum administration of a vaccine can result in a sufficient immune response leading to adequate protection against disease. Factors such as age of the birds, number of birds, type of vaccine, the target organ to be reached, know-how of operator and costs have to be considered in order to determine the optimal route of administration of a given vaccine. The operator must pay attention to hygiene in the environment where the vaccine is prepared and used. Mass application of live vaccines is performed by spray or drinking water. Eye drop application combines the advantages of live vaccine mass application and individual application techniques. Individual application is represented by injection, either *in ovo*, by subcutaneous route, usually at one day of age, by intramuscular/subcutaneous route in adult birds or by transfixion, also known as scari-fication or wing-web stab.

SPRAY VACCINE APPLICATION

Spray administration of live vaccines is used in two very different environments, the hatchery and the farm. Day old administration consists of the vaccination of small groups of approximately 80-150 birds at the same time, being sprayed directly in the delivery box. Usually spray cabinets are used for this purpose. The accurate and consistent volume of vaccine administered to each box allows for a uniformed controlled exposure of the birds to the vaccine. The goal is to cover the birds with liquid, so the vaccine is administered directly to their eyes and nostrils and the droplets that shine on their down will encourage them to pick them off of each other and from the surface of the box. Therefore the particle size is not critical, droplets are bigger (100-800 microns) than for spray application at the farm. Fresh, cool distilled water should be used for vaccine reconstitution as water temperature also has an impact on the viability of a live vaccine. Vaccine administration at the farm is carried out on large groups of birds generally up to several thousands. If the birds are housed

directly on the floor, they are able to move around the barn, which may reduce exposure to the vaccine. For birds housed in cages, it is difficult to reach every row of cages and to spray far enough into each single cage. Before choosing the spray equipment to use for on farm vaccination it is important to understand the features of each type of equipment such as droplet size, distance that droplets can travel, volume of water used per time unit, and the minimum time required to vaccinate a poultry house.

DRINKING WATER VACCINE DISTRIBUTION

Drinking water is one of the most common methods used for mass application of live vaccines to large poultry flocks: it is strictly recommended for live vaccines such as for infectious bursal disease (IBD, also known as Gumboro disease) or encephalomyelitis, and an option for a wide range of respiratory live vaccines, such as infectious laryngotracheitis, Newcastle disease, infectious bronchitis and avian Metapneumovirus. Among the critical aspects to consider, there is the possible inactivation of the live vaccines or the loss of titer, and the need for distribution of a full dose to all of the birds. There are many different aspects that must be considered such as water quality, particularly disinfectant residues, metal ions, detergents, and hardness that can negatively impact the vaccine. The water volume and time of administration, the type and number of drinkers required for a given number of birds have to be taken into account to properly prepare the vaccination procedure in a barn. Water should be treated with a stabilizer, possibly skimmed milk or skimmed milk powder at a rate of 2 g/liter at least 20 minutes before the vaccine will be mixed in. This allows the stabilizer or milk proteins to bind the free metal ions and chlorine in the water, preventing the inactivation of the vaccine virus. The vaccine bottles should be opened under treated water. The vaccine should be mixed in the amount of water that all birds will drink within a maximum of 2 hours. To make sure that the vaccine is properly administered, it is possible to add a dye to the vaccine water. If vaccination is successful, the birds' mouth and beak will be temporarily stained.

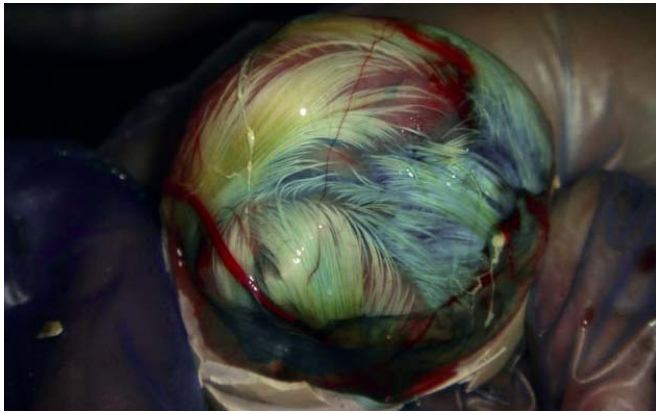


Fig.82.9: *In ovo* injection check. Embryo should be dyed with injected colored vaccine.



Fig.82.10: Carousel for subcutaneous day old chick injections in the hatchery.



Fig.82.11: Subcutaneous day old chick injection with automatic injector in the hatchery.

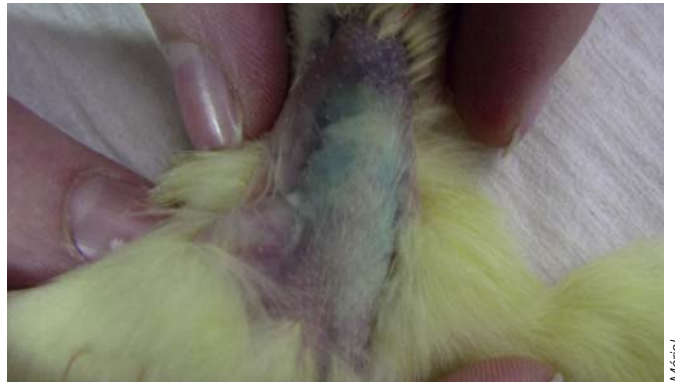


Fig.82.12: Subcutaneous day old chick injection check. Vaccine should be visualized in the neck region.



Fig.82.13: Field subcutaneous neck injection.

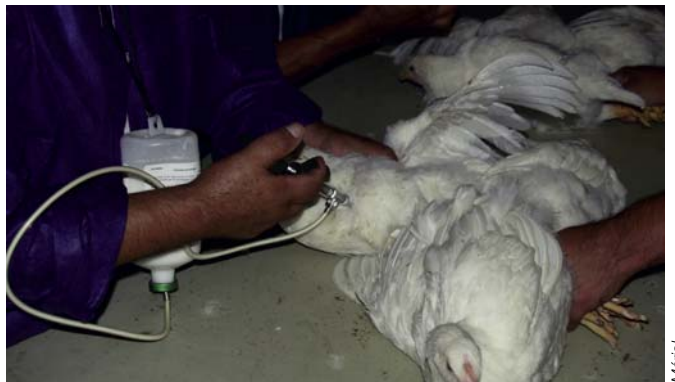

Fig.82.14: Field intramuscular breast injection.

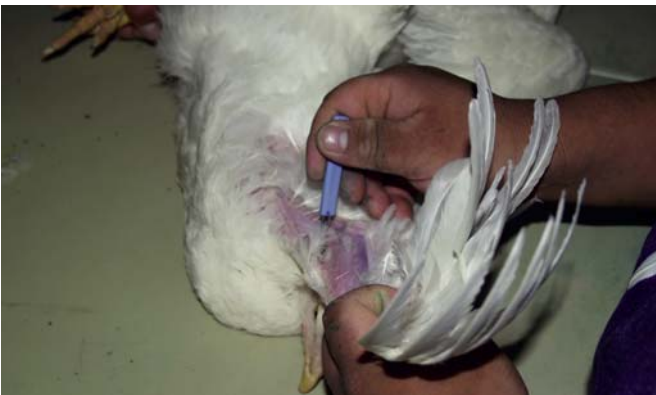

Fig.82.15: Transfixion of the alar membrane or wing web injection.

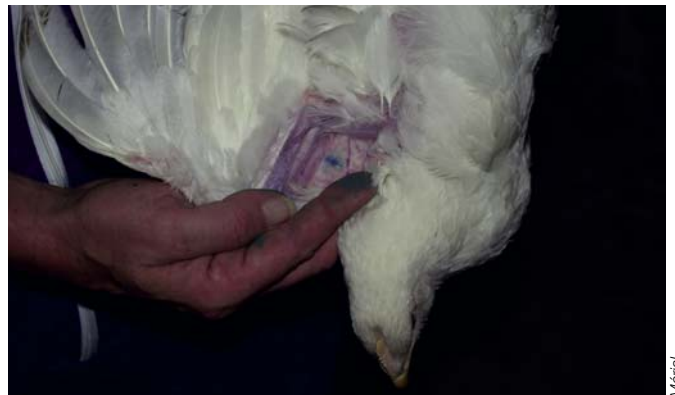

Fig.82.16: Wing web injection check. Deposit of dyed vaccine should be visualized at the points of transfixion.

EYE DROP VACCINE APPLICATION

Eye drop application may be considered as the most effective method of administering live vaccines against respiratory diseases such as infectious laryngotracheitis, Newcastle disease, infectious bronchitis, avian Metapneumovirus and Mycoplasmosis. It allows the delivering of a full dose to the target organs in each bird, facilitating the development of humoral and local immunity due to the contact with the respiratory mucosa and the Harderian Gland. Each bird must be handled individually and the process carried out with care to ensure the absorption of the vaccine drop by the surface of the eye.

IN OVO INJECTION

In ovo vaccination is performed just before eggs are transferred into hatcher trays on day 18-19 of incubation. This method is widely used around the world particularly for chicken broilers and to some extent for layer and breeder vaccination. It pertains to live Marek's vaccines, serotypes 1, 2 or 3, respectively, Rispens CVI988, SB-1 or HVT (Herpesvirus of Turkey), alone or combined, native field strain vaccines or vectors, mainly the HVT vaccine strain, such as the vector vaccine vHVT-IBD (Marek & Gumboro (IBD) disease), vVHT-ND (Marek & Newcastle disease), *etc.* Marek's cell-associated vaccines are stored in liquid nitrogen at -196°C and it is essential to immediately thaw the frozen vaccine in a water bath at around $+27^{\circ}\text{C}$. To preserve the cell viability and vaccine titer all steps should be carried out as quickly as possible, within about 90 seconds. The thawed vaccine has to be mixed with a diluent in order to allow injection. In practice, a small hole is made at the blunt end of the eggshell and vaccine is injected below the chorioallantoic membrane to the amniotic cavity or directly in the embryo. Automatic hatchery injectors are used for *in ovo* vaccination. Integrated sanitation systems usually prevent contamination during *in ovo* vaccine delivery.

SUBCUTANEOUS INJECTION

This method is most commonly used for the administration of Marek's vaccine at one day of age, manually with appropriate syringes or with the help of mechanical vaccinators, usually at the hatchery. It is suitable for the administration of live Marek's vaccines, serotypes 1, 2 or 3, respectively,

Rispens CVI988, SB-1 or HVT (Herpesvirus of Turkey), alone or combined, native field strain vaccines or vectors, mainly the HVT vaccine strain, such as the vector vaccine vHVT-IBD (Marek & Gumboro disease), vHVT-ND (Marek & Newcastle disease), *etc.* This method may be used in the field for manual administration of inactivated adjuvanted vaccines, usually multivalent, with appropriate syringes or with the help of mechanical vaccinators, to future breeders for example.

INTRAMUSCULAR INJECTION

This method is most commonly used for the administration in the field of inactivated adjuvanted vaccines, usually multivalent, comprising several strains of various pathogens. Administered manually with appropriate syringes or with the help of mechanical vaccinators, it is suitable for inactivated multivalent vaccines used as a booster after priming birds with live vaccines earlier in life. For example, a common antigen combination includes Newcastle disease virus, infectious bronchitis virus as well as the egg drop syndrome virus. Most vaccines are formulated with oil emulsion adjuvant, but some are formulated with other adjuvants, such as aluminum hydroxide. Vaccination programs may be based on one single injection before the point of lay, or repeated injections, according to the epidemiological situation and disease challenge. For oil emulsion adjuvanted vaccines it is recommended to use the vaccine at minimum $+20^{\circ}\text{C}$ in order to prevent acute local reactions.

TRANSFIXION (SCARIFICATION; WING-WEB STAB)

Vaccination via the wing web is the most common method of administration of Fowlpox vaccines. A two-prong applicator (double needle) is used to ensure that the vaccine is released into the skin while the needle penetrates it (also known as transfixion). To optimize contact between the vaccine dose and the skin tissues, it is advisable to spread the wing with the underside facing up and to transfix the wing web vertically downwards. One week after vaccination it is advisable to examine the application site in a sample of vaccinated birds. A proper vaccination take will result in the observation of a small nodule (edema and scabbing) due to the local reaction caused by the vaccine.

Disease	Avian species affected or carriers	Vectors or carriers	Current geographic occurrence	Main means of transmission to humans	Probability of occurrence	Human symptoms	Chap.
VIRUS							
Avian influenza	All species	Fomites & pest	Worldwide	Contact, aerosol, dust	Very low to high	Conjunctivitis, influenza-like illness or severe pneumonia and death	II.18
Velogenic Newcastle disease	All species	Fomites & pest	Worldwide	Contact, aerosol, dust	Very low	Conjunctivitis	II.19
Eastern equine encephalitis	Pheasant, pigeon, turkey, duck, etc.	Mosquitoes		Mosquito bite	Low	Neurological disease Case fatality: 50-70%	II.39
Western equine encephalitis	Turkey, pheasant, etc.	Mosquitoes	North, Central and South America	Mosquito bite	Low	Subclinical, sometimes encephalitis	II.39
West Nile disease	Geese, partridge various feral birds, etc.	Mosquitoes	Worldwide	Mosquito bite Human to human	Low	Subclinical, sometimes encephalitis, hepatitis	II.39
Venezuelan equine encephalitis	Shorebirds and other feral species	Mosquitoes	Tropical areas of America	Mosquito bite	Very low, sometimes high	Influenza-like illness, sometimes encephalitis	II.39
Usutu virus	Feral species (<i>Passeriformes</i>)	Mosquitoes	Africa, Europa	Mosquito bite	Exceptional	Fever Encephalitis, hepatitis	II.39
Crimean-Congo hemorrhagic fever	Ostriches	Ticks	Asia, Africa, Middle East, eastern Europe	Ticks, contact with infected tissues (e.g., asymptomatic ostriches)	Exceptional	Hemorrhagic fever, mortality: 30%	II.39
Japanese encephalitis	Hérons, etc.	Mosquitoes	Asia, Australia	Mosquito bite	Moderate, sometimes high	Encephalitis	II.39
St Louis encephalitis	Sparrow, pigeon, etc.	Mosquitoes	North, Central and South America	Mosquito bite	Low	Encephalitis	II.39

Tabl.83.1: Some viral zoonoses involving domestic and wild birds.

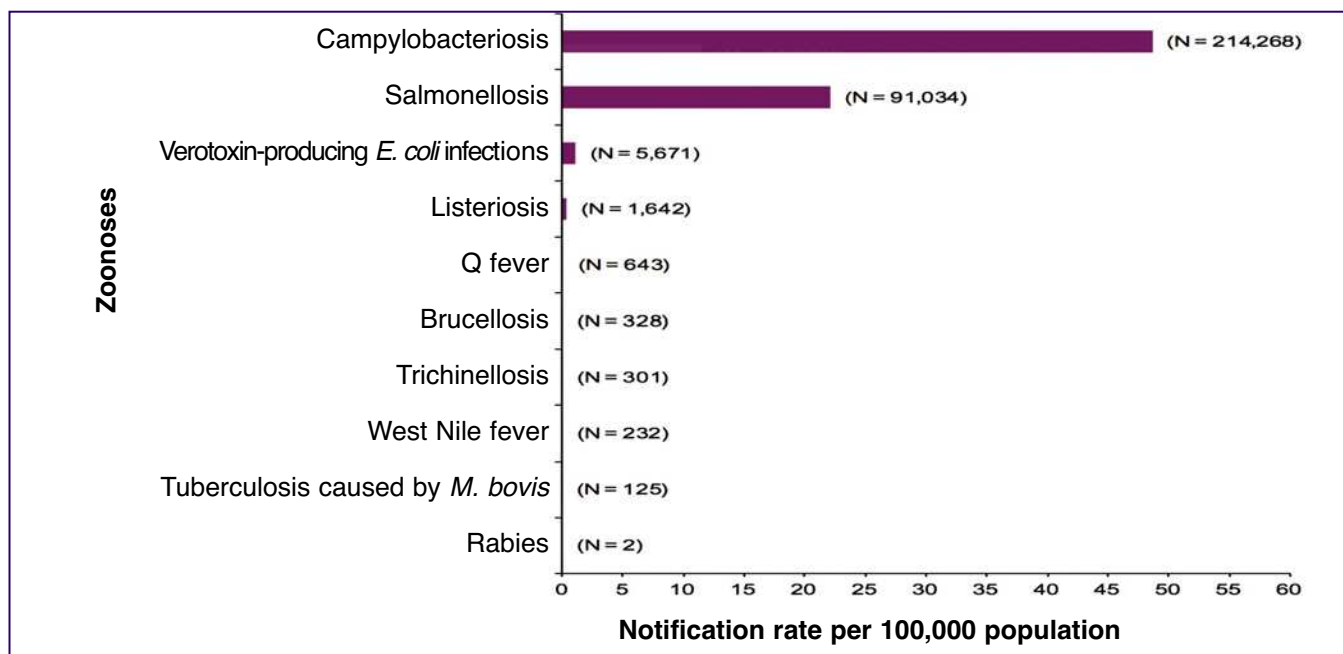


Fig.83.1: Reported notification rates of zoonoses in confirmed human cases in the EU, 2012 (EFSA & ECDC, 2014).

Health measures

83. AVIAN ZONOSSES

INTRODUCTION

Avian zoonoses are caused by many different pathogens, whether it be viruses, bacteria (or toxins thereof), fungal or parasitic diseases. The risk of transmission from bird to human of a pathogen is present at all stages from farm to fork but some pathogens are especially known for indirect transmission via contaminated eggs or meat. Avian zoonoses can also be linked to direct human contact with birds or via vector-borne transmission, particularly by means of mosquitoes or ticks but also through various vectors present in poultry (bloodsucking arthropods and pests).

Other human conditions with an immunological origin are also recognized. This is the case of hypersensitivity pneumonitis (HP), also known as extrinsic allergic alveolitis. It is a complex condition varying in intensity, with multiple clinical presentations. HP is mostly seen in pigeon-keepers. It is the result of an immunologically induced inflammation of the lung parenchyma in response to the inhalation of a large variety of antigens. Avian antigens are typically found in droppings, feathers, or serum of pigeons, parakeets, budgerigars, canaries, chickens, ducks, and turkeys. The prevalence and incidence of HP in the general population is low.

The zoonotic diseases (confirmed or suspected) will be covered based on the etiological agent involved (virus, bacterium, fungus or parasite).

VIRAL ZONOSSES

For many years, Newcastle disease was the most well-known viral zoonosis linked to poultry, until the emergence of the highly pathogenic influenza A virus subtype H5N1 (HPAI H5N1) disease in Asia. Other zoonotic viruses do exist but they are often encountered in wild birds and are transmitted to humans via vectors.

Orthomyxovirus: highly pathogenic avian influenza virus (fowl plague)

Prior to 1997, when human cases related to H5N1 avian influenza were reported in Hong Kong (18 cases, including 6 deaths), only the swine flu had been considered zoonotic. We now know that there is a risk of zoonosis with highly pathogenic avian influenza subtypes H5N1 (referred to by the media as «bird Flu»), H9N2 and H7N7 strains. Generally, clinical signs include conjunctivitis but some fatal

cases have been reported since 2003, particularly in Asia. However, contrary to the prediction of the World Health Organization (WHO) of a pandemic caused by this virus, human cases have remained sporadic as the virus has not adapted to permit rapid diffusion from human to human. From 2003 to January 2014, 650 human cases, including 386 deaths, were linked to influenza A H5N1, mainly in countries where sanitary conditions allow for close contact between humans and birds. More recently, a second outbreak occurred in China, this time with influenza A H7N9. It is not highly pathogenic for birds but caused 265 human cases with 57 deaths between February 2013 and January 2014. Even though wild birds are reservoirs of the virus, human contamination was mainly associated with live poultry markets.

Paramyxovirus: Newcastle disease (ND) or pseudo fowl plague

This is a minor zoonosis. While the velogenic ND virus is responsible for a high mortality rate in poultry, humans will generally present with mild respiratory flu-like symptoms and conjunctivitis (see Chap.II.19).

Alphavirus

Zoonotic alphaviruses are transmitted by mosquitoes. The survival of the viruses in specific geographic regions depends on the presence of the vectors and of vertebrates that will often develop benign viremic infections. Good examples are the Eastern and Western equine encephalitis viruses infecting wild birds on the American continent.

Flavivirus

These viruses are transmitted by mosquitoes or ticks.

Flavivirus transmitted by ticks

Zoonoses caused by flaviviruses that are transmitted by ticks include ovine encephalomyelitis (or louping-ill), primarily seen in the United Kingdom, and the tick-borne encephalitis found in Europe where wild birds act as asymptomatic reservoirs. In the case of louping-ill in sheep, the reservoir mainly consists of the Scottish grouse (*Lagopus lagopus scoticus*). Human infections are rare and most often observed in cases of laboratory or slaughterhouse contamination rather than in rural areas.

Disease	Avian species affected or carriers	Vectors or carriers	Current geographic occurrence	Main means of transmission to humans	Probability of occurrence	Human symptoms	Chap.
BACTERIA							
Chlamydiosis	Turkey, duck, psittacines, pigeons, <i>etc.</i>	-	Worldwide	Aerosol, dust, contact	Low sometimes high	Influenza-like illness, pneumonia, encephalitis, death	III.40
Salmonellosis	All species	Fomites & pest	Worldwide	Oral route Consumption of contaminated foodstuffs Contact	Variable according to risk factors	Gastroenteritis Complications: systemic infections	III.43 III.44 V.76
<i>Escherichia coli</i> STEC O157	Wild birds (Rook bird, gulls)	Fomites & pest	Worldwide	Oral route Consumption of contaminated foodstuffs Contact	Rare	Bloody diarrhea	III.45 V.76
<i>Escherichia coli</i> APEC	All species	Fomites & pest	Worldwide	?	Rare	Urinary infections	III.45
Clostridiosis <i>C. perfringens</i>	All species	Fomites	Worldwide	Oral route Consumption of contaminated foodstuffs	Low	Nausea, diarrhea, cramps, gas formation with distension of bowel	III.51 V.76
Botulism	All species	Fomites	Worldwide	Oral route (ingestion of toxin) Consumption of contaminated foodstuffs	Rare	Nausea, vomiting, sometimes constipation followed by toxic effects on the central nervous system	III.52
<i>Campylobacter</i>	All species	Fomites & pest	Worldwide	Oral route Consumption of contaminated foodstuffs	High	Nausea, vomiting, acute enteritis	III.53 V.76
Tuberculosis <i>Mycobacterium avium</i> complex	All species	Fomites & pest	Worldwide	Aerosol, oral route Predisposing factor: immaturity of immune system	Exceptional	Lymphadenitis Pneumonia	III.54
Erysipeloid	All species	Fomites & pest	Worldwide	Direct contact	Low	Erythematous cutaneous lesion (usually on hands) Endocarditis (rare)	III.55
<i>Staphylococcus aureus</i>	All species	Fomites & pest	Worldwide	Oral route (ingestion of toxin) Consumption of contaminated foodstuffs	High	Nausea, vomiting, gastroenteritis	III.57 V.76
Yersiniosis	All species	Fomites & pest	Worldwide	Oral route Consumption of contaminated foodstuffs Contact (sapronose)	Exceptional	Enteritis or enterocolitis	III.57
Listeriosis	All species	Fomites & pest	Worldwide	Oral route Consumption of contaminated foodstuffs Contact (sapronose)	Low	Abortion, neonatal septicemia, encephalitis skin lesions	III.61 V.76
FUNGI							
Dermatophytosis	Chicken	Fomites	Worldwide	Contact	Moderate	Cutaneous lesion (favus)	IV.40
PARASITES							
Cryptosporidiosis	Turkey	Fomites	Worldwide	Oral route Foodborne	Moderate	Watery diarrhea, epigastric pain, nausea	IV.65

Tabl.83.2: Some bacterial, fungal and parasitic zoonoses involving domestic and wild birds.

Flavivirus transmitted by mosquitoes

Birds are the most important vertebrate hosts in this group of viruses. Pigs, in the case of Japanese encephalitis, and horses may also play the role of host and can contract the disease.

In comparison with alphaviruses, flaviviruses are associated with a greater diversity of hosts. For example, the persistence of the Murray Valley encephalitis virus and Kujin virus disease, both reported in Australia, are linked to viral replication in herons and pelicans. Another example is Japanese encephalitis (JE), which also replicates in herons but may use pigs as an amplification host. Japanese encephalitis is therefore far less common in Muslim countries. The main vector for JE is *Culex tritaeniorhynchus*, which propagates in rice fields. It has been reported that its larvae develops much faster and in greater numbers in rice fields fertilized with nitrogen compounds as opposed to unfertilized fields. This may be a factor in the increased spread of JE throughout India and Indochina.

In the case of St. Louis encephalitis, the most important arboviral disease in North America, sparrows and pigeons are the main reservoirs.

West Nile virus (WNV) is particularly noteworthy for the abnormally high rate of mortality in crows at the Bronx Zoo in 1999. This initial incident is at the origin of a widespread human infection now present in North America and has raised awareness amongst epidemiologists of the importance of mass mortality in birds. An increase in crow mortality due to the Usutu virus of African origin was later observed in Vienna (Austria) in 2001 and drew attention to the possible zoonotic risk of this virus (this zoonotic risk is now suspected in Europe).

In human flavivirus infections, transmission from direct contact between humans does not occur. However, virus transmission via blood transfusions, blood products, or through organ transplantation and breast-feeding has been observed with WNV.

BACTERIAL ZONoses

A bacterial zoonosis can be an infection with bacterial multiplication and/or the effects of a bacterial toxin. Some bacteria are traditionally regarded as zoonotic (for example, listeriosis and enteric yersiniosis), but are also present in the environment and are not necessarily directly transmitted from animals to humans; therefore such infections are also classified as “sapronoses” or “saprozoonoses”.

Avian chlamydiosis (psittacosis)

Infection due to *Chlamydia psittaci* is of special significance for humans because of the possible severity of the disease. Psittacosis is characterized by fever, chills, headaches, photophobia, interstitial pneumonia, coughing and myalgia. The clinical picture varies from inapparent infection to a severe pneumonia that may be accompanied by complications such as myocarditis or encephalitis that can lead to death.

Salmonellosis

Human salmonellosis is usually the result of food contamination rather than a direct contact with birds. Some human infections can be asymptomatic. In most human cases, symptoms appear 4 to 7 days after ingestion of *Salmonella* spp. Clinical signs include abdominal cramps, headaches, fever, nausea, vomiting and profuse watery diarrhea. Occasionally the symptoms can be severe enough that hospitalization is indicated. Only rarely do serious complications or death result from the infection. Other clinical signs can be observed when systemic infections occur affecting systems other than gastrointestinal tract (arthritis, hepatitis, encephalitis).

Colibacillosis

Poultry, especially pigeons in certain geographic areas, are a natural reservoir for Shigatoxin producing *Escherichia coli* (STEC), a potential public health hazard. The colonization of chickens, turkeys and wild birds (free-living waterfowl, crows) with STEC O157:H7 has been reported in different geographic areas. However, poultry is not a significant source of STEC in human disease. Only one report has linked a human contamination by this important enterohemorrhagic pathogen to crows.

Most avian pathogenic *E. coli* (APEC) isolated from poultry are specific clonal types that are only pathogenic for birds and represent a low risk of disease for people or other animals. However, APEC often share multiple virulence factors with uropathogenic *E. coli* that are commonly found in humans, suggesting that poultry products can be a source of *E. coli* in people.

Clostridiosis

Clostridium perfringens type A and type C produce enterotoxins that cause foodborne illnesses in humans. Outbreaks of *Clostridium perfringens*

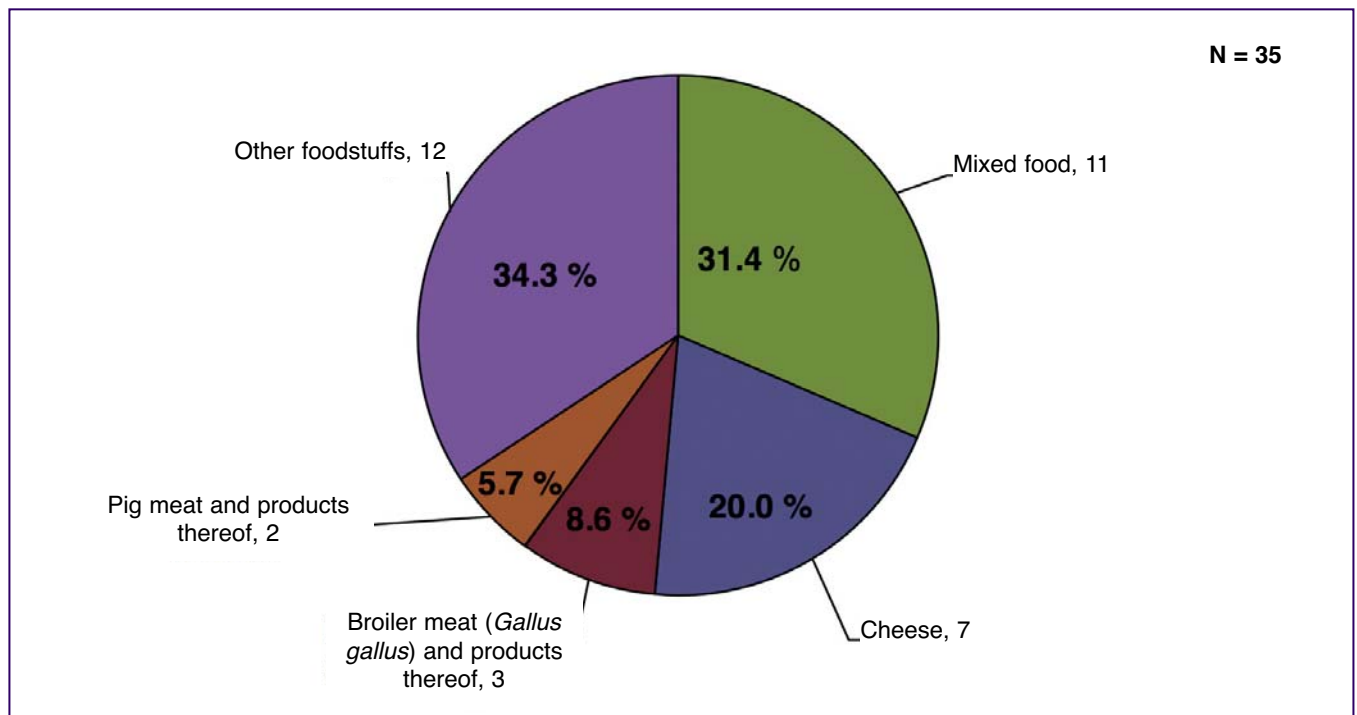


Fig.83.2 : Distribution of food vehicles in strong-evidence outbreaks caused by staphylococcal toxins in the EU, 2012 (EFSA & ECDC, 2014).

Data from 35 outbreaks are included: Belgium (4), Denmark (1), Finland (1), France (9), Germany (3), Poland (3), Portugal (2), Romania (1) and Spain (11).

Other foodstuffs (N = 12) include: bovine meat and products thereof (1), buffet meals (1), crustaceans, shellfish, molluscs and products thereof (1), eggs and egg products (1), meat and product thereof, unspecified (1), milk (1), other or mixed red meat and products thereof (1), poultry meat and products thereof (1) and other foods (4).

Number after the label refers to the number of outbreaks.

type A food poisoning have been traced to the consumption of chicken and high percentages of *C. perfringens*-positive carcasses have been reported.

Botulism, due to *Clostridium botulinum*, is a food-borne disease that is rarely associated with poultry products. The most common food-related outbreaks of botulism are linked to home canning or other canned foods tainted with the bacteria. Clinical signs include variable degrees of flaccid paralysis.

***Campylobacter* spp.**

Campylobacteriosis has been the most frequently reported zoonotic disease in humans in the European Union since 2005 and broiler meat is considered to be the main food-borne source of human campylobacteriosis.

Tuberculosis (*Mycobacterium avium* complex)

Members of the *Mycobacterium avium* complex (MAC) are ubiquitous bacteria that can be found in water, food, and in the environment. They are considered opportunistic pathogens for numerous

animal species including humans, but mainly birds and pigs. Infections caused by the MAC are on the rise in both human and veterinary medicine. Avian tuberculosis is an important disease that affects pet birds, captive exotic birds, wild and domestic birds. It has public health significance, but human infection is likely through a common source to both pigs and humans and appears to be due to human-to-human or human-to-environment contact rather than bird-to-human contact.

Birds can be reservoirs of *Mycobacterium avium* subsp. *paratuberculosis*, which is suspected to be associated with Crohn's disease in humans.

Erysipeloid

Erysipeloid, caused by *Erysipelothrix rhusiopathiae*, in humans is an occupational disease affecting butchers, veterinarians, animal caretakers, etc.

Staphylococcosis

Staphylococcus aureus produces enterotoxins that cause food poisoning in humans. *Staphylococcus aureus* strains found on poultry carcasses can be

endemic strains or may be transmitted from the hands of the workers. Methicillin-resistant *S. aureus* (MRSA) also may be of concern in chicken meat.

Yersiniosis

Yersiniosis is a sapronosis transmitted by consumption of infected food. Contact infection is also possible.

Listeriosis

Listeriosis is a sapronosis that can be a foodborne illness. Direct contact with diseased animals can also lead to infection.

Other bacterial zoonoses

Some other bacterial zoonoses can affect many animal species including birds, but poultry is generally not associated with human contamination: anthrax, Q fever, Lyme disease, pasteurellosis, tularemia.

FUNGAL ZONOOSES: dermatophytoses

Microsporum spp. infections occur worldwide. In rare cases, human transmission of *Microsporum gallinae* or *Trichophyton simii* from chickens has been observed.

PARASITIC ZONOOSES

Parasitic zoonoses are some of the most important human diseases worldwide. They are caused by protozoa, helminths and arthropods. Arthropods play an additional important role as vectors of viruses, rickettsiae, bacteria, protozoa, and helminths.

Zoonoses caused by protozoa

Birds can be hosts of triatomine bugs (type of reduviid bug) that carry *Trypanosoma cruzi*, the parasite that causes Chagas disease. Birds can also be nonhuman hosts of microsporidia, which could potentially be zoonotic, such as *Encephalitozoon intestinalis* (bird host: ducks) or *E. hellem* (bird host: psittacines).

Cryptosporidiosis. Although human cryptosporidiosis is a zoonosis, there is no evidence that suggests that *Cryptosporidium baileyi*, the avian species, is the cause of infection in non-avian

species. Similarly, *C. parvum*, a predominant human pathogen is not known to cause disease in poultry. However, *C. meleagridis* appears to be identical to *C. parvum*.

Zoonoses caused by trematodes

Zoonotic cercarial dermatitis, due to cercariae, is mainly caused by the causal agent of duck bilharziosis, *Trichobilharzia szidati*, to which snails serve as the intermediate host. This disease is prevalent worldwide. Humans can become accidental hosts when bathing or working. Repeated exposure to cercariae may lead to clinical signs such as severe itching, papules or lumps several millimeters in diameter, and erythema.

Zoonoses caused by arthropods

Zoonoses caused by fleas

Fleas, temporary ectoparasites of humans and animals are vectors of diseases. Fleas are found throughout the world. *Ceratophyllus gallinae*, the chicken flea, or *Echidnophaga gallinacean*, a relatively pathogenic flea found in tropical and subtropical regions in young birds, can parasitize humans.

Poultry red mite (*Dermanyssus gallinae*)

This parasite can also attack poultry growers, causing a pruritic dermatitis or allergic reaction with eczema.

REFERENCES

- Dhama K et al. Tuberculosis in Birds: Insights into the *Mycobacterium avium* infections. *Vet med Int*, 2011, doi: 10.4061/2011/712369.
- Diseases of Poultry*. Ed. Swayne DE et al, Wiley-Blackwell Publ. Iowa 2013.
- EFSA (European Food Safety Authority) and ECDC (European Centre for Disease Prevention and Control), 2014. *The European Union Summary Report on Trends and Sources of Zoonoses, Zoonotic Agents and Food-borne Outbreaks in 2012*. EFSA Journal 2014;12(2):3547, 312 pp. doi:10.2903/j.efsa.2014.3547.
- Ejidokun OO et al. Human Vero cytotoxigenic *Escherichia coli* (VTEC) O157 infection linked to birds. *Epidemiol Infect*, 2006; 134:421-423.
- Krauss H et al. *Zoonoses. Infectious diseases transmissible from animals to humans*. Ed. American Society for microbiology, Washington D.C.2003, pp 456.



Fig.84.1: Muscovy ducklings.



Fig.84.2: Muscovy duck. Feathers and bird performances vary depending on the breeding strain.



Fig.84.3: Muscovy duck.



Fig.84.4 & 84.5: Pekin ducks. Ducklings and adults.



Birds/m ²	Muscovy duck		Pekin duck	Mule duck
	Male	Female		
Slatted floor	10	15	10 to 12	6 to 10*
Litter	6	10	5 to 6	3 to 6*

Tabl.84.1. Floor density for Muscovy ducks and Pekin ducks according to the type of flooring.

*With free-range

Age (in days)	Temperatures					
	Muscovy duck		Pekin duck		Mule duck	
	Under radiant	House	Under radiant	House	Under radiant	House
1 to 3	40 - 45°C	30°C	32 - 35°C	27°C	38 - 40°C	25°C
4 to 7	38 - 42°C	29°C	30 - 32°C	23°C	30 - 32°C	23°C
7 to 14	36 - 38°C	27°C	25 - 30°C	20°C	28 - 30°C	21°C
14 to 21	35 - 37°C	25°C	20 - 22°C	18°C	24 - 26°C	19°C
21 to 28	38 - 42°C	22°C	Depending on the season	15°C	20 - 22°C	17°C
28 +	Depending on the season	18 - 22°C			Depending on the season	15°C

Tabl.84.2: Recommended temperatures according to age, duck species and location [under the heat source; house (ambient temperature)].

Other species

84. DUCK BREEDING

INTRODUCTION

In duck production, there are significant differences depending on the species, the environmental conditions where birds are raised, the production objectives and even welfare concerns such as the practice of beak trimming. Therefore, this chapter provides species-specific standards for Pekin (*Anas platyrhynchos*) and Muscovy (*Cairina moschata*) ducks, as well as for the sterile progeny, the mule duck, that comes from crossing these two species. Of course, this short text cannot cover in details all aspects of these productions.

Zootechnical differences between domestic duck species justify management and growing conditions adjusted to each one of them:

- Muscovy ducks are originally from tropical forests and have retained strict ambient temperature requirements and a strong sexual dimorphism justifying a different slaughter age for male and female flocks (optimal age at slaughter: 9 to 10 weeks for females and 12 weeks for males).
- Pekin ducks are natives of colder regions. They are very active and grow very rapidly, requiring more floor space than other species. Both males and females are slaughtered between 42 and 49 days of age.

DENSITY

Muscovy and Pekin ducks produce very fluid droppings and have a propensity for playing with water. This limits acceptable flock densities when ducks are raised on litter. Alternatively, flocks may be grown on totally or partially slatted floors. Specific density data according to the type of flooring are shown in Tabl.83.1. As for mule ducks, high density production is inconceivable without free-range facilities.

Pens between 100 to 200 m² are required for the brooding period and are very useful beyond this period, especially for Pekin ducks and mule ducks.

BROODING

Like for any other poultry, brooding must be done only in facilities that have previously been cleaned

and disinfected. Special attention should be paid to the cleaning of slatted floors. Another consideration regarding the choice of disinfectant is the possible presence of parvoviruses, a pathogen that is very resistant in the environment.

Brooding is a critical phase of production that will greatly influence flock performance results. Each bird must have access to sufficient feed and drinking water under adequate ambient temperature conditions. Ducks in general (and Muscovy ducks in particular) are extremely sensitive to temperature conditions during the first days of life.

Adding small feeding stations (small amount of feed placed on paper directly on the floor) is very useful. These are filled-up regularly throughout the day. The noise that paper makes when ducks are walking on it stimulates their interest and contributes to early feed consumption. Slatted floor facilities are less forgiving than traditional production on litter because slatted floors exacerbate adverse factors such as inadequate temperature and excessive air speed.

Providing a sufficient quantity of good quality drinking water is paramount. Without considering water wastage, it is estimated that ducks consume about 1.5 to 2 times more water than chickens. Any failure to provide adequate drinking water will lead to many cases of nephritis. Waterfowl are particularly sensitive to this condition.

The following are key management parameters:

- 1 radiant of 3000 thermies for 300 to 400 birds [The thermie is equivalent to 3968.3 British thermal unit (BTU)];
- 1 drinking station per 50 birds;
- 1 feeding trough per 50 birds.

TEMPERATURE

Ambient temperature should be gradually reduced according to the time schedule found in Tabl.83.2. Waterfowl being aquatic birds, feathering begins in the abdominal area. Furthermore, it occurs about two weeks later than in chickens. These two factors make ducks extremely sensitive to chilling conditions.

Age	Intensity	Program
First week	60 to 80 lux	All day
2 & 3 weeks	30 lux	Progressive decrease from 24 to 16 hours per day
> 4 weeks	10 lux	10h night, 14h light

Tabl.84.3: Lighting program. For the Muscovy duck, an alternating program improves bird performance (weight - index). It can be set up from two weeks of age by introducing a two-hour period of darkness to reach 6 sequences of two hours of darkness followed by two hours of light.

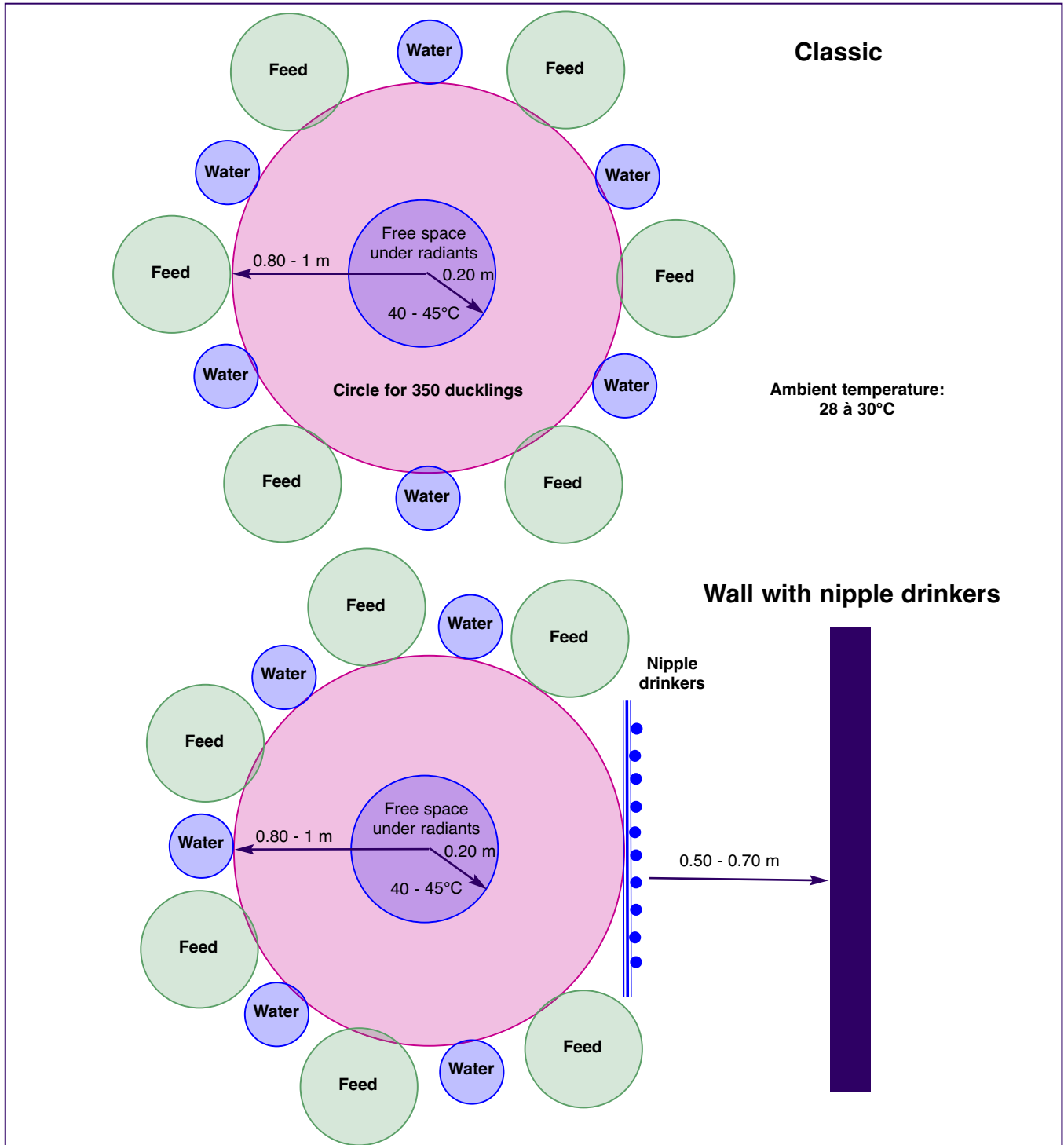


Fig.84.6. Brooding installation diagram: classic or with nipple drinkers (according to document Grimaud Frères)

Section VI

VENTILATION

As early as the first week of production, ventilation is increasingly important to control air humidity and ammonia levels. The quality of the litter is also essential to prevent damage to the webbed feet of ducks, which are more sensitive than the footpads of other birds. The damage to the respiratory system and the negative impact on feed consumption caused by excess ammonia levels have been well described in poultry. Conjunctivitis is also frequently observed, particularly in Pekin ducks.

FEED

Without going into specific details regarding feed composition for each species, it should be noted that feed texture is very important. Crumbs are used for the first few weeks of brooding followed by pelleted feed. The wrong feed texture can have a negative impact on feed conversion, mainly due to wastage. The feeding system should be able to prevent overflowing of feed in the feeding troughs (feeders), by maintaining a good distance between the edge of the trough and the feed level. Feeders will be allowed to get completely empty at least once a week in order to prevent the accumulation of flour at their bottom.

LIGHTING PROGRAM (see Tabl.84.3)

BEAK AND TOE TRIMMING

Beak and toe trimming are intended to limit pecking and scratching that have a negative impact on bird welfare and on carcass quality. The approach used will depend on the species, the type of production and bird density. Transportation conditions will also strongly influence the percentage of scratches observed in a flock. Beak trimming is traditionally carried out between 15 and 20 days of age but it can be advantageously replaced by infrared treatment at one day of age in the hatchery. Toe trimming may be done as early as 10 days but it can be delayed so that beak and toe trimming can be performed on the same day.

These procedures must be performed in a calm, stress-free environment with clean, disinfected and sharp equipment. The beak is trimmed in the middle of the culmen (the upper ridge of the duck's bill at the center of the upper mandible). Toe trimming is performed one toe at a time while making sure to preserve the integrity of the toes.



Girmaud Frères



D Balloy - Réseau Cristal

Fig.84.7: Mule ducks. The mule duck is the result of a cross between a male Muscovy duck and a female Peking duck.

Fig.84.8: Flock of Mule ducks.



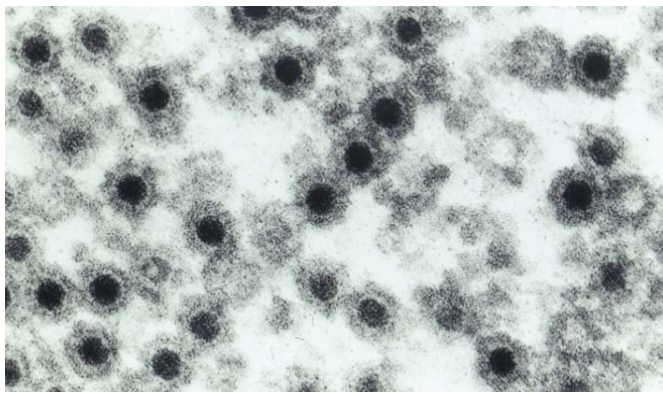
Girmaud Frères



Girmaud Frères

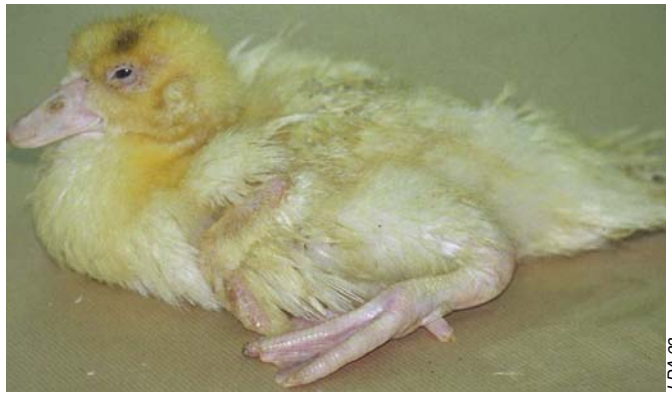Fig.84.9 & 84.10: Control of the environment, feed and drinking water is essential to achieve a good start.

Fig.84.11: Future duck breeders.



Mérial

Fig.85.1: Reovirus. Electronic microscope observation.

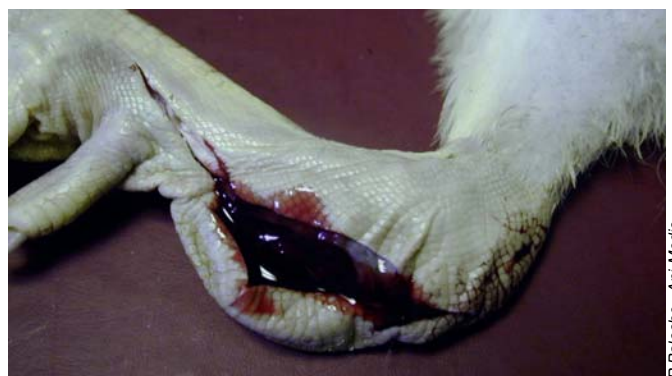

LDA 22

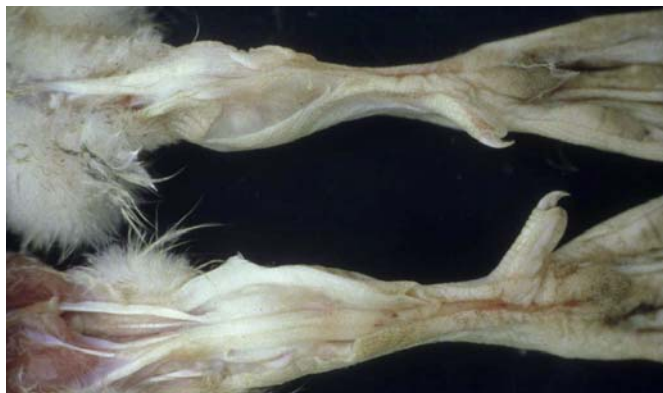Fig.85.2: Duck reovirus. Sick duckling with locomotor disorders.



P Baloché - Ani-Medic

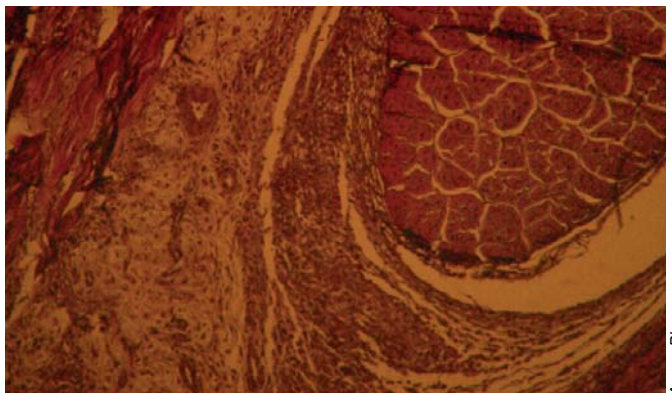


P Baloché - Ani-Medic



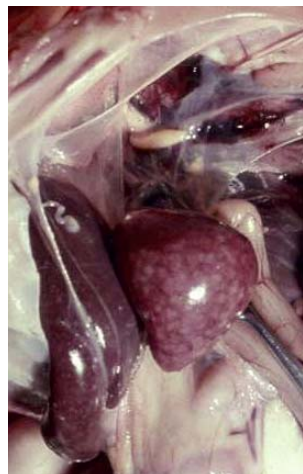LDA 22

Fig.85.3, 85.4 & 85.5: Duck reovirus. Tenosynovitis. Marked swelling of the tendon sheaths.

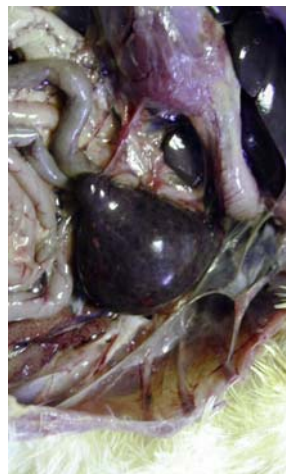

Anses Plougragan

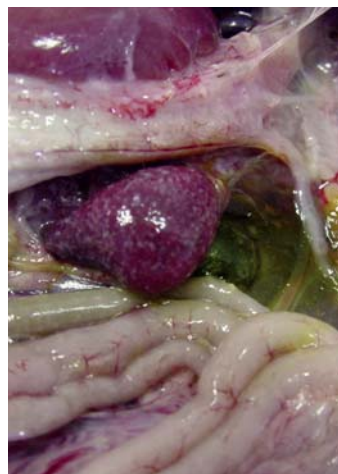
Fig.85.6: Duck reovirus. Microscopic appearance of necrotic foci in the spleen.



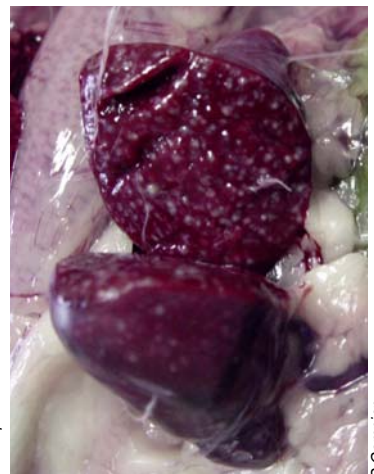Mérial



P Baloché - Ani-Medic



C Campion



C Campion

Fig.85.7, 85.8, 85.9 & 85.10: Duck reovirus. Splenomegaly and miliary foci of necrosis (also observed in the liver).

85. DUCK REOVIRUSIS

INTRODUCTION

Duck reovirus is a viral contagious disease which affects Muscovy ducks. Described for the first time in 1968, the causative agent, a reovirus, was characterized in 1972 by Gaudry. Reoviruses were first identified in 1970 among goslings affected by Derzsy's disease, a disease caused by a parvovirus. Derzsy's disease has long been confused with reovirus. This confusion was probably driven by physico-chemical similarities between the two viral agents and because they frequently co-infect ducks.

ETIOLOGY

The pathogen is an icosahedral non-enveloped reovirus, with a segmented genome comprising a double stranded RNA. Part of its genome has been sequenced. The serotypes and pathotypes are largely unknown. Pathogenicity is quite variable and is strain dependent. No antigenic difference has been shown by crossed seroneutralization between several isolates. Some antigenic similarities have been shown between duck and chicken reoviruses, using an agar gel immuno-diffusion or an enzyme linked immunosorbent assay (ELISA). However, these differences are not demonstrated by serum neutralization techniques. Protection tests against a duck reovirus strain using the chicken reovirus S1133 strain were largely unsuccessful. It was therefore concluded that the antigenic similarities were insufficient to enable cross-immunogenicity.

EPIDEMIOLOGY

The most susceptible waterfowl is undoubtedly the Muscovy duck. Although reoviruses have been isolated in geese and Pekin ducks, the disease has never been diagnosed in these two species. The disease is extremely prevalent in Muscovy duck production, with more than one in ten flocks being infected at certain times of the year.

Feces are the main source of contamination. Reoviruses are highly resistant to heat and in the

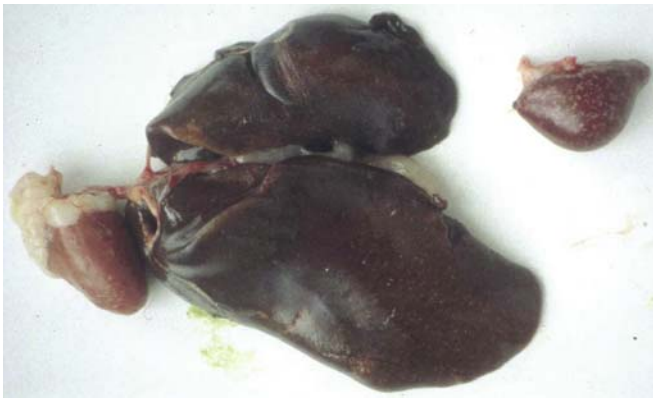external environment, which explains their persistence on contaminated farms. Direct or indirect horizontal transmission occurs by oral-nasal route or by inoculation during routine procedures such as declawing or beak trimming.

CLINICAL SIGNS & LESIONS

In Muscovy duck broilers, the disease progresses over a three to four day period and spreads rapidly to most ducks on affected flocks. Mortality is highly variable and depends on the virulence of the virus strain involved. An acute form occurs between two and three weeks of age, accompanied by respiratory signs (dyspnea, nasal discharge and coughing). Mortality is often elevated and may reach 40% in worst cases.

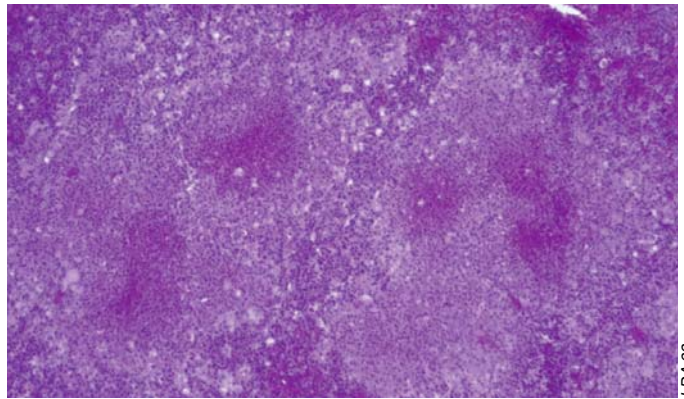
The sub-acute form of the disease is most common. It appears between two and five weeks of age. It is characterized by locomotor disorders, and occasionally respiratory problems (coughing, nasal discharge) as well as conjunctivitis and enteritis. Mortality can reach 5 to 10%. The chronic form occurs in ducklings between four and eight weeks of age, sometimes after an acute episode. Ducks are anorexic, quickly lose weight and have an impaired locomotion. The flock quickly becomes uneven. Convalescent ducks may show compensatory growth within two to three weeks, unlike in Derzsy's disease or parvovirus. A milder form of the disease exists in breeders and is manifested by a drop in egg production, sometimes accompanied by coughing and lameness, and possibly excess mortality.

The most characteristic macroscopic lesions are an enlarged and reactive spleen, dotted with lymphoid islets sometimes considered to be foci of necrosis, fibrinous lesions in the liver, air sacs, and occasionally fibrino-caseous lesions in the heart. In the case of reovirus infection alone, there is neither ascites nor pericardial effusion. Microscopic examination of tissues reveals inflammatory lesions with abundant mononuclear cell infiltrates localized mainly in the liver, spleen and tendons.



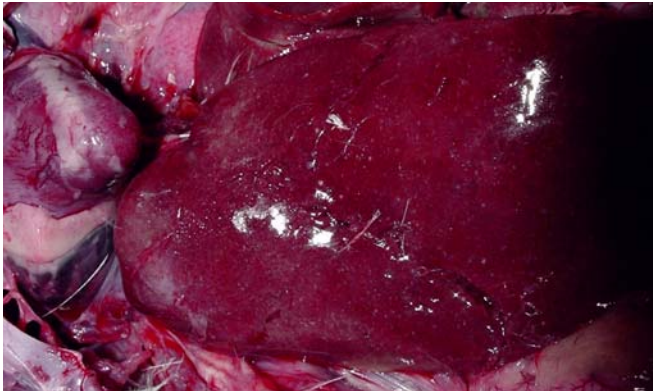
LDA 22

Fig.85.11: Duck reovirus. Miliary foci of necrosis in the spleen and the liver.



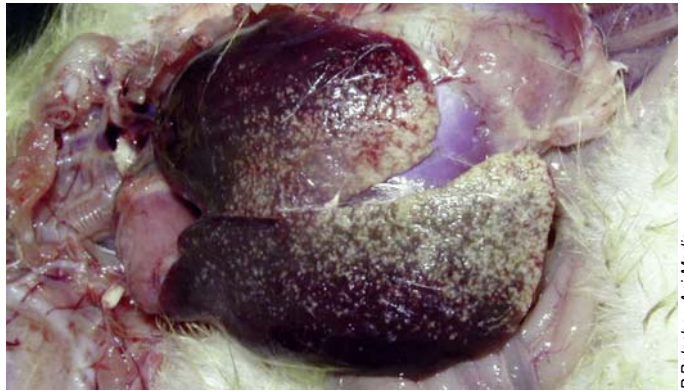
LDA 22

Fig.85.12: Duck reovirus. Necrotic foci in the spleen.



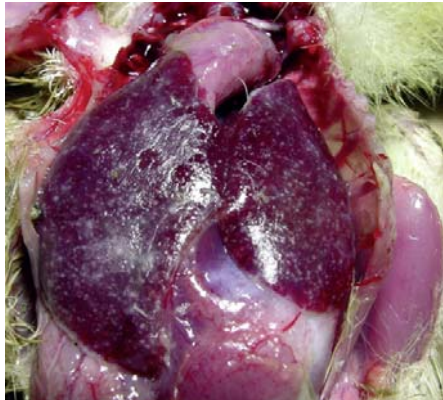Mérial

Fig.85.13: Duck reovirus. Hepatitis with miliary foci of necrosis.



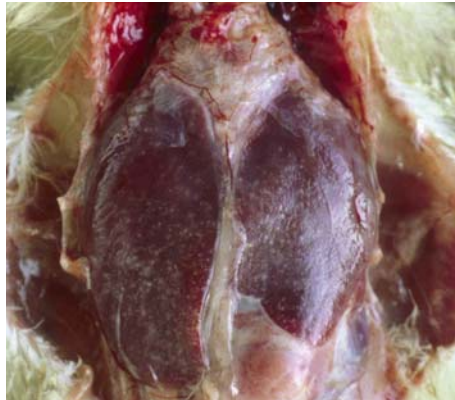P. Baloché - Ani-Medic

Fig.85.14: Duck reovirus. Hepatitis with miliary foci of necrosis and important perihepatitis.



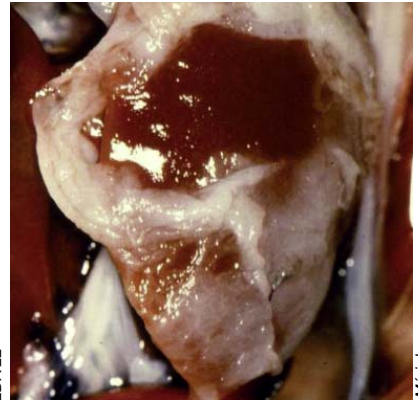
S. Warm

Fig.85.15: Duck reovirus. Pericarditis and perihepatitis.



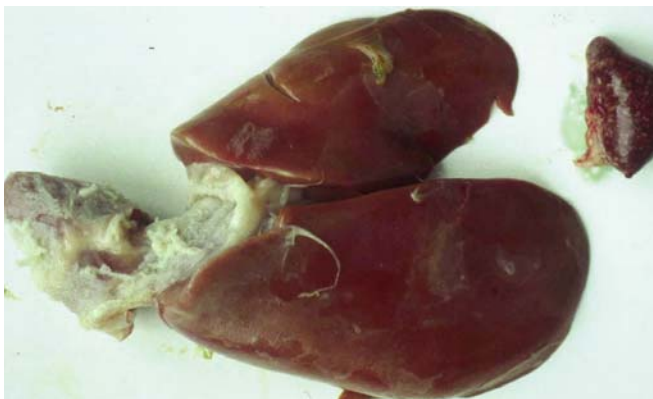LDA 22

Fig.85.16: Duck reovirus. Hepatitis with miliary foci of necrosis associated with perihepatitis and pericarditis.



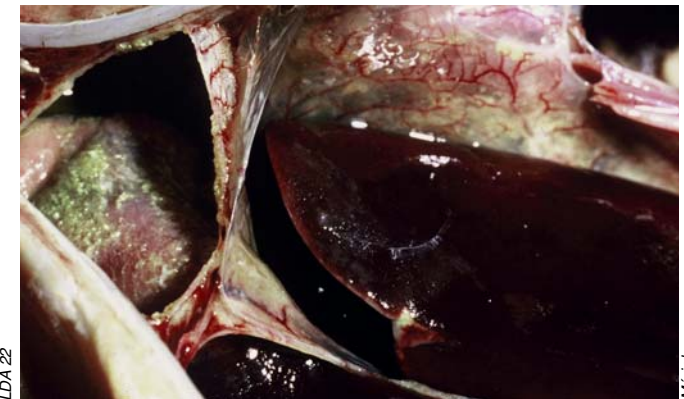
Mérial

Fig.85.17: Duck reovirus. Perihepatitis with the presence of a fibrinous plaque.



LDA 22

Fig.85.18: Duck reovirus. Perihepatitis, pericarditis and miliary foci of necrosis on spleen.



Mérial

Fig.85.19: Duck reovirus. Pericarditis, airsacculitis and perihepatitis.

DIAGNOSIS

Clinical diagnosis is sometimes difficult because of possible confusion with Derzsy's disease or Muscovy duck parvovirus.

Various laboratory tests are necessary to confirm the diagnosis: virus isolation in the viscera, in eggs or in duck embryo cells and identification by an immunofluorescence test; serological examination by agar gel immunodiffusion (not done routinely), or using an ELISA test adapted to ducks but which is difficult to interpret.

Histological examination, particularly of skeletal muscles, heart and tendons, helps confirm the etiology (see Chap. VI.86 on duck parvovirus). Lesions of tenosynovitis and pericarditis are suggestive of reovirus, while lesions of degenerative myopathy point more towards parvovirus. Considering that some gene sequencing has already been done for this virus, molecular biology techniques would enable the development of probes that would make the histological diagnosis more specific.

TREATMENT & CONTROL

There is no specific antiviral therapy. Supportive therapy to reduce mortality is recommended. Antibiotics can sometimes be used against bacterial co-infections.

Convalescent ducks acquire a solid immunity that protects them against reinfection. There is no commercial vaccine available at the moment. Indeed, many attempts at developing traditional vaccines, either live attenuated or inactivated, have been unsuccessful. For the time being, emphasis should be on farm sanitation, in particular, care should be taken during operations such as beak trimming and declawing, in order to minimize the spread of reovirus.

REFERENCES

- Gaudry D et al. A propos d'un nouveau virus isolé chez le canard de barbarie. *Bull Soc Sci Vét Méd Comp Lyon*, 1972,74:137-143.
- Heffels-Redmann U. et al. Structural and biological characteristic of reoviruses isolated from Muscovy ducks. *Avian Path*, 1992,21:481-491.
- Kuntz-Simon G et al., Muscovy duck reovirus sigmaC protein is atypically encoded by the smallest genome segment. *J Gen Virol*, 2002,83:1189-1200.
- Marius-Jestin V et al. Histology data associated with Muscovy duck reovirus infection. *Vet Rec*, 1988,123:32-33.
- Marius-Jestin V. Les techniques ELISA appliquées au diagnostic aviaire. Mise au point d'une technique ELISA pour le diagnostic de la réovirose du canard de Barbarie. *L'Aviculteur*, 1982,423:87-89.

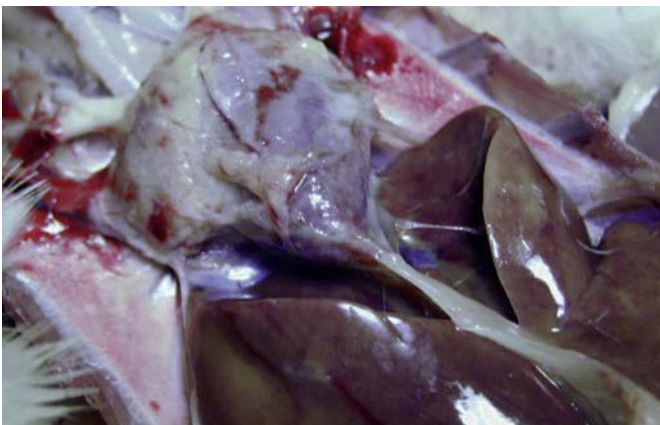

Fig.85.20: Duck reovirus. Pericarditis.

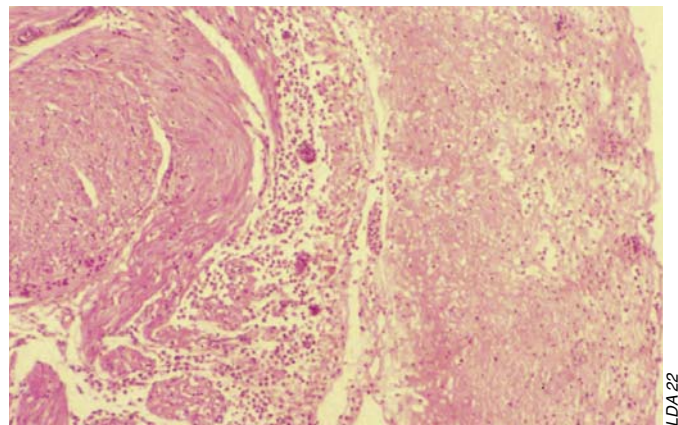
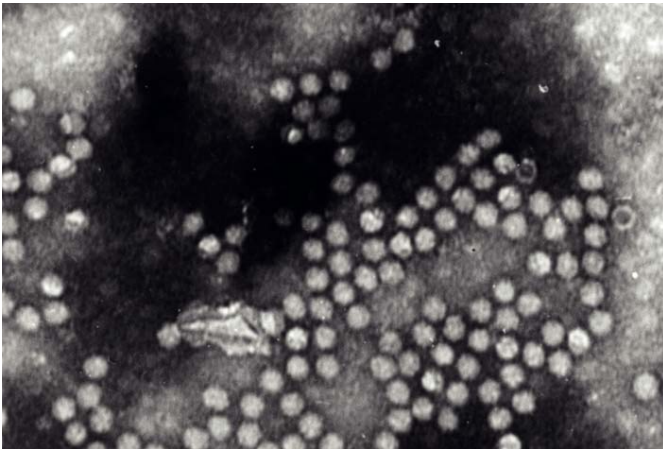


Fig.85.21: Duck reovirus. Microscopic appearance of pericarditis (hematoxylin & eosin, x100).



ANSES Ploufragan

Fig.86.1: Duck parvovirus (electron microscopy). Duck parvoviruses are particularly resistant. Given this level of resistance, the very high degree of viral excretion into the environment by infected birds, and the highly contagious nature of the virus, extremely rigorous preventive measures are needed to mitigate the risk of indirect horizontal transmission.



P. Baloche - Anti-Medic

Fig.86.2: Duck parvovirus. In the acute or peracute form, the farmer is first alerted by a general prostration of the flock and by a sudden increase in mortality, which generally occurs in the first few days of the onset of the disease. The prostrated birds have a characteristic posture, with moving and breathing difficulties. Diarrhea is also noted.



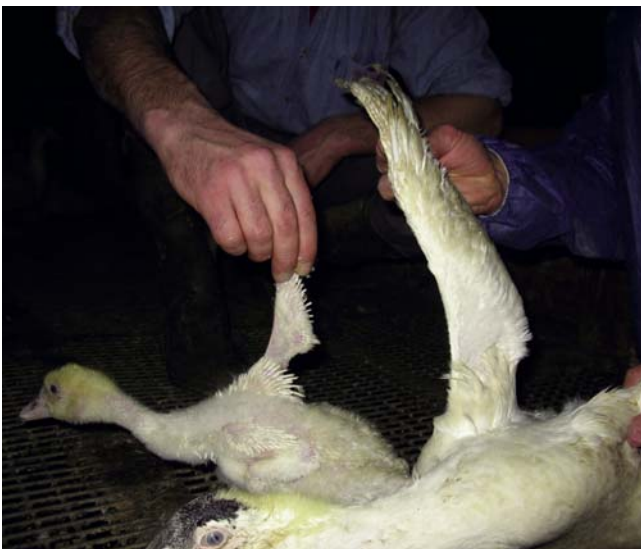JY Ferré



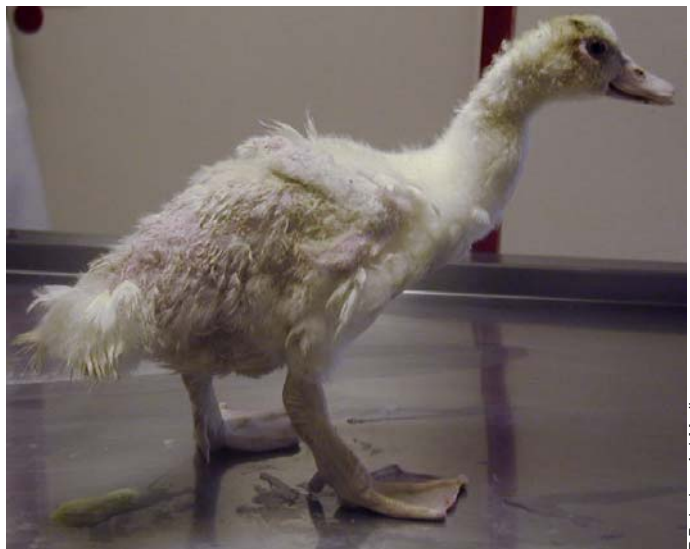JY Ferré



P. Baloche - Anti-Medic



JY Ferré



P. Baloche - Anti-Medic

Fig.86.3, 86.4, 86.5, 86.6 & 86.7: Muscovy duck parvovirus. In the chronic form, the surviving ducks show slowed or even stunted growth (dwarfism). Some have broken and hanging wings and display abnormal posture (lying down with paralyzed legs stretched out behind them) and are poorly feathered. When only the chronic form of the disease is observed (ducks with a certain level of maternal antibodies or first infected at over 4 weeks of age), the heterogeneity of the flock is spectacular, with normal birds alongside cachectic poorly feathered ones.

Other species

86. DUCK PARVOVIROSIS

INTRODUCTION

Duck parvovirus is a contagious viral disease. It first appeared in Muscovy duck farms in Brittany in 1989. It then spread to other duck-rearing regions in the western part of France, causing considerable economic losses for all those involved in this production (high mortality rates, culling of entire flocks, condemnations, reduced yields, unworked days in slaughterhouses, *etc.*). In France, the disease has been controlled using a vaccination program. Since then, duck parvovirus has also been described in Asia and America in the 1990s.

ETIOLOGY

The causal agent is a parvovirus: a small-sized non-enveloped virus measuring about 20 nm, with single-stranded DNA. Phylogenetically, it is close to the parvovirus responsible for Derzsy's disease which infects geese and ducks. However, it presents well-characterized genetic differences within the gene encoding the capsid protein VP2. This protein can be used for differential diagnosis by a gene-sequencing amplification technique and by restriction fragment length polymorphism analysis. The pathogenicity of the first isolated viruses was neutralized by a hyperimmune serum from Derzsy's disease. The antibodies present in ducks infected with the parvovirus were also detected using an antigen prepared from a strain of Derzsy's disease virus, and a vaccine against Derzsy's disease prevented, under experimental conditions, mortalities related to the new parvoviruses. Based on this evidence, parvoviruses associated with duck parvovirus were initially considered to be the same as those of Derzsy's disease. Subsequently, because of differences in cross-reactions between the Derzsy's disease viruses and the new parvoviruses, given the host spectrum of these new viruses restricted to Muscovy ducks and their extreme pathogenicity and very high infectious titers (compared to Derzsy's disease viruses), it was considered preferable to differentiate these new viruses by calling them «duck parvoviruses» (DPV). The different strains of DPV isolated in the world are very homogeneous in their genetic and phenotypic characteristics.

Duck parvoviruses are particularly resistant. Given this level of resistance, the very high degree of viral excretion into the environment by infected birds, and the highly contagious nature of the virus,

extremely rigorous preventive measures are needed to mitigate the risk of indirect horizontal transmission.

EPIDEMIOLOGY

Muscovy ducklings less than 5 weeks of age are susceptible to this disease. Their sensitivity varies with age (decreasing gradually between two and five weeks), sex (males are more sensitive than females) and immune status (level of maternal antibodies during the first week of life and then, their response towards active immunization). Other species, including goslings, are not susceptible.

Not only are sick birds a source of contamination, but any material contaminated by their droppings, including clothing, boots, and equipment of response teams can also help spread the virus. Finally, manure pits located outside poultry buildings constitute a very significant risk factor. Thus, the disease can spread horizontally through direct and indirect transmissions. There is no evidence of vertical transmission.

CLINICAL SIGNS & LESIONS

Before its etiology was established, the disease was initially called «*Syndrome de Mortalité Malabsorption Déplumement Reptation (SMMDR)*» («Malabsorption Crawling Defeathering Mortality Syndrome»), on the basis of a fairly characteristic clinical picture. The term "malabsorption" referred to delayed and even stunted growth. The disease occurs mainly in Muscovy ducklings between two and four weeks of age. The peracute form can be observed starting during the second week of life.

The incubation period lasts six to seven days on average, but varies according to the sensitivity of the ducklings and the infectious viral load. In the field, a drop in feed consumption is observed two to three days before the sudden onset of the disease. This first phase of the disease can be accompanied by respiratory difficulties such as coughing or caseous tracheitis.

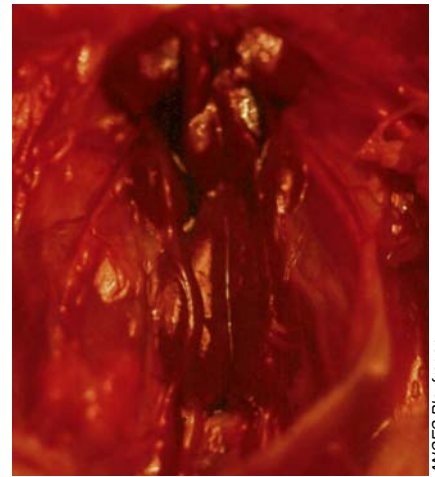In the acute or peracute form, the farmer is first alerted by a general prostration of the flock and by a sudden increase in mortality, which generally occurs in the first few days of the onset of the disease. The prostrated birds have a characteristic posture, with moving and breathing difficulties. Diarrhea is also noted.



JY Ferré



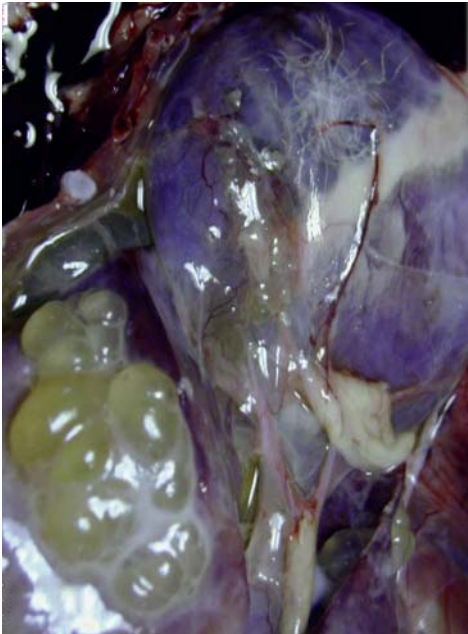
Mérial



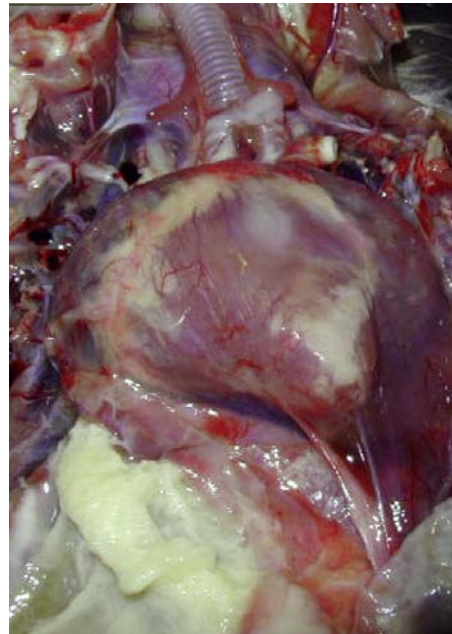
ANSES Ploufragan

Fig.86.8 & 86.9: Muscovy duck parvovirus. Diarrhea is also noted (Fig.86.8). The heterogeneity of the flock is spectacular, with normal birds alongside cachectic poorly feathered ones (Fig.86.9) but requires a differential diagnosis including conditions related to poor management.

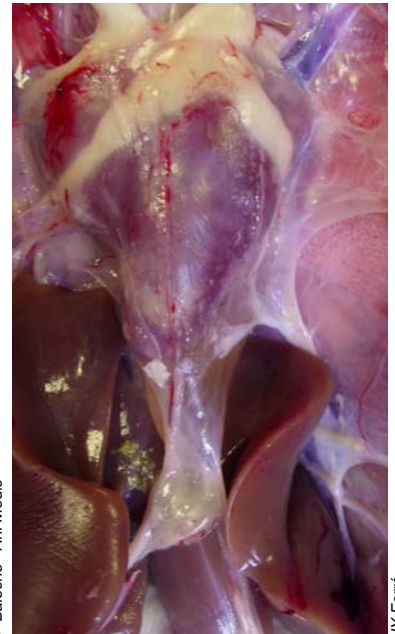Fig.86.10: Muscovy duck parvovirus. Significant level of renal congestion in the early stages of the disease (acute form).



P. Baloche - Ani-Medic



P. Baloche - Ani-Medic



JY Ferré

Fig.86.11: Muscovy duck parvovirus. Ascites may or may not be present. Fig.86.12 & 86.13: Muscovy duck parvovirus. Flaccid hearts and hydropericardia.

In the chronic form, the surviving ducks show slowed or even stunted growth (dwarfism).

In terms of lesions, a significant level of renal congestion is observed in the acute form, with flaccid hearts and hydropericardia. Ascites may or may not be present. Notable histological lesions are degenerative fascicular myopathy or muscular atrophy, degenerative myocarditis, neuritis, polioencephalomyelitis, poliomyelitis, acute hepatitis and multifocal splenic necrosis.

DIAGNOSIS

The clinical diagnosis is based on the species affected (Muscovy ducklings), the age of the flock (less

than 5 weeks of age at the onset of the disease), and on the characteristics of the disease: high mortality (severe in the acute form, more gradual and cumulative in the chronic form), leg paralysis, flock heterogeneity, poor feathering, lack of recovery of affected ducklings, presence of ascites at necropsy. These elements should help distinguish the disease from reovirus. However, both infections can co-exist and parvovirus is not easily clinically distinguishable from Derzsy's disease (apart from the leg paralysis, which is not described in Derzsy's disease).

The histological diagnosis is based on the examination of the following samples: thigh muscle, heart, sciatic nerves, tendons, liver, spleen, brain.

This allows to differentiate the disease from reovirus based on: the absence of tenosynovitis and exudative pericarditis in cases of parvovirus, and the absence of myopathy, myocarditis, neuritis and central nervous system lesions in cases of reovirus.

An ELISA test may enable a parvovirus infection to be suspected on the basis of seroconversion, but it is not possible to distinguish between duck parvovirus and Derzsy's disease with this technique. The ELISA test enables the assessment of maternal immunity, including determining whether this protection is likely to be sufficient or not. Beyond the normal physiological variability in the antibody transmission from the female duck to the ducklings, an inadequate level of maternal antibody protection would suggest a deficiency in the breeders' vaccination program or in the vaccine's administration method, particularly at the time of the booster vaccination before the beginning of the laying period.

The most effective techniques involve the amplification of the capsid gene (VP2/VP3) and the identification (either by sequencing or by performing a restriction profile) of typical sequences of duck parvovirus or Derzsy's disease virus. However, the use of these tests and others, such as virus isolation from tissue samples (by embryonated egg culture or by inoculation of duck embryo fibroblasts) or serum neutralization techniques on cell cultures, requires access to specialized laboratories. Due to differences in the level of viral multiplication between duck parvovirus and Derzsy's disease, it is possible to differentiate the two infections by semi-quantitative techniques based on gene amplification or the use of cold probes. More recently, a molecular characterization technique has been developed and validated. This technique, which uses the target tissues of viral replication, particularly the spleen, can detect the virus responsible for duck parvovirus and can differentiate field strains of the virus from attenuated virus strains used in live vaccines.

TREATMENT & CONTROL

There is no existing treatment once an outbreak occurs.

Besides preventive measures, ducklings need strong maternal immunity to fight the infection during the first week of life, and need an adequate active immunity in order to be protected during the entire period of susceptibility to the virus.

The recommended vaccination program involves a primary vaccination at one day of age, and a subcutaneous booster at about 18 days, with a vaccine combining a viral strain of Derzsy's disease and a strain of parvovirus from duck parvovirus. Two to four weeks before each of the two laying periods, breeders should also receive another booster intramuscularly, using a vaccine combining inactivated viruses from duck parvovirus and from Derzsy's disease with an oil adjuvant to stimulate antibody production. Besides these first generation vaccines (whole-organism vaccines), it is technically possible to develop second generation vaccines (subunit vaccines; e.g., protein antigens). They are currently being developed commercially.

REFERENCES

- Chang PC et al. Phylogenetic analysis of parvoviruses isolated in Taiwan from ducks and geese. *Avian Path*, 2000,29:45-49.
- Dalibart V et al. Caractérisation des lésions histologiques de la parvovirose spontanée du canard de Barbarie (*Cairina moschata*). Diagnostic histopathologique différentiel avec la Réovirose. *Rec Méd Vét*, 1993,169:763-772.
- Fournier D & Gaudry D. Muscovy duck parvovirus (MDP) in France: field vaccination trials. *Proceedings 9th international symposium on waterfowl*, Pisa, Italy, September 16-18th 1992, pp 36-41.
- Gaudry D & Fournier D. Last discoveries on waterfowl pathology: a new parvovirus of Muscovy ducks. *Proceedings of the 9th international symposium on waterfowl*, Pisa 1992, Italy, September 16-18th, pp.33-35.
- Jestin V et al. Isolement de virus de la maladie de Derzsy très pathogènes chez le canard de Barbarie. *Rec Méd Vét*, 1991,167, 849-857.
- Pingret JL et al. Détection des parvovirus des palmipèdes par PCR en temps réel. Utilisation de cette technique pour le suivi post-vaccinal du virus de Derzsy ainsi que comme indicateur en suivi d'élevage. *6èmes journées de la recherche avicole*, Saint-Malo, France, 30-31 mars 2005, pp.423-427.
- Woolcock PR et al. Evidence of Muscovy duck parvovirus in Muscovy ducklings in California, USA. *Vet Rec*, 2000,146:68-72.
- Zadori Z et al. Analysis of the complete nucleotide sequences of goose and muscovy duck parvoviruses indicates common ancestral origin with adeno-associated virus 2. *Virology*, 1995,212 :562-573.

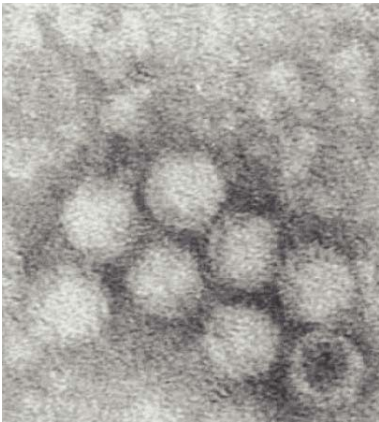


Fig.87.1: Parvovirus of Derzsy's disease (electron microscopy).

Fig.87.2 & 87.3: SBDS in mule ducks. Ducklings with a shorter beak giving them a characteristic goose profile.

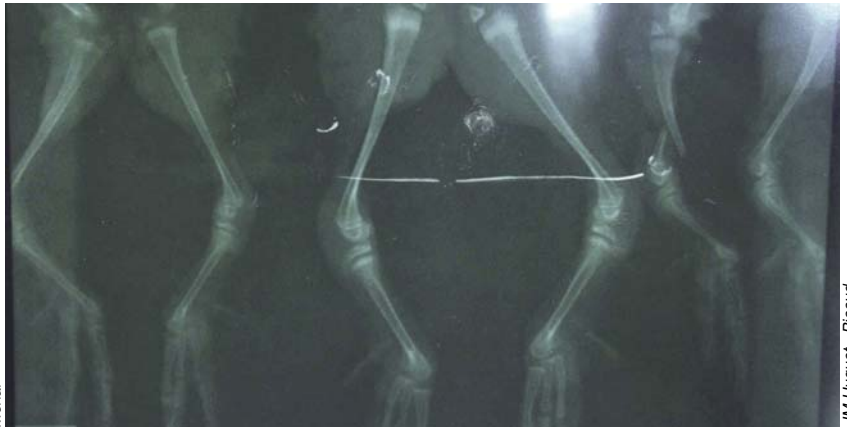

Fig.87.4: SBDS in mule duckling. Growth retardation.

Fig.87.5: SBDS in mule ducks. Radiographs showing, by comparison with the normal duck in the middle, a lack of ossification (long and curved bone poorly ossified) in the two other ducks, and a fractured femur on the right.

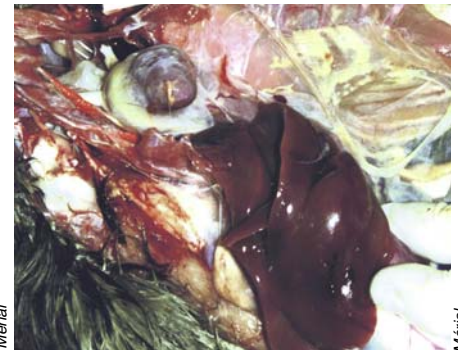
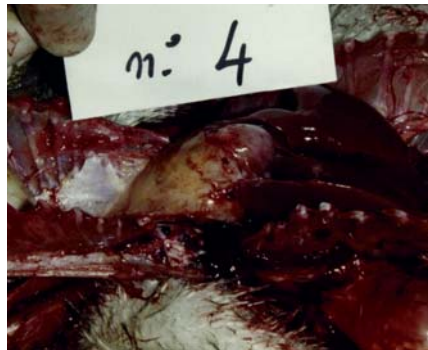
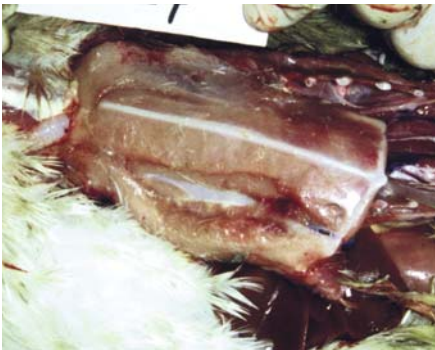

Fig.87.6: SBDS in mule ducks. Melting pectoral muscles.

Fig.87.7: SBDS in mule ducks. Pericarditis.

Fig.87.8: SBDS in mule ducks. Pericarditis and airsacculitis.


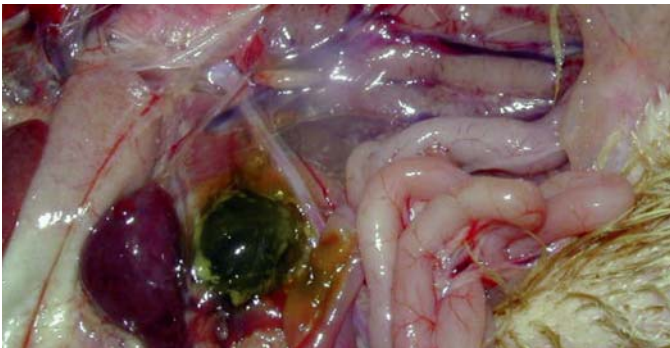


Fig.87.9: SBDS. Splenomegaly, bile retention and intestinal edema.

Fig.87.10: SBDS. Splenomegaly. Comparison with a normal spleen.

Other species

87. DERZSY'S DISEASE (SHORT-BEAK AND DWARFISM SYNDROME IN MULE DUCKS)

INTRODUCTION

Derzsy's disease, caused by a parvovirus very resistant in the external environment, is a viral disease manifested by sub-acute infection in mule ducks (a cross between a female Pekin duck and a male Muscovy duck). The mule duck, like the goose, is susceptible to the parvovirus causing Derzsy's disease. In extreme cases, growth retardation can be seen at an early age. More generally, a syndrome called "short-beaked dwarfism" (SBDS) is observed in 10 to 30% of ducks in an affected flock in the weeks preceding force-feeding. The syndrome rarely leads to on farm mortality.

ETIOLOGY

Derzsy's disease parvovirus was isolated in geese in France in 1972 and then in Muscovy ducks in 1973. It was already known and investigated by Prof. Derzsy's team in Hungary in 1967. This virus is classified in the family of *Parvoviridae*. Avian parvoviruses are small-sized non-enveloped DNA viruses (20 nm in diameter) with icosahedral symmetry. Derzsy's disease parvovirus presents an antigenic relationship with the Muscovy duck parvovirus (causing the «*Syndrome Mortalité, Malnutrition, Déplumement, Reptation*» or «*SMMDR*» which can be translated as Mortality, Malnutrition, Defeathering, Crawling Syndrome), a syndrome that has exclusively affected Muscovy ducks since 1989.

EPIDEMIOLOGY

Ailments associated with mule duck parvovirus are more or less typical depending on the viral infection pressure in the field, with growth retardation as main clinical manifestation. Malformations such as «goose profile», a curvature of the long bones of the lower limbs, are inconsistently associated with growth retardation. The rate of infection most often observed in a flock is between 10 and 30%.

Sick birds are the reservoir of the virus. Birds are not susceptible to the disease before one week of age. The virus is found in feces. Inadequately cleaned slatted floors, with the presence of residual

organic matter, represent a major source of viruses for ducklings. The persistence of the virus in the external environment, particularly on outside runs, helps maintaining the virus on a given production site. Horizontal transmission of the virus is direct (bird to bird) and indirect *via* biological and mechanical vectors (fomites). The plowing and liming of outside runs should be carried out before the introduction of a new flock so as to avoid increasing viral infection pressure between flocks.

CLINICAL SIGNS & LESIONS

The clinical presentation is suggestive of the disease when the short-beak and dwarfism syndrome is present. However, it is a lot less obvious when only growth retardation is observed. The consequence of the resulting heterogeneity of the flock is the inability to force-feed a proportion of affected ducks because of their stunted development. In general, the appearance of short-beak and dwarfism syndrome in mule ducks ready for force-feeding means that the birds must be sorted before being force-fed. This leads to economic losses.

Young ducks are affected by systemic visceral lesions including ascites, pericarditis, airsacculitis and nephritis. All age groups are affected by growth abnormalities (cachexia, fractures and deformities of long bones in particular).

DIAGNOSIS

Diagnosis may be confirmed by histopathology of muscle, bone, heart, liver and spleen tissues of ducks affected by the short-beak dwarfism syndrome.

Laboratory diagnosis is based on viral isolation of the parvovirus in eggs or duck embryo cells. As for serology (virus neutralization in cell cultures), laboratory diagnostic techniques other than histopathology are limited.

More recently, a molecular characterization technique has been developed and validated. The technique, using the target tissues for virus replication,

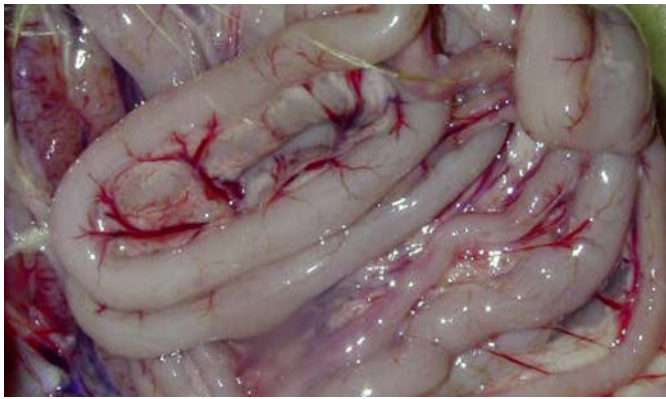


Fig.87.11: SBDS. Intestinal edema.

P. Baloche - Ani-Medic



Fig.87.12: Derzsy's disease. Sick ducklings.

LDA 22

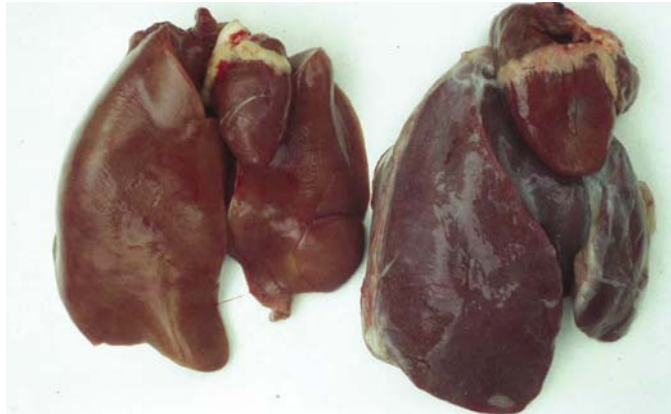

Fig.87.13: Derzsy's disease (Duck). Perihepatitis (compared with normal liver on right).

LDA 22

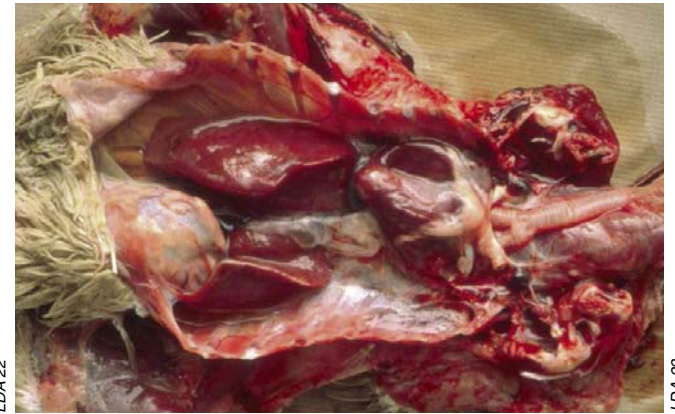

Fig.87.14: Derzsy's disease (Duckling). Ascites.

LDA 22

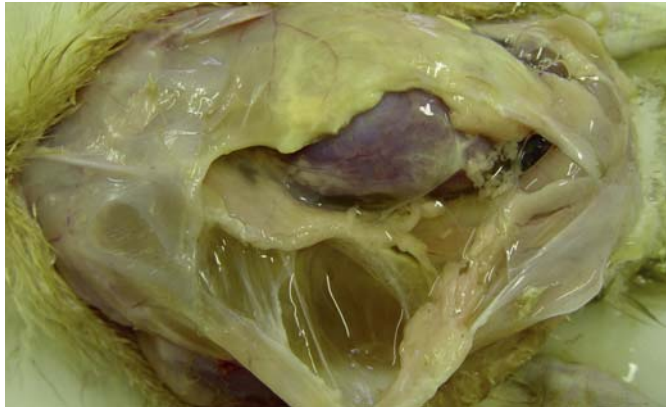

Fig.87.15: Derzsy's disease (Gosling). Ascites.

JL Guérin

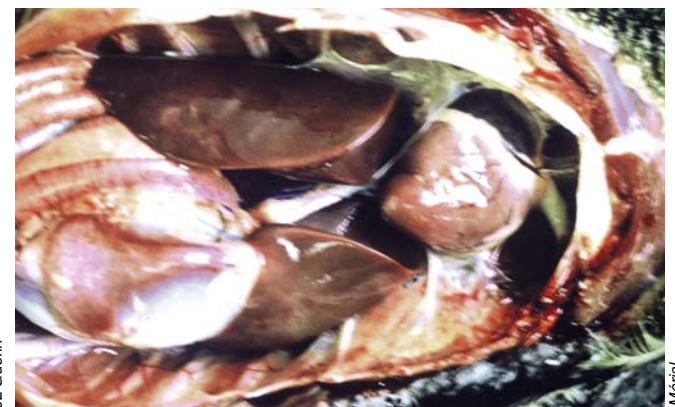


Fig.87.16: Derzsy's disease (Duck). Ascitic hepatonephritis.

Mérial

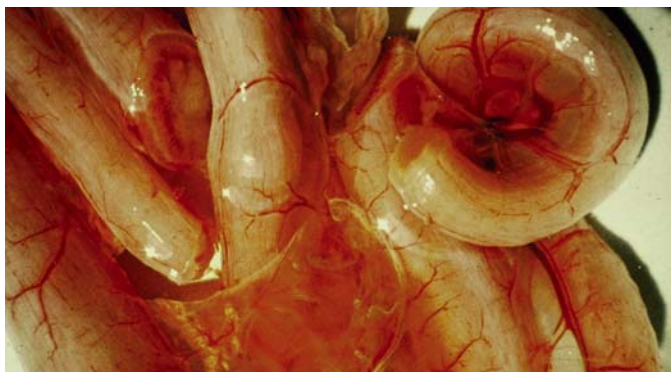

Fig.87.17: Derzsy's disease (Duck). Edema of the intestine.

Mérial

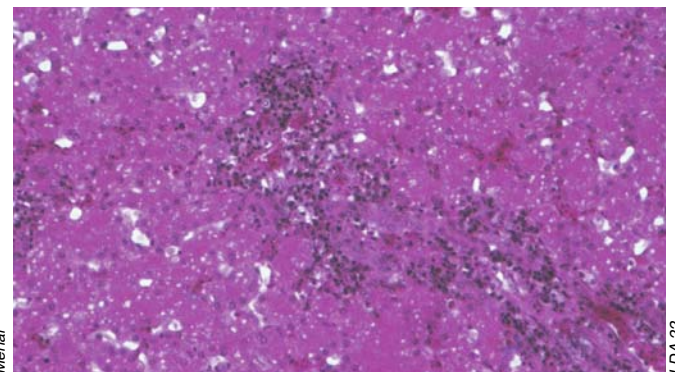


Fig.87.18: Derzsy's disease (Duck). Microscopic appearance of hepatitis (HES x 200).

LDA 22

particularly spleen tissues, enables the detection of Derzsy's disease parvovirus as well as the differentiation between field viruses and the attenuated virus strain of live vaccines used to control the syndrome.

TREATMENT & CONTROL

There is no existing treatment once an outbreak has occurred in a flock.

In addition to stringent biosecurity measures and proper flock management, a vaccination program may be recommended. A live attenuated vaccine is given subcutaneously at 2-3 weeks of age. When there is an increased incidence of cases, a vaccination program is recommended for a transitional period, based on a primary vaccination at one day of age, followed by vaccination at 2 weeks of age.

Breeders are vaccinated at 2-3 weeks of age with the same live attenuated Derzsy's disease vaccine used for meat birds, and then again 2-4 weeks before the flock goes into lay. A third vaccination is usually performed at mid-lay for artificially inseminated Pekin ducks. This vaccination schedule provides passive immunity for ducklings throughout the laying period.

REFERENCES

- Derzsy D. A viral disease of goslings. I. Epidemiological, clinical, pathological and aetiological studies. *Acta Vet Acad Sci Hung*, 1967,17:443-448.
- Gaudry D & Fournier D. Last discoveries on waterfowl pathology: a new parvovirus of Muscovy ducks. *Proc. 9th int. symp. waterfowl*, Pisa, Italy, 1992, Sept 16-18th, pp33-35.
- Jestin V et al. Isolement de virus de la maladie de Derzsy très pathogènes chez le canard de Barbarie. *Rec Méd Vét*, 1991,167:849-857.
- Kisary J & Derzsy D. Viral disease of goslings. IV Characterization of the causal agent in tissue culture system. *Acta Vet Acad Sci Hung*, 1974,24:287-292.
- Lemière S et al. Mise au point d'un protocole de suivi zootechnique versus témoins non vaccinés d'une bande de canards mulards à gaver vaccinée contre la maladie de Derzsy en station. 5^{èmes} Journées Recherche Palmipèdes à foie gras, Pau, 9-10 oct. 2002, pp206-209.
- Pingret JL et al. Détection des parvovirus des palmipèdes par PCR en temps réel. Utilisation de cette technique pour le suivi post-vaccinal du virus de Derzsy ainsi que comme indicateur en suivi d'élevage. 6^{èmes} Journées Recherche Avicole, Saint-Malo, 30-31 mars 2005, pp423-427.

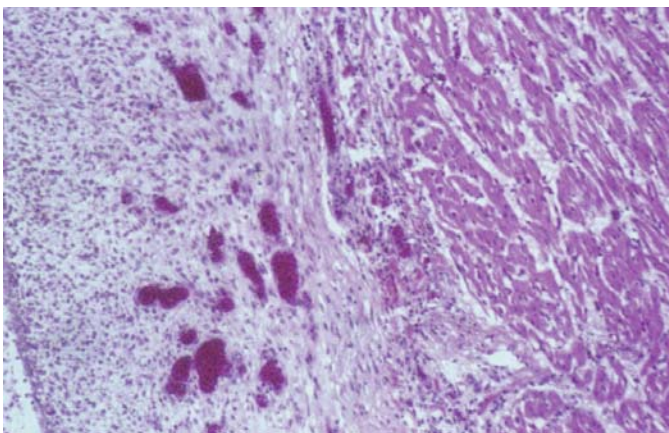


Fig.87.19: Derzsy's disease (Duck). Microscopic appearance of pericarditis (HES × 100).

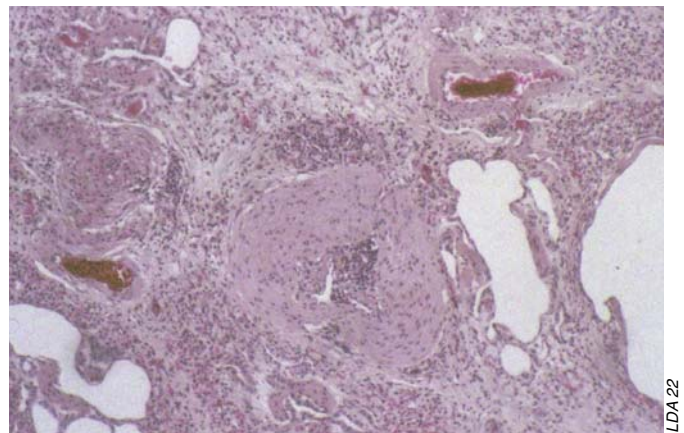


Fig.87.20: Derzsy's disease (Duck). Microscopic appearance of hypertrophy of the arterial wall in the lung (HES × 100).

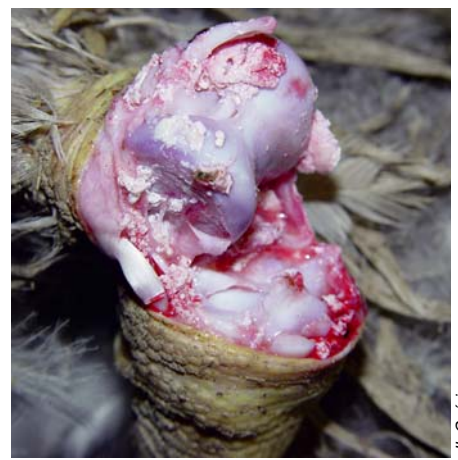
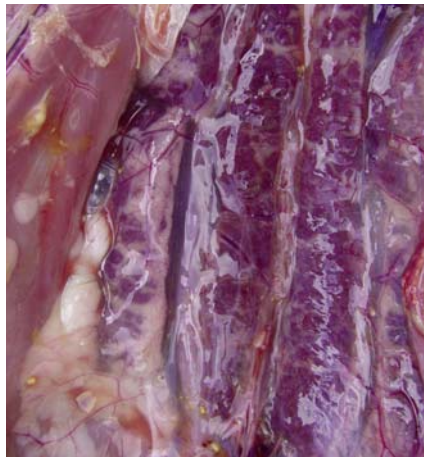
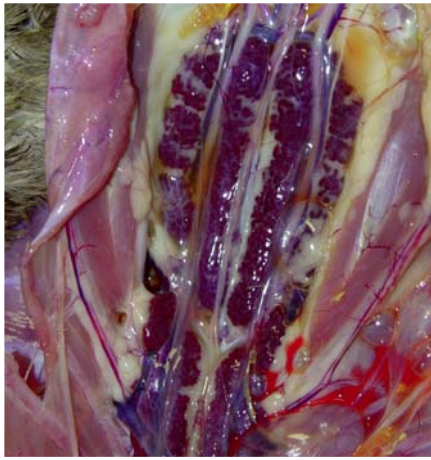Fig.88.1 & 88.2. HNEG (Goslings). Hemorrhagic nephritis.

Fig.88.3. HNEG (Gosling). Affected joint. Note the massive urate deposit on the condyles, causing lameness in the chronic form of the disease.

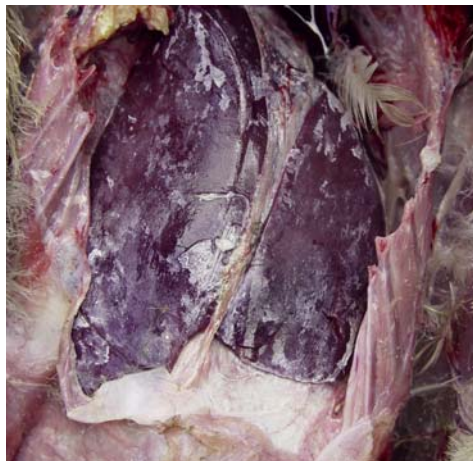

Fig.88.4. HNEG. Secondary visceral gout following infection by polyomavirus.

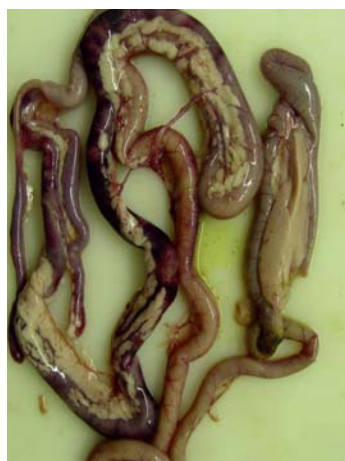

Fig.88.5. HNEG (Gosling). Acute hemorrhagic enteritis.

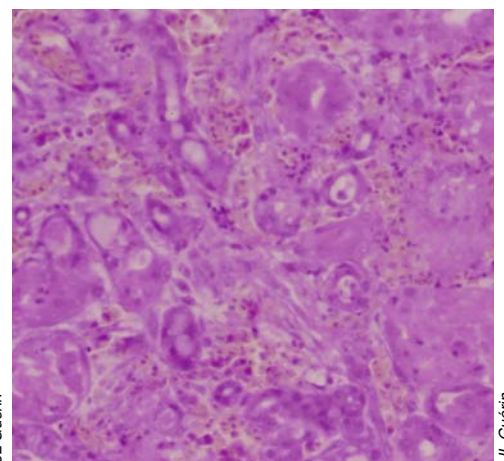


Fig.88.6. HNEG (Gosling). Microscopic appearance of interstitial nephritis and necrosis of the tubular epithelium of the kidney.

INTRODUCTION

Hemorrhagic nephritis enteritis of geese (HNEG) is a contagious viral infection of geese and ducks, associated with a disease in geese only. This disease entity was first described in 1970 in Hungary and was successively reported in France and Germany.

The HNEG has long been regarded as a chronic form of Derzsy's disease and has been named for a long time «late disease of goslings». The polyomavirus causing HNEG was finally isolated and identified 30 years after the first clinical description.

EPIDEMIOLOGY & ETIOLOGY

The agent of HNEG, namely *Goose hemorrhagic polyomavirus* (GHPV) is a member of the *Polyomaviridae* family. It is a small non-enveloped, double-stranded circular DNA virus of 45 nm

in diameter. The GHPV, as other polyomaviruses, is highly resistant to heat, drying and lipid solvents. Infected birds remain chronic carriers, shedding the virus in their droppings. The infection may remain subclinical for several weeks before the onset of clinical signs triggered by risk factors (stress, poor management, intercurrent diseases). Coinfection with *Goose circovirus* (GoCV) may likely exacerbate the pathogenic effect of this polyomavirus.

The disease has only been described in geese but ducks may be asymptomatic carriers and may serve as reservoir. An experimental infection of mule and Muscovy ducks with GHPV did not produce any gross or microscopic lesions.

Transmission of the virus is primarily fecal-oral. Vertical transmission through the egg has never been confirmed but cannot be excluded.

88. HEMORRHAGIC NEPHRITIS ENTERITIS OF GEESE

CLINICAL SIGNS & LESIONS

The disease has been described in goslings between four and twelve weeks of age, and associated with a mortality rate ranging from 20 to 80%. Clinical signs often develop in only a few hours before death: birds show locomotor difficulties and diarrhea that may be hemorrhagic; they isolate themselves from the flock before dying. A more chronic evolution of the disease leads to urate deposits in the viscera and joints, resulting in lameness; mortality may be limited to few birds.

Necropsy findings include edema of subcutaneous connective tissues, gelatinous ascites, nephritis and, less frequently, hemorrhagic enteritis. These lesions vary with age and disease evolution. As stated above, edema and ascites are more prevalent in acute cases, while urate deposits on the serosa of viscera and articulations are more common in chronic cases.

Histopathologically, the most obvious features are a tubulointerstitial nephritis, necrotic lesions of the intestinal mucosa and moderate to severe lymphocytosis of follicles of the bursa of Fabricius. These bursal lesions are certainly the cause of immunosuppression in infected birds, favoring secondary infections. No intranuclear basophilic inclusion bodies, normally associated with polyomavirus infections, have been detected in cells of birds infected with HNEG.

DIAGNOSIS

The diagnosis is essentially clinical, based on the age of goslings, clinical signs and especially the necropsy.

The differential diagnosis must be made considering the subacute form of Derzsy's disease. Clinical signs and lesions associated with secondary bacterial infections may complicate the diagnostic process.

Virus isolation in cell culture is difficult and not routinely accessible. Confirmatory diagnosis is based on the detection of the viral genome using a PCR test (polymerase chain reaction amplification), now routinely available in France. This test can be performed using spleen or kidney samples or cloacal swabs obtained from sick birds. Finally,

an ELISA test has been developed but is not currently used in practice.

TREATMENT & CONTROL

No treatment is available against this viral disease.

Disease prevention is based on biosecurity measures to prevent the introduction and limit the spread of the virus in flocks. Because this virus is known to be extremely resistant in the environment, drastic cleaning and disinfection procedures are required. Chloride derived products are considered effective to inactivate polyomaviruses in the absence of organic matter. The prevention of this disease is also based on controlling risk factors susceptible to trigger clinical signs in infected birds.

An inactivated adjuvanted vaccine has been developed. Experimental results show significant protection by vaccination of breeders providing parental immunity to goslings. At time of print of this book, it was not available in the field.

REFERENCES

- Gelfi J et al. Safety and efficacy of an inactivated Carbopol-adjuvanted Goose haemorrhagic polyomavirus vaccine for domestic geese. *Avian Pathol*, 2010,39:111-116.
- Corrand et al. Pathological and epidemiological significance of Goose haemorrhagic polyomavirus (GHPV) infection in ducks. *Avian Pathol*, 2011, 40:355-360.
- Guérin JL et al. A novel polyomavirus (Goose hemorrhagic polyomavirus) is the agent of Hemorrhagic Nephritis Enteritis of Geese. *J Virol*, 2000,74:4523-4529.
- Guérin JL. Hemorrhagic Nephritis Enteritis of Geese. In "*Diseases of Poultry*", 13th Ed Ames 2013, Iowa State University Press. pp. 440-443.
- Palya V et al. Epizootic occurrence of haemorrhagic nephritis enteritis virus infection of geese. *Avian Pathol*, 2004,33:244-250.
- Pingret JL et al. Goose haemorrhagic polyomavirus (GHPV) infection in ducks. *Vet Rec*, 2002,82:162:5.
- Schettler Ch. Clinical aspect and pathology of hemorrhagic nephritis and enteritis in geese. *Tierarztl Prax*, 1980,8:313-320.




Fig.89.1 & 89.2: DVE. Diarrhea. Greenish liquid droppings (left) sometimes hemorrhagic (right).

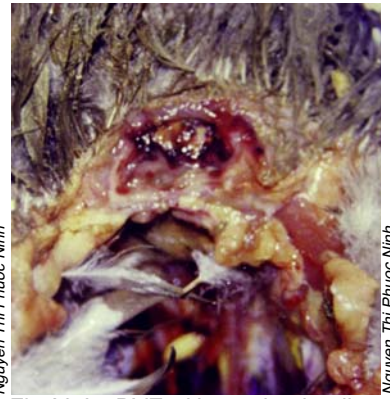

Fig.89.3: DVE. Hemorrhagic diarrhea stains the feathers surrounding the vent.

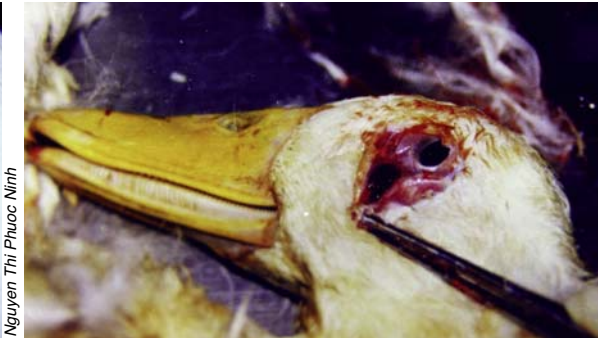


Fig.89.4 & 89.5: DVE. Photophobia with excess lacrymation and eyelid hemorrhages.

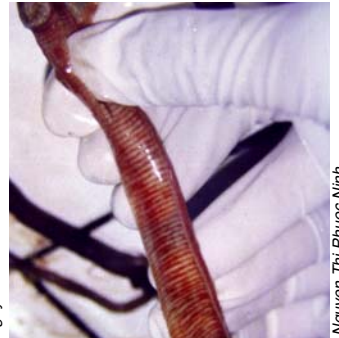

Fig.89.6: DVE. Hemorrhagic trachea.

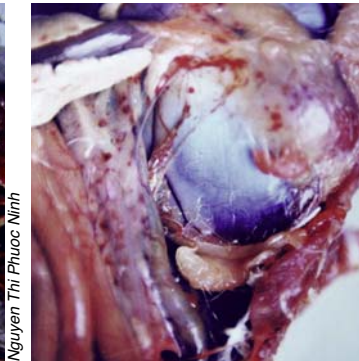
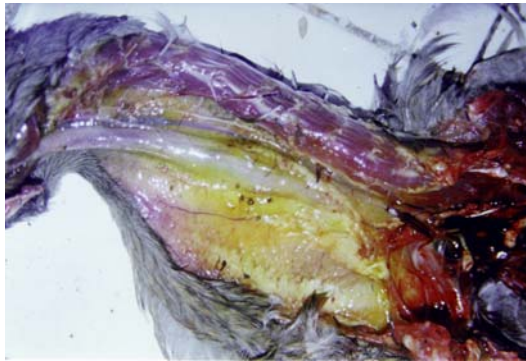


Fig.89.7: DVE. Edema of subcutaneous tissue of the neck.

Fig.89.8: DVE. Hemorrhages in the connective tissues.

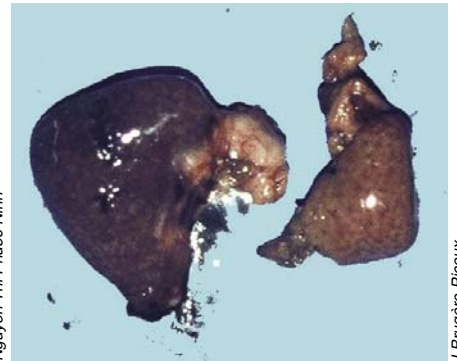


Fig.89.9: DVE. Smaller spleen (dark and mottled). Compare with normal spleen on left.

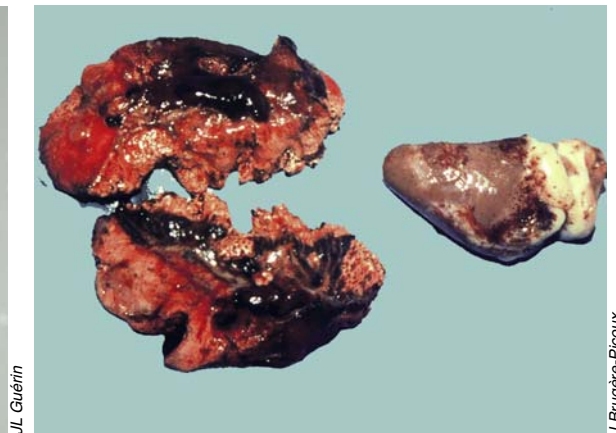
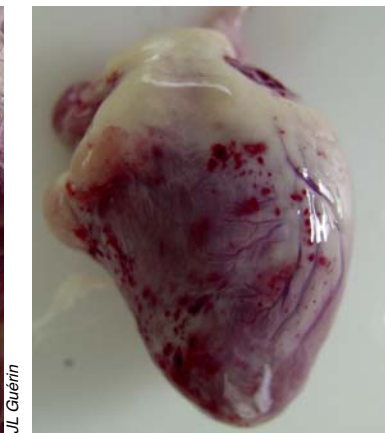
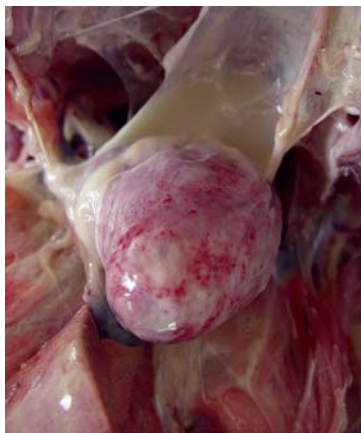


Fig.89.10, 89.11 & 89.12: DVE. Hemorrhages in the epicardium and lungs.

Other species

89. DUCK VIRUS ENTERITIS

INTRODUCTION

Duck virus enteritis (DVE) is an acute and contagious disease of ducks, geese, swans (waterfowl) characterized by general weakness with drooping wings, extreme thirst, diarrhea, high mortality, and by lesions of the vascular, digestive, and lymphoid systems. It may cause substantial economic losses because the mortality rate may reach 100% and egg production may drop 20-100%.

DVE is also called duck plague, *eendenpest* (Dutch), *peste du canard* (France), *Entenpest* (German). It is present in several countries (China, France, Belgium, India, Thailand, England, Canada, Hungary, Denmark, Austria and Vietnam).

ETIOLOGY

The causative agent is a *Herpesvirus* (*anatid herpesvirus 1*), belonging to the *Alpha-herpesvirinae* subfamily. When first observed in the Netherlands in 1923, the disease was mistaken for avian influenza. The differential diagnosis was made in 1942 and the disease was called “duck plague”. Although strains vary in pathogenicity, there is no difference in antigenicity between isolates of DVE virus except in Vietnam, suggesting the presence of two subtypes in this country. A herpesvirus strain isolated in domestic geese in Australia is genetically distinct from the DVE agent.

The virus is nonhemagglutinating and nonhemadsorbing. It grows on the chorioallantoic membrane of 9 to 14 day-old embryonating duck eggs or on duck embryo fibroblasts. Lesions of DEV are characterized by the presence of intranuclear inclusion bodies in cell culture. The virus also can be isolated in ducklings. The virus is not only sensitive to ether but also to chloroform. Exposing the virus to chymotrypsin, trypsin and pancreatic lipase decreased viral infectivity by four logs. The virus is inactivated in 10 minutes at 56°C and 60°C, in two hours at 50°C and in 30 days at 22°C.

EPIDEMIOLOGY

Duck virus enteritis affected birds belong to the *Anatidae* family (ducks, geese, swans). All ages are susceptible.

Horizontal transmission occurs when susceptible ducks are in direct contact with infected ducks or contaminated feed, drinking and pond water (contaminated by droppings of sick wild or domestic waterfowl). Water is important for the horizontal transmission of the disease and the cloaca is the main portal of entry. New outbreaks are more frequently seen in birds having access to open bodies of water where migratory waterfowl can be found. For this reason, these outbreaks present a seasonal incidence.

As with many other herpesvirus infections, the birds surviving the disease become carriers and intermittently excrete the virus (especially when under stress) for several years.

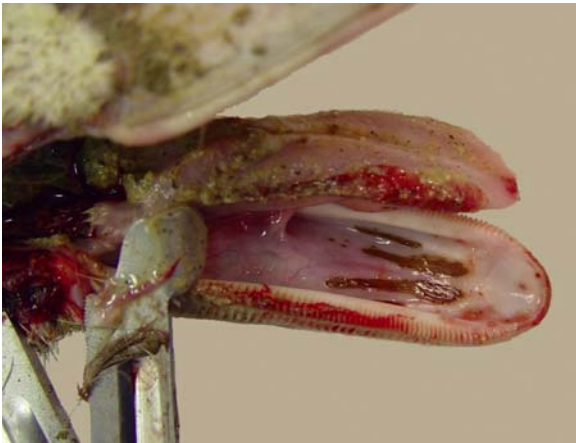Arthropods feeding on viremic birds could possibly transmit the disease, although this has yet to be confirmed.

Vertical transmission has been reported experimentally.

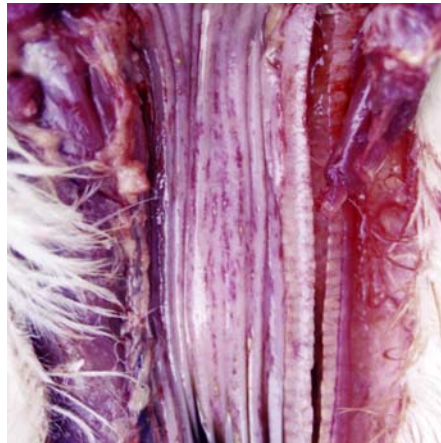CLINICAL SIGNS & LESIONS

The incubation period is three to seven days. Diseased ducks have photophobia with excess lacrymation, pasted eyelids, respiratory distress, nasal discharge, extreme thirst and bloody or greenish watery diarrhea. Sick ducks stand reluctantly and when forced to move, their neck and head are trembling. Some of them have edema of the neck down to the thoracic inlet area.

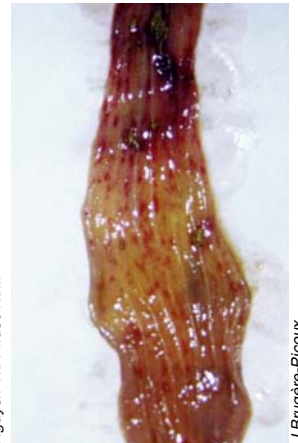In domestic breeders, there is a marked drop in egg production (25-40%). Morbidity and mortality are usually high but vary from as low as 5% to 100%.



JL Guérin



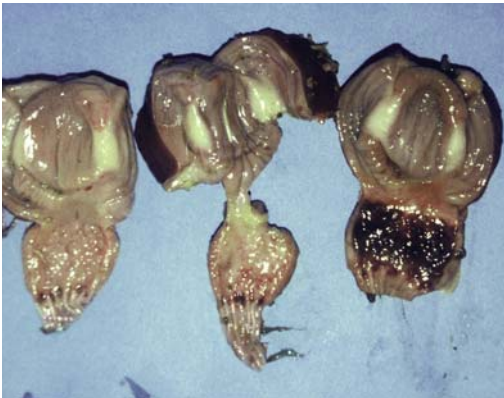
Nguyen Thi Phuoc Ninh



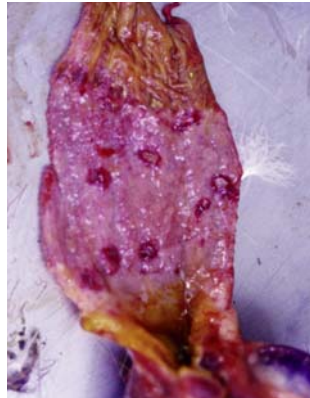
J Brugère-Picoux

Fig.89.13: DVE. Oral ulcers, under the tongue, often indicative of the presence of ulcers in the digestive tract.

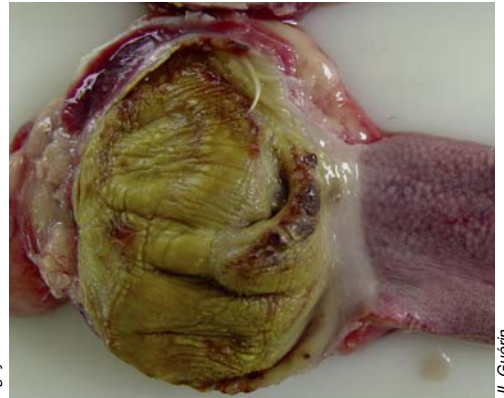Fig.89.14 & 89.15: DVE. Hemorrhages and necrosis of the esophagus.



J Brugère-Picoux



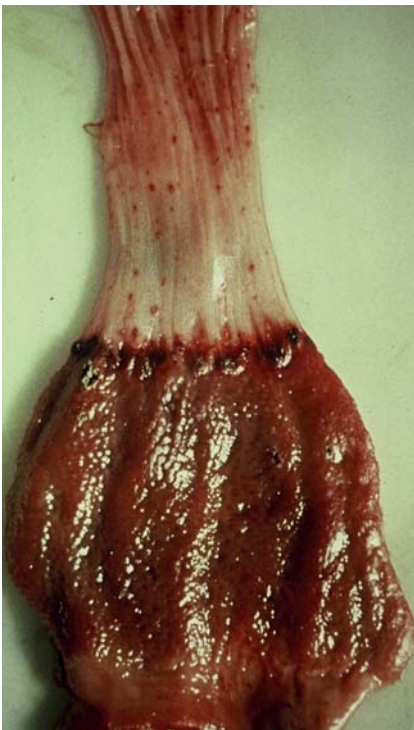Nguyen Thi Phuoc Ninh



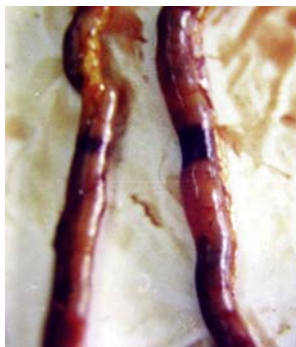JL Guérin

Fig.89.16 & 89.17: DVE. Hemorrhages in the proventriculus.

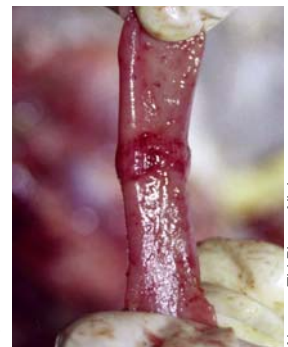Fig.89.18: DVE. Ulcer in the gizzard.



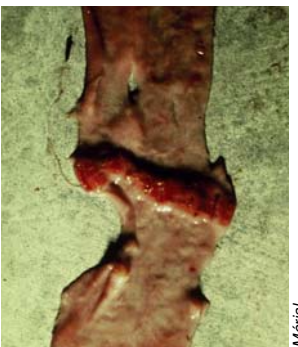Mérial



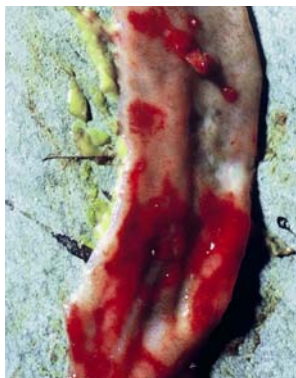Nguyen Thi Phuoc Ninh



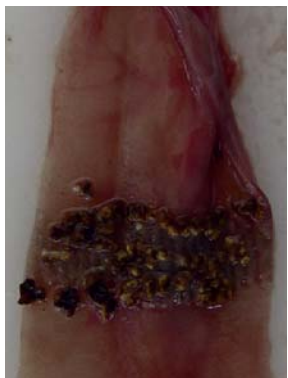Nguyen Thi Phuoc Ninh



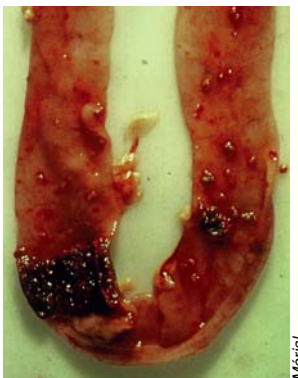Mérial



Nguyen Thi Phuoc Ninh



JL Guérin



Mérial

Fig.89.19: DVE. Hemorrhages in the esophagus and the proventriculus.

Fig.89.20, 89.21, 89.22, 89.23, 89.24 & 89.25: Congestion and hemorrhage of the annular bands (lymphoid patches) of the small intestine are characteristic of DVE, with progression to ulceration covered by fibrinous and hemorrhagic pseudomembranes. Note the characteristic reddened rings visible on the external surface of the intestine.

Most birds that develop clinical signs die. Death usually occurs in one to five days.

Vascular damage is characterized by multiple hemorrhages seen in many organs as well as blood in the body cavities. Hemorrhages are seen on the heart, liver, gizzard, pancreas, intestine, lungs and kidneys.

Prominent lesions are diphtheritic cloacitis and esophagitis (primary sites of viral replication), as well as characteristic hemorrhagic annular bands (lymphoid zones) of the intestines. The liver presents petechiae and multiple foci of necrosis. As mentioned above, a subcutaneous edema of the neck can be seen. In layers, the ovarian follicles may be deformed and discolored with hemorrhages. This may lead to eggs being deposited in the abdominal cavity.

Histologically, intranuclear inclusion bodies can be seen in the cells surrounding necrotic foci.

DIAGNOSIS

The diagnosis of DVE can be made on the basis of clinical and pathological findings. Confirmation is obtained by virus isolation (Muscovy duck embryo liver cell cultures are the most sensitive) but several blind passages are necessary.

Polymerase chain reaction (PCR), immunofluorescence and virus neutralization tests can all be used to detect the virus. An enzyme linked

immunosorbent assay (ELISA) and a serum neutralization test may be carried out to search for specific antibodies.

Duck virus enteritis must be differentiated from duck viral hepatitis, avian influenza, Newcastle disease, pasteurellosis, coccidiosis, and other causes of enteritis.

CONTROL

In commercial duck flocks, biosecurity is essential to prevent contact with wild waterfowl. Vaccinating all of the susceptible domestic ducks with an attenuated vaccine or killed vaccine is necessary in some countries.

REFERENCES

Dardiri AH,. Duck Viral Enteritis (Duck Plague). Characteristics and immune response of the host. *Am J Vet Res*, 1975,36:533 538.
 Gough RE. Duck Virus Enteritis. In *Poultry diseases*, 6th Pattissson M ed., Saunders, 2008, pp 272-275.
 Kaleta E F. Herpesviruses of birds, a review. *Avian Pathol*, 1990,19:193 211.
 Kermer IF & Gough RE, 1986. Duck virus enteritis (anatid herpesvirus Infection) in mute swans (*Cygnus olor*). *Avian Pathol*, 1986,15:161 170.
 Newcombs SS. Duck virus enteritis (duck plague) epizootiology and related investigations. *JAVMA*, 1968,153:1897 1902.
 Sandhu TS & Metwally SA. Duck virus enteritis (duck plague). In: *Diseases of Poultry*, 12th ed, Mosby Wolfe, IM Saif (ed), 1997, pp384-393.

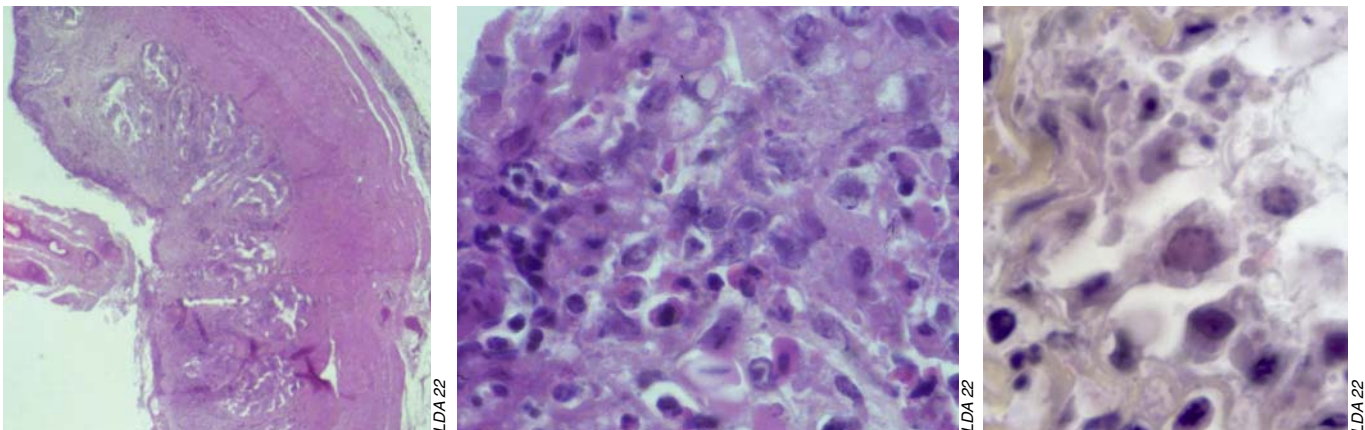


Fig.89.26, 89.27 & 89.28: DVE (esophagus). Necrosis and intranuclear inclusion bodies in esophageal cells.



Fig.90.1: Duckling dead from infection with DH. Note typical opisthotonos.

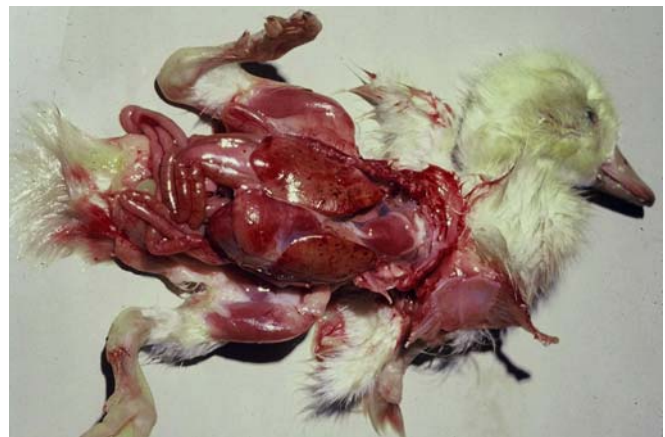

Fig.90.2: Main lesions of DH are found in the liver with hemorrhages.

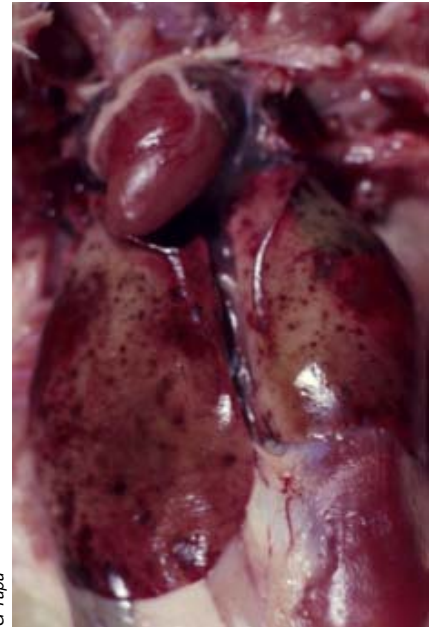
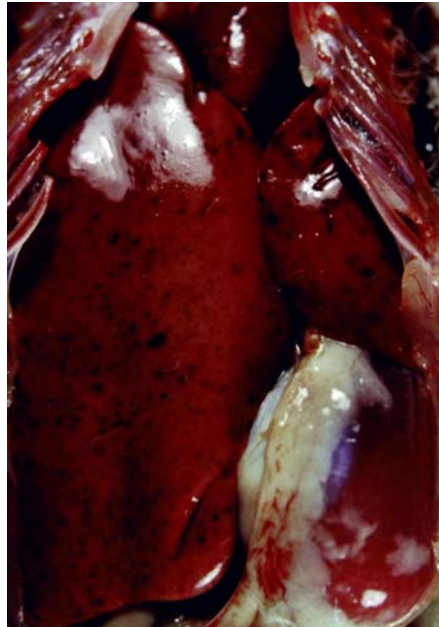
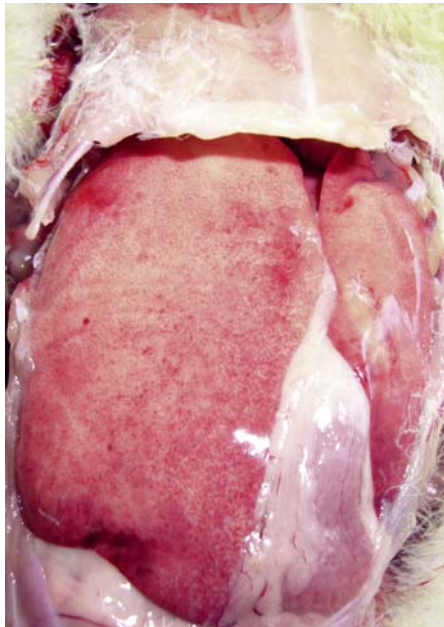
Fig.90.3, 90.4 & 90.5: Livers with punctate or suffusion hemorrhages caused by DH infection.

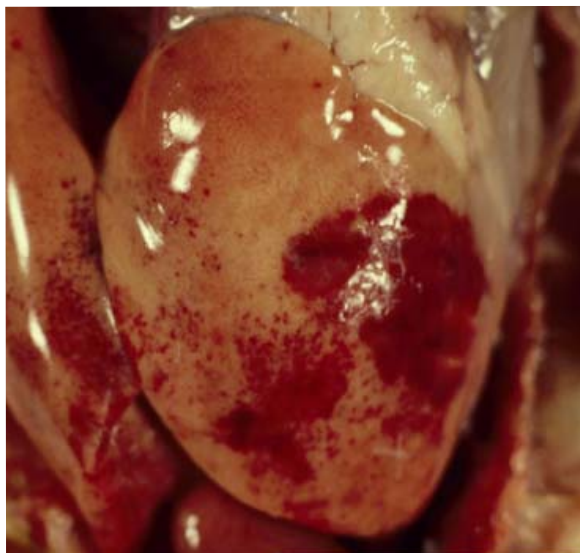


Fig.90.6: DH. Liver with suffusion hemorrhage.

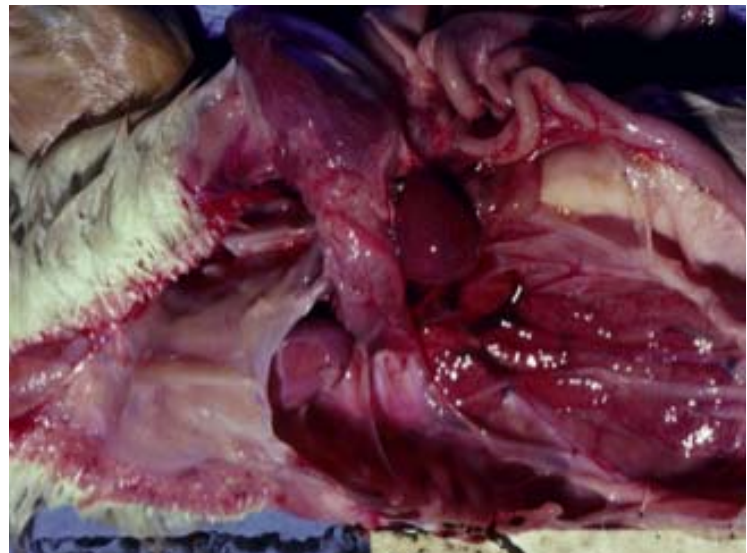


Fig.90.7: DH. Congestion and enlargement of the kidneys.

Other species

90. DUCK HEPATITIS

INTRODUCTION

Duck hepatitis (DH) is an acute disease of ducklings, characterized by a highly fatal virus, rapidly spreading to all susceptible ducklings in a flock, with clinical signs including opisthotonos. The liver of affected birds is enlarged with hemorrhagic lesions. Duck hepatitis is of economic importance to all duck producers.

ETIOLOGY

Duck hepatitis can be caused by three different viruses, namely duck hepatitis virus (DHV) type 1, 2 and 3.

Duck virus hepatitis type 1

Type 1 was first isolated in chicken embryos by Levine and Fabricant (1), during the spring of 1949, when they studied a highly fatal disease in White Pekin ducks on Long Island, New York. Duck hepatitis type 1 is now worldwide in distribution including China. The virus has been classified as a picornavirus (*Avihepatovirus*), which has been estimated to be 20-40 nm in size.

Duck virus hepatitis type 2

Asplin (1965) had described a disease of ducks caused by an agent serologically distinct from classical duck hepatitis virus. The disease occurred in free-range operations in Norfolk, England, affecting 2 to 6 week-old ducks, and causing mortality varying between 30 to 70%. The affected flocks had been vaccinated with attenuated DHV type 1. The isolated agent was studied by assessing cross-protection in ducklings. Results showed that this virus differed from DHV type 1 and was named DHV type 2. The particles were not enveloped, had an astrovirus-like morphology and had been classified as an astrovirus by Gough in 1986. The liver lesions were similar to DHV type 1 and 3. At time of publication, there have been no outbreaks of this disease outside of East Anglia, England.

Duck virus hepatitis type 3

Toth (1969) first reported hepatitis causing about 60% morbidity and 20% mortality in ducklings immunized to DHV type 1 on Long Island. The disease was less severe than DHV type 1 and

mortality rarely exceeded 30%. Based on differences in the characteristics of the agent compared to DHV type 1 and type 2, the agent was named DHV type 3. Haider and Calnek (1979) suggested that DHV type 3 be classified as a picornavirus, but no common antigens could be demonstrated with DHV type 1 using virus neutralisation (VN) and fluorescent antibodies (FA) tests. The disease is only known to have occurred in the United States.

All three serotypes can be grown in duck embryos, duck embryo liver (DEL) and duck embryo kidney (DEK) cells, while DHV type 3 cannot be grown in embryonating chicken eggs.

The DHV type 1 becomes non pathogenic for ducklings after 20 or more passages in chicken embryos and after 6 passages in duck embryo fibroblasts.

The virus is completely inactivated by 1% formaldehyde or 2% caustic soda within 2 hours at 15-20°C or by 5% phenol. Under field conditions, the virus survives at least 10 weeks in uncleaned contaminated brooders and for longer than 37 days in moist feces stored in a cool shed. At 4°C the virus can survive over 2 years and at -20°C for as long as 9 years.

EPIDEMIOLOGY

Duck Hepatitis type 1 outbreaks occur only in ducklings between one to six weeks of age, with Pekin ducklings being most susceptible during the first four weeks of life. Adult breeders on infected premises do not become clinically ill but can become carriers. Chickens and turkeys are resistant. Experimental infections in goslings and mallard ducklings have been reported. Mortality associated to DH has been reported in Muscovy ducklings in some regions of China.

Affected ducklings and birds that have recovered are sources of infection. Contaminate grounds, litter, water, feed, equipment and vehicles are also sources of infection. Wild birds, rodents and workers are mechanical vectors.

Under field conditions the disease spreads rapidly to all susceptible ducklings in a flock. The virus may enter via the oral and respiratory routes. Egg transmission presumably does not take place.

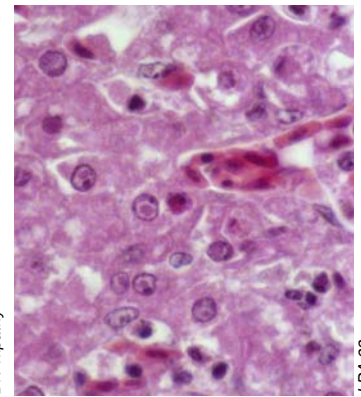
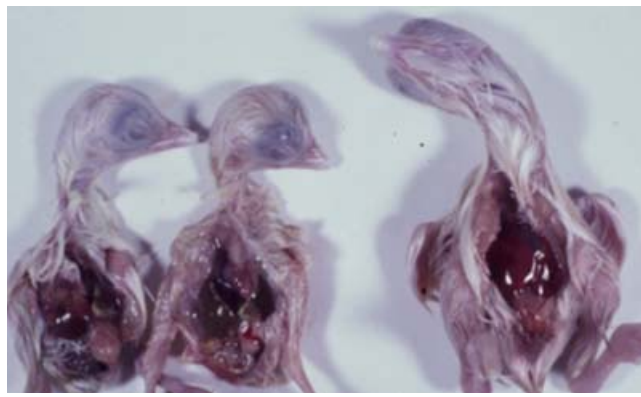
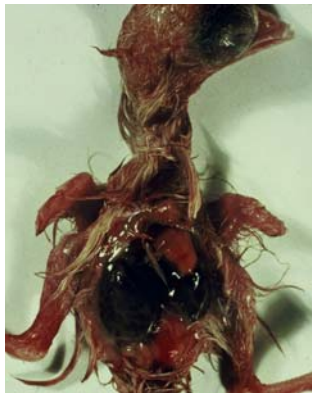

Fig.90.8 & 90.9: DH virus type 1 can usually be isolated from embryonating chick or duck embryos or 1-day-old susceptible ducklings. In Fig.90.9, all chicken embryos are of the same age (two embryos infected on the left and control on the right). Once the virus is isolated, it can be identified by serum neutralization using a known hepatitis antiserum.

Fig.90.10: Duck plague with inclusion bodies in the hepatocytes must be differentiated from DH.

The disease may occur throughout the year. However, in tropical regions a higher incidence of DH was noted in winter and spring. Mortality reaches 90% and morbidity 100% in ducklings less than one week old. Generally, mortality may be 50% or less in ducklings one to three weeks of age; at four to five weeks of age, morbidity and mortality gradually decline.

CLINICAL SIGNS & LESIONS

The incubation period ranges from 1 to 4 days. Ducklings may die without exhibiting any premonitory signs. Onset and spread of infection to the whole flock are very rapid. Early clinical signs include difficulty moving (even refusal to move), many birds squatting down with eyes partially closed. Ducklings are depressed within a short period of time and are found resting on one side, kicking spasmodically with both legs, and dying with their head drawn back.

The characteristic lesions are seen in the liver, which is enlarged, soft, friable, and displays distinct punctate or suffusion hemorrhages. The gall-bladder is full of bile. The spleen is sometimes enlarged and mottled. Kidneys are swollen and congested.

DIAGNOSIS

A presumptive diagnosis of DH in ducklings can usually be made on the basis of clinical signs and characteristic gross lesions. However, isolation and identification of the causative agent is necessary for a definitive diagnosis:

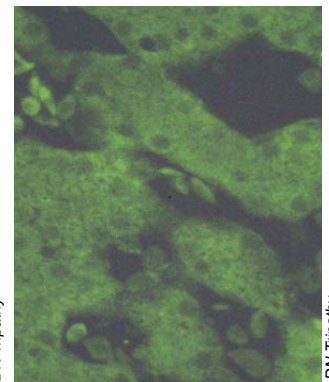
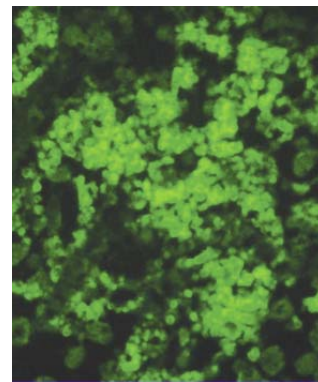


Fig.90.11 & 90.12: Chicken liver cells infected with duck hepatitis virus (DHV) reacted with antibodies labeled against DHV (left) versus non-infected liver cells serving as controls (right).

1. Subcutaneous inoculation of infective liver suspension into five to seven 1 to 7 day-old susceptible ducklings should result in characteristic clinical signs and deaths often occurring within 24 hours. Ducklings should show the typical gross lesions attributable to DHV type 1.
2. Inoculation of infective liver suspension into the allantoic sacs of embryonated duck eggs (aged 10 - 14 days) from susceptible breeders. The embryos should die within 24-72 hours. The allantoic fluid is opalescent or pale greenish-yellow. Gross lesions in the embryos consist of subcutaneous hemorrhages over the whole body and edema.
3. A rapid and accurate diagnosis of DHV type 1 can be made using direct immunofluorescence on livers of field cases or of ducklings inoculated with an infective liver suspension.

Differential diagnosis should consider chlamydia-sis, duck viral enteritis (duck plague), Newcastle

disease, avian influenza, salmonellosis and aflatoxicosis.

TREATMENT & CONTROL

Treatment

Intramuscular injection of 0.5-1.0 ml of convalescent or hyperimmune serum into ducklings in flocks early in an outbreak has been used extensively as treatment of DH but with varying degrees of success.

Passive immunization by injection of yolk from eggs produced by hyperimmune breeder ducks or by specific pathogen-free (SPF) fowls hyperimmunized with DHV type 1 was suggested by Rispens (1969) and Haider (1982). This antibody treatment may reduce mortality and can be used to prevent the occurrence of the disease. This passive protection may last 10 to 15 days.

Control

Good management and strict sanitation practices are needed to control the disease. A site quarantine is important when the disease is suspected or confirmed. Biosecurity measures include preventing the introduction of potentially contaminated personnel, feed, equipment and birds on the production site. Efforts should be made to only introduce ducklings from flocks known to be free of DH.

Vaccination

A live virus vaccine containing DHV type 1, for use in breeders and in susceptible ducklings, has been produced from a modified DHV type 1 passaged more than 50 times in embryonated chicken eggs. The vaccine may be prepared from chicken or duck embryos or cell cultures. Vaccination of breeders in order to achieve passive immunity against DH in their progeny is a well established strategy. At present it is the principal preventive measure against DHV in many countries.

Breeders. Breeders are inoculated with 1 ml of a

DVH modified live virus (MLV) type 1 vaccine intramuscularly two to four weeks before collecting hatching eggs. Revaccination of breeders about every 4 months with the MLV vaccine can maintain passive immunity at a high level. This vaccination schedule practically solved the problem of DVH in ducklings up to 2 weeks of age. But passive immunity does not last longer than 3 weeks. The disease can cause losses among ducklings older than 3 weeks. Therefore, vaccination at three to four weeks of age is needed to induce active immunity to offer protection until market.

Ducklings. Newly hatched ducklings without maternally derived immunity and given a subcutaneous injection (0.5 ml) of a DVH MLV vaccine will develop resistance in 3 days. This vaccination strategy quickly confer active immunity, providing adequate protection for a longer period than passive immunity.

REFERENCES

- Asplin FD. 1965. Duck hepatitis: vaccination against two serological types. *Vet Rec*, 1965, 77:1529-1530.
- Haider SA & Calnek BW. In vitro isolation, propagation, and characterization of duck hepatitis type III. *Avian Dis.* 1979,23:715-729.
- Levine, PP & Fabricant J. A hitherto-undescribed virus disease of ducks in North America. *Cornell Vet.* 1950,40:71-86.
- Rispens BH. Some aspects of control of infectious hepatitis in ducklings. *Avian Dis.* 1969,13:417-426.
- Toth TE. Studies of an agent causing mortality among ducklings immune to duck virus hepatitis. *Avian Dis.* 1969,13:834-846.
- Woolcock PP & Fabricant J. Duck Hepatitis. In "*Diseases of poultry*", Iowa State University Press, Ames 1997. 661-670.
- Woolcock PP. Duck Virus Hepatitis. In "*A Laboratory Manual for the Isolation and Identification of Avian Pathogens*" Fifth Edition, Publ.AAAP, 2008, 175-178.

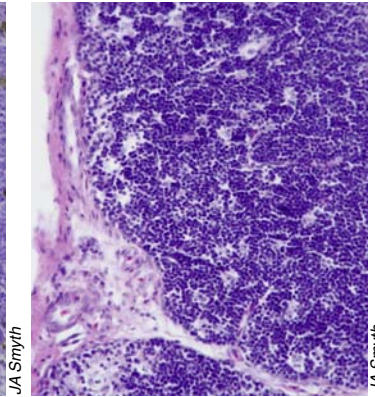
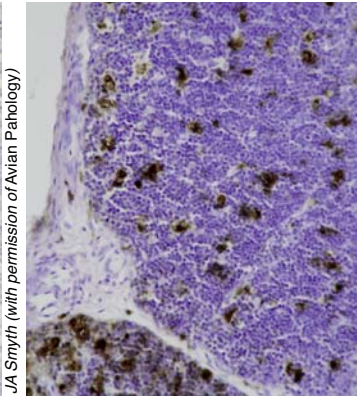
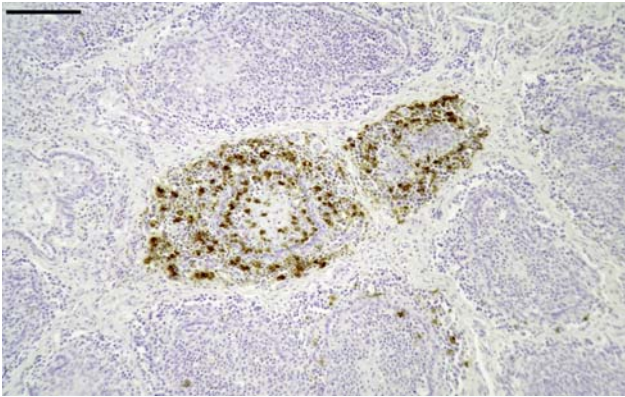


Fig.91.1: Detection of DuCV DNA using *in situ* hybridization. Circovirus DNA (labelled brown) in the bursa of Fabricius (BF) from a duck. Two follicles are heavily labelled, with positive cells in both the cortex and medulla. Other follicles contain a few or no labelled cells. Bar=100 μ m.

Fig.91.2 & 91.3: Goose circovirus infection. Low magnification of an infected thymus showing virus positive cells in both the cortex and medulla (circovirus DNA labelled brown). Hematoxylin and eosin (H&E)-stained section of BF adjacent to the section in Fig.91.3.

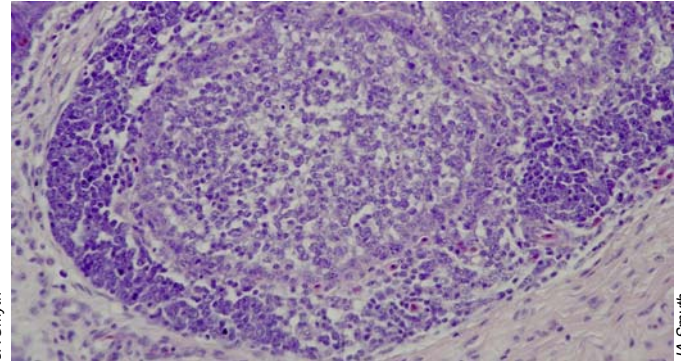
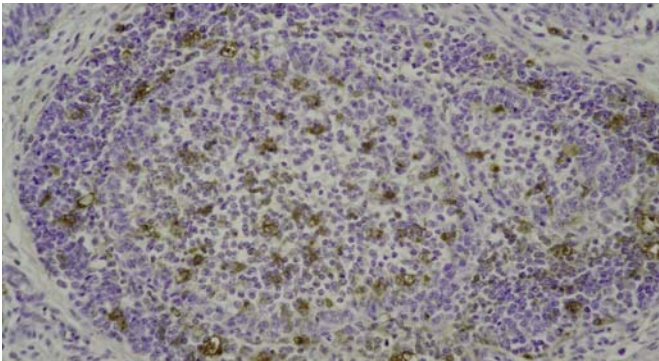


Fig.91.4 & 91.5: Goose circovirus infection. Low magnification image of the BF showing circovirus DNA (labelled brown). Some follicles are heavily infected while others are not. Infected cells are present in both the cortex and medulla of follicles. H&E-stained section of BF adjacent to the section in Fig.91.5.

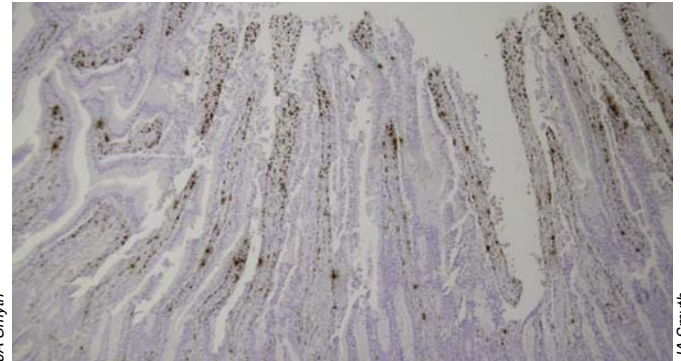
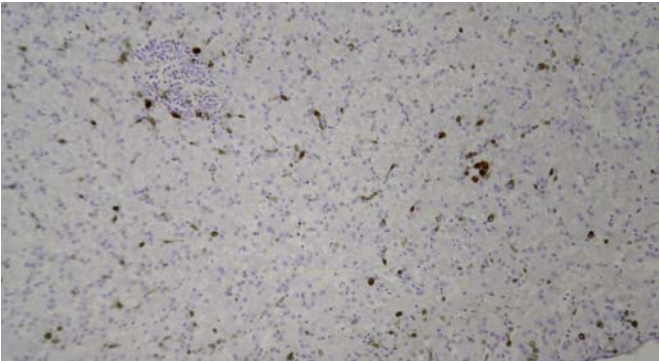


Fig.91.6: Goose circovirus infection. Detection of GoCV DNA using *in situ* hybridization. Circovirus DNA (labelled brown) in the Kupffer cells of the liver.

Fig.91.7: Goose circovirus infection. Detection of GoCV DNA using *in situ* hybridization. Circovirus DNA (labelled brown) in the small intestine.

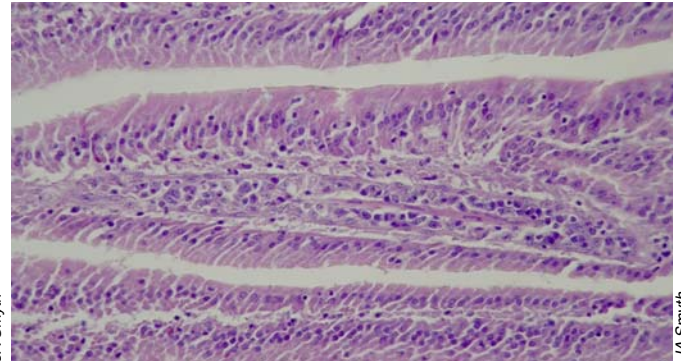
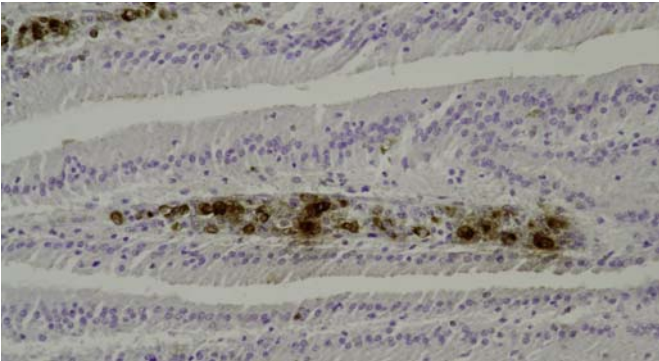


Fig.91.8 & 91.9: Goose circovirus infection. Image of the small intestine showing GoCV DNA (labelled brown). H&E-stained section of small intestine adjacent to the section in Fig.91.9.

Section VI

91. DUCK & GOOSE CIRCOVIRUS INFECTIONS

INTRODUCTION

Circovirus infections in waterfowl have been suspected and demonstrated both in ducks and geese in 1999 and since then, they have been described in Europe, Asia and the Americas.

ETIOLOGY & EPIDEMIOLOGY

Circoviruses are small non enveloped DNA viruses. Several duck species (Pekin, Muscovy and mule ducks) are susceptible to *Duck circovirus* (DuCV). Geese are susceptible to *Goose Circovirus* (GoCV), which is distinct, yet closely related phylogenetically to DuCV. Circoviruses of waterfowl have in common the capacity to invade lymphoid tissues, in particular the bursa of Fabricius and the spleen. Circovirus infections in waterfowl cause immunosuppression, growth retardation, and an increased susceptibility to opportunistic infections such as *Escherichia coli*, *Riemerella anatipestifer* or *Aspergillus fumigatus*. Circoviruses are ubiquitous and very resistant in the environment. Infections are common regardless of the species, but the severity of disease is related to the amount of virus infecting the host.

CLINICAL SIGNS & LESIONS

The clinical picture is that of birds with growth retardation and feathering disorders, in addition to a debilitated appearance associated with immunosuppression. As for circovirus infections in other species, histopathological changes are evident in the lymphoreticular tissues with lymphocytic depletion, particularly in the bursa of Fabricius. Histiocytosis and necrotic lesions are also reported. In general, circovirus is associated with co-infections with other pathogens.

DIAGNOSIS

In the absence of pathognomonic clinical signs, the diagnosis is based mainly on the observation of histopathological changes in the bursa of Fabricius in different species of waterfowl. Drastic lymphocytic depletion should be suggestive of a circovirus infection. Diagnostic tests for GoCV and DuCV are mostly PCR (Polymerase Chain Reaction) based and target tissues are the bursa of Fabricius and the

spleen (tests validated by several laboratories in the Americas, Asia and Europe). A French study has demonstrated the high prevalence of circovirus infection in mule and Muscovy ducks, with around 71% of positive flocks in the field. However, these positive results were not closely correlated with clinical signs or diseases involving other pathogens such as *Riemerella anatipestifer* in mule ducks or parvovirus in Muscovy ducks. Barn sanitary conditions, flock management and other risk factors likely play an important role in the expression of the disease, including on the impact of co-infections following circovirus induced immunosuppression.

TREATMENT & CONTROL

There is no treatment when the disease is confirmed and no vaccine is available on the market to prevent circovirus infection in ducks. Standard biosecurity measures are recommended for the prevention of circovirus infections and co-infections.

REFERENCES

- Banda A et al. Genetic Analysis of a Duck Circovirus Detected in Commercial Pekin Ducks in New York. *Avian Dis*, 2007,51:90-95.
- Chen CL et al. Development of a Polymerase Chain Reaction Procedure for Detection and Differentiation of Duck and Goose Circovirus. *Avian Dis*, 2006,50:92-95.
- Fringuelli E et al. Diagnosis of duck circovirus infections by conventional and real-time polymerase chain reaction tests. *Avian Pathol*, 2005,34:495-500.
- Palya V et al. Diagnostic et recherché des infections à circovirus dans les élevages de canards français. *7èmes journées de la recherche sur les palmipèdes à foie gras*, Arcachon, 16-18 octobre 2006, pp58-61.
- Smyth J et al. Circovirus-infected geese studied by in situ hybridization. *Avian Pathol*, 2005,34:227-232.
- Soike D et al. Novel circovirus in mulard with developmental and feathering disorders. *Vet Rec*, 2004,154:792-793.
- Zhang X et al. An investigation of duck circovirus and co-infection in Cherry Valley ducks in Shandong province, China. *Vet Microbiol*, 2009,133:252-256.



Fig.92.1, 92.2 & 92.3: Ma ducks (shelducks).

L Lu

L Lu

Z Liang



Fig.92.4 & 92.5: Diseased Pekin ducks from infection with signs of paralysis.

D Zhang

D Zhang

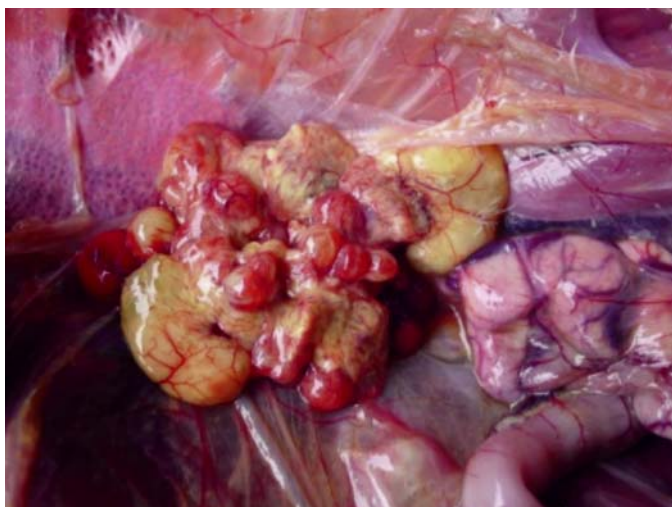
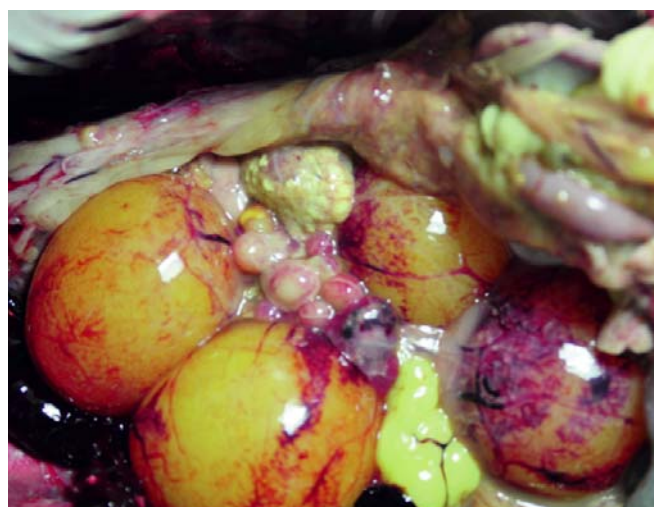


Fig.92.6 & 92.7: The main pathologic changes observed consistently in almost all diseased ducks are found in the ovaries: hyperemia, hemorrhage, degeneration and distortion. (Fig.92.6: Experimentally infected Pekin duck. Fig.92.7: Experimentally infected Shaoxing Ma duck).

D Zhang

D Zhang

92. TEMBUSU VIRUS INFECTION OF DUCKS

INTRODUCTION

Tembusu virus (TMUV) infection is an acute disease of ducks, characterized by a sudden onset and quick spreading through the flock, a severe drop in egg production, and by severe hemorrhage and degeneration of ovarian follicles. The disease is of significant economic importance to egg-laying and breeder duck farms.

ETIOLOGY

The causative agent of the disease was first isolated in chicken embryos, during late spring and early summer in 2010, when an emerging disease in egg-laying ducks was investigated in China. Based on the high nucleotide sequence identity (> 84%) of the agent with mosquito- and chicken-origin TMUV isolates from Malaysia and Thailand, the agent was considered to be an isolate of TMUV, a mosquito-borne flavivirus of the Ntaya virus group. The assessment was performed in an approximately 1-kb region at the 3' terminus of the NS5 gene, which was defined as the criteria for species of the members of the genus *Flavivirus*.

Duck- and goose-origin TMUVs have been estimated to be approximately 45 nm in diameter and their genomes have been determined to be a 10990-nt positive sense RNA molecule. The genome contains a large open reading frame (ORF), encoding a putative polyprotein of 3425 amino acids, which is flanked by 5' and 3' non-coding regions. The polyprotein is predicted to be translationally cleaved into three structural proteins [capsid (C), membrane (M), and envelope (E)] and seven nonstructural proteins (NS1, NS2a, NS2b, NS3, NS4a, NS4b, and NS5). Chinese TMUV isolates have a closer phylogenetic relationship with Thailand isolates than Malaysian isolates.

The TMUV can be grown in embryonated chicken, duck, and goose eggs as well as various cell cultures, including primary DEF (duck embryo fibroblast) cells, DF-1 cells, Vero cells, BHK-21 cells, and mosquito cells (C6/36). In 2000, Kono et al. reported that the embryonated chicken egg-adapted chicken-origin TMUV (Sitiawan strain) can be grown in BK3 cells (transformed chicken B lymphocytes by avian leukosis virus), CPK (cloned

porcine kidney) cells, MARC-145 cells, and CEF (chicken embryo fibroblast) cells.

EPIDEMIOLOGY

Tembusu virus-associated disease occurs mainly in laying ducks and breeders during the laying period. The virus is highly pathogenic for adult Pekin ducks, shelducks (known as Ma ducks in China), and wild ducks. Muscovy ducks are resistant. Tembusu virus has been associated with cases of encephalitis and retarded growth in broiler chicks, and is believed to be causing a disease in adult geese similar to the one seen in ducks. Experimental infections in ducklings and goslings have been reported.

As the firstly reported natural host of TMUV, mosquitoes might be involved in the spread of this virus. TMUV has also been detected in sparrows, suggesting wild birds may play a role in the spread of the disease. Infected ducks shed virus via feces, suggesting probable horizontal transmission through feces-contaminated grounds, litter, water, feed, equipment and vehicles. Under field conditions, the disease spreads rapidly to all susceptible ducks in the flock, indicating that a direct duck-to-duck transmission cannot be completely excluded.

The disease can be reproduced by experimental infections via oral administration, nasal drip, intramuscular and intravenous injections. The virus can be easily detected in *theca folliculus* samples, suggesting that reproductive tissues may be a major site for viral persistence, replication, or both.

Although the disease may occur throughout the year, a higher incidence has been reported in summer and autumn. In an affected duck flock, morbidity is usually high (up to 90%), whereas mortality is generally low.

The duck disease associated with TMUV infection has only been described in China so far.

CLINICAL SIGNS & LESIONS

The disease is characterized by a sudden onset. The spread of the disease in a duck flock is very rapid, with practically all signs being observed within 2-3 days. The first clinical sign is a significant reduc-

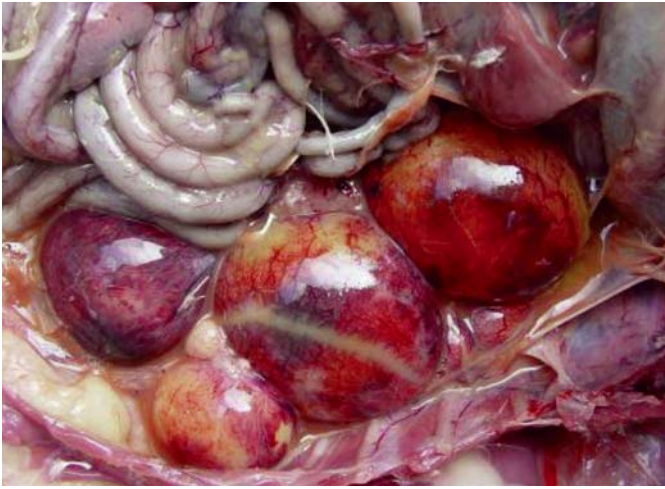

Fig.92.8: Naturally infected Pekin duck. The main pathologic changes observed consistently in almost all diseased ducks are found in the ovaries: hyperemia, hemorrhage, degeneration and distortion.

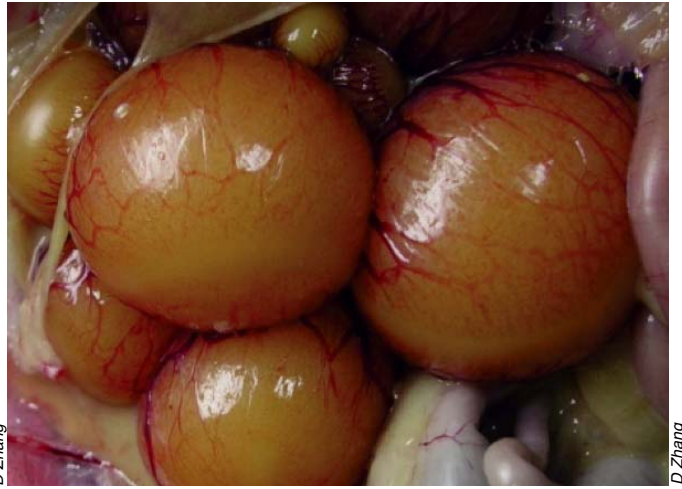


Fig.92.9: Ovary from healthy duck.

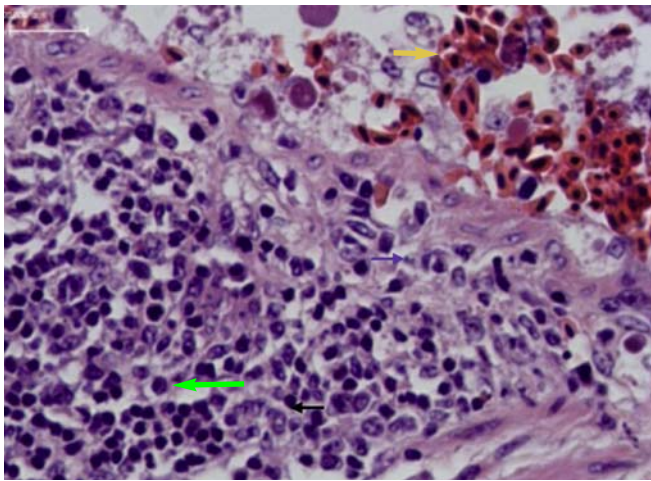


Fig.92.10: Naturally infected Pekin duck. Ovary with hemorrhage (gold arrow), macrophage and lymphocyte infiltration and hyperplasia (green arrow).

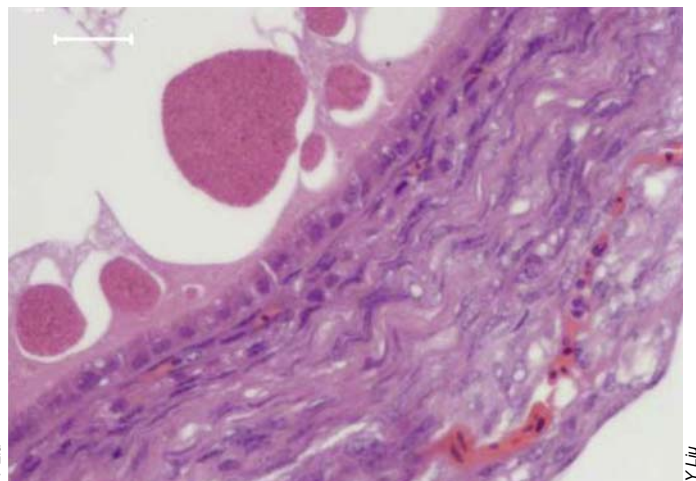


Fig.92.11: Ovary from healthy duck.

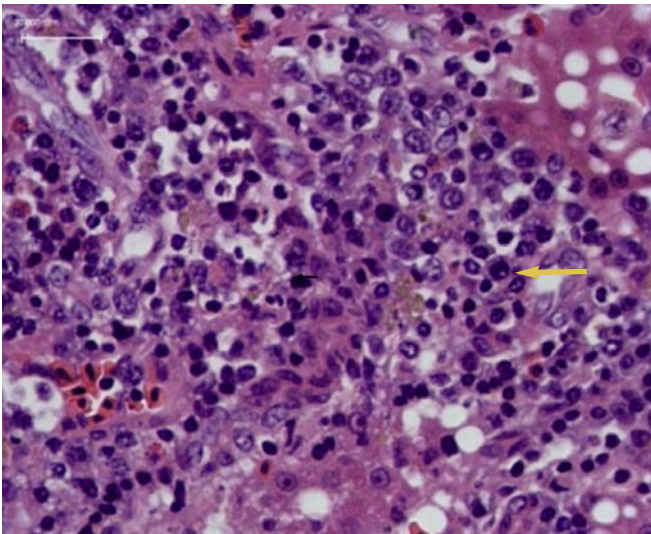


Fig.92.12: Naturally infected Pekin duck. Liver with interstitial inflammation in the portal area (gold arrow).

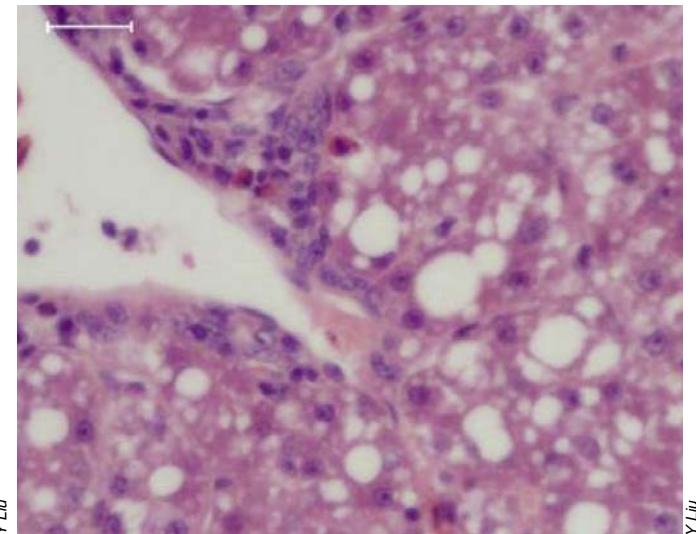


Fig.92.13: Liver from healthy duck.

tion in feed intake, followed by a severe drop in egg production. Within approximately one week after disease onset, feed intake drops by more than 70% and egg production rate may go down to 10% or less. Other frequent signs include acute anorexia, antisocial behavior, rhinorrhea, diarrhea, and ataxia. Some cases exhibit signs of paralysis.

The main pathologic changes observed consistently in almost all diseased ducks are found in the ovaries: hyperemia, hemorrhage, degeneration and distortion. Microscopic changes consist of macrophage, lymphocyte infiltration and hyperplasia. Interstitial inflammation in the portal area of the liver may also be seen.

DIAGNOSIS

A presumptive diagnosis of TMUV infection in ducks can be made based on clinical features and necropsy findings. Sudden onset, rapid spread, severe reduction in egg production within about one week, and the pathologic changes in the ovaries are suggestive of TMUV infection. Definitive diagnosis should be made by isolation and identification of the causative agent.

Virus isolation

The virus can be isolated by inoculation of clarified *theca folliculus* suspension into the allantoic cavities of embryonated chicken eggs (aged 9-10 days) or duck eggs (10-11 days). The embryos should die 72–120 hours after inoculation, and severe cutaneous hemorrhages should be observed. Sometimes, no deaths may be detected in the primary culture; two to three passages may be of help for virus isolation. The mortality of embryos tends to increase with passages. Specimens of cloacal swabs, intestinal contents, brain, and liver can also be used as inoculums.

Experimental infections

Inoculation of virus isolates into 3-5 susceptible Ma ducks or Pekin ducks during the laying period is made via subcutaneous and intramuscular injection, oral administration or nasal drip. The characteristic clinical signs and pathologic changes should be reproduced within 3-4 days. The TMUV-specific RNA should be detected by RT-PCR, and the TMUV should be again isolated from the experimentally infected ducks.

Molecular detection

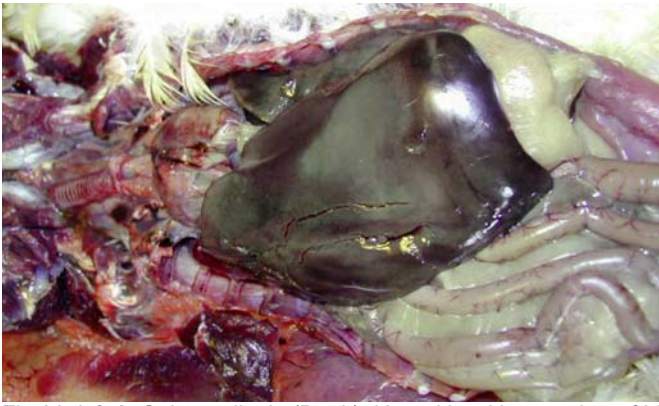A rapid diagnosis of TMUV infection can be made using reverse transcription (RT)-PCR for detection of TMUV-specific RNA in clinical specimens and virus isolates. An indirect ELISA based on recombinant E protein has been developed for rapid detection of TMUV-specific antibodies in duck serum samples.

TREATMENT & CONTROL

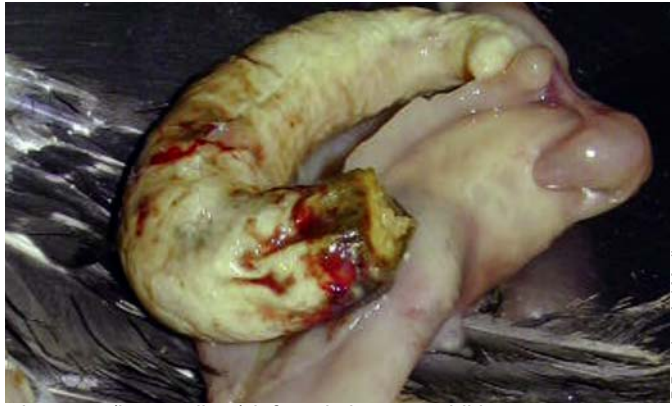There are no vaccines developed for protection of ducks from TMUV infection. Attempts to develop TMUV-specific vaccines are currently underway. However, the better way to prevent TMUV is to implement comprehensive preventative measures such as strict biosecurity, good sanitation, improvement of breeding facilities, monitoring and control of the vector population.

REFERENCES

- Cao Z et al. Primary study on duck hemorrhagic ovaritis. *Chin J Vet Med*, 2010, 46:3-6.
- Cao Z et al. Tembusu Virus in Ducks, China. *Emerg Infect Dis*, 2011,17:1873-1875.
- Huang X et al. Isolation and identification of a novel flavivirus strain JS804 in geese. *Jiang su J Agr Sci*, 2011,27:354-360.
- Kono Y et al. Encephalitis and retarded growth of chicks caused by Sitiawan virus, a new isolate belong to the genus Flavivirus. *Am J Trop Med Hyg*, 2000,63:94-101.
- Kuno G et al. Phylogeny of the genus Flavivirus. *J Virol*, 1998,72:73–83.
- Su J et al. Duck egg-drop syndrome caused by BYD virus, a new Tembusu-related flavivirus. *PLoS ONE*, 2011, 6(3): e18106. doi:10.1371/journal.pone.0018106.
- Tang Y et al. Characterization of a Tembusu virus isolated from naturally infected house sparrows (*Passer domesticus*) in Northern China. *Transbound Emerg Dis*, 2012,20:1-7.
- Yan P et al. An infectious disease of ducks caused by a newly emerged Tembusu virus strain in mainland China. *Virology*, 2011,417:1-8.
- Yun T et al. Complete genome sequence of a novel flavivirus, duck Tembusu virus, isolated from ducks and geese in china. *J Virol*, 2012,86:3406-3407.
- Yun T et al. Identification and molecular characterization of a novel flavivirus isolated from Pekin ducklings in China. *Vet Microbiol*, 2012,157:311-319.

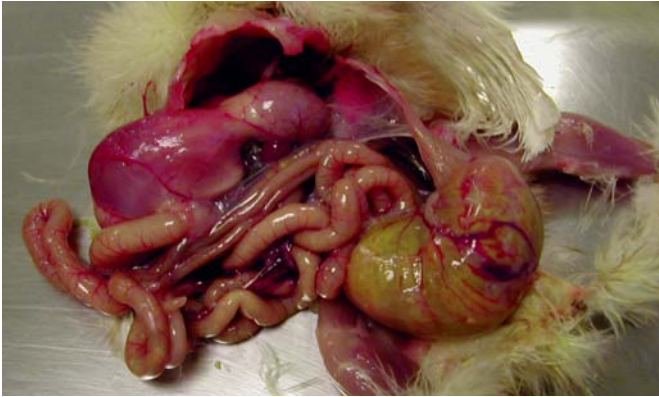


P. Baloché - Ani-Medic

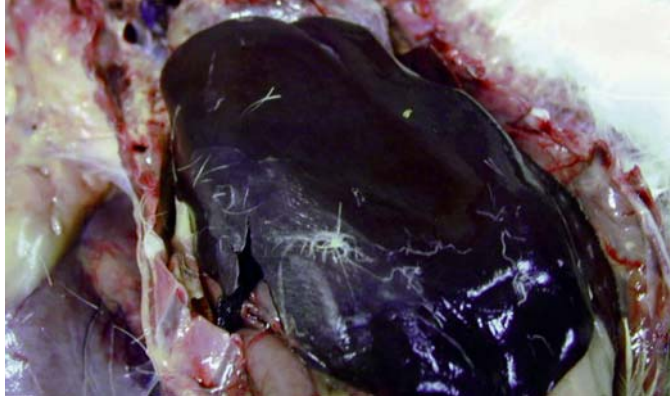


P. Baloché - Ani-Medic

Fig.93.1 & 2: Salmonellosis (Duck). Hepatitis with retention of bile pigments (bronze liver) left and cheesy typhlitis.



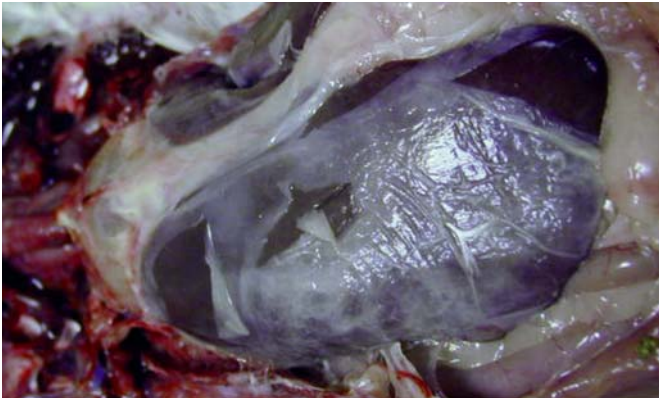
P. Baloché - Ani-Medic



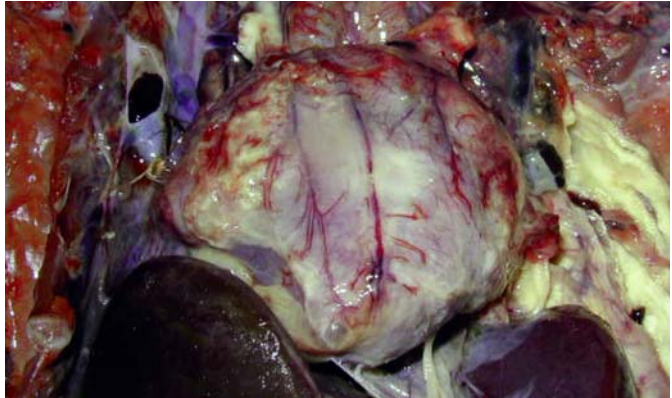
P. Baloché - Ani-Medic

Fig.93.3: Colibacillosis (Duck). Retention of yolk sac.

Fig.93.4: Colibacillosis (Duck). Hepatitis.



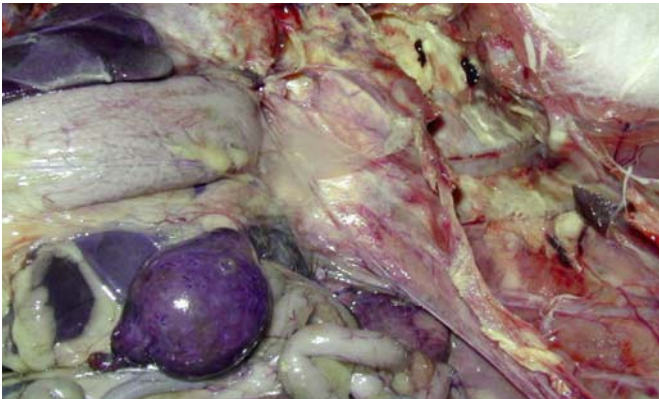P. Baloché - Ani-Medic



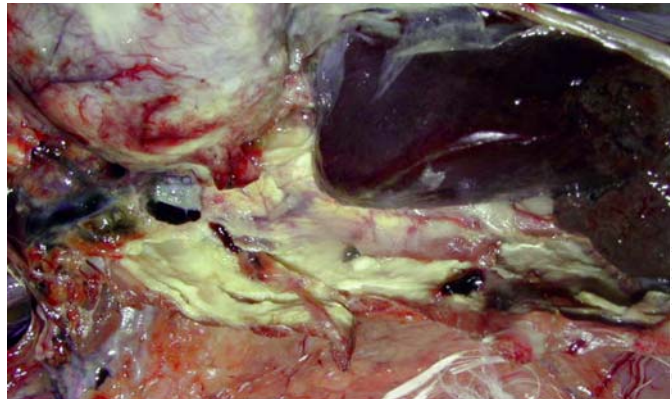
P. Baloché - Ani-Medic

Fig.93.5: Colibacillosis (Duck). Perihepatitis.

Fig.93.6: Colibacillosis (Duck). Pericarditis.



P. Baloché - Ani-Medic



P. Baloché - Ani-Medic

Fig.93.7: Colibacillosis (Duck). Splenomegaly and peritonitis.

Fig.93.8: Colibacillosis (Duck). Peritonitis.

Other species

93. BACTERIAL DISEASES OF DUCKS

INTRODUCTION

There are two types of production:

1) Production of duck meat represented by the Muscovy duck (*Cairina moschata*), male or female; French production represents more than 50% of the European production.

2) Production of fattened ducks, mainly dominated by the fattening of mule ducks, a hybrid resulting from crossing a male Muscovy duck and a common female duck (*Anas domesticus*).

Bacterial diseases occur in both types of production, mainly after 3 weeks of age. However, some diseases may be observed at placement.

BACTERIOSIS BEFORE 3 WEEKS OF AGE

As for other species, there are omphalitis and *Salmonella* infections.

Omphalitis

Egg yolk infection can occur at hatching under conditions of excessive moisture. In 90% of cases, *Escherichia coli* are involved. Other pathogens include *Pseudomonas* spp., *Klebsiella* spp. and possibly *Salmonella* spp. Mortality appears within three days after hatching. A persistent greenish smelly yolk is observed. Diagnosis is confirmed by laboratory isolation of the pathogen(s) involved.

Infections with *Salmonella* (see Chap.III.43 & III.44)

These enterobacteria can cause problems with mortality in young ducklings in flocks infected with viruses (reovirus, parvovirus, *etc.*) and/or subjected to stresses (e.g., cold conditions). *Salmonella* Typhimurium is most frequently isolated, but other serovars may also be involved: *S. Enteritidis*, *S. Virchow*, *S. Hadar*, *S. Indiana*, *etc.*

When transmission is vertical, mortality can occur between 2 and 10 days of age. When horizontal transmission occurs, mortality may be observed in older birds. A septicemic form resulting in diarrhea

and conjunctivitis rapidly leads to death. Possible lesions include fibrinous pericarditis, perihepatitis, miliary foci of necrosis in the liver and spleen, as well as a fairly typical caseous typhlitis. In less acute cases, clinical signs such as lameness, diarrhea, and purulent conjunctivitis are reported.

BACTERIOSIS AFTER 3 WEEKS OF AGE

Colisepticemia (see Chap.III.45)

Ducks of all ages are susceptible to infection by pathogenic strains of *Escherichia coli*.

Septicemic colibacillosis results in a marked congestion of the liver, spleen, lung and kidney, as well as a fibrinous pericarditis and airsacculitis accompanied in some cases by a fibrinous perihepatitis.

Morbidity in some cases can reach 50% and mortality 5% if effective antibiotherapy is not quickly initiated. Isolation of the pathogen in pure culture from liver or spleen samples confirms the diagnosis.

Colisepticemia must be differentiated from riemerellosis.

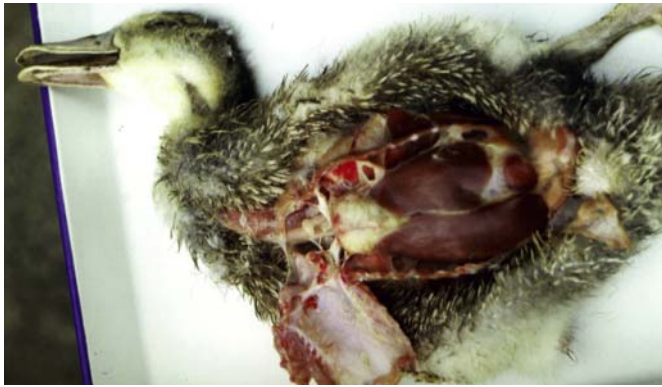***Riemerella anatipestifer* Infection** (see Chap.III.49)

Riemerella anatipestifer infection (RAI) is also known as *Pasteurella anatipestifer* infection, infectious serositis and New Duck disease.

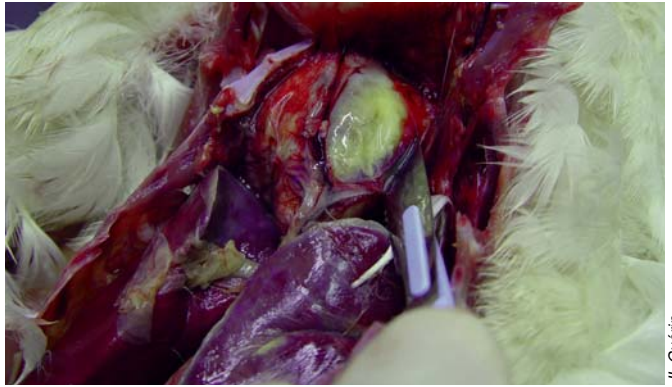
The importance of RAI has grown substantially in mule ducks in parallel with the intensification of fattened duck production.

The classification into serovars based on agar gel precipitation tests has resulted in the designation of over 20 different serotypes. Serotypes most frequently isolated in France are serotypes A, 9, 1 and 2. Within a given serotype, virulence can vary greatly depending on the isolate.

Under field conditions, the pathogen enters *via* the transcutaneous route (footpad lesions or beak) or *via* the pulmonary route.



A Vuillaume

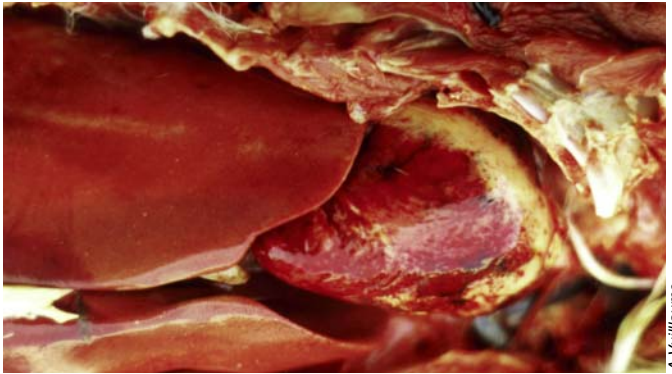


JL Guénin

Fig.93.9 & 93.10: Riemerellosis (Duck). Fibrinous pericarditis and perihepatitis.

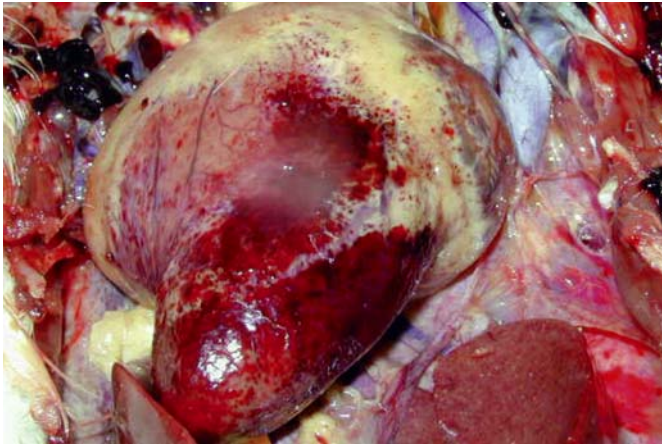


A Vuillaume

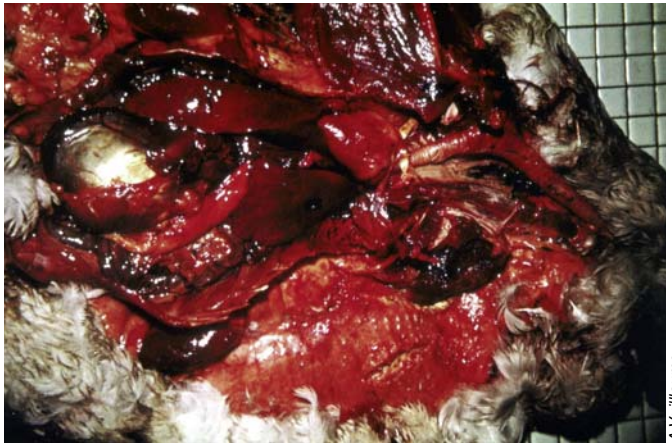


A Vuillaume

Fig.93.11 & 93.12: Cholera (Duck). Hemorrhagic lesions on the epicardium and necrotic foci in the liver.

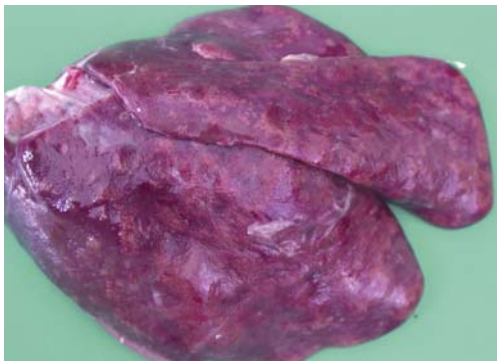

P Balboche - Ani-Medic

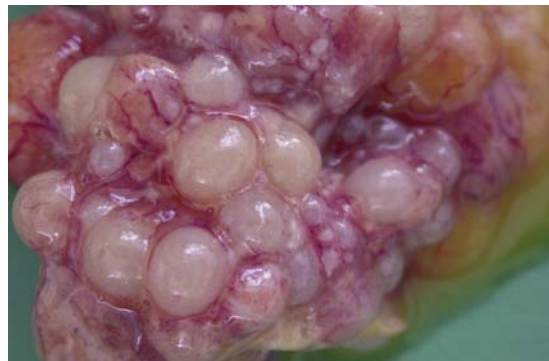

A Vuillaume

Fig.93.13 & 93.14: Cholera (Duck). Sepsis and severe bleeding lesions on the epicardium characterizing a hyperacute evolution.



MT Casaubon Huguerin



MT Casaubon Huguerin

Fig.93.15 & 93.16: Formerly called *Pasteurella anatis*, *Gallibacterium anatis* can affect chicken layers, ducks, geese and ostriches. They will be responsible for sepsis, respiratory disease, severe conjunctivitis and lesion of the reproductive tract causing drops in egg production. Sometimes only an 18 to 85% egg drop is observed. Multifocal necrotic hepatitis (left) and degeneration of the ovary (right).

Clinical signs of RAI are observed between 3 and 5 weeks of age. Average mortality is 7% (ranging between 3 and 24%). The classic form is manifested by marked prostration, incoordination, leg weakness, falling backwards, nervous disorders, shaking of the head and twisted neck. Nonspecific respiratory signs (coughing, runny nose and eyes) are also noted. Death occurs suddenly or after a few days after the onset of clinical signs.

Lesions of polyserositis are observed with fibrinous exudate in the pericardial cavity and on the liver. Pneumonia may occur and a fibrinous airsacculitis is more pronounced near the lungs. Infection of the central nervous system may produce a fibrinous meningitis. A moderate splenomegaly can be seen. Affected females may develop a mucopurulent or caseous salpingitis. Disease duration, in association with secondary infectious pathogens such as *Escherichia coli* can intensify fibrinous lesions.

Mortality occurring during the rearing period partly explains economic losses. The mortality rate of ducks ready for force-feeding doubles during the gavage period. The quality of *foie gras* is also affected.

Disease control is based on proper antibiotherapy. Inactivated homologous vaccines may be used. The success of this strategy rests on using the right serotype for a given farm as well as early vaccination before 15 days of age in order to protect ducklings before they become susceptible to the disease.

Prevention must also include biosecurity measures: improving rearing conditions, reducing stress, improved litter condition and slatted flooring, and optimization of disinfection procedures.

Pasteurellosis or cholera (see Chap.III.46)

Pasteurellosis is the oldest bacterial disease identified that can affect most species of domestic and wild birds. In duck production, it is a common condition during the rearing period and at the time ducks are ready for gavage.

The antigenic diversity of strains of *Pasteurella multocida* and weak cross-protection between field

strains require the characterization of *Pasteurella* isolate obtained from clinical cases. It is based on somatic typing. An experimental pathogenicity test may be carried out by intramuscular injection of 10^8 bacteria at the age of 9 weeks.

Pasteurellosis can be observed in flocks from 4 weeks of age and throughout rearing and force-feeding. Micro-environmental stressors (e.g., cold temperature, wide temperature variations) trigger the multiplication of the pathogen in the bird's upper respiratory tract. Transportation and force-feeding are also major stressors.

Two clinical forms are described:

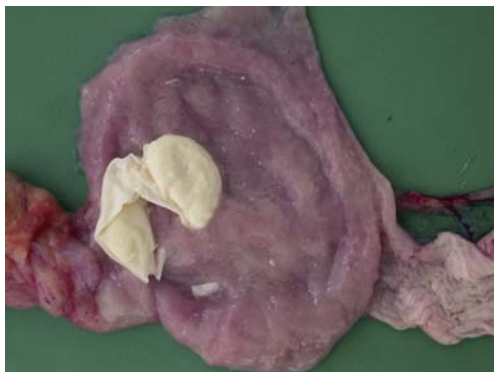- 1) The peracute form is fulminating, causing vascular lesions: diffuse congestion of the carcass with the epicardium constantly bleeding. Bleeding on the muscles, liver and/or lung can also be seen inconsistently. At the microscopic level, thrombi obstruct the veins and arteries of the lungs, liver, kidneys, spleen and brain.
- 2) In the acute form, the disease process may last 1 to 5 days, with signs of depression, cyanosis of the head and diarrhea.

The lesions are highly suggestive of the disease: extensive hemorrhage of the epicardium, liver initially dotted with hemorrhagic lesions then turning necrotic, mucoid content of the intestine.

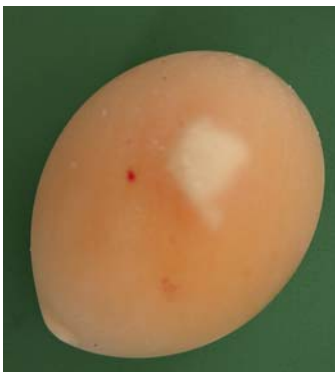
The differential diagnosis should always include intoxications, erysipelas (marked splenomegaly) and colibacillosis. The diagnosis is based on isolation of the bacterium from a blood culture taken from the heart or liver.

If the disease is suspected, antibiotic treatment by injection must be initiated and followed by oral medication. Successful treatment normally stops mortality within a day, but relapse may occur within days following cessation of treatment.

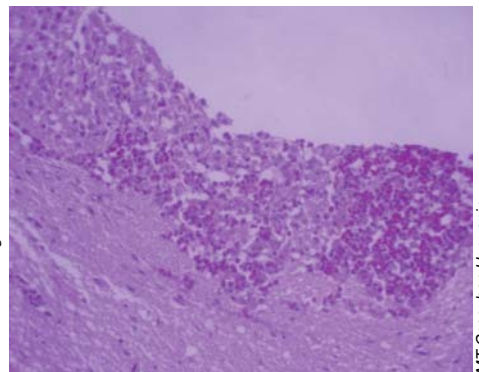
Vaccination using inactivated vaccines administered twice four weeks apart from the age of three weeks can in most cases prevent pasteurellosis. Commercial vaccines combining 3-4 strains are recommended. In case the field strain is different from the commercial vaccine, an inactivated autogenous vaccine can be considered.



MT Casaubon Huguenin



MT Casaubon Huguenin



MT Casaubon Huguenin

Fig.93.17, 93.18 & 93.19: *Gallibacterium anatis*. Involvement of the genital tract results in caseous deposits that can be observed in the uterus (Fig.93.17) and even in the egg albumen (Fig.93.18). Meningitis can also be observed (Fig.93.19).

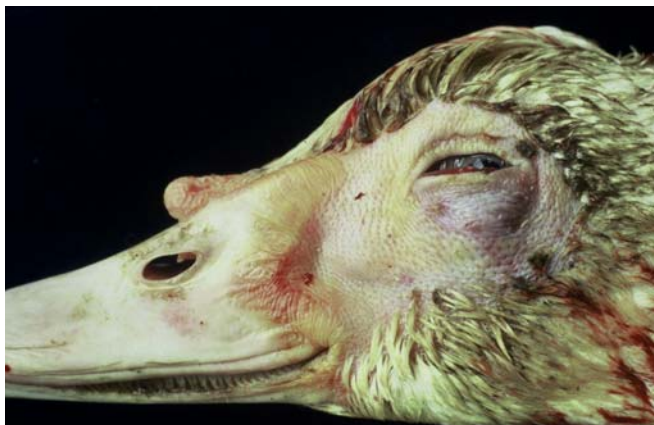


JY Ferré

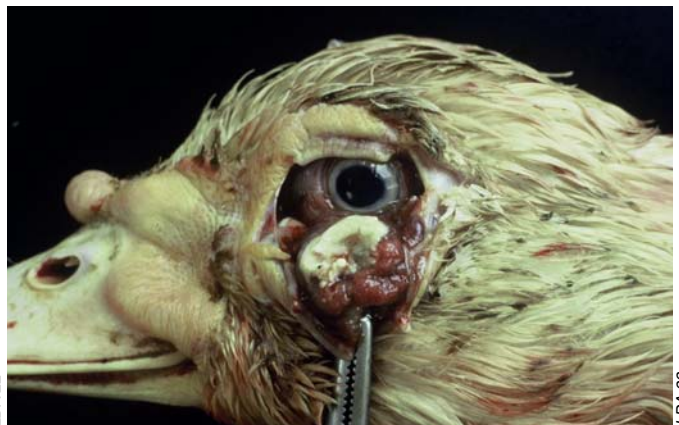

JY Ferré

Fig.93.20 & 93.21: Botulism (Duck). Flaccid paralysis.



LDA 22



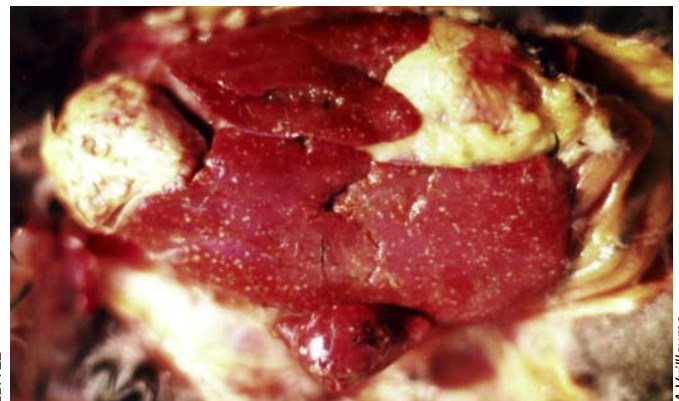LDA 22

Fig.93.22 & 93.23: Yersiniosis (Duck). Sinusitis and conjunctivitis. Presence of a yellowish caseous exudate at the opening of sub-orbital sinuses.



LDA 22

Fig.93.24: Yersiniosis (Duck). Splenomegaly. Compared with the normal spleen on the right.



A Vuillaume

Fig.93.25: Yersiniosis (Duck). Hepatitis with small foci of necrosis.

Chlamydiosis (see Chap.III.40)

Chlamydiosis is due to *Chlamydia psittaci* and is pathogenic for ornamental birds including *Psittacidae* but also for domestic poultry.

In France, the regular discovery of human cases requiring hospitalization especially in the duck industry justified the introduction of the disease on a list of notifiable animal diseases. Investigations in this country have shown that in excess of 50% of mule duck flocks were infected.

Chlamydia psittaci is an obligate intracellular bacterium multiplying by binary fission after phagocytosis in the cytoplasm of the host cell. Eight serovars including six in birds have been identified to date. Among these, serovar C was isolated in ducks, turkeys and partridges, and serovar E was isolated in ducks, pigeons and ostriches with severe clinical signs.

However, often ducks are asymptomatic carriers or show mild upper respiratory signs (e.g., spitting, conjunctivitis, etc.).

Acute clinical forms can also be seen with depression, diarrhea, weight loss, severe respiratory

disorders (dyspnea, mucopurulent nasal discharge) and conjunctivitis with crusts on the eyelids, and finally nervous disorders (head tremors, torticollis, opisthotonos, convulsions).

In the case of an acute progression of the disease, the lesions are splenomegaly, hepatomegaly with small necrotic foci and pericarditis, fibrinous perihepatitis and airsacculitis.

Lesions are not specific and confirmation of diagnosis requires laboratory testing.

Treatment is with tetracyclines and should be prescribed for several weeks to ensure clinical recovery. Note, however, that such treatment does not prevent the presence of shedders and carriers within an infected flock.

REFERENCES

Abadia G. Chlamydoophilose aviaire, une zoonose professionnelle. *Bull Acad Vét de France*, 2004,157:37-44.

"*Diseases of poultry*", Ed. Swayne DE, 13th ed., Wiley-Blackwell Publ. 2013.

Euzeby JP. Dictionnaire de Bactériologie Vétérinaire www.bacdico.net

Thibault E. Laboratoire BIOVAC *Communications personnelles*.

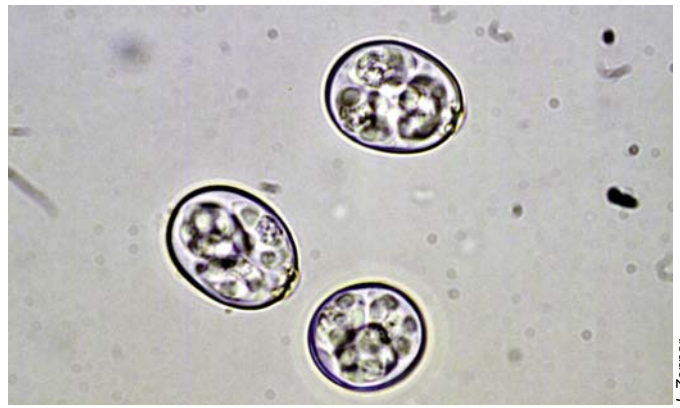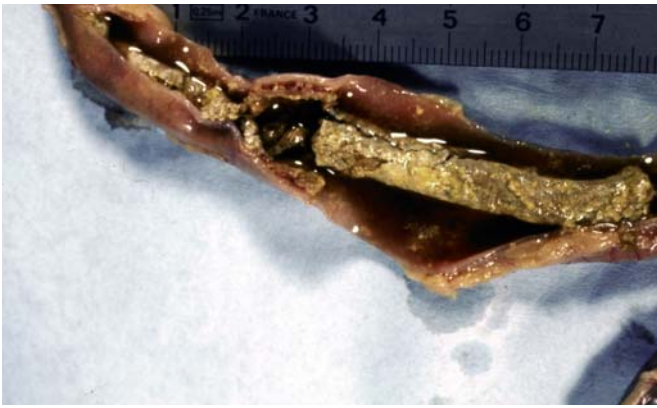


Fig.94.1 & 94.2: *Eimeria mulardi* (Mule duck). Lesions of the jejunum and ileum (left) and sporulated oocysts (right).

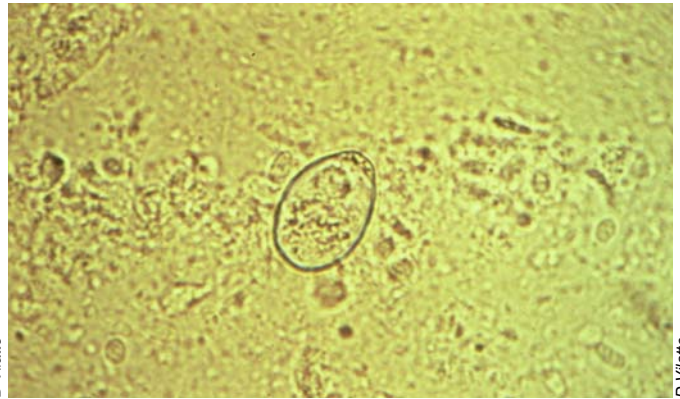
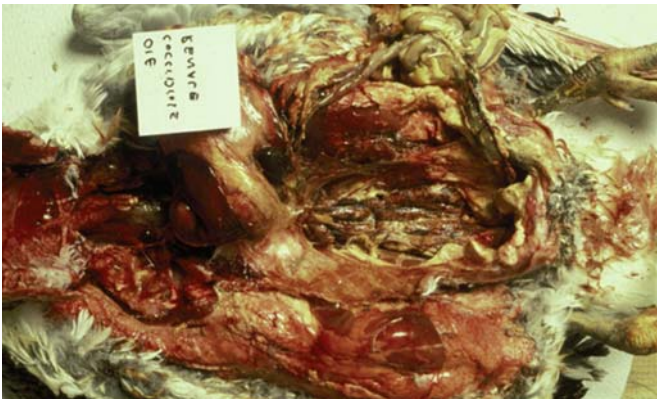

Fig.94.3 & 94.4: *Eimeria truncata* (Goose). This particular coccidiosis of geese is localized in the kidney (left). The kidneys are enlarged and dotted with whitish areas corresponding to schizonts. The non-sporulating oocyst (right) is 15 µm x 22 µm.

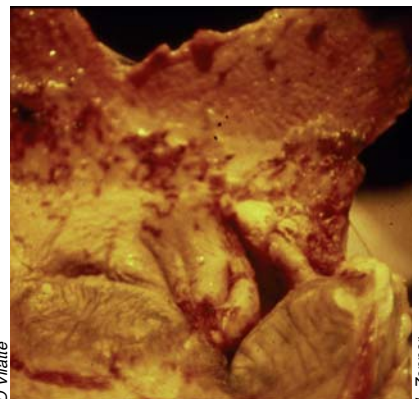
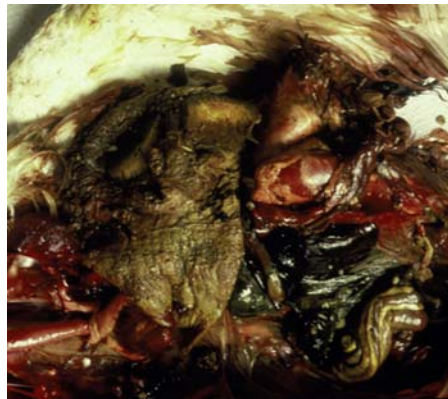
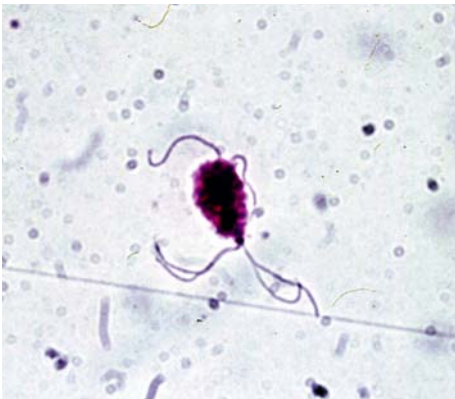
Fig.94.5: *Tetratrichomonas gallinarum* identified by direct microscopic examination of smears in ducks. Fig.94.6 & 94.7: *Amidostomum anseris* (Goose). Parasites cause lesions of the gizzard and anemia. Geese have digestive disorders and rapid weight loss.

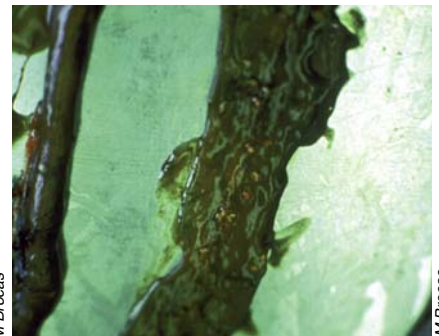
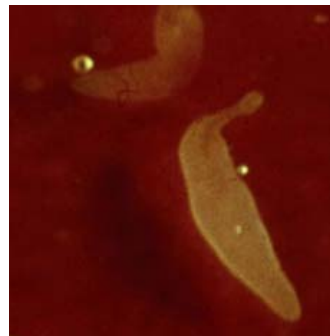
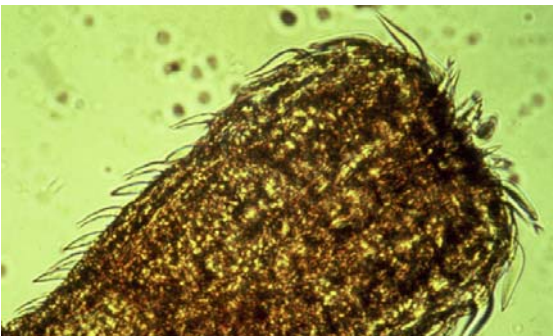


Fig.94.8, 94.9 & 94.10: *Polymorphus (Echinorhynchus)* spp. This parasite is an acanthocephalan, thorny-headed worm (Fig.94.8). Small adult worms have a characteristic orange color (Fig.94.9), making them fairly easy to see in the intestinal content (Fig.94.10).

Section VI

Other species

94. WATERFOWL PARASITOSEs

INTRODUCTION

Parasites of waterfowls are less known than those of chickens. Moreover, geese and domestic ducks may be contaminated by migratory birds.

INTERNAL PARASITES

Protozoa

Coccidiosis. In all duck species combined, 30 different coccidia have been described worldwide. *Coccidia* are generally considered relatively non-pathogenic in ducks because they are found in the superficial epithelium of the intestine. However, *Tizzeria pernicioso* is pathogenic because of its deeper penetration into the intestinal mucosa of common or mule ducklings less than four weeks old. Hemorrhagic enteritis can occur with a mortality rate of 70%. *Eimeria mulardi* is also pathogenic for mule ducks. In geese, *Eimeria truncata* causes a renal coccidiosis.

Trichomoniasis. *Tetratrichomonas anatis* is directly transmitted through the ingestion of contaminated water. The parasite is found mainly in the ceca, large intestine and cloaca. The infection is mostly asymptomatic but it is possible to observe locomotor problems in affected flocks. Similarly, *T. gallinarum* is very frequently encountered in ducks and seems nonpathogenic. However, it may play a role in imbalanced intestinal flora.

Cestodiasis

Ducks are often infected with adult tapeworms found in wildlife. Some tapeworm species are shared between ducks and chickens. Several genera and species are found, but the genera *Fimbrairia* and *Hymenolepis* more frequently observed. In cases of massive infestation, one can observe growth retardation, diarrhea and/or anemia.

Nematodiasis

Capillariosis. *Capillaria contorta* and *C. anatis* are responsible for capillariosis in ducks, respectively in the crop and ceca. These nematodes are not pathogenic but a heavy infestation by *C. contorta*

may cause dysphagia and local inflammation in the crop and esophagus.

Ascaridiosis. *Ascaridia galli* can cause enteritis, weight loss, anemia and even nervous signs. A heavy infestation may cause an intestinal obstruction.

Heterakidosis. Two species of *Heterakis* can parasitize ducks: *Heterakis gallinarum*, common to many other species of birds, and *H. dispar*, a parasite of ducks and geese.

Other nematodes. Other nematodes such as *Echinuria uncinata*, *Amidostomum anseris*, *Epomidiostomum uncinatum* and *Tetrameres* spp. can parasitize the upper digestive tract of waterfowls. Acanthocephalans can also parasitize the digestive tract. *Cyathostoma bronchialis*, agent of cyathostomosis, is a parasitic nematode found in the trachea and bronchi, causing coughing and dyspnea.

EXTERNAL PARASITES

Ducks may harbor external parasites, especially mites and gray lice. Nevertheless, a healthy duck is unlikely to have external parasites because it washes regularly and carefully preens its feathers. However, if raised with other poultry under poor conditions with limited access to water, ducks are more likely to be exposed. Mites identified in ducks are *Dermanyssus gallinae*, *Ornithonyssus bursa*, and mange causing pathogens. Most often they are located in the neck and head areas. Lice can also parasitize waterfowls.

REFERENCES

- "Diseases of poultry", Ed. Swayne DE, 13th ed., Wiley-Blackwell Publ. 2013.
- Dernburg A et al. Consequences of the withdrawal of dimetridazole on intestinal parasitism in ducks. *Vet. Rec.* 2005,29:148-50.
- Kaufmann J. *Parasitic infection of domestic animals*. A diagnostic manual. Birkhäuser Verlag, Basel, Boston 1996., Berlin.
- Villate D. 1989. *Manuel pratique des maladies des palmipèdes*. Nouvelles Ed. de Publications Agricoles, Paris 1989.

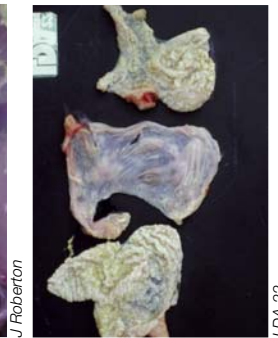
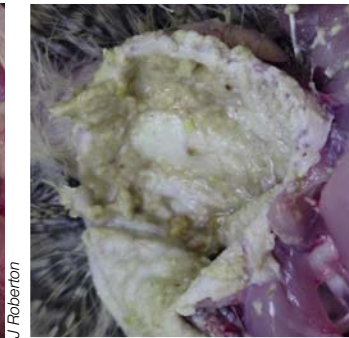
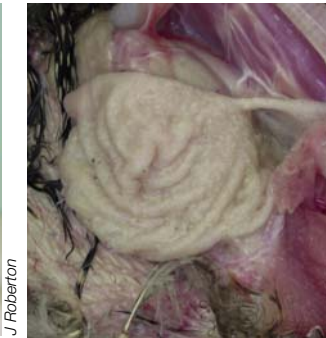

Fig.95.1: Enteritis-chilling syndrome. Young guinea fowls chilled and prostrated.

Fig.95.2, 95.3 & 95.4: Candidiasis – crop mycosis (Guinea fowl). Whitish coating of the mucosa of the crop. Compared with healthy crop in the center of Fig.95.4.

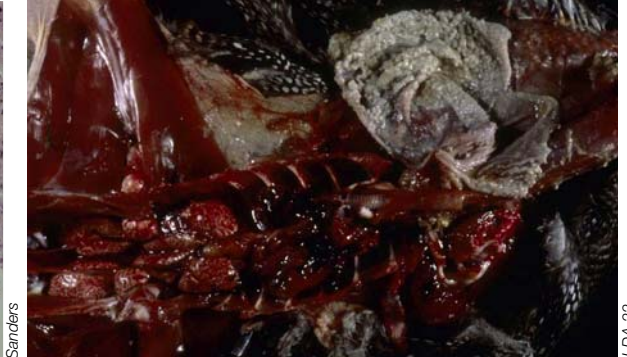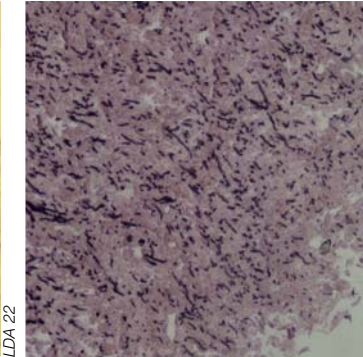
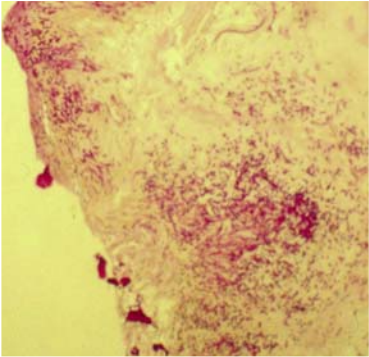


Fig.95.5 & 95.6: Candidiasis – crop mycosis (Guinea fowl). A staining method used to detect polysaccharides of the wall of *Candida albicans* (Periodic acid–Schiff or PAS) shows the presence of yeast on the mucosa of the crop.

Fig.95.7: Candidiasis – crop mycosis (Guinea fowl). The lack of water consumption leads to kidney disease (gout and nephritis).

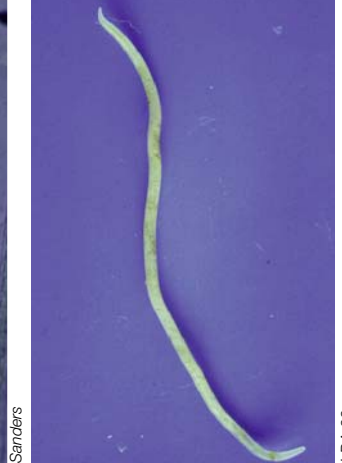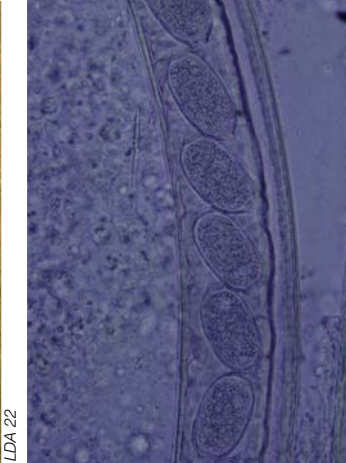
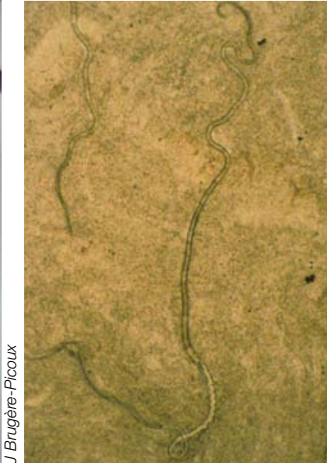

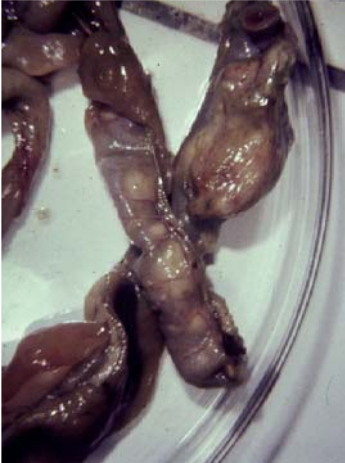
Fig.95.8: Trichomoniasis (Pigeon). In chronic cases, a caseous content is observed in the intestine.

Fig.95.9 & 95.10: *Capillaria* spp. Direct examination of drop-pings (Fig.95.9). Presence of distinctive eggs in a female nematode (Fig.95.10).

Fig.95.11: *Ascaridia galli*.

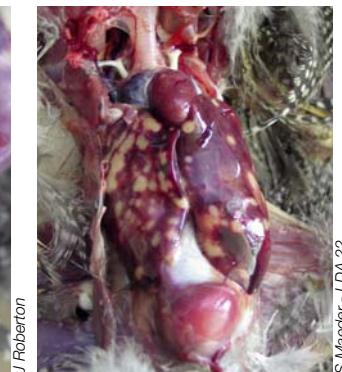
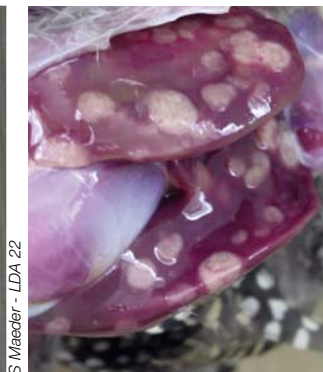
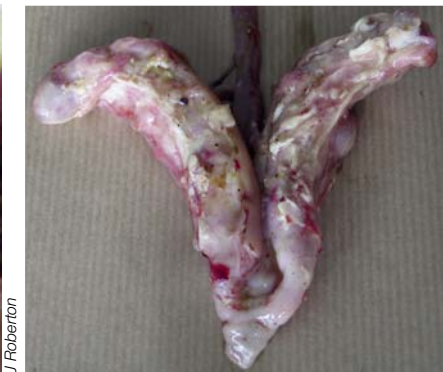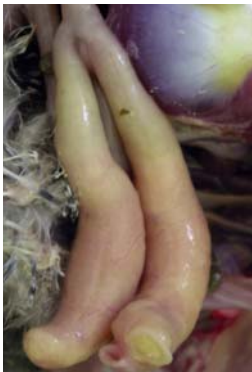Fig.95.12 & 95.13: Histomoniasis (Guinea fowl). Cecal lesions.

Fig.95.14 & 95.15: Histomoniasis (Guinea fowl). Characteristic lesions of hepatic necrosis.

Section VI

Other species

95. GUINEA FOWL PRODUCTION & DISEASES

RAISING GUINEA FOWL

The commercial production of guinea fowls (*Numida meleagris*) is a European peculiarity, France being the main producing country. The production is divided into standard meat production (flocks kept in dark or semi-dark barns), and label production (flocks raised with outdoor access from the age of 6 weeks).

Native of Africa, the guinea fowl remains, in spite of its domestication, a fearful gregarious bird, similar to game birds. It needs more space than a chicken. It is therefore necessary to limit flock density, particularly during the brooding period, by not exceeding 40 birds/m². An average of 16.3 birds/m² is expected at the end of the grow-out period.

Of their natural origins, guinea fowls have retained significant thermal needs, a perching instinct, and a timid behavior that predisposes them to fits of panic. They must therefore be handled carefully. The ambient temperature must be relatively high. The brooding period is sensitive, with a smaller thermoneutral or comfort zone than in chickens (31-33°C). The average temperature of 28°C is maintained until the age of 3 weeks, when it decreases by about one degree per week until the age of six weeks to remain at 25°C until the end of production. As for ambient temperature, the proper management of water quality is essential for successfully starting and raising a flock.

To preserve the quality of the whole carcass, it is advisable to prevent pecking (related to feed deficiencies or competition) and scratches (caused by fits of panic and crowding after a fright). Therefore, efforts should be made to limit stressors as much as possible, by gradually adapting birds to rearing conditions (noises, changes in lighting conditions, etc.). For example, light intensity must be gradually reduced to 5 lux by five weeks of age. A proper lighting program also helps managing the growth rate of the flock. Guinea fowls are slaughtered near the age of sexual maturity. Perches (one meter for 10 birds) may be installed from the age of 6 weeks.

DISEASES OF GUINEA FOWLS

About 50% of all pathological conditions affecting guinea fowls occur within the first four weeks of life, with a high incidence of digestive disorders. The guinea fowl is a minor species for which there

are no specific drugs except parconazole. Medications indicated for the species *Gallus* can be used with the constraint of a long withdrawal time for meat and offals (e.g., 28 days in France).

Gastrointestinal diseases

Enteritis-chilling, enteritis-mortality, or transmissible gastroenteritis syndrome. Described in 1970, this disease occurs around the age of 8-20 days. Young guinea fowls are chilled, prostrated, eat little, and are usually found grouped under a heat source with droopy wings. The litter is dirty and wet. Lesions observed include catarrhal enteritis with a white mucosa, distended ceca with liquid, yellowish content, as well as signs of dehydration and malnutrition (nephritis, visceral urate deposits, soft bones, muscle atrophy). Suspicion of a viral origin seems to be confirmed since 2005 with the high incidence of cases involving the presence of astrovirus, reminiscent of the "Poult enteritis mortality syndrome" or PEMS. Only a strict biosecurity program can prevent this infection.

Candidiasis (also known as crop mycosis caused by *Candida albicans*). Guinea fowls are particularly susceptible to candidiasis, especially following an antibiotic treatment. Palpation reveals an empty crop. Birds are most susceptible between three and six weeks of age. A whitish coating of the mucosa of the crop is observed. The wall of the crop may be thickened. This yeast deposit may cover the esophagus and the proventriculus. Parconazole in the feed at the curative level of 12 mg/Kg of body weight (approximately 60 ppm) is an effective fungicide treatment against candidiasis in guinea fowl.

Coccidiosis. Guinea fowl coccidiosis due specifically to *Eimeria numidae* (the most pathogenic) and *E. grenieri* (the most common), is mainly observed between three and eight weeks of age, although birds are most susceptible between 8 and 15 days of age. Merozoites and schizonts are found in different sections of the gut, while the oocysts are found in the ceca. The lesions are nonspecific (enteritis, intestinal congestion, liquefaction of cecal content). The administration of coccidiostats such as diclazuril and lasalocid in the feed is allowed for guinea fowls since 2011 in Europe.

Trichomoniasis (*Trichomonas gallinarum*). Young guinea fowls are most susceptible to this parasite found mainly in the ceca. Birds are prostrated,

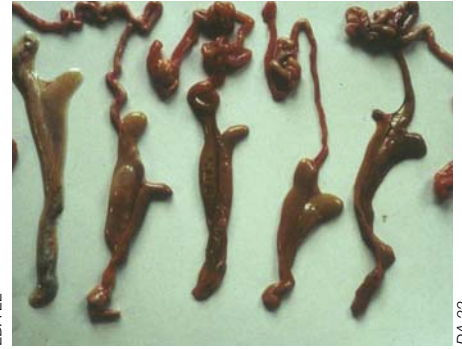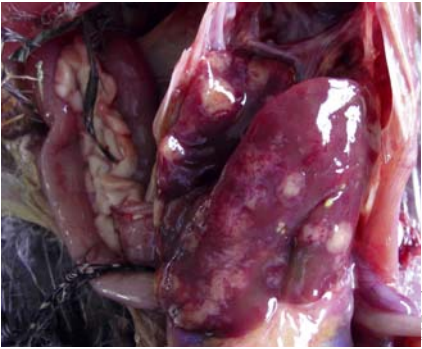


Fig.95.16: Histomoniasis (Guinea fowl). Characteristic lesions of hepatic necrosis.

Fig.95.17: Proventriculitis of guinea fowls.

Fig.95.18: Rotavirus (Guinea fowl). Typhlitis with foamy content.

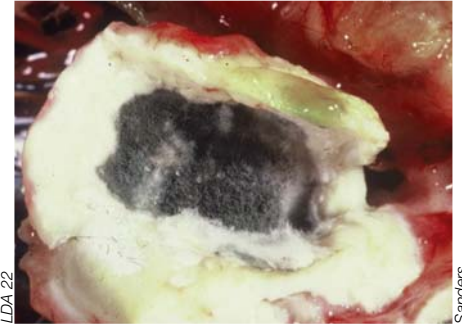
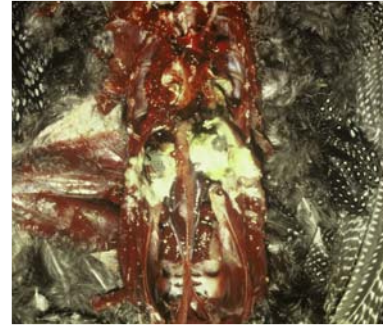
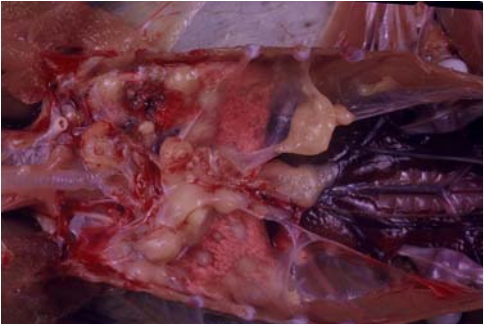


Fig.95.19, 95.20 & 95.21: Respiratory aspergillosis (Guinea fowl). Yellowish nodules on the lungs. The mycelial mat on the air sacs permits the immediate identification of the fungus (Fig.95.21).

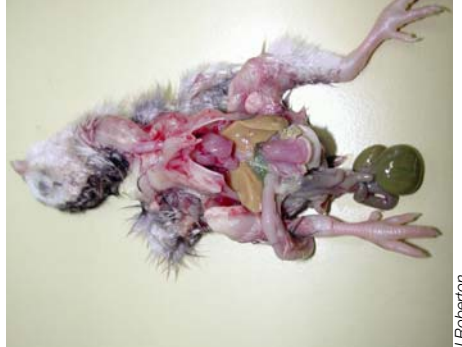
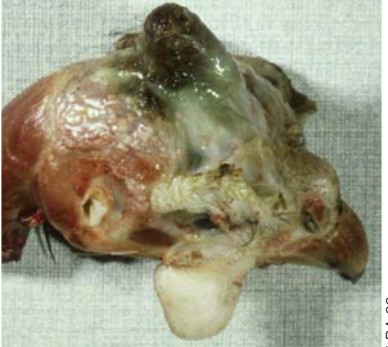
Fig.95.22: Pneumovirus (Guinea fowl). Sinusitis with infra-orbital swelling.

Fig.95.23: Tendinitis (Guinea fowl).

Fig.95.24: Five day-old guinea fowl with yolk sac retention.



Fig.95.25 & 95.26: Guinea fowls with botulism (*Clostridium botulinum*). Flaccid paralysis prevents movement.

chilled and have enteritis with yellowish diarrhea. The ceca appear dilated with a yellowish liquid to foamy content. In older birds the disease is chronic. The ceca are distended and filled with caseous material. Only a strict biosecurity program can help prevent and control this disease.

Capillariasis and other helminthiasis. Guinea fowls are also susceptible to capillariasis (*Capillaria contorta* in the crop or *Capillaria obsignata* in the small intestine) from the age of seven weeks. Capillariasis is mainly a disease observed in birds raised outside, but it can also be seen in birds raised in confinement. Other helminths are known to affect guinea fowls: *Heterakis gallinarum*, *Ascaridia galli* and *Subulura Suctorica*.

Taeniasis. Taeniasis is observed in guinea fowl from the age of seven weeks. It is caused by *Raillietina cesticillus* and *R. tetragona* that have ants or beetles as intermediate hosts.

Histomoniasis (Histomonas meleagridis). The strains isolated from turkeys can be pathogenic in guinea fowls. Guinea fowls may be healthy carriers of *Histomonas meleagridis*; but when affected, the disease may present itself in two different forms:

- Cecal lesions with very large fibrous cores (mortality rate up to 8% in a flock of guinea fowls raised for meat).
- A less frequent septicemic form with characteristic liver lesions (saucer shaped depressions or white foci).

Dilation of proventriculus (proventriculitis). This condition, observed between 4 and 12 weeks of age, is characterized by stunted growth («malabsorption syndrome») and a considerable heterogeneity of the flock. The mortality rate can reach 20% and a large number of carcasses may be downgraded at the slaughterhouse. The main lesion is a substantial dilation of the proventriculus without involvement of the mucosa. Feed particles that are too fine may be involved in this condition.

Respiratory diseases

Aspergillosis. It is encountered when the litter is moldy at harvest or during storage. Since breeding hens are kept in cages, egg contamination is rarely encountered.

Pneumovirus. Observed from the age of six weeks, the clinical signs are intense chilling, prostration, and slight lacrimation. Mortality is very

variable and may reach 0.5% per day. Lesions are subtle: osteitis, eyelid edema. Infraorbital swelling is not always present.

Ornithobacterium rhinotracheale. Swelling of infraorbital sinuses, prostration and a cumulative mortality rate of up to 5% (peak of 1% per day) are observed. Birds die with their head in a forward position. Necropsy findings show the presence of a yellowish mucoid discharge becoming caseous in the sinuses.

Mycoplasma gallisepticum. As for other poultry, guinea fowls are susceptible to this pathogen and mycoplasma-free flocks are at risk of contamination from vectors and carriers of the disease.

Locomotor disorders

Different locomotor disorders can be observed during the brooding period. *Mycoplasma synoviae* may be pathogenic, depending on the strain. Finally, lameness due to staphylococci is uncommon.

Systemic diseases

Salmonellosis. Like for other avian species, young guinea fowls are mostly susceptible to salmonellosis, presenting the same lesions found in other poultry infected with *Salmonella* Enteritidis, *S.* Typhimurium, and *S.* Gallinarum-pullorum.

Colibacillosis. Cases of colisepticemia are uncommon in guinea fowls.

Erysipelas. Guinea fowls infected with *Erysipelothrix rhusiopathiae* usually show acute signs of illness. Birds are prostrated before dying within a few hours. The mortality rate can reach 10%.

Streptococci. Septicemia caused by *Streptococcus* spp. is uncommon and occurs during the brooding period. Nervous signs are present.

Viral pancreatitis. This disease is mostly seen in guinea fowls less than 15 days old and is due to an Aviadenovirus. The morbidity rate varies between 15 and 30%. Nervous signs may be observed: birds lying down, opisthotonos, convulsions. The pancreas is indurated, enlarged and yellowish with the presence of nodules and petechiae. The mortality curve shows a characteristic «bell-like» shape and may reach 10%. The diagnosis is confirmed by the observation of typical intranuclear inclusion bodies in pancreatic cells.



Fig.95.27: Viral pancreatitis (Guinea fowl). Opening the abdominal cavity of diseased birds.

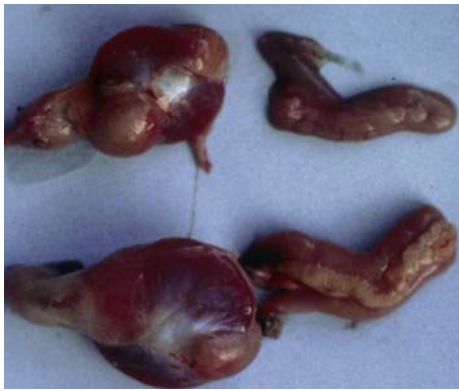

Fig.95.28 & 95.29: Viral pancreatitis (Guinea fowl). Pancreatic hypertrophy (Fig.95.28). Histology. Pancreatic necrosis with basophilic intranuclear inclusion bodies (HES) (Fig.95.29).

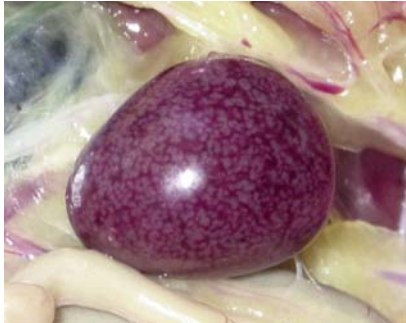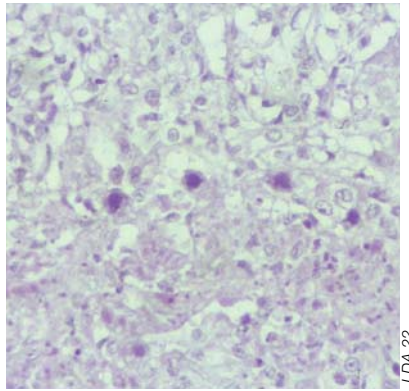


Fig.95.30: Marble spleen disease (Guinea fowl). Hypertrophy and reticulated appearance of spleen.

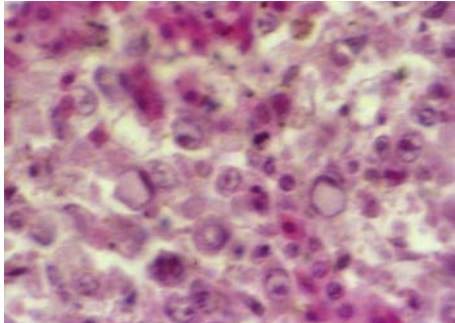


Fig.95.31: Marble spleen disease (Guinea fowl). Distinctive intranuclear inclusion bodies seen during the histological examination of the liver.

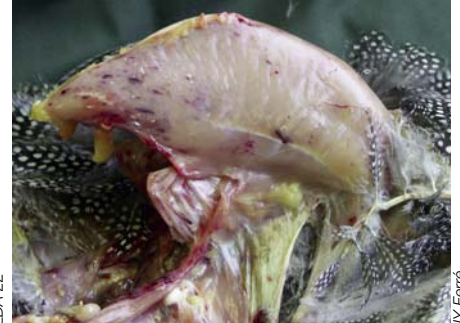

Fig.95.32: Marble spleen disease (Guinea fowl). Intramuscular hemorrhages.

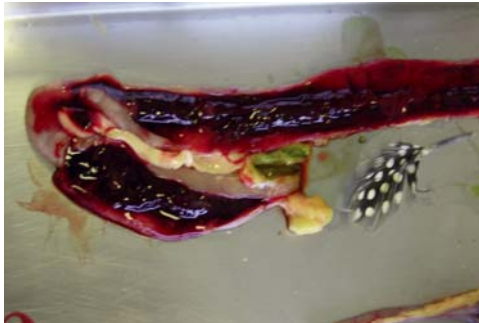

Fig.95.33: Marble spleen disease (Guinea fowl). Hemorrhagic enteritis.



Fig.95.34 & 95.35: Fulminating disease. Prostrated seven week-old guinea fowl (Fig.95.34). Whitish nodules on the pancreas (Fig.95.35).

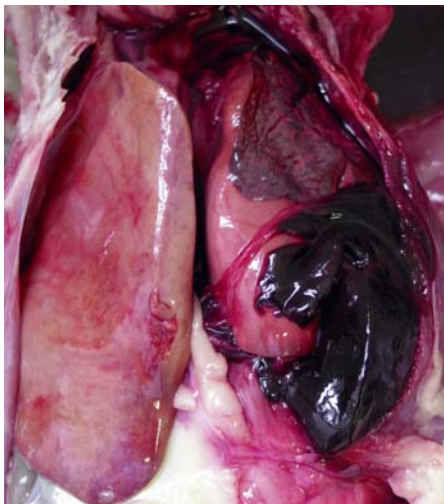
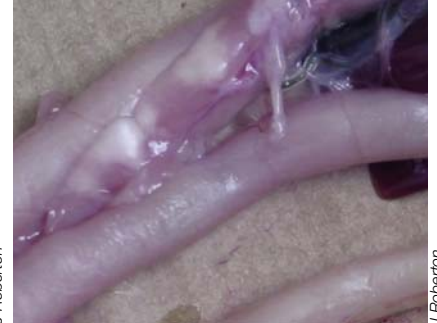

Fig.95.36 & 95.37: Hepatic hemorrhages (Guinea fowl). These hemorrhages only involve the liver (subcapsular hemorrhage).

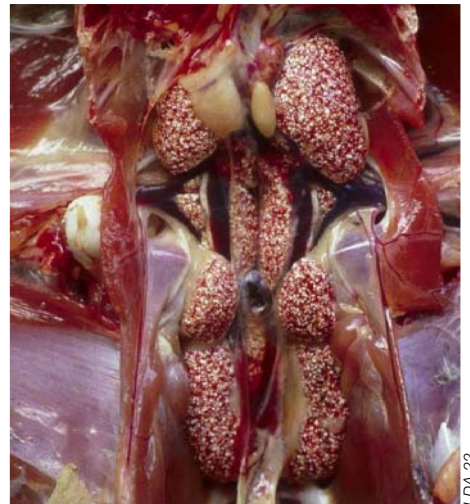
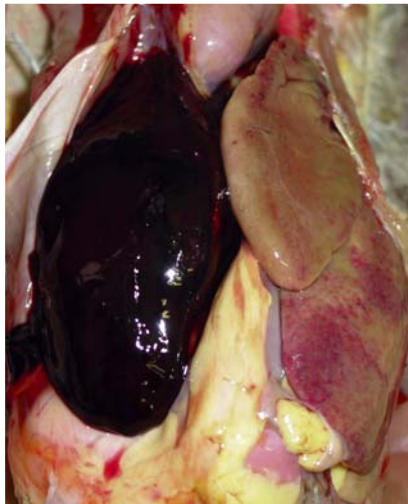

Fig.95.38: Visceral gout (Guinea fowl). Kidney damage.

Marble spleen disease. The disease is caused by the same agent (*Siadenovirus*) responsible for hemorrhagic enteritis of turkeys. It normally occurs around five to seven weeks of age, but it has been described in guinea fowls up to 5 months old and dying suddenly. Mortality rates vary from 0.1% to 0.7% over a two-week period. The spleen is enlarged with a characteristic reticulated appearance. Hemorrhagic lesions can be observed in skeletal muscles and the myocardium. It is not advisable to use the vaccine developed for hemorrhagic enteritis of turkeys (risk of vaccine related disease).

Fulminating disease or X disease. This specific disease of guinea fowl is of viral origin (togavirus, reovirus, herpesvirus, or a coronavirus related to the coronavirus enteritis of turkeys). It appears suddenly at any age with a mortality rate of 30 to 80% in 48 hours. At necropsy, a greenish liquid is found in the intestine; the ceca are distended with a yellow foamy content; the gallbladder is dilated, and lesions of nephritis and necrosis of the pancreas are observed. The differential diagnosis should include endemic diseases associated with a high mortality rate (e.g., avian influenza caused by a highly pathogenic avian influenza virus).

Other viral diseases. Newcastle disease can also affect guinea fowls. However, bird susceptibility varies depending on the viral strain. For the vaccination against Newcastle disease, it is recommended to use a live La Sota vaccine strain and inactivated vaccines for high risk flocks and breeders (the Hitchner B1 vaccine is not recommended). Guinea fowls are as susceptible to influenza viruses as other poultry. Experimentally, guinea fowls appear to show receptivity to infectious bursal disease virus. Encephalomyelitis cases have also been reported, in two to four week-old birds.

Other diseases

Visceral gout. It is observed from the age of 8 weeks in flocks having experienced problems during brooding (enteritis, chilling, etc.) followed by compensatory growth but with inadequate water intake.

Hemorrhagic hepatitis. Starting at two weeks of age, it is possible to observe a sudden mortality in guinea fowls raised for meat. At necropsy, only a subcapsular hepatic hemorrhage is noted. Mortality may vary between 2 and 15% of the flock, depending on measures put in place to reduce the impact of factors related to growth.

Riboflavin deficiency. It is accompanied by a 40-70% reduction in hatchability when the feed contains less than 6 ppm (threshold of 2 ppm).

Intoxications. Vigilance is necessary in feedmills and on multi-species production sites because coccidiostats such as ionophores (monensin) and halofuginone are toxic to guinea fowls. Halofuginone is toxic at 1 ppm: accidental consumption by guinea fowls of a feed containing 2.2 ppm of halofuginone caused enteritis and 50% mortality in a flock in 10 days.

Red mites - Dermanyssus. Red mites are not commonly found in the litter and the environment of guinea fowls. However, when present, they may cause behavioral problems, reduce growth, and lead to increased weekly mortality.

REFERENCES

- Brahem A. A highly virulent Togavirus-like agent associated with the fulminating disease of guinea fowl. *Avian Dis*, 1992,36:133-148.
- Diseases of Poultry*. Ed. Saif YM et al, 11th edition. Blackwell Publ. Iowa, 2008.
- Klès V et al. Herpes-like virus isolated in fatal guinea poult disease. *Vet. Record*, 1988,123:1378.
- Le Coz-Douin J. *L'élevage de la pintade*, Ed. Point Vétérinaire. Maisons Alfort 1992.
- Massi P et al. Adenovirus-associated haemorrhagic disease in guinea fowl. *Avian Pathol*, 1995,24:227-237.
- Onyeausi BI. Susceptibility of guinea fowl (*Numida meleagris galeata*) to infectious bursal disease virus (IBD). *Int. J Science*, 2009,8:595-597.
- Tanyi-J. Pancreatitis caused by reovirus in guinea-fowl *Avian Pathol*, 1994,23:61-77.




Fig.96.1, 96.2, 96.3, 96.4, 96.5 & 96.6: There is many species of quail or Bobwhite. Fig.96.1: Common Bobwhite or Virginia quail (*Colinus virginianus*); Fig.96.2: Japanese quail (*Coturnix japonica*); Fig.96.3: Harlequinor quail (*Coturnix delegorguei*); Fig.96.4: King quail (*Coturnix chinensis*); Fig.96.5: California quail (*Callipepla californica*); Fig.96.6: Mountain quail (*Oreortyx pictus*). The Japanese quail (*Coturnix japonica*) is a species of Old World quail found in East Asia and from which the subspecies *Coturnix coturnix japonica* is the domesticated form.



Fig.96.7: The domestic quail (*Coturnix coturnix japonica*) is the smallest bird subspecies that is bred on farms, for its meat and eggs production. Quail eggs are mottled brown with variations on white to greenish cream.

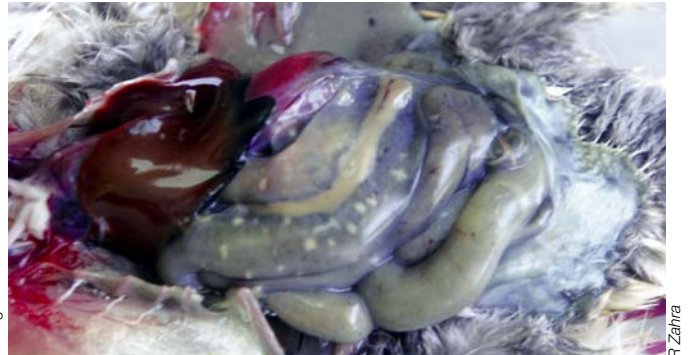

Fig.96.8: Ulcerative enteritis (Quail). Multifocal ulcers in the mucosa of small intestine visible through the wall.

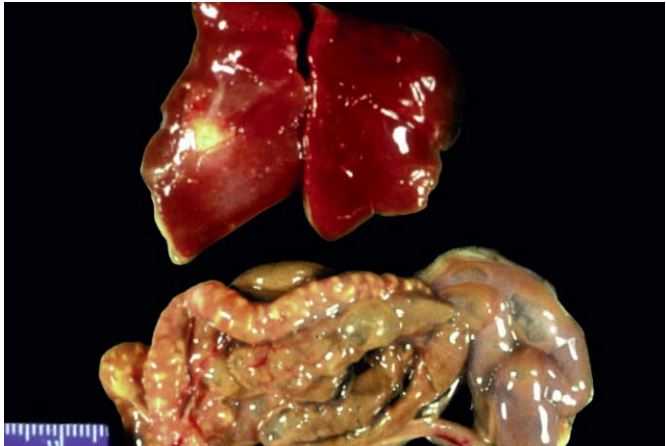


Fig.96.9: Ulcerative enteritis in an adult quail. Hepatitis and enteritis.

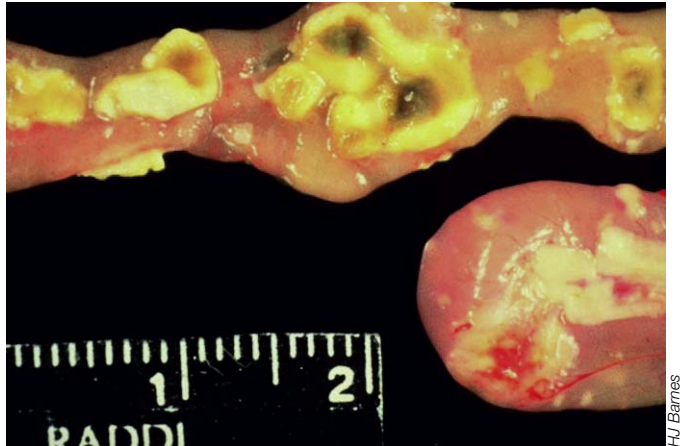


Fig.96.10: Ulcerative enteritis in a quail (age: 3 months). Ulcers in the intestinal mucosa.

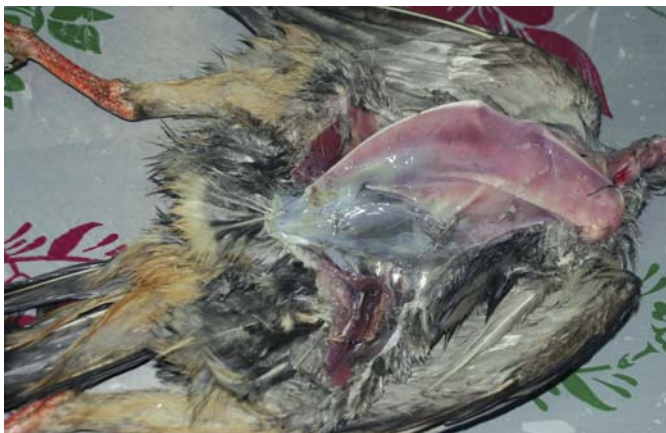

Fig.96.11: Chronic ulcerative enteritis (Quail). Cachexia.

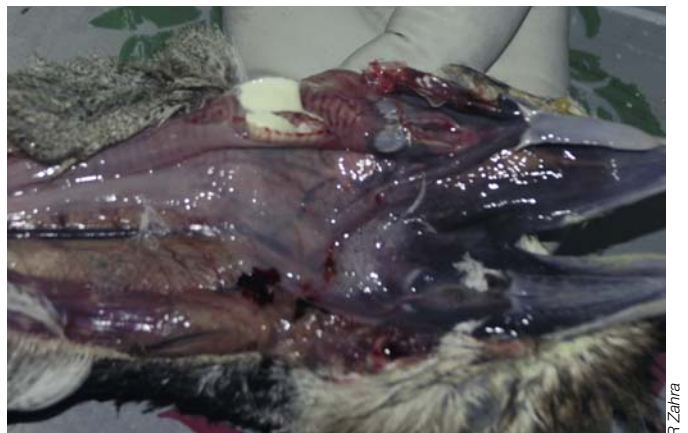

Fig.96.12: Tracheitis (Quail). Caseous exudate in the trachea.

Section VI

96. DISEASES OF QUAIL

INTRODUCTION

Quails are susceptible to many of the pathogens described elsewhere in this manual. This description of quail diseases will focus on clinical entities that are specific to or fairly common in confined bobwhite quail (*Colinus virginianus*) of the «New World» quail subfamily *Odontophorinae*, rather than those of «Old World» quail (*Coturnix* species). Bobwhite quail (BWQ) are found in the wild and raised domestically throughout North America, where they are considered a very popular and important upland game bird species. It is likely that the BWQ, having evolved as a wild species, does not possess highly effective immunity against microbial «diseases of concentration», especially when compared to the domestic chicken that has long been raised in captivity. In addition, natural behaviors change and social stresses are increased in captivity. Thus, disease challenges are often encountered in confinement raised BWQ, even under exemplary management conditions.

In a 5-year summary (1987-1992) of game bird submissions to a diagnostic laboratory in Pennsylvania, bacterial (predominantly clostridial) and parasitic (predominantly capillarid and coccidial) diseases were the most commonly diagnosed problems associated with morbidity and mortality in commercial quail operations.

ULCERATIVE ENTERITIS

Ulcerative enteritis (UE) is so common in confined BWQ that its synonym is “quail disease”. It is caused by *Clostridium colinum*, a Gram positive, anaerobic, rod-shaped bacteria, but overgrowth of *Clostridium perfringens* and/or other *Clostridium* spp. may also play a role.

Transmission is by fecal/oral route, and carrier birds are thought to be an important reservoir. Many BWQ propagators believe that just about any stressor (environment, change in management, concurrent disease) can precipitate UE. Clinical signs include depression, listlessness, and huddled and ruffled appearance. Birds can die fairly acutely (1 or 2 days) in good body condition, or the disease can take a chronic course in which affected quail are anorectic and suffer significant weight loss and debilitation over several weeks. Morbidity and mortality rates are quite variable, and the latter has been reported in the range of 30 to 50% or higher if untreated.

The intestinal lesions are quite characteristic and consist of variably sized multifocal or coalescing round, oval or lenticular ulcers in the mucosa of the small intestine. The cecae and proximal colon may also be affected. The ulcers may progress to full-thickness perforating defects that result in mixed bacterial peritonitis. Other lesions include small multifocal pale areas of necrosis in the liver and splenomegaly.

In most situations, the diagnosis can be made based on the typical gross lesions. Gram stained impression smears may be taken, preferably from liver lesions, to look for Gram positive rod-shaped bacteria. Anaerobic culture and identification of *C. colinum* from intestine or liver can further confirm the diagnosis, but the organism is considered very fastidious and difficult to culture. Tests to rule out other diseases that may have similar lesions (necrotic enteritis, histomoniasis, coccidiosis) may be conducted.

To treat an outbreak, antibiotics with activity against Gram positive bacteria (bacitracin, streptomycin, lincomycin, penicillin, erythromycin, *etc.*) are administered by drinking water or in feed. Control is achieved by avoiding predisposing factors (optimizing management to reduce stress, controlling coccidiosis and other enteric diseases, maintaining good sanitation, stocking at low density). Continuous feeding of medicated feed (bacitracin) is generally used for prevention in floor birds. However, bacitracin has been used for many years, and there is anecdotal evidence that its efficacy against UE has greatly decreased. The most effective prevention is housing the birds on raised wire mesh floors so that access to accumulated feces and contaminated ground is eliminated.

QUAIL BRONCHITIS

Quail bronchitis (QB) is caused by a serotype 1 avian adenovirus denoted «QBV» that is indistinguishable from chicken embryo lethal orphan (CELO) viruses. Chickens and turkeys can be infected by QBV and seroconvert to it, but do not develop clinical disease. The disease in young quail chicks develops and spreads rapidly. The incubation period is 3-7 days and course of disease is 3 to 4 weeks in a flock. Morbidity may approach 100% and mortality can reach 50% or higher. QBV remains in the environment for the rest of the hatching and growing season, and disease may occur

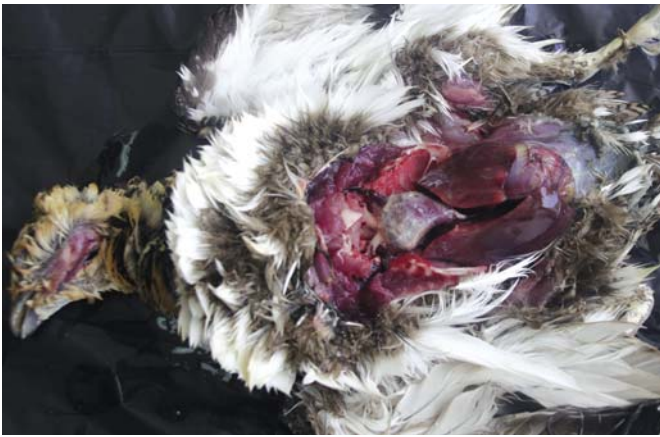

Fig.96.13: Visceral urate deposition over the heart (Quail).

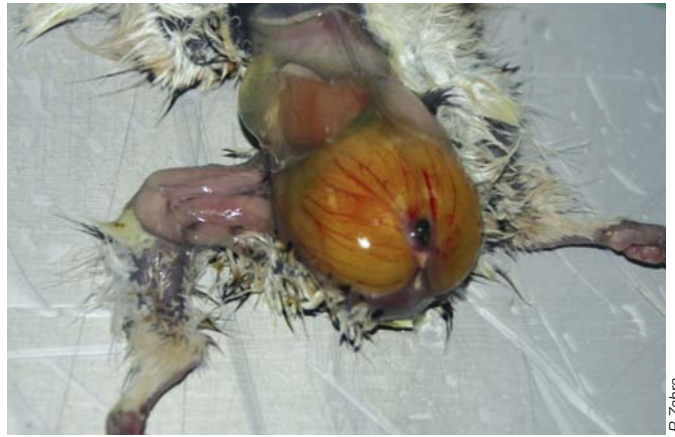

Fig.96.14: Omphalitis (Quail).

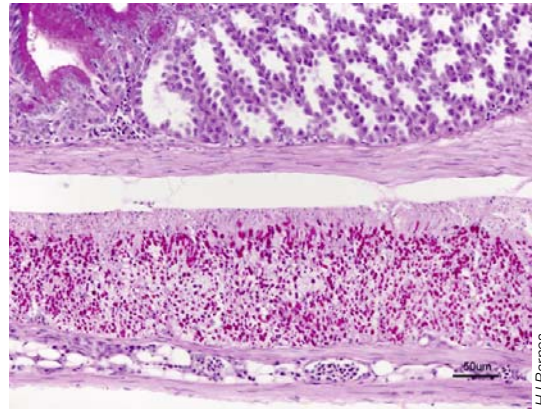
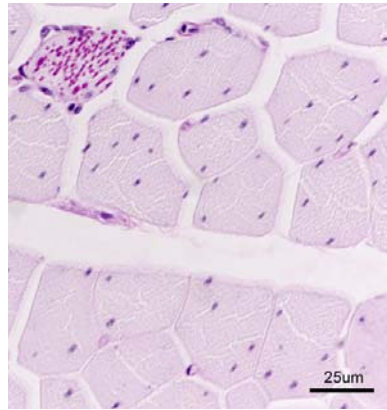
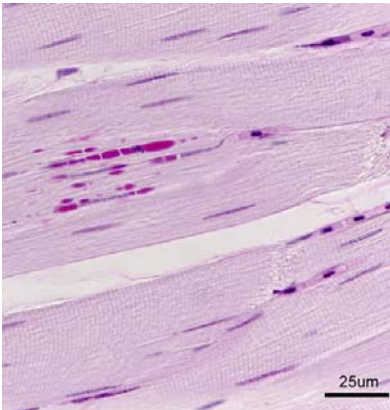


Fig.96.15, 96.16 & 96.17: Quail with generalized glycogenosis. Skeletal muscle (x280, PAS) and proventriculus (x280, PAS). Affected quail showed difficulty in raising their wings. Excessive accumulation of glycogen is seen in the liver, heart, skeletal muscle and brain, apparently due to enzyme activity. The condition appeared between 2 and 12 weeks of age and tissue deposition of glycogen increased with age. The growth of affected quail was normal and there were no deaths from the condition. This glycogen storage disease of the quail provides a model for elucidating the pathogenetic process of human glycogen storage disease type II.

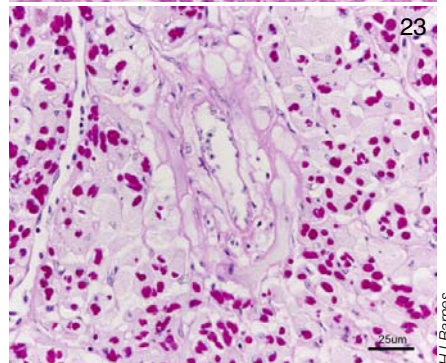
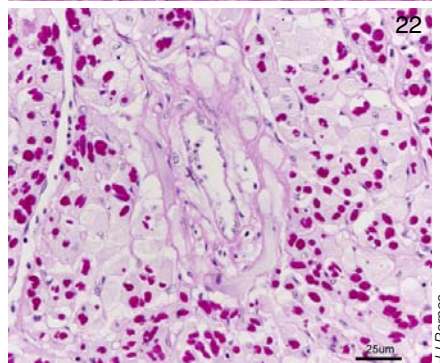
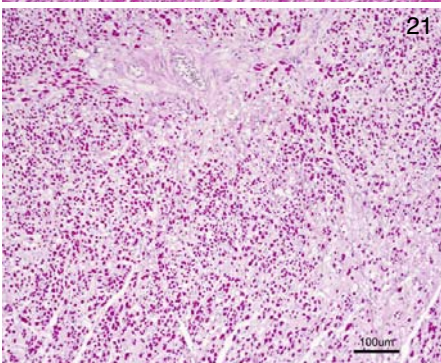
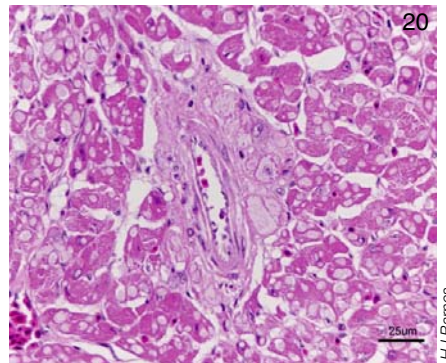
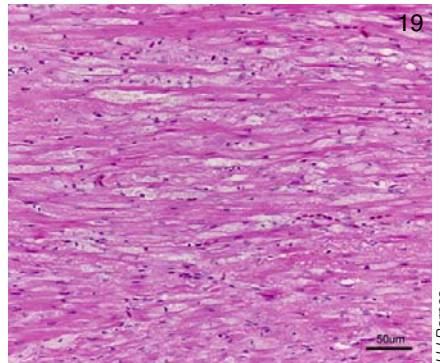
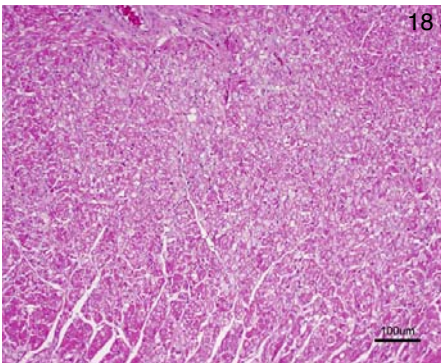


Fig.96.18, 96.19, 96.20, 96.21, 96.22 & 96.23: Quail with generalized glycogenosis seen in heart with different magnifications (x70, x140 & x280), with classic histology and PAS (periodic-acid-Shiff coloring the glycogen - Fig 21, 22 & 23).

in each successive hatch. The main mode of transmission is horizontal (respiratory and fecal-oral), but vertical transmission is also suspected to occur. Possible sources of introduction of QBV include infected breeders, other carrier birds, feces or exudates tracked in from other infected premises.

Manifestation of the disease is most severe in quails infected at less than 4 weeks of age, but milder and subclinical forms can be seen in older growing birds. In birds infected at less than 1 week of age, mortality may occur without noticeable clinical signs. However, in most cases, depression, anorexia and lethargy are noted. Pronounced respiratory signs (including snicking, open-mouthed breathing, oculonasal discharges, head-shaking) are evident. Exudative tracheitis and bronchopneumonia are the main lesions associated with clinical QB. Large, basophilic intranuclear inclusion bodies, typical in appearance of those produced by type 1 adenoviruses, are seen in sloughing mucosal epithelial cells in affected trachea and bronchi, and may be present in other tissues such as liver, bursa, spleen and pancreas. Lesions in other organs have been described.

The diagnosis is confirmed by virus isolation using standard techniques for isolation and identification of any type 1 aviadenovirus, but multiple passages in eggs or cell culture may be required for quail isolates.

No specific anti-viral medication against QBV is available. Supportive care aimed at optimizing the environment and providing comfort are important in limiting mortality and preventing secondary infections. Biosecurity between and within farms, depopulation followed by cleaning and disinfection, deferred hatching, and/or keeping survivors of outbreaks as the following year's breeding stock have been used singly and in combination to control QB. Experiences with autogenous vaccines and vaccines made from "Indiana C" virus have shown highly variable results. An autogenous vaccination program has been described. Quail propagators should realize that introducing any birds of unknown QB status into their home flock may result in an outbreak in the residents or the newcomers depending on each group's previous history of exposure or non exposure to QBV. Assaying for type 1 adenovirus-specific antibodies may be helpful in ascertaining the status of these quail.

QUAIL POX

Quail pox (QP) is caused by a strain of avian poxvirus, and as such shares cross relatedness with, as well as antigenic, immunologic and host specificity

differences from various other strains. Quail poxvirus (QPV) is antigenically distinct from fowl, pigeon and psittacine poxviruses. QPV DNA shows marked differences from fowl pox DNA by restriction endonuclease testing, and immunoblotting techniques have similarly revealed detectable differences in proteins. The details of transmission, incubation period, disease course, clinical signs, lesions and diagnosis of pox in BWQ are similar to those of avian pox in other species of birds. Latency has been demonstrated in fowl pox and is likely possible in QP as well. The mosquito is thought to be an important vector in QP, so potential for outbreaks may be linked temporally and spatially to higher mosquito populations and activity.

In various game farm outbreak accounts, morbidity rates were reported at 30 or 40 %, and mortality rates, at 10 or 20%. Decreased feed consumption and egg production were noted. Both diphtheritic and cutaneous pox forms of disease are seen, and significant facial (especially periocular) and oral proliferative and ulcerative lesions and sinus swelling are described. Blindness from eyelid lesions is thought to be an important contributor to mortality in affected bird. Leg and skin lesions are also reported in free-ranging BWQ.

Vaccination (wing web stab or subcutaneous injection in inguinal region) using commercially available live virus vaccine of quail origin is the control method of choice. Only quail pox vaccine should be used in BWQ, because fowl and pigeon pox vaccines will not protect quail against QP. Vaccination is warranted in all regions where pox is endemic (south and southeast U.S.), and should also be implemented if the disease was present the previous year in a non-endemic area. All young growing birds, either home-raised or introduced should be vaccinated once a year, so that no naïve birds remain. Quail can be vaccinated during an outbreak to lessen spread and severity, if the disease is detected early in its course.

CRYPTOSPORIDIOSIS

Cryptosporidiosis (crypto) in BWQ chicks is an enteric disease caused by a coccidian parasite of an unnamed species in the genus *Cryptosporidium*. It is believed to be a distinct species from *C. baileyi* which infects the upper respiratory tract, cloacal bursa, ureters of chickens and turkeys and *C. meleagridis* which can cause small intestinal enteritis in turkeys. Quail *Cryptosporidium* spp. («quail crypto») does not seem infective to chickens and turkeys.



Fig.96.24: Cholangiohepatitis (Quail).

Transmission is by fecal/oral route, and autoinfection leads to rapid and exponential increases in numbers of organisms before immunity can develop.

«Quail crypto» is a primary pathogen in baby quail chicks, and reports have shown that >90% mortality can occur in affected flocks. Chicks are clinically ill (depressed, down on sides) by 4 to 5 days of age, and mortality increases rapidly. *Post-mortem* lesions include severe dehydration, watery contents in the small intestine and dilated caecae filled with liquid brown fluid and gas (foam). Blunting and fusion of villi and loss of enterocytes from villous tips are evident microscopically in the proximal and mid- small intestine, and the parasites appear as basophilic blebs within the microvillous border.

Diagnosis can be confirmed by visualizing various life stages of the 2-6 μm organisms within the mucosal epithelium of formalin-fixed sections of the small intestine (standard histopathology, transmission electron microscopy) and/or by detecting oocysts (5 μm) in feces or intestinal contents or mucosal scrapings. Standard brightfield, phase contrast or fluorescent microscopy can be used, and various stains (acid fast, auramine-O) can be applied to visualize the organism and differentiate it from organisms of similar size and shape (e.g., yeasts).

No chemotherapeutic drugs or vaccines are effective for treatment or prevention of quail cryptosporidiosis. Sanitation (especially brooding in raised wire cages rather than on conventional floor and litter) and delaying exposure until birds are older are the prevention methods of choice. Oocysts are extremely resistant to inactivation by standard concentrations of disinfectants/sanitizers that readily kill other microbial pathogens. Highly concen-

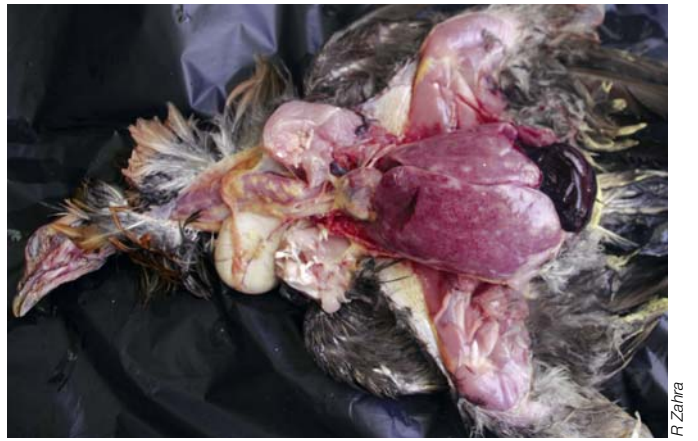

Fig.96.25: Lymphoid leukosis (Quail). Liver enlargement and nodular tumor infiltration.

trated ammonia (>50 %) and 50% commercial bleach each were effective in destroying significant numbers of oocysts experimentally. However, ridding commercial premises of «quail crypto» by disinfectant use is likely futile. Because temperatures > 65°C inactivate the organism, high temperature steam cleaning of metal cages and other impervious surfaces after all organic matter has been removed may be effective.

COCCIDIOSIS

Specific coccidia infecting the intestinal tract of quail have not been well characterized or named, but more than one host specific *Eimeria* species is thought to exist. The life cycle features, pathogenesis and control of coccidiosis in quail are essentially the same as in chickens and turkeys.

Currently in the U.S., monensin and salinomycin are approved for use in feed for quail for control of coccidiosis. Amprolium and sulfonamide class drugs are also used by producers in the drinking water for treatment and control. Vaccines against quail-specific coccidia are not available.

CROP CAPILLARIASIS

Capillaria spp. nematodes (also called crop worms or thread worms) are common parasites associated with debilitation, emaciation and ingluvitis in floor-raised quail. These *Capillaria* spp. has no valid name, although several sources report that both *C. annulata* and *C. contorta* can be found in the crops of quail. Fecal/oral transmission occurs when embryonated capillarid eggs are ingested from contaminated soil (direct) or earthworms (indirect).

In heavy infestations, these nematodes are highly pathogenic. The crop becomes markedly thicke-

ned and inflamed. Whitish flocculent debris may accumulate on the mucosa, and multifocal ulcers may be seen. In severe cases, the lesions extend upward into the esophagus and mouth. Prehension and predigestion are impaired, and varying degrees of malnutrition, emaciation and weakness follow. Spontaneous deaths and/or losses due to increased culling result.

A presumptive diagnosis can be made on gross lesions, but the lesions may be mistaken for candidiasis or trichomoniasis. In capillariasis, manual tearing of the crop wall reveals very small diameter, long, white “threads” spanning the gap between the edges of the torn mucosa. Deep mucosal scrapings reveal nematode fragments and/or double operculated nematode ova. Histopathologic examination of the affected crop also shows the presence of nematodes and their distinctive ova in areas of inflammation and necrosis.

Treatment and control are similar to those for nematode infestations in other avian species. Debilitated birds should be culled. Management aimed at limiting access to contaminated ground and earthworms such as rearing birds on wire and pen sanitation and rotation are important. Several anthelmintic drugs (coumaphos, hygromycin B, fenbendazole, levamisole, tetramisole, *etc.*) have been used commercially or experimentally against capillarids in poultry and pigeons, but none are specifically approved for use in quail in many countries. Maretin (N-hydroxynaphthalimide diethyl phosphate) and haloxon have been referenced as being used experimentally in quail, but higher doses of the latter were toxic.

CANNIBALISM

Cannibalism or «picking» or «pecking» can be a severe problem in BWQ, particularly during brooding and growing, because quail chicks are quite aggressive. Nose picking and toe picking are the most frequently observed types in chicks. Nose picking is more common in 2 to 7 week-old quail in crowded pens. Penmates attack each other near the nares and surrounding tissue at the base of the upper beak. Beaks may be permanently deformed on some survivors. In toe picking, chicks and growing birds attack the dorsum of the feet, toes and shanks of themselves or others. Hunger may initiate the behavior. It is also thought to be more common in birds raised on wire, and the behavior may be triggered by wire cuts or other injuries to the feet. Significant mortality due to blood loss and tissue trauma can occur, especially with nose picking.

Feather picking and vent picking can also occur, both in growing birds and adult breeders. Many control measures for cannibalism have been tried. Low bird density, easy access to abundant feed and water including adequate space at the feeders and drinkers, properly balanced diets, correct feed particle size, and optimal environmental temperatures and lighting are all important to deter vices such as cannibalism. Quick detection of the problem and separation of offenders from victims may also help, before the behavior becomes learned and widespread. Severely traumatized birds should be culled. Beak trimming is generally not practiced on quail. Smaller versions of frontal vision blocking devices (specks, blinders) and/or bits commonly used in pheasants to deter picking are used on quail breeders on some farms.

REFERENCES

- Berkhoff HA. Clostridial diseases- ulcerative enteritis (quail disease). In “*Diseases of Poultry*”, Iowa State Press, 1997, pp 255-260.
- Current WL. Cryptosporidiosis, In “*Diseases of Poultry*”, Iowa State Press, 1997, pp 883-890.
- “*Field Manual of Wildlife Diseases: General Field Procedures and Diseases of Birds*”, U.S. Geological Survey- Biological Resources Division- Information and Technology Report 1999-001, 1999, pp 122-123.
- Gerlach H. Galliformes. In “*Avian Medicine and Surgery*”, W.B. Saunders Company, 1997, pp 953-956.
- Ritchie BW. “*Avian Viruses: Function and Control*”, Wingers Publishing, Inc, 1995, pp 324-235, 286, 307-309.
- Reed WM et al. Intestinal cryptosporidiosis with enteric viral complications in bobwhite quail, *Proceedings 40th Western Poultry Disease Conference*, 1991, p 78.
- Reed WM & Sherman WJ. Adenovirus infections-quail bronchitis. In “*Diseases of Poultry*”, Iowa State Press, 1997, pp 620-624.
- Ritter GD et al. Intestinal cryptosporidiosis and reovirus isolated from bobwhite quail (*Colinus virginianus*) with enteritis, *Avian Dis*, 1986,30:603- 608.
- Ruff MD & Norton RA. Internal parasites- nematodes and acanthocephalans In “*Diseases of Poultry*”, Iowa State Press, 1997, pp 818-819.
- Schwartz LD. *Grower’s Reference on Gamebird Health*, Avicon, Inc., 1995, pp 102-104, 113-115, 143-145, 155-158, 190-192, 339-340.
- Shane SM. A review- common diseases and other conditions of quail. *Avian/exotic practice*, 1985,2:13-23.
- Tripathy DN & Reed WM. Pox, In “*Diseases of Poultry*”, Iowa State Press, 1997, pp 643-649.



Fig.97.1: Traditional free-range pen directly on soil with corn and net coverage.



Fig.97.2: An inadequate number of drinkers induces nephritis due to insufficient access to drinking water.

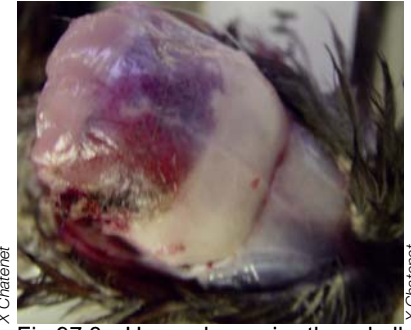

Fig.97.3: Hemorrhage in the skull from trauma (injury from hitting a post in the aviary).

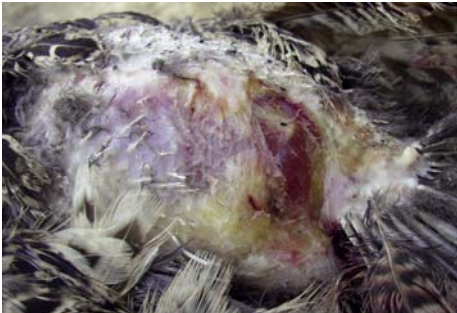

Fig.97.4: Cannibalism is occasionally observed in pheasants grown under poor management conditions.

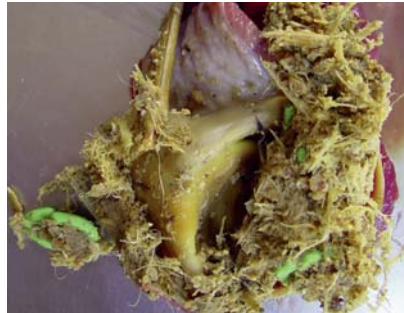

Fig.97.5: Gizzard (Pheasant). Foreign body (anti-pecking rings) ingested by birds outside the pen.

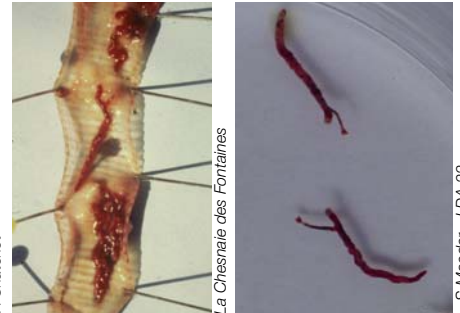

Fig.97.6 & 97.7: *Syngamus trachea* (Pheasant). Presence of parasites in the trachea on the left.

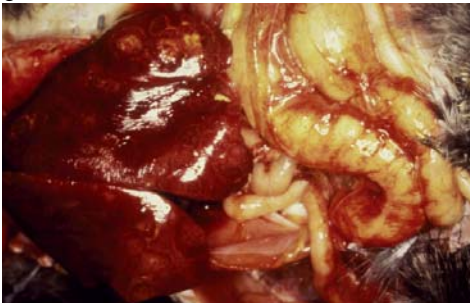


Fig.97.8: Histomoniasis (Pheasant). Hepatitis and typhlitis.

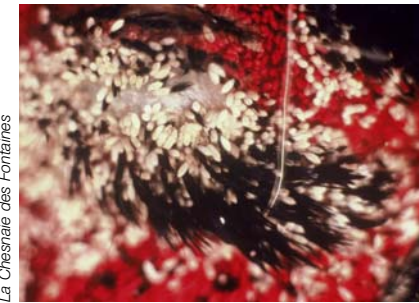


Fig.97.9: Lice (Pheasant).

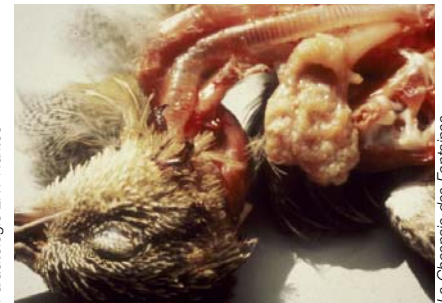

Fig.97.10: Candidiasis of the crop (Pheasant).

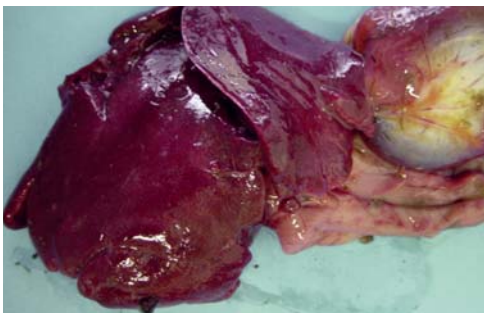


Fig.97.11: Mycotoxosis with liver damage (Pheasant).



Fig.97.12: Calcium deficiency («soft bone» syndrome) in a young pheasant.

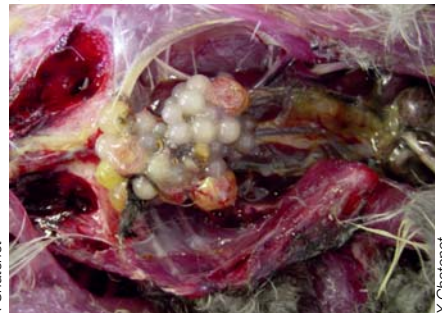


Fig.97.13: Ovary regression of infectious origin (Pheasant).



Fig.97.14: Mycoplasmosis (early phase) caused by *M. gallisepticum* (Pheasant). Conjunctivitis.

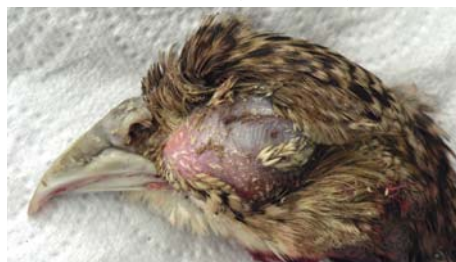

Fig.97.15 & 97.16: Infectious coryza (Pheasant).

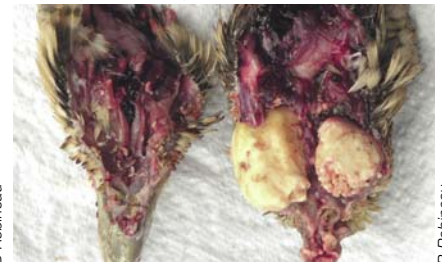

Fig.97.15 & 97.16: Infectious coryza (Pheasant).

Other species

97. PHEASANT PRODUCTION & DISEASES

INTRODUCTION

From an artisanal production born in the 60s, the rearing and production of game today has evolved into commercial operations based on management and sanitation measures found in mainstream poultry production.

For example, in France in 2008, there were an estimated half a million pheasant hen breeders producing annually around 35 million eggs. Of 30 million chicks produced, 12 million are raised to be released.

PHEASANT PRODUCTION

Today's pheasant production focuses on the export market, requiring commercial breeder and hatchery operations. One distinctive feature of this type of production is that a large part is destined to be released into the wild for hunting. Hence, these birds must be healthy to survive, esthetically beautiful, and able to fly. These features require a significant outdoor rearing period to maintain the wild behavior of the birds. However, the first phase of production is done inside buildings similar to typical modern day poultry farms. The impact of these two different production phases is seen in the type of pathogens associated with each one. Another distinctive feature of game production is its seasonality. The hunting season begins in the fall in Northern Europe and finishes before spring's arrival. The peak egg production is around the month of May, while birds produced for release are marketed starting in September. Therefore, game farms are at their maximum capacity during the summer.

DISEASES OF PHEASANTS

Pathogens threatening game production are identical to those found in poultry, but their importance and expressions may vary depending on the phase of production (indoor, outdoor).

Parasitic diseases

Parasitic diseases represented 32% of consultations calls in a French veterinary clinic in 2008. Twelve percent were about flagellates; 10% and 6% were related to coccidia and helminths, respectively.

Flagellates affect primarily birds raised indoor, starting at around three weeks of age. These flagellates, such as *Spironucleus* (formerly *Hexamita*) or *Trichomonas* cause a foamy yellow diarrhea, weight loss and heterogeneity of the flock. Exceptionally, the mortality rate can reach 60 to 80%.

Coccidiosis, caused by *Eimeria* specific to pheasants, produces clinical signs similar to flagellates. They are observed as early as four weeks of age, but especially between seven and eight weeks, which corresponds to the time when the birds are sent outside.

Helminthiasis are controlled by preventative programs based on levamisole or benzimidazole, which explains their low incidence. Their prevalence is directly related to rainfalls in the regions where the pheasants are raised. When present, syngamiasis is readily observed during flock visits. It causes a dry cough and a characteristic yawning. Capillariasis causes weight loss, egg drop and poor shell quality including in caged breeders. The presence of *Heterakis* can be observed without the occurrence of any clinical signs.

Lice are mainly represented by *Menopon gallinae* (shaft louse). Their nits deform the neck plumage of adults. Red mites are especially common in brooding barns. Mange mites are rarely encountered.

Metabolic diseases

Metabolic disorders are as important as parasitic diseases in pheasants. Anti-cannibalism devices and environmental changes (release in aviary, changing aviary, preparation of breeders) may destabilize some birds that may stop drinking, which may lead to nephritis. Nephritis and dehydration may also occur consecutive to management problems during the first week of life. There may also be a non-specific enteritis syndrome with diarrhea associated with nephritis and dehydration in four to five day-old pheasants. Chicks are lethargic with droopy wings. The birds' toes are quickly soiled by manure pellets that may put mechanical pressure on the phalanges leading to necrosis. This relatively common syndrome appeared after the ban on meat-and-bone meal in feed and its etiology

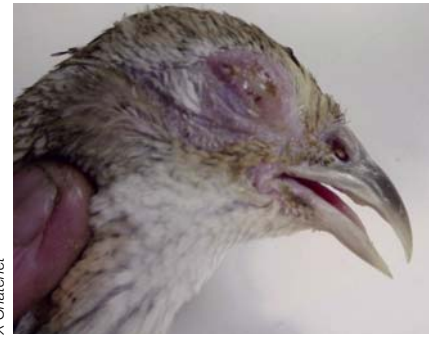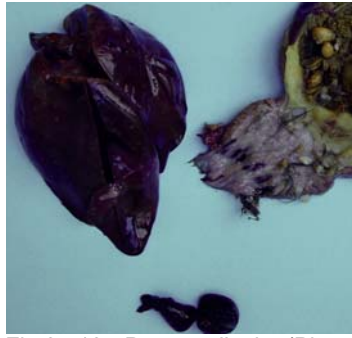



Fig.97.17 & 97.18: Tuberculosis (Pheasant). Presence of granulomas in the liver and spleen.

Fig.97.19: Pasteurellosis (Pheasant).

Fig.97.20: Conjunctivitis caused by *Riemerella anatipestifer* (Pheasant).

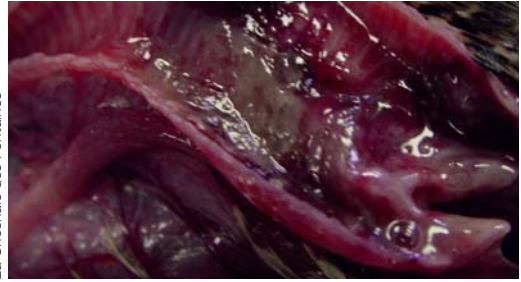


Fig.97.21 & 97.22: Pheasants with ascending flaccid paralysis (wings, legs, neck) caused by botulinum toxin (*Clostridium botulinum*).

Fig.97.23: Infectious laryngotracheitis (Pheasant). Presence of a caseous plug in the lumen of the trachea.

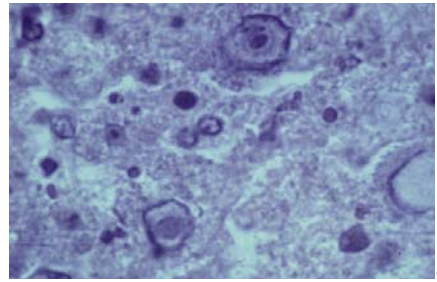


Fig.97.24, 97.25 & 97.26: Marble spleen disease (Pheasant). Acute organ congestion (Fig.97.24) The mottled appearance of the spleen is characteristic of this adenovirus of pheasants (Fig.97.25: Hypertrophy of two spleens on right, normal spleen on left.. Intranuclear inclusion bodies are observed in spleen cells (Fig.97.26).

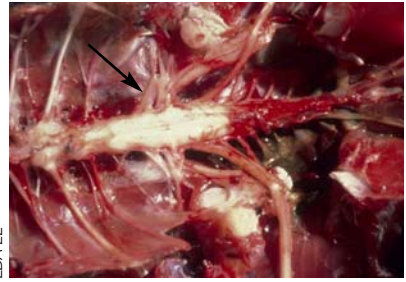
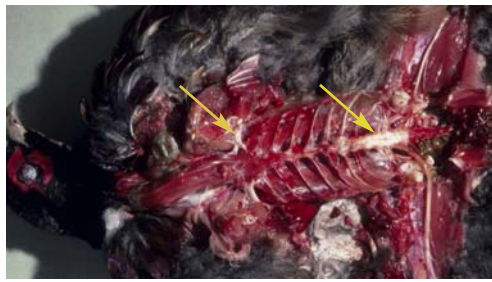
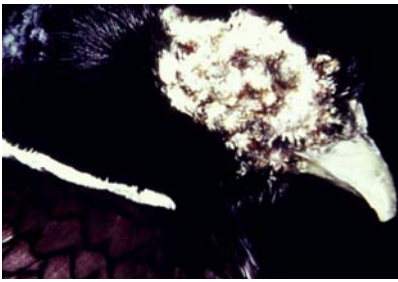

Fig.97.27: Pox in a pheasant with presence of scabs on the head.

Fig. 97.28 & 97.29: Marek's disease (Pheasant). Hypertrophy of brachial and sciatic plexuses (arrows). Magnification of the sciatic nerve.

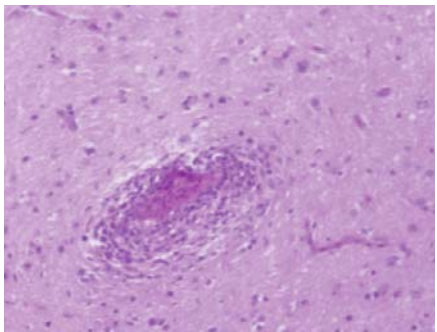


Fig.97.30: Pneumovirus causes a drop in egg production with egg discoloration (Pheasant).

Fig.97.31 & 97.32: Newcastle disease (Pheasant). Encephalitis resulting in nervous signs (prostration, paralysis, etc.) and confirmed by observation of perivascular lymphocytic infiltration in the brain.

remains controversial (rotavirus?). Treatment includes antibiotics that are active against a mixture of Gram-positive bacteria.

Bacterial diseases

Bacterial diseases are relatively less frequent (9% of consultations). *Mycoplasma* spp. are relatively common especially because of bird movement between farms and the simultaneous presence of several game species on the same farm. *Mycoplasma gallisepticum* is responsible for a highly contagious «big head» syndrome, observed especially at the end of the breeding season with the return of cold and wet weather. *Mycoplasma synoviae* causes arthritis and an unusual susceptibility to other respiratory infections. Other mycoplasmas are also pathogenic but more difficult to identify (*M. iners*, *M. iowae*).

Respiratory colibacillosis is rare - even with *Mycoplasma* co-infection. It is generally associated with poor ventilation.

Salmonellosis has become rare. Note that *Salmonella* Enteritidis is responsible for a fatal diarrhea in young pheasants without the persistence of the pathogen in the flock. In contrast, *S. Typhimurium* causes diarrhea with caseous typhlitis, frequently progressing to chronicity. Very stringent sanitation measures should be put in place to decontaminate the farm. *Salmonella* Saint Paul is also pathogenic. Other minor *Salmonella* are sometimes identified, but they are not associated with disease (e.g., *S. Seftenberg*). It is therefore important to do a complete diagnostic work-up in order to identify the causative agent(s) that may be associated with an acute fatal diarrhea.

Botulism is a disease recurring from year to year because it is virtually impossible to decontaminate a soil that contains *Clostridium botulinum* spores. Birds have a classic ascending flaccid paralysis. A control program requires adequate flock management and medication. Vaccination against botulinum toxin is effective for type C botulism, which is the most common. The diagnosis is mainly based on the observation of clinical signs.

Respiratory infections such as *Ornithobacterium rhinotracheale* (sinusitis) or *Riemerella anatispestifer* (blepharitis) are common but involve a limited number of birds in a flock. They do not spread as much in pheasants as in turkeys and chickens. Erysipelas in pheasants presents a septicemic form with lesions that are more or less characteristic.

Viral diseases

Viral diseases represented only 4% of consultation calls in 2008 with the exception of non-specific enteritis of young pheasants (although the viral etiology of this condition has yet to be confirmed).

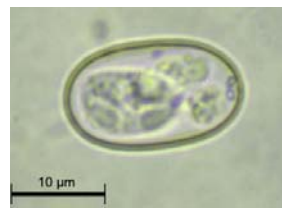
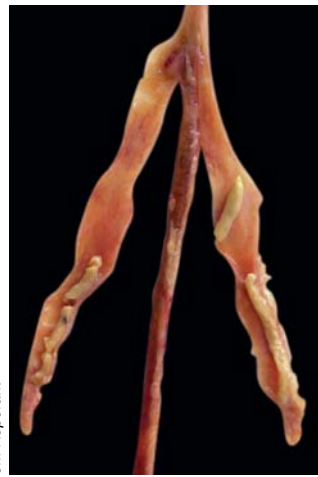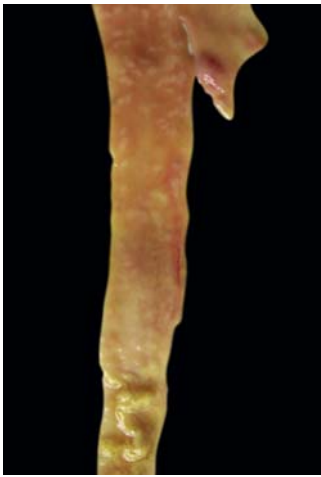Marble spleen disease is a common infection caused by a siadenovirus (see Chap.II.25) that can be prevented by using the live attenuated vaccine for hemorrhagic enteritis of turkeys. Since the vaccine strain originates from pheasants, it is very effective but it has also retained residual pathogenicity, which requires a very rigorous application of the vaccination protocol. Sick birds are usually 9 to 15 weeks of age and die after a short period of prostration. Lesions include a discolored spleen and acute congestion affecting many organs (lungs, liver, etc.).

Pneumovirus infections are mainly reported in breeders and are responsible for a drop in egg production and shell discoloration sometimes associated with sinusitis with serous exudate. Coronaviruses may also play a role when there is a drop in egg production.

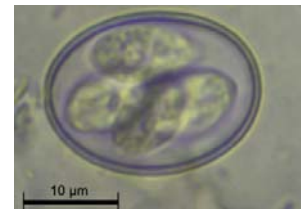
Pheasants are as susceptible as chickens to velogenic Newcastle disease and present the same clinical signs (respiratory, nervous, etc.), and it is possible to vaccinate pheasants with the same vaccines used for chickens. Like many bird species, pheasants are also susceptible to avian influenza viruses.

REFERENCE

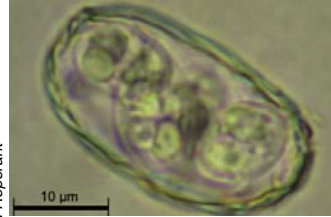Schricke E. *Faisan de chasse. Elevage et pathologie*. Ed. Point vétérinaire. Maisons-Alfort 1991.



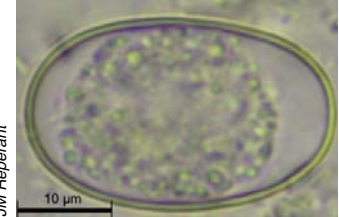
Eimeria legionensis



Eimeria kofoidi



Eimeria padulensis



Eimeria caucasica

Fig.98.1: Coccidiosis of the red-legged partridge (*Eimeria kofoidi*). White foci visible on serous and mucous membranes, in the duodenum and jejunum. These lesions resemble those caused by *Eimeria acervulina* in chickens.

Fig.98.2: Coccidiosis in red-legged partridges (*Eimeria legionensis*). Hard caseum in the ceca containing many oocysts of coccidia. These lesions resemble those caused by *Eimeria adenoeides* in turkeys).

Fig.98.3, 98.4, 98.5 & 98.6: Oocysts of four coccidia species found in red-legged partridges; same magnification. Anticoccidial treatments are administered via drinking water. However, they must be accompanied by stringent litter and stress management measures through proper ventilation and flock density. Recurrences are common even when coccidiostats are incorporated into the feed.

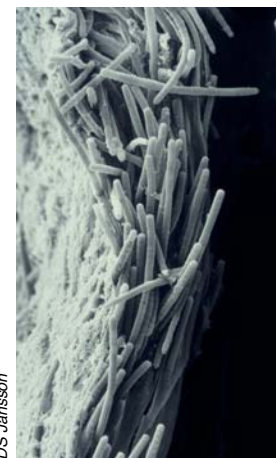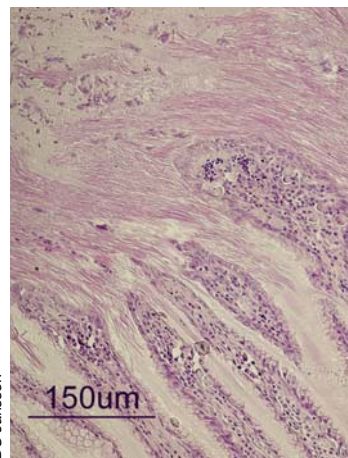
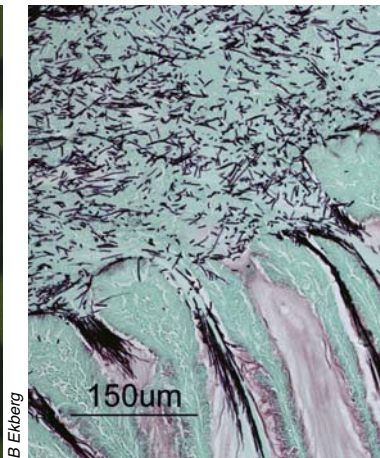
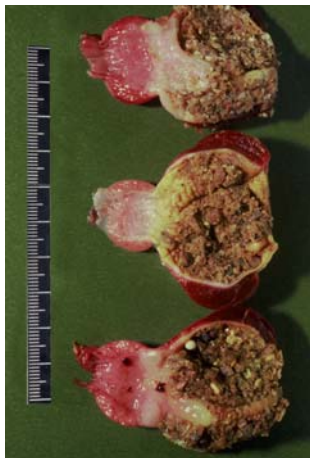


Fig.98.7, 98.8, 98.9 & 98.10: Mycotic proventriculitis (megabacteriosis). This disease was diagnosed in two Swedish gray partridge flocks. Affected birds showed loss of condition, respiratory signs, and a flock mortality rate of 50 and 98%. The proventricular lesions were closely associated with *Macrorhabdus ornithogaster*. Proventriculi were edematous and hyperemic, and viscous mucus adhered to the mucosa (Fig.98.7). Proventricular hemorrhages were commonly detected, and proventricular rupture could occur. Microscopically, mild to severe subacute to chronic lymphoplasmacytic proventriculitis, microabscesses, necrosis, epithelial metaplasia, ulcers, and hemorrhages were observed. *Macrorhabdus ornithogaster* were observed in a mucin layer organized in parallel sheets between mucosal folds (Fig.98.8 with Grocott stain and Fig.98.9 with hematoxylin & eosin stains). Scanning electron microscopy of the proventricular epithelium demonstrated masses of organisms in parallel arrangements with occasional constriction zones (Fig.98.10). Many of the birds also suffered from concurrent respiratory bacterial infections and/or gastrointestinal candidiasis. This disease was reported originally in cage and aviary birds. (DS. Jansson et al, J Zoo Wildlife Med, 2008,39:428-437).

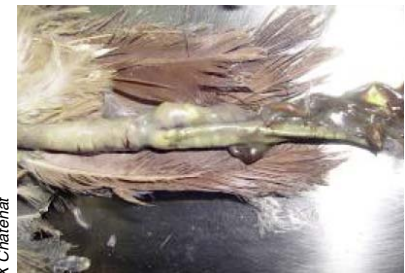
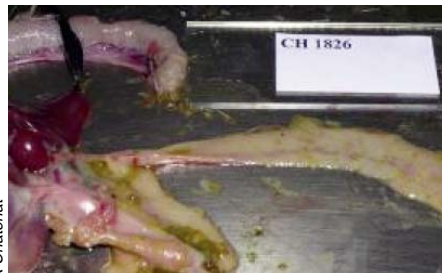
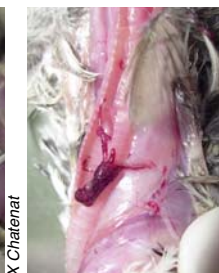Fig.98.11: Capillariasis (Partridge).

Fig.98.12: *Syngamus trachea* (Partridge).

Fig.98.13 & 98.14: Necrotic enteritis in partridges is characterized either by the accumulation of a creamy white content in the digestive tract caused by *Clostridium perfringens* (necrotic enteritis in Fig.98.13) or by ulcerative lesions that can perforate the intestine (ulcero-necrotic enteritis in Fig.98.14) caused by *Clostridium colinum*.

Other species

98. DISEASES OF PARTRIDGE

INTRODUCTION

There are two species of farmed partridges. The red-legged partridge, *Alectoris rufa*, is the most common. The breeding stock in France is estimated at between 300,000 and 350,000 couples producing 25 million eggs of which 16 million go for export. It should not be confused with the chukar partridge (*Alectoris chukar*) introduced in France to obtain heavier birds by crossbreeding local strains. Their release is prohibited. The gray partridge (*Perdix perdix*) is second in importance with a smaller population than the red-legged partridge (about 100,000 couples). As with pheasants, many pathogens are common to both partridges and domestic poultry. The red-legged partridge is more sensitive to digestive disorders while the gray partridge is more affected by respiratory disorders. Only diseases specific to partridges are described in this chapter.

PARASITIC DISEASES

Parasitic diseases are more frequent in red-legged partridges (2/3 of observed diseases compared to 1/3 in gray partridges). Coccidiosis is the most common disease. It results in prostration progressing to rapid weight loss and diarrhea that is often lethal in red-legged partridges.

Flagellates are often present in cases of acute and chronic enteritis in red-legged partridges. They are less common in gray partridges. Although black-head (histomoniasis) may be observed in both species, the most frequently isolated protozoas are *Trichomonas* species and sometimes *Spironucleus* (*Hexamita*). The cecal content is sparkling yellow and birds become emaciated. The presence of nematodes and cestodes is strongly linked to rainfall and soil type. *Capillaria* (mainly found in the crop) leads to emaciation and mortality, including when birds are in breeding cages. Infection with *Syngamus* causes death by suffocation in a large proportion of birds in an affected flock. Teniasis can cause, within hours, a deadly peracute hemorrhagic enteritis.

Candidiasis is mainly observed in the final phase of a chronic digestive infection.

BACTERIAL DISEASES

Bacterial diseases are relatively less frequent. The predominant bacterial disease in partridges is necrotic enteritis, expressed either as a creamy

white content in the digestive tract, or as ulcerative lesions capable of perforating the intestine (ulceronecrotic enteritis) caused by *Clostridium perfringens* and *Clostridium colinum*, respectively. Despite treatment, relapses are frequent for both red-legged and gray partridges, even in flocks known to maintain a high health status. Botulism can be observed in farmed partridges but not as frequently as in pheasants. Clinical signs are typical in the acute form, but sometimes a more insidious form, limited to diarrhea and weight loss, is encountered in red-legged partridges.

Grey partridges are very sensitive to *Mycoplasma gallisepticum* and *M. synoviae*, while red-legged partridges are quite resistant and can act as asymptomatic reservoir of *M. gallisepticum*.

As for other domestic poultry, partridges may be affected by colibacillosis. *Salmonella* are rarely a problem, particularly *Salmonella* Enteritidis, but they may complicate a coccidiosis case. *Salmonella* Typhimurium and *S. St Paul* cause caseous typhilitis and mortality, especially during the first week of age. The septicemic form of erysipelas, characterized by suffusion hemorrhages on the proventriculus, may be confused with Newcastle disease in the red-legged partridge.

Ornithobacterium rhinotracheale has been isolated from sinusitis lesions in gray partridges. In the red-legged partridge, this pathogen has been associated with a severe meningeal syndrome causing a 10-15% mortality rate. This syndrome was associated with osteomyelitis of the spongy bone located behind the ear canal.

VIRAL DISEASES

Viral diseases are less recognized in partridges. Cases of pneumovirus or swollen head syndrome have been reported. The gray partridge is sensitive to Newcastle disease while the red-legged partridge is considered relatively resistant. However, it is important to use caution with certain live vaccines with this species in order to prevent vaccine-related problems. An adenovirus with classical viral hepatitis lesions has been observed in gray partridges. Finally, an acute enteritis syndrome associated with three pathogens (coccidia, trichomonas and candida in the crop) has been observed in young adult red-legged partridges. However, the reproduction of this syndrome using gastrointestinal content after ultrafiltration supports the hypothesis of a viral origin.



Fig.99.1, 99.2 & 99.3: *Columba livia* (rock dove, from which the domestic pigeon, then known as carrier pigeon, were obtained by progressive selection).

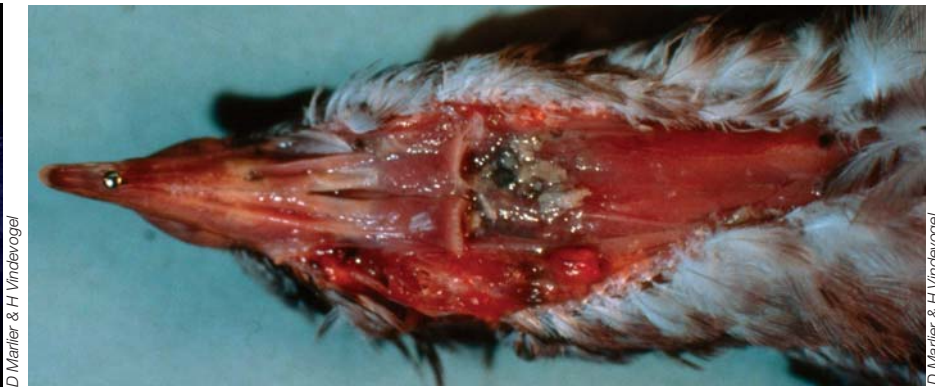

Fig.99.4: Herpetic coryza: grayish yellow wattles.

Fig.99.5: Herpetic coryza: closure of the cleft palate, back of the palate congested; diphtheroid pharyngitis.

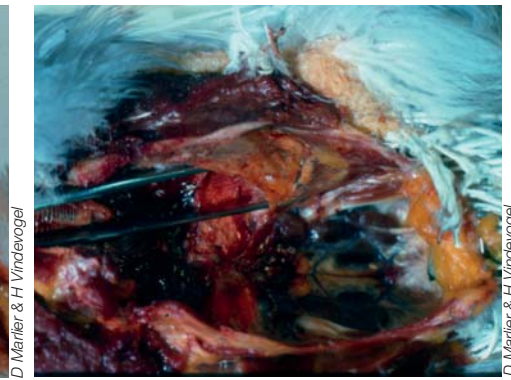
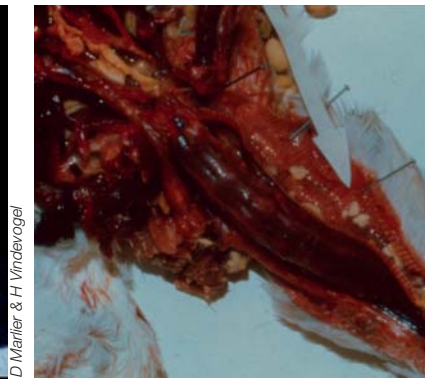


Fig.99.6: Sinusitis in chronic respiratory disease: herpesvirus and *Staphylococcus* infection.

Fig.99.7 & 99.8: Chronic respiratory disease: herpesvirus and *Escherichia coli* infection. Obstruction of the trachea by a caseous plug (left) and chronic airsacculitis (right).

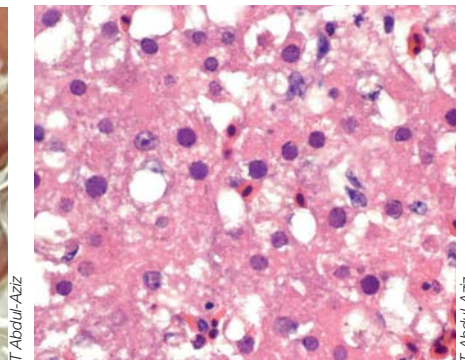
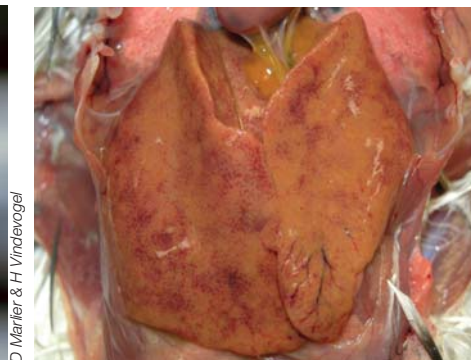

Fig.99.9: Chronic respiratory disease (owl's head). Herpesvirus and *Pasteurella septica* infections.

Fig.99.10 & 99.11: Herpetic hepatitis (three-week-old pigeon). Macroscopic and microscopic lesions.

Section VI

99. DISEASES OF PIGEON

INTRODUCTION

The homing pigeon or domestic pigeon (*Columba livia*) belongs, as well as nearly 300 other species, to the *Columbidae* family. In Europe, this family is represented by five distinct species: two species of doves: *Streptopelia turtur*, *S. decaocto*, and three species of pigeons: *Columba palumbus*, *Columba oenas* and *Columba livia* (rock dove, from which the domestic pigeon and subsequently the carrier pigeon were obtained by progressive selection). The latter is a full-fledged athlete receiving veterinary care as if it were a priced racehorse. Indeed, some can fetch top dollars on the market.

As for all species, diseases of pigeons may be of biological (viral, bacterial, parasitical and fungal) and non-biological (mechanical, physical, chemical, nutritional, genetic, *etc.*) origins. In this chapter, only recent data on «new» clinical entities (infections caused by herpesviruses, adenoviruses, circovirus, and *Streptococcus gallolyticus*), and on current problems associated with the emergence of resistance to conventional treatments for trichomoniasis and respiratory diseases will be presented in details.

VIRAL DISEASES

Herpesvirus infection (coryza)

The *Columbid herpesvirus 1* (CoHV-1), or pigeon herpesvirus, is part of the subfamily *Alphaherpesvirinae*, genus *Mardivirus* (close to the herpesvirus of Marek's disease). This virus was first associated with the clinical syndrome «conjunctivitis, nasopharyngitis» or coryza. This condition is the leading cause of counter performances in carrier pigeons and of stunting in meat pigeons. In Europe, pigeons are the natural hosts of this infection with a prevalence of over 50 percent. In fact, the CoHV-1 is present in 60% of dovecotes where respiratory diseases are observed and it can be isolated in 82% of pigeons suffering from acute coryza. Transmission occurs especially during the force-feeding of squabs after hatching (they are protected by maternal antibodies but will become latent carriers) or by contact (between pigeons or with other susceptible birds). Following recovery, affected pigeons become latent carriers and may shed the virus again, thus maintaining the infection.

Clinical expressions of herpesvirosis in pigeons may be acute (frequent sneezing, conjunctivitis, obstruction of the nostrils, wattles normally white turning yellow-gray) or chronic (sinusitis and intense dyspnea associated with severe secondary bacterial infections). Hence, coryza may have two clinical presentations: wet and dry coryza. The latter is more difficult to detect. The clinical signs observed with wet coryza are sneezing, scratching of nostrils and greyish or yellowish wattles and conjunctivitis. The oral, pharyngeal and laryngeal mucosae are congested and can be dotted with small whitish necrotic foci which can expand and ulcerate. Nasal discharge is abundant and forms crusts that may obstruct the nostrils. In the beak, the nasal discharge dries out because of the airflow and forms yellowish false membranes that do not adhere to the mucosa. With dry coryza, pigeons do not have nasal discharge, but only frequent yawning associated with poor athletic performances. Wattles remain white. The nose has an increased sensitivity when pinched with fingers, resulting in sneezing. The throat is glairy and the mucosae are inflamed. The tear duct is often blocked. In many cases, secondary bacterial complications with *Staphylococcus intermedius* (72%), *Pasteurella multocida* (17%), *Escherichia coli* (9%) and *Streptococcus* β hemolytic (2%) develop and can cause sinusitis and, in some cases, chronic respiratory diseases.

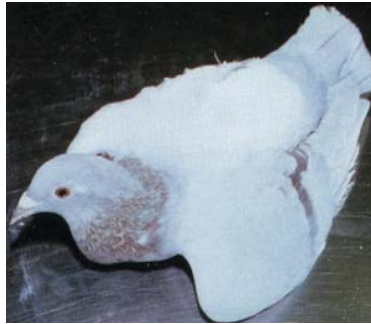Gross lesions are characterized by necrotic damage to the upper respiratory tract and liver. Eosinophilic intranuclear inclusion bodies are observed in the epithelium of affected organs; in the liver, pancreas and brain in cases of generalized infection. The acute form must be differentiated from Newcastle disease (pneumotropic and lentogenic strain) and the chronic form from the diphtheroid form of fowlpox. It is possible to immunize pigeons with a herpesvirus vaccine either attenuated or inactivated with adjuvant to prevent the onset of clinical disease or viral shedding in infected birds in order to limit viral dissemination. However, vaccination will not prevent birds from becoming carriers of the pathogen.

In owls or hawks, CoHV-1 infection does not cause specific clinical signs but a histological examination shows characteristic lesions of hepatosplenitis with necrosis associated with eosinophilic



D Marlier & H Vindvogel

Fig.99.12: Paramyxovirus (PMV1). Torticollis.



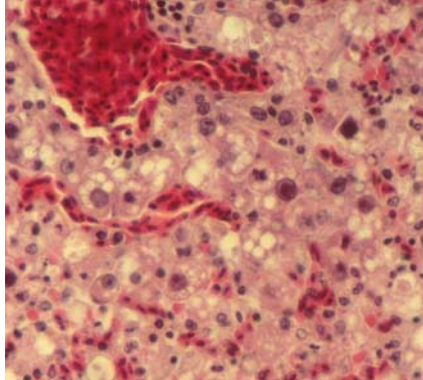
D Marlier & H Vindvogel

Fig.99.13: Paramyxovirus (PMV1). Paralysis of the wings.



D Marlier & H Vindvogel

Fig.99.14: Paramyxovirus (PMV1). Balance disorder.



LDA 22

Fig.99.15: Adenovirus type II (Pigeon). Hepatic necrosis, intranuclear basophilic inclusion bodies (HES × 400).



LDA 22

Fig.99.16 & 99.17: Pigeon pox (cutaneous form). Crusts on the eyelids and beak.

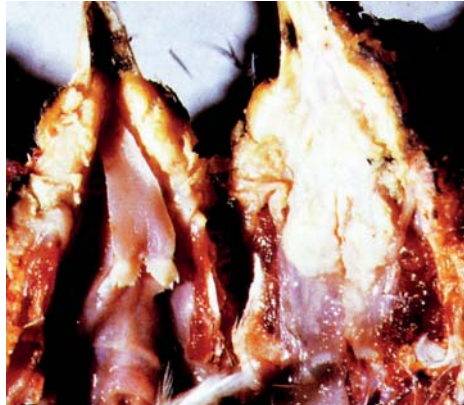

LDA 22



Dnev - Ceva Santé animale

Fig.99.18: Pigeon pox (cutaneous form).



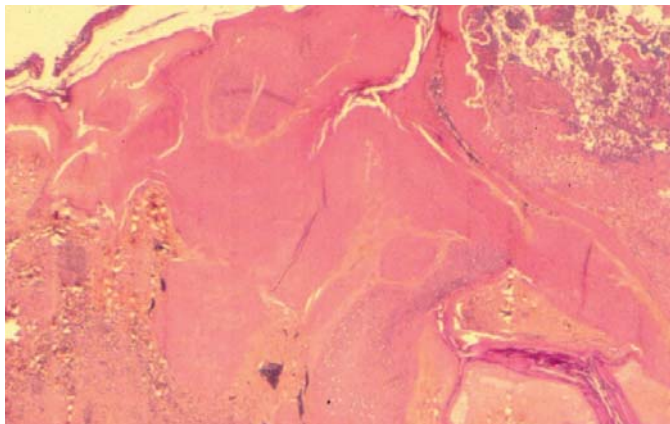
D Marlier & H Vindvogel

Fig.99.19: Diphtheroid form of pigeon pox. Yellowish membranes in the oral cavity.



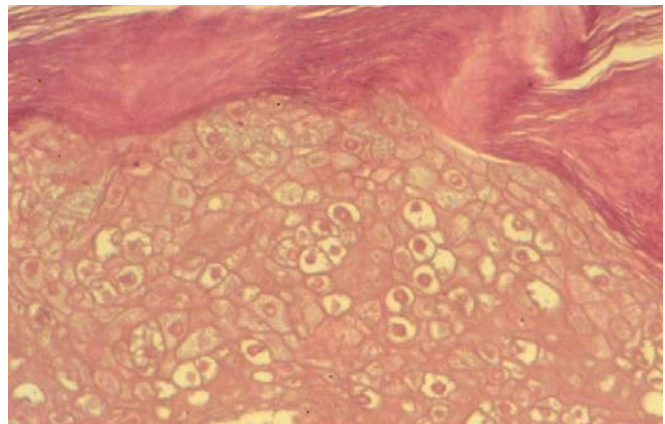
D Marlier & H Vindvogel

Fig.99.20: Sequelae of pigeon pox after a fracture of the lower mandible of the beak.



LDA 22

Fig.99.21: Pigeon pox (skin). Hyperplasia and necrosis of the skin epithelium (HES × 25).



LDA 22

Fig.99.22: Pigeon pox (skin). Ballooning cells and intracytoplasmic inclusion bodies (HES × 400).

intranuclear inclusion bodies. The susceptibility of raptors to this herpesvirus of pigeons justifies not including pigeons in their diet when they are kept in captivity.

The usual therapeutic approach is to assess whether there might be parasitic or bacterial complications, and to adjust the therapy accordingly. No CoHV-1 specific vaccine is currently available. Currently in the field, treatments are often applied in such a way as to contribute to the development of resistant bacterial strains, which may result in significant therapeutic failures. Antibiotic and anti-parasitic treatments should be reserved for sick pigeons only and their judicious application should be according to regulations.

Paramyxovirosis

Paramyxoviruses are classified into several types, with type 1 (PMV1) being the virus of Newcastle disease (ND). Between 1971 and 1973, a ND epidemic due to a velogenic PMV1 virus devastated the European poultry industry. The virus was identified in pigeons with respiratory, digestive and nervous signs. Then in 1980, lentogenic strains of PMV1 were isolated from pigeons presenting only respiratory signs associated with poor athletic performances. Later, viscerotropic and neurotropic mesogenic strains caused more severe clinical problems (tremors, torticollis, paralysis, balance and vision problems). Morbidity ranged from 30 to 70% while the mortality rate remained low (less than 10%). Vaccination is the only way to control the disease. Live attenuated vaccines should not be used in pigeons because they do not effectively protect (only a low level of local immunity develops) which requires the use of inactivated vaccines, preferably in an aqueous adjuvant.

Highly pathogenic avian influenza virus (HPAI)

Pigeons are also susceptible to the orthomyxoviruses of HPAI. When infected, they have nervous, respiratory and/or digestive problems.

Adenovirus

The family *Adenoviridae* includes the genera *Mastadenovirus* and *Aviadenovirus*, the latter including three serogroups. Pigeons are susceptible to certain chicken adenoviruses (serogroup I) (isolation is possible in cell culture) and to a specific pigeon adenovirus that has not been characterized to date because it is not yet possible to grow this virus in culture. Adenovirus infections of pigeons

are known since 1976 but gained significant importance since 1993-1994. In pigeons, adenovirus infections are responsible for two different clinical conditions known as adenovirus type I (classical adenovirus) and type II (necrotic hepatitis). These types refer only to clinical signs and gross lesions and not to antigenic types.

Clinically, adenovirus type 1 affects almost exclusively birds that are less than one year old (mainly 3-5 months). Very liquid diarrhea with vomit, severe weight loss and overall very poor body condition are observed. The infection spreads rapidly in the pigeon house and after a few days, all the young pigeons are affected. In general, the mortality rate is low, with recovery taking place within one to two weeks. However, athletic performances remain below normal for several weeks. In most cases, this form of adenovirus is complicated by bacterial infections, particularly *Escherichia coli*. In this case, the diarrhea becomes putrid. The duration of the disease increases and some pigeons die (sometimes up to 40%). The adenoviruses type 1 should be suspected on the basis of the occurrence of diarrhea and vomiting in almost all the squabs mainly between March and July. The differential diagnosis must include paramyxovirosis, salmonellosis, trichomoniasis and hexamitiasis. At necropsy, there is an acute hemorrhagic to fibrinous duodeno-jejunitis and often an intense diffuse hepatitis. Confirmation of the diagnosis is done by histopathological examination with the observation of intranuclear inclusion bodies in hepatocytes and enterocytes.

In adenovirus type II, pigeons of all ages (from 6 days to 6 years) can be affected. Generally there are only few clinical signs: the pigeon curls up into a ball and die within 24 to 48 hours; very rarely, vomiting or liquid yellowish droppings are present. New cases are observed sporadically over a period of six weeks to two months. In the pigeon house, the overall mortality ranges from 30% to 70%. The most common observation is that, in the same pigeon house, some pigeons die suddenly while others are in perfect health. The differential diagnosis of adenovirus type II must include salmonellosis, streptococcosis and poisoning. At necropsy, the main lesion is an intense necrotic hepatitis. Confirmation of the diagnosis is made by histopathological examination of the liver showing extensive areas of necrosis with the presence of eosinophilic intranuclear inclusion bodies. Using transmission electron microscopy, paracrystalline arrays of icosahedral viral particles are observed in the nucleus of hepatocytes and enterocytes.

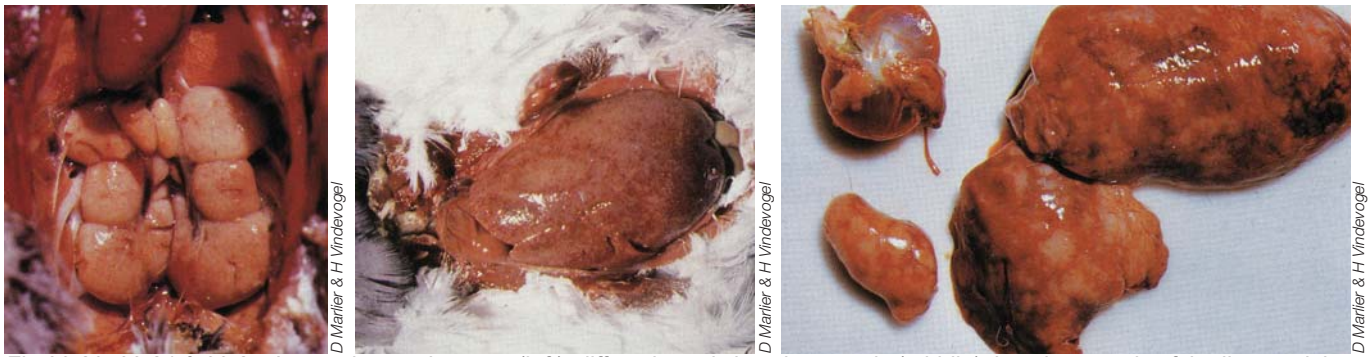


Fig.99.23, 99.24 & 99.25: Leucosis: renal tumors (left), diffuse hepatic lymphomatosis (middle), lymphomatosis of the liver and the spleen (right).

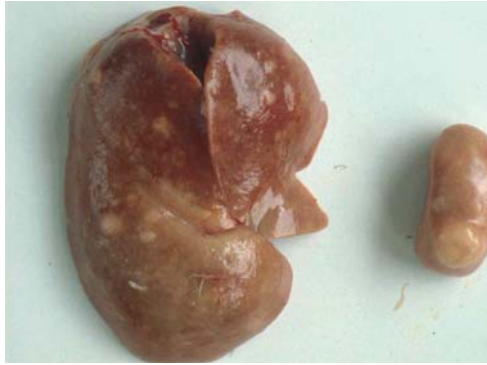


Fig.99.26: Renal neoplasia.

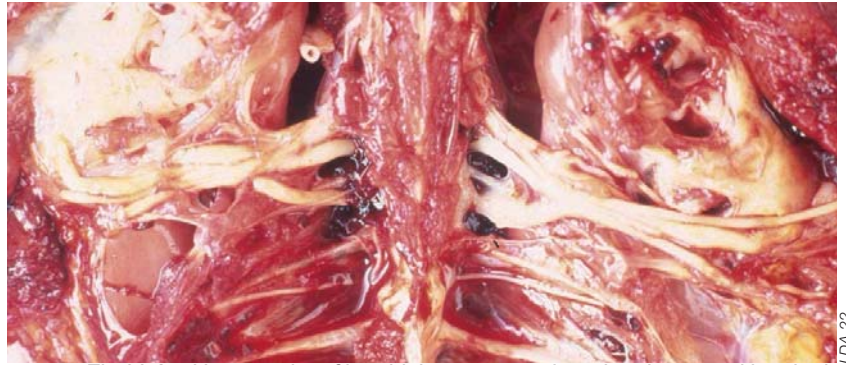


Fig.99.27: Hypertrophy of brachial nerves may be related to a nutritional origin (riboflavin deficiency?), pigeon being refractory to Marek's disease.

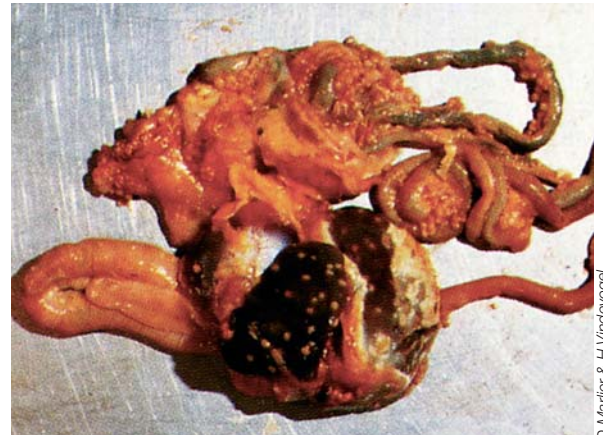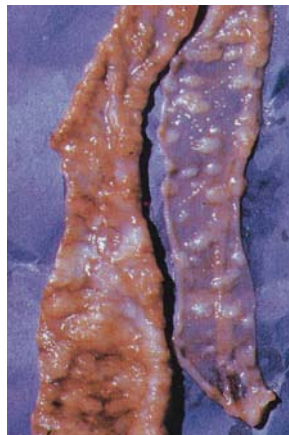

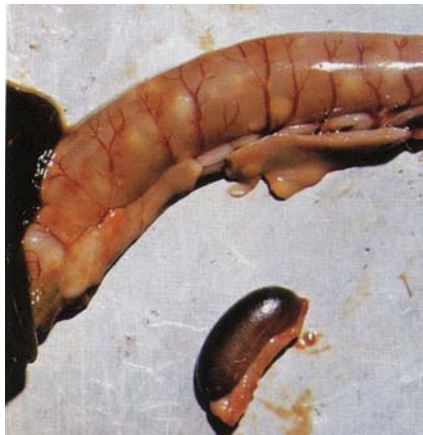
Fig.99.28, 99.29 & 99.30: Salmonellosis (*Salmonella Typhimurium*). Enlarged spleen, transversal ulcers visible by transparency in the duodenal loop, abscesses in the pancreas (left). Intestinal mucosal dotted with many transversal ulcers (middle). Multiple foci in the liver (right).

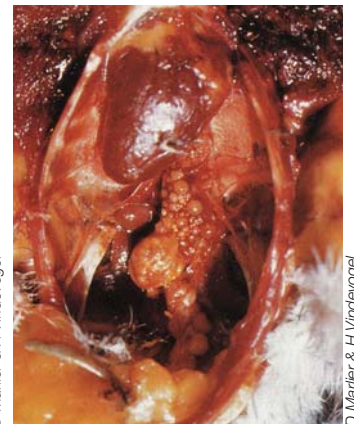
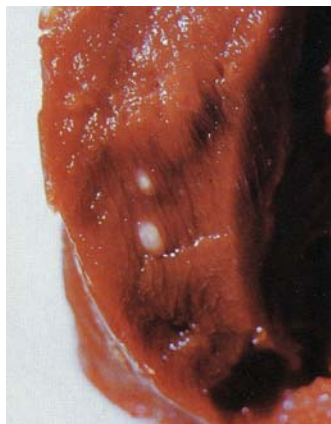

Fig.99.31, 99.32 & 99.33: Salmonellosis (*Salmonella Typhimurium*). Abscesses in the pectoral muscle (left). Humero radio-ulnar arthritis (middle). Oophoritis: caseous pedunculated follicles (right).

There is no specific treatment for adenovirus; the use of vaccines against EDS76 in chickens does not help, since the adenovirus associated with this disease belongs to group III.

Circovirus

The presence of viral particles morphologically similar to circoviruses has been described in 1993 in the United States. This virus infects squabs before the normal involution of the bursa of Fabricius, which is between the ages of five to six months; but viral particles have been found in the bursa as early as four weeks and as late as one year of age. The transmission of the infection is primarily horizontal via droppings but vertical transmission cannot be excluded. The bursa of Fabricius may be the portal of entry into the host for the virus. The virus is highly immunosuppressive and has a tropism for primary and secondary lymphoid organs. The clinical expression of the disease is highly variable, from asymptomatic to 100% mortality depending on secondary infections. Often vaccine failures are observed in particular when vaccinating against PMV1 infections. Generally, morbidity is significant, but mortality is limited, although squabs are in very poor general condition. Unlike the circovirus of parrots (Psittacine Beak and Feather Disease), feather and beak lesions are very rare. Diagnosis is made at necropsy, with the bursa appearing enlarged or atrophied depending on the stage of the disease. Diagnostic confirmation is obtained by observing basophilic intracytoplasmic inclusion bodies in the bursa of Fabricius or by the observation of paracrystalline arrays of non-enveloped virions by transmission electron microscopy. There is no specific treatment or vaccine.

Poxvirus

The pigeon poxvirus is transmitted primarily by contact. Pigeon pox is frequently encountered in squabs, either as a cutaneous epithelioma or in its diphtheroid form. Control is achieved by vaccination (live attenuated pigeon pox virus).

Leukosis

Neoplasias of viral origin observed in pigeons involve mainly the liver, kidneys and spleen.

BACTERIAL DISEASES

There are a considerable number of bacteria that enter the body of a weakened or stressed pigeon without having any recognized etiological role. The main bacterial diseases encountered in pigeons

include chlamydiosis, salmonellosis (paratyphosis), colibacillosis, pasteurellosis, pseudotuberculosis, tuberculosis, staphylococcosis and erysipelas. The clinical expressions of these diseases are presented in other chapters. Typically, the origin of septicemia in pigeons is usually attributed to *Salmonella* Typhimurium variety Copenhagen, more rarely, *Pasteurella multocida* or *Erysipelothrix rhusiopathiae*. An identical pathogenic role is now recognized for *Streptococcus gallolyticus*.

Streptococcus gallolyticus

Streptococcus gallolyticus (previously known as *Streptococcus bovis*) is one of the few pathogenic non- β hemolytic streptococci. There are five serotypes, five biotypes and two sub-biotypes; serotypes 1 to 5 representing 25, 48, 13, 3 and 10% of the strains isolated in Belgium, respectively. The pathogenicity varies according to the serotype, serotypes 1 and 2 being by far the most pathogenic. *Streptococcus gallolyticus* is an opportunistic pathogen. This bacterium is present in the intestinal microflora of 40% of healthy pigeons and can be detected in droppings collected in 80% of pigeon houses. At necropsy, infection with *S. gallolyticus* is found in about 10% of pigeons dying of septicemia. This infection affects pigeons of all ages. Carriers do not usually develop the disease. In an affected pigeon house, *S. gallolyticus* causes sudden deaths in adult birds as well as in young pigeons in the nests. Greenish mucoid droppings are observed. Some pigeons are lamed, while others are no longer able to fly. On palpation, it is possible to detect an indurated area in one of the superficial pectoral muscles. At necropsy, septicemic lesions with the congestion of various organs are observed. An area of focal necrosis, within one or two superficial pectoral muscles, and a serous or serofibrinous liquid around the tendon of the deep pectoral muscle or of the shoulder articulation are sometimes present and would be pathognomonic. The clinical diagnosis is very difficult and must be differentiated from *Salmonella* infection. Diagnostic confirmation is obtained on the basis of gross lesions seen at necropsy and after performing additional tests: culture of cardiac blood or hepatic parenchyma on Slanetz and Bartley agar. No vaccine is available, and even autovaccines have very limited effectiveness. Treatment consists in the administration of antibiotics, the best results being obtained with ampicillin, doxycycline, erythromycin and amoxicillin. Most strains are resistant to tetracyclines and sulfamides/trimethoprim. Relapses are frequent after the end of treatment in a pigeon house.

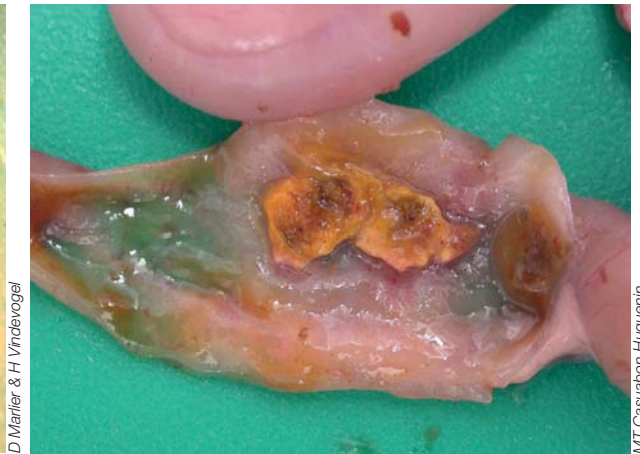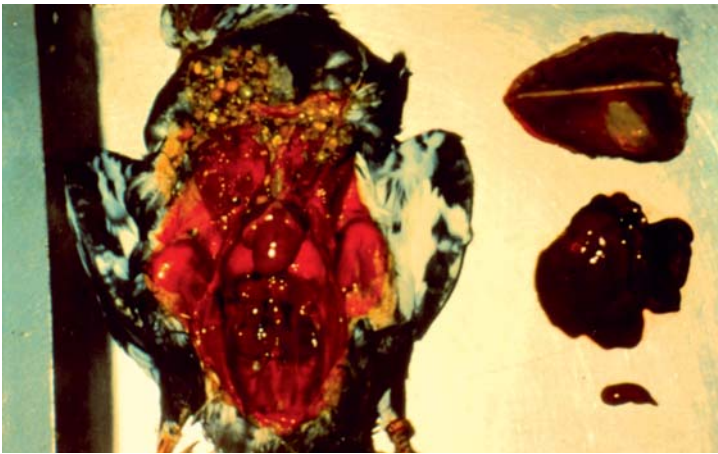


Fig.99.34: Septicemia (*S. gallolyticus*): generalized congested appearance of the cadaver, hepatomegaly and splenomegaly; area of focal necrosis in the right superficial pectoral muscle.

Fig.99.35: *Staphylococcus aureus*. Ulcerative enteritis (Pigeon).

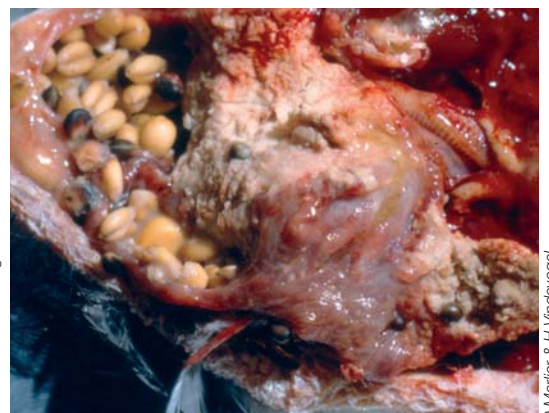
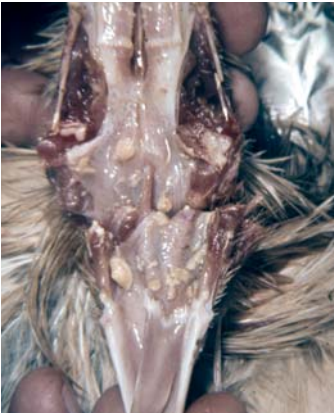
Fig.99.36: Trichomoniasis: abscess in the oral cavity.

Fig.99.37 & 99.38: Trichomoniasis: abscess in the crop.

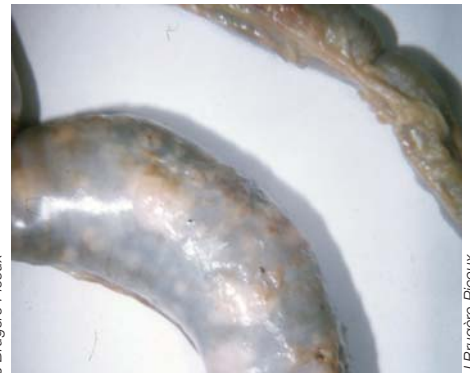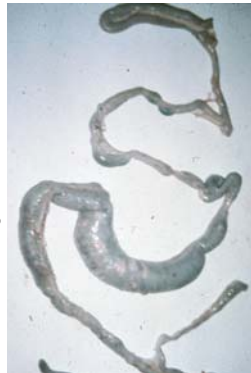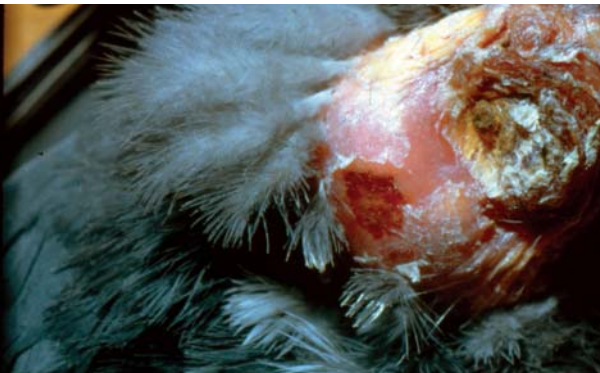


Fig.99.39: Trichomoniasis: abscess of the umbilicus.

Fig.99.40 & 99.41: Trichomoniasis has invaded the entire gastrointestinal tract.

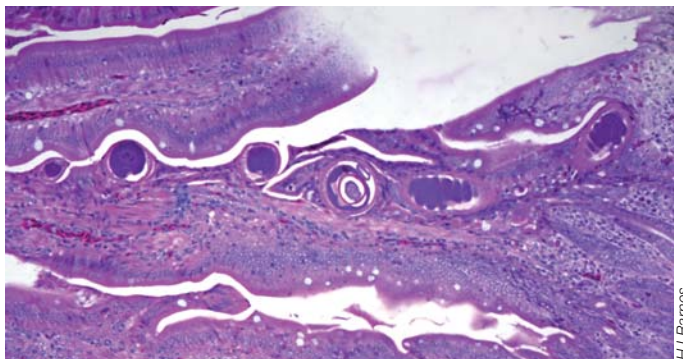
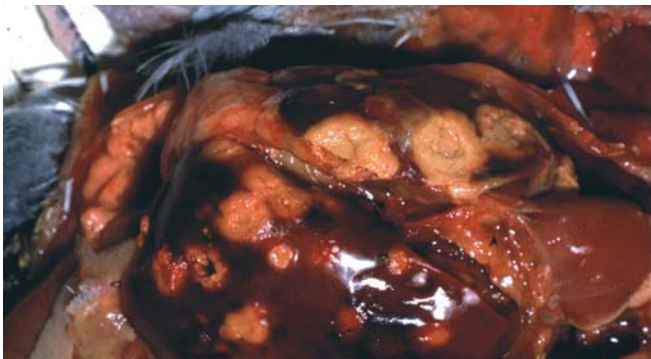


Fig.99.42: Trichomoniasis: multiple caseous abscesses in the liver.

Fig.99.43: Presence of *Capillaria* in the intestine (x 45).

Section VI

PARASITIC DISEASES

Like any other poultry, pigeons can be affected by internal parasites (coccidiosis, trichomoniasis, hexamitiasis, nematodes, cestodes, trematodes) or external parasites (mites, insects) and also fungal diseases (candidiasis, aspergillosis). Although some of these parasites are specific to pigeons, only trichomoniasis, which is very common in pigeons, is presented here.

Trichomoniasis

Trichomoniasis is a parasitic disease caused by a flagellate protozoan (*Trichomonas gallinae*) that reproduces by longitudinal binary fission. Eighty percent of birds are asymptomatic carriers. This infection spreads by direct and indirect contacts; *T. gallinae* surviving several hours in water troughs. Clinical signs in adults are a sore throat, poor flight performance, and more rarely watery diarrhea. In squabs, one can also observe «oral canker» with yellow necrotic lesions of the upper digestive tract (mouth, crop and esophagus). Sometimes there is a systemic spread with involvement of the viscera including the liver with dyspnea, the birds being in very poor general condition. Infections with *T. gallinae* are one of the factors responsible for the recurrence of Pigeon herpesvirus 1 (CoHV-1) episodes in carriers of this virus.

Classically, the treatment of these infections is by oral administration of imidazole derivatives such as carnidazole or ronidazole. Usually, preventive treatments are administered during brooding and curative treatment is reserved for sick birds during periods of competition. Unfortunately in recent years, fanciers have become accustomed to apply inadequate treatments (duration of treatment too short, excessive use, doses too low) and this has

led to the selection of resistant strains and a significant increase in treatment failure. A recent survey showed that the pathogenicity of *T. gallinae* strains is highly variable. *In vitro*, only 23% of strains were highly pathogenic, 35% were moderately pathogenic and 42% had low pathogenicity. Forty-five percent of the strains studied were close to the threshold of resistance, the number of resistant strains being higher when the strains were obtained from houses in which birds had received the most treatments. In 1975, almost all strains were sensitive to treatment with ronidazole at a level of 50 mg/liter of water. Today, the recommended treatment is 100 to 150 mg/liter for a minimum period of five to seven days. Therefore, treatment with the recommended dosage and duration of application should be reserved for heavily infected pigeons (systematic verification by swabbing the mucosa of the crop) showing clinical signs.

REFERENCES

- Duchatel JP *et al.*, Première mise en évidence en Belgique de particules ressemblant a des circovirus chez le pigeon voyageur. *Ann Méd Vét*, 1998,142: 425-428.
- Duchatel JP & Vindevogel H. Miscellaneous herpesvirus infections. In *Diseases of poultry* (ed Y.M. Saif), Blackwell Publ., Ames 2008, pp. 404-409.
- Vereecken M *et al.* Adenovirus infections in pigeons: a review. *Avian Pathol*, 1998,27: 333-338.
- Vindevogel H *et al.* Le pigeon voyageur, seconde édition. Edition du Point Vétérinaire. 1994.
- Vindevogel H *et al.* Fréquence de l'ornithose-psittacose et de l'infection herpétique chez le pigeon voyageur et les psittacidés en Belgique. *Rev Méd Liège*, 1981,36:693-696.
- Woods LW & Latimer KS. Circovirus infection on nonsittacine birds. *J. Avian Med Surg*, 2000,14: 154-163.



Fig.100.1: "Red-necked" Ostrich originating from east Africa.



Fig.100.2: Adult female ostriches in a French farm.



Fig.100.3: Adult emu.



Fig.100.4: Adult male (left) and female (right) ostrich.



Fig.100.5: Adult rhea.



Fig.100.6: From left to right: ostrich, emu and rhea eggs. Chicken egg in foreground for scale.



Fig.100.7 & 100.8: Incubators for ostrich's eggs.



Fig.100.9: Mirage of ostrich's egg.



Fig.100.10: Hatching of ostrich's eggs.



Fig.100.11: Group of young emu chicks.



Fig.100.12: Group of young ostrich chicks.

Other species

100. BREEDING & DISEASES OF RATITES

INTRODUCTION

The general term «ratite» refers to a group of flightless birds in the family *Struthioniformes*, and comes from the Latin «*ratiss*» meaning raft, referring referring to these birds' flat smooth sternum without a keel. Ratites raised commercially include the ostrich, emu and rhea.

The ostrich (*Struthio camelus*) originated throughout Africa and into the Middle East, but survives now only in geographically limited pockets of Africa. Ostriches are the largest living birds; males stand two to three meters in height and weigh up to 150 kg. Females are smaller weighing up to 120 kg. Males have black and white plumage; females and juveniles are brownish grey. Longevity and productivity of over 50 years have been recorded. Ostriches raised domestically in South Africa are known as South African blacks. Birds originating from East (*S. c. massaicus*) and Southern Africa (*S. c. australis*) are known as «red-necked» and «blue-necked», respectively, based on the colour of the legs and necks of male birds during the breeding season. Wild north African (*S. c. camelus*) and Somali (*S. c. molybdophanes*) ostriches also occur, but in geographically limited ranges.

The emu (*Dromaius novaehollandiae*) is native to Australia. Birds may reach 1.8 meters in height and weigh up to 50 kg. Females are slightly taller and heavier. Both sexes have brown and black feathering. The feathers have two separate vanes due to splitting of the feather shaft. Emus have lived up to 30 years in zoos.

The rhea is native to South America. The greater or common rhea (*Rhea americana*) is raised commercially and is smaller than the ostrich and emu, standing up to 1.5 meters in height and weighing 20 to 25 kg. Males may be slightly larger. Birds have grey-brown plumage, which may be darker in the male. The lesser or Darwin's rhea (*Rhea pennata*) is not raised commercially but may be found in zoological collections.

THE RATITE INDUSTRIES

Wild ostriches were captured and domestically bred for commercial feather production, particularly in South Africa, starting in the late 1800's. This industry collapsed early in the 20th century; however, in the 1980's there was a world-wide

resurgence in commercial ostrich farming. Extensive selective breeding of birds has resulted in the «domestic» ostrich, identified as *Struthio camelus* var *domesticus*. Farming of emus, particularly in Australia and North America, and, to a much lesser extent rheas followed. In the 1990's the ratite boom again collapsed as much of the market was based on the sale of chicks to initiate new ventures. The industry has survived at a lower level of production with ostriches still the predominant farmed species worldwide.

Ratites are generally slaughtered between 12 and 18 months, depending on species, season, and husbandry. The traditional products are leather, meat and feathers. Ostrich leather is supple with a prominent quill pattern and is used for a variety of expensive items including cowboy boots, clothing, and handbags. Emu hide is similar, with a more subtle quill pattern. Leather from the birds' legs resembles crocodile or snake-skin.

Ratite meat is similar in appearance and taste to beef and is sold fresh, frozen, or dried. Ratite meat is promoted both as a meat and as a healthy food, due to its low (2-3%) fat content. Ostrich feathers are used for costumes and clothing, and for industrial and domestic feather dusters. Feathers are obtained at slaughter or are plucked from birds raised specifically for feather production. South Africa continues to dominate the world feather market. Markets also exist for products such as cosmetics and emollient creams containing oil rendered from the thick dorsal subcutaneous fat pad and abdominal fat of the emu. This unsaturated, highly penetrating oil is believed to have anti-inflammatory properties. The oil from rhea and ostrich can be also utilized. Small secondary craft markets exist for items made from ratite eggs and feathers.

ANIMAL PRODUCTION

Ratites can be raised intensively or extensively, depending on the climate and amount of area available. In cold northern climates shelter from the elements must be made available. Formulated diets are used in intensive management situations. Breeding animals are generally kept as pairs or trios (ostrich male plus hens). Ostriches and rheas breed in the long-daylight season, in contrast to emus which are short-daylight season breeders. Eggs are collected after lay, stored, and artificially



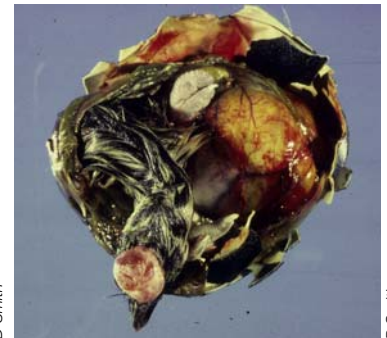
D Smith

Fig.100.13: Ostrich egg malformed.



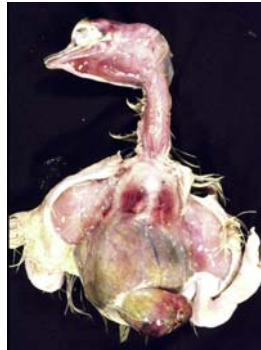
D Smith

Fig.100.14: Emu unhatched egg with bacterial infection (left) and uninfected hatched egg with membranes removed (right).



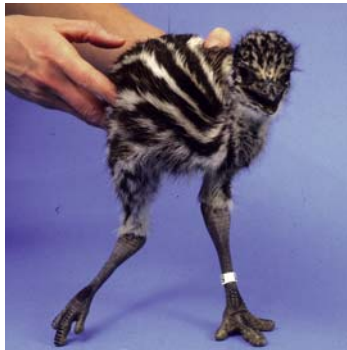D Smith

Fig.100.15: Emu embryo with congenital encephalococele.



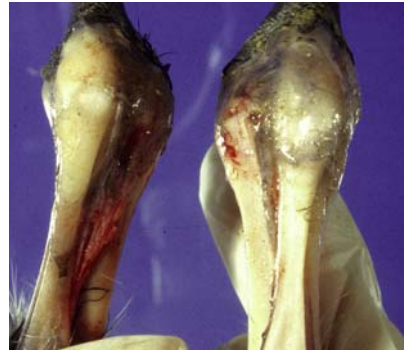V Boves

Fig.100.16: Edematous ostrich chick, dead at hatching.



D Smith

Fig.100.17: Emu chick with rotational deformity of right tarsometatarsus. Bird has also been "declawed".



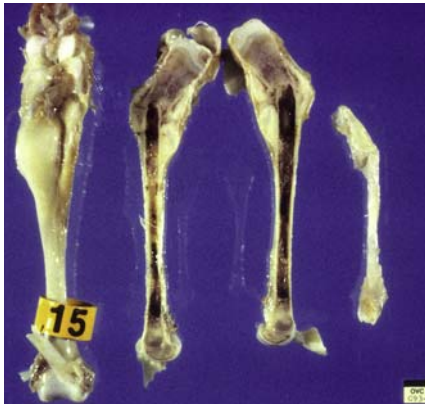D Smith

Fig.100.18: Tibiotarsii and hock joints of emu chick showing medial subluxation of the gastrocnemius tendon (right) associated with rotational deformity.



D Smith

Fig.100.19: Rhea chick with rickets.



D Smith

Fig.100.20: Long bones from rhea chick with metabolic bone disease - rickets.



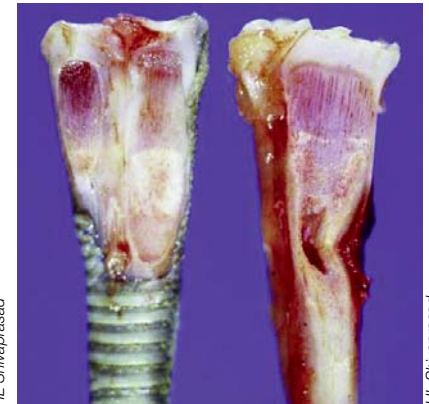HL Shivaprasad

Fig.100.21: Ostrich with rickets of tarsometatarsi.

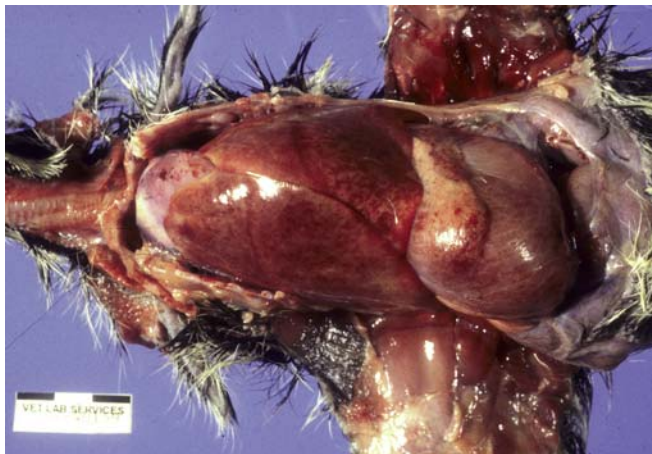

HL Shivaprasad

Fig.100.22 & 100.23: Rickets rhea chick with pathologic fracture.

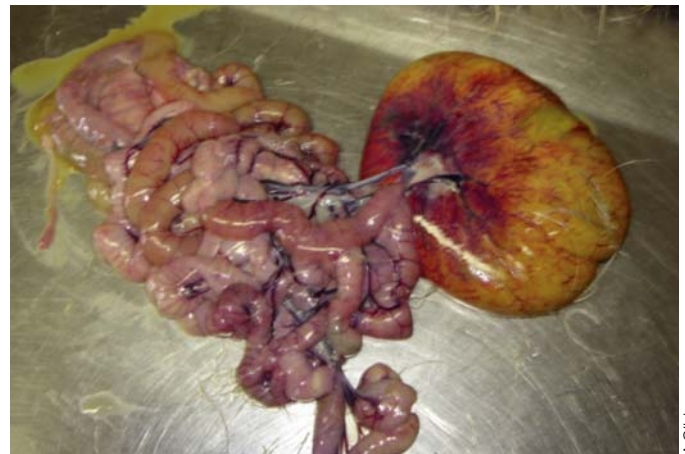

HL Shivaprasad



D Smith

Fig.100.24: Emu chick with bacterial septicemia.



A Olivier

Fig.100.25: Yolk sac retention in an ostrich chick.

incubated in order to maximize production. Average incubation times are 42 days for ostrich, 52 days for emu, and 35-40 days for rhea. Chicks are grouped according to age and/or size after hatching, and are raised in increasingly large enclosures until slaughter, generally on the farm of origin. Growth rates are extremely rapid; associated leg deformities are one of the most common important constraints on chick production.

GENERAL EPIDEMIOLOGY

Ratites are susceptible to a variety of infectious and non-infectious disease conditions. Non-infectious conditions such as trauma, and conditions predisposed to by management factors (e.g., developmental leg deformities, gastric impaction and respiratory aspergillosis) predominate on many farms. The majority of losses occur in chicks less than six months of age. Ratites are easily stressed by environmental or management changes.

Infectious diseases of ratites may be those imported from the countries of origin of the birds, for example, ectoparasitic lice and mites and many gastrointestinal nematodes or may be endemic to the countries where the birds are being raised. Ratites are susceptible to diseases of, and could act as sources of infection for, other avian species including poultry. The clinical signs and pathological features of these diseases in ratites are generally similar to those in other avian species. Readers are directed to the appropriate sections of this book for more detailed descriptions. Little experimental work has been carried out on the epidemiology of disease in ratites, hindered initially by the high value of individual birds and more recently by a lack of funds within the industry. Most of our knowledge on infectious diseases is derived from single animal case reports or outbreaks of disease in small groups of animals.

REGULATORY AND PUBLIC HEALTH ISSUES

Most countries have veterinary regulations concerning the commercial farming and import and export of ratites. These are usually designed to detect or control diseases of major concern to poultry industries, particularly velogenic Newcastle disease and avian influenza, and to exclude foreign disease agents, especially arthropod ectoparasites. The importation and exportation of fertile eggs are often regulated as well.

In some countries ratites are classified as poultry under slaughter regulations. Infectious agents of public health concern include the salmonellae (par-

ticularly *Salmonella* Typhimurium and *S. Enteritidis*), *Campylobacter jejuni*, and possibly *Chlamydia psittaci* or *Erysipelothrix rhusiopathiae*. Crimean Congo hemorrhagic fever has been identified in ostrich slaughterhouse workers in South Africa.

INCUBATION PROBLEMS

Poor success in incubation and hatching results from problems including: inadequate nutrition of or reproductive disease in the dam; poor hygiene in the nest area, during collection and handling, or in the incubator; and improper environmental parameters during incubation and hatching (for example, temperature, humidity, and ventilation). Accurate records are essential to unravel the causes of losses during this period. Eggs can be candled during incubation using strong light sources (ostriches, rheas) or infrared candlers (emus, whose eggs are green).

Unhatched eggs should be checked for fertility, the embryo should be examined for congenital anomalies and measured to try and estimate its developmental age, and the yolk cultured for bacterial or fungal pathogens. Infections can occur transovarially, from fecal or environmental contamination after lay, and from contamination within the incubator. Full embryo necropsies can be performed, especially if there is an increase in embryo mortality or the production of weak chicks. Deaths late in hatching may be associated with abnormal positioning of the embryo within the shell. General patterns of abnormalities can suggest particular areas of concern as they would in other avian species raised commercially. Weak chicks and mortality within the first week of life often reflect the incubation process, rather than difficulties with chick management.

PARTICULAR DISEASES OF CHICKS

The major disease conditions of ratite chicks include: yolk sac retention and infection (bacterial or mycotic); bacterial enteritis and septicemia; gastric impaction and foreign body ingestion; rotational leg deformities associated with rapid growth; and metabolic bone disease. A condition of undetermined etiology, called fading chick syndrome, can result in high mortality in young ostriches. Affected birds waste without specific clinical signs or pathological lesions. Other infectious diseases affecting ostrich chicks include proventricular *Macrorhabdos ornithogaster* (megabacteriosis, avian gastric yeast) and systemic adenoviral infection, both of which can result in high mortality, and cryptosporidial

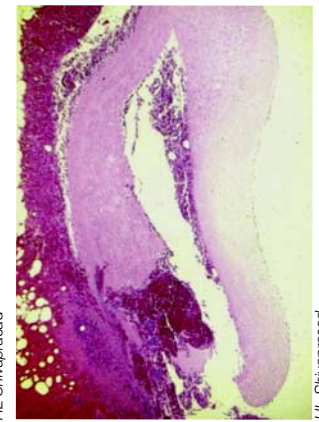
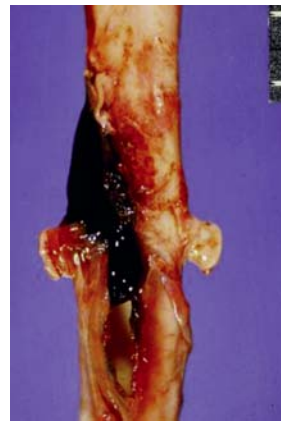
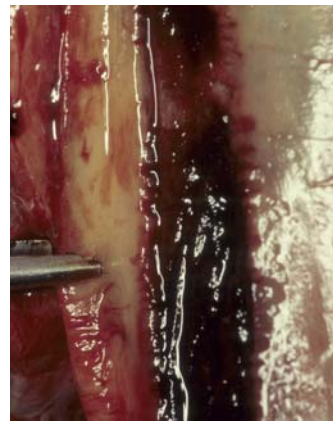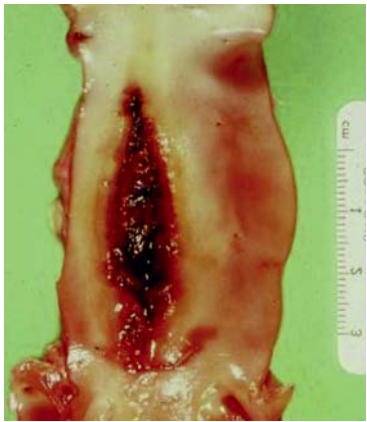Fig.100.26, 100.27 & 100.28: Aortic rupture in ostrich and emu.

Fig.100.29: Aortic rupture. Histopathology.

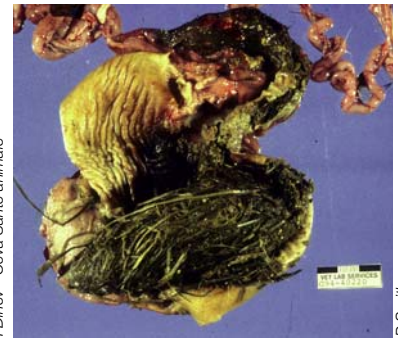


Fig.100.30 & 100.31: Hyperkeratosis in an ostrich linked to impaired metabolism of sulfur-containing amino-acids and vitamin A deficiency.

Fig.100.32: Emu chick - proventriculus and ventriculus impacted with long grass.



Fig.100.33: Ostrich chick - proventriculus and ventriculus impacted with long grass.

Fig.100.34 & 100.35: Foreign material from the proventriculus and ventriculus of an ostrich chick (left) and emu chick (right) can lead to impaction.



Fig.100.36 & 100.37: Female ostrich and young ostrich with feather loss due to feather pecking by self or penmates.

Fig.100.38: Traumatic injuries to the wing of an ostrich.

cloacitis. Megabacteriosis has also been described as a cause of mortality in young rhea.

NON-INFECTIOUS CONDITIONS

Significant losses can derive from trauma, predation and exertional myopathy. Important nutritional diseases include metabolic bone disease (inadequate or imbalanced Ca, P or Vitamin D; phosphorus deficiency rickets in rhea), nutritional myopathy (Vit E/Se deficiency), and aortic rupture presumed due to copper deficiency. Conditions resembling B vitamin deficiencies have also been reported.

Toxic conditions reported include: mycotoxicoses; botulism; heavy metal, salt, and anticoagulant rodenticide poisoning; ingestion of toxic plants (parsley, avocado leaves, yew, acorns, *Lantana camara*, *Senecio sceleratus*), fish meal (gizzerosine), and beetles (cantharidin); and toxicity of therapeutic agents (e.g., furazolidone, ionophores, morantel, lincomycin).

Other sporadic conditions described include familial neuronal storage disease in emu, cloacal prolapse in ostrich and emu chicks associated with cloacitis, intestinal accidents, and heat stroke. Behavioural abnormalities in ostriches may mimic neurologic disease.

BACTERIAL DISEASES

A variety of Gram positive and Gram negative bacteria, for example, *Escherichia coli* cause localized and systemic infections. *Salmonella* spp., especially *S. Typhimurium*, can cause omphalitis, enteritis, septicemia, and sudden death. Emus experimentally infected with *S. Pullorum* seroconvert but actual disease has not been recognized. *Campylobacter jejuni* has been isolated from asymptomatic ratites, and from yolk sac infections, enteritis, and hepatitis in ostrich chicks.

Other organisms causing systemic infection include: *Chlamydia psittaci*, *Mycobacterium avium*, *Pasteurella multocida*, *Bacillus anthracis*, and *Erysipelothrix rhusiopathiae*. Mycoplasmas, including *M. gallisepticum* and *M. synoviae*, have caused sinusitis and respiratory disease in rheas and ostriches, often in conjunction with opportunistic bacteria such as *Avibacterium paragallinarum*, *Bordetella bronchiseptica* and *Bordetella avium*. *Mycobacterium avium* infection generally results in gastro-intestinal/hepatic disease, but cutaneous or mucocutaneous lesions may be identified initially.

Clostridia, especially *Clostridium perfringens* and *Clostridium difficile*, can cause necrotic enteritis and enterotoxemia, particularly after stress or dietary and management changes. In rhea, necrotizing typhlocolitis is caused by combined infection by a spirochete (*Brachyspira hyodysenteriae*) and *Trichomonas* spp. Other bacterial agents include a *Lawsonia* spp. from juvenile emus with cloacitis and cloacal prolapse, and *Clostridium sordellii* from ostriches with hepatitis.

FUNGAL DISEASES

Pulmonary aspergillosis is a significant problem, particularly in young chicks and juveniles. Mycotic upper gastrointestinal system infection caused by *Candida* and zygomycete species occurs in stressed or heavily treated birds. Proventricular infection by *Macrorhabdus ornithogaster* can cause mortality in ostrich and rhea chicks. Dermatomycosis has been described in ostriches.

VIRAL DISEASES

Ratites are susceptible to Paramyxovirus-1 (Newcastle disease) and type A orthomyxoviruses, although their susceptibility does not appear to

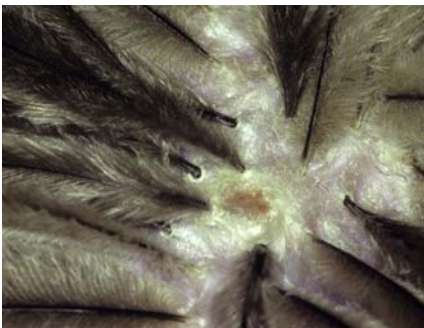

Fig.100.39: Mycobacterial skin lesion in an emu.

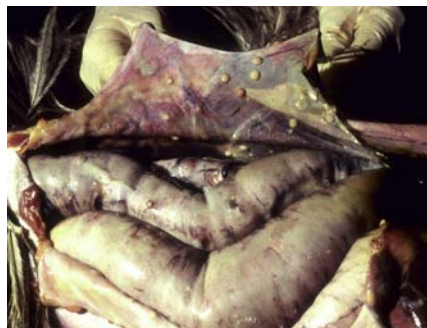

Fig.100.40: Visceral mycobacterial granulomas in an adult emu.

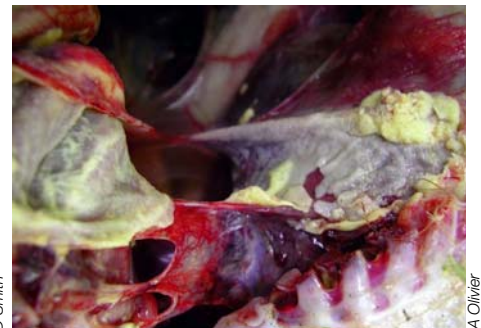
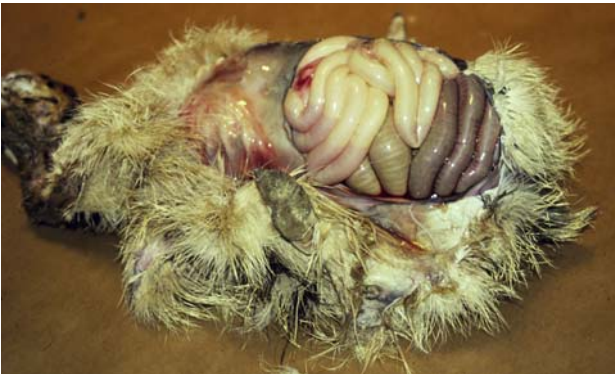
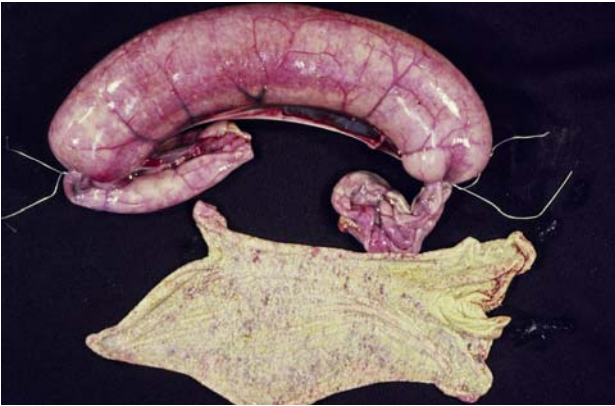
Fig.100.41: Respiratory infections of ostrich associated with mycoplasmas and/or *Escherichia coli* cause airsacculitis characterized by a fibrinous exudate.



V.Bowes

Fig.100.42: Distended intestinal loops in ostrich chick with necrotic enteritis (*Clostridium perfringens*).



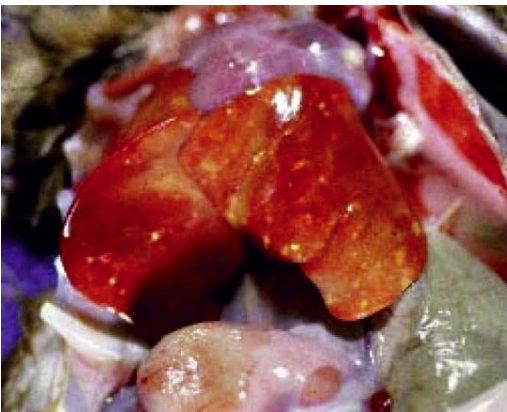
V.Bowes

Fig.100.43: Intestinal segments from ostrich chick with necrotic enteritis (*Clostridium perfringens*).

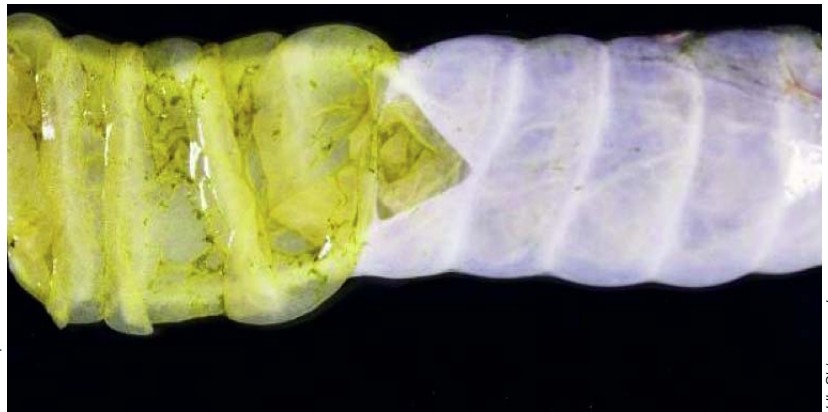


HL Shivaprasad


Fig.100.44: Distended and congested intestinal loops in ostrich with necrotic enteritis (*Clostridium perfringens*).



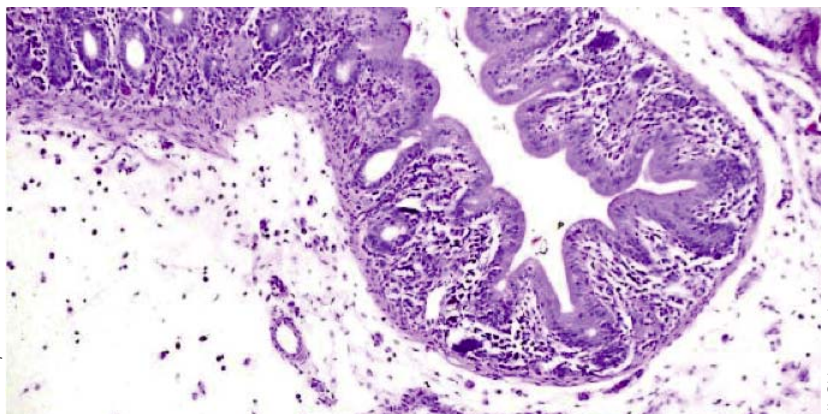
HL Shivaprasad



HL Shivaprasad



HL Shivaprasad



HL Shivaprasad

Fig.100.45 & 100.46: Hepatitis (*Clostridium difficile*) in ostrich.

Fig.100.47 & 100.48: Typhlitis (*Clostridium difficile*) in ostrich.

mirror that of domestic poultry. Outbreaks of LPAI and HPAI (including H7N1) have occurred in ostriches in Africa, particularly South Africa. Acute hemorrhagic enterocolitis and high mortality occur in emu, and possibly ostrich, infected with the Eastern equine encephalomyelitis virus. Neurologic signs predominate with infection of these species by the Western equine encephalomyelitis virus.

The following viral diseases have also been identified in ostriches: avipoxvirus, type 2 avibirnavi-

ruses (infectious bursal disease, ostrich and rhea), Crimean Congo hemorrhagic fever (South Africa), Borna disease (Israel) and Wesselsbron disease (South Africa). Viruses which have been isolated but whose significance is unclear include circovirus from ostrich embryos and eggs, and enteric rotaviruses and coronaviruses. Finally, a spongiform encephalopathy reminiscent of transmissible subacute spongiform encephalopathies in mammals has been reported in Germany (see Chap.II.39).

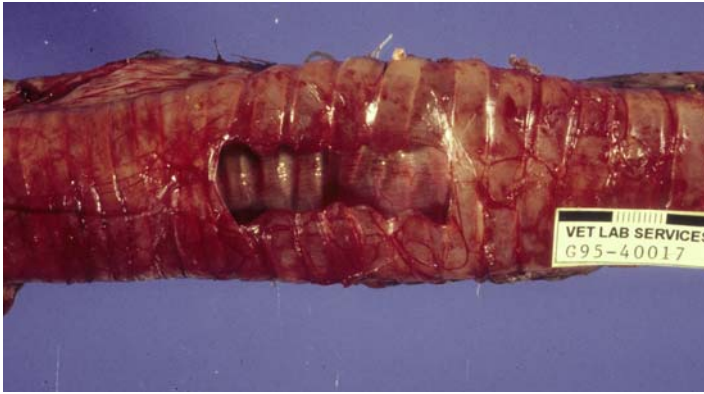


Fig.100.49: Normal feature of the emu trachea-cleft in the tracheal cartilage covered by a thin membrane.

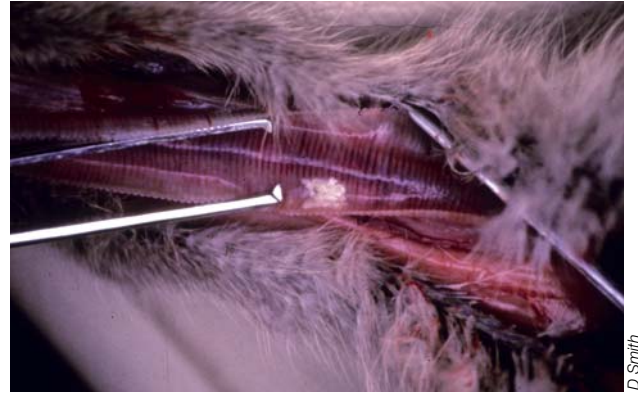

Fig.100.50: Focal mycotic tracheal lesion in a rhea chick.

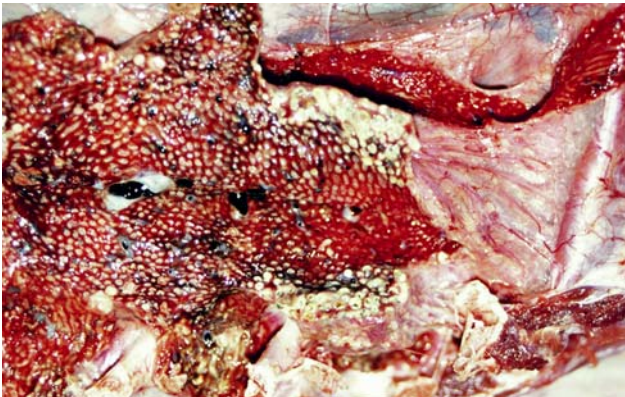

Fig.100.51: Mycotic pneumonia in an ostrich.

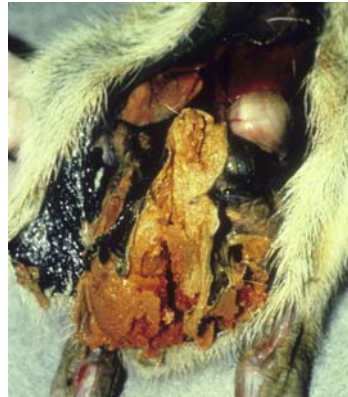

Fig.100.52: Mycotic air sacculitis (aspergillosis) in an ostrich chick.

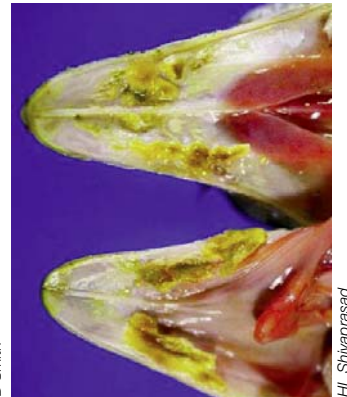

Fig.100.53: Candidose oral cavity ostrich. Note that there is no crop in ratites.

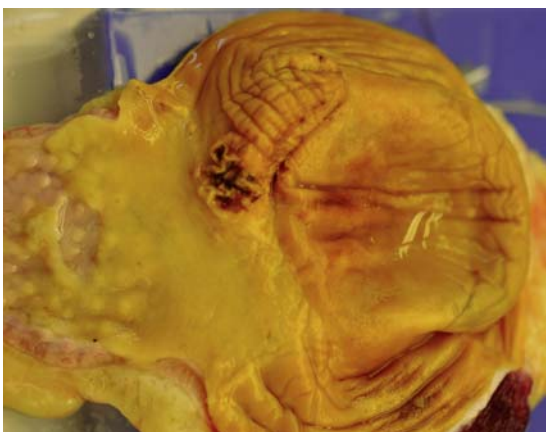


Fig.100.54: *Macrorhabdus ornithogaster* (Hobby chicken). Proventriculus and gizzard.

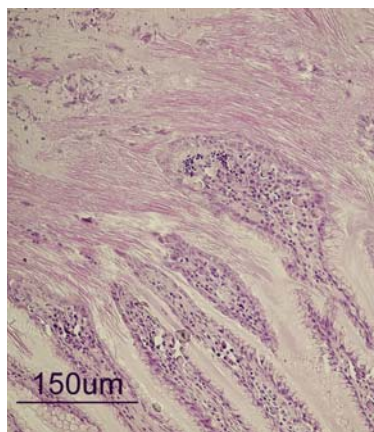
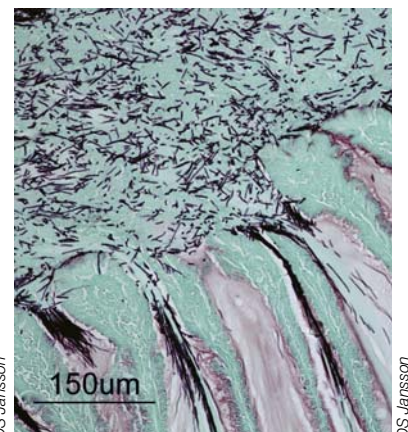


Fig.100.55 & 100.56: *Macrorhabdus ornithogaster*. Proventriculitis (Grey partridge). Histopathology. Hemalun-Eosin stain (left) and Grocott (right) staining.



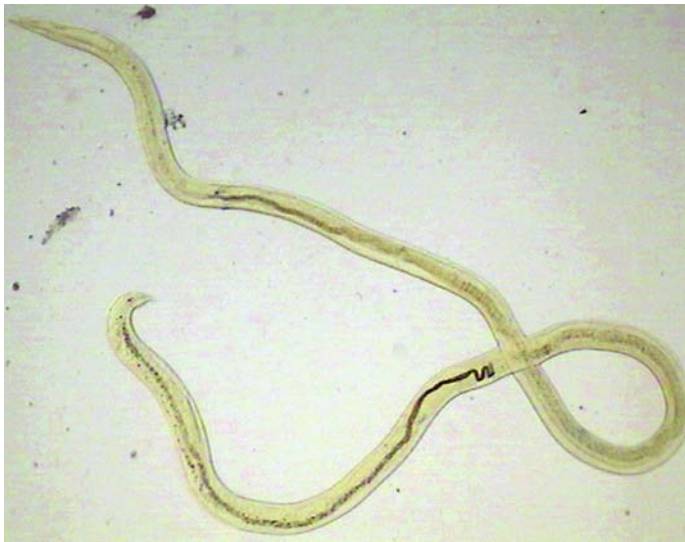


Fig.100.57: *Libyostrongylus* female and egg (Ostrich).

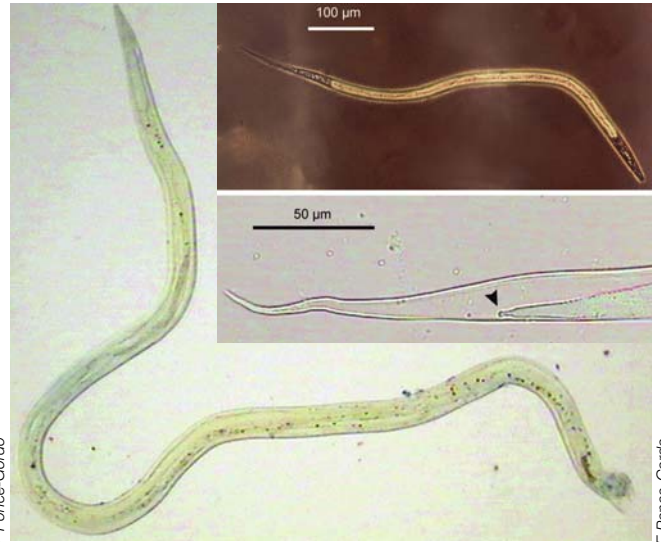

Fig.100.58 & 100.59: *Libyostrongylus* male and larvae (Ostrich).

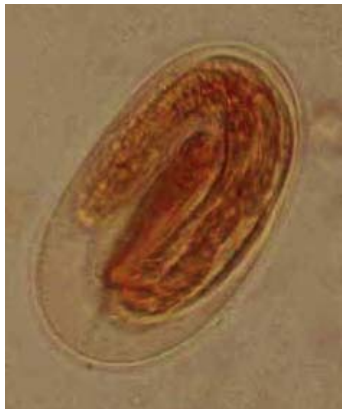

Fig.100.60: *Libyostrongylus* (egg) (Ostrich).

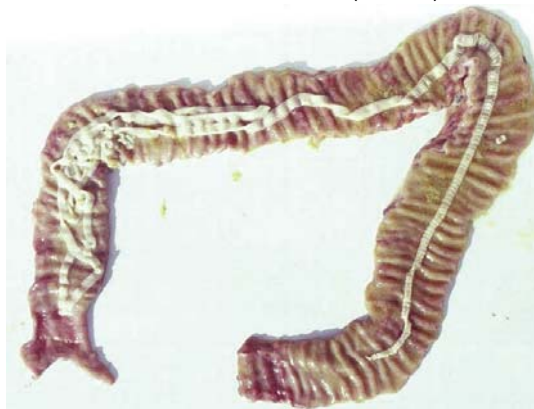

Fig.100.61: *Houuttuyenia* (Ostrich).

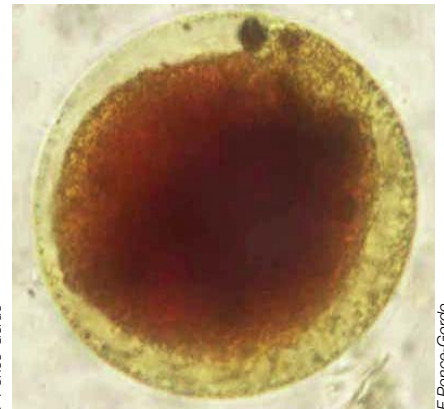


Fig.100.62: *Balantidium* (Ostrich).



Fig.100.63 & 100.64: Ostrich feather with nits of *Struthiolipeurus struthionis* located adjacent to shaft.



Fig.100.65 & 100.66: *Struthiolipeurus struthionis*. Male (left) and female (right).

Section VI

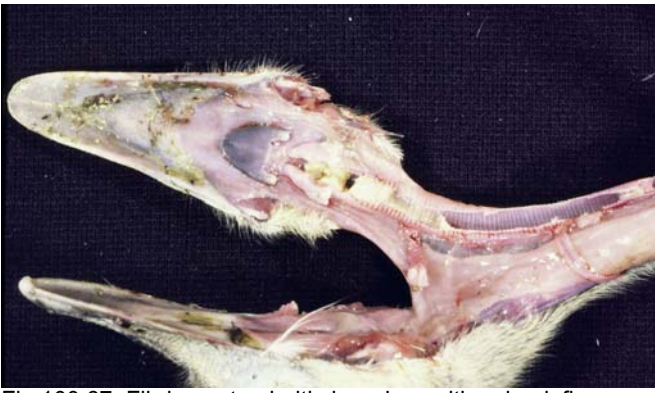

Fig.100.67: Fibrinous tracheitis in a rhea with avian influenza.

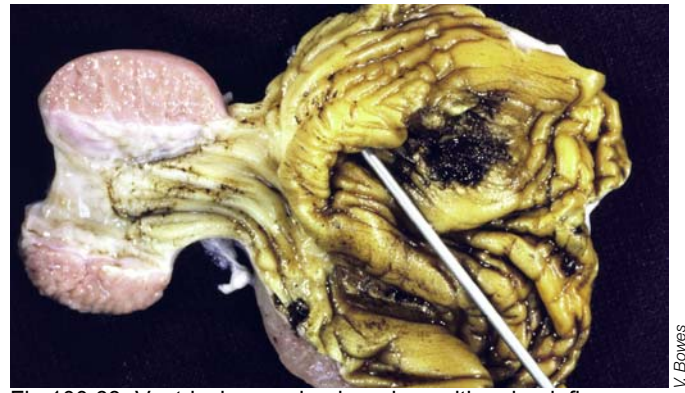


Fig.100.68: Ventricular erosion in a rhea with avian influenza.

PARASITIC DISEASES

The most significant parasites of ratites are:

- *Libyostrongylus douglassi*, a nematode of the proventriculus and ventriculus of ostriches that results in failure to thrive, anemia, impaction, and high mortality in chicks;
- *Houttuynia struthionis*, a small intestinal cestode of ostrich and rhea that can result in poor growth;
- *Deletrocephalus dimidiatus*, an intestinal nematode of rhea causing diarrhea, anemia, and death;
- *Struthiolipeurus struthionis*, the ostrich feather louse which causes irritation, feather loss, poor feather condition, and excessive grooming.

A number of other enteric nematode, trematode, acanthocephalan, and protozoal parasites have been identified from ratites. Protozoal diseases described include giardiasis (ostrich, emu) cryptosporidiosis (ostrich), coccidiosis, toxoplasmosis, histomoniasis (ostrich, rhea) and balantidiosis (ostrich).

Parasites of the respiratory system include *Syngamus trachea* (ostrich, rhea), *Cyathostoma bronchialis* (or *variegatum*) (emu), and air sac and pulmonary filarial nematodes (ostrich, rhea).

Aberrant cerebral migration of *Baylisascaris procyonis* larvae (ostrich and emu, normal host - raccoon) and *Chandlerella quisquali* (emu, normal host - grackle) have been described in North America.

Ectoparasites identified include a variety of Ixodid and Argasid ticks on ostriches; quill mites on ostrich and rhea (eg., *Struthiopterolichus bicaudatus*, *Gabucinia bicaudata*); and feather lice (eg., *Struthiolipeurus* spp.) on ostrich, emu and rhea. Ratites can be harassed and made anemic by large numbers of biting insects such as midges and thrips.

Hemoparasites recognized include *Leukocytozoon struthionis*, *Plasmodium struthionis*, and

Aegyptianella pullorum in ostriches in Africa. *Plasmodium* spp. have also been seen in rhea (*P. relictum*) and emu.

REFERENCES

- Gordo FP et al. Parasites from farmed ostriches (*Struthio camelus*) and rheas (*Rhea americana*) in Europe. *Vet Parasitology*, 2002, 107:137-160.
- Hallam MG. The Topaz Introduction to Practical Ostrich Farming, Zimbabwe, M.G Hallam, 1992.
- Huchzermeyer FW. *Diseases of Ostriches and Other Ratites*, Agricultural Research Council, Onderstepoort 1998.
- Jansson DS et al. Mycotic Proventriculitis in Gray Partridges (*Perdix perdix*) on Two Game Bird Farms. *J Zoo Wildlife Med*, 2008,39:428-437.
- Jensen JM et al. Husbandry and Medical Management of Ostriches, Emus and Rheas, Wildlife and Exotic Animal Teleconsultants, College Station, Texas, 1992.
- Kummrow, MS. Ratites or Struthioniformes: Struthionines, Rheae, Cassuarii, Apteryges (Ostriches, Rheas, Cassowaries, and Kiwis) and Tinamiformes (Tinamous). In: Fowler's Zoo and Wild Animal Medicine, vol 8, eds RE Miller and ME Fowler, Elsevier Health Sciences, 2014, pp. 75-82.
- Minnaar M. The Emu Farmer's Handbook, vol 2, Nyoni Publishing Company, Groveton, Texas, 1998.
- Minnaar P & Minnaar M. The Emu Farmer's Handbook, Induna Company, Groveton, Texas, 1992.
- F Ponce Gordo et al. Parasites from farmed ostriches (*Struthio camelus*) and rheas (*Rhea americana*) in Europe. *Vet parasitology*, 2002,107:137-160.
- Smith DA. Ratites: Tinamiformes (tinamous) and Struthioniformes, Rheiformes, Cassuariformes (ostriches, emus, cassowaries, and kiwis). In: Fowler ME and Miller RE (eds). *Zoo and Wild Animal Medicine*. 5th edition, Saunders, St Louis, 2003, pp. 94-102.
- Tulley TN & Shane SM (eds). *Ratite Management, Medicine and Surgery*, Krieger Publishing Company, Florida 1996.
- Tulley TN & Shane SM (eds). *Ratites: Veterinary Clinics North America: Food Animal Practice*, WB Saunders, Philadelphia, 1998, 14(3).
- Verwoerd DJ. Ostrich Diseases. *Revue Scientifique et Technique OIE*, 2000,19:638-661.

Symptoms & lesions	Species affected	Main clinical signs & lesions	Etiology	Chap.	
BEAK	Deformities	Poultry	Severe beak trimming or toe trimming	Impaired interventions I.3 I.9	
		Psittacines	Acute: sudden death; immunosuppression (acute bursal necrosis); chronic: dystrophic feathers, stunting; immunodepression (necrosis of bursa)	Psittacine beak and feather disease (<i>Circovirus</i>) II.39	
		All species	Lameness; stunting; beaks, claws and bones soft and flexible; enlarged joints (rickety beads); thin or soft-shelled eggs; egg drop; decrease in hatchability	Rickets Osteomalacia IV.69 IV.71	
MOUTH & PHARYNX	Proliferative stomatitis	All species	Cutaneous form: nodular proliferative skin lesions progressing to thick scabs; diphtheritic form: upper digestive and respiratory tract lesions	Fowlpox (<i>Avipoxvirus</i>) II.31	
		Psittacines	Respiratory signs: laryngitis, tracheitis, bronchopneumonia; conjunctivitis, airsacculitis; esophagitis	Pacheco's disease (<i>Psittacid herpesvirus 1</i>) II.39	
		All species	Hyperkeratosis (cornea, mouth, esophagus); nutritional nephropathy; ruffled feathers, corneal hyperkeratosis; nerve lesion; egg drop	Vitamin A deficiency IV.71	
		All species	Reduced feed intake; digestive lesions mainly in crop (coated with multifocal or confluent mats of white cheesy material)	Candidiasis (<i>Candida albicans</i>) IV.62	
		Pigeon, turkey, chicken, etc.	Anorexia; ruffled feathers; «oral canker» (yellow plaques or cheesy masses in buccal cavity, pharynx, esophagus and crop); systematic spread (liver)	Trichomoniasis (<i>Trichomonas gallinae</i>) IV.67	
	Ulcerative stomatitis	All species	Chemicals products: quaternary ammonium, copper sulfate, etc.	Caustic products	
		Psittacines	Sudden death; acute bursal necrosis; chronic: dystrophic feathers, stunting; immunodepression (necrosis of bursa)	Psittacine beak and feather disease (<i>Circovirus</i>) II.39	
		Ducks, turkeys, goose, guinea fowls, etc.	Acute intoxication: diarrhea; necrotic lesions (oral mucosa, gastrointestinal tract); chronic poisoning: stunting; abnormalities of feathering; egg drop; hepatitis; immunodepression (atrophy of bursa)	Trichothecene poisoning (<i>Fusarium</i> spp.) IV.63	
		All species	Feed too finely ground	Nutritional disease IV.71 IV.74	
		Pigeons, turkeys, chickens, etc.	Anorexia; ruffled feathers; «oral canker» (yellow plaques or cheesy masses in buccal cavity, pharynx, esophagus and crop); systematic spread (liver)	Trichomoniasis (<i>Trichomonas gallinae</i>) IV.67	
	ESOPHAGUS & CROP	Dilatation of the crop	Turkeys, chickens	Crop greatly distended and full of feed, particles of bedding, and fluid	Pendulous crop IV.71
			All species	Accumulation of hard, fibrous feed, litter or foreign bodies	Crop impaction IV.71
All species			Reduced feed intake; digestive lesions mainly in crop (coated with multifocal or confluent mats of white cheesy material)	Candidiasis (<i>Candida albicans</i>) IV.62	
Inflammation		Ducks, turkeys, geese, guinea fowls, etc.	Acute intoxication: diarrhea; necrotic lesions (oral mucosa, gastrointestinal tract); chronic poisoning: stunting; abnormalities of feathering; egg drop; hepatitis; immunodepression (atrophy of bursa)	Trichothecene poisoning (<i>Fusarium</i> spp.) IV.63	
		Pigeons, turkeys chickens, etc.	Anorexia; ruffled feathers; «oral canker» (yellow plaques or cheesy masses in buccal cavity, pharynx, esophagus and crop); systematic spread (liver)	Trichomoniasis (<i>Trichomonas gallinae</i>) IV.67	
		All species	Hyperkeratosis (cornea, mouth, esophagus); nutritional nephropathy; ruffled feathers, corneal hyperkeratosis; nerve lesion; egg drop	Vitamin A deficiency IV.71	
Ulcers		All species	Catarrhal inflammation; thickening of the wall of esophagus and crop or in the small intestine or ceca (depending on the species); bloody diarrhea	Capillariidae IV.67	

Tabl.101.1: Differential diagnosis of diseases of mouth, pharynx, esophagus and crop.

Differential diagnosis

101. DIGESTIVE SYSTEM

Symptoms & lesions	Species affected	Main clinical signs & lesions	Etiology	Chap.
PROVENTRICULUS	Enlarged	Chickens	Pale birds; stunting; abnormal feathering (helicopter wings); femoral head fractures; immunodepression; orange diarrhea, enlarged proventriculus	Enteritic problems (<i>Reovirus</i>) II.27 II.28
		Chickens (turkeys)	Depression, weight loss, diarrhea, diffuse or nodular lymphomas in visceral organs (liver, spleen, ovary, kidney, proventriculus, heart, bursa) and sometimes in skin (feathers follicles) and skeletal muscles	Marek's disease Acute form (<i>Very virulent Mardivirus</i>) II.33
		Psittacines	Nervous signs and/or gastrointestinal signs; dilatation of the proventriculus; encephalomyelitis; myocarditis; adenitis; chorioretinitis	Proventricular dilation disease (<i>Avian Bornavirus</i>) II.39
	Proventriculitis	Chickens	Depression; stunting; poor feathering; diarrhea; osteoporosis; bone deformation; intestine and ceca are pale distended with mucus, gas and fluid feces	Runting stunting syndrome (<i>Chicken parvovirus</i>) II.28
		Chickens	Inflammation and enlargement of the proventriculus; impaired growth	Transmissible proventriculitis II.39
		All species	Reduced feed intake; digestive lesions mainly in crop (coated with multifocal or confluent mats of white cheesy material)	Candidiasis (<i>Candida albicans</i>) IV.62
		All species	Anemia; erosions; mortality	<i>Tetrameres</i> spp. IV.67
		All species	Catarrhal inflammation; thickening of the wall of esophagus and crop or in the small intestine or ceca (depending on the species); bloody diarrhea	<i>Capillariidae</i> IV.67
		Waterfowl	Esophagus, crop, gizzard; small intestine	<i>Echinura uncinata</i> IV.67
		Partridges, ostrich, cage birds	Proventriculus: edematous and hyperemic with viscous mucus adhered to the mucosa, hemorrhages, rupture (peritonitis)	Mycotic proventriculitis (<i>Macrohabdus ornithogasterae</i>) VI.100
	Ratites	Nematode in the proventriculus and ventriculus	<i>Libyostrongylus douglassi</i> VI.100	
	Hemorrhages	All species	Sudden onset (mortality up to 100%); egg drop; respiratory signs (sinusitis, facial swelling); hemorrhages; cyanosis; diarrhea; encephalitis; pancreatitis	Highly pathogenic avian influenza virus II.18
Chickens, game birds, pigeons, etc		Sudden death with high mortality; hemorrhagic lesions in the intestinal tract; encephalitis	Newcastle disease (<i>Velogenic paramyxovirus</i>) II.19	
Chickens		Acute form: vent pecking; diarrhea; mortality (10-90%); inflammation of bursa swollen early and atrophied later; petechial hemorrhages (muscles, liver); kidney with urate deposits; milder form: immunodepression	Gumboro disease (<i>Avibirnavirus</i>) II.32	
Waterfowl		Bloody greenish diarrhea; high mortality; conjunctivitis; esophagitis; widespread hemorrhages; intestinal annular bands; egg drop (25-40%); smaller spleen	Duck virus enteritis (<i>Anatid herpesvirus 1</i>) VI.89	
GIZZARD	Erosions or ulcers	Chickens	Several black areas in gizzard filled with blood stained fluid	Gizzard erosions (<i>Aviadenovirus</i>) II.24
		All species	Anorexia; fever; depression; cyanosis of the head; anemia; marked enlargement and mottling of the spleen; hepatitis; nephritis; pericarditis	Spirochaetosis (<i>Borrelia anserina</i>) III.61
		Ducks, turkeys, geese, etc.	Acute intoxication: diarrhea; necrotic lesions (oral mucosa, gastrointestinal tract); chronic poisoning: stunting; abnormalities of feathering; egg drop; hepatitis; immunodepression (atrophy of bursa)	Trichothecene poisoning (<i>Fusarium</i> spp.) IV.63
		Geese	Lesions of the gizzard; anemia; rapid weight loss	<i>Amidostomum anseris</i> VI.94
	Nodules	Chickens, turkeys, quails, pheasants	1-3 week-old chicks; encephalomyelitis (ataxia, paralysis, opisthotonos, tremors); mortality from 25 to 50 %; cataract; egg drop (5 to 10%)	Avian encephalomyelitis (<i>Hepatovirus</i>) II.23
		Chickens, turkeys, etc.	Anorexia, prostration; droopy wings; diarrhea; mortality (up to 100%); dyspnea, blindness, arthritis; nodules on heart, gizzard, pancreas, lung	Pullorum disease (<i>S. Gallinarum-pullorum</i>) I.3 III.42
	Hemorrhages	All species	Sudden onset (mortality up to 100%); egg drop; respiratory signs (sinusitis, facial swelling); hemorrhages; cyanosis; diarrhea; encephalitis; pancreatitis	Highly pathogenic avian influenza virus II.18
		Chickens, game birds, pigeons, etc	Sudden death with high mortality; hemorrhagic lesions in the intestinal tract; encephalitis	Newcastle disease (<i>Velogenic paramyxovirus 1</i>) II.19
		Chickens	2-4 week-old chicks; severe anemia; hematocrit <27%; lymphoid depletion (thymus and bursal atrophy, pale bone marrow); hemorrhages; mortality (up to 60%)	Chicken infectious anemia (<i>Gyrovirus</i>) II.30
		Turkeys, chickens, etc.	Sudden deaths; purple color and turgescence of snood and dewlap, yellow-green diarrhea; mortality; septicemia: congestion or hemorrhages (petechiae); catarrhal enteritis; splenomegaly; valvular endocarditis; arthritis	Erysipelas (<i>E. rhusiopathiae</i>) III.55
		All species	Anorexia; fever; depression; cyanosis of the head; anemia; marked enlargement and mottling of the spleen; hepatitis; nephritis; pericarditis	Spirochaetosis (<i>Borrelia anserina</i>) III.61
Waterfowl		Bloody greenish diarrhea; high mortality; conjunctivitis; esophagitis, widespread hemorrhages; intestinal annular bands; egg drop (25-40%); smaller spleen	Duck virus enteritis (<i>Anatid herpesvirus 1</i>) VI.89	
Impaction	All species	Accumulation of hard, fibrous feed, litter or foreign bodies	Gizzard impaction IV.71	

Tabl.101.2: Differential diagnosis of diseases of the proventriculus and gizzard.

Symptoms & lesions	Species affected	Main clinical signs & lesions	Etiology	Chap.	
INTESTINE	Obstruction	All species	Small intestine twisting around the yolk sac; torsion; parasites; <i>etc.</i>	Intussusception & volvulus	I.3
		All species	Cloacitis; egg laying; coughing; vent pecking	Cloacal/intestinal prolapse	I.9
		Chickens, turkeys	Anemia; intermittent diarrhea; weight loss; egg drop; intestinal impaction	<i>Ascaridia spp.</i>	IV.67
	Enteritis	Chickens	Conjunctivitis, tracheitis, pneumonia; nephritis (young birds); salpingitis (abnormalities of egg-shell and egg albumen); egg drop (>50%); false layers; enteritis	Infectious bronchitis (<i>Coronavirus</i>)	II.21
		Chickens	Pale birds; stunting; abnormal feathering ("helicopter wings"); femoral head fractures; immunodepression; orange diarrhea, enlarged proventriculus	Enteritic problems (<i>Reovirus</i>)	II.27 II.28
		Chickens	Depression; stunting; poor feathering; diarrhea, osteoporosis; bone deformation, intestine and ceca are pale distended with mucus, gas and fluid feces	Runting stunting syndrome (<i>Chicken parvovirus</i>)	II.28
		Turkeys	Depression; stunting; poor feathering; diarrhea, osteoporosis; bone deformation, intestine and ceca are pale distended with mucus, gas and fluid feces	Poult enteritis complex (<i>Turkey parvovirus</i>)	II.28
		Turkeys	Diarrhea; litter eating; high morbidity, low mortality; watery and undigested feed material in intestine; ceca with watery, frothy and brownish contents	Turkey torovirus infection (<i>Torovirus</i>)	II.28
		All species	Diarrhea, stunting of growth lead to uneven flocks; higher mortality; ceca thin-walled, dilated and filled with yellowish frothy fluid	Enterovirus-like virus infection (<i>Picornaviridae</i>)	II.28
		Psittacines, turkey, duck, <i>etc.</i>	Anorexia; lethargy; ruffled feathers; coughing; green droppings; loss of weight; egg drop; conjunctivitis; airsacculitis; pericarditis; enteritis; hepatitis; splenitis	Avian chlamydiosis (<i>Chlamydia psittaci</i>)	III.40
		Turkey, chicken, <i>etc.</i>	No clinical signs to severe diarrhea and death; associated with vibronic hepatitis; egg drop (immune-compromised birds); granuloma in bursa	Campylobacteriosis (<i>Campylobacter spp.</i>)	III.53
		Chickens	Mild enteritis (orange mucus); thickened mucosa; petechiae	Coccidiosis (<i>E. maxima</i>)	IV.64
		Turkeys, ducks, <i>etc.</i>	Watery or foamy diarrhea; nervous signs; dehydration; weight loss	Hexamitiasis	IV.67
		All species	Weakness, emaciation, diarrhea, ataxia progressing to death	<i>Toxoplasma spp</i>	IV.67
		All species	Low pathogenicity; weight loss; catarrhal enteritis; egg drop	Cestodes	IV.67
		Muscovy ducks	Respiratory signs; mortality (up to 40%); enteritis; conjunctivitis; lameness; stunting; egg drop; splenomegaly; perihepatitis; pericarditis; airsacculitis	Duck reovirus (<i>Reovirus</i>)	VI.85
		Geese, Muscovy ducks	Mortality (up to 60%); older birds: hepatitis; nephritis; ascites; intestinal edema; lameness, diarrhea; splenomegaly; poor feathering	Derszy's disease (<i>Parvovirus</i>)	VI.87
		Ulcers	Quails, chickens, <i>etc.</i>	Sudden death; depression; emaciation; watery droppings; deep ulcers (intestine, ceca); peritonitis; hemorrhages (liver, spleen); splenomegaly; hepatomegaly	Ulcerative enteritis (<i>Clostridium colinum</i>)
	All species		Septicemia; diarrhea; blindness; lameness; hepatitis; splenitis; pericarditis; arthritis; air sacculitis, typhilitis; omphalitis; peritonitis; oophoritis; meningitis	Paratyphoid salmonella (<i>Salmonella spp.</i>)	III.43
	Necrosis	Turkeys, chickens, <i>etc.</i>	Rare in poultry; diarrhea and dehydration; intestines and ceca pale and distended with fluid	Enteritis (<i>E. coli</i>)	III.45
		All species	Sudden death; depression; ruffled feathers; diarrhea; intestines distended (gas and foul fluid); fibrinonecrotic enteritis; cholangiohepatitis	Necrotic enteritis (<i>Clostridium spp.</i>)	III.51 VI.98
		Chickens	Distal section of digestive tract: fibrinonecrotic mass covering mucosa or caseous cores	Coccidiosis (<i>E. brunetti</i>)	IV.64
	Hemorrhages	All species	Sudden onset (mortality up 100%); egg drop; respiratory signs (sinusitis, facial swelling); hemorrhages; cyanosis; diarrhea; encephalitis; pancreatitis	Highly pathogenic avian influenza virus	II.18
		Chickens, <i>etc.</i>	Sudden death (2-30%); pallor; lethargy; ruffled feathers, anorexia; yellow droppings; hepatitis; hemorrhages; hydropericardium; pancreatitis; anemia	Inclusion body hepatitis (<i>Aviadenovirus</i>)	II.24
		Turkeys, bustards	Sudden death; depression, bloody droppings, decreased feed and water consumption; 10-15% mortality (up to 60%); swollen dark purple small intestine filled with bloody content; enlarged, mottled spleen followed by atrophy; hepatomegaly	Turkey hemorrhagic enteritis (<i>Siadenovirus</i>)	II.25
		Turkeys, chickens, ducks, geese, <i>etc.</i>	Sudden death; septicemia; hemorrhages (heart, gizzard, abdominal fat); oophoritis; dermal necrosis; enlargement and necrosis of liver and spleen; peritonitis; egg drop	Acute fowl cholera (<i>Pasteurella multocida</i>)	III.46 VI.93
		All species	Catarrhal inflammation; thickening of the wall of esophagus and crop or in the small intestine or ceca (depending on the species); bloody diarrhea	<i>Capillaridae</i>	IV.67
		Geese	Mortality (up to 80%); locomotor difficulties; hemorrhagic diarrhea (sometimes); nephritis; ascites; urate deposits in viscera and joints (chronic form)	Hemorrhagic nephritis enteritis (<i>Polyomavirus</i>)	VI.88
		Waterfowl	Bloody greenish diarrhea; high mortality; conjunctivitis; esophagitis, widespread hemorrhages; intestinal annular bands; egg drop (25-40%); smaller spleen	Duck virus enteritis (<i>Anatid herpesvirus 1</i>)	VI.89
	Granulomas	Chickens, turkeys, <i>etc.</i>	Anorexia; prostration; droopy wings; diarrhea; mortality (up to 100%); dyspnea; blindness; arthritis; nodules (heart, gizzard, pancreas, lung, <i>etc.</i>)	Pullorum disease (<i>S. Gallinarum-pullorum</i>)	I.3 III.42
Turkeys, chickens, quails		Multiple granulomas in liver, ceca, duodenum, and mesentery, but not spleen; sporadic to high morbidity, high mortality	Hjarre's disease (<i>Escherichia coli</i>)	III.45	
All species		Chronic disease; progressive emaciation; pallor; diarrhea; lameness; granuloma: lesion triad "liver, spleen, intestine", bone marrow, ovary, teste, heart, skin, lung	Tuberculosis (<i>Mycobacterium avium</i>)	III.54	
Tumors	Turkeys, chickens, ducks, geese	Runting; pallor; abnormal feather development; lameness; atrophy of thymus and bursa; enlarged peripheral nerves (marginal); proventriculitis, enteritis; hepatomegaly, splenomegaly; other tumors (gonads, pancreas, kidneys, heart)	Reticuloendotheliosis (<i>Gammaretrovirus</i>)	II.35	
	Turkeys	8-10 week-old turkeys; mortality (up to 25%); enlarged marble spleen; tumors (liver, thymus, gonad, pancreas, kidney, intestine, lung, heart)	Lymphoproliferative disease (<i>Retrovirus</i>)	II.35	

Tabl.101.3: Differential diagnosis of diseases of the intestines. Watery diarrhea can also be due to excessive water consumption. Petechiae can be seen on intestines in other hemorrhagic syndromes (e.g., Gumboro disease).

Symptoms & lesions	Species affected	Main clinical signs & lesions	Etiology	Chap.	
CECA	Typhlitis	Turkeys	Diarrhea; listlessness; nervousness; dilated ceca with yellowish frothy content and gaseous fluid	Astrovirus infection (Turkey Astrovirus 1 & 2)	II.29 IV.72
		Chickens, turkeys, etc.	Anorexia, prostration; droopy wings; diarrhea; mortality (up to 100%); dyspnea; blindness; arthritis; nodules (heart, gizzard, pancreas, lung, etc.)	Pullorum disease (S. Gallinarum-pullorum)	I.3 III.42
		All species	Septicemia; diarrhea; blindness; lameness; hepatitis; splenitis; pericarditis; arthritis; air sacculitis; typhlitis; omphalitis; peritonitis; oophoritis; meningitis	Paratyphoid salmonella (Salmonella spp.)	III.43
		Turkeys, chickens, etc.	Rare in poultry; diarrhea and dehydration; intestines and ceca pale and distended with fluid	Enteritis (Escherichia coli)	III.45
		Turkeys, chickens, quails	Multiple granulomas in liver, ceca, duodenum, and mesentery, but not spleen; sporadic to high morbidity, high mortality	Hjarre's disease (Escherichia coli)	III.45
		Ducks, chickens, turkeys, pigeons	Duckling sudden death syndrome; septicemia; splenomegaly; hepatomegaly; osteomyelitis; arthritis; vegetative valvular endocarditis	Streptococcus (Streptococcus gallolyticus)	III.56 VI.99
		Chickens, turkeys, ducks, etc.	Chronic diarrhea (brownish-yellow, frothy and/or mucoid droppings); egg drop (eggs of poor quality); stunting; dilated ceca (foamy & watery content)	Avian intestinal spirochetosis (Brachyspira spp.)	III.58
		Ratites	Enterotoxemia, typhlocolitis	Clostridium sordellii	VI.100
	Parasites	Chickens	Typhlitis; bloody cecas; bloody droppings; cheesy cecal cores	Coccidiosis (E. tenella)	IV.64
		Chickens	Typhlitis; caseous plug, white to grey in color in ceca	Coccidiosis (E. adenoides)	IV.64
		Turkeys, chickens, quails, ducks, etc.	Yellow sulfur diarrhea; abnormal gait; typhlitis; hepatic lesions: necrotic foci in cockade with raised edges and a center depression	Histomoniasis (Histomonas meleagridis)	IV.66
		Ducks, turkeys	Typhlitis and catarrhal enteritis	Cochlosoma anatis	IV.67
		Pigeons, turkeys, chickens, etc.	Anorexia; ruffled feathers; «oral canker» (yellow plaques or cheesy masses in buccal cavity, pharynx, esophagus and crop); systematic spread (liver)	Trichomoniasis (Trichomonas gallinae)	IV.67
		All species	Typhlitis; role as vector for Histomonas	Heterakis spp.	IV.67

Tabl.101.4: Differential diagnosis of diseases of the ceca.

Symptoms & lesions	Species affected	Main clinical signs & lesions	Etiology	Chap.	
PANCREAS	Pancreatitis	Chickens (turkeys)	Depression, weight loss, diarrhea, diffuse or nodular lymphomas in visceral organs (liver, spleen, ovary, kidney, proventriculus, heart, bursa) and sometimes in skin (feathers follicles) and skeletal muscles	Marek's disease Acute form (Very virulent Mardivirus)	II.33
		All species	Sudden onset (mortality up to 100%); egg drop; respiratory signs (sinusitis, facial swelling); hemorrhages; cyanosis; diarrhea; encephalitis; pancreatitis	Highly pathogenic avian influenza virus	II.18
		Chickens, etc.	Sudden death (2-30%); pallor; lethargy; ruffled feathers, anorexia; yellow droppings; hepatitis; hemorrhages; hydropericardium; pancreatitis; anemia	Inclusion body hepatitis (Aviadenovirus)	II.24
		Turkeys	High mortality in poults; hepatitis; pancreatitis; egg drop; splenomegaly	Turkey viral hepatitis	II.39
		Guinea fowls	Distended ceca (foamy yellow content); nephritis; necrosis of pancreas	Fulminating disease	VI.95
		Guinea fowls	Nervous symptoms; pancreas enlarged, with nodules and petechiae	Viral pancreatitis	VI.95
	Atrophy	Chickens	Pale birds; stunting; abnormal feathering (helicopter wings); femoral head fractures; immunodepression; orange diarrhea, enlarged proventriculus	Enteritic problems (Reovirus)	II.27 II.28
		All species	Exudative diathesis, encephalomalacia and muscular dystrophy	Se-deficiency diseases	IV.71
	Nodules or tumors	Chickens (turkeys)	Depression, weight loss, diarrhea, diffuse or nodular lymphomas in visceral organs (liver, spleen, ovary, kidney, proventriculus, heart, bursa) and sometimes in the skin (feathers follicles) and skeletal muscles	Marek's disease Acute form (Very virulent Mardivirus)	II.33
		Chickens, turkeys, etc.	Anorexia; prostration; droopy wings; diarrhea; mortality (up to 100%); dyspnea; blindness; arthritis; nodules (heart, gizzard, pancreas, lung, etc.)	Pullorum disease (S. Gallinarum-pullorum)	I.3 III.42

Tabl.101.5: Differential diagnosis of diseases of the pancreas.

Symptoms & lesions	Species affected	Main clinical signs & lesions	Etiology	Chap.		
DIFFUSE OR FOCAL NEOPLASTIC LESIONS	Hepatomegaly ++++	Chickens (turkeys)	Depression, weight loss, diarrhea, diffuse or nodular lymphomas in visceral organs (liver, spleen, ovary, kidney, proventriculus, heart, bursa) and sometimes in the skin (feathers follicles) and skeletal muscles	Marek's disease Acute form (<i>Very virulent Mardivirus</i>)	II.33	
		Chickens	Depression, pallor, nodular or diffuse tumors of liver, spleen, bursa and other organs; skeletal tissues; subclinical infection without neoplastic lesions; egg drop	Lymphoid leukosis (<i>Retrovirus ALV-A</i>)	II.34	
		Chickens	Diffuse myeloid leukosis: pallor; liver and spleen are enlarged and granular appearance of the liver; bursa sometimes tumorous; tumor infiltration of bone marrow; myeloblastic leukemia; other tumors (ovary, kidneys, bursa)	Myeloid leukosis Myeloblastosis (<i>Retrovirus ALV-J</i>)	II.34	
		Chickens	Subcapsular hemorrhages as a result of increased friability of the liver	Hepatic myelocytoma	II.34	
		Chickens	Tumors (skin or visceral organs); blood-filled cystic masses or solid tumors	Hepatic hemangioma	II.34	
		Turkeys	8-10 week-old turkeys; mortality (up to 25%); enlarged marble spleen; tumors (liver, thymus, gonad, pancreas, kidney, intestine, lung, heart)	Lymphoproliferative disease (<i>Retrovirus</i>)	II.35	
		Turkeys, chickens, ducks, geese	Runting; pallor; abnormal feather development; lameness; atrophy of thymus and bursa; enlarged peripheral nerves (marginal); proventriculitis, enteritis; hepatomegaly, splenomegaly; other tumors (gonads, pancreas, kidneys, heart)	Reticuloendotheliosis (<i>Gammaretrovirus</i>)	II.35	
	Focal or multifocal tumors	Chickens (turkeys)	Depression, weight loss, diarrhea, diffuse or nodular lymphomas in visceral organs (liver, spleen, ovary, kidney, proventriculus, heart, bursa) and sometimes in the skin (feathers follicles) and skeletal muscles	Marek's disease Acute form (<i>Very virulent Mardivirus</i>)	II.33	
		Chickens	Depression, pallor, nodular or diffuse tumors of liver, spleen, bursa and other organs; skeletal tissues; subclinical infection without neoplastic lesions; egg drop	Lymphoid leukosis (<i>Retrovirus ALV-A</i>)	II.34	
		Chickens	Tumoral form of myeloid leukosis: diffuse nodular tumors of creamy-white colour; other tumors [ovary, kidneys, thymus, surface of bones (sternum, ribs, skull)]	Myelocytomatosis (<i>Retrovirus ALV-J</i>)	II.34	
		Turkeys, chickens, ducks, geese	Runting; pallor; abnormal feather development; lameness; atrophy of thymus and bursa; enlarged peripheral nerves (marginal); proventriculitis, enteritis; hepatomegaly, splenomegaly; other tumors (gonads, pancreas, kidneys, heart)	Reticuloendotheliosis (<i>Gammaretrovirus</i>)	II.35	
	HEPATITIS WITH HEPATOMEGALY +++	Viral diseases	Chickens, etc.	Sudden death (2-30%); pallor; lethargy; ruffled feathers, anorexia; yellow droppings; hepatitis; hemorrhages; hydropericardium; pancreatitis; anemia	Inclusion body hepatitis (<i>Aviadenovirus</i>)	II.24
			Turkeys, bustards	Sudden death; depression, bloody droppings, decreased feed and water; 10-15% mortality (up to 60%); small intestine swollen, dark purple and filled with bloody content; spleen enlarged and mottled; hepatomegaly	Turkey hemorrhagic enteritis (<i>Siadenovirus</i>)	II.25
			Chickens	Pallor; sudden deaths; egg drop (up to 20%); abnormal eggs; clotted blood in the abdominal cavity and/or on the liver; hepatitis, spleens enlarged and pale	Hepatitis E (<i>Hepevirus</i>)	II.38
Bacterial diseases		Chickens, turkeys, etc.	Arthritis, synovitis; breast blisters; respiratory signs; egg drop (eggshell apex abnormalities); tenosynovitis, salpingitis; airsacculitis	Infectious synovitis (<i>Mycoplasma synoviae</i>)	III.41	
		Turkeys, chickens	Reduction of hatchability (5-20%); airsacculitis; feather abnormalities and leg deformities	Mycoplasmosis (<i>Mycoplasma iowae</i>)	III.41	
		Chickens, turkeys, etc.	Anorexia, prostration; droopy wings; diarrhea; mortality (up to 100%); dyspnea; blindness; arthritis; nodules (heart, gizzard, pancreas, lung, etc.)	Pullorum disease (<i>S. Gallinarum-pullorum</i>)	I.3 III.42	
		Fowls, turkeys	Pale and shrunken combs; egg drop; small nodular regressing ovarian follicles; hepatitis; oophoritis; salpingitis, white foci or nodules on testes	Fowl typhoid (<i>S. Gallinarum-pullorum</i>)	III.42 VI.93	
		All species	Septicemia; diarrhea; blindness; lameness; hepatitis; splenitis; pericarditis; arthritis; air sacculitis, typhilitis; omphalitis; peritonitis; oophoritis; meningitis	Paratyphoid salmonella (<i>Salmonella</i> spp.)	III.43	
		Turkeys, chickens	Anorexia; diarrhea; paralysis; opisthotonos; torticollis; blindness (white corneal opacity); typhlitis (white caseous casts); meningitis; omphalitis; hepatitis	Arizonosis (<i>S. enterica</i> subsp. <i>arizonae</i>)	III.44	
		Turkeys, chickens, etc.	Sudden death in birds in good conditions with full crops containing feed; hepatitis (bile staining and enlarged liver); gallbladder distension;	Acute colisepticemia (<i>Escherichia coli</i>)	III.45 VI.93	
		Turkeys, chickens ducks, geese, etc.	Sudden death; septicemia; hemorrhages (heart, gizzard, abdominal fat); oophoritis; dermal necrosis; enlargement and necrosis of liver and spleen; peritonitis; egg drop	Acute fowl cholera (<i>Pasteurella multocida</i>)	III.46 VI.93	
		All species	Surface of liver has a characteristic acinous appearance or is mottled with multiple small grayish-white or greenish foci; thickened gallbladder	<i>Clostridium perfringens</i> -associated hepatitis	III.51	
		Quails, chickens, etc.	Sudden deaths; depression, emaciation; watery droppings; deep ulcers (intestine, caeca); peritonitis; hemorrhages (liver, spleen); splenomegaly; hepatomegaly	Ulcerative enteritis (<i>Clostridium colinum</i>)	III.51 VI.96	
		Ducks, chickens, turkeys	Duckling sudden death syndrome; septicemia; splenomegaly; hepatomegaly; osteomyelitis; arthritis; vegetative valvular endocarditis	Streptococcus (<i>Streptococcus gallolyticus</i>)	III.56 VI.99	
		Chickens, turkeys, ducks, geese, etc.	Sudden death; pallor; sinusitis; arthritis (amyloid), synovitis, osteomyelitis, dermatitis, omphalitis; septicemia; green liver; pneumonia; endocarditis; bumble foot	Staphylococcosis (<i>Staphylococcus aureus</i>)	III.57	
		All species	Anorexia; fever; depression; cyanosis of the head; anemia; marked enlargement and mottling of the spleen; hepatitis; nephritis; pericarditis	Spirochaetosis (<i>Borrelia anserina</i>)	III.61	

Tabl.102.1: Differential diagnosis of severe hepatomegaly including tumoral diseases.

Differential diagnosis

102. LIVER DISEASES

Symptoms & lesions	Species affected	Main clinical signs & lesions	Etiology	Chap.	
HEPATOMEGALY +	Viral hepatitis	All species	Respiratory signs (sinusitis, tracheitis, bronchitis, pneumonia, airsacculitis); conjunctivitis; enteritis; egg drop; ovarian regression; involution of the oviduct; mortality <5%	Low pathogenic avian influenza virus	II.18
		Chickens, etc.	Sudden death (2-30%); pallor; lethargy; ruffled feathers, anorexia; yellow droppings; hepatitis; hemorrhages; hydropericardium; pancreatitis; anemia	Inclusion body hepatitis (<i>Aviadenovirus</i>)	II.24
		Quails	Severe respiratory signs; conjunctivitis; neurological signs; tracheitis, bronchitis; airsacculitis; pneumonia; hepatitis	Quail bronchitis virus (<i>Aviadenovirus</i>)	II.24 VI.98
		Turkeys, bustard	Sudden death; depression, bloody droppings, decreased feed and water consumption; 10-15% mortality (up to 60%); swollen dark purple small intestine filled with bloody content; enlarged, mottled spleen followed by atrophy; hepatomegaly	Turkey hemorrhagic enteritis (<i>Siadenovirus</i>)	II.25
		Chickens	Pale birds; stunting; abnormal feathering (helicopter wings); femoral head fractures; immunodepression; orange diarrhea, enlarged proventriculus	Enteritic problems (<i>Reovirus</i>)	II.27 II.28
		Turkeys	High mortality in poults; hepatitis; pancreatitis; egg drop; splenomegaly	Turkey viral hepatitis	II.39
		Psittacines	Respiratory signs: laryngitis, tracheitis, bronchopneumonia; conjunctivitis, airsacculitis; esophagitis	Pacheco's disease (<i>Psittacid herpesvirus 1</i>)	II.39
		Psittacines	Sudden death; hepatosplenomegaly; hemorrhages (heart, intestine, liver)	Polyomavirus infections	II.39
		Muscovy ducks	Respiratory signs; mortality (up to 40%); enteritis; conjunctivitis; lameness; stunting; egg drop; splenomegaly; perihepatitis; pericarditis; airsacculitis	Duck reovirus (<i>Reovirus</i>)	VI.85
		Geese, Muscovy ducks	Mortality (up to 60%); older birds: hepatitis; nephritis; ascites; intestinal edema; lameness, diarrhea; splenomegaly; poor feathering	Derszy's disease (<i>Parvovirus</i>)	VI.87
		Ducks, mule ducks	DHV 1: highly fatal (age<4 weeks); opisthotonos; hepatitis; hemorrhages; pancreatitis; DHV 2 & 3: (age: 3-6 weeks): liver hemorrhages; swollen kidneys	Duck viral hepatitis	VI.90
	Ducks	Paralysis; severe egg drop; diarrhea; degenerate and hemorrhagic ovary	Tembusu virus infection	VI.92	
	Bacterial hepatitis	Psittacines, turkeys, ducks, etc.	Anorexia; lethargy; ruffled feathers; coughing; green droppings; loss of weight; egg drop; conjunctivitis; airsacculitis; pericarditis; enteritis; hepatitis; splenitis	Avian chlamydiosis (<i>Chlamydia psittaci</i>)	III.40
		Chickens, pheasants, quails, etc.	Facial swelling; mortality; egg drop (up to 87%); conjunctivitis; tracheitis; pneumonia; airsacculitis; hepatitis; endocarditis; salpingitis; oophoritis; peritonitis; synovitis	Infectious coryza (<i>Av. paragallinarum</i>)	III.47
		All species	Sudden death; depression; ruffled feathers; diarrhea; intestines distended (gas and foul fluid); fibrinonecrotic enteritis; cholangiohepatitis	Necrotic enteritis (<i>Clostridium</i> spp.)	III.51 VI.98
		Chickens, turkeys	Depression; lameness; reddened moist skin; emphysematous or serosanguineous cellulitis; petechial hemorrhages; gas; "bubble tails"; foul odor	Gangrenous dermatitis (<i>Clostridium</i> spp., <i>S. aureus</i>)	III.51 III.57
		All species	Cauliflower-like or focal hepatitis necrosis due to <i>Helicobacter pullorum</i> ; also associated with <i>Campylobacter jejuni</i>	Vibrionic hepatitis	III.53 III.61
		Turkeys, chickens, ducks, pigeons, etc.	Diarrhea; dyspnea; yellow-green droppings; lameness; conjunctivitis; granulomas: liver, spleen, lungs, heart, kidneys, joints; osteomyelitis	Yersiniosis (<i>Y. pseudotuberculosis</i>)	III.59
		Chickens, turkeys, ducks, etc.	Clinical signs may vary greatly and lesions are not specific; yolk sac infections; sudden death; swelling of the head; diarrhea, arthritis; hepatitis, etc.	Pseudomoniasis (<i>Pseudomonas</i> spp.)	III.60
		All species	Septicemia; encephalitis; mortality (up to 40%); myocarditis; focal hepatic necrosis; nephritis; airsacculitis; salpingitis; enteritis; conjunctivitis	Listeriosis (<i>Listeria monocytogenes</i>)	III.61
GRANULOMAS	Bacteria	Waterfowl	Respiratory disease; egg drop; caseous deposits in the uterus, meningitis	<i>Gallibacterium anatis</i>	VI.93
		Chickens, turkeys, etc.	Anorexia, prostration; droopy wings; diarrhea; mortality (up to 100%); dyspnea; blindness; arthritis; nodules (heart, gizzard, pancreas, lung, etc.)	Pullorum disease (<i>S. Gallinarum-pullorum</i>)	I.3 III.42
		Turkeys, chickens, quails	Multiple granulomas in liver, ceca, duodenum, and mesentery, but not spleen; sporadic to high morbidity, high mortality	Hjarre's disease (<i>Escherichia coli</i>)	III.45
		All species	Chronic disease; progressive emaciation; pallor; diarrhea; lameness; granuloma: lesion triad "liver, spleen, intestine", bone marrow, ovary, teste, heart, skin, lung	Tuberculosis (<i>Mycobacterium avium</i>)	III.54
		Turkeys, chickens, ducks, pigeons, etc.	Diarrhea; dyspnea; yellow-green droppings; lameness, conjunctivitis; granulomas: liver, spleen, lungs, heart, kidneys, joints; osteomyelitis	Yersiniosis (<i>Y. pseudotuberculosis</i>)	III.59 VI.93
	Chickens, turkeys, etc.	Endocarditis; hepatic granulomas; arthritis; amyloidosis (liver, joints)	<i>Enterococcus faecalis</i>	III.56	
Parasites	Pigeons, turkeys, chickens, etc.	Anorexia; ruffled feathers; «oral canker» (yellow plaques or cheesy masses in buccal cavity, pharynx, esophagus and crop); systematic spread (liver)	Trichomoniasis (<i>Trichomonas gallinae</i>)	IV.67	

Tabl.102.2: Differential diagnosis of hepatitis and liver granulomas.

Symptoms & lesions	Species affected	Main clinical signs & lesions	Etiology	Chap.	
HEPATOMEGALY ++	Fatty liver	Chickens	Poor growth; scabs around eyes and beak; chondrodystrophy; sudden death; lipid infiltrations of the liver, kidneys and heart	Fatty liver and kidney syndrome in broiler chicks	IV.71
		Layers	Obesity; egg drop; mortality; pallor and sudden death (hemorrhages); large amount of fat in abdominal cavity and liver (yellow, friable and enlarged)	Fatty liver hemorrhagic syndrome	IV.71
		Turkeys	Enlarged liver with pale yellow and dark red areas	Hepatic lipidosis of turkeys	IV.71
PERIHEPATITIS	Viral infections	All species	Respiratory signs (sinusitis, tracheitis, bronchitis, pneumonia, airsacculitis); conjunctivitis; enteritis; egg drop; ovarian regression; involution of the oviduct; mortality <5%	Low pathogenic avian influenza virus	II.18
		Chickens	Pale birds; stunting; abnormal feathering ("helicopter wings"); femoral head fractures; immunodepression; orange diarrhea, enlarged proventriculus	Enteritic problems (<i>Reovirus</i>)	II.27 II.28
		Muscovy ducks	Respiratory signs; mortality (up to 40%); enteritis; conjunctivitis; lameness; stunting; egg drop; splenomegaly; perihepatitis; pericarditis; airsacculitis	Duck reovirus (<i>Reovirus</i>)	VI.85
		Geese, Muscovy ducks	Mortality (up to 60%); older birds: hepatitis; nephritis; ascites; intestinal edema; lameness, diarrhea; splenomegaly; poor feathering	Derszy's disease (<i>Parvovirus</i>)	VI.87
	Bacterial infections	Psittacines, turkeys, ducks, etc.	Anorexia; lethargy; ruffled feathers; coughing; green droppings; loss of weight; egg drop; conjunctivitis; airsacculitis; pericarditis; enteritis; hepatitis; splenitis	Avian chlamydiosis (<i>Chlamydia psittaci</i>)	III.40
		Chickens, turkeys, game birds, etc.	Chronic respiratory disease; prostration; egg drop and poor egg quality; sinusitis; keratoconjunctivitis; airsacculitis; tenosynovitis; salpingitis	Chronic respiratory disease (<i>Mycoplasma gallisepticum</i>)	III.41
		Chickens, turkeys, etc.	Arthritis, synovitis; breast blisters; respiratory signs; egg drop (eggshell apex abnormalities); tenosynovitis; salpingitis; airsacculitis	Infectious synovitis (<i>Mycoplasma synoviae</i>)	III.41
		Chickens, turkeys, etc.	Anorexia, prostration; droopy wings; diarrhea; mortality (up to 100%); dyspnea; blindness; arthritis; nodules (heart, gizzard, pancreas, lung, etc.)	Pullorum disease (<i>S. Gallinarum-pullorum</i>)	I.3 III.42
		Fowls, turkeys	Pale and shrunken combs; egg drop; small nodular regressing ovarian follicles; hepatitis; oophoritis; salpingitis; white foci or nodules on testes	Fowl typhoid (<i>S. Gallinarum-pullorum</i>)	III.42
		All species	Septicemia; diarrhea; blindness; lameness; hepatitis; splenitis; pericarditis; arthritis; air sacculitis, typhilitis; omphalitis; peritonitis; oophoritis; meningitis	Paratyphoid salmonella (<i>Salmonella</i> spp.)	III.43
		Turkeys, chickens, etc.	Pericarditis; myocarditis; tracheitis; pneumonia and pleuropneumonia; airsacculitis; peritonitis; green droppings	Subacute polyserositis (<i>Escherichia coli</i>)	III.45 VI.93
		Turkeys, chickens ducks, geese, etc.	Sudden death; septicemia; hemorrhages (heart, gizzard, abdominal fat); oophoritis; dermal necrosis; enlargement and necrosis of liver and spleen; peritonitis; egg drop	Acute fowl cholera (<i>Pasteurella multocida</i>)	III.46 VI.93
		Chicken, pheasant, quail, etc.	Facial swelling; mortality; egg drop (up to 87%); conjunctivitis; tracheitis; pneumonia; airsacculitis; hepatitis; endocarditis; salpingitis; oophoritis; peritonitis; synovitis	Infectious coryza (<i>Av. paragallinarum</i>)	III.47
		Duck, turkey, chicken, etc.	Respiratory signs; greenish diarrhea; tremors; torticollis; mortality; septicemia; fibrinous perihepatitis, pericarditis; airsacculitis; meningitis; stunting	Duck septicemia (<i>Riemerella anatipestifer</i>)	III.49 VI.93
		Duck, chicken, turkey	Duckling sudden death syndrome; septicemia; splenomegaly; hepatomegaly; osteomyelitis; arthritis; vegetative valvular endocarditis	Streptococcus (<i>Streptococcus gallolyticus</i>)	III.56 VI.99
		Chicken, turkey, duck	Valvular endocarditis (<i>E. faecium</i> , <i>E. hirae</i> , <i>E. durans</i> , <i>S. gallineous</i> , <i>S. pluranimalium</i> , <i>S. zooepidemicus</i>); encephalomalacia (<i>E. hirae</i> , <i>E. durans</i>); cellulitis (<i>S. dysgalactiae</i>); sepsis (<i>E. faecium</i> , <i>S. pluranimalium</i>)	Enterococcus spp. <i>Streptococcus</i> spp.	III.56
		Chicken, turkey, etc.	Endocarditis; hepatic granulomas; arthritis; amyloidosis (liver, joints)	Enterococcus faecalis	III.56
		Chicken, turkey, duck, etc.	Clinical signs may vary greatly and lesions are not specific; yolk sac infections; sudden death; swelling of the head; diarrhea, arthritis; hepatitis, etc.	Pseudomoniasis (<i>Pseudomonas</i> spp.)	III.60

Tabl.102.3: Differential diagnosis of non infectious hepatomegaly and perihepatitis.

Symptoms & lesions	Species affected	Main clinical signs & lesions	Etiology	Chap.		
LIVER NECROSIS	Intoxications	Ducks, turkeys, geese, guinea fowls, etc.	Acute toxicity: diarrhea; ataxia; convulsions; liver enlarged with small necrotic and hemorrhagic foci; enlarged spleen, pancreas and kidney; atrophy of bursa; chronic intoxication: stunting; egg drop, decreased hatchability	Aflatoxicosis (<i>Aspergillus</i> spp.)	IV.63	
		Ducks, turkeys, goose, etc.	Acute intoxication: tremors; mortality (up to 50%); nephrosis; liver (pale); egg drop; chronic intoxication: stunting; renal failure (urate deposits)	Ochratoxicosis (<i>Aspergillus, Penicillium</i>)	IV.63	
		Ducks, turkeys, goose, guinea fowls, etc.	Acute intoxication: diarrhea; necrotic lesions (oral mucosa, gastrointestinal tract); chronic poisoning: stunting; abnormalities of feathering; egg drop; hepatitis; immunodepression (atrophy of bursa)	Trichothecene poisoning (<i>Fusarium</i> spp.)	IV.63	
		All species	Increased mortality (spiking mortality); hepatic necrosis	Fumonisin poisoning (<i>Fusarium</i> spp.)	IV.63 IV.73	
		All species	Asphyxia, cyanosis of featherless skin, pulmonary oedema and subcapsular hemorrhages in the liver	Acute propane butane intoxication	V.79	
	Parasites	All species	Dyspnea; mortality; nodules (trachea, bronchi, lungs, air sacs); diarrhea; stunting; systemic infection with other localizations: brain, eyes, skin; kidneys, etc.	Brooder pneumonia (<i>Aspergillus fumigatus</i>)	IV.62	
		Turkeys, chickens, quails, ducks, etc.	Yellow sulfur diarrhea; abnormal gait; typhlitis; hepatic lesions: necrotic foci in cockade with raised edges and a center depression	Histomoniasis (<i>Histomonas meleagridis</i>)	IV.66	
		Pigeons, turkeys, chickens, etc.	Anorexia; ruffled feathers; «oral canker» (yellow plaques or cheesy masses in buccal cavity, pharynx, esophagus and crop); systematic spread (liver)	Trichomoniasis (<i>Trichomonas gallinae</i>)	IV.67	
		Turkeys, wild birds	Anemia; lameness; mortality; liver and spleen enlarged and dark	<i>Haemoproteus</i> spp.	IV.67	
		All species	Presence of numerous cysts visible in skeletal and cardiac muscles; other locations: esophagus, brain, lung, liver	Sarcocystosis (<i>Sarcocystis</i> spp.)	IV.67	
	HEMORRHAGES	Hemorrhages & hepatitis	Chickens	Pallor; sudden death; egg drop (up to 20%); abnormal eggs; clotted blood in the abdominal cavity and/or on the liver; hepatitis, spleen enlarged and pale	Hepatitis E (<i>Hepevirus</i>)	II.38
			Ducks, mule ducks	DHV 1: highly fatal (age<4 weeks); opisthotonos; hepatitis; hemorrhages; pancreatitis; DHV 2 & 3: (age: 3-6 weeks): liver hemorrhages; swollen kidneys	Duck viral hepatitis	VI.90
		Other hemorrhages	Chickens	Poor growth; scabs around eyes and beak; chondrodystrophy; sudden death; lipid infiltrations of the liver, kidneys and heart	Fatty liver and kidney syndrome in broiler chicks	IV.71
			Layers	Obesity; egg drop; mortality; pallor and sudden death (hemorrhages); large amount of fat in abdominal cavity and liver (yellow, friable and enlarged)	Fatty liver hemorrhagic syndrome	IV.71
Turkeys			Enlarged liver with pale yellow and dark red areas	Hepatic lipidosis of turkeys	IV.71	
All species			Watery diarrhea; weakness; cerebellar edema; hepatotoxicity; feather loss	Excess organic selenium	IV.71	
Chickens			Decubitus; ataxia; orange mucoid diarrhea; hemorrhage and necrosis of the liver; mild enteritis; atrophy of bursa	Hypoglycemia-spiking mortality syndrome	IV.73	
All species			Anticoagulant effect of vitamin K antagonist causes hemorrhages	Rodenticide poisoning	V.79	
All species			Asphyxia, cyanosis of featherless skin, pulmonary edema and subcapsular hemorrhages in the liver	Acute propane butane intoxication	V.79	
Waterfowl			Bloody greenish diarrhea; high mortality; conjunctivitis; esophagitis; widespread hemorrhages; intestinal annular bands; egg drop (25-40%); smaller spleen	Duck virus enteritis (<i>Anatid herpesvirus 1</i>)	VI.89	
All species	Traumatic hemorrhage	Traumatic injection				
OTHER	Hepatic lesions	Broilers	Pallor; sudden death; cyanosis; marked hypertrophy and dilation of the right ventricle; hydropericardium; congested or mottled liver; congested lungs	Pulmonary hypertension or ascites syndrome	IV.70	
		Chickens	Most birds (1 to 8 weeks of age) found dead on their back (flip-over); full digestive tract; liver enlarged, pale and friable; empty gallbladder	Sudden death syndrome in broiler chickens	IV.70	
		All species	Urate precipitation: kidneys, heart, liver, mesenteries, air sacs, peritoneum, muscles, synovial sheaths, spleen	Visceral urate deposition (visceral gout)	IV.71	

Tabl.102.4: Differential diagnosis of other diseases of the liver (hepatitis, hemorrhages, intoxications, parasites, etc.).

Symptoms & lesions	Species affected	Main clinical signs & lesions	Etiology	Chap.	
NOSTRILS & SINUSES	Nasal discharge	All species	Respiratory signs (sinusitis, tracheitis, bronchitis, pneumonia, airsacculitis); conjunctivitis; enteritis; egg drop; ovarian regression; involution of the oviduct; mortality <5%	Low pathogenic avian influenza virus	II.18
		Chickens, game birds, pigeons, etc	Respiratory signs; loss of weight gain; egg drop; airsacculitis (co-infection)	Newcastle disease (<i>Lentogenic paramyxovirus 1</i>)	II.19
		Chickens	Conjunctivitis, tracheitis, pneumonia; nephritis (young birds); salpingitis (abnormalities of egg-shell and egg albumen); egg drop (>50%); false layers; enteritis	Infectious bronchitis (<i>Coronavirus</i>)	II.21
		All species	Cutaneous form: nodular proliferative skin lesions progressing to thick scabs; diphtheritic form: upper digestive and respiratory tract lesions	Fowlpox (<i>Avipoxvirus</i>)	II.31
		Psittacines	Respiratory signs: laryngitis, tracheitis, bronchopneumonia; conjunctivitis, airsacculitis; esophagitis	Pacheco's disease (<i>Psittacid herpesvirus 1</i>)	II.39
		Psittacines, turkeys, ducks, etc.	Anorexia; lethargy; ruffled feathers; coughing; green droppings; loss of weight; egg drop; conjunctivitis; airsacculitis; pericarditis; enteritis; hepatitis; splenitis	Avian chlamydiosis (<i>Chlamydia psittaci</i>)	III.40
		Turkeys (Chickens)	High morbidity, low mortality (poults); foamy conjunctivitis; sinusitis; dyspnea; submandibular edema; stunting; tracheitis (distortion of tracheal rings)	Bordetellosis (<i>Bordetella avium</i>)	III.50
		Pigeons, turkeys, chickens, etc.	Anorexia; ruffled feathers; «oral canker» (yellow plaques or cheesy masses in buccal cavity, pharynx, esophagus and crop); systematic spread (liver)	Trichomoniasis (<i>Trichomonas gallinae</i>)	IV.67
		All species	Sinusitis; conjunctivitis; blepharitis	Excess ammonia	IV.74
		Pigeons	Conjunctivitis; nasopharyngitis; acute or chronic; wet coryza or dry coryza; necrotic foci in upper respiratory tract and liver	Herpesvirus infection (<i>Columbid herpesvirus 1</i>)	VI.99
	All species	Live vaccine; discrete nasal discharge and/or conjunctivitis	Vaccine reaction	V.82	
	Cough, nasal discharge & sneezing	Quails	Severe respiratory signs; conjunctivitis; neurological signs; tracheitis, bronchitis; airsacculitis; pneumonia; hepatitis	Quail bronchitis virus (<i>Aviadenovirus</i>)	II.24 VI.98
		Turkeys, chickens	Facial edema; egg drop and reduced hatchability; edema and consolidation of lungs, pleuritis; airsacculitis; peritonitis, pericarditis, enteritis, arthritis, meningitis	<i>Ornithobacterium rhinotracheale</i>	III.48
		Ducks, turkeys, chickens, etc.	Respiratory signs; greenish diarrhea; tremors; torticollis; mortality; septicemia; fibrinous perihepatitis, pericarditis; airsacculitis; meningitis; stunting	Duck septicemia (<i>Riemerella anatipestifer</i>)	III.49 VI.93
		Chickens, turkeys, quails, etc.	Respiratory form: sinusitis, bronchopneumonia, airsacculitis; gastrointestinal form: diarrhea, stunting; renal form: kidneys enlarged and pale, urate deposits	Cryptosporidiosis (<i>Cryptosporidium</i> spp.)	IV.65
	Nasal discharge & swollen sinuses	All species	Sudden onset (mortality up to 100%); egg drop; respiratory signs (sinusitis, facial swelling); hemorrhages; cyanosis; diarrhea; encephalitis; pancreatitis	Highly pathogenic avian influenza virus	II.18
		Chickens, game birds, pigeons, etc	Severe respiratory disease (facial edema); nervous signs (torticollis, paralysis); mortality (up to 50%); egg drop	Newcastle disease (<i>Mesogenic paramyxovirus 1</i>)	II.19
		Turkeys, chickens, etc.	Swollen head syndrome; tracheitis; egg drop up to 70%; poor shell quality	Avian Metapneumovirus	II.20
		Chickens, turkeys, game birds, etc.	Chronic respiratory disease; prostration; egg drop and poor egg quality; sinusitis; keratoconjunctivitis; airsacculitis; tenosynovitis, salpingitis	Chronic respiratory disease (<i>Mycoplasma gallisepticum</i>)	III.41
		Chickens, turkeys, etc.	Arthritis, synovitis; breast blisters; respiratory signs; egg drop (eggshell apex abnormalities); tenosynovitis, salpingitis; airsacculitis	Infectious synovitis (<i>Mycoplasma synoviae</i>)	III.41
Turkeys, chickens, ducks, geese, etc.		Sudden death; septicemia; hemorrhages (heart, gizzard, abdominal fat); oophoritis; dermal necrosis; enlargement and necrosis of liver and spleen; peritonitis; egg drop	Acute fowl cholera (<i>Pasteurella multocida</i>)	III.46 VI.93	
Chickens, pheasants, quails, etc.		Facial swelling; mortality; egg drop (up to 87%); conjunctivitis; tracheitis; pneumonia; airsacculitis; hepatitis; endocarditis; salpingitis; oophoritis; peritonitis; synovitis	Infectious coryza (<i>Avibacterium paragallinarum</i>)	III.47	
Turkeys, chickens, ducks, pigeons, etc.		Diarrhea; dyspnea; yellow-green droppings; lameness; conjunctivitis; granulomas: liver, spleen, lungs, heart, kidneys, joints; osteomyelitis	Yersiniosis (<i>Y. pseudotuberculosis</i>)	III.59	
Chickens, turkeys, ducks, etc.		Clinical signs may vary greatly and lesions are not specific; yolk sac infections; sudden death; swelling of the head; diarrhea, arthritis; hepatitis, etc.	Pseudomoniasis (<i>Pseudomonas</i> spp.)	III.60	

Tabl.103.1: Differential diagnosis of diseases affecting nostrils and sinuses.

Differential diagnosis

103. RESPIRATORY DISEASES

Symptoms & lesions	Species affected	Main clinical signs & lesions	Etiology	Chap.		
PHARYNX, LARYNX, TRACHEA & BRONCHI	Diphtheritic membranes	All species	Cutaneous form: nodular proliferative skin lesions progressing to thick scabs; diphtheritic form: upper digestive and respiratory tract lesions	Fowlpox (<i>Avipoxvirus</i>)	II.31	
		All species	Hyperkeratosis (cornea, mouth, esophagus); nutritional nephropathy; ruffled feathers, corneal hyperkeratosis; nerve lesion; egg drop	Vitamin A deficiency	IV.71	
	Serous or hemorrhagic exudate	All species	Sudden onset (mortality up to 100%); egg drop; respiratory signs (sinusitis, facial swelling); hemorrhages; cyanosis; diarrhea; encephalitis; pancreatitis	Highly pathogenic avian influenza virus	II.18	
		All species	Respiratory signs (sinusitis, tracheitis, bronchitis, pneumonia, airsacculitis); conjunctivitis; enteritis; egg drop; ovarian regression; involution of the oviduct; mortality <5%	Low pathogenic avian influenza virus	II.18	
		Chickens, game birds, pigeons, etc	Sudden death with high mortality; hemorrhagic lesions in the intestinal tract; encephalitis	Newcastle disease (<i>Velogenic paramyxovirus 1</i>)	II.19	
		Chickens, game birds, pigeons, etc	Severe respiratory disease (facial edema); nervous signs (torticollis, paralysis); mortality (up to 50%); egg drop	Newcastle disease (<i>Mesogenic paramyxovirus 1</i>)	II.19	
		Chickens	Conjunctivitis, tracheitis, pneumonia; nephritis (young birds); salpingitis (abnormalities of egg-shell and egg albumen); egg drop (>50%); false layers; enteritis	Infectious bronchitis (<i>Coronavirus</i>)	II.21	
		Quails	Severe respiratory signs; conjunctivitis, neurological signs; tracheitis, bronchitis; airsacculitis; pneumonia; hepatitis	Quail bronchitis virus (<i>Aviadenovirus</i>)	II.24 VI.98	
		Psittacines, turkeys, ducks, etc.	Anorexia; lethargy; ruffled feathers; coughing; green droppings; loss of weight; egg drop; conjunctivitis; airsacculitis; pericarditis; enteritis; hepatitis; splenitis	Avian chlamydiosis (<i>Chlamydia psittaci</i>)	III.40	
		Chickens, turkeys, game birds, etc.	Chronic respiratory disease; prostration; egg drop and poor egg quality; sinusitis; keratoconjunctivitis; airsacculitis; tenosynovitis, salpingitis	Chronic respiratory disease (<i>Mycoplasma gallisepticum</i>)	III.41	
		Turkeys (Chickens)	High morbidity, low mortality (poult); foamy conjunctivitis; sinusitis; dyspnea; submandibular edema; stunting; tracheitis (distortion of tracheal rings)	Bordetellosis (<i>Bordetella avium</i>)	III.50	
		All species	Sinusitis; conjunctivitis	Excess ammonia	IV.74	
		All species	Live vaccine; discrete nasal discharge and/or conjunctivitis	Vaccine reaction	V.82	
		Waterfowl	Bloody greenish diarrhea; high mortality; conjunctivitis; esophagitis, widespread hemorrhages; intestinal annular bands; egg drop (25-40%); smaller spleen	Duck virus enteritis (<i>Anatid herpesvirus 1</i>)	VI.89	
		Caseous to hemorrhagic masses	Chickens, pheasants, peafowls	Severe respiratory distress; sudden death; hemorrhage and/or caseous material in the trachea; mortality (1% to 50%)	Acute laryngotracheitis (<i>Iltovirus</i>)	II.22
			Chickens, pheasants, peafowls	Mild tracheitis with unthriftiness, egg drop (5-15 %) without change in eggshell quality; conjunctivitis; sinusitis	Mild form of laryngotracheitis (<i>Iltovirus</i>)	II.22
			Quails	Severe respiratory signs; conjunctivitis, neurological signs; tracheitis, bronchitis; airsacculitis; pneumonia; hepatitis	Quail bronchitis virus (<i>Aviadenovirus</i>)	II.24 VI.98
	Turkeys, chickens, etc.		Pericarditis; myocarditis; tracheitis; pneumonia and pleuropneumonia; airsacculitis; peritonitis; green droppings	Subacute polyserositis (<i>Escherichia coli</i>)	III.45 VI.93	
	All species		Dyspnea; mortality; nodules (trachea, bronchi, lungs, air sacs); diarrhea; stunting; systemic infection with other localizations: brain, eye, skin; kidneys, etc.	Brooder pneumonia (<i>Aspergillus fumigatus</i>)	IV.62	
	Muscovy ducks		Ducklings (< 5 weeks); lameness; bad feathering; diarrhea; hydropericarditis	Muscovy duck parvovirus	VI.86	
	Pigeons		Conjunctivitis; nasopharyngitis; acute or chronic; wet coryza or dry coryza; necrotic foci in upper respiratory tract and liver	Herpesvirus infection (<i>Columbid herpesvirus 1</i>)	VI.99	
	Parasites		Chickens, turkeys, quails, etc.	Respiratory form: sinusitis, bronchopneumonia, airsacculitis; gastrointestinal form: diarrhea, stunting; renal form: kidneys enlarged and pale, urate deposits	Cryptosporidiosis (<i>Cryptosporidium</i> spp.)	IV.65
		Pigeons, turkeys, chickens, etc.	Anorexia; ruffled feathers; «oral canker» (yellow plaques or cheesy masses in buccal cavity, pharynx, esophagus and crop); systematic spread (liver)	Trichomoniasis (<i>Trichomonas gallinae</i>)	IV.67	
		Gallinaceous birds	Dyspnea; hemorrhagic tracheitis with excessive production of mucus	<i>Syngamus trachea</i>	IV.67	

Tabl.103.2: Differential diagnosis of diseases of the pharynx, larynx, trachea and/or bronchi.

Symptoms & lesions	Species affected	Main clinical signs & lesions	Etiology	Chap.	
LUNG	Hemorrhages	All species	Hyperacute evolution or sudden death; suffocation	Heatstroke	I.7
		All species	Sudden onset (mortality up to 100%); egg drop; respiratory signs (sinusitis, facial swelling); hemorrhages; cyanosis; diarrhea; encephalitis; pancreatitis	Highly pathogenic avian influenza virus	II.18
		Chickens, game birds, pigeons, etc.	Severe respiratory disease (facial edema); nervous signs (torticollis, paralysis); mortality (up to 50%); egg drop	Newcastle disease (<i>Mesogenic paramyxovirus 1</i>)	II.19
		Chickens	Conjunctivitis, tracheitis, pneumonia; nephritis (young birds); salpingitis (abnormalities of egg-shell and egg albumen); egg drop (>50%); false layers; enteritis	Infectious bronchitis (<i>Coronavirus</i>)	II.21
		Quails	Severe respiratory signs; conjunctivitis, neurological signs; tracheitis, bronchitis; airsacculitis; pneumonia; hepatitis	Quail bronchitis virus (<i>Aviadenovirus</i>)	II.24 VI.98
		Psittacines, turkeys, ducks, etc.	Anorexia; lethargy; ruffled feathers; coughing; green droppings; loss of weight; egg drop; conjunctivitis; airsacculitis; pericarditis; enteritis; hepatitis; splenitis	Avian chlamydiosis (<i>Chlamydia psittaci</i>)	III.40
		Turkeys (Chickens)	High morbidity, low mortality (poults); foamy conjunctivitis; sinusitis; dyspnea; submandibular edema; stunting; tracheitis (distortion of tracheal rings)	Bordetellosis (<i>Bordetella avium</i>)	III.50
		Waterfowl	Bloody greenish diarrhea; high mortality; conjunctivitis; esophagitis, widespread hemorrhages; intestinal annular bands; egg drop (25-40%); smaller spleen	Duck virus enteritis (<i>Anatid herpesvirus 1</i>)	VI.89
	Caseous nodules	Chickens, turkeys, etc.	Anorexia, prostration; droopy wings; diarrhea; mortality (up to 100%); dyspnea; blindness; arthritis; nodules (heart, gizzard, pancreas, lung, etc.)	Pullorum disease (<i>S. Gallinarum-pullorum</i>)	I.3 III.42
		All species	Chronic disease; progressive emaciation; pallor; diarrhea; lameness; granuloma: lesion triad "liver, spleen, intestine", bone marrow, ovary, teste, heart, skin, lung	Tuberculosis (<i>Mycobacterium avium</i>)	III.54
		Chickens, turkeys, ducks, geese, etc.	Sudden death; palor; sinusitis; arthritis (amyloid), synovitis, osteomyelitis, dermatitis, omphalitis; septicemia; green liver; pneumonia; endocarditis; bumble foot	Staphylococcosis (<i>Staphylococcus aureus</i>)	III.57
		All species	Dyspnea; mortality; nodules (trachea, bronchi, lungs, air sacs); diarrhea; stunting; systemic infection with other localizations: brain, eye, skin, kidneys, etc.	Brooder pneumonia (<i>Aspergillus fumigatus</i>)	IV.62 VI.100
		Chickens, turkeys, etc.	Nervous and pulmonary lesions similar to aspergillosis (but more malacia)	<i>Ochroconis gallopava</i>	IV.62
	Pneumonia and/or pleuropneumonia	Psittacines	Respiratory signs: laryngitis, tracheitis, bronchopneumonia; conjunctivitis, airsacculitis; esophagitis	Pacheco's disease (<i>Psittacid herpesvirus 1</i>)	II.39
		Chickens, turkeys, game birds, etc.	Chronic respiratory disease; prostration; egg drop and poor egg quality; sinusitis; keratoconjunctivitis; airsacculitis; tenosynovitis; salpingitis	Chronic respiratory disease (<i>Mycoplasma gallisepticum</i>)	III.41
		All species	Septicemia; diarrhea; blindness; lameness; hepatitis; splenitis; pericarditis; arthritis; air sacculitis, typhilitis; omphalitis; peritonitis; oophoritis; meningitis	Paratyphoid salmonella (<i>Salmonella</i> spp.)	III.43
		Turkeys, chickens, etc.	Pericarditis; myocarditis; tracheitis; pneumonia and pleuropneumonia; airsacculitis; peritonitis; green droppings	Subacute polyserositis (<i>Escherichia coli</i>)	III.45 VI.93
		Chickens, turkeys, etc.	Localized abscesses: joints, head, oviduct, respiratory tract (pneumonia, airsacculitis), middle ear and meninges (torticollis); fibrinonecrotic dermatitis	Chronic fowl cholera (<i>Pasteurella multocida</i>)	III.46
		Chickens, pheasants, quails, etc.	Facial swelling; mortality; egg drop (up to 87%); conjunctivitis; tracheitis; pneumonia; airsacculitis; hepatitis; endocarditis; salpingitis; oophoritis; peritonitis; synovitis	Infectious coryza (<i>Av. paragallinarum</i>)	III.47
		Turkeys, chickens	Facial swelling; mortality; egg drop (up to 87%); conjunctivitis; tracheitis; pneumonia; airsacculitis; hepatitis; endocarditis; salpingitis; oophoritis; peritonitis; synovitis	<i>Ornithobacterium rhinotracheale</i>	III.48
		Ducks, turkeys, chickens, etc.	Respiratory signs; greenish diarrhea; tremors; torticollis; mortality; septicemia; fibrinous perihepatitis, pericarditis; airsacculitis; meningitis; stunting	Duck septicemia (<i>Riemerella anatipestifer</i>)	III.49 VI.93
		Chickens, turkeys, ducks, etc.	Clinical signs may vary greatly and lesions are not specific; yolk sac infections; sudden death; swelling of the head; diarrhea, arthritis; hepatitis, etc.	Pseudomoniasis (<i>Pseudomonas</i> spp.)	III.60
		Chickens, turkey, quails, etc.	Respiratory form: sinusitis, bronchopneumonia, airsacculitis; gastrointestinal form: diarrhea, stunting; renal form: kidneys enlarged and pale, urate deposits	Cryptosporidiosis (<i>Cryptosporidium</i> spp.)	IV.65
		Tumors	Chickens (turkeys)	Depression, weight loss, diarrhea, diffuse or nodular lymphomas in visceral organs (liver, spleen, ovary, kidney, proventriculus, heart, bursa) and sometimes in the skin (feathers follicles) and skeletal muscles	Marek's disease Acute form (<i>Very virulent Mardivirus</i>)
	Chickens		Depression, pallor, nodular or diffuse tumors of liver, spleen, bursa and other organs; skeletal tissues; subclinical infection without neoplastic lesions: egg drop	Lymphoid leukosis (<i>Retrovirus ALV-A</i>)	II.34
	Turkeys, chickens, ducks, geese		Runting; pallor; abnormal feather development; lameness; atrophy of thymus and bursa; enlarged peripheral nerves (marginal); proventriculitis, enteritis; hepatomegaly, splenomegaly; other tumors (gonads, pancreas, kidneys, heart)	Reticuloendotheliosis (<i>Gammaretrovirus</i>)	II.35
	Turkeys		8-10 week-old turkeys; mortality (up to 25%); enlarged marble spleen; tumors (liver, thymus, gonad, pancreas, kidney, intestine, lung, heart)	Lymphoproliferative disease (<i>Retrovirus</i>)	II.35

Tabl.103.3: Differential diagnosis of lung diseases. Other hemorrhagic lesions may be observed with septicemias (see Chap.VII.105). Urate deposits can also be seen on the lungs (see Chap.IV.71).

Symptoms & lesions	Species affected	Main clinical signs & lesions	Etiology	Chap.	
AIR SACS	Airsacculitis	Chickens, game birds, pigeons, etc	Respiratory signs; loss of weight gain; egg drop; airsacculitis (co-infection)	Newcastle disease (<i>Lentogenic paramyxovirus 1</i>)	II.19
		Psittacines, turkeys, ducks, etc.	Anorexia; lethargy; ruffled feathers; coughing; green droppings; loss of weight; egg drop; conjunctivitis; airsacculitis; pericarditis; enteritis; hepatitis; splenitis	Avian chlamydiosis (<i>Chlamydia psittaci</i>)	III.40
		Chickens, turkeys, game birds, etc.	Chronic respiratory disease; prostration; egg drop and poor egg quality; sinusitis; keratoconjunctivitis; airsacculitis; tenosynovitis, salpingitis	Chronic respiratory disease (<i>Mycoplasma gallisepticum</i>)	III.41
		Chickens, turkeys, etc.	Arthritis, synovitis; breast blisters; respiratory signs; egg drop (eggshell apex abnormalities); tenosynovitis; salpingitis; airsacculitis	Infectious synovitis (<i>Mycoplasma synoviae</i>)	III.41
		Turkeys	Reduced egg hatchability; sinusitis; airsacculitis; poor growth; helicopter feathering; skeletal abnormalities (osteomyelitis, osteodystrophy)	Mycoplasmosis (<i>Mycoplasma meleagridis</i>)	III.41
		Turkeys, chickens	Reduction of hatchability (5-20%); airsacculitis; feather abnormalities and leg deformities	Mycoplasmosis (<i>Mycoplasma iowae</i>)	III.41
		All species	Septicemia; diarrhea; blindness; lameness; hepatitis; splenitis; pericarditis; arthritis; air sacculitis; typhilitis; omphalitis; peritonitis; oophoritis; meningitis	Paratyphoid salmonella (<i>Salmonella spp.</i>)	III.43
		Turkeys, chickens, etc.	Pericarditis; myocarditis; tracheitis; pneumonia and pleuropneumonia; airsacculitis; peritonitis; green droppings	Subacute polyserositis (<i>Escherichia coli</i>)	III.45 VI.93
		Chickens, turkeys, etc.	Localized abscesses: joints, head, oviduct, respiratory tract (pneumonia, airsacculitis), middle ear and meninges (torticollis); fibrinonecrotic dermatitis	Chronic fowl cholera (<i>Pasteurella multocida</i>)	III.46
		Chickens, pheasants, quails, etc.	Facial swelling; mortality; egg drop (up to 87%); conjunctivitis; tracheitis; pneumonia; airsacculitis; hepatitis; endocarditis; salpingitis; oophoritis; peritonitis; synovitis	Infectious coryza (<i>Av. paragallinarum</i>)	III.47
		Turkeys, chickens	Facial edema; egg drop and reduced hatchability; edema and consolidation of lungs, pleuritis; airsacculitis; peritonitis, pericarditis, enteritis, arthritis, meningitis	<i>Ornithobacterium rhinotracheale</i>	III.48
		Ducks, turkeys, chickens, etc.	Respiratory signs; greenish diarrhea; tremors; torticollis; mortality; septicemia; fibrinous perihepatitis; pericarditis; airsacculitis; meningitis; stunting	Duck septicemia (<i>Riemerella anatipestifer</i>)	III.49 VI.93
		Chickens, turkeys, etc.	Endocarditis; hepatic granulomas; arthritis; amyloidosis (liver, joints)	<i>Enterococcus faecalis</i>	III.56
		Chickens, turkeys, ducks, etc.	Clinical signs may vary greatly and lesions are not specific; yolk sac infections; sudden death; swelling of the head; diarrhea, arthritis; hepatitis, etc.	Pseudomoniasis (<i>Pseudomonas spp.</i>)	III.60
		All species	Dead-in-shell embryos; weak chicks or poults; septicemia; hepatitis; arthritis	<i>Acinetobacter spp.</i>	III.61
		All species	Dead-in-shell embryos; weak chicks; arthritis; cellulitis; diarrhea; septicemia	<i>Aeromonas spp.</i>	III.61
		All species	Yolk sac infection; septicemia, salpingitis, oophoritis, cellulitis; respiratory disease	<i>Proteus spp.</i>	III.61
		All species	Dyspnea; mortality; nodules (trachea, bronchi, lungs, air sacs); diarrhea; stunting; systemic infection with other localizations: brain, eye, skin, kidneys, etc.	Brooder pneumonia (<i>Aspergillus fumigatus</i>)	IV.62 VI.100
		Ducks, turkeys, geese, etc.	Acute intoxication: tremors; mortality (up to 50%); nephrosis; liver (pale); egg drop; chronic intoxication: stunting; renal failure (urate deposits)	Ochratoxicosis (<i>Aspergillus, Penicillium</i>)	IV.63
		Chickens, turkeys, quails, etc.	Respiratory form: sinusitis, bronchopneumonia, airsacculitis; gastrointestinal form: diarrhea, stunting; renal form: kidneys enlarged and pale, urate deposits	Cryptosporidiosis (<i>Cryptosporidium spp.</i>)	IV.65
All species	Aisacculitis; dyspnea	Excessive amount of dust	IV.74		
Muscovy ducks	Respiratory signs; mortality (up to 40%); enteritis; conjunctivitis; lameness; stunting; egg drop; splenomegaly; perihepatitis; pericarditis; airsacculitis	Duck reovirus (<i>Reovirus</i>)	VI.85		
Geese, Muscovy ducks	Mortality (up to 60%); older birds: hepatitis; nephritis; ascites; intestinal edema; lameness, diarrhea; splenomegaly; poor feathering	Derszy's disease (<i>Parvovirus</i>)	VI.87		

Tabl.103.4: Differential diagnosis of airsacculitis.

Symptoms & lesions	Species affected	Main clinical signs & lesions	Etiology	Chap.	
INFECTIOUS CARDIAC DISEASES	Myocarditis	All species	Highly pathogenic avian influenza virus	II.18	
		Chickens, game birds, pigeons, etc	Newcastle disease (<i>Velogenic paramyxovirus 1</i>)	II.19	
		Turkeys, chickens psittacines	Other paramyxovirus (serotypes 2, 3, 6 & 7)	II.19 II.39	
		Chickens, turkeys, quails, pheasants	Avian encephalomyelitis (<i>Hepatovirus</i>)	II.23	
		Geese, ducks and other species	West Nile virus (<i>Flavivirus</i>)	II.37	
		Pheasants, etc.	Eastern equine encephalitis	II.37	
		Turkeys, pheasants, partridges	Western equine encephalitis (<i>Alphavirus</i>)	II.37	
		Turkeys	Turkey meningoencephalitis	II.37	
		Partridges, turkeys	Highlands J virus	II.37	
		Ostriches	Turlock-like bunyavirus	II.37	
		Turkeys	Reovirus infection of turkey	II.39	
		Psittacines	Proventricular dilation disease (<i>Avian Bornavirus</i>)	II.39	
		Turkeys	Myocarditis, pericarditis	Myocarditis (<i>Reovirus</i>)	II.39
		Psittacines, turkeys, ducks, etc.	Avian chlamydiosis (<i>Chlamydia psittaci</i>)	III.40	
		Turkeys, chickens, etc.	Subacute polyserositis (<i>Escherichia coli</i>)	III.45 VI.93	
		Turkeys, chickens, etc.	Erysipelas (<i>Erysipelothrix rhusiopathiae</i>)	III.55	
		Chickens, turkeys, ducks	<i>Enterococcus</i> spp. <i>Streptococcus</i> spp.	III.56	
		All species	Staphylococcosis (<i>Staphylococcus aureus</i>)	III.57	
	All species	Listeriosis (<i>Listeria monocytogenes</i>)	III.61		
	Waterfowl	Duck virus enteritis (<i>Anatid herpesvirus 1</i>)	VI.89		
	Endocarditis	Chickens, turkeys, etc.	Chronic fowl cholera (<i>Pasteurella multocida</i>)	III.46	
		Chickens, pheasants, quails, etc.	Infectious coryza (<i>Av. paragallinarum</i>)	III.47	
		Ducks, chickens, turkeys, pigeons	<i>Streptococcus</i> spp. (<i>Streptococcus gallolyticus</i>)	III.56 VI.99	
		Chickens, turkeys, etc.	<i>Enterococcus faecalis</i>	III.56	
	Pericarditis	Chickens, turkeys, game birds, etc.	Chronic respiratory disease (<i>Mycoplasma gallisepticum</i>)	III.41	
		All species	Paratyphoid salmonella (<i>Salmonella</i> spp.)	III.43	
		Turkeys, chickens ducks, geese, etc.	Acute fowl cholera (<i>Pasteurella multocida</i>)	III.46 VI.93	
		Turkeys, chickens	<i>Ornithobacterium rhinotracheale</i>	III.48	
		Ducks, turkeys, chickens, etc.	Duck septicemia (<i>Riemerella anatipestifer</i>)	III.49 VI.93	
		Chickens, turkeys, ducks, etc.	Pseudomoniasis (<i>Pseudomonas</i> spp.)	III.60	
		Muscovy ducks	Duck reovirus (<i>Reovirus</i>)	VI.85	
		Mule ducks	SBDS Derszy's disease (<i>Parvovirus</i>)	VI.87	

Tabl.104.1: Differential diagnosis of infectious cardiac diseases. Bacteria causing myocarditis may also be associated with endocarditis and/or pericarditis (*Chlamydia psittaci*, *Escherichia coli*, *Avibacterium gallinarum*, *Erysipelothrix rhusiopathiae*, *Streptococcus* spp. etc.).

Differential diagnosis

104. CARDIOVASCULAR DISEASES

Many cardiovascular diseases are important causes of death in poultry and other species of birds (see Chap.IV.70). Some cardiovascular diseases occur in association with systemic or local disease produced by infectious, nutritional, toxic or unknown causes.

Differential diagnosis of cardiovascular diseases includes cardiac diseases and pathology of blood vessels. The differential diagnosis of septicemias with and without hemorrhagic lesions is presented in Chap.VII.105.

Symptoms & lesions	Species affected	Main clinical signs & lesions	Etiology	Chap.	
OTHER CARDIAC DISEASES	Blood vessels	Turkeys, ratites	Sudden death; carcasses pale; large amounts of blood in the abdominal cavity	Aortic rupture	IV.70 VI.100
		Turkeys	Sudden death syndrome in turkeys associated with perirenal hemorrhages	Perirenal hemorrhages	IV.70
		All species	Common disorder of the aorta and other major arteries	Atherosclerosis	IV.70
	Fungus & parasites	All species	Dyspnea; mortality; nodules (trachea, bronchi, lungs, air sacs); diarrhea; stunting; systemic infection with other localizations: brain, eye, skin; kidneys, etc.	Brooder pneumonia (<i>Aspergillus fumigatus</i>)	IV.62
		All species	Weakness, emaciation, diarrhea, ataxia progressing to death	<i>Toxoplasma</i> spp	IV.67
		All species	Presence of numerous cysts visible in skeletal and cardiac muscles; other locations: esophagus, brain, lung, liver	Sarcocystosis (<i>Sarcocystis</i> spp.)	IV.67
	Hemorrhages or hydropericardium	Turkeys, chickens, ducks, geese, etc.	Sudden death; septicemia; hemorrhages (heart, gizzard, abdominal fat); oophoritis; dermal necrosis; enlargement and necrosis of liver and spleen; peritonitis; egg drop	Acute fowl cholera (<i>Pasteurella multocida</i>)	III.46 VI.93
		Turkeys, chickens, etc.	Sudden death; purple color and turgescence of snood and dewlap; yellow-green diarrhea; mortality; septicemia: congestion or hemorrhages (petechiae); catarrhal enteritis; splenomegaly; valvular endocarditis; arthritis	Erysipelas (<i>Erysipelothrix rhusiopathiae</i>)	III.55
		Waterfowl	Bloody greenish diarrhea; high mortality; conjunctivitis; esophagitis; widespread hemorrhages; intestinal annular bands; egg drop (25-40%); smaller spleen	Duck virus enteritis (<i>Anatid herpesvirus 1</i>)	VI.89
		Chickens	Accumulation of up to 10 ml of fluid in the pericardium; small areas of necrosis in the liver and heart muscle	Hydropericardium syndrome (<i>Aviadenovirus</i>)	II.24
		Muscovy ducks	Ducklings (< 5 weeks); lameness; bad feathering; diarrhea; hydropericarditis	Muscovy duck parvovirus	VI.86
	Cardiomyopathies	All species	Precipitation of urates: kidneys; heart, liver, mesenteries, air sac, peritoneum, muscles, synovial sheaths, spleen;	Visceral urate deposition (visceral gout)	IV.71
		Turkeys	Poults (2 weeks of age); sudden death or cardiomyopathy; ruffled feathers, cyanosis and dyspnea; dilatation of the right ventricle or both ventricles	Round heart disease	IV.70
		Chickens	Myocardial degeneration (4 and 8 months of age); heart pale and enlarged, with hypertrophy confined to the left ventricle	Round heart disease	IV.70
		Broilers	Pallor; sudden death; cyanosis; marked hypertrophy and dilation of the right ventricle; hydropericardium; congested or mottled liver; congested lungs	Pulmonary hypertension or ascites syndrome	IV.70
		Chickens	Most birds (1 to 8 weeks of age) found dead on their back (flip-over); full digestive tract; liver enlarged, pale and friable; empty gallbladder	Sudden death syndrome in broiler chickens	IV.70
		Chickens, turkeys	Thickening of the ventricle wall	Hypertrophic cardiomyopathy	IV.70
		All species	Degenerative changes in the myocardium due to hypoxia, nutritional deficiencies, intoxications, etc.	Degenerative and inflammatory changes	IV.70
		All species	Material retained in the gizzard; myocardial degeneration; nephrosis; nervous signs	Lead poisoning	V.79
	HEART NODULES	Neoplasia	Chickens (turkeys)	Depression, weight loss, diarrhea, diffuse or nodular lymphomas in visceral organs (liver, spleen, ovary, kidney, proventriculus, heart, bursa) and sometimes in the skin (feather follicles) and skeletal muscles	Marek's disease Acute form (<i>Very virulent Marek's disease virus</i>)
Chickens			Depression, pallor, nodular or diffuse tumors of liver, spleen, bursa and other organs; skeletal tissues; subclinical infection without neoplastic lesions; egg drop	Lymphoid leukosis (<i>Retrovirus ALV-A</i>)	II.34
Turkeys, chickens, ducks, geese			Runting; pallor; abnormal feather development; lameness; atrophy of thymus and bursa; enlarged peripheral nerves (marginal); proventriculitis, enteritis; hepatomegaly, splenomegaly; other tumors (gonads, pancreas, kidneys, heart)	Reticuloendotheliosis (<i>Gammaretrovirus</i>)	II.35
Turkeys			8-10 week-old turkeys; mortality (up to 25%); enlarged marble spleen; tumors (liver, thymus, gonad, pancreas, kidney, intestine, lung, heart)	Lymphoproliferative disease (<i>Retrovirus</i>)	II.35
Granuloma		Chickens, turkeys, etc.	Anorexia, prostration; droopy wings; diarrhea; mortality (up to 100%); dyspnea; blindness; arthritis; nodules (heart, gizzard, pancreas, lung, etc.)	Pullorum disease (<i>S. Gallinarum-pullorum</i>)	I.3 III.42
		All species	Chronic disease; progressive emaciation; pallor; diarrhea; lameness; granuloma: lesion triad "liver, spleen, intestine", bone marrow, ovary, teste, heart, skin, lung	Tuberculosis (<i>Mycobacterium avium</i>)	III.54

Tabl.104.2: Differential diagnosis of blood vessel affections, cardiac diseases with nodules and other cardiac diseases.

Symptoms & lesions	Species affected	Main clinical signs & lesions	Etiology	Chap.	
BURSA OF FABRICIUS & THYMUS	Hemorrhages, granuloma, etc. in bursa	All species	Sudden onset (mortality up to 100%); egg drop; respiratory signs (sinusitis, facial swelling); hemorrhages; cyanosis; diarrhea; encephalitis; pancreatitis	Highly pathogenic avian influenza virus	II.18
		Chickens, game birds, pigeons, etc.	Sudden death with high mortality; hemorrhagic lesions in the intestinal tract; encephalitis	Newcastle disease (<i>Velogenic paramyxovirus 1</i>)	II.19
		Chickens	Acute form: vent pecking; diarrhea; mortality (10-90%); inflammation of bursa swollen early and atrophied later; petechial hemorrhages (muscles, liver); kidney with urate deposits; milder form: immunodepression	Gumboro disease (<i>Avibirnavirus</i>)	II.32
		Turkeys, chickens, etc.	No clinical signs to severe diarrhea and death; associated with vibronic hepatitis; egg drop (immune-compromised birds); granuloma in bursa	Campylobacteriosis (<i>Campylobacter</i> spp.)	III.53
		All species	Hyperkeratosis (cornea, mouth, esophagus); nutritional nephropathy; ruffled feathers; corneal hyperkeratosis; nerve lesion; egg drop	Vitamin A deficiency	IV.71
		Waterfowl	Bloody greenish diarrhea; high mortality; conjunctivitis; esophagitis; widespread hemorrhages; intestinal annular bands; egg drop (25-40%); smaller spleen	Duck virus enteritis (<i>Anatid herpesvirus 1</i>)	VI.89
	Atrophy	All species	Inability of chicks to reach the water; watery diarrhea; renal damage; water refusal or water deprivation; coccidiosis; visceral urate deposition; etc.	Dehydration Water deprivation	I.9 IV.72
		Chickens	Conjunctivitis, tracheitis, pneumonia; nephritis (young birds); salpingitis (abnormalities of egg-shell and egg albumen); egg drop (>50%); false layers; enteritis	Infectious bronchitis (<i>Coronavirus</i>)	II.21
		Chickens, etc.	Sudden death (2-30%); pallor; lethargy; ruffled feathers; anorexia; yellow droppings; hepatitis; hemorrhages; hydropericardium; pancreatitis; anemia	Inclusion body hepatitis (<i>Aviadenovirus</i>)	II.24
		Turkeys, chickens, ducks, geese, etc.	Runting; pallor; abnormal feather development; lameness; atrophy of thymus and bursa; enlarged peripheral nerves (marginal); proventriculitis; enteritis; hepatomegaly; splenomegaly; other tumors (gonads, pancreas, kidneys, heart)	Reticuloendotheliosis (<i>Gammaretrovirus</i>)	II.35
		Turkeys	8-10 week-old turkeys; mortality (up to 25%); enlarged marble spleen; tumors (liver, thymus, gonad, pancreas, kidney, intestine, lung, heart)	Lymphoproliferative disease (<i>Retrovirus</i>)	II.35
		Turkeys	High morbidity; depression; mortality (age<6 weeks); egg drop; mucoid droppings; intestines filled with watery material and gas; bursa atrophied	Turkey Coronavirus (<i>Coronavirus</i>)	II.36
		Pheasants, etc.	Encephalitis; increased mortality; egg drop (turkey breeders)	Eastern equine encephalitis	II.37
		Chickens, turkeys, etc.	Arthritis; synovitis; breast blisters; respiratory signs; egg drop (eggshell apex abnormalities); tenosynovitis, salpingitis; airsacculitis	Infectious synovitis (<i>Mycoplasma synoviae</i>)	III.41
		Turkeys, chickens, etc.	Sudden death in birds in good conditions with full crops containing feed; hepatitis (bile staining and enlarged liver); gallbladder distension; splenomegaly	Acute colisepticemia (<i>Escherichia coli</i>)	III.45
		Turkeys	Severe stunting; high mortality; "helicopter birds"; atrophy of thymus (and less severely atrophy of bursa and spleen); immunodepression	Poult enteritis mortality syndrome	II.29 IV.72
	Hypertrophy of bursa	Chickens	Acute form: vent pecking; diarrhea; mortality (10-90%); inflammation of bursa swollen early and atrophied later; petechial hemorrhages (muscles, liver); kidney with urate deposits; milder form: immunodepression	Gumboro disease (<i>Avibirnavirus</i>)	II.32
		Chickens (turkeys)	Depression, weight loss, diarrhea, diffuse or nodular lymphomas in visceral organs (liver, spleen, ovary, kidney, proventriculus, heart, bursa) and sometimes in the skin (feather follicles) and skeletal muscles	Marek's disease Acute form (<i>Very virulent Mardivirus</i>)	II.33
		Chickens	Depression, pallor, nodular or diffuse tumors of liver, spleen, bursa and other organs; skeletal tissues; subclinical infection without neoplastic lesions; egg drop	Lymphoid leukosis (<i>Retrovirus ALV-A</i>)	II.34
		Chickens	Diffuse myeloid leukosis: pallor; liver and spleen are enlarged and granular appearance of the liver; bursa sometimes tumorous; tumor infiltration of bone marrow; myeloblastic leukemia; other tumors (ovary, kidneys, bursa)	Myeloid leukosis Myeloblastosis (<i>Retrovirus ALV-J</i>)	II.34
SPLEEN	Virus	Chickens	Splenomegaly	<i>Aviadenovirus</i> splenomegaly	II.24
		Turkeys, bustards	Sudden death; depression, bloody droppings, decreased feed and water consumption; 10-15% mortality (up to 60%); swollen dark purple small intestine filled with bloody content; enlarged, mottled spleen followed by atrophy; hepatomegaly	Turkey hemorrhagic enteritis (<i>Siadenovirus</i>)	II.25
		Chickens	Pallor; sudden death; egg drop (up to 20%); abnormal eggs; clotted blood in the abdominal cavity and/or on the liver; hepatitis; spleen enlarged and pale	Hepatitis E (<i>Hepevirus</i>)	II.38
		Pheasants, turkeys, guinea fowls	Sudden death; depression; spleen enlarged with grey necrotic foci; acute pulmonary congestion; hepatomegaly	Marble spleen disease (<i>Siadenovirus</i>)	II.24 VI.97
	Other	Fowls, turkeys	Pale and shrunken combs; egg drop; small nodular regressing ovarian follicles; hepatitis; oophoritis; salpingitis; white foci or nodules on testes	Fowl typhoid (<i>S. Gallinarum-pullorum</i>)	III.42 VI.93
		Turkeys, chickens, ducks, geese, etc.	Sudden death; septicemia; hemorrhages (heart, gizzard, abdominal fat); oophoritis; dermal necrosis; enlargement and necrosis of liver and spleen; peritonitis; egg drop	Acute fowl cholera (<i>Pasteurella multocida</i>)	III.46 VI.93
		Turkeys, chickens, ducks, pigeons, etc.	Diarrhea; dyspnea; yellow-green droppings; lameness; conjunctivitis; granulomas: liver, spleen, lungs, heart, kidneys, joints; osteomyelitis	Yersiniosis (<i>Y. pseudotuberculosis</i>)	III.59
		All species	Anorexia; fever; depression; cyanosis of the head; anemia; marked enlargement and mottling of the spleen; hepatitis; nephritis; pericarditis	Spirochaetosis (<i>Borrelia anserina</i>)	III.61

Tabl.105.1: Major diseases accompanied by atrophy or hypertrophy of the bursa of Fabricius and thymus [atrophy of the bursa of Fabricius and thymus is also seen under immunodepressive diseases (see Tabl.105.2)] and with some disorders with lesions of the spleen. Note that splenomegaly is observed with many infectious diseases.

Differential diagnosis

105. HEMATOPOIETIC SYSTEM

In birds, the organs of the immune system are classified into primary or central lymphoid organs (thymus and bursa of Fabricius) and secondary or peripheral lymphoid organs (see Chap.I.14). The peripheral lymphoid organs and tissues include the spleen, the bone marrow and the Harderian gland. In addition, birds have head-associated lymphoid tissues (HALT), bronchus-associated lymphoid tissues (BALT), and gut-associated lymphoid tissues (GALT). Examples of GALT include esophageal tonsils, Meckel's diverticulum, Peyer's patches, cecal tonsils as well as annular bands in ducks.

Changes in size or color of lymphoid organs are visual indicators for the differential diagnosis of diseases of the hematopoietic system. This essentially includes immunosuppressive diseases (e.g., chicken infectious anemia, infectious bursal

disease, Marek's disease, diseases caused by avian reovirus, circovirus, mycotoxines) but also septicemic diseases (see Tabl.109.2) and all causes of anemia (see Tabl.112.4). The degree of atrophy or enlargement of the thymus and bursa of Fabricius is sometimes difficult to evaluate. It is also important to take into account the involution of these organs occurring with age. Often the lesions observed in the liver (see Chap.VII.102) are also in the spleen (with some exceptions like coligranuloma or Hjarre's disease). In many cases the changes in lymphoid organs (edema, hemorrhage, atrophy, granuloma, etc.) are not specific to a given disease. Furthermore, hypertrophy of primary lymphoid organs can be followed by atrophy during the course of the disease. That is why we only present the main diseases involving the hematopoietic system.

Symptoms & lesions	Species affected	Main clinical signs & lesions	Etiology	Chap.	
IMMUNODEPRESSIVE DISEASES	Viral immunodepressive diseases	Chickens	Lameness; swelling of the tarsometatarsal joint (tendinitis); tenosynovitis/arthritis; rupture of the gastrocnemius tendon	Viral arthritis (<i>Reovirus</i>)	II.27
		Chickens	2-4 week-old chicks; severe anemia; hematocrit <27%; lymphoid depletion (thymus and bursal atrophy, pale bone marrow); hemorrhages; mortality (up to 60%)	Chicken infectious anemia (<i>Gyrovirus</i>)	II.30
		Chickens	Acute form: vent pecking; diarrhea; mortality (10-90%); inflammation of bursa swollen early and atrophied later; petechial hemorrhages (muscles, liver); kidney with urate deposits; milder form: immunodepression	Gumboro disease (<i>Avibirnavirus</i>)	II.32
		Chickens (turkeys)	Depression, weight loss, diarrhea, diffuse or nodular lymphomas in visceral organs (liver, spleen, ovary, kidney, proventriculus, heart, bursa) and sometimes in the skin (feather follicles) and skeletal muscles	Marek's disease Acute form (<i>Very virulent Mardivirus</i>)	II.33
		Chickens (turkeys)	Severe atrophy of lymphoid organs; high mortality between 10 and 14 days of age	Marek's disease Acute cytolytic disease (<i>Very virulent + Mardivirus</i>)	II.33
		Psittacines	Sudden death; acute bursal necrosis; chronic: dystrophic feathers, stunting; immunodepression (necrosis of bursa)	Psittacine beak and feather disease (<i>Circovirus</i>)	II.39
		Waterfowl	Bloody greenish diarrhea; high mortality; conjunctivitis; esophagitis, widespread hemorrhages; intestinal annular bands; egg drop (25-40%); smaller spleen	Duck virus enteritis (<i>Anatid herpesvirus 1</i>)	VI.89
		Waterfowl	Growth retardation; feathering disorders; immunodepression	Duck or geese circovirus	VI.91
		Pigeons	Anorexia, lethargy, regurgitation from the crop, diarrhea and loss of weight; atrophy of bursa	Young Pigeons Disease Syndrome (<i>Circovirus</i>)	II.39 VI.99
	Toxin or toxic	Ducks, turkeys, geese, guinea fowls, etc.	Acute toxicity: diarrhea; ataxia; convulsions; liver enlarged with small necrotic and hemorrhagic foci; spleen, enlarged pancreas and kidney; atrophy of bursa; chronic intoxication: stunting; egg drop; decreased hatchability	Aflatoxicosis (<i>Aspergillus</i> spp.)	IV.63
		Ducks, turkeys, geese, guinea fowls, etc.	Acute intoxication: diarrhea; necrotic lesions (oral mucosa, gastrointestinal tract); chronic poisoning: stunting; abnormalities of feathering; egg drop; hepatitis; immunodepression (atrophy of bursa)	Trichothecene poisoning (<i>Fusarium</i> spp.)	IV.63
		All species	Potent estrogenic properties (birds traditionally resistant to this toxin)	Zearalenone	IV.63
		All species	Material retained in the gizzard; myocardial degeneration; nephrosis; nervous signs	Lead poisoning	V.79

Tabl.105.2: Main viral immunosuppressive diseases and toxins or toxic inducing immunodepression.

INTRODUCTION

Poultry in a production environment may experience skeletal muscle disease of nutritional, degenerative, toxic, and iatrogenic causes. The following cases are shared for general review and discussion; definitive diagnosis was not always forthcoming. These cases point to an ongoing need for collaboration in resolving health and product quality issues in muscle.

NUTRITIONAL MYOPATHIES (see also Chap. IV.69 & IV.71)

Deficiencies of vitamin E or selenium cause classic nutritional myopathy (Fig.106.1 to 106.4), but these are not common as a clinical event. During feed manufacturing, vitamins and trace minerals are added as a premix and omission errors can occur as multiple deficiencies. Vitamin E, a labile fat soluble vitamin, is susceptible to destruction by rancid fats, and deficiency is most commonly seen as encephalomalacia. Vitamin E and selenium however may have sparing effects on other muscle conditions and have a role in the management of emerging developmental problems. The ongoing selection for muscle yield in meat-type poultry is a factor but not well defined. This is evidenced histologically by the presence of occasional degenerative fibers in major muscle groups of clinically normal broiler chickens. Although within normal limits, it indicates that the transition from normal to disease is not always clearly demarcated and is likely influenced by subtle nutritional and physiological factors.

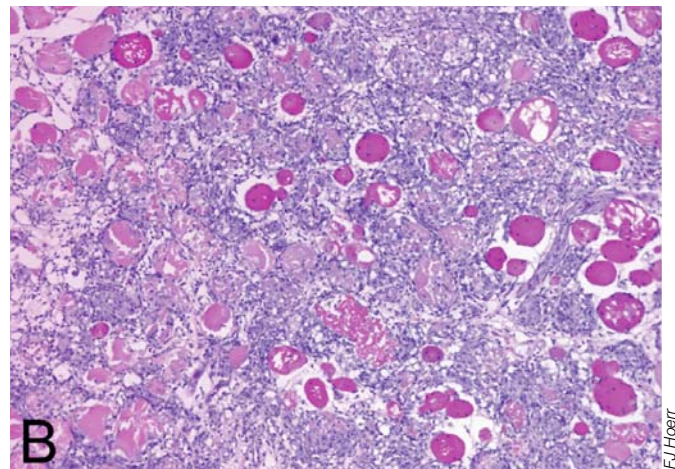
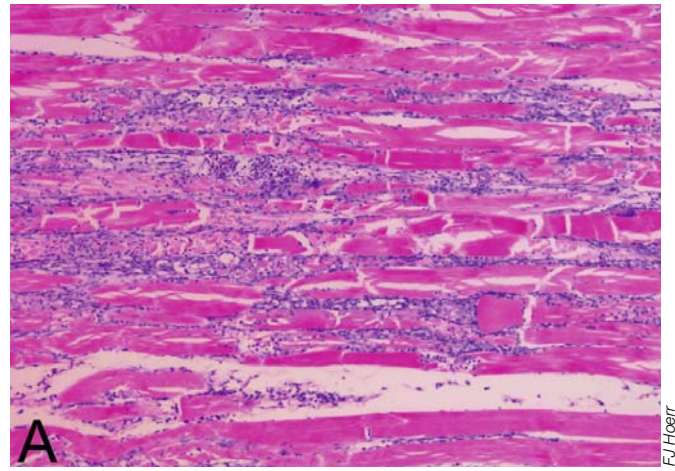


Fig.106.1 & 106.2: Broilers at processing; nutritional myopathy. A) Pectoral muscle fiber necrosis, inflammation, and early regeneration. B) Sagittal section showing swollen muscle fibers with vacuolization and increased eosinophilic staining, and many collapsed sarcolemmal tubules with macrophage infiltration. Vitamin E was reportedly omitted from the withdrawal feed. Lesions were also identified in cooked muscle, below.

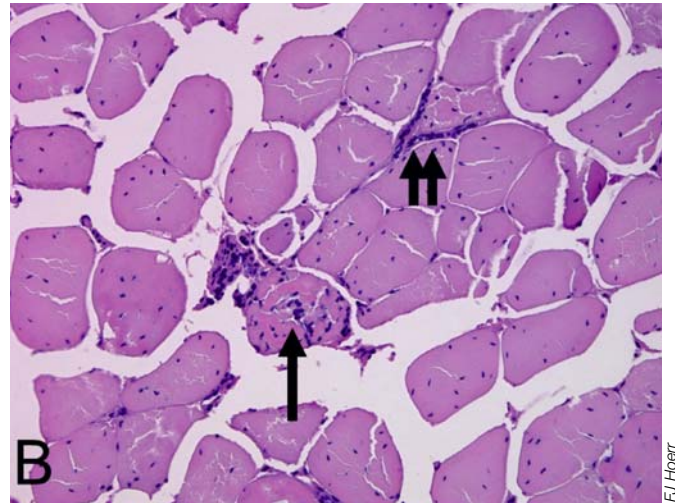
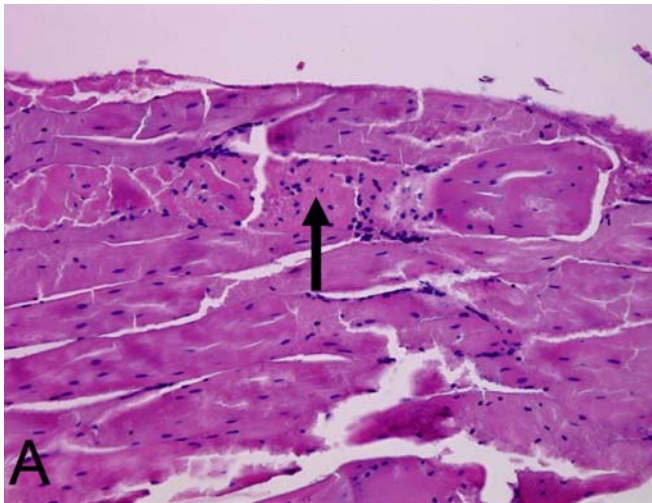


Fig.106.3 & 106.4: Cooked pectoral (breast) muscle, fixed in formalin and routinely processed for histopathology. A) Individual necrotic fiber (arrow). B) Necrotic muscle fiber with macrophage infiltration (arrow); shrunken fiber with reactive endomyseum (double arrow). Vitamin E was reportedly omitted from the withdrawal feed.

Differential diagnosis

106. MUSCLE DISEASES



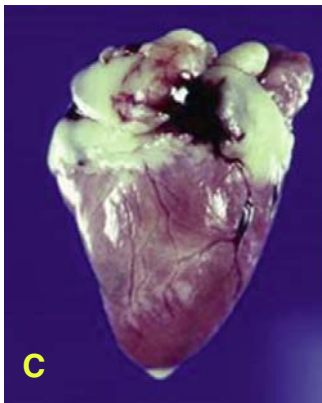A

FJ Hoerr



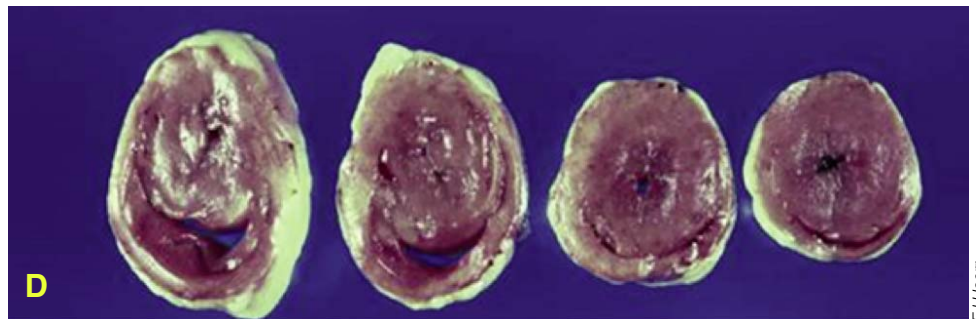
B

R Williams



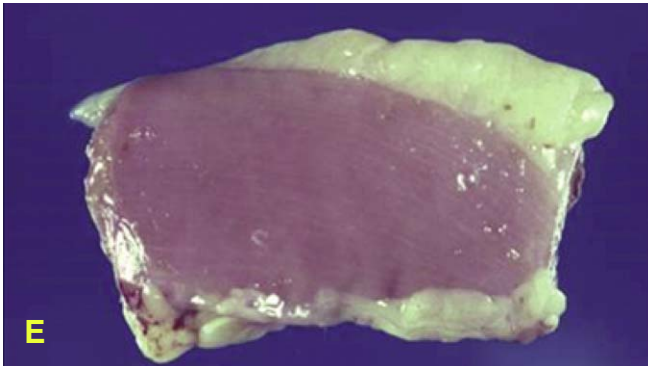
C

FJ Hoerr



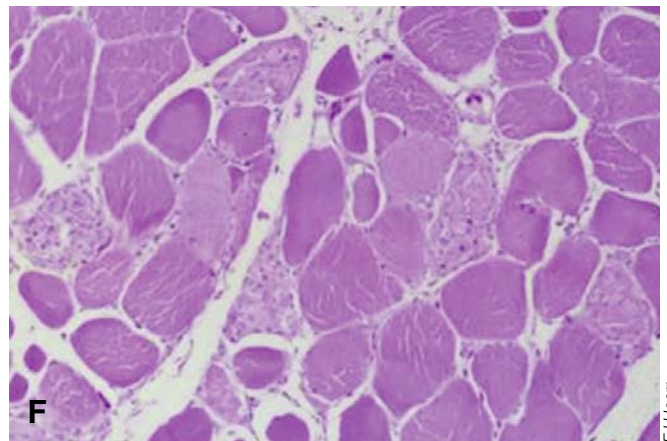
D

FJ Hoerr



E

FJ Hoerr



F

FJ Hoerr

Fig.106.5 to 106.10: Ionophore intoxication. A) Recumbent broiler with legs extended caudally. B) Broiler breeders consumed feed adulterated with monensin and salinomycin; legs are extended caudally. Photos C to F are represent tissues from these breeders examined at necropsy. C,D) Pallor in the myocardium confirmed histologically to be myocardial necrosis. E) Diffusely pale wet adductor muscle from leg. F) Necrosis of muscle fibers in the adductor muscle.

IONOPHORE INTOXICATION (see also Chap. IV.69)

The most common toxic myopathy is caused by inadvertent or excessive exposure to ionophore coccidiostats (monensin, salinomycin, and narasin) (Fig.106.5 to 106.10). Feed manufacturing errors can result in excessive exposure to broilers, and inadvertent exposure of turkeys and broiler breeders.

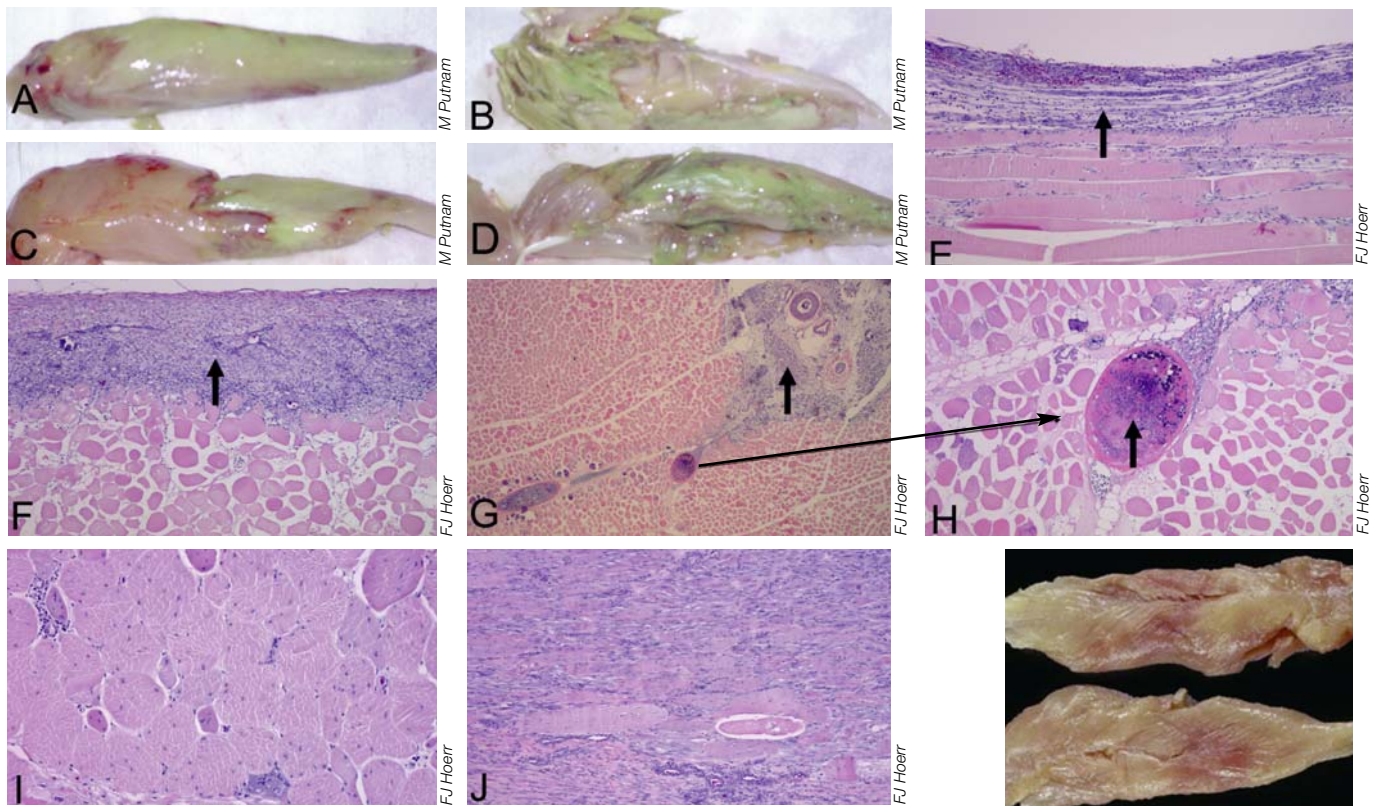


Fig.106.11 & to 106.20: Broilers at processing; deep pectoral myopathy. A-D) Green discoloration of the deep pectoral muscle was responsible for losses at processing. E, F) Edema, hemorrhage, and fibroplasia cause thickening of the sheath of the deep pectoral muscle (arrows), with necrosis of adjacent muscle fibers. G) Necrosis of perivascular muscle fibers (arrow) results from the swelling of muscle due to exertion, and compression of vessels, causing muscle hypoxia and necrosis. H) Higher magnification of a perimyseal blood vessel with a thrombus (arrow). I, J) Multifocal to confluent degeneration and necrosis of deeper muscle fibers.

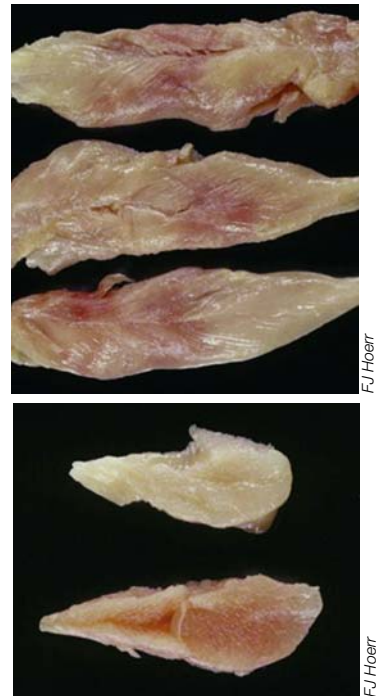


Fig.106.23 & 106.24: Acute deep pectoral myopathy in broilers. Top: The muscle is red and wet but the localized lesion in the midbody of the muscle is consistent with pressure developing between the muscle body and the sheath (removed). This lesion likely developed during loading and transport to processing. Below: Reddened affected and more normal muscle.

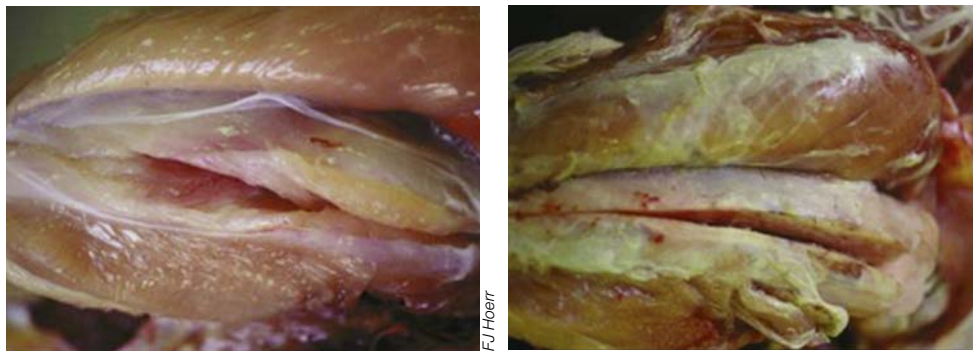


Fig.106.21 & 106.22: Deep pectoral myopathy, broiler breeders. This is often confused with sepsis by field personnel but bacterial cultures are sterile. In breeders, this condition is caused by increased spontaneous activity with wing flapping. Left. Acute; Right. Subacute to chronic.

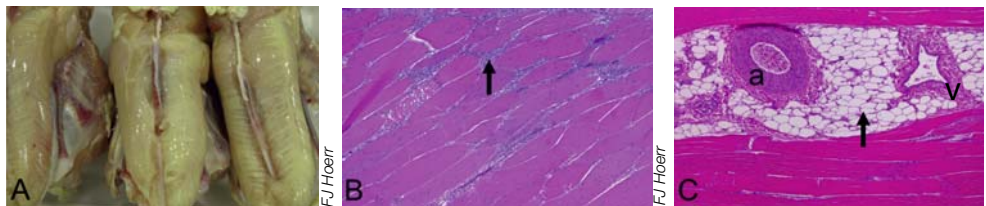


Fig.106.25, 106.26 & 106.27: Broilers at processing; deep pectoral myopathy and white striping. A) White stripes in deep pectoral muscle raised questions about meat quality. B) Necrosis and loss of muscle fibers (arrow) are adjacent the sheath of the deep pectoral muscle, consistent with mild deep pectoral myopathy. C) Increased perimyseal fat (arrow) is also present and contributes to the grossly striped appearance of the muscle; normal artery (a) and vein (v).

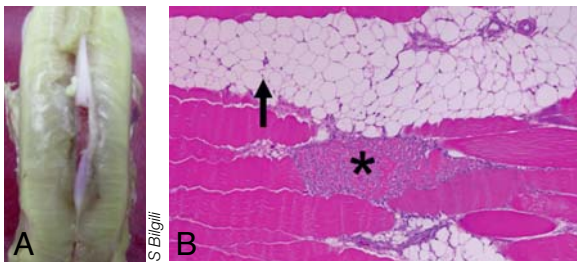


Fig.106.28 & 106.29: Broilers, 62 days, white stripped muscle. White stripes in pectoral and adductor muscles may be due to fat deposition in the perimysium, the connective tissue that surrounds bundles of 10-100 muscle fibers. This is normal in leg muscle but abnormal in pectoral muscles. A) Pectoral muscle with white striping. B) Band of adipose tissue (arrow) is the reason for the white stripe, accompanied by a single necrotic muscle fiber (*).

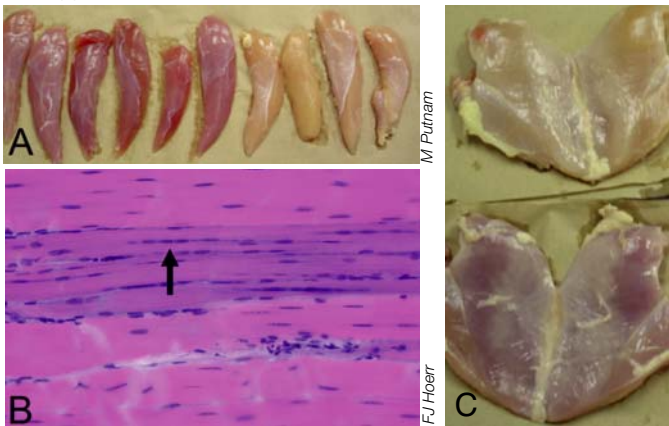


Fig.106.30, 106.31 & 106.32: Broiler, dry red muscle. A) Deep pectoral. The five samples on the left are affected; the four on the right are within normal limits. B) Muscle fibers lack individual definition and have increased eosinophilic staining, an early degenerative change. Basophilic regenerating muscle fibers have nuclei aligned in an internal rows (arrow). The fiber degeneration and regeneration was suggestive of a myopathy contributing to the problem detected during processing. C) Top. Normal superficial pectoral muscle. Bottom. Dry red pectoral muscle, which is associated with a high pH at processing.

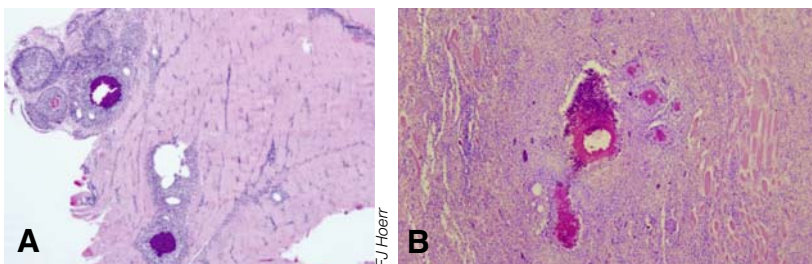


Fig.106.33 & 106.34: Broiler breeders, vaccine adjuvant myositis. A) Pectoral muscle with lymphohistiocytic inflammation occurring as concentric infiltration around clear vacuoles of vaccine adjuvant and an eosinophilic coagulum of fibrin and cell debris. B) Intense inflammation around central adjuvant droplets, with locally diffuse lymphohistiocytic myositis.

REFERENCES

Duclos MJ et al. Muscle growth and meat quality. *J Appl Poult Res*, 2007,16:107-112.
 Fulton RM. Toxins and poisons. In: *Diseases of Poultry* 13th ed., 2013, Ed. Swayne, D.E. pp. 1287-1316.
 Guetchom B et al. Effect of extra dietary vitamin E on preventing nutritional myopathy in broiler chickens. *J Appl Poult Res*. 2012,21:548-555.
 Klasing, K.C. Nutritional diseases. In: *Diseases of Poultry* 13th ed., 2013, Ed. Swayne, D.E. pp. 1205-1232.
 Leeson, S. Metabolic challenges: past, present, and future. *J Appl Poult Res*, 2007,16:121-125.
 Lien RJ et al. Induction of deep pectoral myopathy in broiler chickens via encouraged wing flapping. *J Appl Poult Res*,

DEEP PECTORAL MYOPATHY & WHITE STRIPED MUSCLE (see also Chap.IV.69)

Deep pectoral myopathy is the most common degenerative condition, which develops from exertion-related muscle swelling and pressure-induced ischemia from the constraining muscle sheath (Fig.106.11 to 106.24). Emerging conditions include white striped muscle, which is characterized by increased fat deposition and possibly involves early nutritional interaction with muscle stem cells (Fig.106.25 to 106.30). Scattered individual necrotic fibers commonly occur in clinically normal broilers; possibly an incidental finding or an indication of underlying nutritional or metabolic stress.

DRY RED MUSCLE & PALE SOFT EXUDATIVE MUSCLE

Other conditions include dry red firm “wooden” muscle (Fig.106.30, 106.31 & 106.32) and pale soft exudative muscle which are characterized by high and low pH extremes in muscle, respectively. The pathogeneses are largely undefined. These conditions are increasingly presented to the pathologist for examination, with the line between product quality control and disease diagnosis increasingly blurred.

IATROGENIC MUSCLE LESIONS

Common iatrogenic muscle lesions include inflammatory reactions at vaccine deposition sites which can influence health and eventually product quality (Fig.106.33 & 106.34).

2012,21:556-562.

Mallia JG et al. Roaster breast meat condemned for cyanosis: a dark firm dry-like condition? *Poult Sci*, 2000,79:908-912.

Powell, D.J., D.C. McFarland, A.J. Cowieson, W.I. Muir, and S.G. Vellerman. The effect of nutritional status and muscle fiber type on myogenic satellite cell fate and apoptosis. *Poult Sci*, 2014,93: 163-173.

Yang, X.J., X.X. Sun, C.Y. Li, X.H. Wu, and J.H. Yao. Effects of copper, iron, zinc, and manganese supplementation in a corn and soybean meal diet on the growth performance, meat quality, and immune responses of broiler chickens. *J. Appl. Poult. Res.* 20:263-271, 2011.

Yin H et al. Expression profiles of muscle genes in postnatal skeletal muscle in lines of chickens divergently selected for high and low body weight. *Poult Sci*, 2014,93:147-154.

Symptoms & lesions	Species affected	Main clinical signs & lesions	Etiology	Chap.	
JOINTS	Arthritis, synovitis & tendinitis	Chickens	Lameness; swelling of the tarsometatarsal joint (tendinitis); tenosynovitis/arthritis; rupture of the gastrocnemius tendon	Viral arthritis (<i>Reovirus</i>)	II.27
		Chickens, turkeys, game birds, etc.	Chronic respiratory disease; prostration; egg drop and poor egg quality; sinusitis; keratoconjunctivitis; airsacculitis; tenosynovitis; salpingitis	Chronic respiratory disease (<i>Mycoplasma gallisepticum</i>)	III.41
		Chickens, turkeys, etc.	Arthritis, synovitis; breast blisters; respiratory signs; egg drop (eggshell apex abnormalities); tenosynovitis; salpingitis; airsacculitis	Infectious synovitis (<i>Mycoplasma synoviae</i>)	III.41
		Turkeys	Reduced egg hatchability; sinusitis, airsacculitis; poor growth; helicopter feathering; skeletal abnormalities (osteomyelitis, osteodystrophy)	Mycoplasmosis (<i>Mycoplasma meleagridis</i>)	III.41
		Chickens, turkeys, etc.	Anorexia, prostration; droopy wings; diarrhea; mortality (up to 100%); dyspnea; blindness; arthritis; nodules (heart, gizzard, pancreas, lung, etc.)	Pullorum disease (<i>S. Gallinarum-pullorum</i>)	I.3 III.42
		All species	Septicemia; diarrhea; blindness; lameness; hepatitis; splenitis; pericarditis; arthritis; airsacculitis; typhlitis; omphalitis; peritonitis; oophoritis; meningitis	Paratyphoid salmonella (<i>Salmonella</i> spp.)	III.43
		Turkeys, chickens, etc.	Chronic lameness; excess mortality; osteomyelitis (arched back, paralysis); osteoarthritis; synovitis; spondylitis, <i>valgus-varus</i> leg deformity	Osteoarthritis, synovitis (<i>Escherichia coli</i>)	III.45
		Chickens, turkeys, etc.	Localized abscesses: joints, head, oviduct, respiratory tract (pneumonia, airsacculitis), middle ear and meninges (torticollis); fibrinonecrotic dermatitis	Chronic fowl cholera (<i>Pasteurella multocida</i>)	III.46
		Chickens, turkeys, etc.	Sudden death; purple color and turgescence of snood and dewlap, yellow-green diarrhea; mortality; septicemia: congestion or hemorrhages (petechiae); catarrhal enteritis; splenomegaly; valvular endocarditis; arthritis	Erysipelas (<i>Erysipelothrix rhusiopathiae</i>)	III.55
		Ducks, chickens, turkeys	Duckling sudden death syndrome; septicemia; splenomegaly; hepatomegaly; osteomyelitis; arthritis; vegetative valvular endocarditis	Streptococcus spp. (<i>Streptococcus gallolyticus</i>)	III.56
		Chickens, Muscovy ducks	Lameness progressing to paralysis; decubitus with legs extended forward; femoral head necrosis; tendonitis; arthritis; osteomyelitis (spinal abscesses)	Enterococcus spp. (<i>Enterococcus cecorum</i>)	III.56
		Chickens, turkeys, etc.	Endocarditis; hepatic granulomas; arthritis; amyloidosis (liver, joints)	Enterococcus faecalis	III.56
		Chickens, turkeys, ducks	Valvular endocarditis (<i>E. faecium</i> , <i>E. hirae</i> , <i>E. durans</i> , <i>S. gallineous</i> , <i>S. pluranimalium</i> , <i>S. zooepidemicus</i>); encephalomalacia (<i>E. hirae</i> , <i>E. durans</i>); cellulitis (<i>S. dysgalactiae</i>); sepsis (<i>E. faecium</i> , <i>S. pluranimalium</i>)	Enterococcus spp. Streptococcus spp.	III.56
		All species	Sudden death; palor; sinusitis; arthritis (amyloid); synovitis; osteomyelitis; dermatitis; omphalitis; septicemia; green liver; pneumonia; endocarditis; bumble foot	Staphylococcosis (<i>Staphylococcus aureus</i>)	III.57
		Turkeys, chickens, ducks, pigeons, etc.	Diarrhea; dyspnea; yellow-green droppings; lameness, conjunctivitis; granulomas: liver, spleen, lungs, heart, kidneys, joints; osteomyelitis	Yersiniosis (<i>Y. pseudotuberculosis</i>)	III.59
		Chickens, turkeys, ducks, etc.	Clinical signs may vary greatly and lesions are not specific; yolk sac infections; sudden death; swelling of the head; diarrhea; arthritis; hepatitis, etc.	Pseudomoniasis (<i>Pseudomonas</i> spp.)	III.60
		All species	Dead-in-shell embryos; weak chicks; arthritis; cellulitis; diarrhea; septicemia	Aeromonas spp.	III.61
		All species	Dead-in-shell embryos; weak chicks or poults; septicemia; hepatitis; arthritis	Acinetobacter spp.	III.61
		Muscovy ducks	Respiratory signs; mortality (up to 40%); enteritis; conjunctivitis; lameness; stunting; egg drop; splenomegaly; perihepatitis; pericarditis; airsacculitis	Duck reovirus (<i>Reovirus</i>)	VI.85
		Mule ducks	Short-beaked dwarfism syndrome (SBDS); growth retardation; deformities and fractures of long bones; splenomegaly; intestinal edema	SBDS Derszy's disease (<i>Parvovirus</i>)	VI.87
OSTEOMYELITIS & TUMOR	Spinal osteomyelitis	Turkeys	Reduced egg hatchability; sinusitis; airsacculitis; poor growth; helicopter feathering; skeletal abnormalities (osteomyelitis, osteodystrophy)	Mycoplasmosis (<i>Mycoplasma meleagridis</i>)	III.41
		Chickens, Muscovy ducks	Lameness progressing to paralysis; decubitus with legs extended forward; femoral head necrosis; tendonitis; arthritis; osteomyelitis (spinal abscesses)	Enterococcus spp. (<i>Enterococcus cecorum</i>)	III.56
		All species	Sudden death; pallor; sinusitis; arthritis (amyloid), synovitis, osteomyelitis, dermatitis, omphalitis; septicemia; green liver; pneumonia; endocarditis; bumble foot	Staphylococcosis (<i>Staphylococcus aureus</i>)	III.57
		Turkeys, chickens	Osteomyelitis; septicemia; skin lesions	Arcanobacterium pyogenes	III.61
	Other	Chickens	Severe lameness; wing tip used for support during rising and sitting	Femoral head necrosis	IV.69
		Chickens	Tumoral form of myeloid leucosis: diffuse nodular tumors of creamy-white colour; other tumors [ovary, kidneys, thymus, surface of bones (sternum, ribs, skull)]	Myelocytomatosis (<i>Retrovirus ALV-J</i>)	II.34
		All species	Dyspnea; mortality; nodules (trachea, bronchi, lungs, air sacs); diarrhea; stunting; systemic infection with other localizations: brain, eye, skin; kidneys, etc.	Brooder pneumonia (<i>Aspergillus fumigatus</i>)	IV.62
		Chickens, guinea fowls, turkeys	Abnormal growth of bone resulting in pericortical accumulation of immature bone	Osteopetrosis (<i>Retrovirus</i>)	II.34 IV.69

Tabl.107.1: Differential diagnosis of infectious disease of joints and bone.

Differential diagnosis

107. LOCOMOTOR DISORDERS

Any lesion of the nervous, vascular, muscular and skeletal systems can be at the origin of a locomotion disorder. The differential diagnosis of cardiovascular, muscular and nervous system diseases is described in chapters VII.104, VII.106 and VII.107, respectively.

Locomotor disorders are also reported with dermatitis, in particular with pododermatitis (see Chap.VII.112).

The chronic evolution of some diseases may lead to urate deposits on viscera and in joints, resulting in lameness.

Non-infectious musculoskeletal disorders are mainly nutritional diseases (osteodystrophies) or conditions resulting from a multifactorial origin (hereditary and/or congenital affection, feed, environmental factors) as well as muscular or cutaneous disorders.

Symptoms & lesions	Species affected	Main clinical signs & lesions	Etiology	Chap.	
LAMENESS	Osteodystrophies	All species	Paralysis (fracture or displacement of vertebra); bone fragility (fractures); regressive ovaries; egg drop; shelled-egg partially calcified; enlarged parathyroid glands	Osteoporosis «Cage layer fatigue»	IV.69
		All species	Lameness; stunting; beaks, claws and bones soft and flexible; enlarged joints (rickety beads); thin or soft-shelled eggs; egg drop; decrease in hatchability	Rickets Osteomalacia	IV.69 IV.71
		Poultry	Stunting; dermatitis; poor feathering; «curled toe» paralysis (neuropathy)	Riboflavin deficiency	IV.71
	Multifactorial origin	Turkeys, etc.	Short, thick and usually misshapen long bones and enlargement of the hock joint	Chondrodystrophy «Turkey syndrom 65»	IV.69
		Chickens, turkeys	Long bone distortion of the distal tibiotarsal joint; rotation of the tibia may also occur (to be differentiated from slipped tendon)	Angular (Valgus-varus) deformity & tibial rotation	IV.69
		Chickens, turkeys	Growth plate abnormality with failure of removal of avascular prehypertrophying chondrocytes	Tibial dyschondroplasia	IV.69
		Chickens, turkeys	Paresis or paralysis (lesion of fourth thoracic vertebra pinching spinal cord)	Spondylolisthesis	IV.69
		All species	Degeneration of the articular cartilage causes pain and lameness (coxofemoral, femoro-tibial or intertarsal joints)	Degenerative joint disease	IV.69
	Other	All species	Young birds on slippery surfaces	Spraddle or splay legs	I.3 IV.69
		All species	Tophi, urate deposits around joints, particularly those of the feet (looking like bumble foot)	Articular urate deposition (articular gout)	IV.71 VI.88
TENDONS & FOOT	Tendons	All species	Subluxation of the gastrocnemius tendon; enlarged hock; usually laterally	Perosis (slipped tendon)	IV.69
		Chickens	May be complication of tenosynovitis; characteristic hock sitting posture; hematomas (green legs)	Rupture of the gastrocnemius tendon	IV.69
	Foot	Poultry	Severe beak trimming or toe trimming	Impaired interventions	I.3 I.9
		All species	Sudden death; palor; sinusitis; arthritis (amyloid), synovitis, osteomyelitis, dermatitis, omphalitis; septicemia; green liver; pneumonia; endocarditis; bumble foot	Staphylococcosis (<i>Staphylococcus aureus</i>)	III.57
		All species	Local injury to integument of the footpad; lameness and reluctance to move; complications: sternal bursitis, arthritis, osteomyelitis and/or tendinitis	Pododermatitis	IV.69

Tabl.107.2: Differential diagnosis of other locomotor disorders.

Symptoms & lesions	Species affected	Main clinical signs & lesions	Etiology	Chap.	
Virus	All species	Sudden onset (mortality up to 100%); egg drop; respiratory signs (sinusitis, facial swelling); hemorrhages; cyanosis; diarrhea; encephalitis; pancreatitis	Highly pathogenic avian influenza virus	II.18	
	Chickens, game birds, pigeons, etc	Sudden death with high mortality; hemorrhagic lesions in the intestinal tract; encephalitis	Newcastle disease (<i>Velogenic paramyxovirus 1</i>)	II.19	
	Turkeys, chickens psittacines	Egg drop; respiratory disease (laryngotracheitis); encephalitis; myocarditis; pancreatitis	Other paramyxovirus (serotypes 2, 3, 6 & 7)	II.19 II.39	
	Chickens, turkeys, quails, pheasants	1-3 week-old chicks; encephalomyelitis (ataxia, paralysis, opisthotonos, tremors); mortality from 25 to 50 %; cataract; egg drop (5 to 10%)	Avian encephalomyelitis (<i>Hepatovirus</i>)	II.23	
	Chickens (turkeys)	Neoplastic lymphoid infiltration and inflammation of nerves and central nervous system: paralysis of legs and wings; torticollis; paralysis and dilation of the crop; transient paralysis; blindness (ocular involvement)	Marek's disease Classical form (<i>Virulent Mardivirus</i>)	II.33	
	Turkeys, chickens, ducks, geese	Runting; pallor; abnormal feather development; lameness; atrophy of thymus and bursa; enlarged peripheral nerves (marginal); proventriculitis; enteritis; hepatomegaly; splenomegaly; other tumors (gonads, pancreas, kidneys, heart)	Reticuloendotheliosis (<i>Gammaretrovirus</i>)	II.35	
	Turkeys	8-10 week-old turkeys; mortality (up to 25%); enlarged marble spleen; tumors (liver, thymus, gonad, pancreas, kidney, intestine, lung, heart)	Lymphoproliferative disease (<i>Retrovirus</i>)	II.35	
	Pheasants, etc.	Encephalitis; increased mortality; egg drop (turkey breeders)	Eastern equine encephalitis	II.37	
	Turkeys, pheasants, etc.	Encephalitis, egg drop and small eggs, white even without shell (turkey breeders)	Western equine encephalitis	II.37	
	Partridges, turkeys	Drowsiness; ruffled feathers; severe egg drop; high mortality (poult)	Highlands J virus	II.37	
	Geese, ducks, etc.	Weakness; incoordination; fatal encephalitis; myocarditis	West Nile virus	II.37	
	Turkeys	Paralysis (<10 weeks); mortality up to 80%; hemorrhagic ovary; egg drop	Turkey meningoencephalitis	II.37	
	Ostriches	Myocarditis, encephalomyelitis	Turlock-like bunyavirus	II.37	
	Muscovy ducks	Ducklings (< 5 weeks); lameness; poor feathering; diarrhea; hydropericarditis	Muscovy duck parvovirus	VI.86	
	Bacteria	Psittacines, turkeys, ducks, etc.	Anorexia; lethargy; ruffled feathers; coughing; green droppings; loss of weight; egg drop; conjunctivitis; airsacculitis; pericarditis; enteritis; hepatitis; splenitis	Avian chlamydiosis (<i>Chlamydia psittaci</i>)	III.40
Chickens, turkeys, game birds, etc.		Chronic respiratory disease; prostration; egg drop and poor egg quality; sinusitis; keratoconjunctivitis; airsacculitis; tenosynovitis; salpingitis	Chronic respiratory disease (<i>Mycoplasma gallisepticum</i>)	III.41	
Turkeys, chickens		Anorexia; diarrhea; paralysis; opisthotonos; torticollis; blindness (white corneal opacity); typhlitis (white caseous casts); meningitis; omphalitis; hepatitis	Arizonosis (<i>S. enterica</i> subsp. <i>arizonae</i>)	III.44	
Turkeys, chickens, etc.		Colisepticemia localisations: meningitis, encephalitis, panophthalmitis	Meningitis, panophthalmitis (<i>Escherichia coli</i>)	III.45	
Chickens, turkeys, etc.		Localized abscesses: joints, head, oviduct, respiratory tract (pneumonia, airsacculitis), middle ear and meninges (torticollis); fibrinonecrotic dermatitis	Chronic fowl cholera (<i>Pasteurella multocida</i>)	III.46	
Turkeys, chickens		Facial edema; egg drop and reduced hatchability; edema and consolidation of lungs, pleuritis; airsacculitis; peritonitis; pericarditis; enteritis; arthritis; meningitis	<i>Ornithobacterium rhinotracheale</i>	III.48	
All species		Flaccid paralysis progressing cranially to the wings, neck, and eyelids ("limber neck"); increase in mortality without lesions	Botulism (<i>Clostridium botulinum</i>)	III.51 III.52	
Chickens, turkeys, ducks		Valvular endocarditis (<i>E. faecium</i> , <i>E. hirae</i> , <i>E. durans</i> , <i>S. gallineus</i> , <i>S. pluranimalium</i> , <i>S. zooepidemicus</i>); encephalomalacia (<i>E. hirae</i> , <i>E. durans</i>); cellulitis (<i>S. dysgalactiae</i>); sepsis (<i>E. faecium</i> , <i>S. pluranimalium</i>)	<i>Enterococcus</i> spp. <i>Streptococcus</i> spp.	III.56	
All species		Sudden death; palor; sinusitis; arthritis (amyloid); synovitis; osteomyelitis; dermatitis; omphalitis; septicemia; green liver; pneumonia; endocarditis; bumble foot	Staphylococcosis (<i>Staphylococcus aureus</i>)	III.57	
Chickens, turkeys, ducks, etc.		Clinical signs may vary greatly and lesions are not specific; yolk sac infections; sudden death; swelling of the head; diarrhea; arthritis; hepatitis, etc.	Pseudomoniasis (<i>Pseudomonas</i> spp.)	III.60	
All species		Septicemia; encephalitis; mortality (up to 40%); myocarditis; focal hepatic necrosis; nephritis; airsacculitis; salpingitis; enteritis; conjonctivitis	Listeriosis (<i>Listeria monocytogenes</i>)	III.61	
All species		Spinal cord compression (<i>Staphylococcus</i> spp. or <i>Enterococcus caecorum</i>)	Spinal osteomyelitis	IV.69	
Waterfowl		Respiratory disease; egg drop; caseous deposits in the uterus, meningitis	<i>Gallibacterium anatis</i>	VI.93	
Fungi		All species	Dyspnea; mortality; nodules (trachea, bronchi, lungs, air sacs); diarrhea; stunting; systemic infection with other localizations: brain, eye, skin, kidneys, etc.	Brooder pneumonia (<i>Aspergillus fumigatus</i>)	IV.62
		Chickens, turkeys, etc.	Nervous and pulmonary lesions similar to aspergillosis (but more malacia)	<i>Ochroconis gallopava</i>	IV.62
Parasites	Pigeons, turkeys, chickens, etc.	Anorexia; ruffled feathers; «oral canker» (yellow plaques or cheesy masses in buccal cavity, pharynx, esophagus and crop); systematic spread (liver)	Trichomoniasis (<i>Trichomonas gallinae</i>)	IV.67	
	All species	Presence of numerous cysts visible in skeletal and cardiac muscles; other locations: esophagus, brain, lung, liver	Sarcocystosis (<i>Sarcocystis</i> spp.)	IV.67	
	All species	Weakness, emaciation, diarrhea, ataxia progressing to death	<i>Toxoplasma</i> spp.	IV.67	
	All species	Severe anemia; mortality; splenomegaly; nephritis; occlusion of brain capillaries; parasites found in red blood cells	Avian malaria (<i>Plasmodium</i> spp.)	IV.67	

Tabl.108.1: Differential diagnosis of central nervous system diseases. Following sepsis, other bacteria can be localized in the central nervous system (*Salmonella* spp., *Mycoplasma* spp., etc.).

Differential diagnosis

108. NERVOUS & OCULAR DISEASES

Symptoms & lesions	Species affected	Main clinical signs & lesions	Etiology	Chap.		
OTHER NERVOUS DISEASES	Viral neuritis	Chickens, game birds, pigeons, etc	Severe respiratory disease (facial edema); nervous signs (torticollis, paralysis); mortality (up to 50%); egg drop	Newcastle disease (<i>Mesogenic paramyxovirus 1</i>)	II.19	
		Chickens (turkeys)	Neoplastic lymphoid infiltration and inflammation of nerves and central nervous system: paralysis of legs and wings; torticollis; paralysis and dilation of the crop; transient paralysis; blindness (ocular involvement)	Marek's disease Classical form (<i>Virulent Mardivirus</i>)	II.33	
		Turkeys, chickens, ducks, geese	Runting; pallor; abnormal feather development; lameness; atrophy of thymus and bursa; enlarged peripheral nerves (marginal); proventriculitis; enteritis; hepatomegaly; splenomegaly; other tumors (gonads, pancreas, kidneys, heart)	Reticuloendotheliosis (<i>Gammaretrovirus</i>)	II.35	
		Turkeys	8-10 week-old turkeys; mortality (up to 25%); enlarged marble spleen; tumors (liver, thymus, gonad, pancreas, kidney, intestine, lung, heart)	Lymphoproliferative disease (<i>Retrovirus</i>)	II.35	
		Muscovy ducks	Ducklings (< 5 weeks); lameness; poor feathering; diarrhea; hydropericarditis	Muscovy duck parvovirus	VI.86	
	Deficiencies or toxic	Poultry	Reduced growth rate; dermatitis; poor feathering; "curled toe" paralysis	Riboflavin deficiency	IV.71	
		Ducks, turkeys, geese, guinea fowls, etc.	Acute toxicity: diarrhea; ataxia; convulsions; liver enlarged with small necrotic and hemorrhagic foci; spleen, enlarged pancreas and kidney; atrophy of bursa; chronic intoxication: stunting, egg drop, decreased hatchability	Aflatoxicosis (<i>Aspergillus spp.</i>)	IV.63	
		Poultry	Loss of appetite and growth; weakness; paralysis; opisthotonos	Thiamin deficiency	IV.71	
		All species	Diarrhea; wet litter; egg drop; progressive muscular weakness; death; ascite; hydropericardium; right ventricular hypertrophy	Excess of salt	IV.71	
		Poultry	Nervous signs (ataxia); 2-3 week-old chicks; encephalomalacia	Nutritional encephalomalacia	IV.71	
		All species	Material retained in the gizzard; myocardial degeneration; nephrosis	Lead poisoning	V.79	
		All species	Opisthotonos; cerebro-cortical necrosis (inhibition of thiamine utilisation)	Excess Amprolium	V.79	
	OCULAR DISEASES	Virus	All species	Cutaneous form: nodular proliferative skin lesions progressing to thick scabs; diphtheritic form: upper digestive and respiratory tract lesions	Fowlpox (<i>Avipoxvirus</i>)	II.31
			All species	Respiratory signs (sinusitis, tracheitis, bronchitis, pneumonia, airsacculitis); conjunctivitis; enteritis; egg drop; ovarian regression; involution of the oviduct; mortality <5%	Low pathogenic avian influenza virus	II.18
Chickens (turkeys)			Neoplastic lymphoid infiltration and inflammation of nerves and central nervous system: paralysis of legs and wings; torticollis; paralysis and dilation of the crop; transient paralysis; blindness (ocular involvement)	Marek's disease Classical form (<i>Virulent Mardivirus</i>)	II.33	
Chickens, turkeys, quails, pheasants			1-3 week-old chicks; encephalomyelitis (ataxia, paralysis, opisthotonos, tremors); mortality from 25 to 50 %; cataract; egg drop (5 to 10%)	Avian encephalomyelitis (<i>Hepatovirus</i>)	II.23	
Waterfowl			Bloody greenish diarrhea; high mortality; conjunctivitis; esophagitis; widespread hemorrhages; intestinal annular bands; egg drop (25-40%); smaller spleen	Duck virus enteritis (<i>Anatid herpesvirus 1</i>)	VI.89	
Bacteria		All species	Septicemia; diarrhea; blindness; lameness; hepatitis; splenitis; pericarditis; arthritis; airsacculitis; typhlitis; omphalitis; peritonitis; oophoritis; meningitis	Paratyphoid salmonella (<i>Salmonella spp.</i>)	III.43	
		Turkeys, chickens	Anorexia; diarrhea; paralysis; opisthotonos; torticollis; blindness (white corneal opacity); typhlitis (white caseous casts); meningitis; omphalitis; hepatitis	Arizonosis (<i>S. enterica subsp. arizonae</i>)	III.44	
		Turkeys, chickens, other species	Colisepticemia localisations: meningitis, encephalitis, panophthalmitis	Meningitis, panophthalmitis (<i>Escherichia coli</i>)	III.45	
		Turkeys (Chickens)	High morbidity, low mortality (poult); foamy conjunctivitis; sinusitis; dyspnea; submandibular edema; stunting; tracheitis (distortion of tracheal rings)	Bordetellosis (<i>Bordetella avium</i>)	III.50	
		Turkeys, chickens, ducks, pigeons, etc.	Diarrhea; dyspnea; yellow-green droppings; lameness, conjunctivitis; granulomas: liver, spleen, lungs, heart, kidneys, joints; osteomyelitis	Yersiniosis (<i>Y. pseudotuberculosis</i>)	III.59	
		Chickens, turkeys, ducks, etc.	Clinical signs may vary greatly and lesions are not specific; yolk sac infections; sudden death; swelling of the head; diarrhea; arthritis; hepatitis, etc.	Pseudomoniasis (<i>Pseudomonas spp.</i>)	III.60	
Others		All species	Dyspnea; mortality; nodules (trachea, bronchi, lungs, air sacs); diarrhea; stunting; systemic infection with other localizations: brain, eye, skin, kidneys, etc.	Brooder pneumonia (<i>Aspergillus fumigatus</i>)	IV.62	
		All species	Ophthalmia; parasite in the nictitating membrane or conjunctival sacs	<i>Oxyspirura spp.</i>	IV.67	
		All species	Sinusitis; conjunctivitis; blepharitis	Excess ammonia	IV.74	
	All species	Hyperkeratosis (cornea, mouth, esophagus); nutritional nephropathy; ruffled feathers; corneal hyperkeratosis; nerve lesion; egg drop	Vitamin A deficiency	IV.71		

Tabl.108.2: Differential diagnosis of other nervous diseases and ocular diseases.

Symptoms & lesions	Species affected	Main clinical signs & lesions	Etiology	Chap.	
SEPTICEMIA	Virus	All species	Sudden onset (mortality up to 100%); egg drop; respiratory signs (sinusitis, facial swelling); hemorrhages; cyanosis; diarrhea; encephalitis; pancreatitis	Highly pathogenic avian influenza virus	II.18
		Chickens, game birds, pigeons, etc.	Sudden death with high mortality; hemorrhagic lesions in the intestinal tract; encephalitis	Newcastle disease (<i>Velogenic paramyxovirus 1</i>)	II.19
		Psittacines	Sudden death; acute bursal necrosis; chronic: dystrophic feathers, stunting; immunodepression (necrosis of bursa)	Psittacine beak and feather disease (<i>Circovirus</i>)	II.39
		Ducks, mule ducks	DHV 1: highly fatal (age < 4 weeks); opisthotonos; hepatitis; hemorrhages; pancreatitis; DHV 2 & 3 (age: 3-6 weeks): liver hemorrhages; swollen kidneys	Duck viral hepatitis (<i>Duck Astrovirus 1, 2 & 3</i>)	VI.90
	Bacteria	Psittacines, turkeys, ducks, etc.	Anorexia; lethargy; ruffled feathers; coughing; green droppings; loss of weight; egg drop; conjunctivitis; airsacculitis; pericarditis; enteritis; hepatitis; splenitis	Avian chlamydiosis (<i>Chlamydia psittaci</i>)	III.40
		Chickens, turkeys, game birds, etc.	Chronic respiratory disease; prostration; egg drop and poor egg quality; sinusitis; keratoconjunctivitis; airsacculitis; tenosynovitis, salpingitis	Chronic respiratory disease (<i>Mycoplasma gallisepticum</i>)	III.41
		Chickens, turkeys, etc.	Arthritis; synovitis; breast blisters; respiratory signs; egg drop (eggshell apex abnormalities); tenosynovitis; salpingitis; airsacculitis	Infectious synovitis (<i>Mycoplasma synoviae</i>)	III.41
		Chickens, turkeys, etc.	Anorexia, prostration; droopy wings; diarrhea; mortality (up to 100%); dyspnea; blindness; arthritis; nodules (heart, gizzard, pancreas, lung, etc.)	Pullorum disease (<i>S. Gallinarum-pullorum</i>)	I.3 III.42
		Fowls, turkeys	Pale and shrunken combs; egg drop; small nodular regressing ovarian follicles; hepatitis; oophoritis; salpingitis; white foci or nodules on testes	Fowl typhoid (<i>S. Gallinarum-pullorum</i>)	III.42
		All species	Septicemia; diarrhea; blindness; lameness; hepatitis; splenitis; pericarditis; arthritis; airsacculitis; typhlitis; omphalitis; peritonitis; oophoritis; meningitis	Paratyphoid salmonella (<i>Salmonella</i> spp.)	III.43
		Turkeys, chickens	Anorexia; diarrhea; paralysis; opisthotonos; torticollis; blindness (white corneal opacity); typhlitis (white caseous casts); meningitis; omphalitis; hepatitis	Arizonosis (<i>S. enterica</i> subsp. <i>arizonae</i>)	III.44
		Turkeys, chickens, etc.	Sudden death in birds in good conditions with full crops containing feed; hepatitis (bile staining and enlarged liver); gallbladder distension; splenomegaly	Acute colisepticemia (<i>Escherichia coli</i>)	III.45
		Turkeys, chickens, ducks, geese, etc.	Sudden death; septicemia; hemorrhages (heart, gizzard, abdominal fat); oophoritis; dermal necrosis; enlargement and necrosis of liver and spleen; peritonitis; egg drop	Acute fowl cholera (<i>Pasteurella multocida</i>)	III.46 VI.93
		Turkeys, chickens	Facial edema; egg drop and reduced hatchability; edema and consolidation of lungs, pleuritis; airsacculitis; peritonitis, pericarditis, enteritis, arthritis, meningitis	<i>Ornithobacterium rhinotracheale</i>	III.48
		Ducks, turkeys, chickens, etc.	Respiratory signs; greenish diarrhea; tremors; torticollis; mortality; septicemia; fibrinous perihepatitis; pericarditis; airsacculitis; meningitis; stunting	Duck septicemia (<i>Riemerella anatipestifer</i>)	III.49 VI.93
		Turkeys (Chickens)	High morbidity, low mortality (poult); foamy conjunctivitis; sinusitis; dyspnea; submandibular edema; stunting; tracheitis (distortion of tracheal rings)	Bordetellosis (<i>Bordetella avium</i>)	III.50
		Turkeys, chickens, etc.	Sudden death; purple color and turgescence of snood and dewlap, yellow-green diarrhea; mortality; septicemia: congestion or hemorrhages (petechiae); catarrhal enteritis; splenomegaly; valvular endocarditis; arthritis	Erysipelas (<i>Erysipelothrix rhusiopathiae</i>)	III.55
		Ducks, chickens, turkeys	Duckling sudden death syndrome; septicemia; splenomegaly; hepatomegaly; osteomyelitis; arthritis; vegetative valvular endocarditis	<i>Streptococcus</i> spp. (<i>Streptococcus gallolyticus</i>)	III.56
		Chickens, turkeys, etc.	Endocarditis; hepatic granulomas; arthritis; amyloidosis (liver, joints)	<i>Enterococcus faecalis</i>	III.56
		Chickens, turkeys, ducks	Valvular endocarditis (<i>E. faecium</i> , <i>E. hirae</i> , <i>E. durans</i> , <i>S. gallineus</i> , <i>S. pluranimalium</i> , <i>S. zooepidemicus</i>); encephalomalacia (<i>E. hirae</i> , <i>E. durans</i>); cellulitis (<i>S. dysgalactiae</i>); sepsis (<i>E. faecium</i> , <i>S. pluranimalium</i>)	<i>Enterococcus</i> spp. <i>Streptococcus</i> spp.	III.56
		All species	Sudden death; palor; sinusitis; arthritis (amyloid); synovitis; osteomyelitis; dermatitis; omphalitis; septicemia; green liver; pneumonia; endocarditis; bumble foot	Staphylococcosis (<i>Staphylococcus aureus</i>)	III.57
		Chickens, turkeys, ducks, etc.	Clinical signs may vary greatly and lesions are not specific; yolk sac infections; sudden death; swelling of the head; diarrhea; arthritis; hepatitis, etc.	Pseudomoniasis (<i>Pseudomonas</i> spp.)	III.60
		All species	Septicemia; encephalitis; mortality (up to 40%); myocarditis; focal hepatic necrosis; nephritis; airsacculitis; salpingitis; enteritis; conjunctivitis	Listeriosis (<i>Listeria monocytogenes</i>)	III.61
		All species	Anorexia; fever; depression; cyanosis of the head; anemia; marked enlargement and mottling of the spleen; hepatitis; nephritis; pericarditis	Spirochaetosis (<i>Borrelia anserina</i>)	III.61
	Turkeys, chickens	Osteomyelitis; septicemia; skin lesions	<i>Arcanobacterium pyogenes</i>	III.61	
	All species	Dead-in-shell embryos; weak chicks; arthritis; cellulitis; diarrhea; septicemia	<i>Aeromonas</i> spp.	III.61	
	All species	Dead-in-shell embryos; weak chicks or poults; septicemia; hepatitis; arthritis	<i>Acinetobacter</i> spp.	III.61	
	All species	Salpingitis, septicemia and/or pneumonia	<i>Gallibacterium</i> spp.	III.61	
All species	Yolk sac infection; septicemia, salpingitis, oophoritis, cellulitis; respiratory disease	<i>Proteus</i> spp.	III.61		

Tabl.109.1: Sudden deaths associated with viral or bacterial septicemia.

Differential diagnosis

109. SUDDEN DEATHS

Sudden deaths are observed in apparently healthy birds that do not show any warning signs, and feed is often present in the oral cavity and crop. These sudden deaths are encountered with septicemic conditions striking individual birds in flocks experiencing a high mortality rate (see Tabl.108.1). It may also be caused by nutritional problems or intoxications, cardiovascular disorders or pro-

blems related to the microenvironment of the birds. Finally, in some cases the cause of sudden death remains unknown (e.g., «flip-over»).

Sudden deaths should be differentiated from «pseudo-sudden death», which is when warning signs are present but not observed or missed by the poultry grower.

Symptoms & lesions	Species affected	Main clinical signs & lesions	Etiology	Chap.	
OTHER CAUSES OF SUDDEN DEATH	Nutrition or intoxication	All species	Muscle weakness; sudden death	Potassium deficiency	IV.71
		All species	Diarrhea; wet litter; egg drop; progressive muscular weakness; death; ascite; hydropericardium; right ventricular hypertrophy	Excess of salt	IV.71
		All species	Poor feathering; periocular and eyelids epidermitis; foodpad dermatitis	Biotin deficiency	IV.71
		Layers	Obesity; egg drop; mortality; pallor and sudden death (hemorrhages); large amount of fat in abdominal cavity and liver (yellow, friable and enlarged)	Fatty liver hemorrhagic syndrome	IV.71
		Poultry	Kidneys atrophied, distended ureters with uroliths, urate deposits; sudden death	Urolithiasis	IV.71
		All species	Inability of chicks to reach the water; watery diarrhea; renal damage; water refusal or water deprivation; coccidiosis; visceral urate deposition; etc.	Dehydration Water deprivation	I.9 IV.72
		All species	Material retained in the gizzard; myocardial degeneration; nephrosis; nervous signs	Lead poisoning	V.79
		All species	Asphyxia, cyanosis of featherless skin, pulmonary edema and subcapsular hemorrhages in the liver	Acute propane butane intoxication	V.79
	Vascular	Chickens, turkeys	Concentric heart hypertrophy; sudden death	Hypertrophic cardiomyopathy	IV.70
		Turkeys, ratites	Sudden death; carcasses pale; large amounts of blood in the abdominal cavity	Aortic rupture	IV.70 VI.100
		Turkeys	Sudden death syndrome in turkeys associated with perirenal hemorrhage	Perirenal hemorrhage	IV.70
	Parasites	Turkeys, chickens, quails, ducks, etc.	Yellow sulfur diarrhea; abnormal gait; typhlitis; hepatic lesions: necrotic foci in cockade with raised edges and a center depression	Histomoniasis (<i>Histomonas meleagridis</i>)	IV.66
		All species	Presence of numerous cysts visible in skeletal and cardiac muscles; other locations: esophagus, brain, lung, liver	Sarcocystosis (<i>Sarcocystis</i> spp.)	IV.67
	Others	All species	Hyperacute evolution or sudden death; suffocation	Heatstroke	I.7
		Chickens	Most birds (1 to 8 weeks of age) found dead on their back (flip-over); full digestive tract; liver enlarged, pale and friable; empty gallbladder	Sudden death syndrome in broiler chickens	IV.70
		Quails, chickens, etc.	Sudden deaths; depression; emaciation; watery droppings; deep ulcers (intestine, ceca); peritonitis; hemorrhages (liver, spleen); splenomegaly; hepatomegaly	Ulcerative enteritis (<i>Clostridium colinum</i>)	III.51 VI.96
		All species	Sudden death; depression; ruffled feathers; diarrhea; intestines distended (gas and foul fluid); fibrinonecrotic enteritis; cholangiohepatitis	Necrotic enteritis (<i>Clostridium</i> spp.)	III.51 VI.98
		Chickens	Decubitus; ataxia; orange mucoid diarrhea; hemorrhage and necrosis of the liver; mild enteritis; atrophy of bursa	Hypoglycemia-spiking mortality syndrome	IV.73

Tabl.109.2: Other causes of sudden deaths.

Symptoms & lesions	Species affected	Main clinical signs & lesions	Etiology	Chap.	
OVARY	Regression	All species	Respiratory signs (sinusitis, tracheitis, bronchitis, pneumonia, airsacculitis); conjunctivitis; enteritis; egg drop; ovarian regression; involution of the oviduct; mortality <5%	Low pathogenic avian influenza virus	II.18
		Turkeys, chickens, etc.	Swollen head syndrome; tracheitis; egg drop up to 70%; poor shell quality	Avian Metapneumovirus	II.20
		Fowls, quails	Drastic egg drop; abnormal eggs (thin-shelled, soft-shelled or shell-less eggs, rough surface) in apparently healthy birds; salpingitis; inactive ovaries	Egg drop syndrome (Atadenovirus)	II.26
		Pheasants, etc.	Encephalitis; increased mortality; egg drop (turkey breeders)	Eastern equine encephalitis	II.37
	Oophoritis	Fowls, turkeys	Pale and shrunken combs; egg drop; small nodular regressing ovarian follicles; hepatitis; oophoritis; salpingitis; white foci or nodules on testes	Fowl typhoid (S. Gallinarum-pullorum)	III.42
		Turkeys, chickens, other species	Egg drop; sporadic mortality; "egg peritonitis"; salpingitis; obstruction of oviduct; yolk peritonitis; oophoritis; epididymo-orchitis	Salpingitis, orchitis (Escherichia coli)	III.45
		Chickens, turkeys, ducks, etc.	Clinical signs may vary greatly and lesions are not specific; yolk sac infections; sudden death; swelling of the head; diarrhea; arthritis; hepatitis, etc.	Pseudomoniasis (Pseudomonas spp.)	III.60
		All species	Yolk sac infection; septicemia; salpingitis; oophoritis; cellulitis; respiratory disease	Proteus spp.	III.61
	Hemorrhages	All species	Sudden onset (mortality up to 100%); egg drop; respiratory signs (sinusitis, facial swelling); hemorrhages; cyanosis; diarrhea; encephalitis; pancreatitis	Highly pathogenic avian influenza virus	II.18
		Chickens, game birds, pigeons, etc.	Sudden death with high mortality; hemorrhagic lesions in the intestinal tract; encephalitis	Newcastle disease (Velogenic paramyxovirus 1)	II.19
		Turkeys	Paralysis (<10 weeks); mortality up to 80%; hemorrhagic ovary; egg drop	Turkey meningoencephalitis	II.37
		Turkeys, chickens, ducks, geese, etc.	Sudden death; septicemia; hemorrhages (heart, gizzard, abdominal fat); oophoritis; dermal necrosis; enlargement and necrosis of liver and spleen; peritonitis; egg drop	Acute fowl cholera (Pasteurella multocida)	III.46 VI.93
		Waterfowl	Bloody greenish diarrhea; high mortality; conjunctivitis; esophagitis; widespread hemorrhages; intestinal annular bands; egg drop (25-40%); smaller spleen	Duck virus enteritis (Anatid herpesvirus 1)	VI.89
		Ducks	Paralysis; severe egg drop; diarrhea; degenerate and hemorrhagic ovary	Tembusu virus infection	VI.92
	Tumor	Chickens (turkeys)	Depression, weight loss, diarrhea, diffuse or nodular lymphomas in visceral organs (liver, spleen, ovary, kidney, proventriculus, heart, bursa) and sometimes in the skin (feather follicles) and skeletal muscles	Marek's disease Acute form (Very virulent Mardivirus)	II.33
		Chickens	Depression, pallor, nodular or diffuse tumors of liver, spleen, bursa and other organs; skeletal tissues; subclinical infection without neoplastic lesions; egg drop	Lymphoid leukosis (Retrovirus ALV-A)	II.34
		Chickens	Diffuse myeloid leukosis: pallor; liver and spleen are enlarged and granular appearance of the liver; bursa sometimes tumorous; tumor infiltration of bone marrow; myeloblastic leukemia; other tumors (ovary, kidneys, bursa)	Myeloid leukosis Myeloblastosis (Retrovirus ALV-J)	II.34
		Chickens	Tumoral form of myeloid leukosis: diffuse nodular tumors of creamy-white colour; other tumors [ovary, kidneys, thymus, surface of bones (sternum, ribs, skull)]	Myelocytomatosis (Retrovirus ALV-J)	II.34
		Turkeys, chickens, ducks, geese	Runting; pallor; abnormal feather development; lameness; atrophy of thymus and bursa; enlarged peripheral nerves (marginal); proventriculitis, enteritis; hepatomegaly, splenomegaly; other tumors (gonads, pancreas, kidneys, heart)	Reticuloendotheliosis (Gammaretrovirus)	II.35
	OVIDUCT	Salpingitis	Turkeys, chickens, etc.	Swollen head syndrome; tracheitis; egg drop up to 70%; poor shell quality	Avian Metapneumovirus
Pheasants, etc.			Encephalitis; increased mortality; egg drop (turkey breeders)	Eastern equine encephalitis	II.37
Chickens			Conjunctivitis, tracheitis, pneumonia; nephritis (young birds); salpingitis (abnormalities of egg-shell and egg albumen); egg drop (>50%); false layers; enteritis	Infectious bronchitis (Coronavirus)	II.21
Chickens, turkeys, game birds, etc.			Chronic respiratory disease; prostration; egg drop and poor egg quality; sinusitis; keratoconjunctivitis; airsacculitis; tenosynovitis, salpingitis	Chronic respiratory disease (Mycoplasma gallisepticum)	III.41
Chickens, turkeys, etc.			Arthritis, synovitis; breast blisters; respiratory signs; egg drop (eggshell apex abnormalities); tenosynovitis; salpingitis; airsacculitis	Infectious synovitis (Mycoplasma synoviae)	III.41
Turkeys, chickens, other species			Egg drop; sporadic mortality; "egg peritonitis"; salpingitis; obstruction of oviduct; yolk peritonitis; oophoritis; epididymo-orchitis	Salpingitis, orchitis (Escherichia coli)	III.45
Chickens, turkeys, ducks			Valvular endocarditis (E. faecium, E. hirae, E. durans, S. gallineus, S. pluranimalium, S. zooepidemicus); encephalomalacia (E. hirae, E. durans); cellulitis (S. dysgalactiae); sepsis (E. faecium, S. pluranimalium)	Enterococcus spp. Streptococcus spp.	III.56
Chickens, turkeys, ducks, etc.			Clinical signs may vary greatly and lesions are not specific; yolk sac infections; sudden death; swelling of the head; diarrhea; arthritis; hepatitis, etc.	Pseudomoniasis (Pseudomonas spp.)	III.60
All species			Salpingitis, septicemia and/or pneumonia	Gallibacterium spp.	III.61
All species			Yolk sac infection; septicemia, salpingitis, oophoritis, cellulitis; respiratory disease	Proteus spp.	III.61

Tabl.110.1: Differential diagnosis of main ovarian and oviduct lesions. These lesions are also seen under septicemic diseases.

Differential diagnosis

110. REPRODUCTIVE SYSTEM

The differential diagnosis of disorders of the reproductive system is essentially relevant to breeders of all species and layers for some species like fowl and quail. For this reason, this differential diagnosis will focus essentially on mature females and lesions of their reproductive system, including eggs.

LESIONS OF REPRODUCTIVE SYSTEM

Ovary (see Tabl.110.1)

Ovary infections can be acute or chronic. The «baked» appearance of the ovary is characteristic of a chronic evolution.

Oviduct (see Tabl.110.2)

Hypoplasia of the oviduct is especially encountered in «false layers» infected early (by the infectious bronchitis virus). Incomplete development of the oviduct may be occasionally accompanied by large fluid filled cysts. Affected hens appear to have ascites and are exhibiting a penguin-like posture. This posture is also seen in cases of oviduct obstruction and yolk peritonitis.

Salpingitis is the main cause of egg production drop. It can be due to bacterial or viral infections. During a viral outbreak, the lining of the oviduct is edematous and congested with or without clinical signs or gelatinous exudate. A bacterial infection will result in the formation of fibrinopurulent exudate with the possibility of eggs being laid in the abdomen, leading to peritonitis.

Prolapse or eversion of the oviduct leading to cannibalism is seen particularly with cachectic or obese birds.

EGG PRODUCTION PROBLEMS

Egg drops

The definition of an egg drop is a sudden drop of egg production of at least 5%. It is important to be aware of target production values in order to be able to detect early a drop in egg production. Breeding companies regularly publish updates of these target values (see Fig.110.1).

Egg drop can be transitory (6-8% during 1-32 days) or serious (20-30% during one to several

weeks). When assessing an egg drop, one must take into account the mortality rate. For example, avian infectious bronchitis causes a significant drop in egg production but a low mortality rate. By contrast, the same egg drop can be observed due to a higher mortality rate in flocks infected with a velogenic strain of the Newcastle disease virus. It may also be difficult to determine whether an egg production loss involves most birds in a given flock, or whether only some hens are producing less or may have completely stopped laying eggs.

Multiple and possibly mixed causes of egg drops are:

- *Feed.* A transitory egg drop may occur in layers after a reduction in feed consumption (error in feed formulation, incorrectly adjusted feeders, contaminants).
- *Water.* Interruption or inadequate water supply (or alteration of water quality) can result in a serious drop in egg production.
- *Stress* (light below recommended intensity, heat stress, overstocking, pest and vermin, etc.).
- *Steatosis, viral and bacterial infections* (see Tabl.110.3)

Egg quality (see Chap.I.5)

Egg formation may be altered substantially depending on the lesions affecting the reproductive tract. For example, replication of some strains of infectious bronchitis virus in the magnum is associated with a defective and irregular deposit of albumin that also affects shell formation. The replication of Atadenovirus in the uterus will cause major shell deformities (e.g., soft shell or even no shell). Finally the eggshell apex abnormalities observed with *Mycoplasma synoviae* infection is caused by functional and/or ultrastructural defects in the oviduct, mainly located in the mammillary layer of the calcified zone.

REFERENCES

- Alcorn MJ. How to carry out a field investigation. In “*Poultry diseases*”, Ed. Pattison et al, Elsevier 2008, pp 24-38.
- Brugère-Picoux J & Lecoanet J. Les chutes de ponte ont de multiples causes. *Le Courrier Avicole*, 1980,36, n°780, 23-31.
- Majo N & Dolz R. Autopsie des volailles. Ed. du Point Vétérinaire, 2012, 82pp.
- Feberwee A et al. Induction of eggshell apex abnormalities by *Mycoplasma synoviae*: field and experimental studies. *Avian Pathol*, 2009, 38:77-85.

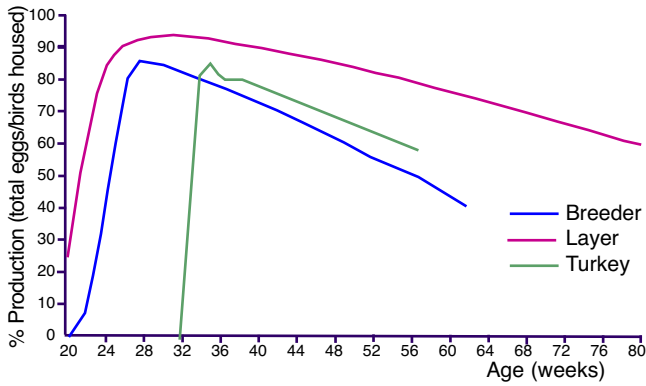


Fig. 110.1: Production figures for different laying flocks. Note the contrast in egg production numbers and persistence for a modern laying bird, broiler breeder and turkey breeder.

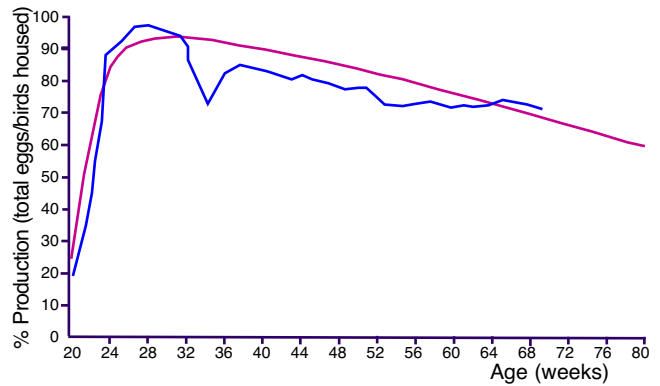


Fig. 110.2: Egg drop caused by an error in providing dietary calcium (CaCO_3 replaced by MgCO_3). This laying curve pattern is also observed with lighting failure or with a red mite infestation.

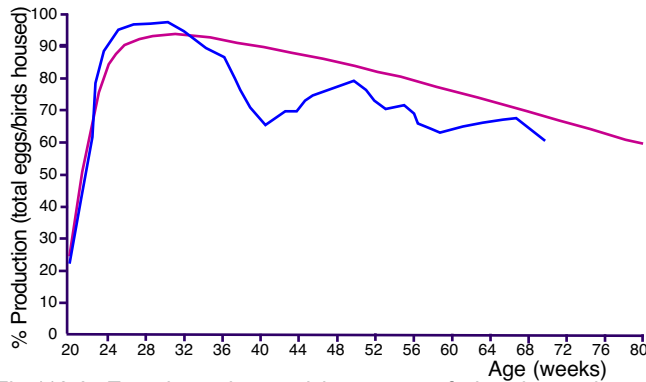


Fig. 110.3: Egg drop observed in a case of chronic respiratory disease (*Mycoplasma gallisepticum*).

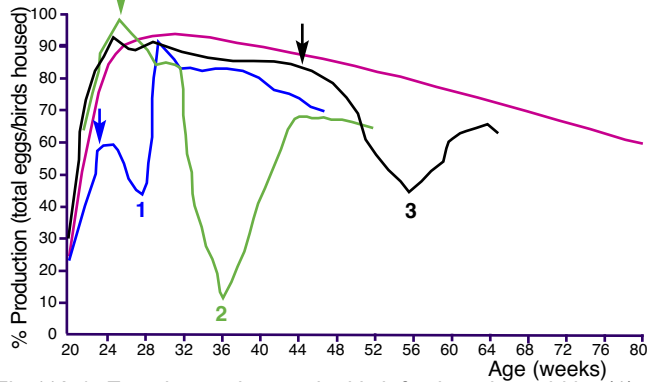


Fig. 110.4: Egg drops observed with infectious bronchitis; (1) at onset of lay; (2) at maximum of lay (same curve as for avian flu with a very high mortality); (3) in the middle of lay.

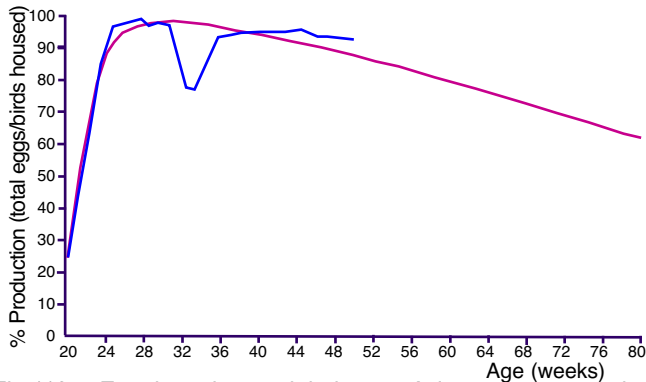


Fig. 110.5: Egg drop observed during an *Avian metapneumovirus* infection.

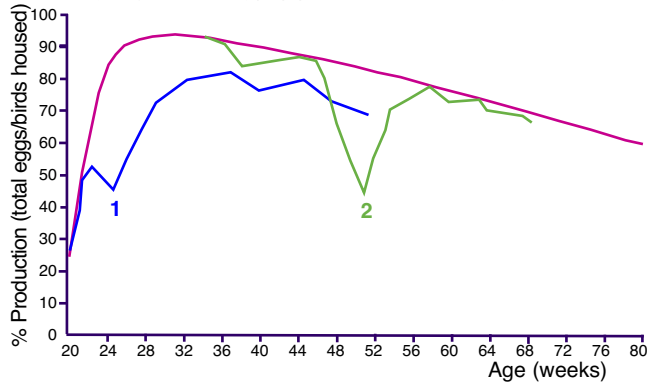


Fig. 110.6: Fig. 110.6: Egg drop observed with avian encephalomyelitis; (1) onset of lay (sudden fall, long and incomplete recovery); (2) during laying (moderate sudden V drop).

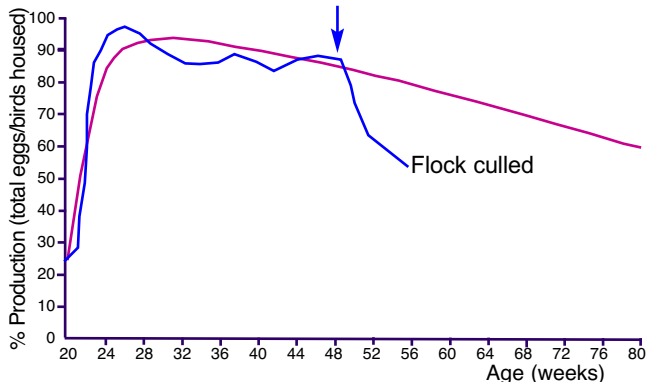


Fig. 110.7: Egg drop observed with salmonellosis resulting in the culling of the flock.

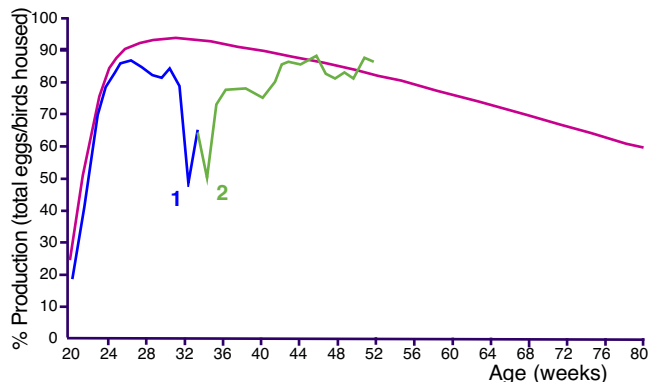


Fig. 110.8: Parasitosis of an "organic" flock (ascariasis); (1) first egg drop before treatment; (2) second egg drop: water consumption refusal due to the bitter taste of treated water (phytotherapy).

Symptoms & lesions	Species affected	Main clinical signs & lesions	Etiology	Chap.	
EGG DROP SYNDROME	Chronic	Chickens, turkeys, game birds, etc.	Chronic respiratory disease; prostration; egg drop and poor egg quality; sinusitis; keratoconjunctivitis; airsacculitis; tenosynovitis, salpingitis	Chronic respiratory disease (<i>Mycoplasma gallisepticum</i>)	III.41
		Chickens, turkeys, etc.	Arthritis, synovitis; breast blisters; respiratory signs; egg drop (eggshell apex abnormalities); tenosynovitis; salpingitis; airsacculitis	Infectious synovitis (<i>Mycoplasma synoviae</i>)	III.41
		Fowls, turkeys	Pale and shrunken combs; egg drop; small nodular regressing ovarian follicles; hepatitis; oophoritis; salpingitis; white foci or nodules on testes	Fowl typhoid (<i>S. Gallinarum-pullorum</i>)	III.42
		Turkeys, chickens, other species	Egg drop; sporadic mortality; «egg peritonitis»; salpingitis; obstruction of oviduct; yolk peritonitis; oophoritis; epididymo-orchitis	Salpingitis, orchitis (<i>Escherichia coli</i>)	III.45
		All species	Chronic disease; progressive emaciation; pallor; diarrhea; lameness; granuloma: lesion triad «liver, spleen, intestine» bone marrow, ovary, teste, heart, skin, lung	Tuberculosis (<i>Mycobacterium avium</i>)	III.54
		All species	End of laying period (physiological)	Physiology	I.10
		All species	Aflatoxicosis, ochratoxicosis, ergotism & trichothecene poisoning	Mycotoxins	IV.63
		All species	Inability of chicks to reach the water; watery diarrhea; renal damage; water refusal or water deprivation; coccidiosis; visceral urate deposition; etc.	Dehydration Water deprivation	I.9 IV.72
	5-15%	Chickens, pheasants, peafowls	Mild tracheitis with unthriftiness; egg drop (5-15%) without change in eggshell quality; conjunctivitis; sinusitis	Mild form of laryngotracheitis (<i>Iltovirus</i>)	II.22
		Chickens, turkeys, quails, pheasants	1-3 week-old chicks; encephalomyelitis (ataxia, paralysis, opisthotonos, tremors); mortality from 25 to 50%; cataract; egg drop (5 to 10%)	Avian encephalomyelitis (<i>Hepatovirus</i>)	II.23
		Pheasants, etc.	Encephalitis; increased mortality; egg drop (turkey breeders)	Eastern equine encephalitis	II.37
		Turkeys	Paralysis (<10 weeks); mortality up to 80%; hemorrhagic ovary; egg drop	Turkey meningoencephalitis	II.37
		Chickens	Pallor; sudden deaths; egg drop (up to 20%); abnormal eggs; clotted blood in the abdominal cavity and/or on the liver; hepatitis; spleens enlarged and pale	Hepatitis E (<i>Hepevirus</i>)	II.38
		Turkeys	High morbidity; depression; mortality (age<6 weeks); egg drop; mucoid droppings; intestines filled with watery material and gas; bursa atrophied	Turkey Coronavirus (<i>Coronavirus</i>)	II.36
		Chickens, turkeys, ducks, etc.	Chronic diarrhea (brownish-yellow, frothy and/or mucoid droppings); egg drop (eggs of poor quality); stunting; dilated ceca (foamy & watery content)	Avian intestinal spirochetosis (<i>Brachyspira</i> spp.)	III.58
		All species	Abrupt egg drop; reduced egg size; cannibalism	Sodium deficiency	IV.71
		Poultry	Nervousness; pecking; stress; aggression; egg drop; stunting; anemia; bloodstains eggs; mortality	Poultry red mite (<i>Dermanyssus gallinae</i>)	IV.68
		All species	Nervousness; egg drop; stunting; anemia	Northern fowl mite	IV.68
		All species	Paralysis (fracture or displacement of vertebra); bone fragility (fractures); regressive ovaries; egg drop; shelled-egg partially calcified; enlarged parathyroid glands	Osteoporosis "Cage layer fatigue"	IV.69
		All species	Lameness; stunting; beaks, claws and bones soft and flexible; enlarged joints («rickety beads»); thin or soft-shelled eggs; egg drop; decrease in hatchability	Rickets Osteomalacia	IV.69 IV.71
		All species	Hyperkeratosis (cornea, mouth, esophagus); nutritional nephropathy; ruffled feathers; corneal hyperkeratosis; nerve lesion; egg drop	Vitamin A deficiency	IV.71
	>15%	All species	Sudden onset (mortality up to 100%); egg drop; respiratory signs (sinusitis, facial swelling); hemorrhages; cyanosis; diarrhea; encephalitis; pancreatitis	Highly pathogenic avian influenza virus	II.18
		Chickens, game birds, pigeons, etc	Sudden death with high mortality; hemorrhagic lesions in the intestinal tract; encephalitis	Newcastle disease (<i>Velogenic paramyxovirus 1</i>)	II.19
		All species	Respiratory signs (sinusitis, tracheitis, bronchitis, pneumonia, airsacculitis); conjunctivitis; enteritis; egg drop; ovarian regression; involution of the oviduct; mortality <5%	Low pathogenic avian influenza virus	II.18
		Turkeys, chickens, ducks, etc.	Swollen head syndrome; tracheitis; egg drop up to 70%; poor shell quality	Metapneumovirus	II.20 VI.97
		Chickens	Conjunctivitis, tracheitis, pneumonia; nephritis (young birds); salpingitis (abnormalities of egg-shell and egg albumen); egg drop (>50%); false layers; enteritis	Infectious bronchitis (<i>Coronavirus</i>)	II.21
		Fowls, quails	Drastic egg drop; abnormal eggs (thin-shelled, soft-shelled or shell-less eggs, rough surface) in apparently healthy birds; salpingitis; inactive ovaries	Egg drop syndrome (<i>Atadenovirus</i>)	II.26
		Partridges, turkeys	Drowsiness; ruffled feathers; severe egg drop; high mortality (poults)	Highlands J virus	II.37
		Chickens, pheasants, quails, etc.	Facial swelling; mortality; egg drop (up to 87%); conjunctivitis; tracheitis; pneumonia; airsacculitis; hepatitis; endocarditis; salpingitis; oophoritis; peritonitis; synovitis	Infectious coryza (<i>Avibacterium paragallinarum</i>)	III.47
		Turkeys, chickens	Facial edema; egg drop and reduced hatchability; edema and consolidation of lungs, pleuritis; airsacculitis; peritonitis; pericarditis; enteritis; arthritis; meningitis	<i>Ornithobacterium rhinotracheale</i>	III.48
		All species	Pruritus, skin irritation and injury causing various lesions (loss of feathers, crusts, excoriations); stunting; egg drop (up to 40%); mortality	Lice	IV.68
		Layers	Obesity; egg drop; mortality; pallor and sudden death (hemorrhages); large amount of fat in abdominal cavity and liver (yellow, friable and enlarged)	Fatty liver hemorrhagic syndrome	IV.71
		Waterfowl	Bloody greenish diarrhea; high mortality; conjunctivitis; esophagitis; widespread hemorrhages; intestinal annular bands; egg drop (25-40%); smaller spleen	Duck virus enteritis (<i>Anatid herpesvirus 1</i>)	VI.89
Ducks	Paralysis; severe egg drop; diarrhea; degenerate and hemorrhagic ovary	Tembusu virus infection	VI.92		
Waterfowl	Respiratory disease; egg drop; caseous deposits in the uterus; meningitis	<i>Gallibacterium anatis</i>	VI.93		

Tabl.110.2: Differential diagnosis of sudden drop in egg production. Other causes of drop in egg production are related to diseases leading to a reduction in feed consumption.

Symptoms & lesions	Species affected	Main clinical signs & lesions	Etiology	Chap.	
RENAL TUMORS	Neoplasia	Chickens (turkeys)	Depression, weight loss, diarrhea, diffuse or nodular lymphomas in visceral organs (liver, spleen, ovary, kidney, proventriculus, heart, bursa) and sometimes in the skin (feather follicles) and skeletal muscles	Marek's disease Acute form (<i>Very virulent Mardivirus</i>)	II.33
		Chickens	Depression, pallor, nodular or diffuse tumors of liver, spleen, bursa and other organs; skeletal tissues; subclinical infection without neoplastic lesions; egg drop	Lymphoid leukosis (<i>Retrovirus ALV-A</i>)	II.34
		Chickens	Diffuse myeloid leukosis: pallor; liver and spleen are enlarged and granular appearance of the liver; bursa sometimes tumorous; tumor infiltration of bone marrow; myeloblastic leukemia; other tumors (ovary, kidneys, bursa)	Myeloid leukosis Myeloblastosis (<i>Retrovirus ALV-J</i>)	II.34
		Chickens	Solid sheets of relatively immature myelocytes	Renal myelocytoma	II.34
		Chickens	Tumors (skin or visceral organs); blood-filled cystic masses or solid tumors	Renal hemangioma	II.34
		Turkeys	8-10 week-old turkeys; mortality (up to 25%); enlarged marble spleen; tumors (liver, thymus, gonad, pancreas, kidney, intestine, lung, heart)	Lymphoproliferative disease (<i>Retrovirus</i>)	II.35
		Turkeys, chickens, ducks, geese	Runting; pallor; abnormal feather development; lameness; atrophy of thymus and bursa; enlarged peripheral nerves (marginal); proventriculitis, enteritis; hepatomegaly; splenomegaly; other tumors (gonads, pancreas, kidneys, heart)	Reticuloendotheliosis (<i>Gammaretrovirus</i>)	II.35
		All species	Nephroblastoma; tubular adenoma; adenocarcinoma	Other renal tumors	
NEPHRITIS	Viral diseases	All species	Sudden onset (mortality up to 100%); egg drop; respiratory signs (sinusitis, facial swelling); hemorrhages; cyanosis; diarrhea; encephalitis; pancreatitis	Highly pathogenic avian influenza virus	II.18
		Chickens, game birds, pigeons, etc	Sudden death with high mortality; hemorrhagic lesions in the intestinal tract; encephalitis	Newcastle disease (<i>Velogenic paramyxovirus 1</i>)	II.19
		Chickens	Conjunctivitis; tracheitis; pneumonia; nephritis (young birds); salpingitis (abnormalities of egg-shell and egg albumen); egg drop (>50%); false layers; enteritis	Infectious bronchitis (<i>Coronavirus</i>)	II.21
		Geese, ducks and other species	Weakness; incoordination; fatal encephalitis; myocarditis	West Nile virus (<i>Flavivirus</i>)	II.37
		Chickens	Transient diarrhea; stunting; nephritis with urate deposits	Avian nephritis (<i>Aviastrovirus</i>)	II.39
		Psittacines	Nervous signs and/or gastrointestinal signs; dilatation of the proventriculus; encephalomyelitis; myocarditis; adrenalitis; chorioretinitis	Proventricular dilation disease (<i>Avian Bornavirus</i>)	II.39
		Psittacines	Sudden death; hepatosplenomegaly; hemorrhages (heart, intestine, liver)	Polyomavirus infections	II.39
		Geese, Muscovy ducks	Mortality (up to 60%); older birds: hepatitis; nephritis; ascites; intestinal edema; lameness; diarrhea; splenomegaly; poor feathering	Derszy's disease (<i>Parvovirus</i>)	VI.87
	Geese	Mortality (up to 80%); locomotor problems; hemorrhagic diarrhea (sometimes); nephritis; ascites; urate deposits in viscera and joints (chronic form)	Hemorrhagic nephritis enteritis (<i>Polyomavirus</i>)	VI.88	
	Bacterial diseases	Psittacines, turkeys, ducks, etc.	Anorexia; lethargy; ruffled feathers; coughing; green droppings; loss of weight; egg drop; conjunctivitis; airsacculitis; pericarditis; enteritis; hepatitis; splenitis	Avian chlamydiosis (<i>Chlamydia psittaci</i>)	III.40
		Turkeys, chickens, etc.	Sudden death in birds in good conditions with full crops containing feed; hepatitis (bile staining and enlarged liver); gallbladder distension; splenomegaly	Acute colisepticemia (<i>Escherichia coli</i>)	III.45
		Chickens, turkeys, ducks	Valvular endocarditis (<i>E. faecium</i> , <i>E. hirae</i> , <i>E. durans</i> , <i>S. gallineus</i> , <i>S. pluranimalium</i> , <i>S. zooepidemicus</i>); encephalomalacia (<i>E. hirae</i> , <i>E. durans</i>); cellulitis (<i>S. dysgalactiae</i>); sepsis (<i>E. faecium</i> , <i>S. pluranimalium</i>)	<i>Enterococcus</i> spp. <i>Streptococcus</i> spp.	III.56
		Ducks, chickens, turkeys, pigeons	Duckling sudden death syndrome; septicemia; splenomegaly; hepatomegaly; osteomyelitis; arthritis; vegetative valvular endocarditis	<i>Streptococcus</i> spp. (<i>Streptococcus gallolyticus</i>)	III.56 VI.99
		Chickens, turkeys, ducks, etc.	Clinical signs may vary greatly and lesions are not specific; yolk sac infections; sudden death; swelling of the head; diarrhea, arthritis; hepatitis, etc.	Pseudomoniasis (<i>Pseudomonas</i> spp.)	III.60
	Abscess	All species	Septicemia; diarrhea; blindness; lameness; hepatitis; splenitis; pericarditis; arthritis; airsacculitis; typhlitis; omphalitis; peritonitis; oophoritis; meningitis	Paratyphoid salmonella (<i>Salmonella</i> spp.)	III.43
All species		Sudden death; palor; sinusitis; arthritis (amyloid); synovitis; osteomyelitis; dermatitis; omphalitis; septicemia; green liver; pneumonia; endocarditis; bumble foot	Staphylococcosis (<i>Staphylococcus aureus</i>)	III.57	
Turkeys, chickens, ducks, pigeons, etc.		Diarrhea; dyspnea; yellow-green droppings; lameness; conjunctivitis; granulomas: liver, spleen, lungs, heart, kidneys, joints; osteomyelitis	Yersiniosis (<i>Y. pseudotuberculosis</i>)	III.59 VI.93	

Tabl.111.1: Differential diagnosis of renal tumors, nephritis and abscesses in kidneys.

Differential diagnosis

111. URINARY DISORDERS

Differential diagnosis of disorders of the urinary system is often difficult, in particular in the case of nephritis or visceral urate deposition. Indeed, if there are diseases caused by pathogenic agents with renal tropism (e.g., infectious bronchitis virus or avian nephritis virus), kidney damage is most

often secondary to a systemic disease (septicemia) or accompanied with a hemorrhagic syndrome. It can also be a nephrosis due to a dysfunction of the urinary system (e.g., inadequate intake of water leading to urolithiasis, nephritis and visceral urate deposition).

Symptoms & lesions	Species affected	Main clinical signs & lesions	Etiology	Chap.	
VISCERAL URATE DEPOSITION	Fungal diseases & mycotoxicosis	All species	Dyspnea; mortality; nodules (trachea, bronchi, lungs, air sacs); diarrhea; stunting; systemic infection with other localizations: brain, eye, skin, kidneys, etc.	Brooder pneumonia (<i>Aspergillus fumigatus</i>)	IV.62
		Ducks, turkeys, geese, guinea fowls, etc.	Acute toxicity: diarrhea; ataxia; convulsions; liver enlarged with small necrotic and hemorrhagic foci; enlarged spleen, pancreas and kidney; atrophy of bursa; chronic intoxication: stunting; egg drop, decreased hatchability	Aflatoxicosis (<i>Aspergillus</i> spp.)	IV.63
		Ducks, turkeys, geese, etc.	Acute intoxication: tremors; mortality (up to 50%); nephrosis; liver (pale); egg drop; chronic intoxication: stunting; renal failure (urate deposits)	Ochratoxicosis (<i>Aspergillus, Penicillium</i>)	IV.63
	Nephrosis or nephritis	Chickens	Conjunctivitis; tracheitis; pneumonia; nephritis (young birds); salpingitis (abnormalities of egg-shell and egg albumen); egg drop (>50%); false layers; enteritis	Infectious bronchitis (<i>Coronavirus</i>)	II.21
		Chickens	Acute form: vent pecking; diarrhea; mortality (10-90%); inflammation of bursa swollen early and atrophied later; petechial hemorrhages (muscles, liver); kidney with urate deposits; milder form: immunodepression	Gumboro disease (<i>Avibirnavirus</i>)	II.32
		Chickens	Poor growth; scabs around eyes and beak; chondrodystrophy; sudden death; lipid infiltrations of the liver, kidneys and heart	Fatty liver and kidney syndrome in broiler chicks	IV.71
		All species	Watery diarrhea; weakness; cerebellar edema; hepatotoxicity; feather loss	Excess organic selenium	IV.71
		All species	Urate precipitation: kidneys, heart, liver, mesenteries, air sacs, peritoneum, muscles, synovial sheaths, spleen	Visceral urate deposition (visceral gout)	IV.71
		All species	Material retained in the gizzard; myocardial degeneration; nephrosis; nervous signs	Lead poisoning	V.79
	OTHER RENAL LESIONS	Congestion or hemorrhages	All species	Sudden onset (mortality up to 100%); egg drop; respiratory signs (sinusitis, facial swelling); hemorrhages; cyanosis; diarrhea; encephalitis; pancreatitis	Highly pathogenic avian influenza virus
Chickens, game birds, pigeons, etc			Sudden death with high mortality; hemorrhagic lesions in the intestinal tract; encephalitis	Newcastle disease (<i>Velogenic paramyxovirus 1</i>)	II.19
Geese			Mortality (up to 80%); locomotor problems; hemorrhagic diarrhea (sometimes); nephritis; ascites; urate deposits in viscera and joints (chronic form)	Hemorrhagic nephritis enteritis (<i>Polyomavirus</i>)	VI.88
Waterfowl			Bloody greenish diarrhea; high mortality; conjunctivitis; esophagitis; widespread hemorrhages; intestinal annular bands; egg drop (25-40%); smaller spleen	Duck virus enteritis (<i>Anatid herpesvirus 1</i>)	VI.89
Ducks, mule ducks			DHV 1: highly fatal (age<4 weeks); opisthotonos; hepatitis; hemorrhages; pancreatitis; DHV 2 & 3 (age: 3-6 weeks): liver hemorrhages; swollen kidneys	Duck viral hepatitis (DHV 1, 2 & 3)	VI.90
Turkeys			Sudden death syndrome in turkeys associated with perirenal hemorrhages	Perirenal hemorrhages	IV.70
Parasites		Chickens, turkeys, quails, etc.	Respiratory form: sinusitis, bronchopneumonia, airsacculitis; gastrointestinal form: diarrhea, stunting; renal form: kidneys enlarged and pale, urate deposits	Cryptosporidiosis (<i>Cryptosporidium</i> spp.)	IV.65
		All species	Severe anemia; mortality; splenomegaly; nephritis; occlusion of brain capillaries; parasites found in red blood cells	Avian malaria (<i>Plasmodium</i> spp.)	IV.67
		Geese	Renal coccidiosis	Coccidiosis (<i>Eimeria truncata</i>)	VI.94

Tabl.111.2: Differential diagnosis of other renal lesions with or without visceral urate deposition.

Symptoms & lesions	Species affected	Main clinical signs & lesions	Etiology	Chap.	
ABNORMAL FEATHERING, FEATHER LOSS, INJURIES, etc.	Cannibalism, burns, etc.	All species	Inability of chicks to reach the water; watery diarrhea; renal damage; water refusal or water deprivation; coccidiosis; visceral urate deposition; <i>etc.</i>	Dehydration Water deprivation	I.9 IV.72
		All species	Excess temperature of barn or brooder; burns; loss of feathers	Burns, excess heat	I.7
		All species	Behavior disorder not associated with a specific disease; overcrowding; persecution or feather pecking of sick or deficient birds	Cannibalism	I.9
		Poultry	Severe beak trimming or toe trimming	Impaired interventions	I.9
	Nutrition & intoxication	Ducks, turkeys, geese, guinea fowls, <i>etc.</i>	Acute intoxication: diarrhea; necrotic lesions (oral mucosa, gastrointestinal tract); chronic poisoning: stunting; abnormalities of feathering; egg drop; hepatitis; immunodepression (atrophy of bursa)	Trichothecene poisoning (<i>Fusarium spp.</i>)	IV.63
		Chickens	Stunting; egg drop; nervous incoordination; abnormal feather development; enteritis; necrosis of extremities (beak, comb, toes)	Ergotism (<i>Claviceps purpurea</i>)	
		All species	Lameness; stunting; beaks, claws and bones soft and flexible; enlarged joints («rickety beads»); thin or soft-shelled eggs; egg drop; decrease in hatchability	Rickets Osteomalacia	IV.69 IV.71
		All species	Watery diarrhea; weakness; cerebellar edema; hepatotoxicity; feather loss	Excess organic selenium	IV.71
		Poultry	Reduced growth rate; dermatitis; poor feathering; «curled toe» paralysis	Riboflavin deficiency	IV.71
		All species	Poor growth; poor feathering; scaly skin; chondrodystrophy; egg drop	Zinc deficiency	IV.71
		All species	Poor feathering, periocular and eyelids epidermitis, foodpad dermatitis	Biotin deficiency	IV.71
		All species	Dermatitis (beak, eyelids, vent, feet) and feather loss	Pantothenic acid deficiency	IV.71
		All species	Abrupt egg drop; decreased egg size; cannibalism	Sodium deficiency	IV.71
		Turkeys, chickens, <i>etc.</i>	Dermatitis (plantar footpad); hyperkeratosis; necrose; ulcers; pain	Contact dermatitis	IV.71
		All species	Hyperkeratosis (cornea, mouth, esophagus); nutritional nephropathy; ruffled feathers, corneal hyperkeratosis; nerve lesion; egg drop	Vitamin A deficiency	IV.71 VI.100
		Virus	Chickens	Pale birds; stunting; abnormal feathering (helicopter wings); femoral head fractures; immunodepression; orange diarrhea, enlarged proventriculus	Enteritic problems (<i>Reovirus</i>)
	Chickens		Depression; stunting; poor feathering; diarrhea, osteoporosis; bone deformation, intestine and ceca are pale distended with mucus, gas and fluid feces	Runting stunting syndrome (<i>Chicken parvovirus</i>)	II.28
	Turkeys		Depression; stunting; poor feathering; diarrhea; osteoporosis; bone deformation; intestine and ceca are pale distended with mucus, gas and fluid feces	Poult enteritis complex (<i>Turkey parvovirus</i>)	II.28 IV.72
	Turkeys, chickens, ducks, geese, <i>etc.</i>		Runting; pallor; abnormal feather development; lameness; atrophy of thymus and bursa; enlarged peripheral nerves (marginal); proventriculitis, enteritis; hepatomegaly, splenomegaly; other tumors (gonads, pancreas, kidneys, heart)	Reticuloendotheliosis (<i>Gammaretrovirus</i>)	II.34 II.35
	Muscovy ducks		Ducklings (< 5 weeks); lameness; bad feathering; diarrhea; hydropericarditis	Muscovy duck parvovirus	VI.86
	Mule ducks		Short-beaked dwarfism syndrome (SBDS); growth retardation; deformities and fractures of long bones; splenomegaly; intestinal edema	SBDS Derszy's disease (<i>Parvovirus</i>)	VI.87
	Waterfowl		Growth retardation; feathering disorders; immunodepression	Duck or geese circovirus	VI.91
	Bac-teria	Turkeys, chickens	Reduction of hatchability (5-20%); airsacculitis; feather abnormalities and leg deformities	Mycoplasmosis (<i>Mycoplasma iowae</i>)	III.41
	Parasites	All species	Pruritus, skin irritation and injury causing various lesions (loss of feathers, crusts, excoriations), stunting; egg drop (up to 40%); mortality	Lice	IV.68
		Poultry	Nervousness; pecking; stress; aggression; egg drop; stunting; anemia; bloodstained eggs; mortality	Poultry red mite (<i>Dermanyssus gallinae</i>)	IV.68
		All species	Nervousness; egg drop; stunting; anemia	Northern fowl mite (<i>Ornithonyssus sylviarum</i>)	IV.68
		All species	Scaly, thickened and wrinkled skin	Depluming mite (<i>Neocnemidocoptes gallinae</i>)	IV.68
		All species	Skin thickened and hyperkeratotic with crusts; legs and claws gradually deform, causing lameness; beak lesions	Scaly leg mite (<i>Knemidocoptes mutans</i>)	IV.68
		Ratites	Feather lice	<i>Struthiolipeuris spp.</i>	VI.100

Tabl.112.1: Differential diagnosis abnormal feathering, feather loss, injuries, *etc.*

Differential diagnosis

112. SKIN & FEATHER DISEASES

Skin and feather diseases can be indicative of different problems in the farm (virus, bacteria, parasites, malnutrition, intoxication, *etc.*). It can also be a significant poultry welfare problem when these conditions are accompanied by pain or behavioral problems, including cannibalism.

Differential diagnosis of skin and feather diseases must consider natural processes occurring in mature layers upon completion of a laying cycle (molting, replacement of older feathers by new ones). Finally, ruffled feathers or pallor of the skin can be seen in many diseases and are not specific.

Symptoms & lesions	Species affected	Main clinical signs & lesions	Etiology	Chap.	
LOCALIZED SKIN DISEASES	Omphalitis	All species	Septicemia; diarrhea; blindness; lameness; hepatitis; splenitis; pericarditis; arthritis; airsacculitis; typhlitis; omphalitis; peritonitis; oophoritis; meningitis	Paratyphoid salmonella (<i>Salmonella</i> spp.)	III.43
		Turkeys, chickens, <i>etc.</i>	Yolk sac infection; omphalitis (abdominal distention, high mortality, mushy chick disease); septicemia; peritonitis; oophoritis or salpingitis in breeders	Omphalitis (<i>Escherichia coli</i>)	III.45
		Chickens, turkeys	Depression; lameness; reddened moist skin; emphysematous or serosanguineous cellulitis; petechial hemorrhages; gas; «bubble tails»; foul odor	Gangrenous dermatitis (<i>Clostridium</i> spp., <i>S. aureus</i>)	III.51 III.57
		Chickens, turkeys, ducks	Valvular endocarditis (<i>E. faecium</i> , <i>E. hirae</i> , <i>E. durans</i> , <i>S. gallineus</i> , <i>S. pluranimalium</i> , <i>S. zooepidemicus</i>); encephalomalacia (<i>E. hirae</i> , <i>E. durans</i>); cellulitis (<i>S. dysgalactiae</i>); sepsis (<i>E. faecium</i> , <i>S. pluranimalium</i>)	Enterococcus spp. Streptococcus spp.	III.56
		Chickens, turkeys, ducks, geese, <i>etc.</i>	Sudden death; palor; sinusitis; arthritis (amyloid); synovitis; osteomyelitis; dermatitis; omphalitis; septicemia; green liver; pneumonia; endocarditis; bumble foot	Staphylococcosis (<i>Staphylococcus aureus</i>)	III.57
		Chickens, turkeys, ducks, <i>etc.</i>	Clinical signs may vary greatly and lesions are not specific; yolk sac infections; sudden death; swelling of the head; diarrhea, arthritis; hepatitis, <i>etc.</i>	Pseudomoniasis (<i>Pseudomonas</i> spp.)	III.60
		Turkeys, chickens	Osteomyelitis; septicemia; skin lesions	<i>Arcanobacterium pyogenes</i>	III.61
		All species	Yolk sac infection; septicemia; salpingitis; oophoritis; cellulitis; respiratory disease	<i>Proteus</i> spp.	III.61
	Sternal bursitis	Chickens, turkeys, <i>etc.</i>	Arthritis; synovitis; breast blisters; respiratory signs; egg drop (eggshell apex abnormalities); tenosynovitis; salpingitis; airsacculitis	Infectious synovitis (<i>Mycoplasma synoviae</i>)	III.41
		Turkeys	Reduced egg hatchability; sinusitis; airsacculitis; poor growth; helicopter feathering; skeletal abnormalities (osteomyelitis, osteodystrophy)	Mycoplasmosis (<i>Mycoplasma meleagridis</i>)	III.41
		Turkeys, chickens, <i>etc.</i>	Cellulitis (serosanguineous to caseated, fibrinoheterophilic exudate in subcutaneous tissues); swollen head syndrome; other colibacillosis lesions	Cellulitis (<i>Escherichia coli</i>)	III.45
	Pododermatitis	All species	Sudden death; palor; sinusitis; arthritis (amyloid); synovitis; osteomyelitis, dermatitis; omphalitis; septicemia; green liver; pneumonia; endocarditis; bumble foot	Staphylococcosis (<i>Staphylococcus aureus</i>)	III.57
		Chickens, turkeys, ducks, <i>etc.</i>	Clinical signs may vary greatly and lesions are not specific; yolk sac infections; sudden death; swelling of the head; diarrhea; arthritis; hepatitis, <i>etc.</i>	Pseudomoniasis (<i>Pseudomonas</i> spp.)	III.60
		Turkeys, chickens	Osteomyelitis; septicemia; skin lesions	<i>Arcanobacterium pyogenes</i>	III.61
		All species	Local injury to integument of the footpad; lameness and reluctance to move; complications: sternal bursitis, arthritis, osteomyelitis and/or tendinitis	Pododermatitis	IV.69
		Turkeys, chickens, <i>etc.</i>	Dermatitis (plantar footpad); hyperkeratosis; necrose; ulcers; pain	Contact dermatitis	IV.71 IV.74
	Other	Broiler chickens	Superficial ulceration and scabbing of skin on the thighs; multifactorial problem: poor feathering, high stocking density, poor litter	Scabby hip syndrome	

Tabl.112.2: Differential diagnosis of some localized skin diseases.

Symptoms & lesions	Species affected	Main clinical signs & lesions	Etiology	Chap.	
SKIN & SUBCUTANEOUS DISORDERS	Congestion, cyanosis, hemorrhages, etc.	All species	Sudden onset (mortality up to 100%); egg drop; respiratory signs (sinusitis, facial swelling); hemorrhages; cyanosis; diarrhea; encephalitis; pancreatitis	Highly pathogenic avian influenza virus	II.18
		Chickens, game birds, pigeons, etc.	Sudden death with high mortality; hemorrhagic lesions in the intestinal tract; encephalitis	Newcastle disease (<i>Velogenic paramyxovirus 1</i>)	II.19
		Turkeys, chickens, etc.	Swollen head syndrome; tracheitis; egg drop up to 70%; poor shell quality	Avian Metapneumovirus	II.20
		Chickens	2-4 week-old chicks; severe anemia; hematocrit <27%; lymphoid depletion (thymus and bursal atrophy, pale bone marrow); hemorrhages; mortality (up to 60%)	Chicken infectious anemia (<i>Gyrovirus</i>)	II.30
		Psittacines	Sudden death; hepatosplenomegaly; hemorrhages (heart, intestine, liver)	Polyomavirus infections	II.39
		Chickens, turkeys, game birds, etc.	Chronic respiratory disease; prostration; egg drop and poor egg quality; sinusitis; keratoconjunctivitis; airsacculitis; tenosynovitis; salpingitis	Chronic respiratory disease (<i>Mycoplasma gallisepticum</i>)	III.41
		Turkeys, chickens, etc.	Sudden death; purple color and turgescence of snood and dewlap; yellow-green diarrhea; mortality; septicemia: congestion or hemorrhages (petechiae); catarrhal enteritis; splenomegaly; valvular endocarditis; arthritis	Erysipelas (<i>Erysipelothrix rhusiopathiae</i>)	III.55
		Turkeys, chickens, quails, ducks, etc.	Yellow sulfur diarrhea; abnormal gait; typhlitis; hepatic lesions: necrotic foci in cockade with raised edges and a center depression	Histomoniasis (<i>Histomonas meleagridis</i>)	IV.66
		Poultry	Black or blue/black gelatinous subcutaneous edema	Exudative diathesis	IV.71
		All species	Asphyxia, cyanosis of featherless skin, pulmonary edema and subcapsular hemorrhages in the liver	Acute propane butane intoxication	IV.79
		Waterfowl	Bloody greenish diarrhea; high mortality; conjunctivitis; esophagitis; widespread hemorrhages; intestinal annular bands; egg drop (25-40%); smaller spleen	Duck virus enteritis (<i>Anatid herpesvirus 1</i>)	VI.89
		Viral dermatitis	All species	Cutaneous form: nodular proliferative skin lesions progressing to thick scabs; diphtheritic form: upper digestive and respiratory tract lesions	Fowlpox (<i>Avipoxvirus</i>)
Psittacines	Sudden death; acute bursal necrosis; chronic: dystrophic feathers, stunting; immunodepression (necrosis of bursa)		Psittacine beak and feather disease (<i>Circovirus</i>)	II.39	
Bacterial dermatitis	Turkeys, chickens, etc.	Cellulitis (serosanguineous to caseated, fibrinoheterophilic exudate in subcutaneous tissues); swollen head syndrome; other colibacillosis lesions	Cellulitis (<i>Escherichia coli</i>)	III.45	
	Chickens, turkeys, etc.	Localized abscesses: joints, head, oviduct, respiratory tract (pneumonia, airsacculitis), middle ear and meninges (torticollis); fibrinonecrotic dermatitis	Chronic fowl cholera (<i>Pasteurella multocida</i>)	III.46	
	Chickens, turkeys	Depression; lameness; reddened moist skin; emphysematous or serosanguineous cellulitis; petechial hemorrhages; gas; «bubble tails»; foul odor	Gangrenous dermatitis (<i>Clostridium</i> spp., <i>S. aureus</i>)	III.51 III.57	
	All species	Chronic disease; progressive emaciation; pallor; diarrhea; lameness; granuloma: lesion triad "liver, spleen, intestine", bone marrow, ovary, teste, heart, skin, lung	Tuberculosis (<i>Mycobacterium avium</i>)	III.54	
	Chickens, turkeys, ducks	Valvular endocarditis (<i>E. faecium</i> , <i>E. hirae</i> , <i>E. durans</i> , <i>S. gallineus</i> , <i>S. pluranimalium</i> , <i>S. zooepidemicus</i>); encephalomalacia (<i>E. hirae</i> , <i>E. durans</i>); cellulitis (<i>S. dysgalactiae</i>); sepsis (<i>E. faecium</i> , <i>S. pluranimalium</i>)	<i>Enterococcus</i> spp. <i>Streptococcus</i> spp.	III.56	
	All species	Sudden death; palor; sinusitis; arthritis (amyloid); synovitis; osteomyelitis; dermatitis; omphalitis; septicemia; green liver; pneumonia; endocarditis; bumble foot	Staphylococcosis (<i>Staphylococcus aureus</i>)	III.57	
	Chickens, turkeys, ducks, etc.	Clinical signs may vary greatly and lesions are not specific; yolk sac infections; sudden death; swelling of the head; diarrhea; arthritis; hepatitis, etc.	Pseudomoniasis (<i>Pseudomonas</i> spp.)	III.60	
Mycotic dermatitis	All species	Dyspnea; mortality; nodules (trachea, bronchi, lungs, air sacs); diarrhea; stunting; systemic infection with other localizations: brain, eye, skin, kidneys, etc.	Brooder pneumonia (<i>Aspergillus fumigatus</i>)	IV.62	
	All species	Reduced feed intake; digestive lesions mainly in crop (coated with multifocal or confluent mats of white cheesy material)	Candidiasis (<i>Candida albicans</i>)	IV.62	
	Poultry	Superficial invasion of unfeathered skin (comb, wattle, shanks): epidermal hyperplasia and hyperkeratosis	Dermatophytosis (Favus) (<i>Microsporum</i> spp.)	IV.62	

Tabl.112.3: Differential diagnosis of skin or subcutaneous disorders.

Symptoms & lesions	Species affected	Main clinical signs & lesions	Etiology	Chap.		
NODULES & FOLLICULITIS	Neoplasia	Chickens (turkeys)	Depression, weight loss, diarrhea, diffuse or nodular lymphomas in visceral organs (liver, spleen, ovary, kidney, proventriculus, heart, bursa) and sometimes in the skin (feather follicles) and skeletal muscles	Marek's disease Acute form (<i>Very virulent Mardivirus</i>)	II.33	
		Chickens	Depression; pallor; nodular or diffuse tumors of liver, spleen, bursa and other organs (skeletal tissues); subclinical infection without neoplastic lesions; egg drop	Lymphoid leukosis (<i>Retrovirus ALV-A</i>)	II.34	
		Chickens	Diffuse myeloid leukosis: pallor; liver and spleen are enlarged and granular appearance of the liver; bursa sometimes tumorous; tumor infiltration of bone marrow; myeloblastic leukemia; other tumors (ovary, kidneys, bursa)	Myeloid leukosis Myeloblastosis (<i>Retrovirus ALV-J</i>)	II.34	
		Chickens	Tumoral form of myeloid leukosis: diffuse nodular tumors of creamy-white colour; other tumors [ovary, kidneys, thymus, surface of bones (sternum, ribs, skull)]	Myelocytomatosis (<i>Retrovirus ALV-J</i>)	II.34	
		Turkeys, chickens, ducks, geese	Runting; pallor; abnormal feather development; lameness; atrophy of thymus and bursa; enlarged peripheral nerves (marginal); proventriculitis, enteritis; hepatomegaly; splenomegaly; other tumors (gonads, pancreas, kidneys, heart)	Reticuloendotheliosis (<i>Gammaretrovirus</i>)	II.35	
	Abscess	Chickens, turkeys, etc.	Localized abscesses: joints, head, oviduct, respiratory tract (pneumonia, airsacculitis), middle ear and meninges (torticollis); fibrinonecrotic dermatitis	Chronic fowl cholera (<i>Pasteurella multocida</i>)	III.46	
		All species	Chronic disease; progressive emaciation; pallor; diarrhea; lameness; granuloma: lesion triad "liver, spleen, intestine", bone marrow, ovary, teste, heart, skin, lung	Tuberculosis (<i>Mycobacterium avium</i>)	III.54	
	SKIN PALLOR	Intestinal malabsorption	Chickens	Pale birds; stunting; abnormal feathering (helicopter wings); femoral head fractures; immunodepression; orange diarrhea, enlarged proventriculus	Enteritic problems (<i>Reovirus</i>)	II.27 II.28
			All species	Intestinal malabsorption and anemia	Coccidiosis	IV.64
			Chickens, turkeys	Anemia; intermittent diarrhea; weight loss; egg drop; intestinal impaction	Ascaridia spp.	IV.67
Anemia		Turkeys, bustards	Sudden death; depression, bloody droppings, decreased feed and water consumption; 10-15% mortality (up to 60%); swollen dark purple small intestine filled with bloody content; enlarged, mottled spleen followed by atrophy; hepatomegaly	Turkey hemorrhagic enteritis (<i>Siadenovirus</i>)	II.25	
		Chickens	2-4 week-old chicks; severe anemia; hematocrit <27%; lymphoid depletion (thymus and bursal atrophy, pale bone marrow); hemorrhages; mortality (up to 60%)	Chicken infectious anemia (<i>Gyrovirus</i>)	II.30	
		Chickens	Leukemia, malignant cells remaining within the blood vessels; erythrosthiasis in liver, spleen, bone marrow; distinctive cherry-red coloration of liver and spleen; other tumors in kidneys, sometimes hemorrhages in muscles	Erythroid leukosis (<i>Retrovirus ALV-J</i>)	II.35	
		Fowls, turkeys	Pale and shrunken combs; egg drop; small nodular regressing ovarian follicles; hepatitis; oophoritis; salpingitis; white foci or nodules on testes	Fowl typhoid (<i>S. Gallinarum-pullorum</i>)	III.42	
		All species	Anorexia; fever; depression; cyanosis of the head; anemia; marked enlargement and mottling of the spleen; hepatitis; nephritis; pericarditis	Spirochaetosis (<i>Borrelia anserina</i>)	III.61	
		All species	Increasing mortality; severe anemia; ascites and right ventricular failure	Aegyptianella pullorum	III.61	
		All species	Severe anemia; mortality; splenomegaly; nephritis; occlusion of brain capillaries; parasites found in red blood cells	Avian malaria (<i>Plasmodium spp.</i>)	IV.67	
		Turkeys, ducks, geese, etc.	Anemia; hemorrhages; important decreased growth; high mortality rates; parasitized leukocytes observed on blood smears	Leucocytozoonosis (<i>Leucocytozoon spp.</i>)	IV.67	
		Poultry	Nervousness; pecking; stress; aggression; egg drop; stunting; anemia; bloodstained eggs; mortality	Poultry red mite (<i>Dermanyssus gallinae</i>)	IV.68	
		All species	Nervousness; egg drop; stunting; anemia	Northern fowl mite (<i>Ornithonyssus sylviarum</i>)	IV.68	
		Layers	Obesity; egg drop; mortality; pallor and sudden death (hemorrhages); large amount of fat in abdominal cavity and liver (yellow, friable and enlarged)	Fatty liver hemorrhagic syndrome	IV.71	

Tabl.112.4: Differential diagnosis of nodules, folliculitis or skin pallor.



Fig.113.1 & 113.2: Normal fecal droppings (note 1).



Fig.113.3 & 113.4: Normal cecal droppings. Cecal dropping of Fig.113.4 is normal but it is deposited on intestinal dropping.

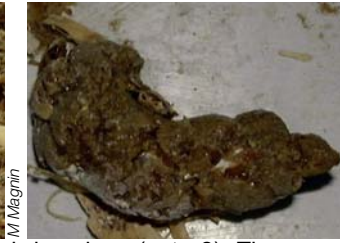

Fig.113.5, 113.6 & 113.7: Fecal droppings (note 2). These moderate changes are the first alert signs of an intestinal disorder.

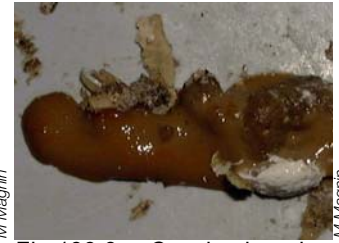
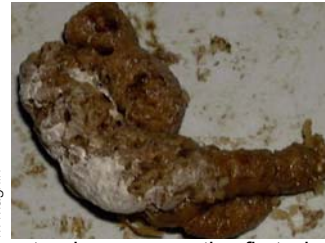
Fig.113.8: Cecal dropping (note 2).

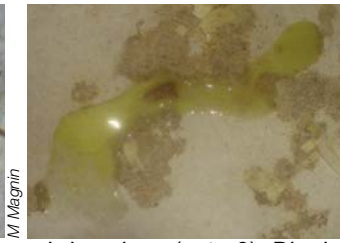

Fig.113.9, 113.10 & 113.11: Faecal droppings (note 3). Diarrheic droppings can be observed in aviadenovirus (Fig.113.10: Inclusion body hepatitis), sometimes with undigested feed and/or orange mucus (Fig.113.11: Coccidiosis with *Eimeria acervulina*).




Fig.113.12: Caecal dropping (note 3). Foamy, color change, liquid or no consistency.




Fig.113.13 & 113.14: Fecal droppings (note 4). Severe changes indicating a serious disease (Fig.113.13: presence of blood and Fig.113.14: Fumonisin intoxication).

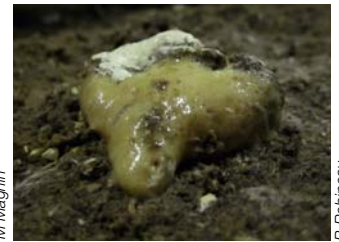

Fig.113.15 & 113.16: Cecal dropping (note 4). Very foamy (mousse), spread, color change, liquid (Fig.113.16: *Brachyspira* spp.).




Fig.113.17 & 113.18: Dropping observation must be carried around waterers (Fig.113.17: presence of blood) and leakage from drinkers should not be confused with diarrhea (Fig.113.18).

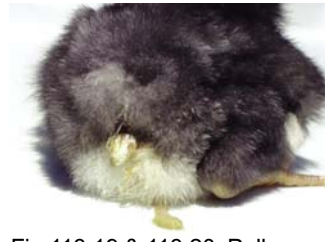


Fig. 113.19 & 113.20: Pullorum disease. White diarrhea. Feathers around the vent in many chickens is stained with diarrheic feces or pasted with dry faeces.

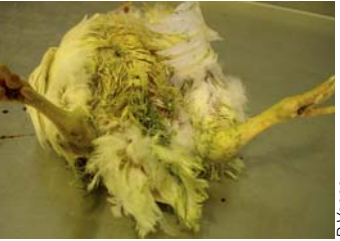


Fig.113.21 & 113.22: Gumboro disease. Observation concerns not only the aspect of droppings in the litter but also birds at necropsy.




Fig.113.23 & 113.24: Evaluation of the water content of droppings with ELANCOBOX (Fig.113.23). Example of normal droppings on absorbent paper in Fig.113.24.

Differential diagnosis

113. AVIAN DROPPINGS

Observation of avian droppings is a diagnostic tool for early intervention during a bowel and/or cecal disease. It thus allows to limit the economic losses associated with decreases in production (meat, eggs) and before the onset of significant mortality. When examining fecal or cecal droppings, it is important to assess water content (normal, moderate, aqueous or very liquid during diarrhea), increased volume, loss of consistency, color change (especially the presence of melena or fresh blood), oily appearance, presence of undigested feed and/or abnormal smell.

It is important to observe droppings around the drinkers in order to be consistent. But, in addition to droppings in the litter, one must also look at the birds, especially the cloacal area and feathers soiled and stained with diarrheal droppings, sometimes forming a pasty mass after drying.

The evaluation of the water content of manure ensures good litter quality (especially the prevention of skin diseases and pododermatitis) and early detection of enteritis in flocks. This can be done using tools such as ELANCOBOX. This tool includes a special absorbent paper placed on the litter and under a slatted box on which the birds will defecate. This system provides a good assessment of the moisture content of droppings. It is

important to assess the water consumption of the flock to determine whether the «aqueous» swelling of fecal droppings comes from an overconsumption of water (in this case non-pathological causes are to be sought) or intestinal damage with impaired reabsorption. Both problems could occur concurrently.

Many diseases are associated with diarrhea and its color may or may not be specific. For example, the green color is caused by a bile pigment due to anorexia and the white color results from an excessive amount of white urates in droppings (as the disease progresses, the droppings become totally white).

REFERENCES

- Atlas of avian diseases (Cornell University). <http://partnersah.vet.cornell.edu/avian-atlas/>.
- Bostvironnois C. Utilisation de l'ELANCOBOX chez le poulet comme outil de diagnostic précoce des enteritis. Bilan et perspectives. 5èmes *J Recherche Avicole* Tours, 26 & 27 mars 2003,9-12.
- Kemin Industries. Your guide to abnormal avian droppings. *Int Poultry Prod.* 2013,21(4):13.
- Proudfoot FG & Dewitt WF. The effect of the pellet binder lignosol FG on the chickens digestive system and general performance. *Poultry Sci*, 1976;55:629-631.

Aspect	Origin	Others aspects	Examples (figures)	Chap.	
CHANGES OF FAECAL & CAECAI DROPPINGS	Healthy (note 1)	Faecal	Small with a white urate cap, rather molded, usually have a down feather attached to it, have no sign of wetness surrounding it; no smell, dry, color greenish brown, absence of mucus or undigested grains	(113.1 & 113.2)	
		Caecal	Varies in color (can be dark almost black/brown), firm and smooth, viscous, smelly	(113.3 & 113.4)	
	Red flag (note 2)	Faecal	Increased size, beginning of destructureation, oily, increased moisture	(113.5, 113.6 & 113.7)	
		Caecal	Watery, loss of consistency, foamy, color change, early caecal dysfunction	(113.8)	
	Bad (note 3)	Faecal	Watery, lost firmness, undigested feed, may have orange mucus	(113.9) Aviadenovirus (113.10) Coccidiosis (113.11)	II.24 IV.64
		Caecal	Foamy, color change, liquid, no consistency	(113.12)	
	Danger (note 4)	Faecal	Watery diarrhea, undigested feed, mucus, necrotic material and/or blood	(113.13) 113.10: Mycotoxicosis	IV.63
		Caecal	Very foamy (mousse), spread, color change, liquid	(113.15) Brachyspira spp. (113.16)	III.58

Tabl.113.1: Guide to abnormal avian droppings (adapted from Kemin Industries, 2013).



Fig.113.25, 113.26, 113, 27 & 113.28: Other tools assessing the water content of droppings can be more precise and also allow a better observation of their composition and color. Fig.113.25: normal. Fig.113.26: orange liquid (coccidiosis). Fig.113.27: orange liquid and enteritis (coccidiosis). Fig.113.28: disease (grey droppings).

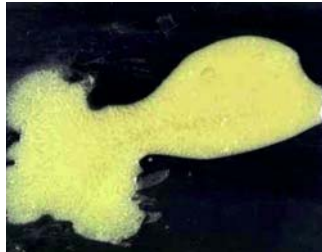



Fig.113.29: Orange mucoid droppings.

Fig.113.30: Histomoniasis. Brilliant yellow dropping.

Fig.113.31: Poult enteritis mortality syndrom (PEMS).

Fig.113.32 Droppings of caramel color.

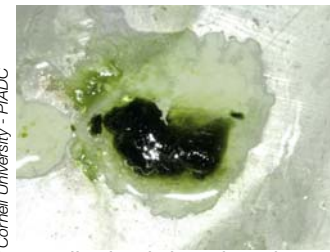


Fig.113.33, 113.34 & 113.35: Green diarrheal droppings in acute septicemic disease like highly pathogenic avian influenza (Fig.113.33, one day post experimental inoculation), Newcastle disease (Fig.113.34) or duck viral enteritis (Fig.113.35).

Fig.113.36: Green droppings can also be observed without diarrhea.

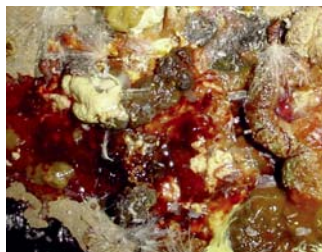

Fig.113.37: Presence of hemorrhagic droppings on litter.

Fig.113.38: Caramel droppings then become hemorrhagic if no early treatment of coccidiosis.

Fig.113.39: Coccidiosis (*E. tenella*). Hemorrhagic cecal dropping.

Fig.113.40: Grey dropping.




Fig.113.41: Feed in dropping.

Fig.113.42 & 113.43: Excess of salt in the ration causes diarrhea, excretion of diluted urine and wet litter. Observation of a severe diarrhea on ELANCOBOX paper.

Fig.113.44: Fasting is accompanied by a high excretion of urates.

Aspect	Origin	Common causes	Examples (figures)	Chap.
COLOR	Orange	Fecal or cecal Orange tinge caused by sloughing of the intestinal mucosa, coccidiosis (<i>Eimeria maxima</i> or <i>E. acervulina</i>) with or without diarrhea, hypoglycemia - spiking mortality syndrome of broiler chickens (HSMS), mucus, first droppings after fasting, loss of carotenes and vitamins, other	Coccidiosis (<i>E. maxima</i>) Coccidiosis (<i>E. acervulina</i>) HSMS (113.11 & 113.29)	IV.64 IV.64 IV.73
	Yellow	Fecal or cecal Inclusion body hepatitis, avian enterovirus-like virus infection, histomoniasis (blackhead, brilliant yellow droppings, wasting, typhlitis); poult enteritis mortality syndrome (PEMS): yellow to watery brown droppings; foamy: problem of maldigestion and fermentation in ceca (undigested food, infection, parasites, etc.)	Inclusion body hepatitis Histomoniasis PEMS (113.10, 113.30 & 113.31)	II.24 IV.66 IV.72
	Caramel	Fecal or cecal With or without foam, foamy yellow-brownish (or caramel) in <i>Brachyspira</i> spp. infection, first stage of coccidiosis or some other parasites, other	Brachyspira spp. Coccidiosis (<i>E. maxima</i>) Parasites (113.16 & 113.32)	III.58 IV.64 IV.67
	Green	Faecal or caecal Biliary origin: fasting, anorexia (related to disease); fat problem in feed (rancidity, quantity, absorption, etc.); Acute septicemic diseases, (avian Influenza, Newcastle disease, spirochaetosis, duck virus enteritis), hepatic diseases (clostridiosis, colibacillosis, etc.), other	Avian influenza Newcastle disease Colibacillosis Clostridiosis Spirochaetosis Duck virus enteritis (113.33, 113.34, 113.35 & 113.36)	II.18 II.19 III.45 IV.51 III.61 VI.89
	Red (blood)	Faecal or caecal Acute hemorrhagic enteritis: turkey hemorrhagic enteritis (<i>Siadenovirus</i>), hemorrhagic nephritis enteritis of geese (or HNEG), coccidiosis (caecal coccidiosis due to <i>E. tenella</i>); parasites, wound, cannibalism, other	Turkey hemorrhagic enteritis Coccidiosis (<i>E. tenella</i>) Parasites HNEG Duck virus enteritis (113.13, 113.17, 113.37, 113.38 & 113.39)	II.25 IV.64 IV.67 VI.88 VI.89
	Grey	Fecal or cecal Malabsorption, mixture of bile and urates, antitrypsin factor [soya or rapeseed (Canola) undercooked], other	(113.28 & 113.40)	
	Black (tarry)	Fecal or cecal Too warm temperature with excess water consumption, (each °C above the comfort zone leads to an increase in water consumption by 10%); presence of melena (digested blood; pellet binder "Lignosol FG"; excess fiber (e.g., wheat, barley)		
OTHER	Undigested food Fecal or cecal	Malabsorption, transit too fast, inadequate size particles in the ration, other	(113.41)	

Tabl.113.2: Guide to abnormal color or composition of avian droppings.

Common causes	Less common causes	Rare causes
Heat stress I.7 Vent prolapse I.9	Raw soybean meal Hardware disease Mold toxins in feed IV.63 Excess salt in the diet IV.71	Toxic plants
Marek's disease II.33 Lymphoid leukosis II.34	Rotavirus or entero-like virus infections II.18 Infectious coryza III.47	Avian influenza II.18 Newcastle disease II.19
Pullorum disease III.42 Paratyphoid salmonella III.43 Arizonosis III.44 Colibacillosis III.45 Clostridiosis III.51	Fowl cholera III.46 Avian tuberculosis III.54 Erysipelas III.55 Avian intestinal spirochetosis III.58	Chlamydiosis III.40 Campylobacteriosis III.53 Listeriosis III.61
Coccidiosis IV.64	Aspergillosis IV.62 Heavy infections with threadworms IV.67	Histomoniasis IV.66

Tabl.113.3: Some causes of diarrhea in chicken (adapted from J Gauthier & R Ludlow, <http://www.dummies.com/how-to/content/diarrhea-in-adult-chickens.html>).

Preface

The French Directorate General for Food (Ministry of Agriculture, Agrifood and Forestry seeks to ensure the safety and quality of food. For that reason, it is responsible for animal health and public health.

Combating animal diseases is a priority; a priority pursued through the intervention of government departments and agencies and concerted action in conjunction with representatives of the various industries involved. It cannot however be fully achieved without an efficient surveillance and prevention system.

The sanitary status of our country regarding animal health, and particularly poultry, is currently very favorable. However, maintaining that status requires constant vigilance. It is for that reason that a national platform for epidemiological surveillance in animal health was set up in 2011 in France with farmers' and veterinarians' organizations. That platform contributes to early detection of diseases.

Poultry farming is a major component part of French animal production. Poultry diseases, due to the direct (sick animals, mortality) or indirect (increased production costs, trade barriers) losses they generate, have a negative impact on the value of that production and can have serious political and socio-economic consequences.

Animal health is also an important factor in the competitiveness of poultry farming and is thus a major economic issue for France, an export-oriented country, developing high value-added food production. Some poultry diseases (salmonella, avian influenza) can also have a direct negative impact on public health.

This book is a publication of reference that is indispensable for all stakeholders in the poultry sector: farmers, veterinarians or student veterinarians, and officials in many countries, since it will be translated into several languages. That work will contribute to improving the effectiveness of the fight against poultry diseases around the world.

I wish to congratulate Jeanne Brugère-Picoux for this important project she has now brought to fruition.

This book will certainly constitute a world reference in avian pathology, in particular due to its extensive illustrations.

Patrick Dehaumont
Director General for Food

Preface

Poultry is the predominant type of animal production in both developed and developing countries. While poultry production has expanded significantly in recent decades, particularly in Asia, since late 2003 growth has been curbed worldwide by the spread of avian influenza.

Poultry production is critical to the economy and food security of many developing countries because not only is poultry easy to farm and well suited to backyard production, in many cases it is a staple food.

The spread of poultry diseases is a serious and continuing threat. Accordingly, 22 poultry diseases have been included in the list of diseases considered by the Member Countries of the World Organisation for Animal Health (OIE) to be a priority. Member Countries are obliged to notify the OIE officially of the presence or absence of these diseases in accordance with Chapter 1.1 of the OIE Terrestrial Animal Health Code, which is a reference standard for the World Trade Organization in the field of international trade. Surveillance requirements for such avian diseases as influenza have also been reinforced by including infection with avian influenza viruses, even in the absence of clinical signs, as well as onset of the disease in wildlife. In addition, 15 avian diseases are included in the OIE Manual of Diagnostic Tests and Vaccines for Terrestrial Animals, to facilitate methods of diagnosis and improve the quality of vaccines for use in certain situations.

This richly illustrated manual of poultry diseases is a key reference work that reviews poultry production systems across the globe, describing the range of diseases affecting all domesticated bird species, and contains a section on differential diagnosis to aid in detecting and recognising specific diseases.

My congratulations to the teachers and specialists from around the world who contributed articles to this manual, especially the originators and editors, Professors Jeanne Brugère-Picoux and Jean-Pierre Vaillancourt who, along with the authors, invested a great deal of personal effort to produce this important publication.

Doctor Bernard Vallat

Director General of the World Organisation for Animal Health (OIE)

Foreword

At a time when poultry production has greatly evolved in developed and developing countries, veterinary training in poultry medicine and pathology has not received as much attention as for other domestic animals. This is disconcerting considering that it has been known for quite some time that different types of poultry production would be expanding in many countries in the world. This is why we have produced a new edition of the Poultry Pathology Manual that was first edited in French in 1992 ("*Chaire de pathologie médicale du bétail et des animaux de basse-cour*" Edition, Maisons-Alfort). At that time, this manual included texts written by instructors involved in the poultry pathology specialized training course created in 1989 at the School of Veterinary Medicine of Alfort (*Ecole nationale vétérinaire d'Alfort*). With over 400 photos, this first edition already offered a relatively large number of images in support of the texts.

The main objective of the current edition is to provide a comprehensive update on practical information related to poultry diseases in order to assist with the diagnosis of conditions affecting all poultry species (chickens, turkeys, ducks, guinea fowls, quail, pheasants, partridges, pigeons, ratites). This new edition also puts emphasis on poultry disease control. As a result, several chapters were added on biosecurity, water sanitation, epidemiology, etc. Since macroscopic and microscopic examinations of lesions are an important component of the diagnostic process, we included about 2700 images. As we developed this book project, we were able to appreciate the value of putting together this image collection obtained from University colleagues (in particular H. John Barnes, HL Shivaprasad and Marie-Thérèse Casaubon Huguenin), Dr Hervé Morvan, veterinary laboratory of Côtes d'Armor (LDA 22), Dr François Biet (Sanders photos), Ceva Animal Health laboratories (collection of professor I. Dinev), Merial and Bayer, field veterinarians as well as the authors who contributed to the image collection of their chapter and to other chapters. Finally, we gratefully acknowledge the leadership of the *American Association of Avian pathologists* (AAAP), Cornell University (USA), the journals *Avian Pathology*, *Virology* and *Israel Journal of Veterinary Medicine* who graciously authorized the use of their images. We also wish to express our sincere gratitude to Sylvie Gutzer and Franklin Simon (Publi-Santé editions), Romain Caillet (Toppan Leefung Printing) and Aurélie Mercier, whose assistance was really useful for the making of the layout of this book.

This project also included translating the text in several languages in order to reach poultry people in developed and developing countries. These first four editions are in French, English, Chinese and Spanish. We wholeheartedly thank our colleague Xiaoling Chen and her brother Zhengwen Chen who did the translation for the Chinese edition. It was as well a real pleasure to discover the enthusiasm of our Mexican colleagues, in particular Drs Miguel Marquez and Nestor Ledesma who led the translation for the Spanish edition. Finally, we are grateful to the authors who assisted us in translating their chapters from French to English (Geneviève Bénard, Jean-Denis Bailly, Stéphane Lemièrre, Dominique Fournier and Moncef Bouzouaia) or from English to Spanish (Arturo Anadon).

Other translations are planned (including Portuguese, Russian, Lithuanian, Vietnamese, Arab, etc.) based on the same principle as for the first four editions, which is non-profit work by poultry professionals.

In order to avoid the tedious work of producing a detailed index for each edition, we elected to produce at the end of the manual a series of differential diagnosis tables referring back to specific disease chapters.

This manual is the culmination of a long and fruitful collaboration with authors of diverse scientific background coming from around the world. We wish to express to them our deep gratitude for accepting to join us pro bono in this adventure.

Because we wanted to produce and distribute this manual at the lowest possible cost, our project was done without the assistance of a professional publisher. The French Association for the Advancement of Sciences (*Association française pour l'avancement des sciences* or AFAS), created by Claude Bernard, accepted to serve as publisher in order to limit expenses to a strict minimum.

All computer hardware required for this project could be obtained via an apprenticeship tax collected from generous French donors and made available to the medical pathology service for livestock and backyard animals from the National Veterinary School of Alfort. Thanks to this, we can offer this 740 page manual at cost. But our ability to go to print was dependent on having a sufficient number of pre-ordered manuals. We started a subscription process in August 2013. We are very grateful to our subscribers [particularly our colleagues Patrick Dehaumont and Jean-Luc Angot from the French Ministry of Agriculture, veterinary laboratories, the World Organisation for Animal Health (OIE), the Animal, Society, Food Association (*Association animal, société, aliment* ou ASA) and to our donors [Société Nérévia, the association "SSAFE", and the veterinary drug union (SIMV)] that allow us to print 8000 copies of the manual with a four language e-book version included with each paper copy. We also wish to thank the Minister of Agriculture, Mr Jacques Godfrain who provided us with the financial support for the production of the Chinese edition of the manual.

Notwithstanding our efforts, this work is not perfect. Hence, one may find oversights in the texts or with the images. For this, we are hoping for your indulgence.

Finally, this edition could only be dedicated to our respective families who had to endure the consequences of the workload that came with the creation of this manual.

Jeanne Brugère-Picoux & Jean-Pierre Vaillancourt
Co-editors-in-Chief

Editors-in-Chief: Jeanne Brugère-Picoux & Jean-Pierre Vaillancourt

Associate editors: HL Shivaprasad, Daniel Venne & Moncef Bouzouaia

Contributing Authors

Hayet Abbassi

Veterinarian
University of Minnesota
St. Paul Minnesota, USA

Tahseen A Abdul-Aziz

Veterinary pathologist
Rolling animal disease diagnostic
Lab., North Carolina department of
agriculture and consumer services
Raleigh, North Carolina, USA

Karim T Adjou

Maître de conférences
Pathologie médicale du bétail et des
animaux de basse-cour
École nationale vétérinaire d'Alfort
Maisons-Alfort, France

Nadir Alloui

Professeur
Pathologie aviaire
Institut vétérinaire de Batna
Batna, Algérie

Arturo Anadón

Professor
Facultad de veterinaria/Departamento
de toxicología y farmacología
Universidad Complutense de Madrid
Madrid, Spain

Claude Aubert

Institut technique d'aviculture
Ploufragan, France

Jean-Denis Bailly

Maître de conférences
Hygiène et industrie des denrées
alimentaires
Ecole nationale vétérinaire de Toulouse
Toulouse, France

Dominique Balloy

Docteur vétérinaire
Réseau cristal, Labovet conseil
Les Herbiers, France

Caroline Banet Noach

Docteur vétérinaire
Phibro animal health corporation
Israel

Hervé Banon

Docteur vétérinaire
Groupe ANIBIO, Arzacq, France

Kate Barger

Veterinarian,
Director of world animal welfare
Cobb-Vantress, Inc.,
Davidson, USA

H John Barnes

Professor
Department of population health and
pathobiology
College of Veterinary Medicine
Raleigh, North Carolina, USA

Geneviève Bénard

Professeur
Hygiène et industrie des denrées
alimentaires,
École nationale vétérinaire de Toulouse
Toulouse, France

Magne Bisgaard

Professor emeritus
Faculty of health and medical sciences
University of Copenhagen, Denmark

Patrick J Blackall

Senior principal research fellow
The university of Queensland
Queensland, Australia

Moncef Bouzouaia

Professeur
Aviculture et pathologie aviaire
Faculté de médecine vétérinaire
Sidi-Thabet, Tunisie

Henri Brugère

Professeur honoraire
Physiologie, pharmacologie et
thérapeutique
École nationale vétérinaire d'Alfort
Maisons-Alfort, France

Jeanne Brugère-Picoux

Professeur honoraire
Pathologie médicale du bétail et des
animaux de basse-cour
École nationale vétérinaire d'Alfort
Maisons-Alfort, France

Marie-Pierre Callait-Cardinal

Maître de Conférences
Parasitologie, Vetagro-Sup
Campus vétérinaire de Lyon
Marcy L'Étoile, France

Carol J Cardona

Professor
College of veterinary medicine
University of Minnesota, St-Paul, USA

Marie Thérèse Casaubon Huguenin

Facultad de medicina Veterinaria y
zootecnia, Ciudad universitaria,
México

Donna K Carver

Professor
Department of Poultry Science
North Carolina state university
Raleigh, North Carolina, USA

Eliane Chatelain (†)

Professeur
Anatomie,
Vetagro-Sup, Campus vétérinaire de
Lyon, Marcy L'Étoile, France

Xavier Chatenet

Docteur vétérinaire
Réseau cristal, Labovet Conseil
Les Essarts, France

Xiaoling Chen

Institute for animal husbandry and
veterinary science, Beijing municipal
academy of agriculture and forestry
Beijing, China
陈小玲
研究员
北京市农林科学院畜牧兽医研究所
中国北京

Sonia Chénier

Clinicienne - pathologiste
Pathologie et microbiologie
Université de Montréal
St. Hyacinthe, Québec, Canada

Younès Chorfi

Professeur
Biomédecine, Faculté de médecine
vétérinaire, Université de Montréal
St. Hyacinthe, Québec, Canada

Jens P Christensen

Associate Professor
Veterinary disease biology
Faculty of live sciences
University of Copenhagen, Denmark

Steven Clark

Senior technical veterinarian, Zoetis
West Jefferson, North Carolina, USA

Rocio Crespo

Associate Professor
Avian health and food safety lab.
Washington state University
Pullman, Washington, USA

Rosine Danguy-des-Déserts

Docteur vétérinaire
Directrice du pôle santé animale
Labocea (LDA 22) Ploufragan, France

James F Davis

Veterinary director of diagnostics
North Georgia poultry laboratory
network, Oakwood, Georgia, USA

Sherrill Davison

Associate professor,
Laboratory of avian medicine and
pathology, New Bolton Center
School of Veterinary Medicine
University of Pennsylvania, USA

Christophe Degueurce

Professeur
Anatomie, École nationale vétérinaire
d'Alfort, Maisons-Alfort, France

Nathalie Doublet

Docteur Vétérinaire
Praxivet, St Quentin, France

Patricia A Dunn

Senior Research Associate; Avian
Pathologist and field investigator
College of agricultural sciences,
Veterinary and biomedical sciences
Pennsylvania State University, USA

Mohamed El Houadfi

Professor
Poultry diseases
Institut agronomique et vétérinaire
Hassan II Institut, Morocco

Michel E Eregae

Veterinary Epidemiologist
COOPI - Cooperazione internazionale
Nairobi regional office, Nairobi, Kenya

Nicolas Eterradossi

Directeur adjoint
Agence nationale de sécurité sanitaire,
de l'alimentation, de l'environnement
et du travail (ANSES), Virologie,
immunologie, parasitologie aviaires &
cunicoles, Ploufragan, France

Oscar J Fletcher

Professor
Department of population health &
pathobiology, College of veterinary
medicine, North Carolina state uni-
versity, Raleigh, NC, USA

Dominique Fournier

Docteur Vétérinaire
Filavie, Roussay, France

Chris Fritts

Merial Select, Gainesville, GA, USA

Eric N Gingerich

Veterinarian
Diamond V, Zionsville, IN, USA

Jean-Luc Guérin

Professeur
Pathologie aviaire
Ecole nationale vétérinaire de Toulouse
Toulouse, France

James S Guy

Professor
Department of population health &
pathobiology, North Carolina state
university, Raleigh, NC, USA

Vincent Guyonnet

Docteur vétérinaire
Burnbrae Farms Ltd
Lyn Ontario, Canada

Hafez M Hafez

Professor
Institut of poultry diseases
Free university Berlin
Berlin, Germany

Frederic J Hoerr

Veterinary pathologist
Veterinary diagnostic pathology, LLC
Auburn, Alabama, USA

Daral J Jackwood

Professor
The Ohio state university/Ohio agri-
cultural research and
development center
Wooster, Ohio, USA

Véronique Jestin

Agence nationale de sécurité sanitaire,
de l'alimentation, de l'environnement
et du travail (ANSES), Virologie,
immunologie, parasitologie aviaires &
cunicoles, Ploufragan, France

Jean-Yves Jouglar

Maître de Conférences
Clinique des oiseaux & faune sauvage
Ecole nationale vétérinaire de Toulouse
Toulouse, France

Erhard Franz Kaleta

Professor
Clinic for birds, reptiles, amphibians
and fish, Justus Liebig University
Giessen, Giessen, Germany

Isabelle Kempf

Docteur vétérinaire
Mycoplasmologie & bactériologie
Agence nationale de sécurité sani-
taire, de l'alimentation, de l'environ-
nement et du travail (ANSES),
Ploufragan, France

Joseph Le Bars

Ingénieur agronome
Institut National de la Recherche
Agronomique, Tournefeuille, France

Stéphane Lemièrre

Docteur vétérinaire
Merial, Lyon, France

Catherine M Logue

Professor
Department of veterinary
microbiology and preventive
medicine, College of veterinary
medicine, Iowa state university, USA

Luce Lopez

Patóloga clínica
Col. San Lucas, Xochimanca
Del. Xochimilco, México, D.F.

Stéphanie Maeder

Docteur vétérinaire
Ministère de l'agriculture/Direction
générale des politiques agricole,
agroalimentaire et des territoires
Paris, France

Michel Magnin

Docteur vétérinaire
BNA Nutrition Animale
Château-Gontier, France

Didier Marlier

Professeur
Clinique aviaire, Faculté de médecine
vétérinaire, Université de Liège, Belgique

Michael P Martin

Associate Professor
Department of population health &
pathobiology, North Carolina state
university, Raleigh, NC, USA

María Rosa Martínez-Larrañaga

Profesora
Facultad de veterinaria/Departamento
de toxicología y farmacología
Universidad Complutense de Madrid
Madrid, Spain

Ron Meijerhof

Consultant
Poultry performance plus
Voorst, The Netherlands

Antoine Mercier

Docteur vétérinaire
Réseau cristal, Malestroit, France

Serge Messier

Professeur
Pathologie et microbiologie, Faculté de
médecine vétérinaire, Université de
Montréal, St. Hyacinthe, Québec, Canada

Guy Meulemans

Avian virology & immunology unit
Veterinary and agrochemical research
center, Bruxelles, Belgique

Andrea M Miles

Veterinarian
Wilmington, North Carolina, USA

Hervé Morin

Docteur vétérinaire
Groupe Grimaud, La Corbière
Roussay, France

Nguyen Thi Phuoc Ninh

Professeur
Poultry diseases
Tu-Duc University, Vietnam

LK Nolan

Professor
College of veterinary medicine
Iowa state university, Ames, Iowa, USA

Robert L Owen

Director of Veterinary Services
Best Veterinary Solutions
New Oxford, PA, USA

Jean-Paul Picault

Microbiologiste
Agence nationale de sécurité sanitaire,
de l'alimentation, de l'environnement
et du travail (ANSES), Ploufragan,
France

L Pfeleiderer

Faculté de médecine vétérinaire
Université de Montréal
St. Hyacinthe, Québec, Canada

Manon Racicot

Épidémiologiste vétérinaire
Agence canadienne d'inspection des
aliments
St-Hyacinthe, Québec Canada

F Rauw

Bio-Engineer
Brussels, Belgium
Veterinary and agrochemical research
center, Bruxelles, Belgique

Thomas Redmann

Veterinarian
Clinic for birds, reptiles, amphibians
and fish
Justus Liebig University Giessen
Giessen, Germany

Jean-Michel Réperant

Docteur en parasitologie
Agence nationale de sécurité sanitaire,
de l'alimentation, de l'environnement
et du travail (ANSES),
Ploufragan, France

Jacques Roberton

Docteur Vétérinaire
Cabinet vétérinaire La Chesnaie
Tours, France

Brice Robineau

Docteur Vétérinaire
FINALAB, Chateaubourg, France

Yves Robinson

Pathologiste vétérinaire
Agence Canadienne d'inspection des
aliments (ACIA)
St-Hyacinthe, Québec, Canada

Stacey L. Schultz-Cherry

Researcher
Department of infectious diseases
St. Jude children's research hospital
Memphis, Tennessee, USA

H L Shivaprasad

Professor
California animal health and food safety
laboratory system, tulare branch,
University of California-Davis, USA

Amer Silim

Professeur honoraire
Faculté de médecine vétérinaire
Université de Montréal
St. Hyacinthe, Québec, Canada

Dale Smith

Professor
Department of Pathobiology, Ontario
Veterinary College, University of
Guelph, Guelph, Ontario, Canada

John S Smith

Director of Health Services
Fieldale Farms Corporation
Athens, Georgia, USA

David Suarez

Research leader
US Department of Agriculture,
Athens, Georgia, USA

Didier Toquin

Agence nationale de sécurité sani-
taire, de l'alimentation, de l'enviro-
nement et du travail (ANSES),
Ploufragan, France

Deoki N Tripathy

Professor emeritus
Department of pathobiology, College
of veterinary medicine, University of
Illinois, Urbana, Illinois, USA

Jean-Pierre Vaillancourt

Professeur
Département de sciences cliniques
Faculté de médecine vétérinaire
Université de Montréal
St. Hyacinthe, Québec, Canada

Thierry Van den Berg

Operational Director Viral Diseases
Veterinary and agrochemical research
center,
Bruxelles, Belgique

Louis Van der Heide (†)

Professor
University of Connecticut
Storrs, Connecticut, USA

Daniel Venne

Docteur vétérinaire
Couvoir Scott Ltée,
Québec, Canada

Alain Villeneuve

Professeur
Pathologie et microbiologie
Faculté de médecine vétérinaire
Université de Montréal
St. Hyacinthe, Québec, Canada

Henri Vindevogel

Professeur honoraire
Clinique Aviaire
Faculté de médecine vétérinaire
Université of Liège, Liège, Belgique

Susan E Watkins

Professor
Center of excellence for poultry science
University of Arkansas
Fayetteville, Arkansas, USA

Guo Yupu

Professor
College of Animal Health,
China Agricultural University
Beijing, China
郭玉璞
教授
中国农业大学动物医学院
中国北京

Dabing Zhang

College of Animal Health
China Agricultural University
Beijing, China
张大丙
教授
中国农业大学动物医学院
中国北京

Guillermo Zavala

Director of veterinary services
Avian health international LLC
Flowery Branch, GA, USA

Lionel Zenner

Professeur
Parasitologie
Vetagro-Sup,
Campus vétérinaire de Lyon,
Marcy L'Étoile, France

CONTENTS

Prefaces	v	SECTION II. VIRAL DISEASES	
Foreword	ix	18 Avian influenza virus	136
Authors	xi	<i>D Suarez</i>	
SECTION I. GENERALITIES		19 Newcastle disease & other avian paramyxoviruses	144
1 Poultry production in the world	2	<i>G Meulemans, F Rauw & Th Van der berg</i>	
<i>JP Vaillancourt</i>		20 Avian metapneumovirus	156
2 Chicken production	8	<i>N Eterradossi, D Toquin, JP Picault & V Jestin</i>	
<i>MP Martin</i>		21 Infectious bronchitis	164
3 Chick quality	16	<i>E Kaleta & T Redmann</i>	
<i>R Meijerhof</i>		22 Infectious laryngotracheitis	172
4 Commercial table egg production	24	<i>D Davison</i>	
<i>E Gingerich</i>		23 Avian encephalomyelitis	176
5 Egg quality	32	<i>HL Shivaprasad</i>	
<i>R Meijerhof</i>		24 Aviadenovirus (inclusion body hepatitis)	178
6 Turkey production	40	<i>ME Eregae, JP Vaillancourt & J Brugère-Picoux</i>	
<i>DK Carver</i>		25 Siadenovirus (hemorrhagic enteritis)	184
7 Breeding in hot climate	44	<i>ME Eregae, JP Vaillancourt & J Brugère-Picoux</i>	
<i>M Bouzouaia</i>		26 Atadenovirus (egg drop syndrome)	186
8 Poultry droppings & manure	54	<i>ME Eregae, JP Vaillancourt & J Brugère-Picoux</i>	
<i>M Bouzouaia & C Aubert</i>		27 Reovirus infections	188
9 Poultry welfare	60	<i>L Van der Heide (†) & JP Vaillancourt</i>	
<i>K Barger</i>		28 Other viral enteric infections	194
10 Peculiarities of avian physiology	70	<i>L Pfeiderer & JP Vaillancourt</i>	
<i>H Brugère</i>		29 Astrovirus infections	200
11 Blood biochemistry in birds	80	<i>SL Schultz-Cherry & JP Vaillancourt</i>	
<i>Y Chorfi & D Venne</i>		30 Chicken infectious anemia	204
12 Avian hematology	86	<i>C Cardona & HL Shivaprasad</i>	
<i>L Lopez</i>		31 Fowlpox	208
13 Epidemiologic concepts & analysis of field studies in poultry	90	<i>D Tripathy</i>	
<i>JP Vaillancourt</i>		32 Infectious bursal disease	214
14 Avian immunology	102	<i>DJ Jackwood</i>	
<i>A Silim & H Abbassi</i>		33 Marek's disease	220
15 Avian anatomy	110	<i>A Miles</i>	
<i>C Degueurce, J Brugère-Picoux & E Chatelain (†)</i>		34 Avian leukosis	226
16 Avian necropsy	120	<i>G Zavala</i>	
<i>S Chénier</i>		35 Reticuloendotheliosis & lymphoproliferative disease	236
17 Diagnostic laboratory	126	<i>P Vaillancourt & OJ Fletcher</i>	
<i>R Crespo</i>		36 Turkey coronavirus	242
		<i>JS Guy & JP Vaillancourt</i>	

37 Arbovirus infections <i>C Banet-Noach</i>	248	57 Staphylococcosis <i>HL Shivaprasad</i>	374
38 Hepatitis-splenomegaly syndrome <i>HL Shivaprasad</i>	254	58 <i>Brachyspira</i> spp. (avian intestinal spirochetosis) <i>B. Robineau</i>	376
39 Other viral infections <i>HL Shivaprasad & J Brugère-Picoux</i>	256	59 Yersiniosis <i>HL Shivaprasad</i>	380
SECTION III. BACTERIAL DISEASES		60 Pseudomoniasis <i>HL Shivaprasad</i>	382
40 Avian chlamydiosis <i>HL Shivaprasad</i>	272	61 Other bacterial diseases <i>J Brugère-Picoux</i>	384
41 Avian mycoplasmosis <i>I Kempf</i>	278	SECTION IV. OTHER DISEASES	
42 Pullorum disease & fowl typhoid <i>HL Shivaprasad</i>	286	62 Fungal diseases <i>KT Adjou & J Brugère-Picoux</i>	390
43 Paratyphoid salmonella <i>RL Owen</i>	292	63 Mycotoxicosis <i>J Le Bars & JD Bailly</i>	398
44 Arizonosis <i>HL Shivaprasad</i>	298	64 Coccidiosis <i>V Guyonnet</i>	408
45 Colibacillosis <i>LK Nolan, HJ Barnes, TA Abdul-Aziz, CM Logue & JP Vaillancourt</i>	300	65 Cryptosporidiosis <i>H Abbassi & JM Réperant</i>	418
46 Fowl cholera <i>JP Christensen & M Bisgaard</i>	316	66 Histomoniasis <i>MP Callait-Cardinal & L Zenner</i>	424
47 Infectious coryza & related diseases <i>PJ Blackall & X Chen</i>	326	67 Internal parasites <i>A Villeneuve & J Brugère-Picoux</i>	428
48 <i>Ornithobacterium rhinotracheale</i> <i>HM Hafez</i>	332	68 External parasites & poultry pests <i>A Villeneuve & J Brugère-Picoux</i>	440
49 <i>Riemerella anatipestifer</i> infection <i>D Tripathy</i>	336	69 Diseases of the musculoskeletal systems <i>MT Casaubon Huguenin & J Brugère-Picoux</i>	448
50 Bordetellosis <i>D Venne & J Brugère-Picoux</i>	338	70 Cardiovascular diseases <i>HL Shivaprasad</i>	460
51 Clostridial diseases <i>JS Smith</i>	342	71 Nutritional diseases <i>Y Chorfi, J Brugère-Picoux & D Venne</i>	470
52 Laboratory diagnosis of botulism <i>S Maeder & R Danguy-des-Déserts</i>	352	72 Poults enteritis mortality syndrome <i>JP Vaillancourt, DK Carver, JS Guy & JH Barnes</i>	484
53 <i>Campylobacter</i> spp. <i>DK Carver</i>	356	73 Hypoglycemia - spiking mortality <i>JF Davis</i>	492
54 Avian tuberculosis <i>MT Casaubon Huguenin & J Brugère-Picoux</i>	360	74 Environment & pathology <i>M Bouzouaia, J Brugère-Picoux & D Venne</i>	496
55 Erysipelas <i>J Brugère-Picoux</i>	364	SECTION V. HEALTH MEASURES	
56 Streptococci & enterococci <i>D Balloy</i>	368	75 Slaughterhouse condemnations <i>G Bénard, M. Racicot & Y. Robinson</i>	508

76 Toxi-infections <i>S Messier</i>	526	95 Guinea fowl production & diseases <i>J Roberton, B Robineau & N Doublet</i>	624
77 Pharmacological considerations <i>A Anadón & H Brugère</i>	530	96 Diseases of quail <i>P Dunn</i>	630
78 Antimicrobial treatments <i>S Clark, A Anadón & JP Vaillancourt</i>	536	97 Pheasant production & diseases <i>X Chatenet</i>	636
79 Toxicology and residues in poultry <i>A Anadón & MR Martínez Larrañaga</i>	542	98 Diseases of partridge <i>X Chatenet</i>	640
80 Biosecurity & poultry production <i>M Racicot & JP Vaillancourt</i>	552	99 Diseases of pigeon <i>D Marlier & H Vindevogel</i>	642
81 Understanding and optimizing water quality for poultry <i>SE Watkins</i>	562	100 Breeding & diseases of ratites <i>D Smith</i>	650
82 Vaccination techniques <i>S Lemièrè & C Fritts</i>	572	SECTION VII. DIFFERENTIAL DIAGNOSIS	
83 Avian zoonoses <i>J Brugère-Picoux & JP Vaillancourt</i>	576	101 Digestive system <i>N Alloui, M Bouzouaia & J Brugère-Picoux</i>	662
SECTION VI. OTHER SPECIES		102 Liver diseases <i>J Brugère-Picoux & M Bouzouaia</i>	666
84 Duck production <i>H Morin</i>	584	103 Respiratory diseases <i>M EL Houadfi & M Bouzouaia</i>	670
85 Duck reovirus <i>D Fournier & S Lemièrè</i>	588	104 Cardiovascular diseases <i>HL Shivaprasad, J Brugère-Picoux & M Bouzouaia</i>	674
86 Duck parvovirus <i>S Lemièrè & D Fournier</i>	592	105 Hematopoietic system <i>D Venne, M Bouzouaia & J Brugère-Picoux</i>	676
87 Derzsy's disease (short-beak and dwarfism syndrome in mule ducks) <i>S Lemièrè & D Fournier</i>	596	106 Muscular diseases <i>FJ Hoerr</i>	678
88 Hemorrhagic nephritis enteritis of geese <i>JL Guérin</i>	600	107 Locomotor disorders <i>J Brugère-Picoux & M Bouzouaia</i>	682
89 Duck virus enteritis <i>Nguyen Thi Phuoc Ninh</i>	602	108 Nervous & ocular diseases <i>J Brugère-Picoux, M Bouzouaia & JP Vaillancourt</i>	684
90 Duck hepatitis <i>G Yupu</i>	606	109 Sudden deaths <i>M Bouzouaia, JP Vaillancourt & J Brugère-Picoux</i>	686
91 Duck & goose circovirus infections <i>S Lemièrè</i>	610	110 Reproductive system <i>A. Mercier, S Lemièrè & J Brugère-Picoux</i>	688
92 Tembusu virus infection of ducks <i>D Zhang</i>	612	111 Urinary disorders <i>M EL Houadfi, M Bouzouaia & J Brugère-Picoux</i>	692
93 Bacterial diseases of ducks <i>JY Jouglar</i>	616	112 Skin & feather diseases <i>N Alloui, M Bouzouaia & J Brugère-Picoux</i>	694
94 Waterfowl parasitoses <i>H Banon & L Zenner</i>	622	113 Avian droppings <i>D Venne, M Magnin & J Brugère-Picoux</i>	698

Manual of POULTRY DISEASES

"Poultry is the predominant type of animal production in both developed and developing countries. While poultry production has expanded significantly in recent decades, particularly in Asia, since late 2003 growth has been curbed worldwide by the spread of avian influenza.

Poultry production is critical to the economy and food security of many developing countries because not only is poultry easy to farm and well suited to backyard production, in many cases it is a staple food. This richly illustrated manual of poultry diseases is a key reference work that reviews poultry production systems across the globe, describing the range of diseases affecting all domesticated bird species, and contains a section on differential diagnosis to aid in detecting and recognising specific diseases."



Doctor Bernard Vallat
Director General of the World Organisation for Animal Health (OIE)



Université 
de Montréal



AFAS